

COLUMBIA LIBRARIES OFFSITE  
HEALTH SCIENCES STANDARD




HX64139549

RC941 .C89

Embryology, anatomy,

**RECAP**



THE LIBRARIES  
COLUMBIA UNIVERSITY



HEALTH SCIENCES  
LIBRARY





Digitized by the Internet Archive  
in 2010 with funding from  
Open Knowledge Commons

<http://www.archive.org/details/embryologyanatom00cull>



OTHER BOOKS  
BY  
**THOMAS S. CULLEN**

---

**Cancer of the Uterus.** Large octavo of 693 pages, with 310 colored and half-tone text-cuts and 11 lithographs in colors. Cloth, \$7.50 net; Half Morocco, \$8.50 net.

**Adenomyoma of the Uterus.** Large octavo of 270 pages, illustrated. Cloth, \$5.00 net; Half Morocco, \$6.50 net.

WITH HOWARD A. KELLY

**Myomata of the Uterus.** Large octavo of 723 pages, with 388 illustrations, 19 in colors. Cloth, \$7.50 net; Half Morocco, \$9.00 net.



# EMBRYOLOGY, ANATOMY, AND DISEASES

*OF THE*

# UMBILICUS

*TOGETHER WITH*

# DISEASES OF THE URACHUS

*BY*

THOMAS STEPHEN CULLEN

Associate Professor of Gynecology in the Johns Hopkins University  
Assistant Visiting Gynecologist to the Johns Hopkins Hospital

ILLUSTRATED

*BY*

MAX BRÖDEL

*PHILADELPHIA AND LONDON*

W. B. SAUNDERS COMPANY

1916

---

Copyright, 1916, by W. B. Saunders Company

---

To My Mother

MARY CULLEN

Daughter of the late Rev. Thomas and Mary Greene

Born on July 12, 1841, at Polminick, near

Penzance, Cornwall, England

THIS BOOK

is affectionately dedicated





## PREFACE

DURING the summer of 1904 I saw a case of cancer of the umbilicus with Dr. Jacob L. Winner. Up to that time I had thought that hernia was practically the only lesion to be noted in this locality. The patient did well for a time, but later large intra-abdominal tumors could be felt and finally he died. No autopsy was obtained. Histologic examination of the umbilical growth showed that it was an adenocarcinoma.

I was at a loss to explain the presence of glands in this position, and a cursory examination of the text-books failed to elucidate the matter. I could not rid myself of the desire to find out definitely just how an adenocarcinoma could exist in the umbilicus, and several years later, when other and more pressing problems had been completed, I carefully searched the literature for cases of cancer of the umbilicus and was amazed to find the records of many instances.

In the majority of the cases the umbilical growth was secondary to a cancer of the stomach, gall-bladder, intestine, or ovary. Cases of primary adenocarcinoma and of squamous-cell carcinoma of the umbilicus occur, but they are very rare.

During this study I encountered a wealth of material dealing with the omphalomesenteric duct. We have long been familiar with Meckel's diverticulum, but two facts, that the omphalomesenteric duct may be patent throughout its entire extent at birth, and that remnants of the outer end of the duct may give rise to the small umbilical polyps sometimes noted after the cord drops off, have not been commonly appreciated.

The literature is rich in records of devastating infections that prevailed before the era of asepsis. These occurred generally in hospitals, and most often when an epidemic of puerperal sepsis was rampant among the mothers. The descriptions of some of them are intensely graphic, and from the detailed reports of the individual cases one can obtain a wonderful picture of the terminal infections occurring in these infants.

I found a somewhat extensive literature on dermoids of the umbilicus, but on analyzing the cases was obliged to conclude that the majority of these growths represented nothing more than inflammations due to irritation exerted by an umbilical concretion. It was the presence of caseous material and the admixture of wool from the patient's clothing that had led to the erroneous diagnosis.

I found records of cases of Paget's disease, diphtheria, and syphilis of the umbilicus. There is also an extensive literature on the escape of intra- and extra-abdominal fluid, usually pus, through the umbilicus, and many cases of umbilical fistula are recorded.

Many umbilical tumors have been reported, some benign, others malignant. I was especially interested in one group of cases. These tumors were small; they always occurred in women; they tended to swell at the menstrual period, and some

urachus have been collected, the cases classified, and the appropriate methods of treatment outlined. I trust that this work may help the general practitioner, the pediatrician, and the surgeon to treat more satisfactorily lesions of this heretofore relatively unknown region, unknown, although up to the day of birth it is on the main highway between the mother and the child.

THE JOHNS HOPKINS HOSPITAL, *May*, 1916.

THOMAS S. CULLEN.

## CONTENTS

CHAPTER	PAGE
I. EMBRYOLOGY OF THE UMBILICAL REGION.....	1
II. ANATOMY OF THE UMBILICAL REGION.....	34
III. UMBILICAL INFECTIONS IN THE NEW-BORN.....	70
IV. UMBILICAL HEMORRHAGE.....	106
V. GRANULATION TISSUE OR GRANULOMA OF THE UMBILICUS.....	116
VI. REMNANTS OF THE OMPHALOMESENTERIC DUCT.....	118
VII. CONGENITAL POLYPS; FISTULE OR CYSTIC DILATATIONS AT THE UMBILICUS; WITH A MUCOSA MORE OR LESS SIMILAR TO THAT OF THE PYLORIC REGION OF THE STOMACH, AND SECRETING AN IRRITATING FLUID BEARING A MARKED RE- SEMBLANCE TO GASTRIC JUICE. PERSISTENCE OF THE OUTER PORTION OF THE OMPHALOMESENTERIC DUCT.....	144
VIII. MECKEL'S DIVERTICULUM.....	159
IX. INTESTINAL CYSTS.....	174
X. A PATENT OMPHALOMESENTERIC DUCT.....	188
XI. THE PATENT OMPHALOMESENTERIC DUCT (Continued).....	214
XII. PROLAPSUS OF THE BOWEL THROUGH A PATENT OMPHALOMESENTERIC DUCT.....	222
XIII. CYSTS IN THE ABDOMINAL WALL DUE TO REMNANTS OF THE OMPHALOMESENTERIC DUCT.....	238
XIV. PERSISTENCE OF THE OMPHALOMESENTERIC VESSELS.....	242
XV. UMBILICAL CONCRETIONS ASSOCIATED WITH INFLAMMATORY CHANGES IN THE AB- DOMINAL WALL.....	247
XVI. ABSCESS IN THE SUBUMBILICAL SPACE.....	262
XVII. PAGET'S DISEASE OF THE UMBILICUS.....	268
XVIII. DIPHThERIA OF THE UMBILICUS. SYPHILIS OF THE UMBILICUS; TUBERCULOSIS OF THE UMBILICUS; ATROPHIC TUBERCULID COMMENCING AT THE UMBILICUS ..	277
XIX. THE ESCAPE OF RETROPERITONEAL AND ABDOMINAL FLUID FROM THE UMBILICUS; THE OPENING OF AN APPENDIX ABSCESS AT THE UMBILICUS. ABSCESS OF THE LIVER OPENING AT THE UMBILICUS; PERITONITIS WITH THE ESCAPE OF Pus FROM THE UMBILICUS; THE PIECEMEAL REMOVAL OF A SUPPURATING OVARIAN CYST THROUGH THE UMBILICUS.....	287
XX. FECAL FISTULE AT THE UMBILICUS.....	309
XXI. THE ESCAPE OF ROUND WORMS FROM THE UMBILICUS.....	328
XXII. THE ESCAPE OF VARIOUS FOREIGN SUBSTANCES FROM THE UMBILICUS.....	337
XXIII. UMBILICAL TUMORS.....	351
XXIV. ADENOMYOMA OF THE UMBILICUS.....	373
XXV. CARCINOMA OF THE UMBILICUS.....	400
XXVI. SARCOMA OF THE UMBILICUS.....	449
XXVII. UMBILICAL HERNIA.....	459
XXVIII. THE URACHUS.....	481
XXIX. CONGENITAL PATENT URACHUS.....	487
XXX. REMNANTS OF THE URACHUS.....	515
XXXI. URACHAL REMNANTS PRODUCING TUMORS BETWEEN THE UMBILICUS AND SYMPHY- SIS.....	526

CHAPTER	PAGE
XXXII. LARGE URACHAL CYSTS . . . . .	539
XXXIII. ABSCESSSES IN THE ANTERIOR ABDOMINAL WALL BETWEEN THE UMBILICUS AND SYMPHYSIS DUE TO INFECTION OF URACHAL REMAINS OR OF URACHAL CYSTS . . .	567
XXXIV. URACHAL CAVITIES BETWEEN THE SYMPHYSIS AND UMBILICUS COMMUNICATING WITH THE BLADDER OR UMBILICUS OR WITH BOTH . . . . .	578
XXXV. ACQUIRED URINARY FISTULA AT THE UMBILICUS . . . . .	607
XXXVI. URACHAL CONCRETIONS AND URINARY CALCULI ASSOCIATED WITH URACHAL REMAINS . . . . .	620
XXXVII. MALIGNANT CHANGES IN THE URACHUS . . . . .	628
XXXVIII. BLEEDING FROM THE URACHUS INTO THE BLADDER . . . . .	647
XXXIX. TUBERCULOSIS OF THE PATENT URACHUS . . . . .	649
—————	
INDEX OF NAMES . . . . .	655
INDEX . . . . .	667



## LIST OF ILLUSTRATIONS

Fig.	Page
1. SAGITTAL SECTION SHOWING A VERY EARLY STAGE IN THE FORMATION OF THE UMBILICUS AND ALLANTOIS . . . . .	2
2. A MORE ADVANCED STAGE IN THE FORMATION OF THE UMBILICAL REGION . . . . .	2
3. A COMPOSITE PICTURE SHOWING THE FORMATION OF THE UMBILICUS IN AN EMBRYO . . . . .	3
4. A DIAGRAMMATIC REPRESENTATION OF A HUMAN EMBRYO, ABOUT 3.5 MM. LONG, SHOWING THE EFFECT OF THE EXPANDING AMNION UPON THE YOLK-SAC AND BODY-STALK . . . . .	4
5. SAGITTAL VIEW OF A HUMAN EMBRYO 5 MM. IN LENGTH . . . . .	5
6. ANTERIOR VIEW AND TRANSVERSE SECTION OF A HUMAN EMBRYO 7 MM. LONG, SHOWING THE UMBILICAL REGION . . . . .	6
7. SAGITTAL SECTION OF THE UMBILICAL REGION IN AN EMBRYO 7 MM. IN LENGTH . . . . .	7
8. SAGITTAL VIEW OF THE UMBILICAL REGION OF A HUMAN EMBRYO 10 MM. IN LENGTH . . . . .	8
9. GRAPHIC RECONSTRUCTION OF THE UMBILICAL CORD OF A HUMAN EMBRYO 12.5 MM. IN LENGTH . . . . .	9
10. ANTERIOR VIEW OF THE UMBILICAL CORD OF A HUMAN EMBRYO 18 MM. IN LENGTH . . . . .	10
11. SAGITTAL SECTION OF THE UMBILICAL REGION IN A HUMAN EMBRYO 23 MM. IN LENGTH . . . . .	11
12. A GRAPHIC RECONSTRUCTION OF THE UMBILICAL REGION OF A HUMAN EMBRYO 3 CM. LONG . . . . .	12
13. SAGITTAL SECTION OF THE UMBILICAL REGION IN A HUMAN EMBRYO 4.5 CM. IN LENGTH . . . . .	13
14. A GRAPHIC RECONSTRUCTION OF THE UMBILICAL REGION OF A HUMAN EMBRYO 4.5 CM. IN LENGTH AS VIEWED FROM WITHIN THE ABDOMEN . . . . .	14
15. SAGITTAL VIEW OF A GRAPHIC RECONSTRUCTION OF THE UMBILICAL REGION OF A HUMAN EMBRYO 5.2 CM. IN LENGTH . . . . .	15
16. INTRA-ABDOMINAL VIEW OF THE UMBILICAL REGION OF A HUMAN EMBRYO 6.5 CM. IN LENGTH . . . . .	17
17. INTRA-ABDOMINAL VIEW OF THE UMBILICAL REGION IN A HUMAN EMBRYO 7.5 CM. LONG . . . . .	18
18. INTRA-ABDOMINAL VIEW OF THE UMBILICAL REGION IN A HUMAN EMBRYO 9 CM. IN LENGTH . . . . .	18
19. INTRA-ABDOMINAL VIEW OF THE UMBILICAL REGION IN A HUMAN EMBRYO 10 CM. IN LENGTH . . . . .	19
20. INTRA-ABDOMINAL VIEW OF THE UMBILICAL REGION IN A HUMAN EMBRYO 12 CM. LONG . . . . .	19
21. INTRA-ABDOMINAL VIEW OF THE UMBILICAL REGION IN A HUMAN EMBRYO 12 CM. IN LENGTH . . . . .	20
22. INTRA-ABDOMINAL VIEW OF THE UMBILICAL REGION IN A HUMAN EMBRYO 12 CM. IN LENGTH . . . . .	21
23. CROSS-SECTION OF THE UMBILICAL CORD AT THE UMBILICUS IN A HUMAN EMBRYO 12 CM. IN LENGTH . . . . .	22
24. INTERNAL VIEW OF THE UMBILICAL REGION IN A HUMAN EMBRYO 15 CM. LONG . . . . .	23
25. A COMPOSITE REPRESENTATION OF ABNORMAL UMBILICAL STRUCTURES, BASED ON THE WORK OF KEIBEL, LÖWY, AND OTHERS . . . . .	24
26. A COMPOSITE REPRESENTATION OF ABNORMAL UMBILICAL STRUCTURES, BASED ON THE WORK OF KEIBEL, LÖWY, AND OTHERS . . . . .	24
27. A COMPOSITE REPRESENTATION OF ABNORMAL UMBILICAL STRUCTURES, BASED ON THE WORK OF KEIBEL, LÖWY, AND OTHERS . . . . .	24
28. THE UMBILICAL REGION IN A FETUS ABOUT FIVE MONTHS OLD VIEWED FROM THE LEFT . . . . .	25
29. SIDE AND POSTERIOR VIEWS OF THE UMBILICAL REGION IN A FETUS OF SIX TO SEVEN MONTHS . . . . .	25
30. THREE DIAGRAMS OF THE UMBILICAL RING AND ITS SIGNIFICANCE IN THE DEVELOPMENT OF VENTRAL HERNIA . . . . .	27

FIG.	PAGE
31. THE APPEARANCE OF THE YOLK-SAC (UMBILICAL VESICLE) IN A PREGNANCY, WITH THE EMBRYO 5.5 CM. LONG . . . . .	28
32. THE UMBILICAL REGION, THE CORD, AND THE PLACENTA AT TERM . . . . .	29
33. A DIAGRAMMATIC REPRESENTATION OF THE UMBILICAL REGION OF A FETUS AT TERM . . . . .	32
34. NORMAL UMBILICUS ACCORDING TO CATTEAU . . . . .	35
35. A TYPE OF UMBILICAL REGION IN THE ADULT, VIEWED FROM WITHIN . . . . .	44
36. A FREQUENT TYPE OF THE UMBILICAL REGION IN THE ADULT, VIEWED FROM WITHIN . . . . .	44
37. THE UMBILICAL REGION OF AN ADULT, VIEWED FROM WITHIN . . . . .	45
38. CLASSIC TYPE OF UMBILICUS . . . . .	47
39. DISPOSITION OF THE VASCULAR CORDS (USUAL TYPE) . . . . .	48
40. VASCULAR CORDS OF THE ANASTOMOSING TYPE, NOTED 7 TIMES IN 50 CASES . . . . .	48
41. VASCULAR CORD TYPE, NOTED 5 TIMES IN 50 CASES . . . . .	49
42. VASCULAR CORDS, NOTED 5 TIMES IN 50 CASES, COMPLETELY FILLING THE UMBILICAL RING . . . . .	49
43. VASCULAR CORDS, NOTED 3 TIMES IN 50 CASES . . . . .	49
44. VASCULAR CORDS, NOTED IN 2 OUT OF 50 CASES . . . . .	50
45. UMBILICAL FASCIA. PERITONEUM IN PLACE . . . . .	52
46. UMBILICAL FASCIA AND UMBILICAL MESENTERY . . . . .	52
47. REDUPLICATION OF THE LINEA ALBA. PERITONEUM REMOVED . . . . .	52
48. ATROPHY OF THE UMBILICAL FASCIA, POSTERIOR VIEW . . . . .	53
49. FORMATION OF A MESENTERY. PERITONEUM IN PLACE . . . . .	53
50. MESENTERY OF THE URACHUS AND OF THE UMBILICAL ARTERIES . . . . .	53
51. ADIPOSE FRINGES. FROM A WELL-DEVELOPED YOUNG WOMAN. PERITONEUM IN PLACE . . . . .	54
52. ADIPOSE FRINGES IN A STOUT SUBJECT. PERITONEUM IN PLACE . . . . .	54
53. PERITONEAL DIVERTICULA. PERITONEUM IN PLACE . . . . .	55
54. PERI-UMBILICAL FOSSETTES. PERITONEUM IN PLACE . . . . .	55
55. OVARIAN PEDICLE PASSING FROM UTERUS OUT THROUGH A HERNIAL RING IN THE ABDOMINAL WALL . . . . .	57
56. EXTRA-ABDOMINAL MULTILOCULAR FIBROCYSTOMA OF THE OVARY . . . . .	58
57. AN EXTRA-ABDOMINAL MULTILOCULAR FIBROCYSTOMA . . . . .	59
58. SUPERFICIAL LYMPHATICS OF THE UMBILICAL REGION . . . . .	64
59. THE DEEP UMBILICAL LYMPHATICS AS SEEN FROM THE PERITONEAL SIDE . . . . .	65
60. THE UMBILICAL VESSELS ABOUT THE TIME OF BIRTH . . . . .	72
61. THE UMBILICAL VESSELS IN THE ADULT . . . . .	72
62, 63. METHOD OF TREATING THE UMBILICAL STUMP AT BIRTH . . . . .	98
64. NATURE'S METHOD OF CHECKING BLEEDING FROM THE UMBILICAL ARTERIES . . . . .	107
65. AN UMBILICAL GRANULATION . . . . .	117
66. THE GRADUAL ATROPHY OF THE OMPHALOMESENTERIC DUCT . . . . .	121
67. AN UMBILICAL POLYP CONNECTED WITH MECKEL'S DIVERTICULUM BY A FIBROUS CORD . . . . .	121
68. AN UMBILICAL POLYP ATTACHED TO THE SMALL BOWEL BY A FIBROUS CORD . . . . .	121
69. AN UMBILICAL POLYP ON THE PROMINENT PART OF AN UMBILICAL HERNIA . . . . .	123
70. A POLYPOID OUTGROWTH FROM THE UMBILICUS . . . . .	129
71. TUBULAR GLANDS FROM THE UMBILICAL POLYP SHOWN IN FIG. 70 . . . . .	129
72. A DIVERTICULAR TUMOR AT THE UMBILICUS . . . . .	132
73. A GLANDULAR TUMOR FROM THE UMBILICUS . . . . .	132
74. A GLANDULAR GROWTH AT THE UMBILICUS . . . . .	133
75. SECTION IN THE LONG AXIS OF A SMALL UMBILICAL GROWTH . . . . .	134
76. ADENOMA OF THE UMBILICUS . . . . .	135
77. AN UMBILICAL POLYP ATTACHED TO A MECKEL'S DIVERTICULUM BY A FIBROUS CORD . . . . .	138
78. AN UMBILICAL POLYP ATTACHED TO A MECKEL'S DIVERTICULUM BY A FIBROUS CORD . . . . .	138
79. AN UMBILICAL POLYP . . . . .	139
80. A SMALL INTESTINAL POLYP ALMOST FILLING THE UMBILICAL DEPRESSION . . . . .	139
81. AN UMBILICAL POLYP . . . . .	140
82. PORTION OF AN INTESTINAL POLYP PARTIALLY FILLING THE UMBILICAL DEPRESSION . . . . .	141
83. TRANSVERSE SECTION OF A PSEUDOPYLORIC CONGENITAL FISTULA AT THE UMBILICUS . . . . .	149

Fig.	PAGE
84. HIGH-POWER PICTURE OF A FISTULOUS TRACT AT THE UMBILICUS, SHOWING GLANDS RESEMBLING THOSE OF THE PYLORUS. . . . .	150
85. AN UMBILICAL FISTULA LINED WITH MUCOSA RESEMBLING THAT OF THE STOMACH . . . . .	150
86. APPEARANCE OF THE UMBILICAL DEPRESSION IN VON ROSTHORN'S CASE . . . . .	152
87. GASTRIC MUCOSA AT THE UMBILICUS. . . . .	153
88. APPEARANCE OF THE UMBILICUS AFTER REMOVAL OF THE STOMACH MUCOSA SEEN IN FIG. 87. . . . .	154
89. PERSISTENCE OF THE OUTER END OF THE OMPHALOMESENTERIC DUCT . . . . .	156
90. ATROPHY OF THE INNER END OF THE OMPHALOMESENTERIC DUCT. . . . .	156
91. A LONG UMBILICAL POLYP AS A REMNANT OF THE OMPHALOMESENTERIC DUCT . . . . .	156
92. MECKEL'S DIVERTICULUM. . . . .	159
93. A MECKEL'S DIVERTICULUM ATTACHED TO THE ABDOMINAL WALL AT THE UMBILICUS. . . . .	160
94. AN ABNORMALLY LARGE MECKEL'S DIVERTICULUM . . . . .	161
95. A MECKEL'S DIVERTICULUM WITH A LOBULATED EXTREMITY. . . . .	161
96. A MECKEL'S DIVERTICULUM WITH HERNIAL PROTRUSIONS FROM ITS SURFACE . . . . .	162
97. A SHORT MECKEL'S DIVERTICULUM SPRINGING FROM THE MESENTERIC ATTACHMENT . . . . .	163
98. AN ACCESSORY PANCREAS IN THE TIP OF MECKEL'S DIVERTICULUM . . . . .	163
99. A MECKEL'S DIVERTICULUM COMPLETELY TYING OFF A LOOP OF SMALL BOWEL. . . . .	164
100. A DIVERTICULUM TYING OFF A LOOP OF SMALL BOWEL. . . . .	165
101. STRANGULATION OF A MECKEL'S DIVERTICULUM CAUSING VOLVULUS OF THE ILEUM. . . . .	166
102. FATAL INTESTINAL OBSTRUCTION DUE TO THE PASSAGE OF THE BOWEL THROUGH A HOLE IN THE MESENTERY OF A MECKEL'S DIVERTICULUM. . . . .	170
103. INVERSION OF A MECKEL'S DIVERTICULUM INTO THE LUMEN OF THE BOWEL . . . . .	171
104. A WELL-DEVELOPED LOOP OF SMALL BOWEL IN A DERMOID CYST OF THE OVARY. . . . .	175
105. AN INTESTINAL CYST. . . . .	176
106. AN INTESTINAL CYST ATTACHED TO THE UMBILICUS BY A PEDICLE BUT NOT CONNECTED WITH THE BOWEL. . . . .	176
107. VOLVULUS OF MECKEL'S DIVERTICULUM. . . . .	177
108. AN INTESTINAL CYST DEVELOPING FROM MECKEL'S DIVERTICULUM. . . . .	178
109. INTESTINAL CYSTS IN THE ABDOMINAL CAVITY. . . . .	182
110. AN INTRAMESENTERIC CYST. . . . .	183
111. A PATENT OMPHALOMESENTERIC DUCT. . . . .	190
112. A PATENT OMPHALOMESENTERIC DUCT WITH A POLYPOID FORMATION AT THE UMBILICUS . . . . .	190
113. A VERY SHORT OMPHALOMESENTERIC DUCT. . . . .	190
114. A PATENT OMPHALOMESENTERIC DUCT WITH A POLYP-LIKE FORMATION AT THE UMBILICUS. . . . .	190
115. A PATENT OMPHALOMESENTERIC DUCT. . . . .	192
116. A PATENT OMPHALOMESENTERIC DUCT. . . . .	193
117. A PATENT OMPHALOMESENTERIC DUCT. . . . .	197
118. A PATENT OMPHALOMESENTERIC DUCT. . . . .	197
119. A PATENT OMPHALOMESENTERIC DUCT. . . . .	202
120. A PATENT OMPHALOMESENTERIC DUCT. . . . .	205
121. A PATENT OMPHALOMESENTERIC DUCT. . . . .	206
122. PART OF A PATENT OMPHALOMESENTERIC DUCT. . . . .	206
123. INTESTINAL MUCOSA COVERING THE CUTANEOUS OR UMBILICAL END OF A PATENT OMPHALOMESENTERIC DUCT . . . . .	207
124. AN UMBILICAL POLYP AND A FIBROUS NODULE AT THE UMBILICUS. THERE WAS ORIGINALLY A PATENT OMPHALOMESENTERIC DUCT. . . . .	209
125. LONGITUDINAL SECTION THROUGH THE ENTIRE CENTER OF A PARTIALLY CLOSED OMPHALOMESENTERIC DUCT . . . . .	209
126. A PATENT OMPHALOMESENTERIC DUCT. . . . .	211
127. A PATENT OMPHALOMESENTERIC DUCT OPENING AT THE BASE OF THE UMBILICAL CORD. . . . .	216
128. A PATENT OMPHALOMESENTERIC DUCT. . . . .	216
129. A PATENT OMPHALOMESENTERIC DUCT AS SEEN FROM THE ABDOMINAL CAVITY . . . . .	216
130. INVERSION OF THE BOWEL THROUGH A PATENT OMPHALOMESENTERIC DUCT OPENING ON THE SIDE OF THE UMBILICAL CORD. . . . .	219

FIG.	PAGE
131. A PATENT OMPHALOMESENTERIC DUCT OF LARGE DIAMETER. . . . .	224
132. COMMENCING PROLAPSUS OF SMALL BOWEL THROUGH A PATENT OMPHALOMESENTERIC DUCT. . . . .	224
133. PARTIAL PROLAPSUS OF THE SMALL BOWEL THROUGH THE OMPHALOMESENTERIC DUCT . . . . .	224
134. PROLAPSUS OF THE SMALL BOWEL THROUGH THE PATENT OMPHALOMESENTERIC DUCT. . . . .	224
135. COMPLETE PROLAPSUS OF THE BOWEL THROUGH THE PATENT OMPHALOMESENTERIC DUCT . . . . .	225
136. PROLAPSUS OF THE SMALL BOWEL THROUGH THE PATENT OMPHALOMESENTERIC DUCT, AND AN UMBILICAL HERNIA BETWEEN THE LOOPS OF PROLAPSED BOWEL. . . . .	225
137. PROLAPSE OF THE SMALL BOWEL THROUGH AN OPEN OMPHALOMESENTERIC DUCT . . . . .	227
138. PROLAPSUS OF THE BOWEL THROUGH A PATENT OMPHALOMESENTERIC DUCT. . . . .	228
139. PROLAPSUS OF THE BOWEL THROUGH A PATENT OMPHALOMESENTERIC DUCT, WITH SECONDARY COMPLICATIONS. . . . .	229
140. PROLAPSUS AND INVERSION OF THE INTESTINE THROUGH A PATENT OMPHALOMESENTERIC DUCT. . . . .	230
141. PROLAPSUS OF THE BOWEL THROUGH THE PATENT OMPHALOMESENTERIC DUCT . . . . .	232
142. A SMALL CYST OF THE UMBILICUS DUE TO A REMNANT OF THE OMPHALOMESENTERIC DUCT. . . . .	238
143. SMALL CYST OF THE ABDOMINAL WALL DUE TO A REMNANT OF THE OMPHALOMESENTERIC DUCT. . . . .	238
144. A SMALL INTESTINAL CYST LYING BETWEEN THE PERITONEUM AND THE RECTI . . . . .	240
145. AN OMPHALOMESENTERIC DUCT ORIGINATING FROM THE CONCAVE SIDE OF THE BOWEL AND ATTACHED TO THE UMBILICUS BY A FIBROUS CORD . . . . .	243
146. A REMNANT OF AN OMPHALOMESENTERIC DUCT CAUSING FATAL INTESTINAL OBSTRUCTION. . . . .	245
147. A SMALL UMBILICAL CONCRETION. . . . .	249
148. ACUTE INFLAMMATION OF THE UMBILICUS DUE TO AN ACCUMULATION OF SEBACEOUS MATERIAL. . . . .	249
149. CHOLESTEATOMA FROM THE UMBILICUS IN CASE 1. . . . .	251
150. CHOLESTEATOMA FROM CASE 2. . . . .	251
151. A CONNECTIVE-TISSUE PROJECTION REALLY REPRESENTING A SMALL FIBROMA IN THE FLOOR OF THE UMBILICUS. . . . .	252
152. ENLARGEMENT OF FIG. 151. . . . .	252
153. SUBUMBILICAL PHLEGMON. . . . .	262
154. THE SUBUMBILICAL SPACE. . . . .	264
155. PAGET'S DISEASE OF THE UMBILICUS. . . . .	270
156. PAGET'S DISEASE OF THE UMBILICUS. . . . .	270
157. PAGET'S DISEASE OF THE UMBILICUS. . . . .	271
158. PAGET'S DISEASE OF THE UMBILICUS. . . . .	274
159. THE APPEARANCE IN A CASE OF PAGET'S DISEASE OF THE UMBILICUS AFTER TREATMENT WITH RADIUM. . . . .	275
160. SYPHILIS OF THE UMBILICUS. . . . .	284
161. ATROPHIC TUBERCULID STARTING AT THE UMBILICUS. . . . .	286
162. LEAKAGE FROM AN ABDOMINAL ANEURYSM PRODUCING A TEMPORARY ABDOMINAL TUMOR; SUBSEQUENT ESCAPE OF THE BLOOD INTO THE RIGHT RENAL POCKET. . . . .	288
163. THE MANNER IN WHICH A PERIPROSTATIC ABSCESS MAY OCCASIONALLY RUPTURE AT THE UMBILICUS. . . . .	289
164. ESCAPE OF PLEURAL FLUID FROM THE UMBILICUS. . . . .	289
165. THE OPENING OF A BROAD LIGAMENT ABSCESS AT THE UMBILICUS. . . . .	290
166. ABDOMINAL PREGNANCY WITH SPONTANEOUS ESCAPE OF LIQUOR AMNII FROM THE UMBILICUS. . . . .	348
167. SMALL PAPILLOMA IN THE UMBILICAL DEPRESSION. . . . .	365
168. A SMALL UMBILICAL TUMOR CONTAINING GLANDS AND STROMA IDENTICAL WITH THOSE OF THE UTERINE MUCOSA. . . . .	376
169. GLANDS FROM A SMALL UMBILICAL TUMOR. . . . .	377
170. TYPICAL UTERINE MUCOSA IN A SMALL UMBILICAL TUMOR. AN ENLARGEMENT OF AREA B IN FIG. 168. . . . .	378



Fig.	PAGE
171. GLANDS IN A SMALL UMBILICAL TUMOR . . . . .	379
172. DILATED GLANDS IN A SMALL UMBILICAL TUMOR . . . . .	380
173. DICHOTOMOUS BRANCHING OF GLANDS IN A SMALL UMBILICAL TUMOR . . . . .	381
174. UTERINE GLANDS IN AN UMBILICAL TUMOR . . . . .	381
175. GLAND HYPERTROPHY IN A SMALL UMBILICAL TUMOR . . . . .	382
176. A TUMOR OF THE UMBILICUS COMPOSED PARTLY OF HYPERTROPHIC SWEAT-GLANDS . . . . .	383
177. UTERINE MUCOSA IN AN UMBILICAL TUMOR . . . . .	384
178. A SMALL UMBILICAL TUMOR CONTAINING NUMEROUS GLANDS . . . . .	388
179. GLANDS IN A SMALL UMBILICAL TUMOR . . . . .	389
180. AN ADENOMYOMA IN THE ABDOMINAL WALL NEAR THE ANTERIOR ILIAC SPINE . . . . .	394
181. A SMALL UMBILICAL TUMOR CONTAINING GLANDS SIMILAR TO THOSE OF THE BODY OF THE UTERUS . . . . .	396
182. ADENOMYOMA OF THE UMBILICUS . . . . .	397
183. A GROUP OF SWEAT-GLANDS IN AN UMBILICAL TUMOR . . . . .	398
184. APPEARANCE OF THE CARCINOMATOUS UMBILICUS AFTER REMOVAL . . . . .	424
185. CARCINOMA OF THE UMBILICUS SECONDARY TO CARCINOMA OF THE OVARIES . . . . .	432
186. A MALIGNANT GROWTH OF THE UMBILICUS, APPARENTLY A CARCINOMA SECONDARY TO SOME ABDOMINAL GROWTH . . . . .	439
187. ADENOCARCINOMA OF THE UMBILICUS SECONDARY TO AN INTRA-ABDOMINAL GROWTH . . . . .	440
188. ADENOCARCINOMA OF THE UMBILICUS . . . . .	441
189. A SECTION SHOWING CARCINOMA OF THE RIGHT INGUINAL GLANDS . . . . .	442
190. SECONDARY CARCINOMA OF THE UMBILICUS . . . . .	443
191. TELANGIECTATIC MYXOSARCOMA OF THE UMBILICUS . . . . .	450
192. APPEARANCE OF THE UMBILICUS AFTER REMOVAL OF THE TUMOR SHOWN IN FIG. 191 . . . . .	450
193. MYXOSARCOMA OF THE UMBILICUS . . . . .	451
194. TELANGIECTATIC MYXOSARCOMA PROJECTING FROM THE RIGHT SIDE OF THE UMBILICUS . . . . .	452
195. A TELANGIECTATIC MYXOSARCOMA . . . . .	452
196. A CASE OF CONGENITAL UMBILICAL HERNIA . . . . .	460
197. AN AMNIOTIC HERNIA . . . . .	462
198. SEVERAL LOOPS OF BOWEL WHICH LAY OUTSIDE THE UMBILICUS AND WERE NIPPED OFF DURING FETAL LIFE. THE CHILD LIVED A SHORT TIME AFTER BIRTH . . . . .	464
199. A SEROUS UMBILICAL HERNIA . . . . .	469
200. FREEING THE UMBILICAL HERNIAL SAC FROM THE ABDOMEN . . . . .	472
201. CLOSURE OF THE HERNIAL OPENING AT THE UMBILICUS . . . . .	473
202. CLOSURE OF THE HERNIAL OPENING AT THE UMBILICUS . . . . .	474
203. AN UMBILICAL HERNIA ASSOCIATED WITH MARKED PROLAPSUS OF THE ABDOMINAL WALL . . . . .	475
204. AN UMBILICAL HERNIA AND A MARKEDLY PENDULOUS ABDOMEN IN A PATIENT WEIGH- ING 464 POUNDS . . . . .	476
205. THE ABDOMINAL SCAR AFTER THE REMOVAL OF A VERY LARGE AREA OF FAT . . . . .	477
206. AN UMBILICAL CYST . . . . .	478
207. EXSTROPHY OF THE BLADDER OPENING AT OR NEAR THE UMBILICUS . . . . .	482
208. EXSTROPHY OF THE BLADDER. A SIDE VIEW OF THE CASE DEPICTED IN FIG. 207, SHOW- ING THE RELATIVE DISTANCE FROM THE SYMPHYSIS TO THE OPENING IN THE ABDOMINAL WALL . . . . .	483
209. EXSTROPHY OF THE BLADDER . . . . .	483
210. ESCAPE OF URINE FROM THE UMBILICUS WHEN THE INNER URETHRAL ORIFICE IS BLOCKED BY A MEMBRANE . . . . .	488
211. A PATENT URACHUS WITH A MUSHROOM-LIKE PROJECTION AT THE UMBILICUS . . . . .	489
212. A PATENT URACHUS WITH A PENILE PROJECTION AT THE UMBILICUS . . . . .	489
213. THE APPEARANCE OF THE UMBILICUS IN A CASE IN WHICH BOTH A PATENT OMPHALOMES- ENTERIC DUCT AND A PATENT URACHUS EXISTED . . . . .	493
214. CROSS-SECTION OF THE PATENT OMPHALOMESENTERIC DUCT AND OF THE PATENT URA- CHUS IN THE SAME CHILD . . . . .	493
215. A PICTURE OF THE CHILD THREE WEEKS AFTER REMOVAL OF A PATENT OMPHALOMES- ENTERIC DUCT AND A PATULOUS URACHUS . . . . .	494
216. A PATENT URACHUS . . . . .	497

FIG.	PAGE
217. A URACHUS OPEN FROM BLADDER TO UMBILICUS . . . . .	498
218. AN OPEN URACHUS . . . . .	499
219. ESCAPE OF URINE FROM THE UMBILICUS DUE TO A PATENT URACHUS . . . . .	502
220. A PATENT URACHUS WITH A PENILE PROJECTION AT THE UMBILICUS . . . . .	505
221. A RING-SHAPED VESICAL CALCULUS WITH A FINE HAIR IN ITS AXIS . . . . .	507
222. A PARTIALLY PATENT URACHUS . . . . .	515
223. A PATENT URACHUS . . . . .	517
224. A PORTION OF A URACHUS SEVEN TIMES ENLARGED, WITH NUMEROUS LARGE AND SMALL DILATATIONS . . . . .	518
225. PORTION OF A URACHUS TEN TIMES ENLARGED . . . . .	518
226. CYSTS OF THE URACHUS ARRANGED LIKE A STRING OF PEARLS . . . . .	520
227. SPINDLE-SHAPED DILATATIONS OF THE URACHUS . . . . .	520
228. A SMALL CYST OF THE URACHUS . . . . .	532
229. A PATENT URACHUS . . . . .	534
230. A MULTILOCULAR CYST OF THE URACHUS . . . . .	535
231. SECTION OF A PATENT URACHUS . . . . .	536
232. TRANSVERSE SECTION OF A PATENT URACHUS . . . . .	537
233. A SMALL CYST OF THE URACHUS . . . . .	538
234. A DIFFUSE NEUROMA OF THE BLADDER . . . . .	542
235. CUT SURFACE OF THE BLADDER SHOWING A DIFFUSE NEUROMA OF ITS WALLS . . . . .	543
236. A DIFFUSE NEUROMA FORMING A MANTLE AROUND THE CAVITY OF THE BLADDER . . . . .	544
237. DIAGRAM SHOWING THE ARRESTED DEVELOPMENT OF THE GENITAL TRACT AND THE RE- LATION OF THE MALFORMED PARTS TO THE CYST OF THE URACHUS . . . . .	551
238. SECTION OF THE SEGMENT OF URACHUS WHICH PASSED BETWEEN THE BLADDER AND THE CYST-WALL, AS SEEN UNDER A LOW POWER . . . . .	552
239. THE ABDOMINAL CONTOUR IN A CASE OF VERY LARGE URACHAL CYST . . . . .	558
240. A URACHAL CYST TURNED INSIDE OUT AND SHOWING PAPILLARY MASSES, PARTICULARLY IN THE LOWER PART OF THE PICTURE . . . . .	559
241. INFECTED URACHAL REMAINS . . . . .	568
242. AN INFECTED URACHUS OPENING BETWEEN THE UMBILICUS AND BLADDER . . . . .	570
243. URACHAL CYST . . . . .	576
244. A DILATED URACHUS COMMUNICATING WITH THE BLADDER . . . . .	579
245. LARGE ACCUMULATION OF URINE IN A PARTIALLY PATENT URACHUS . . . . .	579
246. AN INFECTED URACHUS OPENING AT THE UMBILICUS . . . . .	580
247. A PATENT URACHUS DILATED IN ITS MIDDLE PORTION . . . . .	580
248. ACCUMULATION OF A LARGE QUANTITY OF URINE IN A URACHAL POUCH . . . . .	581
249. FETAL BONES REMOVED FROM AN OLD EXTRA-UTERINE PREGNANCY SAC . . . . .	584
250. A PHOSPHATIC DEPOSIT ON THE END OF A LONG BONE . . . . .	585
251. A DILATED URACHUS COMMUNICATING WITH THE BLADDER . . . . .	598
252. URACHAL CYST . . . . .	599
253. URACHAL CYST . . . . .	603
254. URACHAL CYST . . . . .	603
255. A PATENT URACHUS CONTAINING A VESICAL CALCULUS . . . . .	625
256. CARCINOMA OF THE PATENT URACHUS . . . . .	632
257. A MULTILOCULAR AND MALIGNANT CYST OF THE URACHUS . . . . .	637
258. GIANT-CELLS IN THE WALL OF AN ADENOCARCINOMATOUS CYST OF THE URACHUS . . . . .	638
259. GIANT-CELLS IN THE WALL OF AN ADENOCARCINOMA OF THE URACHUS . . . . .	639
260. GIANT-CELLS IN THE WALL OF AN ADENOCARCINOMATOUS CYST OF THE URACHUS . . . . .	640-641
261. ADENOCARCINOMA OF THE URACHUS . . . . .	642
262. A PAPILLARY-LIKE AREA IN AN ADENOCARCINOMATOUS CYST OF THE URACHUS . . . . .	643
263. METASTASIS FROM ADENOCARCINOMA OF THE URACHUS . . . . .	644
264. AN UMBILICAL CYST . . . . .	645
265. WALL OF AN UMBILICAL CYST . . . . .	645
266. GIANT-CELLS IN THE WALL OF AN UMBILICAL CYST . . . . .	646
267. TUBERCULOSIS OF THE URACHUS . . . . .	652
268. AN AREA SUGGESTING A TUBERCLE . . . . .	653
269. A TUBERCLE FROM DR. EASTMAN'S CASE OF TUBERCULOSIS OF THE URACHUS . . . . .	654

## LIST OF PLATES

PLATE	PAGE
I. DRAWINGS OF NORMAL UMBILICI.....	40
II. DRAWINGS OF NORMAL UMBILICI.....	41
III. DRAWINGS OF NORMAL UMBILICI.....	42
IV. DRAWINGS OF NORMAL UMBILICI.....	43
V. CANCER OF THE UMBILICUS APPARENTLY SECONDARY TO A TUMOR OF THE OVARY.....	434-435
VI. UMBILICAL HERNIA.....	466-467
VII. EXSTROPHY OF THE BLADDER.....	484-485



# THE UMBILICUS AND ITS DISEASES.

## CHAPTER I.

### EMBRYOLOGY OF THE UMBILICAL REGION.

General considerations.  
Development of the  
Amnion.  
Yolk-sac.  
Body-stalk.  
Allantois and Urachus.  
Cœlom.  
Umbilical vessels.  
Umbilical cord.  
Omphalomesenteric duct.

A COMPREHENSIVE study of the diseases of the umbilicus necessarily calls for a thorough knowledge of the embryology of this region. In early fetal life, however, the changes are so rapid and varied that they might well be termed kaleidoscopic; hence it becomes somewhat difficult to follow the various steps in the development of the umbilicus.\*

Among the various authors who have discussed the diseases of the urachus and who have dwelt briefly upon its development may be mentioned Cazin (1862), Ahlfeld (1876), Freer (1887), Ledderhose (1890), Monod (1899), and Vaughan (1905). The literature on the embryology of the umbilicus is, however, on the whole very meager.

In order that the gradual development of the umbilicus may be clearly understood, it is necessary to begin with a very young embryo. Fig. 1 represents an embryo 0.7 mm. long. The embryo forms only a very small portion of the specimen. On its dorsal surface, and forming a sort of cap, is the *a m n i o n* (colored green). The *y o l k - s a c* is relatively large, and lies in front of the embryo. Connecting all the fetal structures with the placenta is the *b o d y - s t a l k*. It will be noted even at this stage that a portion of the yolk-sac is projecting into the body-stalk. This is the commencement of the *a l l a n t o i s*, which is in reality a recess of the yolk-sac.

When the embryo is about 1.7 mm. long (Fig. 2), its outlines are well defined and the heart is clearly seen. The amniotic cavity is much larger, and the amnion, both above and below, extends farther forward than the embryo. The yolk-sac, although larger, has not kept pace in growth with the embryo and the amnion. It is continued upward in the embryo, forming the fore-gut, and downward, forming the hind-gut. The allantois has projected farther into the body-stalk. At this period a depression exists where the amnion and yolk-sac join; this marks the in-

\* The illustrations in this chapter are arranged chiefly according to the age of the embryo from which they were obtained.

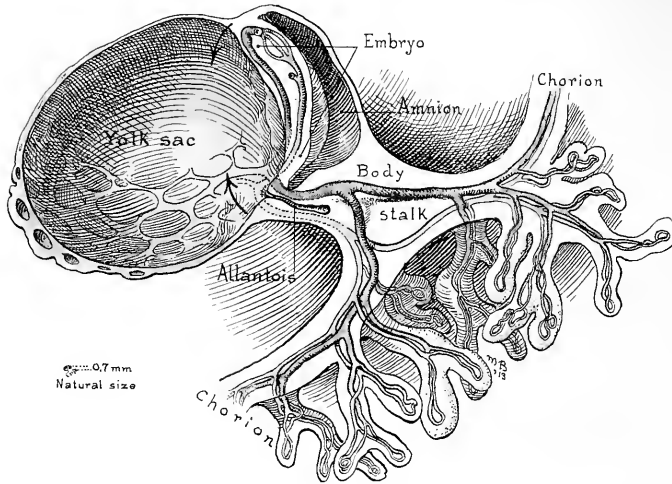


FIG. 1.—SAGITTAL SECTION SHOWING A VERY EARLY STAGE IN THE FORMATION OF THE UMBILICUS AND ALLANTOIS. (Human embryo, 0.7 mm. long.)

Note the origin of the allantois from the cavity of the yolk-sac. The umbilical region will be formed by a gradual approximation of the cranial and caudal ends of the yolk-sac, as indicated by the arrows. The embryonic surface of the yolk-sac will later become the alimentary canal.

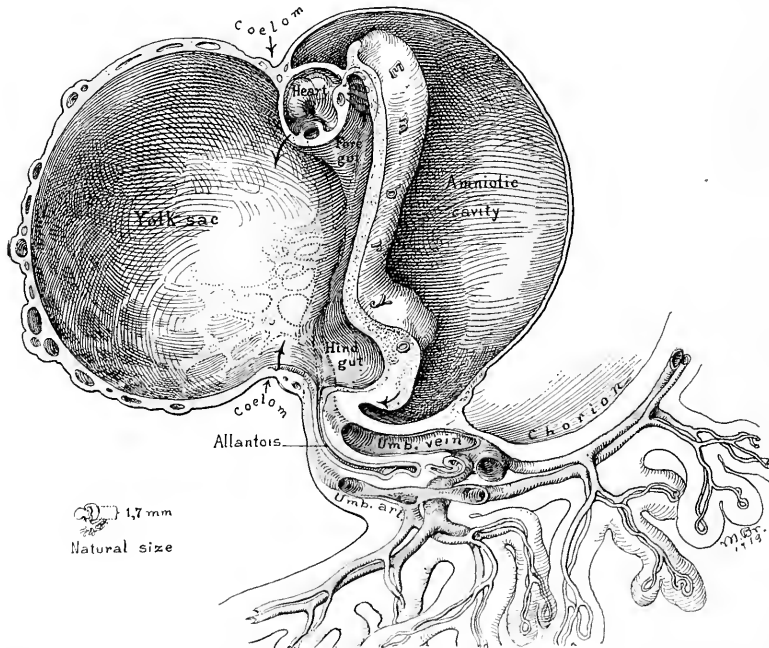


FIG. 2.—A MORE ADVANCED STAGE IN THE FORMATION OF THE UMBILICAL REGION. (Human embryo, 1.7 mm. long. Mall series, 391.) (This embryo has been very carefully described by Dr. Walter E. Dandy (Amer. Jour. Anat., 1910, x, 85).)

Note the advancing approach of the cranial and caudal portions of the yolk-sac and its division into a main cavity and two recesses, the fore-gut and the hind-gut, into the latter of which the allantois now opens. The vitelline arteries and veins are clearly seen on the embryonic side of the yolk-sac. The amnion is now gradually enveloping the embryo. Compare the situation of the coelom in this with that in the subsequent pictures. There is as yet no umbilical cord. For the first stage of its development, see Fig. 3.

folding of the exocoelom. The arrows indicate the direction that it will follow later.

In Fig. 3 we have a composite picture representing the appearances in an embryo 2.5 mm. long. The embryo has now assumed a definite form, and many of its structures can be traced. The amnion has continued to grow and now almost completely encircles the embryo. The yolk-sac has increased little, if any, in size.

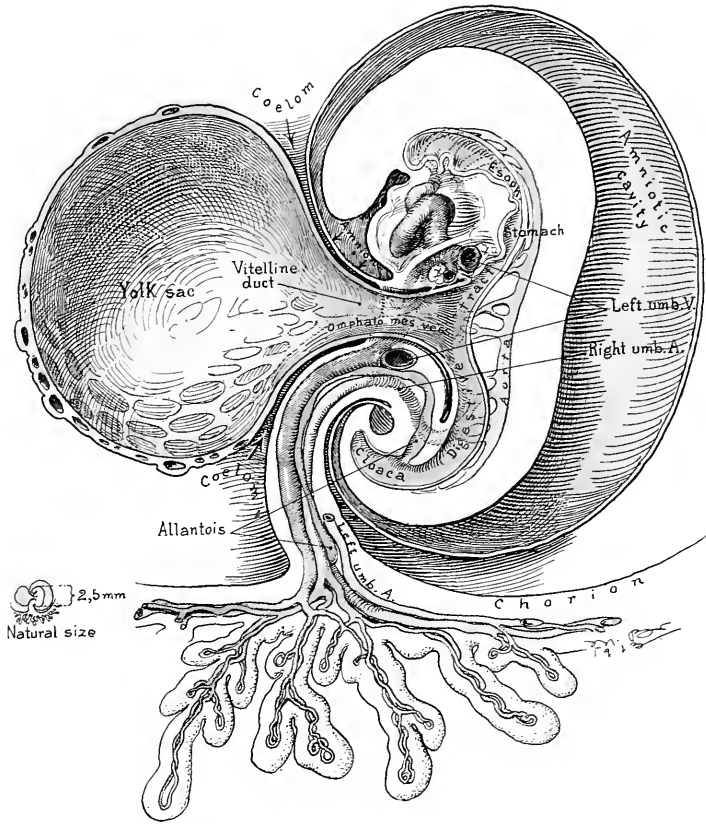


FIG. 3.—A COMPOSITE PICTURE SHOWING THE FORMATION OF THE UMBILICUS IN AN EMBRYO 2.5 MM. LONG.

This drawing was made after a careful study of several embryos of this length described in the literature. Each author was interested in some particular region, but not in the embryo as a whole. The yolk-sac has now become greatly narrowed at its entrance into the body. The narrowed portion is now referred to as the vitelline or omphalomesenteric duct. In its wall are seen the right omphalomesenteric vessels. The digestive tract already shows well-defined differentiation. The allantois now opens into the cloaca. The amnion almost completely encircles the embryo, and in so doing has combined the vitelline duct with the body-stalk, containing the chorionic vessels and the allantois, into a common cord. As the development advances this cord will become more compact, thinner, and longer. The exocoelom has been drawn into the embryo and will later unite with the coelom of the pleuroperitoneal cavity.

It has been forced away from the embryo by the increase in development of the embryo and of the amnion. The narrowed portion of the yolk-sac is now called the omphalomesenteric or vitelline duct. This duct naturally communicates with the digestive tract, which is now becoming more and more differentiated. The digestive tract ends below in the cloaca.

We can now for the first time really speak of an umbilical cord. This consists of the body-stalk and the omphalomesenteric duct, which have as yet not fused.

The portion of the yolk-sac now forming the cloaca has been carried far back, and opening into it is the allantois, which can be followed out in the body-stalk almost to the placenta. It terminates in a bulbous extremity. Its caliber in the cord may vary considerably.

At this stage the exocoelom has been carried in between the amnion and the yolk-sac. It fills in the space around the omphalomesenteric duct, and is destined to join the pleuroperitoneal cavity.

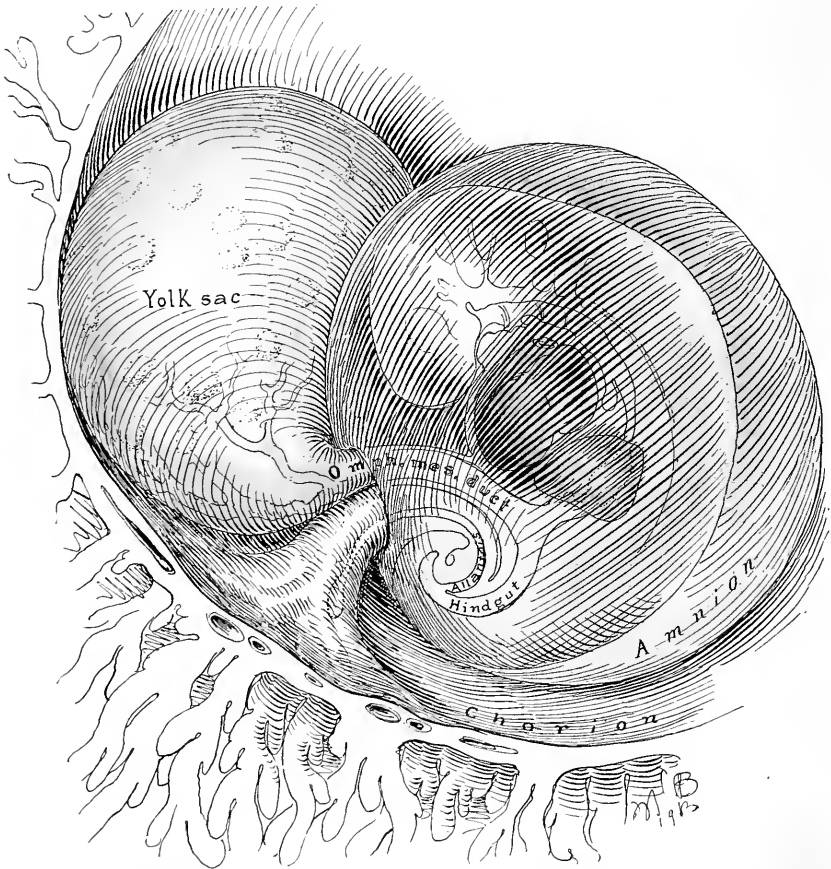


FIG. 4.—A DIAGRAMMATIC REPRESENTATION OF A HUMAN EMBRYO, ABOUT 3.5 MM. LONG, SHOWING THE EFFECT OF THE EXPANDING AMNION UPON THE YOLK-SAC AND BODY-STALK.

The amnion has now completely encircled the embryo, and with its increase in size has crowded the yolk-sac away. Outside the amnion the yolk-sac and body-stalk are separate structures; inside the amniotic ring they are fused, forming the umbilical cord. The amnion covers the cord as far as the embryo. It is probable that the tension produced on the yolk-stalk by the amnion contributes to the primitive kink in the alimentary canal.

In Fig. 4 we have a diagrammatic representation of a human embryo 3.5 mm. long. The embryo is completely encircled by the amnion. The yolk-sac is somewhat larger than before, but is smaller than the fetal sac. The umbilical cord is formed of the body-stalk and omphalomesenteric duct. Externally to the amnion they are separate and distinct; within the cavity they are held together by a sheath consisting of amnion.

Fig. 5 represents a human embryo 5 mm. in length. The amnion is now much



larger than the yolk-sac, and the portion of the omphalomesenteric duct external to the sac has become much smaller than the body-stalk. The esophagus, stomach, liver, pancreatic buds, and first curve of the small intestine are clearly visible. Attached to this, and extending out into the cord, is the omphalomesenteric or vitelline duct, accompanied by the omphalomesenteric vessels. The allantois,

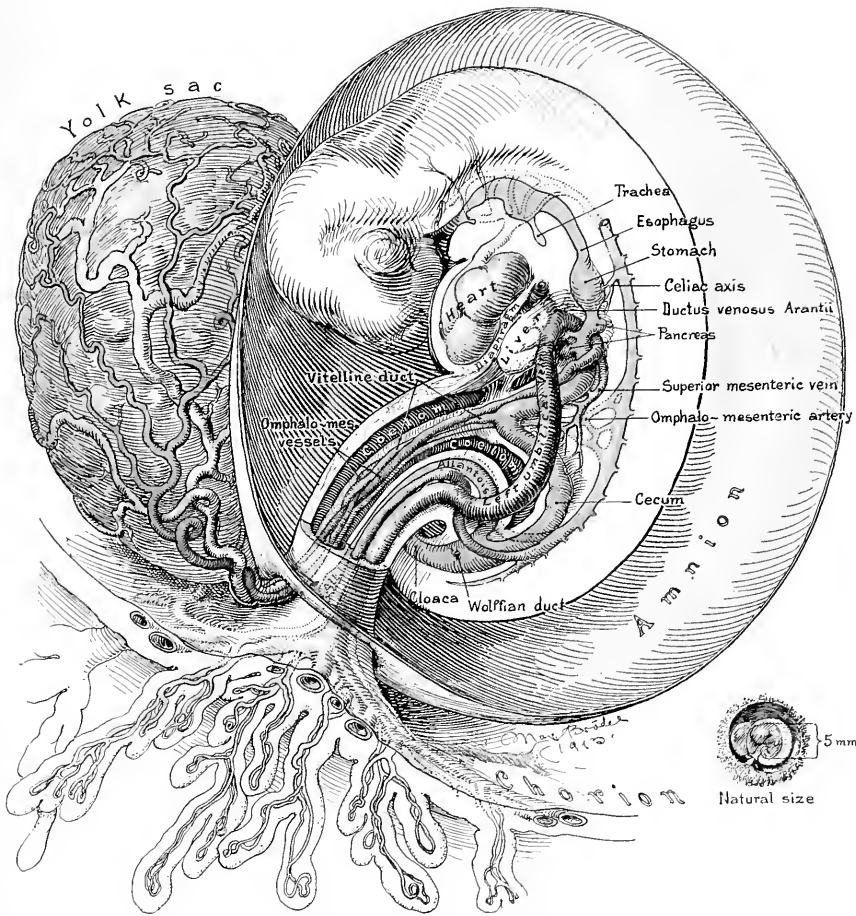


FIG. 5.—SAGITTAL VIEW OF A HUMAN EMBRYO 5 MM. IN LENGTH.

In large part the left halves of the amnion and embryo have been removed, in order to bring clearly into view the structure of the cord. The expanding amnion has almost reached the chorion, hence but little remains of the extra-amniotic portion of the yolk-stalk and of the body-stalk. The umbilical cord has become longer. The caudal portion of the cord is firm and contains the umbilical arteries and veins; the latter, soon after leaving the body, form a common trunk, which usually curves toward the left. Between the two umbilical arteries lies the allantois, the bulbous end of which still persists almost to the amnion. The cranial portion of the cord is looser in texture. It contains the cœlomic cavity, in which lies the omphalomesenteric duct, accompanied by its vessels. Note that the superior mesenteric vein empties into the omphalomesenteric vein behind the pancreatic buds. The omphalomesenteric artery still arises by several branches from the aorta.

which opens into the cloaca, can be followed outward in the cord almost to the placenta. The cord now contains the omphalomesenteric duct and its vessels, surrounded by exocoelom, as well as the two umbilical arteries, the umbilical vein, and the allantois. By the time the embryo is 10 mm. long (Fig. 8) the yolk-sac is relatively very small, the cord is well formed, and in its outer portion already shows

some tendency to twist. The small intestine still consists of one loop, and the greater portion of it has been drawn out into the cord apparently by the omphalomesenteric duct or its vessels. It lies in a cavity—the exocoelom. The umbilical cord, on section near the fetus, is now seen to contain the umbilical vein, the exocoelomic cavity with the major part of the small intestine and the omphalomesenteric vessels lying in it; in the lower wall of the cord the umbilical arteries appear with the allantois between them.

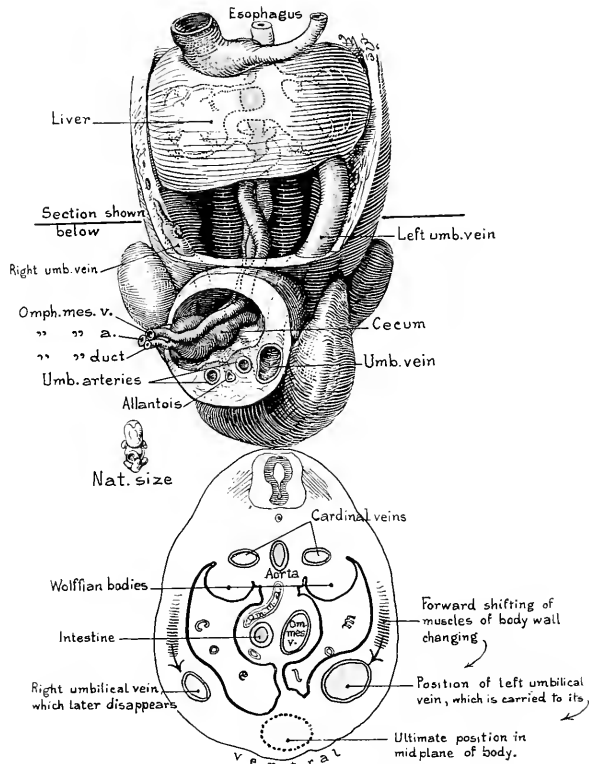


FIG. 6.—ANTERIOR VIEW AND TRANSVERSE SECTION OF A HUMAN EMBRYO 7 MM. LONG, SHOWING THE UMBILICAL REGION.

The umbilical cord has been cut off near the embryo in order to show the thick lower portion containing the umbilical vessels and allantois. The upper portion consists mainly of the exocoelomic cavity, which contains the intestinal loop and the omphalomesenteric vessels. The omphalomesenteric duct has been drawn to the right, in order that it may be more clearly seen. Note the narrow coelomic ring through which the intestine and vessels emerge. At the outer end of the intestinal loop the omphalomesenteric duct begins.

The lower diagram represents a transverse section of the body at the level indicated in the upper picture. The purpose of this diagram is to show the shifting of the left umbilical vein toward the mid-line of the body, as a result of the ventral growth of the body-wall. The right umbilical vein is destined to disappear.

By the time the embryo has reached 18 mm. in length (Fig. 10) the small intestine shows numerous convolutions, and nearly all the small bowel lies in the exocoelomic cavity in the cord outside of the embryo.

In a longitudinal section of the cord near the body, in an embryo 23 mm. in length (Fig. 11), the exocoelomic cavity is seen to contain convolutions of small bowel, having attached to them the omphalomesenteric vessels. In the lower wall of the cord are the umbilical arteries, the umbilical vein, and the allantois.

The small, cyst-like spaces in the wall of the cord are partially organized areas of exocoelom.

By the time the embryo is 3 cm. long the exocoelomic cavity in the cord contains many loops of small bowel (Fig. 12).

With the growth of the embryo the intestines rapidly recede into the abdomen (Fig. 15). The exocoelom and all traces of the omphalomesenteric duct and its vessels disappear, but remnants of the allantois may or may not persist in the cord.

After this short survey of the gradual development of the umbilical region of the embryo it may be well to trace briefly the individual structures.

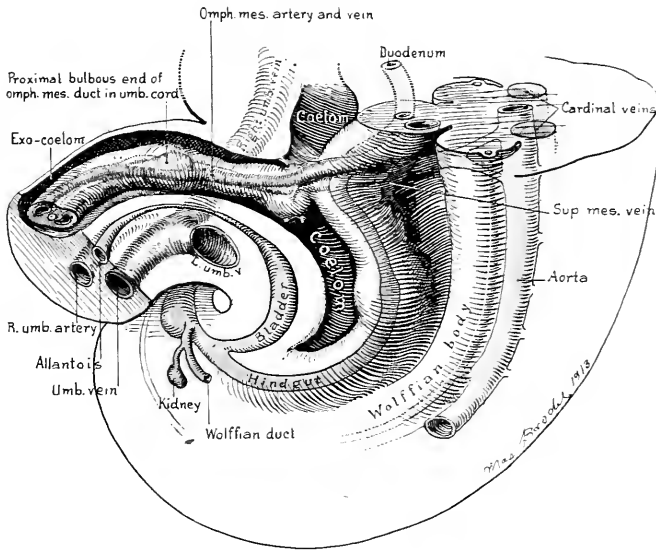


FIG. 7.—SAGITTAL SECTION OF THE UMBILICAL REGION IN AN EMBRYO 7 MM. IN LENGTH.

This is a reconstruction from the Mall embryo No. 2. A detailed description of this embryo by Mall will be found in the *Journal of Morphology*, 1891, vol. v, p. 459. The exocoelom in the cord contains the omphalomesenteric stalk, in the body of which are seen the omphalomesenteric vessels and the duct. The connection of the duct with the intestine has disappeared, but the duct still persists in the cord and shows a bulbous dilatation at its proximal end. If it still persists in later life, we shall have a cyst in the abdominal wall or in the structures of the umbilicus. The junction of the superior mesenteric vein with the omphalomesenteric vein is clearly seen in the mesentery.

### THE AMNION.

A clear idea of the way in which the amnion develops is essential, inasmuch as this membrane plays an important rôle in the formation of the umbilical cord, and occasionally of the umbilical region itself. In the very early embryo (Fig. 1) it is a small, flaccid sac, covering the posterior surface of the embryo.

By the time the embryo reaches 1.7 mm. in length (Fig. 2), the amnion has increased in size to such an extent that it not only covers the posterior surface of the embryo, but has also extended beyond the head and tail, and already shows a tendency to arch over the anterior surface.

When the embryo reaches 2.5 mm. in length, the amnion is seen to have almost engulfed the embryo, surrounding it on all sides except where the yolk-sac and body-stalk enter its ventral surface. Fig. 3 clearly indicates that the expansile force of the amnion and of the embryo has pushed the major portion of the yolk-sac away,

leaving only its narrowed portion—now called the omphalomesenteric duct—to connect it with the digestive tract.

Fig. 4 shows the amniotic sac of an embryo 3.5 mm. long. Here the fetus and the major portion of the omphalomesenteric duct and of the body-stalk are contained in the amniotic cavity, which is approximately spherical.

By the time the embryo is 5 mm. in length the amniotic sac is much larger than

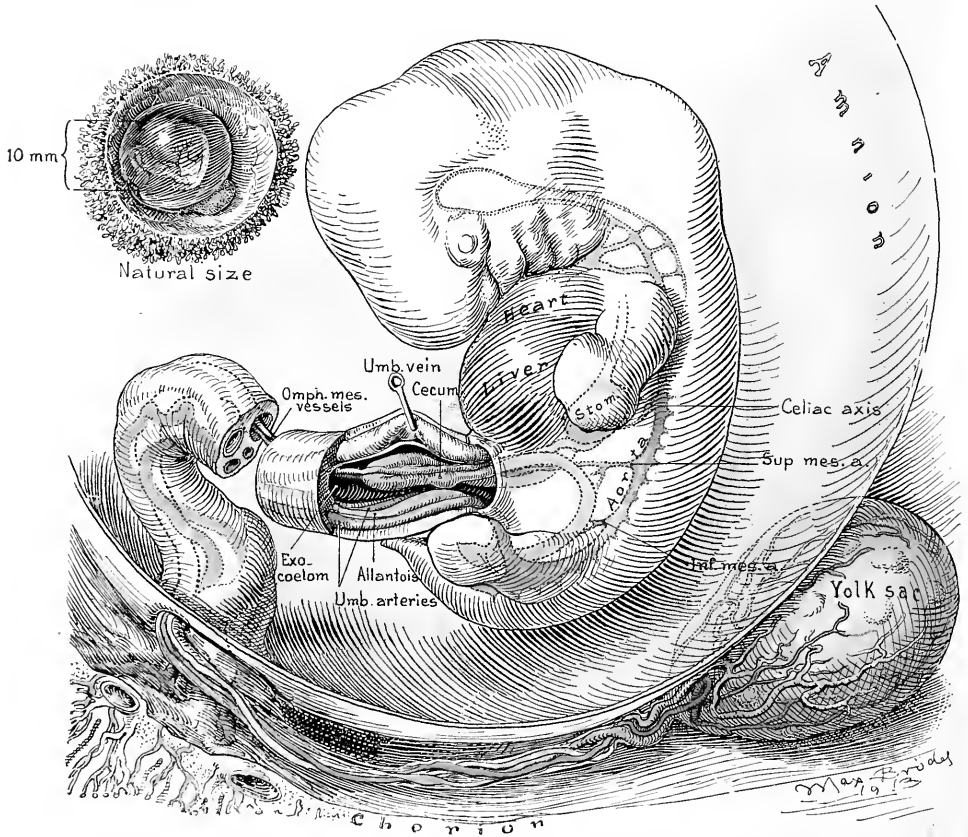


FIG. 8.—SAGITTAL VIEW OF THE UMBILICAL REGION OF A HUMAN EMBRYO 10 MM. IN LENGTH.

The yolk-sac now lies far removed from the umbilical cord; its vessels and stalk follow a tortuous course. The umbilical cord here shows the first indication of a twist, which may be caused by the embryo rotating toward the right. In the embryos examined by us there has been but one exception to this rule. The small intestine extends a considerable distance into the exocoelom of the cord. At the outer end of the intestinal loop is situated the delicate omphalomesenteric duct. The omphalomesenteric vein passes on the left side of the intestinal loop; the artery, on the right side.

the yolk-sac (Fig. 5), and the amnion is reflected in on the cord to the umbilicus. In rare instances, as noted on page 67, when the skin is lacking at the umbilicus, the amnion covers over this defect, forming an *amnion umbilicus*.

When the embryo reaches 10 mm. in length, the amnion is well developed (Fig. 8). The amnion of an embryo 23 mm. long (Fig. 11) presents essentially the same picture.

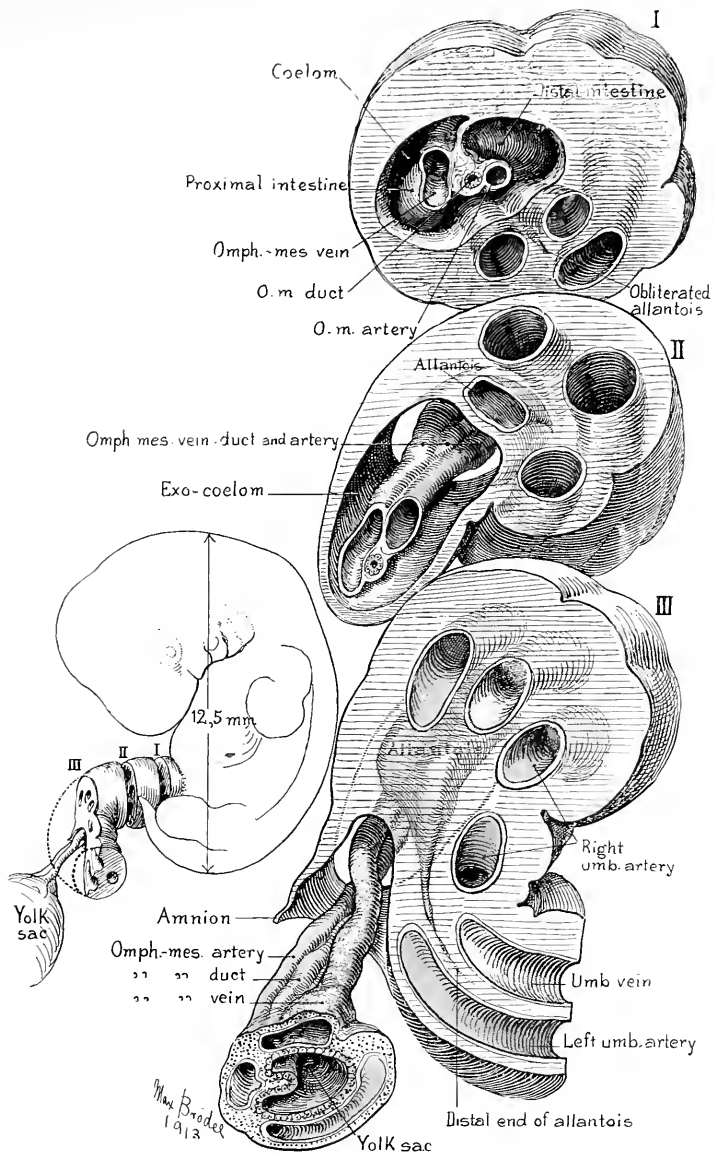


FIG. 9.—GRAPHIC RECONSTRUCTION OF THE UMBILICAL CORD OF A HUMAN EMBRYO 12.5 MM. IN LENGTH. (Mall collection, No. 317.)

The figure to the left shows the manner in which the cord has been cut into the portions I, II, and III. On the right are shown frontal views of the three sections. They are represented as being semitransparent, in order to give a clear idea of the course of the contained structures.

Section I: Embryonic end of cord, showing cœlomic ring through which protrudes the primitive intestine. Note the position of the proximal intestine (jejunum) and the distal intestine (ileum). To the right and above, the omphalomesenteric vessels are seen emerging by the side of the intestine. The vein comes from above the gut and the artery from below; between them lies the duct, which is still connected with the intestine. A delicate mesenterium accompanies these structures for a short distance into the cord (*cf.* also Fig. 7). The umbilical arteries and vein are seen in the lower part of the cord. Here the allantois lies between the arteries and becomes obliterated.

Section II: This section of the cord is farther from the umbilicus, and shows a twist of the structures, somewhat after the manner of the left turn of a screw. The exocoelom with its contents now lies to the right; the umbilical vessels and allantois have shifted to the left. The allantois has again increased in size, and lies between the umbilical arteries and the exocoelom.

Section III: This section of the cord is still farther from the umbilicus. It shows the amniotic ring, through which emerge the omphalomesenteric duct and its vessels. The allantois decreases rapidly in size and becomes lost between the left umbilical artery and the umbilical vein.

## THE YOLK-SAC.

In an early pregnancy, when the embryo is about 0.7 mm. long (Fig. 1), the yolk-sac is represented by a nearly circular cyst, intimately blended with the anterior surface of the embryo. The sac has relatively thin walls, which are traversed by delicate traceries of blood-vessels. Even in this early stage a small prolongation of the yolk-sac extends into the body-stalk. This prolongation is the beginning of the allantois.

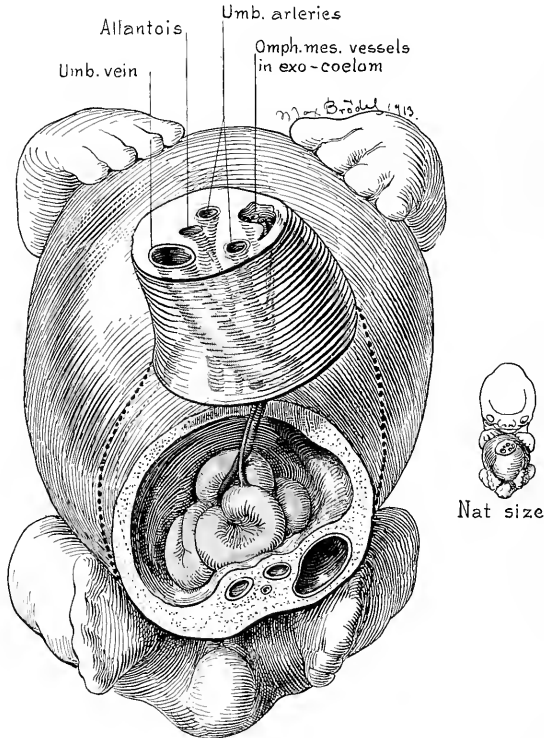


FIG. 10.—ANTERIOR VIEW OF THE UMBILICAL CORD OF A HUMAN EMBRYO 18 MM. IN LENGTH.

A portion of the cord has been removed, as shown by the dotted line. The exocoelomic cavity has increased materially in size and contains several loops of intestine, including the cecum and budding appendix, seen on the extreme left (right in picture). The narrow coelomic ring is obscured by the intestine. The omphalomesenteric duct has disappeared, and we now have only the omphalomesenteric vessels passing out into the exocoelom. This more rapid disappearance of the delicate epithelial structure of the vitelline duct, as contrasted with the preservation of the stronger tissues of the blood-vessels, is probably caused by the continued tension to which the yolk-stalk is subjected. (See Figs. 11 and 12) The exocoelomic cavity rapidly tapers to a narrow chink, as seen in the upper and more distal section. In the mid-line of the cord below are the two umbilical arteries, with the allantois between and slightly below them. The umbilical vein lies to the left. The characteristic twist of the cord, including all of its structures, is clearly seen.

When the embryo has reached a length of about 1.7 mm. (Fig. 2), the yolk-sac is larger, but has not kept pace in development with either the embryo or the amnion. It has extended\* into the anterior surface of the embryo, above forming the fore-gut, below the hind-gut. The allantois, which has originated from the yolk-sac and is still connected with it, extends much farther into the body-stalk.

\* In reality it is the forward growth of the upper and lower ends of the embryo, as indicated by the arrows, that produces the recesses destined to become the alimentary canal.

By the time the embryo is 2.5 mm. in length (Fig. 3) the yolk-sac is smaller than either the embryo or the amnion. With the increase in size of the amniotic sac the yolk-sac has been forced away from the embryo. The cavity of the yolk-sac, however, still communicates freely with the digestive tract by a broad channel—the omphalomesenteric or vitelline duct. During the development of the embryo

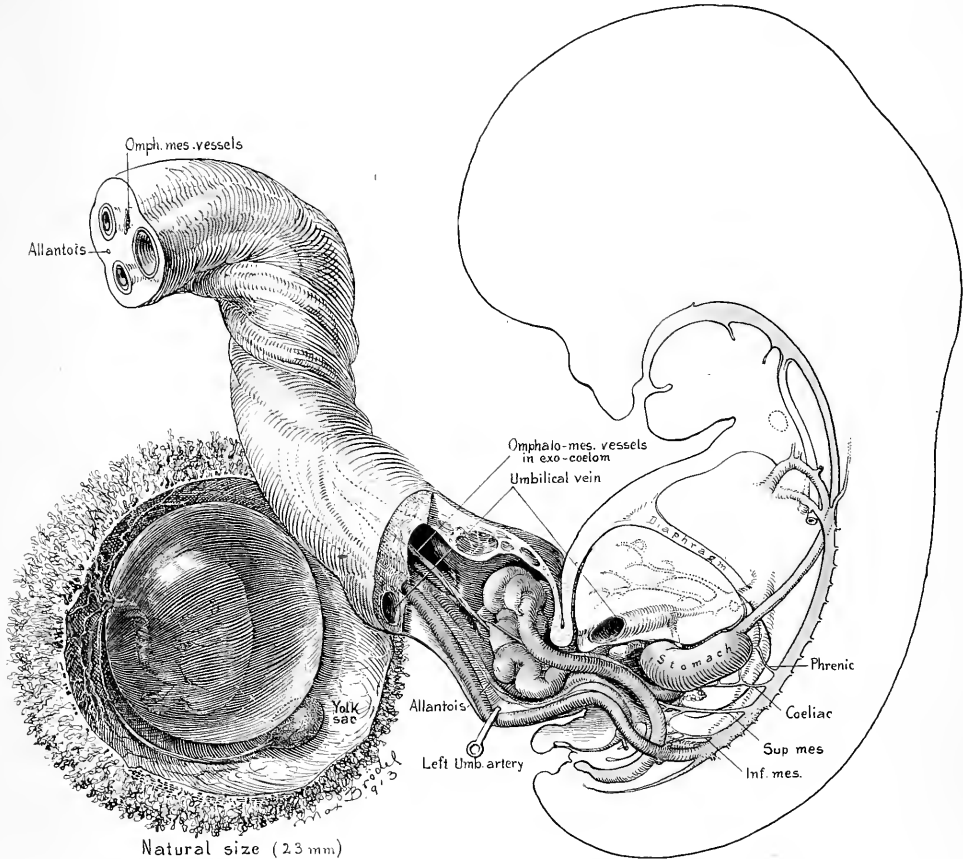


FIG. 11.—SAGITTAL SECTION OF THE UMBILICAL REGION IN A HUMAN EMBRYO 23 MM. IN LENGTH.

The small drawing to the left, which is of natural size, accurately depicts the relation of the yolk-sac to the cord and amnion. Its stalk is very long, and the yolk-sac has become relatively smaller. The umbilical cord now shows very marked twisting. The exocoelomic cavity in the umbilical cord now contains practically all the intestine with the exception of the jejunum and descending colon. The distal portion of the cavity is funnel-shaped, the apex being directed away from the embryo. The omphalomesenteric duct has disappeared, but its vessels persist. The small cystic spaces in the upper wall of the cord mark the beginning obliteration of the exocoelom. The umbilical vein has been partly removed in order to bring into view the deeper structures. The two umbilical arteries, accompanied by the allantois, are in their usual position in the lower part of the cord. Note the slight spindle-shaped dilatation of the allantois in its course.

and its digestive tract the allantois has been carried downward and backward. It now opens into the cloaca, and can be traced out in the body-stalk as far as the placenta.

By the time the embryo is 3.5 mm. long (Fig. 4) the amnion has completely encircled the embryo. The yolk-sac has increased somewhat in size, is pear-shaped, covered with a tracery of blood-vessels, and appears to have small, shallow, cyst-

like elevations on its surface. It is still intimately connected with the embryo through its omphalomesenteric duct, which joins the body-stalk, passing into the amniotic sac and thence to the embryo.

When the embryo reaches 5 mm. in length (Fig. 5), the yolk-sac is about the

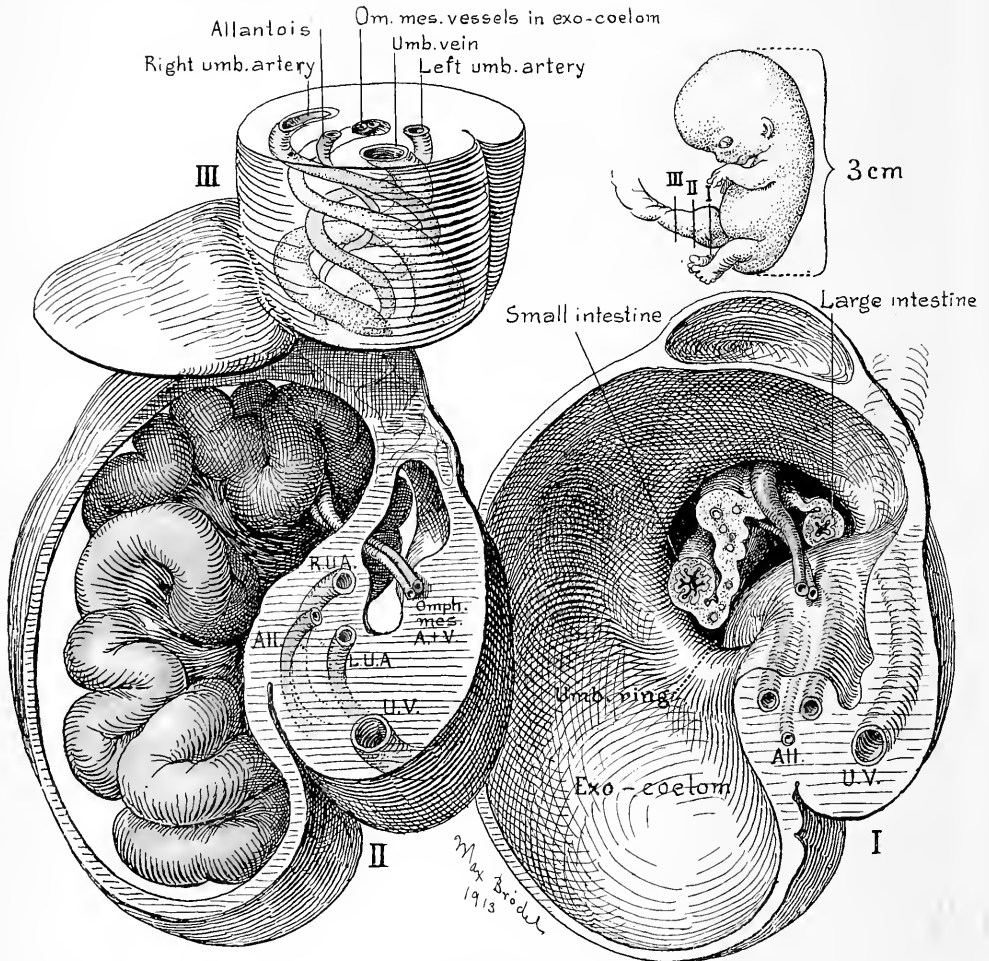


FIG. 12.—A GRAPHIC RECONSTRUCTION OF THE UMBILICAL REGION OF A HUMAN EMBRYO 3 CM. LONG. (Mall collection, No. 86.)

The small sketch in the right upper corner indicates the points at which the sections of the cord have been made. This stage marks the maximal development of the exocoelom, the intestine completely filling its cavity. Section I, the nearest to the embryo, gives a frontal view of the narrow exocoelomic ring, which, on account of the solid tissue containing the vascular structures below, appears in the form of a crescent. Emerging from the ring we see the small intestine to the right of the embryo, and the large intestine to the left, with the accompanying mesentery between them. In the cross-section of the mesentery are seen numerous sections of its arteries and vein. The omphalomesenteric vein passes outside of and above the mesentery; the omphalomesenteric artery comes from below, as seen in Section II. They soon leave the intestine and pass out into the funnel-shaped exocoelom.

same size. It is now beginning to play a minor rôle, and its omphalomesenteric duct is much smaller in caliber.

In an embryo 10 mm. long (Fig. 8) the yolk-sac is found pushed to one side. It is now connected with the extra-amniotic portion of the umbilical cord by the



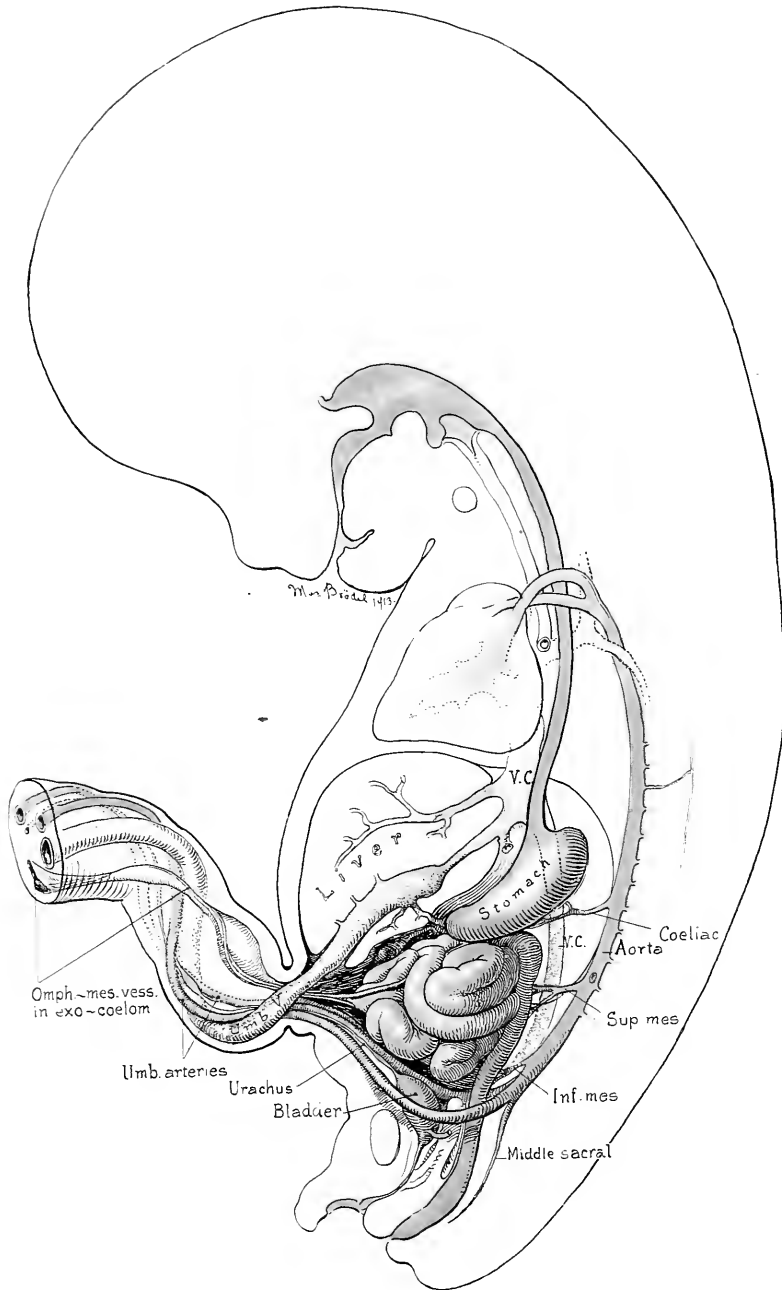


FIG. 13.—SAGITTAL SECTION OF THE UMBILICAL REGION IN A HUMAN EMBRYO 4.5 CM. IN LENGTH.

The intestine has receded completely into the abdominal cavity. The exocoelomic cavity, although small in size is still clearly recognizable in the cord, where it shows spindle-shaped dilatations. It now contains only the omphalo-mesenteric vessels, which have become embedded in its wall. The allantois (urachus) is the distal prolongation of the urinary bladder, and shows already the characteristic dilatations noticeable in older embryos and occasionally found after birth. The structures of the cord show the characteristic twisting of the embryo to the right.

attenuated omphalomesenteric duct and its blood-vessels. These present a twisted appearance. The omphalomesenteric vessels still persist in the cord near the embryo, but the duct at this point has usually disappeared.

By the time the embryo has reached a length of 23 mm. (Fig. 11) the yolk-sac is relatively insignificant, and, although still attached to the cord, is far removed from the site of its insertion into the placenta.

When the embryo is about 5.5 cm. in length (Fig. 31), the yolk-sac, now called

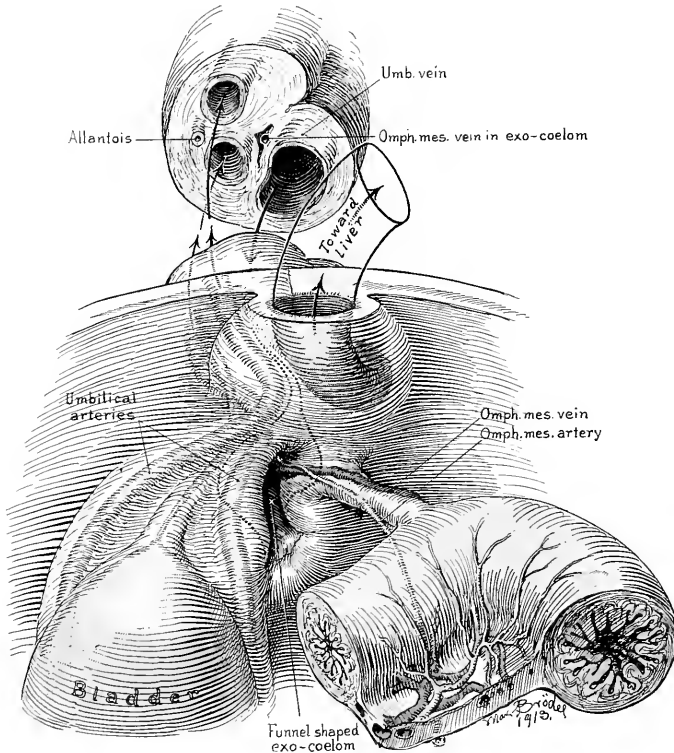


FIG. 14.—A GRAPHIC RECONSTRUCTION OF THE UMBILICAL REGION OF A HUMAN EMBRYO 4.5 CM. IN LENGTH AS VIEWED FROM WITHIN THE ABDOMEN.

Coming from below are the two umbilical arteries with the urachus between them. Above is the umbilical vein, inclosed in a bulbous thickening of the surrounding tissue. The body-wall of the embryo at the cord has closed, save for an irregular slit. The exocoelom outside the general peritoneal cavity dilates, as indicated by the dotted line; it soon becomes obliterated. Plunging into the upper corner of the exocoelom, and adherent to its wall, are the omphalomesenteric vessels, accompanied by a thick cord of embryonic connective tissue, which, near the intestine, has an epithelial center but no lumen. This is undoubtedly a remnant of the omphalomesenteric duct. The section of the cord shown above is taken from near the embryo. It depicts the characteristic position of the allantois, and the narrow, slit-like termination of the exocoelom with the omphalomesenteric vein in its wall, the artery having disappeared.

the umbilical vesicle, is a small, translucent, elongated, and flattened cyst, about 3 by 5 mm., attached to the insertion of the cord into the placenta by a delicate vascular thread—all that remains of the omphalomesenteric structures. The vesicle remains about the same size until birth. It is then recognized as a small, blunt or pear-shaped cyst, lying between the amnion and placenta (Fig. 32). Its pedicle can be traced for a variable distance in the substance of the umbilical cord.

In short, the yolk-sac in the very beginning of life is an important structure. From it the allantois and the gastro-intestinal tract develop, the connecting link

with the body being the omphalomesenteric duct. The omphalomesenteric or vitelline duct in time usually disappears, but, as will be noted elsewhere, traces of the allantois not infrequently persist.

Those wishing for a more detailed description of the umbilical vesicle or yolk-sac, together with the histologic findings, should read the article by Arthur Meyer, published in 1904. Meyer studied the umbilical vesicles of 18 normal human embryos from the Mall collection. In addition he examined a number of pathologic specimens and also some taken from the placenta at birth. He pointed out that the vesicle in the early embryo is lined with one layer of cuboidal epithelium,

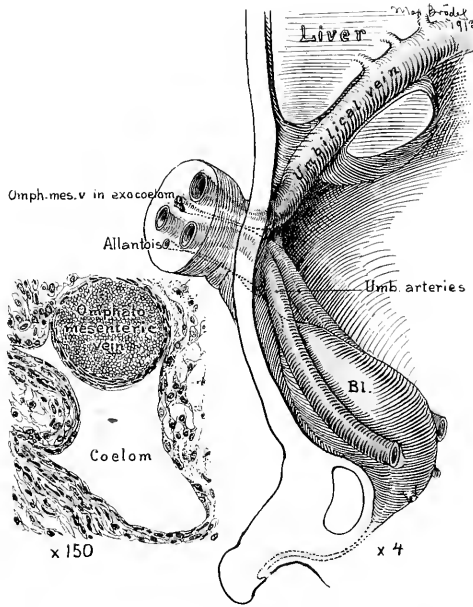


FIG. 15.—SAGITTAL VIEW OF A GRAPHIC RECONSTRUCTION OF THE UMBILICAL REGION OF A HUMAN EMBRYO 5.2 CM. IN LENGTH.

From within, the relations of the umbilical arteries to the vein are clearly seen. They surround the funnel-shaped remnant of the exocoelom. No trace of the omphalomesenteric vessels is to be seen in the peritoneal cavity, but in cross-sections of the cord near the embryo the lumen of the umbilical vein still persists, as indicated in the small drawing to the left. It is embedded in the wall of the exocoelom, but has no connection with any other vascular structure. The bladder bulges out between the umbilical arteries. The urachus (allantois) passes out into the cord between and below the umbilical arteries. This is the characteristic arrangement. The urachus shows two dilatations.

and that, passing out into the walls of the vesicle, are little bays or tubules. He also drew attention to the calcareous material found in the cavity of the vesicle at term. A further consideration of this subject here would carry us too far afield.

### THE BODY-STALK.

In the early stages the embryo rests upon the body-stalk. This fact is clearly shown in Fig. 1. The stalk at this period is much larger than the embryo. It also supports the yolk-sac and the amnion, and through it the blood-vessels of the placenta pass to and from the embryo. When the embryo reaches about 1.7 mm. in length (Fig. 2), the body-stalk is found to be still of about the same size, but its

upper or embryonic portion passes more ventralward and its upper end lies almost directly below the hind-gut. Its blood-vessels have increased materially in diameter. With the development of the embryo and the expansion of the amnion the body-stalk becomes longer and assumes more the appearance of a cord, which is inserted into the ventral surface of the embryo. This is particularly well seen in Fig. 3, which is from an embryo 2.5 mm. long.

When the embryo reaches a length of 3.5 mm. (Fig. 4), the body-stalk closely resembles an umbilical cord. Together with the omphalomesenteric duct, it passes into the amniotic cavity, where the two fuse and become the umbilical cord.

In an embryo 5 mm. long (Fig. 5) the body-stalk, as such, lying outside the amniotic sac, is very short, the amnion lying in almost direct contact with the chorion.

The intra-amniotic portion of the body-stalk will be considered when we come to speak of the umbilical cord.

#### THE ALLANTOIS AND URACHUS.

The allantois is one of the first structures differentiated in the embryo. For example, in an embryo 0.7 mm. long (Fig. 1) it is recognized as a recess of the yolk-sac extending into the body-stalk. It rapidly increases in length, and in an embryo 1.7 mm. long has penetrated deeply into the body-stalk (Fig. 2).

In an embryo 2.5 mm. long (Fig. 3) a portion of the yolk-sac has been definitely differentiated into the digestive tract. Its caudal portion has been carried downward and forward, terminating in the cloaca. The allantois now starts from the cloaca, and, after curving upward, passes outward in the body-stalk to end in a bulbous extremity near the placenta.

In the embryo 5 mm. long (Fig. 5) it still communicates with the cloaca, and, after emerging from the abdomen, passes out in the body-stalk, which now forms an integral part of the umbilical cord.

By the time the embryo is 7 mm. long the allantois has been partially separated from the bowel by the urorectal septum. The lower portion of the allantois has been converted into the bladder (Fig. 7), and its upper part now passes off from the fundus, extending upward and forward and passing out in the cord as heretofore.

Fig. 6, also from an embryo 7 mm. long, shows the relation of the allantois to the umbilical arteries. It lies between and slightly below them, and, whenever found either in the early or in the late stages of fetal life or after birth, it invariably occupies this position.

The patency of the allantois in the umbilical cord varies markedly. Sometimes, even in the early embryo, the duct may be impervious at some points and dilated at others. Thus, in an embryo 12.5 mm. long (Fig. 9) the allantois is obliterated in a cross-section of the cord near the fetus; in a second section a little farther out in the cord it is seen as a somewhat flattened tube, nearly as large as an umbilical artery; in a third section of the cord, still farther out, the allantois forms an irregular sac, the distal end of which terminates in a thread-like process.

Examination of an embryo 23 mm. long (Fig. 11) shows a urachus patent at the point where it emerges from the abdomen. It then becomes impervious, and farther out forms a delicate, spindle-like dilatation.

The intra-abdominal portion of the allantois in the well-differentiated embryo is

called the urachus. Fig. 13, from an embryo 4.5 cm. long, shows the urachus passing upward from the summit of the bladder. In some places it is recognized as a slender filament, but in its course it has two delicate, spindle-like dilatations. The allantois in the cord contains several similar dilatations.

As the embryo becomes larger the bladder may extend somewhat high up, reach-

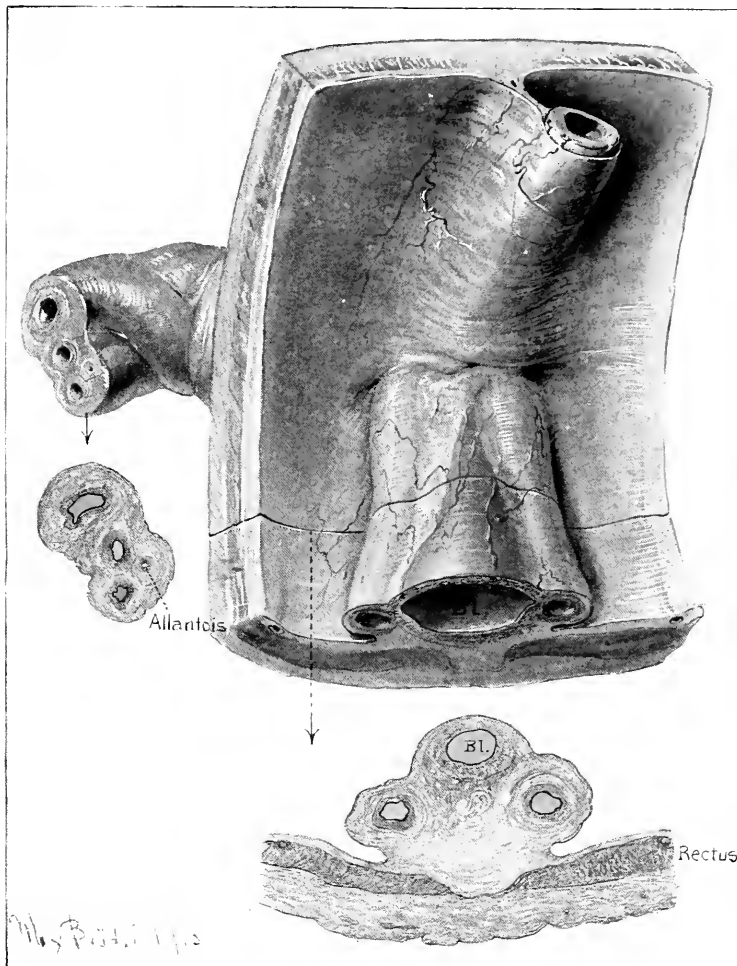


FIG. 16.—INTRA-ABDOMINAL VIEW OF THE UMBILICAL REGION OF A HUMAN EMBRYO 6.5 CM. IN LENGTH. (X 9.)

A portion of the abdominal wall, including the umbilicus, has been excised. The bladder lies between the umbilical arteries and gradually diminishes in caliber toward the umbilicus. This is clearly seen in the cross-section projected in the lower picture. The umbilical vein emerges from the abdominal wall just above the umbilical region. The umbilical opening is closed, its former position being now recognized as several shallow pits in the peritoneum. To the left is a cross-section of the flattened cord, containing, in addition to the umbilical vessels, the allantois, which is obliterated at this point. There are no remnants of either exocoelom or omphalomesenteric structures.

ing almost to the umbilicus. This is seen in Fig. 15, from an embryo 5.2 cm. long. The urachus is short, and just where it enters the cord is seen a spindle-shaped dilatation. A similar dilatation is noted in the outer or allantoic portion. The upward extension of the bladder is well shown in Fig. 16, from an embryo 6.5 cm. in length. A cross-section a little below the umbilicus shows that the bladder at

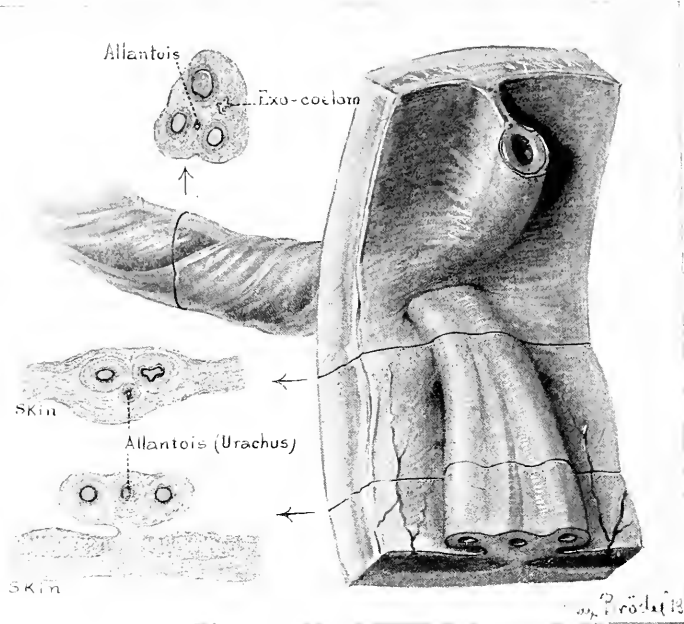


FIG. 17.—INTRA-ABDOMINAL VIEW OF THE UMBILICAL REGION IN A HUMAN EMBRYO 7.5 CM. LONG. (X 6.)

In this case the allantois (urachus) is very narrow, as seen in the cross-section of the abdominal wall, as well as in the cross-section of the cord. The tissues containing the umbilical arteries and urachus are attached to the abdominal wall by a well-defined but narrow mesentery. This, however, is exceptional. At the umbilicus the coelomic ring is obliterated and appears as a crescent between the umbilical arteries and vein. Farther out in the cord, however the exocoelom can still be clearly seen as a small, star-shaped cavity. The cord is markedly twisted.

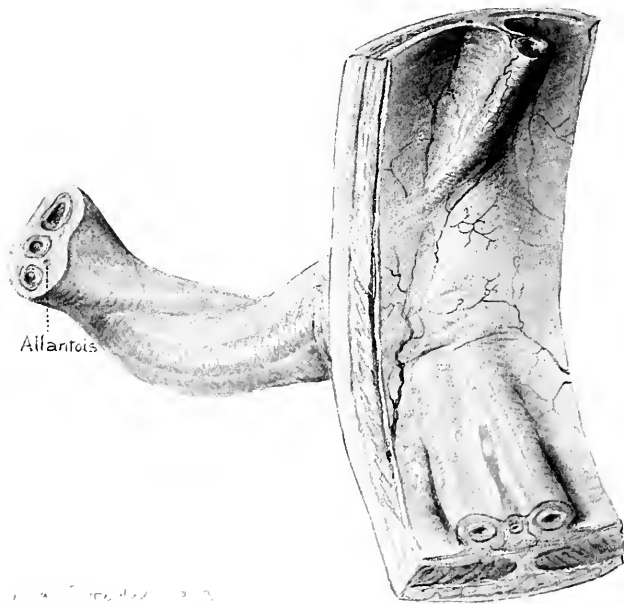


FIG. 18.—INTRA-ABDOMINAL VIEW OF THE UMBILICAL REGION IN A HUMAN EMBRYO 9 CM. IN LENGTH. (X 7.)

The urachus shows a spindle-shaped widening at its upper portion. Microscopically it could, however, be traced in its continuity not only to the umbilicus, but also out into the cord, as indicated by the cross-section of the cord, where it occupies its characteristic position in relation to the umbilical arteries. The umbilical ring is entirely bridged over by a band of subperitoneal connective tissue. A considerable space exists between the umbilical vein and the umbilical arteries. This arrangement closely resembles that noted in the adult. There is no trace of the omphalo-mesenteric structures in the cord.

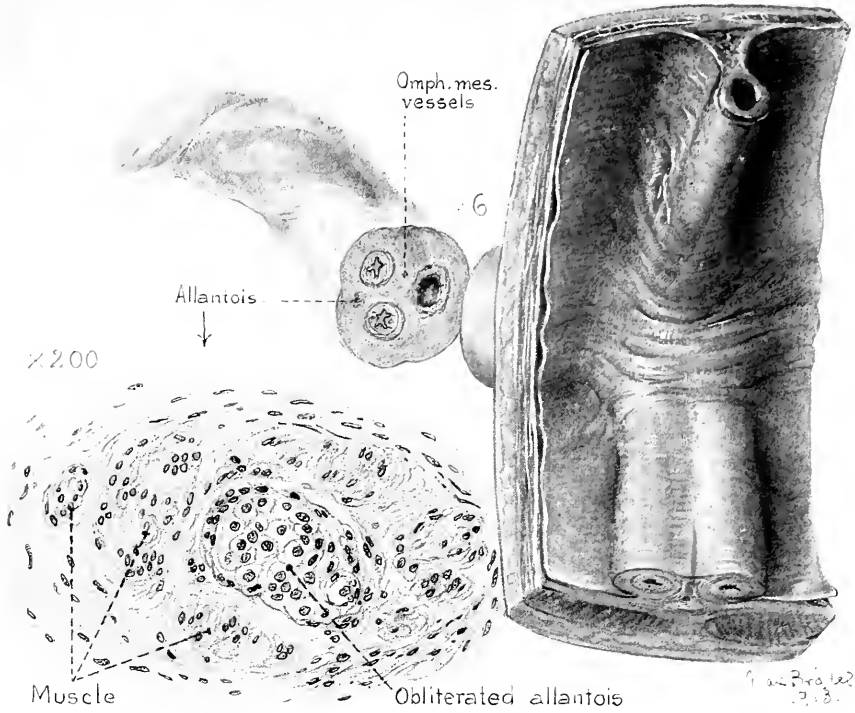


FIG. 19.—INTRA-ABDOMINAL VIEW OF THE UMBILICAL REGION IN A HUMAN EMBRYO 10 CM. IN LENGTH. (X 6.)

The urachus is very narrow, but is continued out into the cord (allantois). In this cross-section of the cord it was recognized as a nest of polygonal cells devoid of a lumen, and surrounded by several bundles of well-defined non-stripped muscle. This muscle surrounded the urachus down to, and merged into, that of the bladder. The umbilical ring is completely sealed over by a broad connective-tissue band. In the cross-section of the cord no remnants of the exocoelomic cavity were demonstrable, but in its place were traces of blood-vessels, evidently remains of the omphalomesenteric vessels.

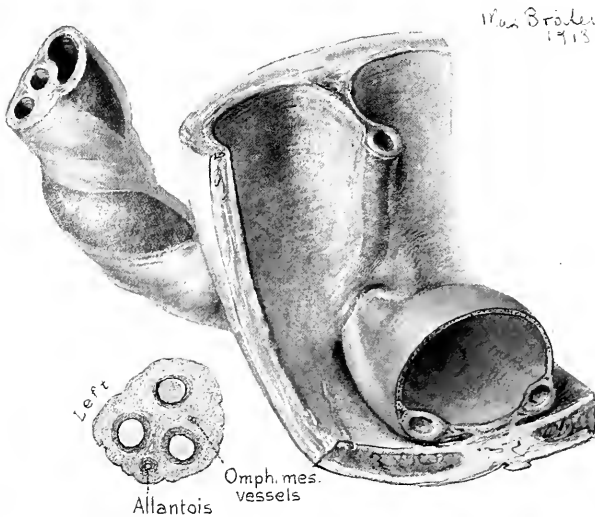


FIG. 20.—INTRA-ABDOMINAL VIEW OF THE UMBILICAL REGION IN A HUMAN EMBRYO 12 CM. LONG. (X 3.)

The bladder is unusually distended, and reaches almost to the umbilicus. Both it and the umbilical vessels have a well-defined mesenteric attachment to the abdominal wall. The bladder was closed above, and the urachus was recognized as a solid cord. In the umbilical cord, however, the allantois showed here and there traces of a lumen. The umbilical ring was completely closed. At its site was a crescent-shaped pit. The exocoelom had disappeared in the cord, but traces of the omphalomesenteric vessels were still visible.

this point is almost tubular. It gradually tapers off, and ends just below the umbilical depression.

It would seem, from an examination of numerous embryos, that the degree of extension of the bladder upward is subject to much variation. Fig. 17 is from an embryo 7.5 cm. long. The bladder is evidently low. Cross-sections near the bladder and also in the neighborhood of the umbilicus show a patent urachus, and a

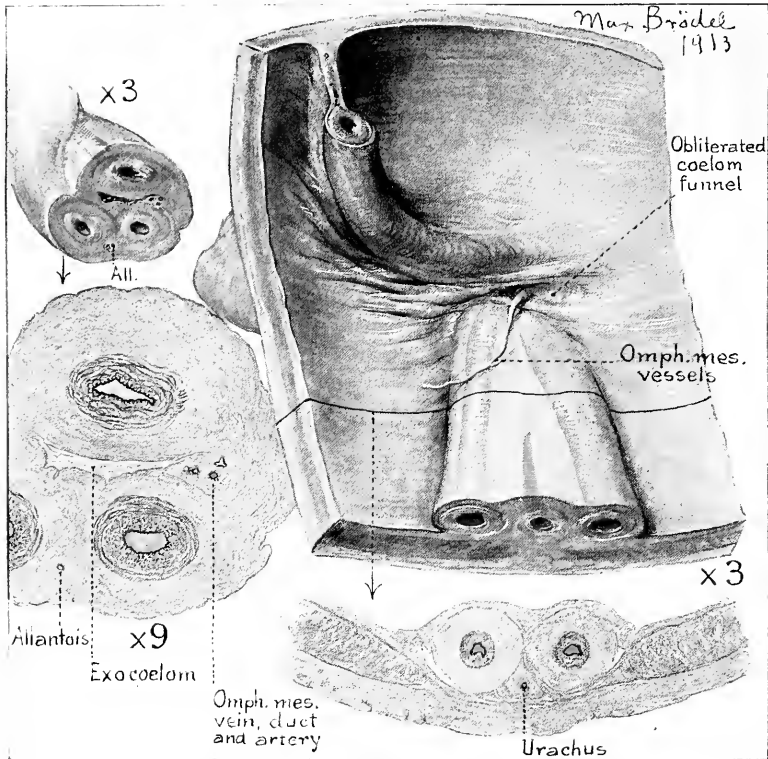


FIG. 21.—INTRA-ABDOMINAL VIEW OF THE UMBILICAL REGION IN A HUMAN EMBRYO 12 CM. IN LENGTH. ( $\times 3$ )

The urachus gradually narrows, but microscopically could be traced as a cord for a considerable distance out into the umbilical cord. In the main it was solid, but here and there appeared to have a lumen. The umbilical vessels now have very well-developed muscular coats, the inner longitudinal layer being especially thick. The umbilical ring shows a puckering, possibly due to the hardening. It is obliterated. Note the oval, funnel-shaped depression between the umbilical arteries and vein. Adherent to the bottom of this is a cord which was attached to a loop of small bowel. This is the remnant of the omphalomesenteric duct or vessels. In the cord the exocoelom is recognized as a slit-like cavity traversed by delicate trabeculae of young connective tissue. At one side of this slit is a dense mass of tissue containing the patent omphalomesenteric vessels, and the duct which appeared as a mass of epithelial cells but showed no lumen.

cross-section of the cord, at some distance from the body, shows that the allantois (urachus) is patent here also.

In Fig. 19, from an embryo 10 cm. long, the cord near the umbilicus shows the allantois, which, however, is obliterated and represented by a solid nest of polygonal cells surrounded by cross-sections of groups of non-striped muscle, showing that the urachus has a longitudinal outer muscular covering.

Figs. 22 and 23, from an embryo 12 cm. long, are very instructive. Fig. 22 shows a cross-section of the abdominal wall made near the umbilicus. Here the



urachus is very small and almost solid. In a section of the cord, at a short distance from the embryo, the allantois is found to be patent and surrounded by one or more layers of the characteristic polygonal cells. This polygonal character of the cells is also clearly shown in Fig. 23, which was taken from the same cord close to the abdominal wall. In Fig. 20, also from an embryo 12 cm. long, the bladder extends almost to the umbilicus.

Figs. 28 and 29 show the relation of the bladder to the umbilicus in embryos of five and about six and one-half months respectively: in both cases it extended almost to the umbilicus.

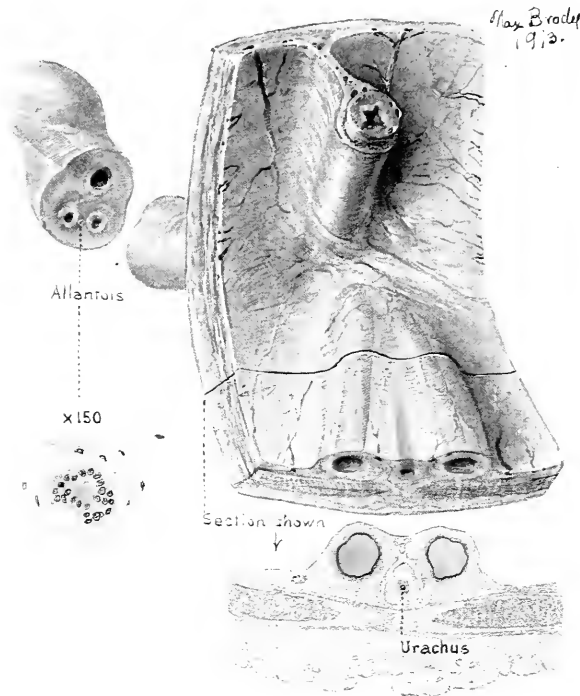


FIG. 22.—INTRA-ABDOMINAL VIEW OF THE UMBILICAL REGION IN A HUMAN EMBRYO 12 CM. IN LENGTH. ( $\times 3$ .)

The urachus is very narrow, as seen in the lower cross-section. In the cord, however, it (the allantois) has at several points a definite lumen lined with polygonal cells. The umbilical ring is completely closed. Fig. 23 gives an external view of the umbilical region of the same embryo.

From the foregoing it is seen that the allantois develops from the yolk-sac; that it is one of the earliest structures to make its appearance, and that, after a time, it is carried downward and forward, coming off from the cloaca. The bladder develops from the lower portion of the allantois. The upper portion of the allantois is continued to the umbilicus and then passes to the cord. Its intra-abdominal portion is now called the urachus.

The urachus and allantois soon become solid cords in a part of their course, but show an inherent tendency to develop spindle-like dilatations at irregular intervals. These dilatations are characteristic of the urachus and allantois, and it should occasion no surprise if they are found at any period in the development of

the embryo. They undoubtedly persist in many persons and account for the small cysts not infrequently noted at operation. That the urachus occasionally remains patent at birth is attested by the number of children with a urinary umbilical fistula at birth. This phase is discussed at length in Chapter XXIX.

The tube composing the urachus and allantois is lined with from one to three

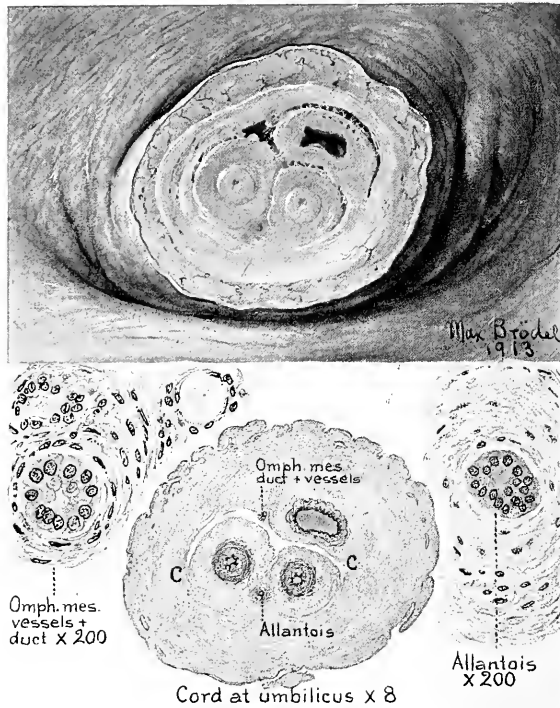


FIG. 23.—CROSS-SECTION OF THE UMBILICAL CORD AT THE UMBILICUS IN A HUMAN EMBRYO 12 CM. IN LENGTH. (X 8.)

This drawing is also from the embryo shown in Fig. 22. In the upper figure the cord has been cut across about 1 mm. from the abdominal wall. The umbilical arteries are surrounded by Wharton's jelly. In the triangle below and between them is a small, opaque cord, the allantois. Above the right umbilical artery an irregular lumen, continued as a slit on either side, represents the disappearing exocoelomic cavity. The slit-like portion above the vein is already partially organized. Surrounding the entire mass is a dense layer of connective tissue, and external to this is the subcutaneous adipose tissue traversed by numerous cutaneous vessels. The lower picture shows a microscopic section still nearer the embryo. The slit-like exocoelom (c, c) stands out much more clearly. In its upper wall are seen the omphalomesenteric vessels and duct. An enlarged view of these is given on the left. Here the omphalomesenteric duct is recognized as a solid nest of epithelial cells. The allantois is visible slightly below and between the umbilical arteries, whose lumina are star-shaped. The drawing to the right shows that the allantois is patent and surrounded by polygonal cells. The allantois here is inclosed in embryonic connective tissue which is devoid of muscle.

layers of transitional epithelium, similar to that of the bladder, and is surrounded by a coat of longitudinal non-stripped muscle.

#### THE CÆLOM.

Without a clear conception of the exocoelom, the early embryologic appearances of the umbilical region cannot well be understood. In the embryo 1.7 mm. long (Fig. 2) a small depression exists at or near the point where the yolk-sac and amnion merge. The arrows indicate the direction that the exocoelom will later follow.

When the embryo has reached a length of 2.5 mm. (Fig. 3), the exocoelom has extended inward between the yolk-sac and amnion; it now completely encircles the omphalomesenteric duct, and has extended upward toward the stomach and downward toward the cloaca. From this picture it can be readily understood why at a later stage the omphalomesenteric duct and its vessels lie in the exocoelomic cavity in the umbilical cord.

The exocoelom, which has extended into the embryo, later unites with the coelomic or pleuroperitoneal cavity.

By the time the embryo reaches a length of 5 mm. (Fig. 5) the body-stalk and the omphalomesenteric duct with its vessels have merged into the umbilical cord,

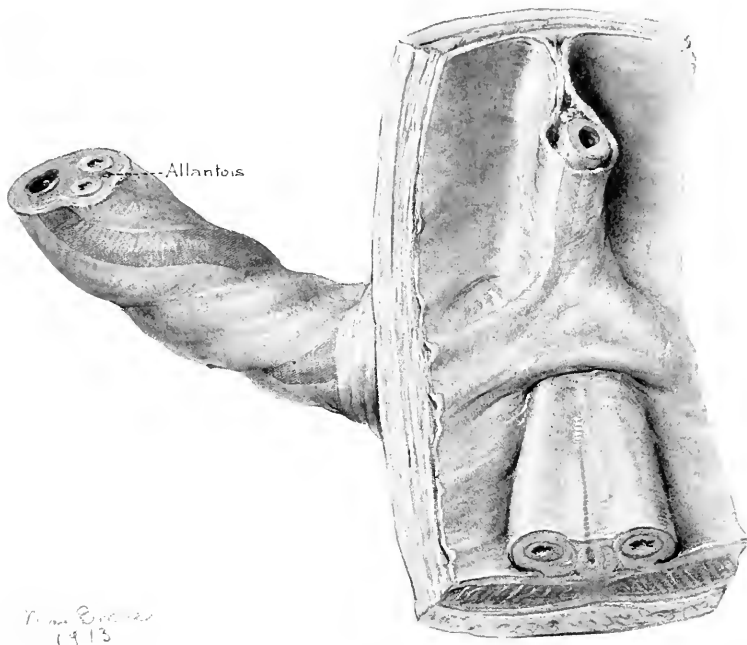


FIG. 24.—INTERNAL VIEW OF THE UMBILICAL REGION IN A HUMAN EMBRYO 15 CM. LONG. (× 4.)

The urachus is very much attenuated, but is still continuous as a cord, with the partially obliterated allantois seen in the cross-section of the cord. The umbilical ring is closed by a firm transverse fibrous band.

and with the fusion it is but natural that the omphalomesenteric structures should still be surrounded by the exocoelom. The portion of the coelom outside the abdomen is referred to as the exocoelom, whereas the intra-abdominal portion, with which it is still continuous, is called the coelom.

As the embryo continues to develop, the omphalomesenteric duct, which is still a part of the small bowel and lies in the exocoelom, evidently makes traction on the gut and draws it out into the exocoelomic cavity. In an embryo 7 mm. long this cavity (Fig. 6) contains the cecum. In another embryo of the same length (Fig. 7) the free opening between the coelom and the exocoelom of the cord is clearly depicted.

When the embryo reaches a length of 10 mm. (Fig. 8), the small bowel, which

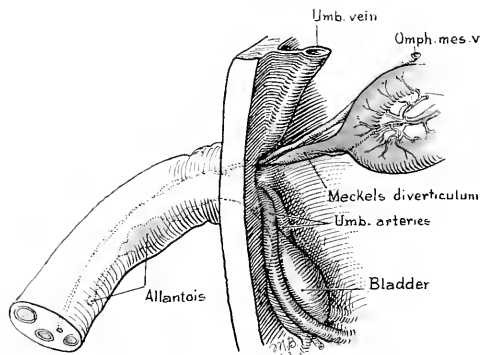


FIG. 25.—A COMPOSITE REPRESENTATION OF ABNORMAL UMBILICAL STRUCTURES BASED ON THE WORK OF KEIBEL, LÖWY, AND OTHERS.

The bladder gradually tapers into the urachus and is obliterated at the umbilicus. In the cord are seen numerous dilations of the allantois (urachus). The omphalomesenteric duct (Meckel's diverticulum) goes to the umbilicus, where it becomes lost in the coelomic funnel. It is accompanied by the omphalomesenteric vessels. The artery terminates in its wall; the vein continues and becomes lost in the exocoelom of the cord.

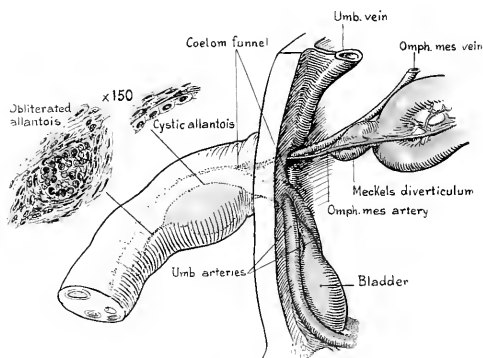


FIG. 26.—A COMPOSITE REPRESENTATION OF ABNORMAL UMBILICAL STRUCTURES BASED ON THE WORK OF KEIBEL, LÖWY, AND OTHERS.

The allantois in the cord shows one large and one small dilatation. The large dilatation is lined with one layer of flattened epithelium. The obliterated cord between the dilations consists of closely packed epithelial cells. The inner end of the omphalomesenteric duct persists as a sac-shaped Meckel's diverticulum. Its vessels continue on into the coelomic funnel at the umbilicus, but become lost in the exocoelom of the cord.

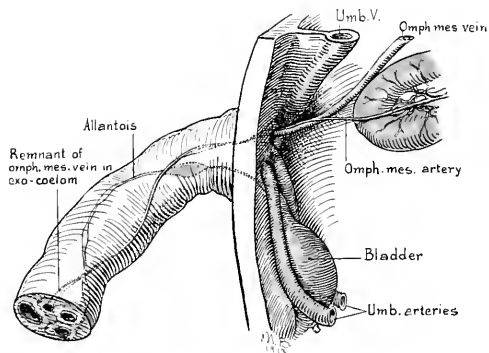


FIG. 27.—A COMPOSITE REPRESENTATION OF ABNORMAL UMBILICAL STRUCTURES BASED ON THE WORK OF KEIBEL, LÖWY, AND OTHERS.

The allantois shows numerous spindle-shaped dilations in the cord, with obliterated portions between. The omphalomesenteric duct has disappeared, but the vessels still persist, the vein continuing farther out than the artery.

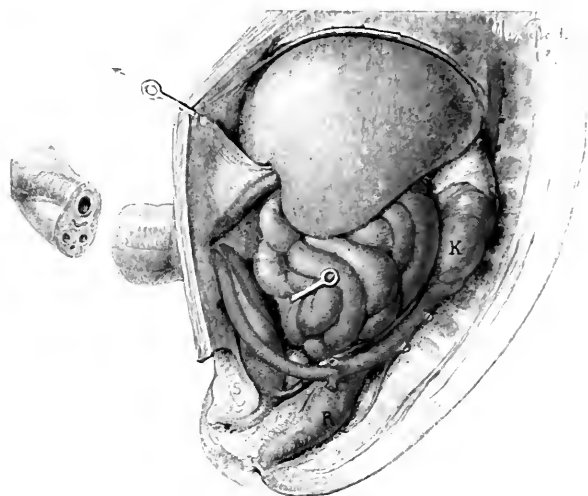


FIG. 28.—THE UMBILICAL REGION IN A FETUS ABOUT FIVE MONTHS OLD VIEWED FROM THE LEFT.

Note the portion of the triangular falciform ligament between the umbilical vein and the ventral abdominal wall. The bladder and allantois (urachus) are in the usual position; the latter is becoming obliterated. In the cord it appears below and between the umbilical arteries. In the center of the cord is the sickle-shaped lumen of the exocoelom, which, however, is bridged over in many places by delicate strands of connective tissue. In the abdomen a shallow pit still marks the position of the umbilical ring.

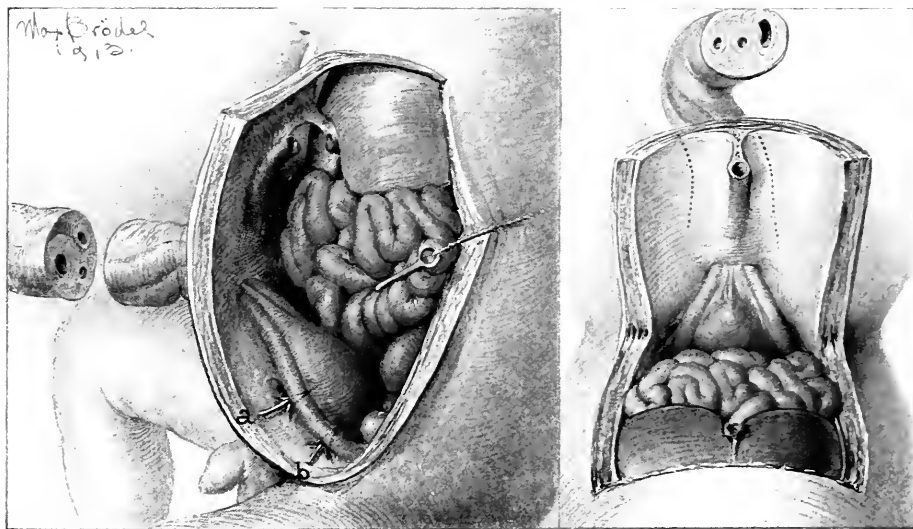


FIG. 29.—SIDE AND POSTERIOR VIEWS OF THE UMBILICAL REGION IN A FETUS OF SIX TO SEVEN MONTHS.

The left figure shows the characteristic recesses (*a, b*) between the umbilical artery and the abdominal wall. (See also Figs. 17, 20, and 24.) The bladder reaches nearly to the umbilicus, the urachus being very short. In the section of the cord shown, neither the allantois nor the omphalomesenteric structures could be demonstrated. The falciform ligament of the liver is very short; hence the close union between the umbilical vein and the abdominal wall. The umbilical ring is closed by a broad band of connective tissue. The figure to the right shows the characteristic triangular shape of the upper part of the bladder, and also its sudden narrowing into the urachus above.

consists of one long loop, is found extending for quite a distance out into the cord. It lies free in the exocoelom, and is accompanied by the vessels of the omphalomesenteric duct. A somewhat similar picture was noted in the cord of an embryo 12.5 mm. long (Fig. 9).

With the continued development of the embryo and the simultaneous increase in the number of the intestinal loops, more and more of the intestine develops in the exocoelomic cavity. Fig. 10 represents the findings in an embryo 18 mm. long; Fig. 11, those in an embryo 23 mm. in length.

The maximal size of the exocoelomic cavity in the cord is probably reached when the embryo is about 30 mm. in length (Fig. 12). In this picture the exocoelomic cavity appears to the right of the solid portion of the cord. It contains nearly all of the bowel.

By the time the embryo has reached a length of 4.5 cm. (Figs. 13 and 14) the intestine has receded into the abdomen and a section of the cord near the body will reveal only a trace of the exocoelomic cavity. This is recognized as a more or less triangular slit, containing only the omphalomesenteric vessels. In Fig. 15, taken from an embryo 5.2 cm. long, a small exocoelomic cavity still exists, and adherent to its upper wall is the patent omphalomesenteric vein.

Even in embryos 12 cm. long (Figs. 21 and 23) slit-like traces of the exocoelom may be found in the cord near the fetus.

To the clinician the chief interest in the exocoelom lies in the fact that in rare instances the intestine does not entirely recede, but remains incarcerated in this extra-abdominal cavity, giving rise to the large ventral herniæ occasionally noted at birth.

#### THE UMBILICAL VESSELS.

These consist of two arteries, and in the beginning of two veins, the right and the left. The left vein is the larger and persists; the right disappears before the embryo is 10 mm. long.

Even in the very early embryo, 0.7 mm. long (Fig. 1), the umbilical arteries and veins are seen in the body-stalk. At this stage they convey the placental blood to and from the primitive embryo. By the time the embryo is 1.7 mm. long (Fig. 2) the umbilical arteries, after passing along the primitive digestive tract, enter the body-stalk beside the allantois and divide into many placental branches. Just before entering the embryo, the umbilical vein divides into two branches. These pass up the right and left abdominal wall to unite with the hepatic circulation.

In the embryo 2.5 mm. in length (Fig. 3), the cord is seen to contain two umbilical arteries and one umbilical vein, which at the embryo divides into two trunks, the right and the left. The umbilical arteries pass downward toward the caudal extremity of the embryo; the vein goes upward toward the liver.

When the embryo has reached 5 mm. in length (Fig. 5), we still find the two umbilical arteries, which, after passing along the cord, enter the ventral surface of the embryo and pass downward.

Fig. 6, from an embryo 7 mm. long, shows clearly the relations of the right and left umbilical veins. The left umbilical vein is very large and runs upward to the

liver. The right vein is much smaller, lies partly embedded in the abdominal wall, and is soon completely lost.

In the embryo 23 mm. long (Fig. 11) the umbilical vein is clearly seen entering the substance of the liver. The umbilical arteries, in the cord as well as in the abdomen, lie on either side of the allantois. They pass downward to the pelvis.

In the embryo 4.5 cm. long (Fig. 13) the vein is seen at the umbilicus, curving from the lower to the upper portion of the cord, and passing directly into the substance of the liver, which at this time reaches almost to the umbilicus. The umbilical arteries at this period in the development of the embryo, after passing to either side of the allantois (urachus), skirt along each side of the bladder. They originate from the lower portion of the aorta.

The subsequent relation of the umbilical vessels is clearly depicted in Figs. 28

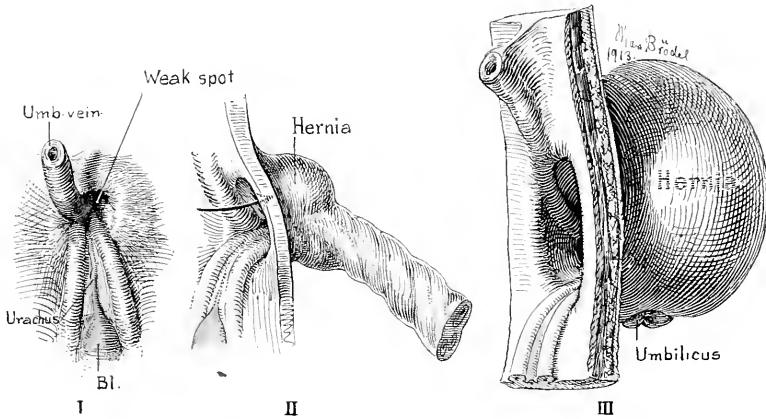


FIG. 30.—THREE DIAGRAMS OF THE UMBILICAL RING AND ITS SIGNIFICANCE IN THE DEVELOPMENT OF VENTRAL HERNIA.

I. Dissection of the umbilical ring in a human embryo eight months old, viewed from within. The peritoneum and subperitoneal connective tissue, containing a small amount of fat, have been carefully removed, exposing a funnel-shaped opening above and to the right of the umbilical arteries. The umbilical vein lies to the left of this weak spot. The umbilical arteries are the strongest structures in the wall of the ring, and a hernial protrusion usually occurs above or to one side of them. Occasionally the umbilical vein is situated to the right of the ring, in which case the weak spot would be on the left side.

II. Side-view of the umbilical ring, showing the favorite position of the small hernial protrusion often seen in newborn babes.

III. A larger hernia, representing a later stage of the same type. Note how the umbilicus becomes lodged at the lower portion of the hernial pouch.

and 29. The relation of the umbilical vessels at term is well shown in Fig. 30. The umbilical vein is of large size, and passes directly from the umbilicus to the substance of the liver. It is supported by the suspensory ligament of the liver, as is graphically shown in Figs. 28 and 29. The umbilical arteries lie on either side of the urachus, pass downward on each side of the bladder, and are connected with the anterior division of the internal iliac arteries. After birth the distal portions of their lumina become narrower, and the vessels finally appear as the obliterated hypogastric arteries. Their last pervious branches are the superior vesical arteries.

It was along the umbilical vein and the umbilical arteries that infections of the new-born were so prone to occur in preaseptic days. (See Chapter III.)

The inner appearance of the umbilicus at birth is shown in Fig. 32. Shortly

after birth the umbilical vein and the umbilical arteries become impervious (Fig. 61). In the adult the thickened outer edge of the suspensory ligament of the liver represents what remains of the umbilical vein; below the umbilicus are three cords which are usually solid, the central one passing to the summit, the others to the right and left of the bladder. These three cords are the remnants of the urachus and of the umbilical arteries.

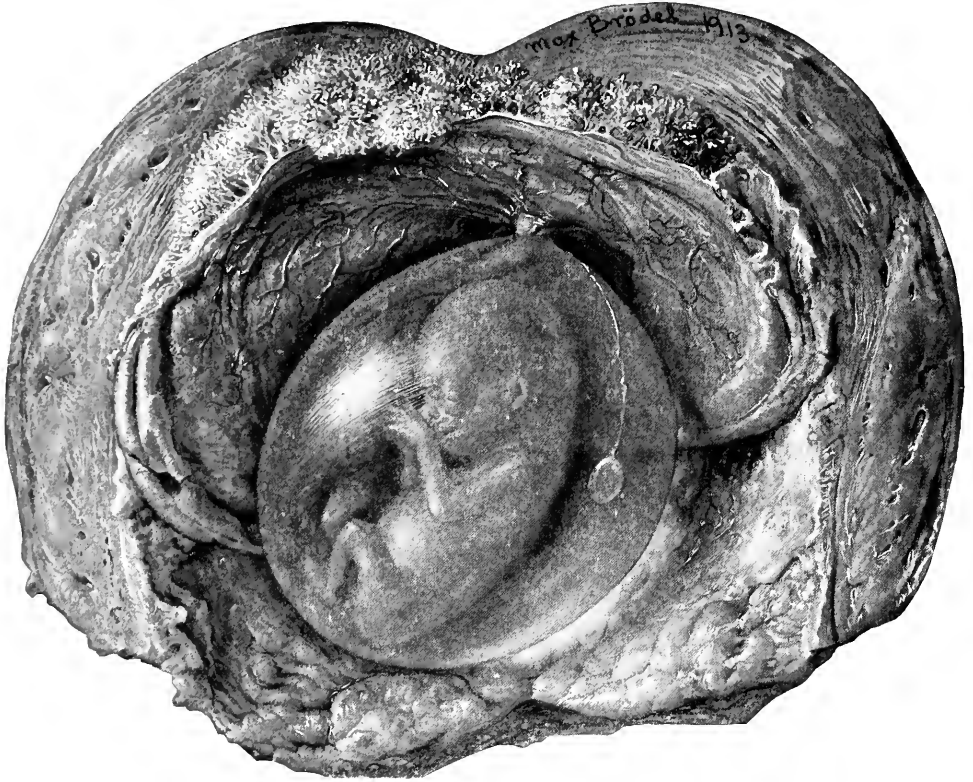

FIG. 31.—THE APPEARANCE OF THE YOLK-SAC (UMBILICAL VESICLE) IN A PREGNANCY, WITH THE EMBRYO 5.5 CM. LONG.

The chorion has been split and turned back on the uterine wall. The amniotic cavity is still intact, appearing as a tensely filled oval cyst containing the embryo. Coming from the placental attachment of the umbilical cord is a delicate vascular thread which passes to the flattened, yellowish, opaque yolk-sac, now referred to as the umbilical vesicle. It remains approximately this size until birth. (See Fig. 32.)

#### THE UMBILICAL CORD.

In the very early embryo, as shown in Figs. 1 and 2, there is no umbilical cord as such, but it is represented by its chief constituent, the body-stalk.

By the time the embryo reaches 2.5 mm. in length there has come into existence what might be termed the primitive cord (Fig. 3). This is composed of the omphalomesenteric duct and the body-stalk, both of which pass into the ventral surface of the embryo. The omphalomesenteric duct occupies the upper or fragile part of the cord, and is surrounded by exocoelom. The lower and firmer part of the cord contains the umbilical arteries, the umbilical vein, and the allantois.

When the embryo reaches 3.5 mm. in length (Fig. 4), the amnion has completely encircled the embryo. Outside the amniotic sac the omphalomesenteric



duct and body-stalk are separate, but within the sac they have become more or less fused, forming the umbilical cord.

In the embryo 5 mm. long this fusion of the cord is clearly seen (Fig. 5). The outer walls of the cord show some degree of organization. In the upper part of the cord is the exocœlomic cavity, communicating with the intra-abdominal portion, and containing the omphalomesenteric duct and its vessels. In the lower part of the cord are the component parts of the body-stalk, the umbilical vein, the two umbilical arteries, and the allantois.

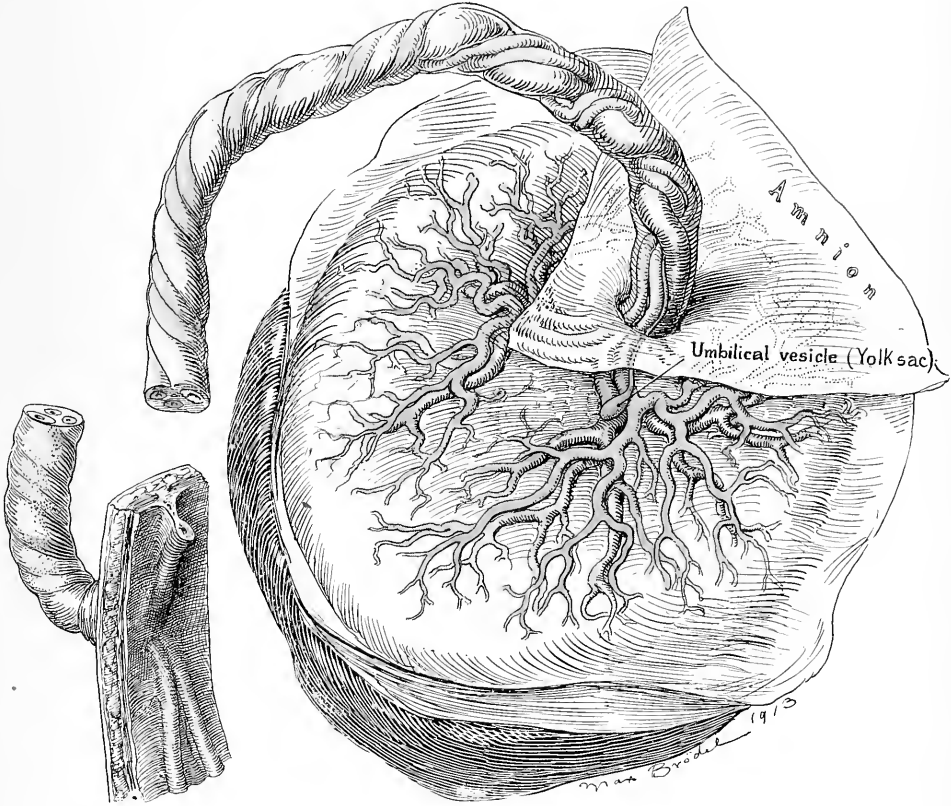


FIG. 32.—THE UMBILICAL REGION, THE CORD, AND THE PLACENTA AT TERM. (About half natural size.) The greater part of the cord has been omitted as irrelevant. The yolk-sac still persists as the umbilical vesicle, between the amnion and the chorion. Its duct, however, after traveling a short distance, becomes lost in the cord.

A similar picture is shown in the embryo 7 mm. long (Figs. 6 and 7). In the former picture it will be noted that the exocœlomic cavity, that is, the portion in the cord, has increased in size, and that it contains, in addition to the omphalomesenteric duct, a small portion of the bowel. The umbilical arteries lie in the lower portion of the cord, and between them, and at a slightly lower level, is the allantois. The umbilical vein usually lies to the left of the arteries (to the right in the picture).

When the embryo is 10 mm. in length (Fig. 8), the vein lies in the upper wall of the cord. The exocœlomic cavity contains the omphalomesenteric duct, to

which a loop of small bowel is attached; and situated in the lower part of the cord are the umbilical arteries and the allantois. The outer part of the cord, even at this early date, shows a tendency to become twisted.

Examination of the cord in an embryo 12.5 mm. long (Fig. 9) shows an exocoelomic cavity varying considerably in diameter. This cavity near the body contains small intestine and the omphalomesenteric artery and vein, but a little farther out only the omphalomesenteric duct and its vessels. The remaining portion of the cord contains the umbilical arteries, the umbilical vein, and the allantois. The allantois at some points is a flaccid tube, but at other points shows sac-like dilatations. It finally tapers off and ends in a point.

In the embryo 18 mm. long (Fig. 10) the cord near the umbilicus is distinctly enlarged. This enlargement is due to a marked dilatation of the exocoelomic cavity, which contains almost all the bowel, including the cecum and the omphalomesenteric vessels. A section farther out in the cord shows a small prolongation of the exocoelom, containing the omphalomesenteric vessels and cross-sections of the umbilical arteries, the umbilical vein, and the allantois.

A longitudinal section of the cord in an embryo 23 mm. long presents an interesting picture (Fig. 11). Near the embryo the upper wall of the cord contains small, cyst-like spaces, which represent areas undergoing organization. The exocoelomic cavity is large, and contains nearly all the small bowel. Passing out between the coils of small intestine are the omphalomesenteric artery and vein, which are continued far out into the solid portion of the cord. In the lower wall of the cord are the umbilical arteries, the umbilical vein, and the allantois, which at some points is solid and at other points can be recognized as spindle-like dilatations. At this stage the cord shows marked twisting in its outer portion, and a cross-section here shows the umbilical arteries and vein, with remnants of the omphalomesenteric vessels and of the allantois.

The umbilical cord of an embryo 30 mm. long (Fig. 12) shows an even greater enlargement near the embryo. This is due to the passive increase in size of the exocoelomic cavity, which now contains many loops of small bowel. Passing out between these loops are the omphalomesenteric vessels, which traverse the exocoelomic cavity, and continue their course outward in a narrow chink of the exocoelom. The solid portion of the cord is small in comparison with the exocoelomic cavity. It contains the umbilical arteries and vein, as well as the allantois.

By the time the embryo reaches 45 mm. in length (Figs. 13 and 14) the intestine has usually receded into the abdomen. The exocoelomic cavity is very small, and contains only the omphalomesenteric vessels. A cross-section of the cord near the umbilicus now contains, in addition to the umbilical arteries and vein, a small chink of exocoelom with the omphalomesenteric vessels in its interior, and the allantois. The allantois varies much in diameter: in some places it is a solid cord; at other points it shows spindle-like dilatations (Fig. 13). A cross-section of an embryo 5.2 cm. in length presents a precisely similar picture. In Fig. 15 a cross-section of the omphalomesenteric vein is seen adherent to a small exocoelomic space.

From this time until birth the cord shows only a few minor variations. The relation of the vein to the arteries naturally varies according to the amount of twisting of the cord, but the relation of the allantois to the arteries is constant. It lies between and slightly below the arteries.

Fig. 16 gives a cross-section of the cord in an embryo 6.5 cm. long.

Fig. 17 gives a cross-section of the cord in an embryo 7.5 cm. long.

Fig. 18 gives a cross-section of the cord in an embryo 9.0 cm. long.

Fig. 19 gives a cross-section of the cord in an embryo 10.0 cm. long.

Fig. 20 gives a cross-section of the cord in an embryo 12.0 cm. long.

Fig. 21 gives a cross-section of the cord in an embryo 12.0 cm. long.

Fig. 22 gives a cross-section of the cord in an embryo 12.0 cm. long.

Fig. 23 gives a cross-section of the cord in an embryo 12.0 cm. long.

Fig. 24 gives a cross-section of the cord in an embryo 15.0 cm. long.

In embryos 12 cm. in length the patent allantois may be detected in the cord at a considerable distance from the fetus (Fig. 22). Remnants of the omphalomesenteric duct in the cord, as seen in Fig. 21, are very rare.

### THE OMPHALOMESENTERIC DUCT.

In the very early embryo the yolk-sac is intimately attached to its ventral surface (Fig. 1), and in a short time extends into the embryo, forming the fore-gut and the hind-gut (Fig. 2). The amnion rapidly encompasses the embryo, and pushes the yolk-sac away. Inasmuch as part of the yolk-sac already forms the digestive tract, it is firmly anchored to the embryo. The rest of the yolk-sac still retains its connection with the digestive tract by a drawn-out and narrow portion, which is called the omphalomesenteric or vitelline duct (Fig. 3). The yolk-sac proper, the omphalomesenteric duct, and the primitive digestive tract, at this stage, form various portions of one and the same cavity. The omphalomesenteric duct can be recognized in the embryo 2.5 mm. long. It will be noted in Fig. 3 that the omphalomesenteric duct is surrounded on all sides by exocoelom; in other words, it lies in the exocoelomic cavity.

In an embryo 5 mm. in length (Fig. 5) the first loop of small bowel is seen, and passing off from its convexity is the omphalomesenteric or vitelline duct. This duct, accompanied by the omphalomesenteric artery and vein, passes outward in the exocoelomic cavity of the cord, and emerging from the amniotic sac reaches the yolk-sac.

When the embryo reaches 7 mm. in length (Fig. 6) a loop of small bowel can be seen in the exocoelomic cavity of the cord, and projecting from its convex surface the patent omphalomesenteric duct. Accompanying the duct are the omphalomesenteric artery and vein.

In another embryo of the same length (Fig. 7) we note that the duct has already lost its connection with the small bowel. Beyond this point, however, it is patent and appears as a bulbous dilatation in the cord a short distance from the embryo. Hence it is evident that variations may exist and that the duct may or may not still be connected with the small bowel when the embryo is 7 mm. long.

A study of Fig. 8, from an embryo 10 mm. in length, shows that the first loop of small bowel extends far outward in the exocoelomic cavity of the cord. It is accompanied by the omphalomesenteric vessels, which are continued out into the cord for the entire length, terminating in the yolk-sac. The duct accompanies the vessels as far as the yolk-sac.

In Fig. 9, from an embryo 12.5 mm. long, the omphalomesenteric duct is patent in the exocoelom, and apparently still communicates with the small bowel. The

duct is lined with one layer of low cuboid epithelium. The patent portion can be traced outward in the cord; it forms a bulbous dilatation near the yolk-sac, into which it opens. The yolk-sac also is lined with one layer of cuboid epithelium.

In the embryo of 18 mm. (Fig. 10) all trace of the omphalomesenteric duct is lost, but its vessels are still found in the cord. They lie in a funnel-shaped pro-

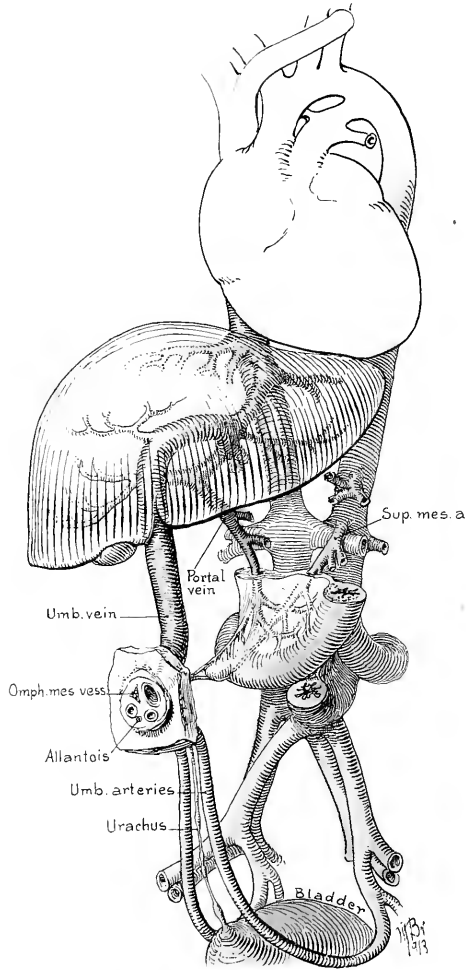


FIG. 33.—A DIAGRAMMATIC REPRESENTATION OF THE UMBILICAL REGION OF A FETUS AT TERM.

An exceptional feature of the picture is the persistence of the omphalomesenteric structures in the form of a well-defined vascular Meckel's diverticulum. Note the relationship between the omphalomesenteric vessels, the superior mesenteric artery, and the portal vein. In the cord the vitelline vessels still persist in the organized exocoelom. At birth all trace of the omphalomesenteric structure has usually disappeared, but the allantoic cord often persists, and is seen between and below the umbilical arteries. It is continuous with the urachus, which may have a number of spindle-shaped dilatations down to the bladder. These may or may not have lumina.

longation of the exocoelom. These vessels can be easily followed in Figs. 11, 12, 13, 14, and 20. Generally speaking, the omphalomesenteric duct usually disappears when the embryo is between 4 and 12 mm. in length, but its vessels persist long after the duct has disappeared.

In the earliest stages the omphalomesenteric arteries are two in number; they

pass out on each side of the yolk-sac. They arise from a plexus of from two to four smaller vessels directly from the aorta. The left artery disappears, the right persists, follows the omphalomesenteric duct, and terminates in a network over the entire yolk-sac (Figs. 2, 4, and 5). The proximal portion of the omphalomesenteric artery later becomes converted into the superior mesenteric artery.

In the beginning the omphalomesenteric veins are two in number. The right disappears; the left collects the blood from the entire yolk-sac and from the omphalomesenteric duct, and in the liver anastomoses with the left umbilical vein. Before entering the liver it receives tributaries from the intestine (*vena mesenterica superior*, Fig. 7). It later forms the portal vein.

In Fig. 14, from an embryo 4.5 cm. long, the omphalomesenteric duct still persists as a cord passing from the intestine to the abdominal wall. It consists of embryonic connective tissue and has an epithelial center, but no lumen.

Fig. 23 is a cross-section of the umbilical cord near the abdominal wall of an embryo 12 cm. long. The omphalomesenteric duct is recognized as a solid epithelial cord. Its blood-vessels are still patent.

Although the duct usually disappears early in the embryologic development, it is occasionally found patent at birth. In other cases only a portion of the duct remains. When the duct remains patent, an umbilical fecal fistula develops as soon as the cord comes away. If the inner end be patent, we have a Meckel's diverticulum (Fig. 26). This may or may not be adherent to the umbilicus (Fig. 25). In rare instances the duct is obliterated both at the intestine and at the umbilicus, but the median portion persists. In such a case we have an intestinal cyst. In a few cases remnants of the duct have been detected in the umbilical region between the peritoneum and the abdominal wall. One of the most frequent sites for remains of the duct is at the point of attachment of the umbilical cord. In such cases, when the cord comes away, a small, raspberry-like mass will be noted at the navel. Occasionally the omphalomesenteric vessels may still persist as imperious fibrous cords (Fig. 21). These have in some instances given rise to intestinal obstruction. All these conditions which produce definite clinical entities will be discussed fully in subsequent chapters.

#### LITERATURE CONSULTED ON EMBRYOLOGY OF THE UMBILICAL REGION.

- Ahlfeld, Fr.: Die Allantois des Menschen und ihr Verhältnis zur Nabelschnur. *Arch. f. Gynäk.*, 1876, x, 81.
- Cazin, Henry: Étude anatomique et pathologique sur les diverticules de l'intestin. Thèse de Paris, 1862, No. 138.
- Freer, James A.: Abnormalities of the Urachus. *Ann. of Surg.*, 1887, v, 107.
- Ledderhose, G.: Chirurgische Erkrankungen des Nabels. *Deutsche Chirurgie*, 1890, Lief. 45 b.
- Löwy, H.: Die Rückbildung der Allantois beim Menschen. *Arch. für Anat. und Physiologie*, Anat. Abth., 1905, 159-176.
- Meyer, Arthur: On the Structure of the Human Umbilical Vesicle. *Amer. Jour. Anat.*, 1904, iii, 155.
- Monod, J.: Des fistules urinaires ombilicales dues à la persistance de l'ouraque. Thèse de Paris, 1899, No. 62.
- Vaughan, George T.: Patent Urachus. Review of the cases reported. Operation on a case complicated with stones in the kidneys. A note on tumors and cysts of the urachus. *Trans. Amer. Surg. Assoc.*, 1905, xxiii, 273.
- Mall, Franklin P.: *Jour. Morphology*, 1891, v, 459-477.

## CHAPTER II.

### THE ANATOMY OF THE UMBILICAL REGION.

The appearance of the umbilicus from without.  
Personal clinical studies of the various forms of the umbilicus.  
The umbilicus as viewed from its peritoneal side.  
Varieties of the fibrous ring.  
Disposition of the vessels.  
Peri-umbilical veins.  
Varieties of umbilical fascia.  
Elevation of the peritoneum in the form of a mesentery.  
Peritoneal fringes containing fat.  
Diverticula.  
Clinical examples of defects of the abdominal wall.  
Relation of the outside of the umbilicus to the peritoneal side.  
The umbilicus in animals.  
The lymphatics of the umbilical region.  
The sensory nerve-supply of the umbilicus.  
The skin umbilicus.  
The amniotic umbilicus.  
Absence of the umbilicus.  
The umbilicus during pregnancy.

KÜSTER, in 1874, in his paper, "New Growths of the Umbilicus in the Adult and Their Operative Treatment," briefly refers to the anatomy of the umbilical region.

He enumerates the layers of the abdominal wall in the region of the umbilicus as follows:

1. The skin.
2. The superficial fascia and more or less fat.
3. The superficial sheath of the abdominal muscle.
4. The rectus abdominalis.
5. The deep layer of the sheath.
6. The subperitoneal connective tissue.
7. The peritoneum.

In the mid-line of the abdomen layers 3-5 are replaced by a thick cord of connective tissue, forming the linea alba, which, at the umbilicus, may reach 1 cm. in breadth.

The umbilical scar contains four fetal structures: (1) the umbilical vein, which passes to the liver along the suspensory ligament; (2) and (3), the umbilical arteries, passing downward and outward to the bladder; (4) the urachus, which passes to the bladder.

### THE APPEARANCE OF THE UMBILICUS.

Catteau in his thesis, in 1876, on the Umbilicus and its Modifications in cases of Abdominal Distention, refers in some detail to the appearance of this region.

According to this author, the typical umbilicus presents a circular cushion or base, which forms the elevated outer margin of an area showing a hollow, from the bottom of which arises an elevation which Catteau calls the *mamelon*. Situated in or near this elevation is the umbilical scar. Between the *mamelon* and the umbilical cushion is a definite furrow. Fig. 34 shows roughly the component parts of Catteau's typical umbilicus.

Probably the most thorough study of the subject was made by Bert and Viannay, who, in over one hundred cases, made molds of the umbilicus. The following is taken from some of the more important portions of their article: The umbilicus is a depression in the skin, at the bottom of which is concealed the cicatrix left by the throwing off of the cord. This cicatrix is drawn inward by the retraction of the umbilical vessels and of the special tissue which surrounds them (Wharton's jelly). Bert and Viannay set out to study more especially the morphology of the outside of the umbilicus, inasmuch as investigations bearing upon this special point up to that time had been lacking. They claimed that their method was superior to that employed by Catteau, who had relied on sketches made at the bedside of the patient, which lack both the exactness and the fidelity of molds. Their work was based on the comparative study of 112 models made in different hospitals, from individuals whose ages varied from two and one-half to seventy-seven years. More than half of the patients were males. They were taken as they came, without being selected, except that none presenting a pathologic umbilicus, distended by an intraperitoneal effusion or by a hernial sac, was included.

The examination of the molds at once impressed these observers with the fact that the form of the umbilicus presents a great variability, rendering a definite classification somewhat difficult. Nevertheless, a certain number of types can be distinguished. In one the umbilicus has its longest diameter directed transversely—the *transverse umbilicus*. In another, on the contrary, the prominence is vertical—the *vertical umbilicus*. Furthermore, in a third type—the *round umbilicus*—the vertical and transverse diameters are more or less equal.

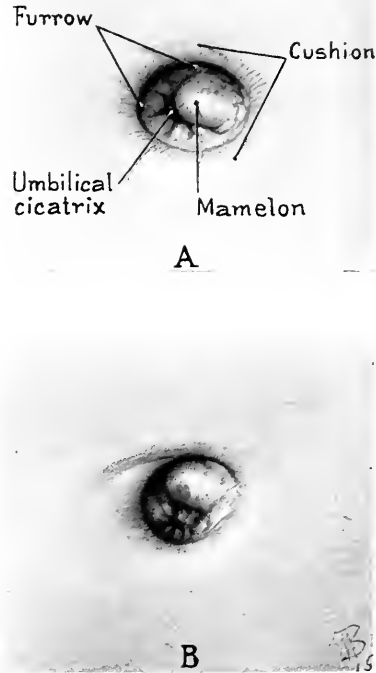


FIG. 34.—NORMAL UMBILICUS ACCORDING TO CATTEAU.

*A* represents the scheme of the normal umbilicus as described by Catteau. This so-called typical umbilicus consists of a cushion and a central depression, in the bottom of which are two structures—a *mamelon* which is more or less prominent, and the umbilical cicatrix. The *mamelon* must be regarded as the remains of the solid lower part of the fetal cord which contained the umbilical arteries and urachus (allantoic stalk). The cicatrix, on the other hand, seems to be due to the puckering of the skin over the region where the exocoelomic funnel has left the embryo. The *mamelon* is said to lie, as a rule, to the left of the umbilical cicatrix, as indicated here. We have, however, observed the reverse. (See Plate II, No. 22.) The projection of the *mamelon* from the umbilical depression naturally gives rise to a surrounding furrow.

*B* illustrates the only example of this type that we have encountered in about 200 cases, and consequently our findings do not substantiate the claims of Catteau.

Between these three main types can be found a large variety of intermediary forms. Sometimes, even after careful examination, one would hesitate to determine to which class a given umbilicus belongs.

Bert and Viannay's figures are as follows. Instances of—

1. Transverse umbilicus.....	71 cases
2. Round umbilicus.....	29 “
3. Vertical umbilicus.....	12 “

They examined systematically the umbilical cicatrix in all patients coming under their care. They regard the umbilicus as a cutaneous depression,—a sort of retracted cone,—in which one is able to distinguish the base, open in front and continuous with the skin of the abdomen. The bottom, or the summit, according to the point of view, is adherent, and is formed by the umbilical cicatrix and the surrounding parts.

They also drew attention to the fact that Catteau had spoken of four constituent elements—a cutaneous cushion or collar, which corresponded to their base; an elevation or mamelon, which corresponded to their bottom and which carried the cicatrix; and, finally, a furrow or groove. They pointed out that the four elements are present in an occasional umbilicus, which they would then speak of as *t h e c o m p l e t e u m b i l i c u s*, but that this complete umbilicus is met with in less than half of the cases. For example, in 112 molds Bert and Viannay found the umbilicus 34 times devoid of a central mamelon, and 21 times without a surrounding cushion, but as the cushion and the mamelon, or teat-like elevation, are divided by the furrow, when one of the two elements or when both are absent, the depression is also absent. The absence of one or more of these constituents of the umbilicus creates multiple combinations, which are capable of producing a certain number of types—a type of umbilicus without cushion or mamelon, a type with cushion and without mamelon, a type without cushion but with mamelon, and so on.

The *b a s e, c u s h i o n, o r u m b i l i c a l h o l l o w* is open in front and continuous with the skin of the abdomen in something like 18.75 per cent of the cases. When the surrounding skin inclines gradually toward the umbilical depression by a gentle slope, no prominence can be distinguished. In such cases we are dealing with an umbilicus without cushion. More frequently the base of the umbilical depression is surrounded by a circular elevation, a veritable cutaneous cushion. In about 6 per cent of the cases this cushion is complete and forms a uniform elevation, completely surrounding the cutaneous orifice of the umbilical depression. Ordinarily it is incomplete and occupies only a portion of the circumference of the umbilicus; for example, half of the circumference, the superior or inferior, or one of its lateral walls. This cushion then takes the form of a half-moon, a crescent, etc., and gives rise to numerous varieties in the appearance of the umbilicus.

The *b o t t o m o f t h e u m b i l i c a l d e p r e s s i o n*, despite Catteau's description, is not always occupied by an eminence carrying the cicatrix.

(a) *A s m o o t h d e p r e s s i o n*. In 34 cases Bert and Viannay found the bottom absolutely smooth, without any trace of elevation or mamelon. In these cases the umbilical depression was also regular and infundibular in form. They observed two varieties: In the first the umbilical orifice may be large, widely open, presenting at its extreme bottom the cicatrix, smooth or depressed, and having a



stellar or linear aspect; in the second the opening is narrow, and one has to separate the folds in order to see the cicatrix which occupies the bottom of the depression.

(b) **The mamelon or elevation.** In about two-thirds of the cases the bottom of the umbilical depression is occupied by an eminence or mamelon. The form of the eminence shows an infinite variation: sometimes—and this is the rule—it is single, sometimes double, occasionally triple. When the mamelon is double, the two elevations may be juxtaposed, so that a vertical or median depression separates them. When superimposed, the superior elevation is separated from the inferior by a small transverse depression. Usually, however, when the mamelon exists, it is single.

(c) **The umbilical cicatrix** occupies the bottom of the umbilical depression when the latter is smooth. In the umbilicus with a mamelon in the depression it occupies sometimes the central point; at other times it is on one side of the mamelon. The cicatrix may be punctiform and hardly visible; at other times it is linear and branches in different directions. It may be vertical or more frequently transverse. Sometimes it has a stellar arrangement with a variable number of branches.

(d) **The walls** of the umbilical depression may present as many variations as the other elements constituting the umbilicus. These variations are chiefly dependent on the depth of the umbilical depression, which itself depends upon the degree of development of the subcutaneous adipose tissue. Hence we find an explanation of the fact that a deep umbilicus is more frequent in women and in stout people. On the other hand, young infants, old men, and cachectic patients have an umbilicus less deep, or even on a level with the skin. In the deep umbilicus the walls are sometimes absolutely smooth. Sometimes the depression is occupied by a cutaneous elevation uniting the cushion and mamelon, a condition analogous to that found in the case of the muscular pillars which hold up the walls of the ventricle of the heart.

**The umbilical cavity** varies in size and in form. It can readily be understood that the degree of depth of the umbilical depression, the presence or absence of the central mamelon, and the larger or smaller opening at the base of the skin, will modify entirely the form and dimensions of the cavity of the umbilicus. From this point of view the examination of their plaster molds is very instructive. They show that the axis of the umbilical opening is rarely perpendicular to its base. Instead of passing directly into the depth, it deviates sometimes upward, sometimes downward, sometimes laterally. Moreover, the solid cone of the plaster mold, representing the cavity of the umbilical depression, is always more or less incurved. Sometimes it is turned out in a fantastic fashion. In their series of molds, in addition to the transverse, the round, and the vertical umbilicus, with or without cushion, with or without mamelon, they encountered several odd forms—for example, the funnel-shaped umbilicus, those suggesting the mouth of a furnace, the snout of a fish, and others.

#### PERSONAL CLINICAL STUDIES OF THE VARIOUS FORMS OF THE UMBILICUS.

Together with Mr. Brödel I visited the various wards of the Johns Hopkins Hospital and examined the umbilicus of nearly all the patients, males and females, young and old, white and black, including quite a number of pregnant patients.

Thus in the large group of pictures presented we have a rather comprehensive idea of the various forms the umbilicus may assume under normal conditions. With the examination of many thousands of people doubtless other forms will be detected, but the pictures here presented serve to show the forms usually met with.

The 60 drawings of normal umbilici arranged on Plates I-IV were made in the wards with the patients in bed. This insured uniformity of posture, and eliminated accidental skin-folds, such as always appear when the body is in flexion or in hyperextension. These plates show that it is difficult to speak of a definite and uniform topography of this region. The variations are exceedingly numerous, and include a large number of the most bizarre forms. The following are attempts to roughly classify the cases into groups:

**Group I.**—Cushion incomplete; presents a crescent or horseshoe fold below the umbilicus (Figs. 1-7). This condition suggests a taut urachus and lateral umbilical ligaments pulling the navel downward.

**Group II.**—Cushion incomplete, but found above the umbilicus. This is the reverse of what is present in Group I (Figs. 8-12). This condition suggests the presence of a taut and short round ligament of the liver coexisting with relaxation of the abdominal wall. The most pronounced cases of this type seem to be found in women who have had many children.

**Group III.**—Funnel-shaped umbilicus (Figs. 13-19). The cushion has been padded with adipose tissue. At the bottom of the funnel the umbilical scar is found. The mamelon is absent. A deep funnel has a narrow apex (Fig. 14). A shallow funnel, on the other hand, possesses a broad bottom (Fig. 16). The cicatrix may be large (Fig. 16) or small (Fig. 19), central (Fig. 19) or peripheral (Fig. 18).

**Group IV.**—The horizontal oval umbilicus. A cushion completely surrounds a well-marked mamelon and an umbilical cicatrix (Figs. 20-24). This is the group which most nearly coincides with Catteau's scheme of the normal navel.

**Group V.**—The horizontal, slit-like umbilicus, short or long, occurs in both sexes. It should be remembered that almost every type of navel can be made to appear as a horizontal slit by bending the body sharply forward. In the three cases, Figs. 25-27, the appearances are not due to this factor, but represent the abdomen at rest with the individual in the recumbent posture.

**Group VI.**—The triangular, slit-like umbilicus resembling the letter T (Figs. 28, 29, 31), or horizontal, like an H viewed from the side (Fig. 30).

**Group VII.**—The perpendicular, slit-like umbilicus (Figs. 32-35). This form suggests a closer approach of the two recti muscles, with a consequent increased efficiency against intra-abdominal pressure.

**Group VIII.**—The perpendicular oval umbilicus (Figs. 36-41). Cushion and mamelon and scar are arranged as in Group IV (Figs. 20-24), with the usual range of variations.

**Group IX.**—The prominent, button-like umbilicus (Figs. 42-60). The button may be round (Fig. 42), oval (Fig. 45), or spiral (Figs. 54 and 55), usually with a central horizontal, scar-like furrow. A crescent-shaped pit may be found under the button (Figs. 49, 50, and 59). The button may have a cushion as a collar (Fig. 42) or be without one (Figs. 44 and 48). In pregnancy the button form may be simulated by a small hernial protrusion (Fig. 60). (See also Plate VI, p. 467.)

A few general facts worthy of note are as follows:

(1) The navel in the colored race is usually larger than that in the white race. This may be due to the fact that the negro's skin is thicker than that of the white, or possibly to the lack of proper medical attention during labor, resulting in a larger scar. Compare—

WHITE		COLORED
Fig. 6	with	Fig. 7
“ 19	“	“ 16
“ 54	“	“ 55
“ 58	“	“ 56

(2) The umbilicus in the infant is much larger in proportion to the body weight than is that of the adult. Compare—

(3) There is no definite relation between the size of the adult and the size of the umbilicus. A small person may have a large umbilicus, and vice versa.

(4) In the adult the depressed umbilicus is far more frequent than the elevated or button-shaped type.

(5) The button is the infantile form.

(6) A large umbilicus of the horizontal type is associated with a wide linea alba, also with diastasis of the recti abdominis muscles. Diastasis of the recti is especially pronounced in infants and children. It is also found at the end of pregnancy (Fig. 60), when it may lead to the formation of a small hernia. (See also Plate VI, p. 467.)

(7) The linea nigra in a multipara may be in the mid-line (Figs. 24, 31, and 40), or bilaterally displaced at the umbilicus, as in Figs. 21 and 60.

(8) The umbilicus of a multipara is, as a rule, more wrinkled, and the peri-umbilical skin more relaxed in character than in a nullipara (Figs. 9, 29, 30, 37, and 40).

(9) Except for the growth of hair around the navel in the adult male, there are no sexual differences between it and the navel in a nullipara. (In these drawings, in order to insure clearness of form, the hair has been omitted.)

(10) Obesity has a tendency to produce the funnel-shaped umbilicus (Figs. 12, 14, and 19).

#### HISTOLOGIC APPEARANCE OF THE UMBILICUS.

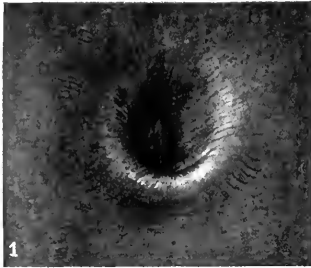As pointed out by Hertz and others, the umbilical pit is at first covered over with squamous epithelium, but is devoid of papillæ. Later the epithelium is identical with that of the outer skin. The scar, however, is usually lacking in sebaceous or sweat-glands. According to Hertz, Pernice was able to detect in three infants remnants of the omphalomesenteric duct in the scar, it being recognized as a canal lined with cylindric epithelium.

#### THE UMBILICUS AS VIEWED FROM ITS PERITONEAL SIDE.

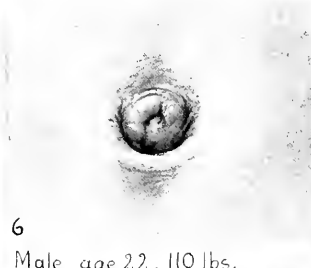The most important articles bearing on this subject are those of Gauderon (1876) and of Levadoux (1907).

As was pointed out in the chapter on the Embryology of the Umbilical Region, the umbilical arteries, the urachus, one or both umbilical veins, and the omphalo-

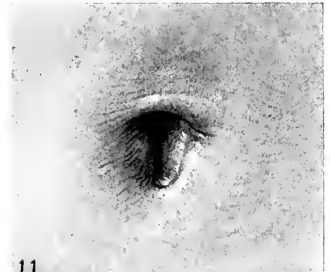
PLATE I.




1 Female, age 27. 97 lbs. Opara



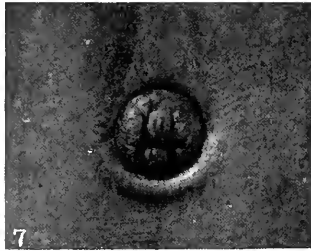
6 Male, age 22. 110 lbs.



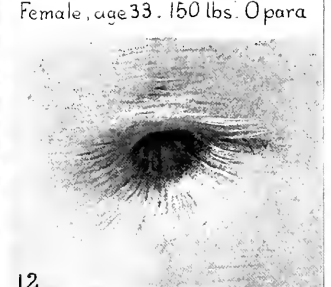11 Female, age 33. 150 lbs. Opara



2 Female, age 33. 120 lbs. Opara



7 Female, age 38. 116 lbs. Ipara




12 Female, age 58. 228 lbs. 5 para




3 Male, age 30. 148 lbs



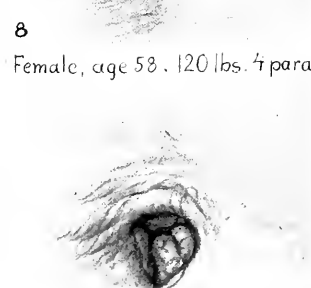
8 Female, age 58. 120 lbs. 4 para



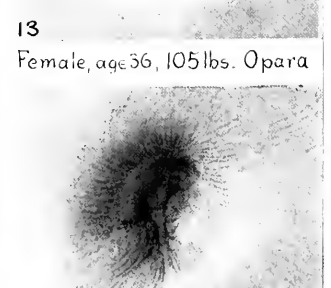
13 Female, age 36. 105 lbs. Opara



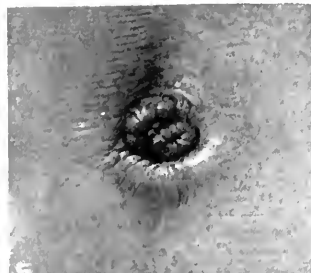
4 Female, age 33. 115 lbs. 4 para



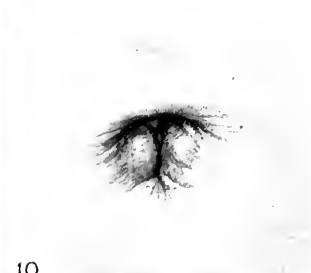9 Female, age 60. 120 lbs. 10 para



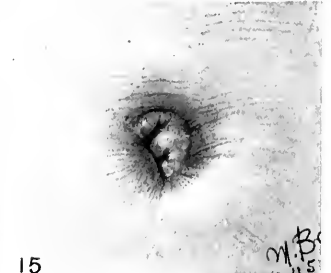
14 Male, age 46. 178 lbs.



5 Female, age 50. 110 lbs. Opara

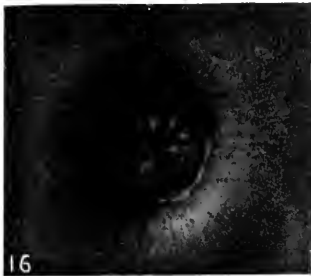

10 Male, age 39. 130 lbs.



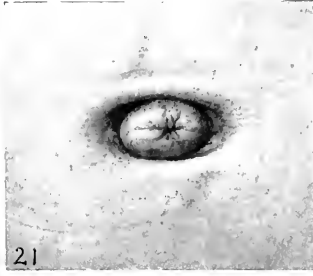
15 Female, age 28. 129 lbs. Opara

PLATE II.



16

Female, age 22, 130 lbs. 0 para



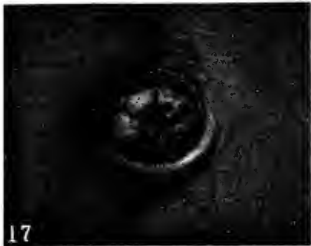21

Female, age 19, 145 lbs. 1 para



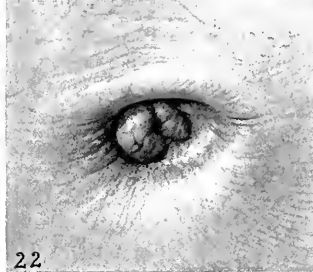26

Male, age 58. 138 lbs.



17

Female, age 23, 112 lbs. 0 para



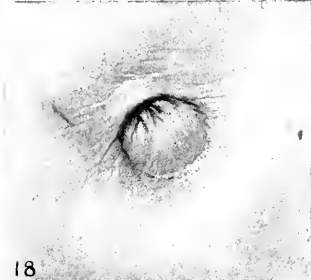
22

Male, age 19. 120 lbs.



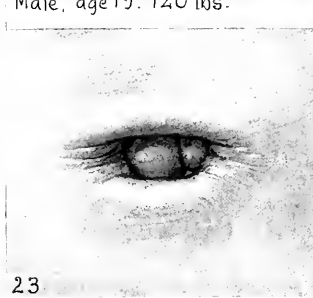
27

Male, age 42. 125 lbs.



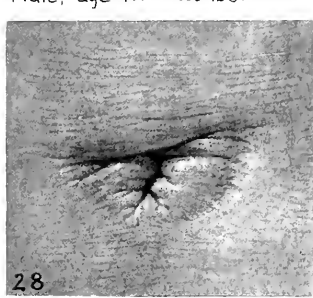
18

Female, age 42, 139 lbs. 3 para



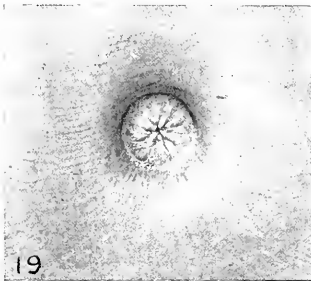
23

Male, age 33. 140 lbs.



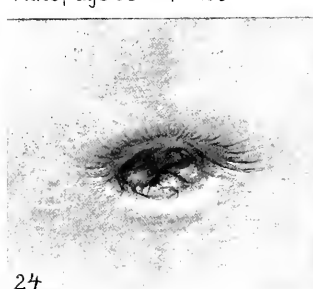28

Female, age 18, 140 lbs. 0 para



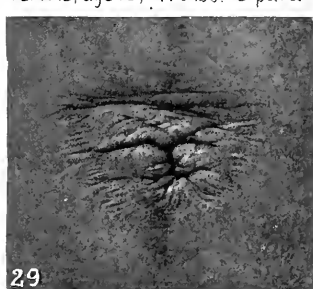
19

Male, age 63, 186 lbs.



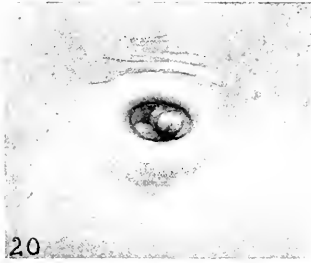
24

Female, age 38. 125 lbs 3 para



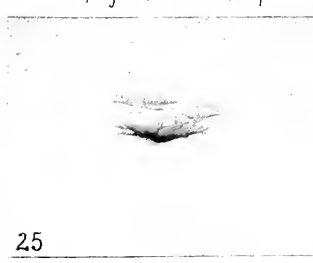
29

Female, age 45, 100 lbs 4 para



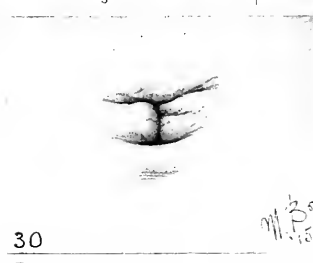20

Male, age 46, 107 lbs.



25

Female, age 79. 85 lbs. 0 para

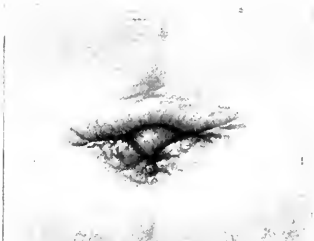

30

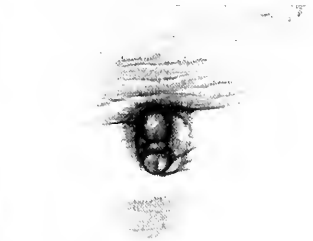Female, age 44, 135 lbs. 3 para

M.P.S.

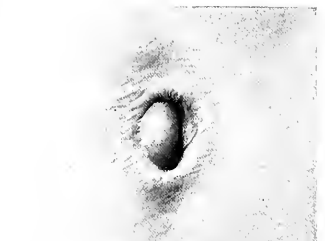
PLATE III.



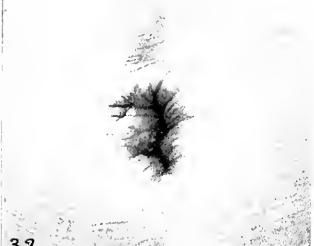31  
Female, age 29, 149 lbs. 7 para



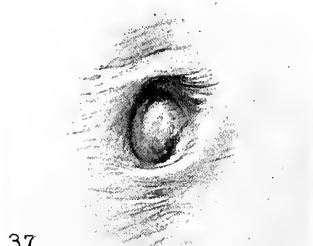
36  
Female, age 66, 125 lbs. 2 para




41  
Female, age 28, 130 lbs. 2 para



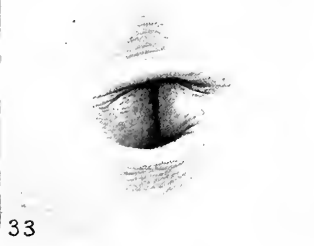32  
Female, age 24, 150 lbs. 3 para



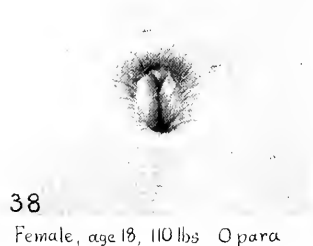37  
Female, age 32, 110 lbs. 6 para



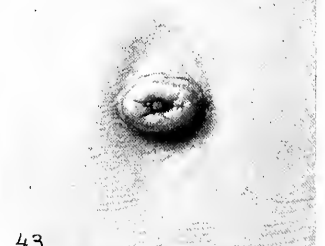
42  
Female, age 28, 99 lbs. 2 para



33  
Male, age 28, 120 lbs



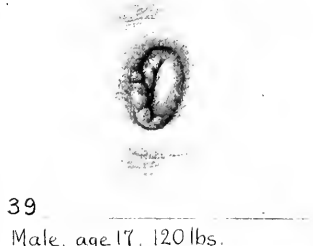38  
Female, age 18, 110 lbs 0 para




43  
Male, 6 months 9 lbs.



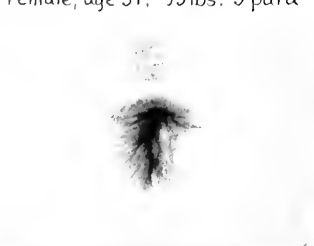34  
Female, age 31, 95 lbs. 3 para



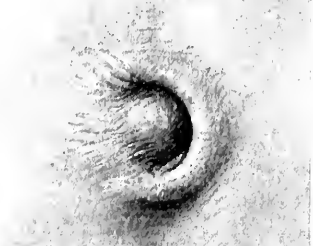
39  
Male, age 17, 120 lbs.



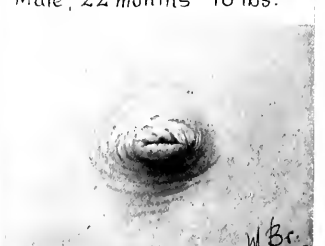44  
Male, 22 months 10 lbs.



35  
Male, age 39 150 lbs



40  
Female, age 38, 128 lbs. 4 para



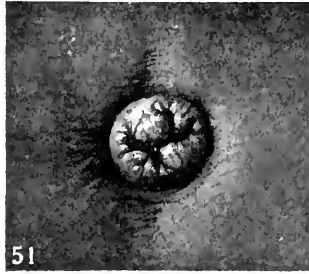
45  
Female, 2 1/2 months 5 lbs.

W.B.C.  
1915

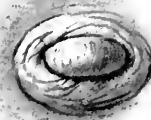PLATE IV.



46  
Female, 6 months, 8 1/2 lbs.



51  
Female, age 15, 90 lbs, 0 para




56  
Male, age 2 1/4 years 16 lbs.



47  
Male, 6 years, 43 lbs.



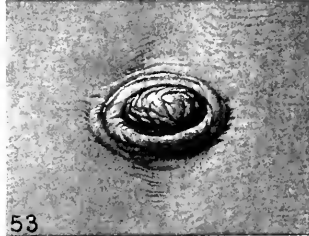
52  
Female, age 47, 101 lbs, 0 para




57  
Female, age 6, 45 lbs.



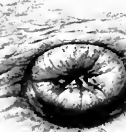48  
Female, 13 days 8 lbs.



53  
Male, age 3 1/2, 30 lbs.




58  
Male, age 36, 120 lbs.



49  
Female, age 52, 100 lbs, 11 para



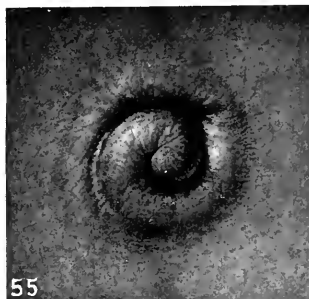54  
Male, age 44, 130 lbs.




59  
Male, 8 months, 17 1/2 lbs.



50  
Female, age 4, 40 lbs.



55  
Female, age 20, 116 lbs, 1 para



60  
Female, age 21, 115 lbs. pregnant

M.B.C.

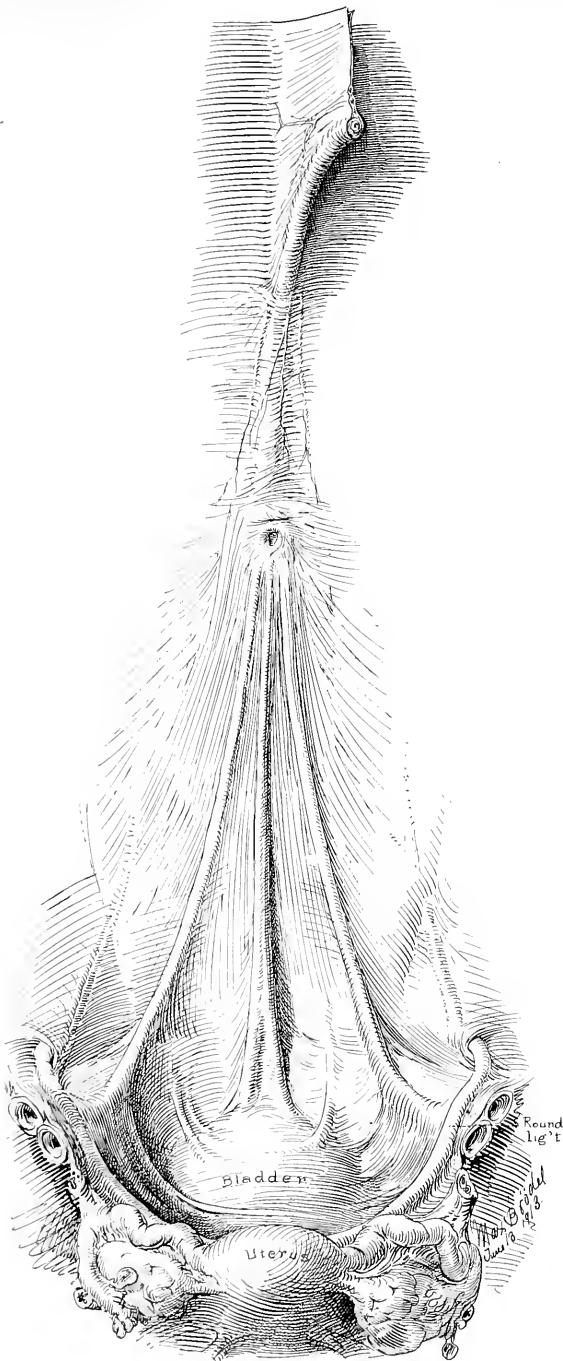


FIG. 35.—A TYPE OF UMBILICAL REGION IN THE ADULT, VIEWED FROM WITHIN. (Half nat. size.)

Within the umbilical ring is seen a small, shallow pit with strong resistant walls and base. There is no mesentery of the obliterated hypogastric arteries or of the urachus, excepting perhaps in their pelvic portion. They are, nevertheless, clearly seen throughout their entire extent. The triangular falciform ligament is very short, and the round ligament of the liver becomes lost in the abdominal wall at least 8 cm. above the umbilicus. (Personal observation.)

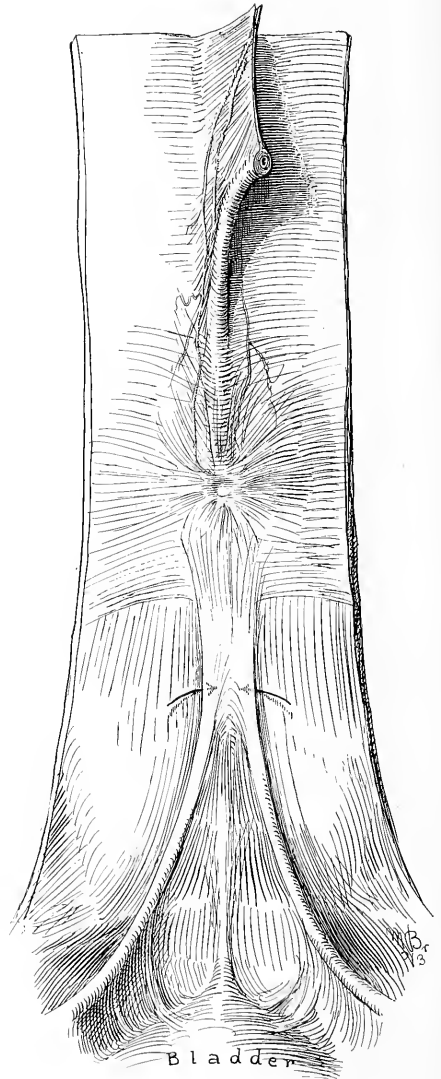


FIG. 36.—A FREQUENT TYPE OF THE UMBILICAL REGION IN THE ADULT, VIEWED FROM WITHIN. (Half nat. size.)

The umbilical ring is covered with radiating bundles of fascia through which the position of the ring can still be seen. The urachus and obliterated hypogastric vessels are not clearly defined in their upper portion, but appear to be lost in a broad, flat band. As the two arrows show, there is a shallow recess behind this band on each side. The round ligament of the liver shows the same arrangement as in the preceding figure. (Personal observation.)



mesenteric duct with its vessels, pass through the umbilical opening in early fetal life. About five or six months before birth all traces of the omphalomesenteric duct and its vessels usually disappear. The right umbilical vein is gone, and the urachus can generally be recognized as a solid cord. Thus in the normal umbilicus at birth we have to do with the remains of the umbilical arteries, the remnant of the urachus, the occluded umbilical vein, the peritoneum covering the umbilical region, and lastly with the umbilical ring, and in a certain number of cases the umbilical fascia.

In the consideration of this subject I shall dwell chiefly upon the results obtained by Gauderon and by Levadoux, and briefly mention the findings of Max Brödel during his studies on the embryology of the umbilical region.

In Figs. 35, 36, and 37 are shown the most common appearances of the inner surface of the anterior abdominal wall, not only at the umbilicus, but also above and below this point.

Gauderon described his findings in 10 infants. He was struck with the variations in the relationship of the peritoneum of the umbilicus to the umbilical cicatrix. Sometimes he found the peritoneum presenting

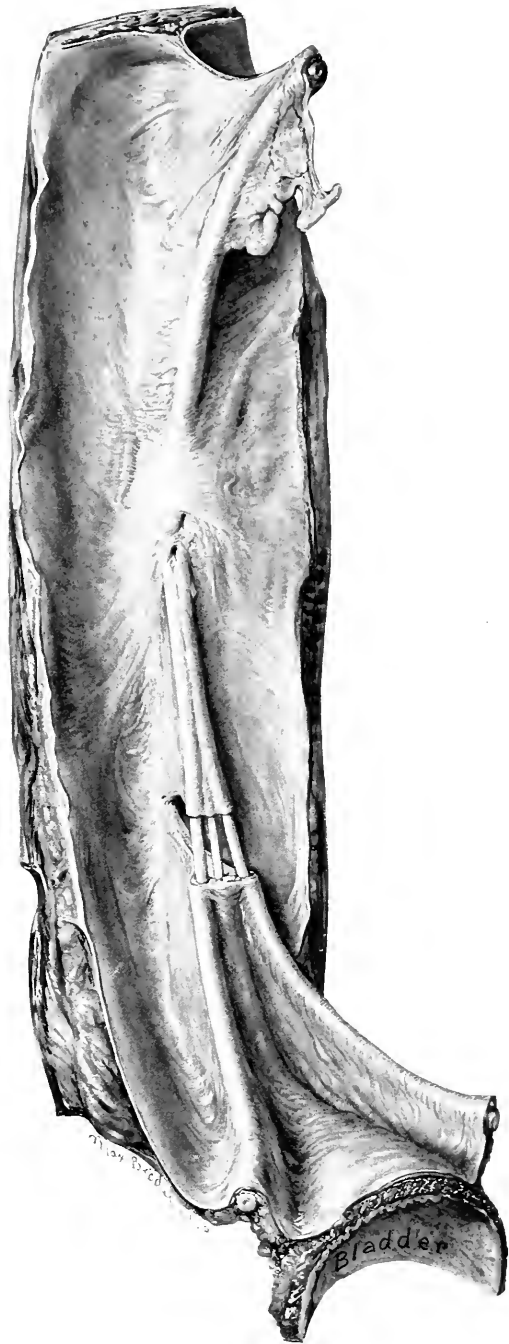

FIG. 37.—THE UMBILICAL REGION OF AN ADULT, VIEWED FROM WITHIN. (About half nat. size.)

The umbilical ring is bridged over with fascial bands running for the greater part in a transverse direction. There are small globular masses of subperitoneal fat distributed around the vessels and the ring. Between these are seen two small shallow pits. The fibrous tissue at their bottoms is particularly strong. Below are seen the two obliterated hypogastric (umbilical) arteries. Between them is the urachus, passing from the umbilicus to the bladder. A portion of the mesentery-like attachment to the ventral body-wall has been removed so as to show better the size of the structures, their relation to one another, and to the thin, band-like mesenteriolum. Above, the round ligament of the liver (obliterated umbilical vein) is seen suspended from the free border of the triangular falciform ligament. This ligament does not reach to the umbilicus; the round ligament continues just under the peritoneum, where it may be palpated as a broad band. From the free border of the round ligament are seen hanging a few pedunculated masses of fat. (Personal observation.)

a smooth surface at the umbilicus; in other cases there was a slight depression. In a few cases—4 times out of 10—the peritoneum was adherent to the umbilicus; in the remaining cases it was free. Sometimes it could be easily separated.

Before the separation of the peritoneum of the umbilicus it was easy to determine the existence or absence of the umbilical fascia, which forms the posterior part of the umbilical canal described by Richet. In some of the cases the peritoneum was not reinforced at the umbilicus by any trace of the lamellæ composed of fibers of the transversalis fascia. Gauderon says he was able to determine this fact in an infant two years of age. In 7 of his cases he encountered no other trace of the umbilical fascia except portions of lamellæ of the transversalis, which reinforce the peritoneum for about 4 or 5 cm. around the umbilicus. These lamellæ are not adherent to the posterior aponeurosis of the rectus muscle on the right, and as a consequence in these cases one cannot say that there exists a partial umbilical canal, as described by Richet. In only 2 of his 10 dissections did Gauderon find a complete umbilical canal, as described by Richet. One of these subjects was a child three years old, the other, four years old. In one of these cases the peritoneum had separated completely and one could see clearly remnants of the umbilical vein, of the umbilical artery, and of the urachus. These were inserted to the right of the inferior half circumference of the umbilical ring. In consequence, to the left and above the ring was a small depression in which there was found a small lump of fat. According to Gauderon, it is in this depression that the peritoneum tends to lie.

Gauderon sums up his investigations as follows: In the majority of infants the umbilical fascia shows defects. It was lacking 8 times in 10 cases. When it exists, it is not so placed as to reinforce the peritoneum at the umbilicus and to protect against distention or rupture. The umbilicus is one of the weakest parts of the abdomen.

The most important article on this subject is that written by Levadoux and published in 1907. This work was carried on under the direction of Charpy. In addition to comparative study, he examined 50 human cadavers. His investigations embrace the study of the umbilical ring in mammals, a consideration of the classic umbilicus, personal observations on the varieties in the form of the umbilicus, the form of the outer umbilicus, together with the anatomic formation of the ring, and the appearance of the inner surface of the umbilicus.

I have made a brief translation of the salient features of Levadoux's valuable paper, and all the references are exactly as the author has given them.

From his Chapter II, I have taken the following classic description of the umbilicus: The umbilicus of the adult is the orifice in the linea alba which corresponds to the point of attachment of the umbilical cord of the fetus. It is closed externally by the cicatricial skin, which is adherent to its contour. Its inner surface is free, and separated from the abdominal cavity by the parietal peritoneum which covers its surface. Sometimes—about once in five cases—an umbilical fascia of variable thickness covers the ring and makes a reinforcement of the peritoneum. This opening with its borders measures 1 cm. or more in diameter. It may very well be likened to the mouth of a furnace, with its upper margin arched and its lower margin rectangular. The central orifice is about 2 to 4 mm. in diameter and free. It is closed solely by a ball of fat. The margins of the orifice are formed by the oblique fascia of the aponeurosis of the linea alba, to which are added behind the

fibers of the arch, so that there is formed a homogeneous mass. The upper border of the ring is free; the inferior border receives the insertion of the urachus, the umbilical arteries, and the umbilical vein (Fig. 38) in four separate cords.

The vein is attached sometimes to the right or to the center, and may be divided into filaments. The fusion of these various cords with the base of the ring results in a fibrous nodule which is thick and very adherent to the skin. The parietal peritoneum covers the inner surface of the ring; it is only lightly adherent, and in stout subjects is usually separated by adipose lobules. Sometimes it passes directly over the orifice and at other times is depressed. At this point only the skin and peritoneum close the abdominal cavity.

**The umbilical fascia**, when it exists, extends upward for a variable distance. It is formed by the fibers of the transversalis fascia attached to the peritoneum. This may extend to the margin of the rectus muscle, or join with the posterior layer of the aponeurosis. According to Stratz, a well-formed umbilical canal is situated high and should be small. Hyrtl compares the umbilical orifice in man to that in animals.

In Chapter III Levadoux takes up the varieties and forms of the umbilicus. He considers:

1. Varieties of the fibrous ring.
2. Variations in the disposition of the vascular cords.
3. Variations of the umbilical fascia and their interpretation.
4. Varieties of peritoneum with special reference to—(a) the formation of the mesoperitoneum; (b) fatty fringes; (c) diverticula; (d) atrophy.

**Varieties of the Fibrous Ring.**—This ring represents the remains of the passage of the cœlomic funnel through the linea alba. Its outer surface can be studied after removal of the skin; by raising the peritoneum one brings into view the posterior surface. Viewed from its outer and subcutaneous surface, this ring is circular in form and closely adherent to the skin which covers it. Viewed from its posterior or subperitoneal surface also, it not infrequently appears circular,—in 22 out of 50 cases,—but sometimes it is elliptic, the axis running transversely. One type referred to by Blandin has the form of a semicircle or resembles the mouth of a furnace (Fig. 38). Since his description appeared, this has been considered as the normal type. Richet, who has more recently considered this question, described this orifice as quadrilateral, with rounded angles. In the case of individuals who have an umbilicus that is nearly circular, this configuration is explained by the disposition and the mode of insertion of the umbilical arteries and the urachus.

Where it has been impossible to recognize the ring, the orifice has been found completely closed, sometimes by fusion of the lateral walls, sometimes by some peculiar arrangement of the vessels. The margins of this fibrous ring have a variable thickness. In a little less than two-thirds of his cases Levadoux could observe no difference between the thickness of the margins of the ring and that of the linea alba. In several fat cadavers the fibrous ring was less thick than other portions of

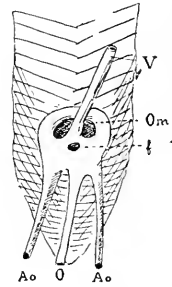


FIG. 38.—CLASSIC TYPE OF UMBILICUS. (After Levadoux.)

V, umbilical vein. The umbilical arteries (Ao, Ao) and the urachus (O) are attached to the lower margin of the ring. Om represents the ring, which is semicircular. f is the intervascular depression.

the linea alba, and in 17 of his subjects it was manifestly thicker. This reinforcement was produced by a fibrous cushion on the posterior surface of the ring. Levadoux disagreed with Richet that at this point in all cases superimposed fibers were present, but he found that, when the posterior pad existed, he could disassociate a certain number of these fibers and determine that they were not continuous with the sheaths of the muscles, but terminated on a level with the cushion. In all probability Levadoux had to do here with supplementary fibers. The central orifice of the ring measures from almost nothing to 6 mm. in diameter.

**Disposition of the Vessels.**—This is discussed at length by Levadoux (p. 33). What impressed him most in this study was the great diversity of types. The majority of cases corresponded to the description given by Robin (*Mém. de la Soc. de Biologie*, 1860, 107). Levadoux designates two main groups:

**Group 1.**—The inferior cords unite into one before reaching the lower

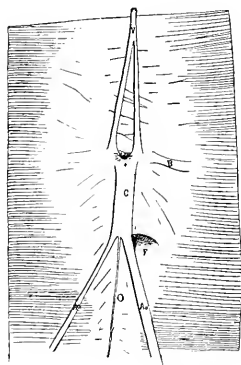


FIG. 39.—DISPOSITION OF THE VASCULAR CORDS (USUAL TYPE). (After Levadoux.)

Noted 18 times in 50 cases. The peritoneum has been removed. The umbilical vein (*V*) is bifurcated and terminates on either side of the ring. The urachus (*O*) and the arteries (*Ao, Ao*) unite in *C*. *F*, a depression. *B*, a bridge. +, the umbilical ring.

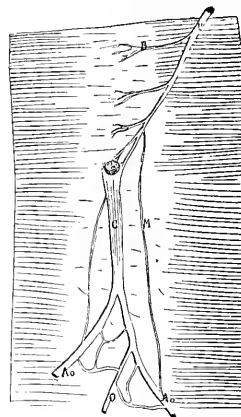


FIG. 40.—VASCULAR CORDS OF THE ANASTOMOSING TYPE, NOTED 7 TIMES IN 50 CASES. (After Levadoux.)

The peritoneum has been removed. *B*, branches of the umbilical vein. *M*, an anastomosis between the umbilical vein and the right umbilical artery; *C*, a common cord formed by both umbilical arteries and the urachus.

and lateral margins of the fibrous umbilical ring. The vein remains independent of this cord, and is inserted as two or three branches in the superior or lateral walls of the ring.

**Group 2.**—The inferior cords and the superior cord send anastomoses\* reciprocally.

Levadoux gives a careful detailed description of the majority of types encountered and a classification according to the frequency with which they are found.

**Variety 1** (Fig. 39) was noted 18 times in 50 cases. The three vessels, the urachus and the umbilical arteries, unite at the same point, 4 cm. below the umbilicus; the resulting cord is flattened in its anteroposterior diameter, and inserted by its upper extremity upon the inferior half of the circumference of the umbilical ring. Before its termination the urachus is reduced to a simple cylindrical

\* Where Levadoux uses the term anastomosis the reader should consider it as meaning a fibrous connection of the solid vessel-walls.

filament, whereas the remnants of the umbilical arteries still retain a good caliber. The vein, at a point about 6 cm. above the umbilicus, divides into two cords of equal size. These lie on the lateral wall of the ring, and their insertions merge with the more lateral fibers in the inferior cord. The peritoneum covering these vessels is applied in such a way that no mesentery for them exists.

Variety 2 (Fig. 40) was noted 7 times in 50 cases. Here at one point the union of the three inferior cords has not taken place. The urachus has become adherent to the right umbilical artery, about 8 cm. below the umbilicus. The left artery joins the cord at a point 2 cm. farther up. The resulting ligament is inserted into the inferior and lateral borders of the ring. The vein terminates in

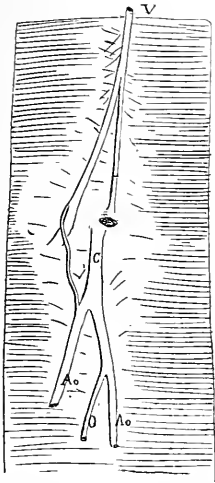


FIG. 41.—VASCULAR CORD TYPE, NOTED 5 TIMES IN 50 CASES. (After Levadoux.)

V, the umbilical vein, which passes downward and divides into two branches, one inserted into the upper border of the ring, the other passing downward into the abdominal wall. Ao and O are the umbilical arteries and the urachus which unite to form the cord (C) that is inserted into the left lateral wall of the ring.

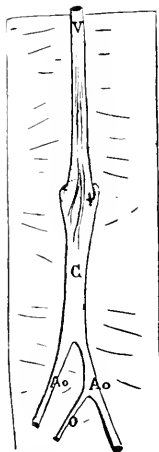


FIG. 42.—VASCULAR CORDS, NOTED 5 TIMES IN 50 CASES, COMPLETELY FILLING THE UMBILICAL RING. (After Levadoux.)

The peritoneum has been raised. The umbilical ring (+) is closed by the anastomosis of the cords on its posterior surface.

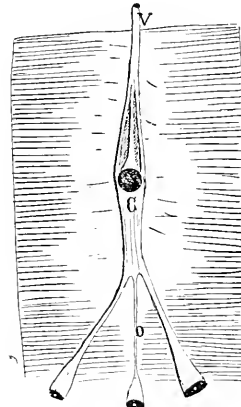


FIG. 43.—VASCULAR CORDS, NOTED 3 TIMES IN 50 CASES. (After Levadoux.)

The peritoneum has been removed. The umbilical vein divides into three branches; the umbilical arteries and the urachus are hypertrophied and permeable. They terminate in delicate filaments which have united to form a common cord (C).

two short branches: one is inserted into the upper border of the ring, the other joins the right margin of the ring, where it merges with the fibers from the inferior cord. A long branch from the umbilical vein passes downward and anastomoses with the trunk of the right umbilical artery. The umbilical vein then divides and gives off three branches which terminate in the linea alba above the umbilicus.

Variety 3 (Fig. 41) was noted 5 times in 50 cases. The three inferior cords unite as in Fig. 40. The common cord is short, and is inserted at a point to the left of the middle of the ring and in its left lateral part. The vein presents two long branches of bifurcation: one is inserted into the superior border of the ring; the other passes to the abdominal wall and receives anastomoses from the left umbilical artery.

Variety 4 (Fig. 42) was noted 5 times in 50 cases. Here the inferior vessels form a cord in the same way. The umbilical orifice posteriorly is completely closed. The inferior vessels and the superior vessels fuse together at this point, forming a continuous cord from the inferior surface of the liver to the summit of the bladder, and unite with the lateral structures at the umbilicus.

Variety 5 (Fig. 43) was noted 3 times in 50 cases. The three cords are hypertrophied and permeable up to a certain point; they end abruptly as a delicate cylinder at a point 2 or 3 cm. below the umbilicus, and are inserted into the inferior circumference of the ring. The vein divides into three portions, one of which is inserted into the upper border of the ring, its two lateral branches passing downward on either side and joining the inferior cord.

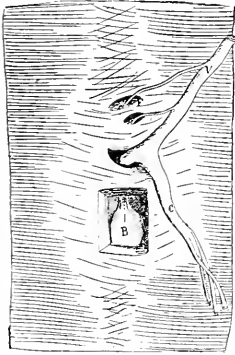


FIG. 44.—VASCULAR CORDS, NOTED IN 2 OUT OF 50 CASES. (After Levadoux.)

The umbilical openings do not correspond. The peritoneum has been removed. The inferior cord (C) and the vein (V) pass through the orifice and descend in front of the linea alba to become fixed in the umbilical cushion (B), which is shown through the window cut out in the abdominal wall.

Variety 6 was noted 3 times in 50 cases. The urachus and the umbilical arteries show marked branchings, and pass upward as a network. The umbilical vein divides into three branches. The middle one becomes attached to the upper portion of the umbilical ring. The lateral cords are continuous with the inferior filaments.

Variety 7 was noted in 2 out of 50 cases. The urachus divides into numerous filaments, which disappear in the linea alba, 5 cm. below the umbilicus. The two arteries form a cord of small caliber, which terminates in the linea alba at a point 5 cm. below the ring. The umbilical vein bifurcates. One of its branches is inserted into the right lateral margin of the umbilicus; the other anastomoses with the umbilical arteries.

Variety 8 (Fig. 44) was noted in 2 out of 50 cases. This type is very curious, and is found in those subjects in whom the cutaneous cicatrix does not correspond with the fibrous ring, but is situated below it. The two cords unite before penetrating into the fibrous ring. The united trunk which results, after passing through this ring, becomes subcutaneous and is inserted all around the cushion of the umbilicus. The fibers forming the inferior cord describe a crook in order to reach their termination at the umbilicus. The vein has two branches which terminate in the skin, after having passed through two orifices in the linea alba.

As a rule, the history of the filaments resulting from obliteration of the umbilical vessels is as follows: The urachus and the umbilical arteries unite in a common cord at a variable distance from the umbilicus. This flattened cord is inserted into the inferior and lateral margins of the ring. The umbilical vein divides into a variable number of filaments, which are inserted most frequently into the lateral margins of the ring—sometimes into the superior margin. A variable number of the ramifications of the vein and of the inferior cord terminate in the abdominal wall before reaching the umbilicus.

**Peri-umbilical Veins.**—On page 46 Levadoux discusses the peri-umbilical veins. These have been described by Sappey, and more recently by Jores. Mériel has also published a note on this subject (Soc. anat. de Paris, 1902). This system

of veins, which results from a union of the vesico-umbilical veins and the portal system, is very interesting. It is formed by two veins, the right and left peri-umbilical veins, and plays an important pathologic rôle in cases of cirrhosis of the liver. Jores considers the right peri-umbilical vein as the intra-abdominal portion of the right umbilical vein. Levadoux noted the presence of these peri-umbilical veins, but did not include them in his studies.

**Varieties of Umbilical Fascia.**—Levadoux (p. 46) describes the different varieties of umbilical fascia, and mentions the description of it by Vidal de Cassis (*Des hernies ombilicales et épigastriques*, Thèse de Paris, 1848). Later this aponeurotic sheath was described by Richet (*Anatomie med.-chir.* 1856–1857), by Gauderon (Thèse de Paris, 1876), and Sachs (*Die Fascia Umbilicalis*. *Arch. f. path. Anat.*, 1877). Richet called it the “umbilical fascia.” From a study upon a well-formed and well-developed cadaver he found that the peritoneum, which envelops the umbilical vein, for the last 3 or 4 cm. above the umbilical ring is reinforced by a whitish layer of fibers directed transversely, and with the edge at right angles to the direction of the vein. These fibers may be continuous with the muscle, or they merge below with the posterior layer and the corresponding aponeurosis. Below, the fascia does not pass to the umbilical cicatrix. Sometimes, however, one finds it prolonged and terminating imperceptibly in the fibrous cord of the arteries. Above, it sometimes ends sharply at a point 3 or 4 cm. from the ring. At other times it is impossible to assign the precise limits of its termination. This umbilical fascia, though definite in certain subjects, is limited in others.

Richet considers the space situated between the posterior surface of the *linea alba* and the umbilical fascia as a canal, and calls it the “umbilical groove.” This canal contains in the adult the fibro-cellular cord, vestiges of the umbilical vein, surrounded by a cellular tissue, the meshes of which in some individuals are filled with an abundance of yellowish fat. Richet tries to establish a parallel between the umbilical canal and the inguinal canal. Gauderon examined 10 children, from two to fifteen years of age, and found the fascia well formed in only two cases. In seven cases it was reduced to lamellæ which were not adherent to the corresponding sheath.

In speaking of variations in the condition of the umbilical fascia Sachs distinguished three groups:

1. The fascia does not exist or ends far above the upper border of the ring.
2. The fascia in its inferior border is sharply defined; it covers the upper border of the ring or is flush with it.
3. The fascia covers the entire ring.

So far as the relative frequency is concerned, Sachs, from 207 autopsies made on infants between one and eleven months of age, arrived at the following conclusions:

Fascia absent in . . . . .	64 cases
Fascia present in . . . . .	143 “
Fascia covering the ring in . . . . .	48 “
Fascia above the ring or flush with it in . . . . .	25 “

Levadoux now gives his own observations.

Fascia absent in . . . . .	8 cases
Fascia situated high and represented by a bridge 1 cm. broad in . . . . .	9 “
Fascia developed 1 or more cm. in width, but not reaching the superior border of the ring in . . . . .	11 “
Fascia reaching the upper border of the ring in . . . . .	7 “
Fascia covering part of the ring in . . . . .	3 “
Fascia covering all the ring in . . . . .	5 “
Fascia descending below the ring in . . . . .	7 “

According to Levadoux, the absence of the fascia is, therefore, much less frequent than is indicated by Sachs' figures. In the former's 50 observations it was lacking in only 8 cases (16 per cent), whereas Sachs gives 31 per cent, a percentage that is nearly double.

Levadoux would explain this difference in the findings by the difference in the ages of the bodies examined. Sachs made his observations on infants. Levadoux', on the contrary, were made upon adults. Levadoux goes on to say that in certain cases the fascia may form in the course of the growth of the individual, since we know that the fibrous tissue does not reach its full development until after puberty.

The fascia is represented by a simple bridge which may be easily overlooked. In such a case it is situated 4 or 5 cm. above the umbilicus. The fibers which form it may reach a breadth varying from several millimeters to one centimeter, and are

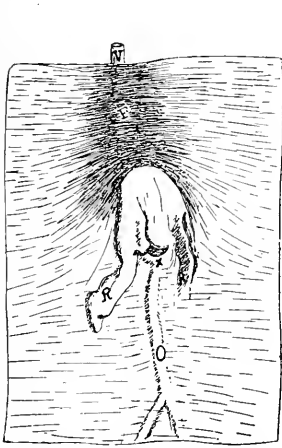

FIG. 45.—UMBILICAL FASCIA. PERITONEUM IN PLACE. (After Levadoux.)

X, umbilical ring; F, the umbilical fascia; R, the fringe of adipose tissue; O, the inferior cord; V, the umbilical vein.

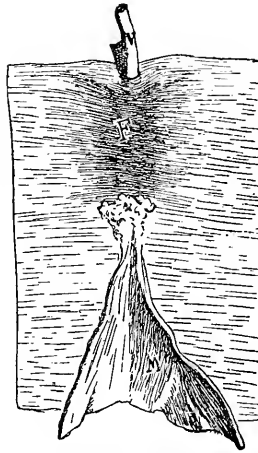


FIG. 46.—UMBILICAL FASCIA AND UMBILICAL MESENTERY. (After Levadoux.)

The peritoneum is in place. It is reinforced by the umbilical fascia (F). V is the umbilical vein; X, the umbilicus. The umbilical arteries are contained in a mesoperitoneum.

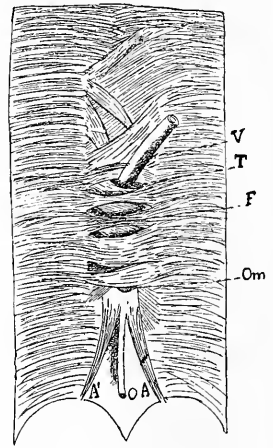


FIG. 47.—REDUPLICATION OF THE LINEA ALBA. PERITONEUM REMOVED. (After Levadoux.)

The umbilical vein (V) enters by an orifice (T) into a canal of the linea alba. The posterior wall is formed by the thickened fascia (F). Om, the umbilicus; o, the urachus; A, A', the arteries.

always merged laterally with the corresponding sheaths. They may be disassociated or intimately blended together. In 11 out of 50 cases this umbilical fascia was formed of the fibers of the transversalis fascia, reaching as high as 5 or 6 cm. Its upper border was some distance from the ring (Fig. 45). The umbilical vein, therefore, passes along a canal formed by the linea alba and this fibrous sheath, which varies in thickness. It is easy to see that there exists no groove at the point of entrance or disappearance of this ligament. The peritoneum is intimately attached to it. In 7 cases only was fascia found reaching to the superior border of the ring (Fig. 46) and forming the type of Richet.

In 3 cases the fascia descended a little below the middle of the ring, leaving the inferior part of this orifice covered with peritoneum only. Finally, in 5 cases the fascia covered the ring completely, ending at its inferior border, and 7 times it descended 3 to 4 cm. below its lower border.



The umbilical fascia varies, not only as regards its situation and extent, but also in its thickness. In certain types (30 out of 42) the fibers of the transversalis fascia, of which it is constituted, were intimately united; in the other cases they formed a reticulum, like a more or less coarse meshwork. In two observations the fascia presented, toward the middle of its extent, a rectangular orifice 3 cm. long. Here a zone of peritoneal atrophy was noted (Fig. 48).

The relations of the umbilical vein to the umbilical fascia are nearly constant. The vein passes in front of the fascia, which is applied to the posterior surface of the linea alba. Levadoux says that in its course it is usually surrounded by adipose tissue; nevertheless, we have one observation, communicated by Charpy, which does not conform to this rule. In this case the linea alba, 10 cm. above the umbili-

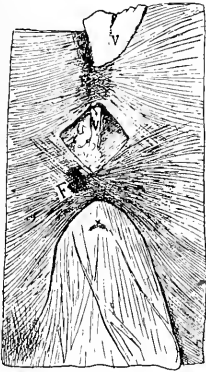

FIG. 48.—ATROPHY OF THE UMBILICAL FASCIA, POSTERIOR VIEW. (After Levadoux.)

The peritoneum is in place. The fascia (*F, F*) presents two atrophic patches, the one lozenge-shaped, the other at the level of the umbilicus (*X*). *V*, the umbilical vein.




FIG. 49.—FORMATION OF A MESENTERY. PERITONEUM IN PLACE. (After Levadoux.)

The mesentery (*M*) of the umbilical vein (*V*) and the mesentery of the inferior vascular cord (*M'*) form a longitudinal partition. *G*, fringes of adipose tissue. *X*, the umbilicus.




FIG. 50.—MESENTERY OF THE URACHUS AND OF THE UMBILICAL ARTERIES. (After Levadoux.)

The peritoneum is in place. It is reinforced by the fascia (*F*), behind which is the vein (*V*). *+*, the umbilicus. Below the umbilicus is the long mesentery (*M*) containing the urachus and the umbilical arteries.

cus, presented an abnormal thickening of 3 mm. (Fig. 47). The umbilical vein disappeared into a canal at a point 25 mm. above the ring. The anterior part was membranous and showed little resistance, whereas the posterior part was dense and exceptionally thick. This evidently represented not a portion of the umbilical fascia, but a sort of transposition of the linea alba behind the vein. When this fascia exists, its superior and inferior margins are nearly always very sharp and have an arched arrangement.

After having removed the peritoneum, one finds in a zone limited by the crest of the fascia a small cushion of cellular tissue. Beneath the inferior margin of this fascia this cushion is blended with the transversalis fascia. Toward the lateral borders, therefore, says Richet, the transversalis fibers merge with the posterior portion of the sheath. Levadoux, in dealing with pieces of fascia placed in formalin

(0.5 per cent. for fifteen days), found it possible to separate the umbilical fascia from its sheath. He says that he carried out the plane of cleavage of the aponeurosis to the transversalis muscle. At its level he could see that the disassociated layer was a continuation of the posterior sheath of the aponeurosis developing from the transversalis muscle.

In 36 out of 50 cases the peritoneum was applied intimately to the umbilical region, forming a definite covering. In such cases the fibrous ring is not visible from the peritoneal surface. No depression marks the umbilical cicatrix.

**Elevation of the Peritoneum in the Form of a Mesentery.**—Normally the umbilical vein travels in the free margin of a mesentery, a continuation of the falciform ligament of the liver, which is attached to the anterior abdominal wall. The mesentery is very short, and terminates in the inferior part of the liver, that is to say, about 7 or 8 cm. above the umbilicus. In 3 out of 50 cases this mesentery ex-

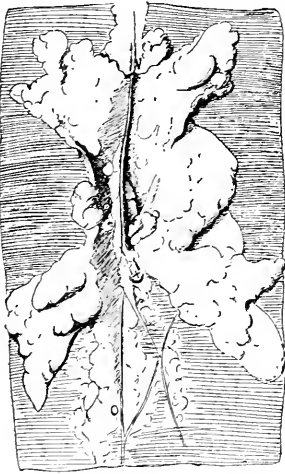


FIG. 51.—ADIPOSE FRINGES. FROM A WELL-DEVELOPED YOUNG WOMAN. PERITONEUM IN PLACE. (After Levadoux.)

The umbilicus (X) is closed by a pad of adipose tissue. V, the umbilical vein; O, the urachus.



FIG. 52.—ADIPOSE FRINGES IN A STOUT SUBJECT. PERITONEUM IN PLACE. (After Levadoux.)

Om is the umbilicus, at the bottom of a mass of adipose fringes. V is the vein. O shows the inferior umbilical vessels.

tended much farther down, reaching to within 3 cm. of the superior margin of the ring, while in 4 other cases it reached the upper border of the ring.

In these 4 cases, besides the mesentery of the umbilical vein, there existed an elevation of the peritoneum over the inferior cords. These united in a single cord at the summit of the bladder. They approached one another at the median line, and raised the peritoneum *en masse* as far as their insertion at the umbilicus (Fig. 49). Between the umbilical insertion of these two mesenteries, at the level of the posterior surface of the ring, there existed two folds of peritoneum containing fat. The inferior mesentery may also exist alone, as occurred in two cases (Fig. 50). In another case this mesentery was represented by two peritoneal elevations each corresponding to an umbilical artery (Fig. 46).

**Peritoneal Fringes Containing Fat.**—The peritoneum may be folded, fringed, and raised in folds to a greater or less degree by masses of adipose tissue which infiltrate the subserous tissue. When the fat attains a certain development, these

fringes, as a whole, become arranged somewhat in the shape of a collaret in which the umbilical ring occupies the center (Fig. 51). Their existence is not very rare in the human being. They are similar to the epiploic fringes of the large intestine, and to those of the pleura or of the pericardium, as described by Cruveilhier and more recently by Poirier. Occasionally, the fatty umbilical fringe presents an appearance similar to that seen in Fig. 52. This condition is also present in the dog.

This disposition of the adipose tissue in the umbilical region is often somewhat disconcerting to the surgeon, for when working in this area he is at times uncertain whether or not he is really in the peritoneal cavity. A knowledge of this arrangement of the fat will prevent any confusion on his part.

#### DIVERTICULA.

Levadoux (p. 61) takes up the discussion of diverticula. The peritoneum presented at the level of the ring (14 times in 50 of his cases) a more or less pronounced diverticular depression. In 8 out of 50 cases there were peri-umbilical fossettes




FIG. 53.—PERITONEAL DIVERTICULA. PERITONEUM IN PLACE. (After Levadoux.)

Three diverticula (*a, b, c*) occupied by lobules of adipose tissue, which have been removed. X is the umbilicus; V is the umbilical vein with its three branches; O, the urachus.

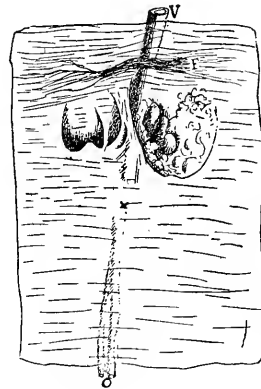


FIG. 54.—PERI-UMBILICAL FOSSETTES. PERITONEUM IN PLACE. (After Levadoux.)

X is the umbilical ring, above which are two peritoneal fossettes occupied by adipose tissue, and above these again the fascia (*F*).

in the peritoneum. The umbilical diverticulum corresponds to a fibrous ring more or less open behind. The peri-umbilical fossettes are found at the breaking of the linea alba. They are of two kinds, and may exist together or separately in the same subject. The more common form is that resembling a crescent. Sometimes it occupies the lateral portion of the ring, sometimes the inferior margin; in other cases again, the other half of the ring is occupied by a mass of adipose tissue. This crescent may be replaced (6 times in 14 cases) by an ellipse which is largest in its transverse axis, whereas in 2 out of 14 cases it was represented as a round cupola.

As regards their relation to the umbilicus, the peri-umbilical fossettes may themselves be divided into two groups—the subumbilical and those situated above the umbilicus. The former were noted by Levadoux only twice in 50 cases. Di-

verticula above the umbilicus were met with a little more frequently—6 times in 50 cases. They are usually multiple, and correspond to a defect in the umbilical fascia. Their arrangement and anatomic constitution are characterized by the presence of small adipose fringes which cover them (Figs. 53 and 54). The linea alba at their level is lacking, and properitoneal lobules are found. In this group of peri-umbilical fossettes we have included only those situated less than 3 cm. from the ring.

#### CLINICAL EXAMPLES OF DEFECTS OF THE ABDOMINAL WALL.

The subject of defects in the abdominal wall presents many points of interest. Two cases of this character have come under my observation.

In July, 1910, I saw, in consultation with Dr. A. H. A. Mayer, a boy, aged seventeen, who had a small hernial protrusion 4 cm. above and to the left of the umbilicus. This hernial protrusion projected 1 cm. through the fascia and was lobulated, forming a mass 3 cm. in diameter. The patient was of spare build. On cutting down on the hernial sac I found a small defect in the abdominal wall, through which protruded a small portion of the omentum. The omentum was readily returned, and the opening easily obliterated with a few sutures.

In the Journal of the American Medical Association (October 14, 1911, lvii, 1251) I reported a most unusual case of an ovarian tumor which had passed through a hernial opening to the outer side of the right rectus and at a point a considerable distance from the umbilicus. Although this case is slightly foreign to diseases of the umbilical region, it is of sufficient interest to warrant description here:

**A n E x t r a - a b d o m i n a l M u l t i l o c u l a r O v a r i a n C y s t .**— On October 31, 1910, I saw, with Dr. Frank R. Smith, a woman who had a kidney-shaped tumor slightly below and to the right of the umbilicus. The patient had noticed a small lump in this situation several years before, which, for a long while, had remained quiescent, but during the last year had gradually increased in size. At operation it was found to be a partly solid, partly cystic tumor of the ovary, lying external to the abdominal muscles, the tumor and its surrounding sac being covered over with a small amount of adipose tissue and the skin. The pedicle of the tumor passed through a hernial ring to the outer side of the right rectus and obliquely across the lower abdominal cavity to what corresponded to the normal insertion of the right utero-ovarian ligament.

I have been unable to find any reference to a similar case in the literature.

**H i s t o r y .**— Mrs. M. W., aged fifty-six, was a short, well-developed woman, and apart from a tumor mass in the lower abdomen was in excellent health. She had had 11 children. Her periods had ceased at fifty. She had felt some pain in the right ovarian region for fifteen years, and for about ten years she had noticed a little tumor situated in the right lateral abdominal wall slightly above a line drawn between the umbilicus and the anterior superior spine. This, from her description, seemed to have been about the size of an ovary. During the last ten months this small lump had increased in size until it formed a lobulated mass, elongate in form, about 10 by 8 cm. It seemed to be but a short distance beneath the skin, and could be lifted up to some extent in the hand, but its absolute relationship could not be determined on account of the presence of a considerable amount of adipose tissue.

**O p e r a t i o n .**— November 1, 1910. On making a pelvic examination under

anesthesia, I found that the uterus was normal and that there was no thickening laterally. Not being sure of the exact condition, I made a median incision. The uterus was normal; the left tube and ovary presented the usual appearance. The right tube showed no change, but the right utero-ovarian ligament was markedly drawn out into a band about 1 cm. broad. This led to a hernial opening with smooth margins in the right lateral abdominal wall, below and to the right of the

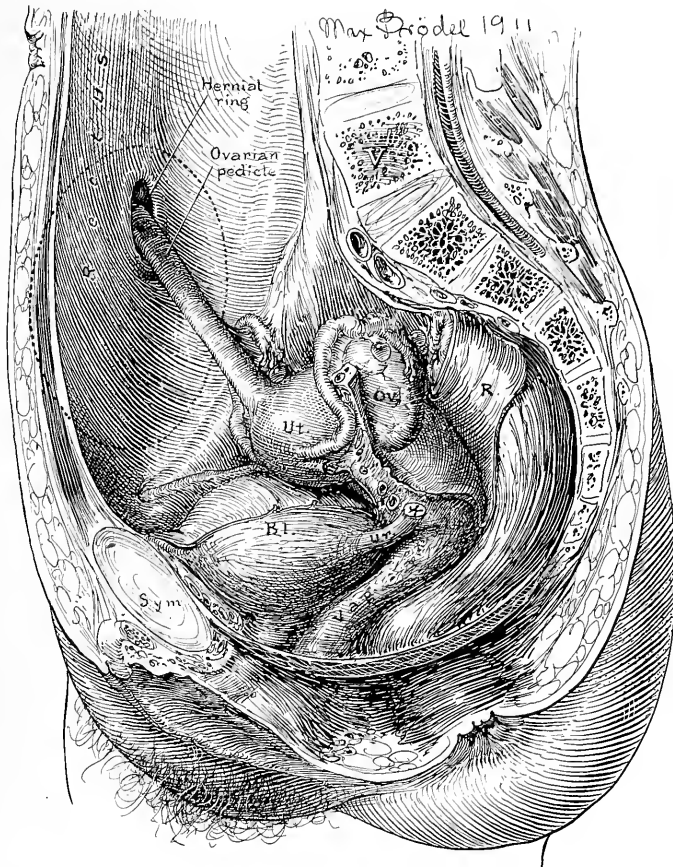


FIG. 55.—OVARIAN PEDICLE PASSING FROM UTERUS OUT THROUGH A HERNIAL RING IN THE ABDOMINAL WALL.

A schematic representation of the pelvic structures as found at operation. The uterus and left appendages were normal. The right tube was unaltered, but passing from the uterus, where the right ovary should have been, was a band 1 cm. broad. This ran upward and outward and passed out through an abdominal ring to the outer side of the right rectus. At the ring a finger could be passed completely around this pedicle. It was nowhere adherent to the ring. The exact location of the ring is well shown. On looking through it a small portion of the glistening tumor could be readily seen. The dotted line indicates the relative size of the tumor.

umbilicus, but at least 12 cm. from the inguinal region (Fig. 55). After obtaining good exposure I found that this flattened band of the utero-ovarian ligament passed directly into a hernial opening about 2.5 cm. in diameter, and into this opening a finger could readily be introduced. The intra-abdominal portion of the pedicle was clamped off and sutured. An incision was then made over the prominent part of the abdominal tumor, which proved to be extra-abdominal. The more prominent part of this tumor lay directly beneath the skin, in the adipose tissue, and was

very easily freed by blunt dissection to the point where the hernial ring entered the abdomen. I then cut the peritoneum around the hernial ring and delivered the tumor, with its peritoneal covering intact. The space occupied by the tumor having been obliterated, and the inner incision having been sutured, the outer wound was now closed. The ovarian tumor was multilocular.

There had evidently been a hernial protrusion through the right lateral abdomi-

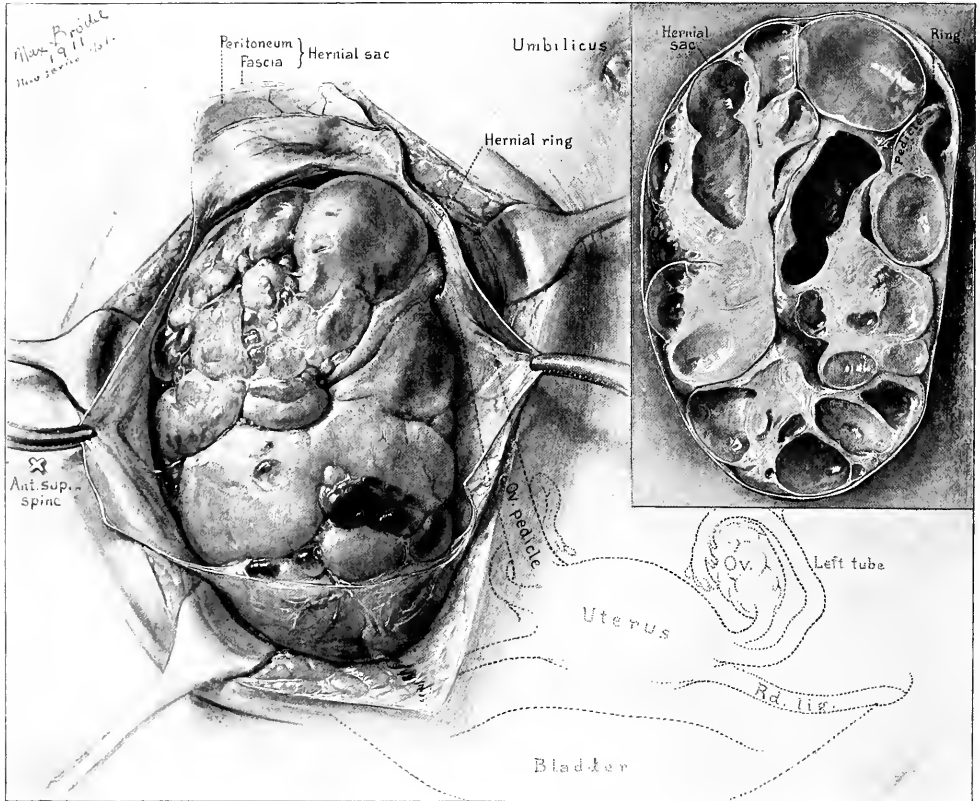


FIG. 56.—EXTRA-ABDOMINAL MULTILOCULAR FIBROCYSTOMA OF THE OVARY.

The dotted lines indicate the pelvic structures and the right ovarian pedicle passing upward and outward until it emerges from the hernial ring, a short distance below and to the outer side of the umbilicus. After the abdominal relations had been determined, an incision was made directly over the tumor, and it and its peritoneal covering were removed intact. A thin layer of fascia and the peritoneum formed the sac. The tumor was roughly kidney-shaped and lobulated; it consisted partly of a solid tissue, partly of cysts. Deep clefts subdivided the tumor into several portions. The tumor in the main was free from adhesions, but in a few places there were points of union between it and the peritoneal covering. The drawing in the right upper corner shows the tumor on section. The fibrous tissue is abundant, but at this level the cysts predominate. The clefts are seen to have extended through the tumor. It was possible to lift the various segments out without disturbing the remaining ones. Fig. 57 gives the real form of the tumor when liberated from pressure.

nal wall, into which the ovary had dropped and in which it had remained for several years. During the last year it had increased in size and given rise to a multilocular ovarian cyst. Naturally, with the increase in size, the escape of the ovary from the sac had become impossible.

**Macroscopic Examination of Hardened Specimen (Path. No. 15,723).**—The hernial opening was about 2.5 cm. in diameter. Its margins

consisted of peritoneum, outside of which was a zone of adipose tissue. The tumor itself was kidney-shaped (Fig. 56), 12 cm. long, 7 cm. broad, and 6 cm. in thickness. It was covered everywhere with peritoneum, which could be readily separated from it. Here and there, attached to the outer surface of the peritoneum, were tags of adipose tissue. The tumor itself was in large measure solid, resembling a fibroma. It presented a lobulated appearance (Fig. 57). Here and there between nodules it showed cystic spaces, oblong, irregular, or round, varying from 2 mm. to 2 cm. in diameter. The majority of these were transparent and contained clear fluid. Some of them were slightly blood-tinged. So much could be made out through a window which was cut in the peritoneum. On peeping in through the hernial ring one could see cysts varying from 2.5 cm. to 3 cm. in diameter, and apparently filled with clear fluid. After the drawing had been made, the tumor was cut in two. The appearance on section is well shown in the drawing in the right upper corner of Fig. 56.

**Histologic Examination.**—The solid portion of the tumor consisted in large part of fibrous tissue containing triangular or spindle-shaped nuclei. In some places the nuclei were abundant, in others scanty in number. The tissue showed a considerable degree of hyaline degeneration. At one or two points characteristic ovarian stroma was still in evidence. No Graafian follicles could be found, but after an examination of numerous sections a typical corpus fibrosum was noted. In some sections a few bundles of non-stripped muscle were visible. The stroma had a meager blood-supply, except in a few areas, where there were groups of rather large veins.

Scattered sparingly through the stroma were small circular or irregular glands, occurring singly or in groups of two or three. They were found to be lined with cylindric epithelium, and were similar to those so frequently noted in the hilum of the ovary. Some of the very small cystic spaces, noted macroscopically, were lined with cylindric ciliated epithelium and had an underlying stroma that stained rather deeply and that consisted of cells with oval vesicular nuclei. This stroma stood out in sharp contrast to the surrounding fibrous tissue. Such cysts frequently contained a little fairly fresh blood. They reminded one very much of the cystic spaces so frequently noted in an adenomyoma, but I believe that they represented only the earlier stages of the larger cysts.

The large cysts were lined with one layer of epithelial cells, which were cylindric, cuboid, or almost flat. Projecting into some of the cysts were papillary folds. These occasionally occurred as delicate, irregular, finger-like projections, but in the main as blunt, single, or branching outgrowths. All of them were covered over

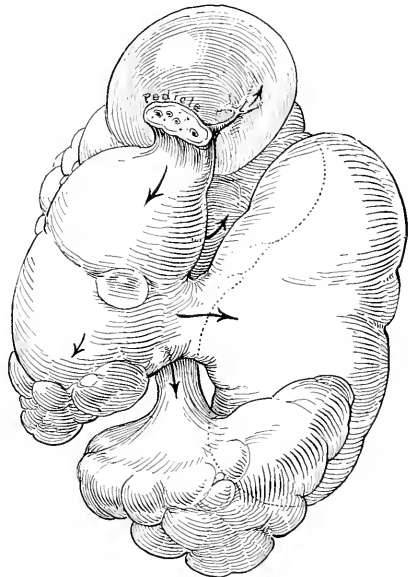


FIG. 57.—AN EXTRA-ABDOMINAL MULTILOCULAR FIBROCYSTOMA.

A schematic representation of the shape which the tumor tended to assume, when relieved from its surrounding pressure. It in reality consisted of four lobes similar in character and joined together by broad or narrow pedicles.

with one layer of epithelium. The stroma of the papillary masses had in many places undergone almost complete hyaline degeneration, and in a few liquefaction of this hyaline material had taken place. Even in some of the larger cysts a moderate amount of fresh blood was present. The stroma cells beneath the cyst epithelium had in some places become swollen and spheric, and were filled with yellow or brown pigment, indicating the absorption of blood at some previous time.

On the surface of the tumor were a moderate number of vascular adhesions, and on the under and protected side of these the peritoneal cells had become cuboid, as is common on the under side of tubal or ovarian adhesions.

From the above description it will be seen that the dense matrix of the tumor consisted essentially of fibrous tissue, and that scattered throughout this were multiple cysts, in large measure similar in character, some of which had small papillary masses projecting into them. Had the tumor developed in the abdominal cavity, I believe that in all probability it would have been a multilocular cystoma, but as it lay between the abdominal muscles and skin, a rapid cystic growth was much more difficult, and the fibrous tissue was thus allowed to keep pace with the cystic formation.

There was no sign of malignancy.

Dr. Bloodgood tells me that he observed a case of hernia of the abdominal wall at the semilunar line, that was between the rectus muscle and those forming the lateral abdominal wall. The sac contained non-adherent loops of small bowel. The condition was readily cured. In our case the opening was also at, or near, the semilunar line, but instead of small bowel, the ovary had for some reason occupied the space and later had gone on to tumor development. It is just possible that this weakness in the wall had become particularly accentuated during a pregnancy, and that the ovary, during its ascent with the pregnant uterus, had dropped into the cavity. The possibility of an embryonic displacement of the ovary cannot, of course, be excluded.

#### THE RELATION OF THE OUTSIDE OF THE UMBILICUS TO THE PERITONEAL SIDE.

Out of 13 complete umbilici, in 8 Levadoux noted a posterior umbilical fossette; in the other 5 cases the orifice was well closed by the umbilical fascia, which descended to its inferior border. When the fascia was raised, the fibrous ring was readily seen to be more or less open behind. In the 9 umbilici showing the teat-like elevation, without cushion, in 3 there was a corresponding peritoneal fossette; four others had only fascia covering the posterior opening of the fibrous ring; in the 2 others the fascia and fossette were absent. The opening was well closed by cord-like branches of the vessels. The type of the incomplete umbilicus, with cushion and without teat-like elevation, is much more common (in 23 out of 50 cases). Frequently it shows a well-closed fibrous orifice. In 3 cases only did Levadoux note the peritoneal fossette; in 4 cases the umbilical fascia descended behind the ring. Out of 15 cases, in 9 the orifice was closed by a simple reapproachment of the margins, in 6 by a soldering of the margins and anastomosis of the fibrous cord of the inferior umbilical with the superior umbilical vessels. As a result of these studies Levadoux draws the following conclusions:

(1) The teat-like elevation of the umbilicus corresponds nearly always with the fibrous ring, which is open.



(2) When the cutaneous umbilicus is complete, in the majority of cases (8 out of 13) an umbilical peritoneal fossette is present.

(3) The umbilicus without the teat-like elevation usually corresponds to a fibrous ring that is closed (24 out of 27 times). The same holds good in obese subjects.

(4) The existence or the non-existence of the umbilical fascia at the level of the fibrous ring bears no relation to the cutaneous form of the umbilicus.

Having gone fully into the findings of Levadoux, I shall merely mention the results obtained by Brödel in his studies of the embryology of the umbilical region.

Fig. 16 gives the intraperitoneal view of the umbilicus in a human embryo 6.5 cm. long.

Fig. 17 gives the intraperitoneal view of the umbilicus in a human embryo 7.5 cm. long.

Fig. 18 gives the intraperitoneal view of the umbilicus in a human embryo 9 cm. long.

Fig. 19 gives the intraperitoneal view of the umbilicus in a human embryo 10 cm. long.

Fig. 20 gives the intraperitoneal view of the umbilicus in a human embryo 12 cm. long.

Fig. 21 gives the intraperitoneal view of the umbilicus in a human embryo 12 cm. long.

Fig. 22 gives the intraperitoneal view of the umbilicus in a human embryo 12 cm. long.

Fig. 24 gives the intraperitoneal view of the umbilicus in a human embryo 15 cm. long.

Fig. 28 gives the intraperitoneal view of the umbilicus in a human embryo about five months old.

Fig. 29 gives the intraperitoneal view of the umbilicus in a human embryo six to seven months old.

These pictures show the relations of the umbilical arteries to the urachus, and their mode of termination at or near the umbilical ring. They also give the relations of the umbilical vein. They show the appearance of the umbilical ring as viewed from the abdomen, and depict the mesenteries frequently found supporting the umbilical vessels and the urachus.

Figs. 35, 36, and 37 give accurate types of the adult umbilicus as seen at operation or at autopsy.

#### THE UMBILICUS IN ANIMALS.

In a comparative study of the umbilicus Levadoux examined two species of hoofed animals, the horse and the donkey. He examined ten horses and two donkeys. In these animals the umbilicus is represented by an ellipsoid depression, arranged in a cranio-caudal direction. Posteriorly it is bounded by a smooth surface and a rudimentary vestige of a cutaneous cicatrix. In front of this the hairs have a disposition to diverge, on account of a sagittal line which forms a grand axis of the depression and produces what may be termed a "tuft." This disposition of the hair is entirely contrary to that observed in man, where the hairs of the umbilical region converge toward the umbilicus.

Levadoux (p. 18) says that in mammals there exists a cutaneous depression, circular in form, and completely covered with hair, located in the median abdominal line at the same height as in the solipeds.

For rodents Levadoux confined his observations to the mouse, water-rat, guinea-pig, and rabbit. In the mouse and in the rat nothing can be seen from the outer surface to indicate the point of implantation of the umbilical cord. In the guinea-pig, on the other hand, toward the middle of the median abdominal line, is seen a circular surface divested of hair, somewhat prominent, and about 3 mm. in diameter. It is surrounded by a circular furrow, and suggests the elevation in the human umbilicus. Thus, the cutaneous abdominal cicatrix is absent in the mouse and rat. The hairs have no special disposition. The rabbit does not present the cutaneous umbilical cicatrix, but the linea alba is clearly visible throughout the entire length of the recti muscles.

The carnivora are then dealt with (p. 23). The cat and the dog were studied. So far as regards the umbilical region, the cat has nothing to distinguish it from the rabbit. The anatomy of the umbilical region of the dog is more interesting, because it resembles more closely that found in the human being. The cutaneous surface of the umbilicus presents teat-like projections, smooth or covered with silky hair-follicles which project to a greater or less extent. Surrounding this teat-like projection is a furrow, and sometimes around the furrow is a remnant of a cushion. This arrangement was noted in 7 out of 10 cases. In the other cases the teat-like projections were lacking, and Levadoux found nothing more than a depression. All the abdominal hair converged toward the umbilicus.

The inner surface of the umbilicus of the horse and donkey shows a lozenge-shaped hollow which corresponds to the cutaneous depression. This is surrounded in all directions by a fibrous cord which is half cylindrical and firmly attached. The two cords which are formed of longitudinal fibers unite at the two extremities of the lozenge and terminate in the linea alba, 4 or 5 cm. from their point of union. On transverse section at the site of this depression the fibrous thickenings are seen to be formed from the subjacent fibers, which become merged with those of the linea alba. The fibers in the linea alba have a radiating direction as regards this lozenge, and the deeper ones are inserted in its margins. At its anterior extremity, at the point of reunion of the two pillars, it is represented by a cylindrical cord which is the remains of the umbilical vein. This cord, which is intimately connected with the abdominal wall by the peritoneum, terminates in the inferior surface of the liver. In the solipeds there does not exist a vestige of the urachus or of the umbilical arteries. The peritoneum which covers the bottom of this depression is separated by the transversalis fascia.

On page 18 he briefly describes the inner appearance of the umbilicus in ruminants—the cow and the sheep. On page 20 he takes up the consideration of the rodents and describes the inner appearance of the umbilicus in the mouse, water-rat, guinea-pig, and rabbit.

#### THE LYMPHATICS OF THE UMBILICAL REGION.

Relatively little has been written on the lymphatics of this region, either by the clinician or the anatomist. The former studied the manner in which abdominal carcinomata reach the umbilicus, and the mode of dissemination of primary umbilical growths, whereas the anatomist has reached his conclusions by injecting the lymphatics of the umbilical region. Although our knowledge of the subject is as yet by no means complete, the findings are of much interest.

In Figs. 58 and 59 Max Brödel has given us composite pictures of what is known of the umbilical lymphatics.

Neveu, in 1890, speaking of secondary malignant tumors of the umbilicus, says that the superficial lymphatics below the umbilicus pass to the inguinal glands, while the superficial lymphatics above the umbilicus pass to the axillary glands. The deeper umbilical lymphatics situated just external to the peritoneum are very abundant, especially in the median line. The deep lymphatics below the umbilical region pass to the iliac glands; those above the umbilicus go to the retrosternal glands. Neveu then briefly quotes Sappey's findings.

Quénu and Longuet, in their exhaustive monograph on secondary cancer of the umbilicus (1896), say that the lymphatics constitute an excellent avenue along which abdominal carcinomata may reach the umbilicus. They describe the manner in which the lymphatics of the pyloric end of the stomach and those of the duodenum communicate with those of the under surface of the liver. From this point there is a free lymphatic communication with the umbilicus along the suspensory ligament.

Speaking of the mode of extension of pelvic carcinomata to the umbilicus, these authors say that certain lymphatics of the uterus pass along the round ligament to the inguinal glands, and at times to the iliac glands; that there is a free lymphatic communication between the umbilicus and the inguinal and iliac glands, and consequently there is a direct connection between the pelvic lymphatics and the umbilicus.

Le Coniac, in 1898, when considering carcinoma of the umbilicus, secondary to carcinoma of the uterus or ovaries, says that a direct lymphatic path can be traced from the pelvis to the umbilicus. He quotes the studies of Poirier, who also found that some of the uterine lymphatics pass to the inguinal region, while others enter the iliac glands. From either the inguinal or iliac glands the cancer may extend to the umbilicus, in the later part of the journey probably passing against the lymph current. In the chapter on Cancer of the Umbilicus the following occurs: "The careful study of many umbilical lesions in the past has demonstrated that when the liver is involved in a malignant growth, which has extended to or encroached upon the suspensory ligament, the growth tends to pass by way of the lymphatics out along the suspensory ligament to the umbilicus. When a malignant pelvic growth extends to the umbilicus, it usually follows the lymphatics found in the course of the remnants of the obliterated umbilical arteries and urachus upward to the umbilical depression. If the umbilicus is the seat of a malignant growth, the inguinal or axillary glands may be secondarily involved according as the growth occupies the upper or lower part of the umbilicus."

Of special interest are the reports of primary and secondary carcinomata (pp. 402, 412), in which is given a clear description of the various avenues along which the carcinoma may extend.

#### AN ANATOMIC STUDY OF THE UMBILICAL LYMPHATICS.

Cunéo and Marcille, in 1901, injected the umbilical lymphatics in 10 new-born children, and divided them into three groups, of which they gave the following description:

1. Cutaneous lymphatics.
2. Lymphatics of the fibrous umbilical thickening.
3. Lymphatics of the aponeurosis surrounding the umbilical ring.

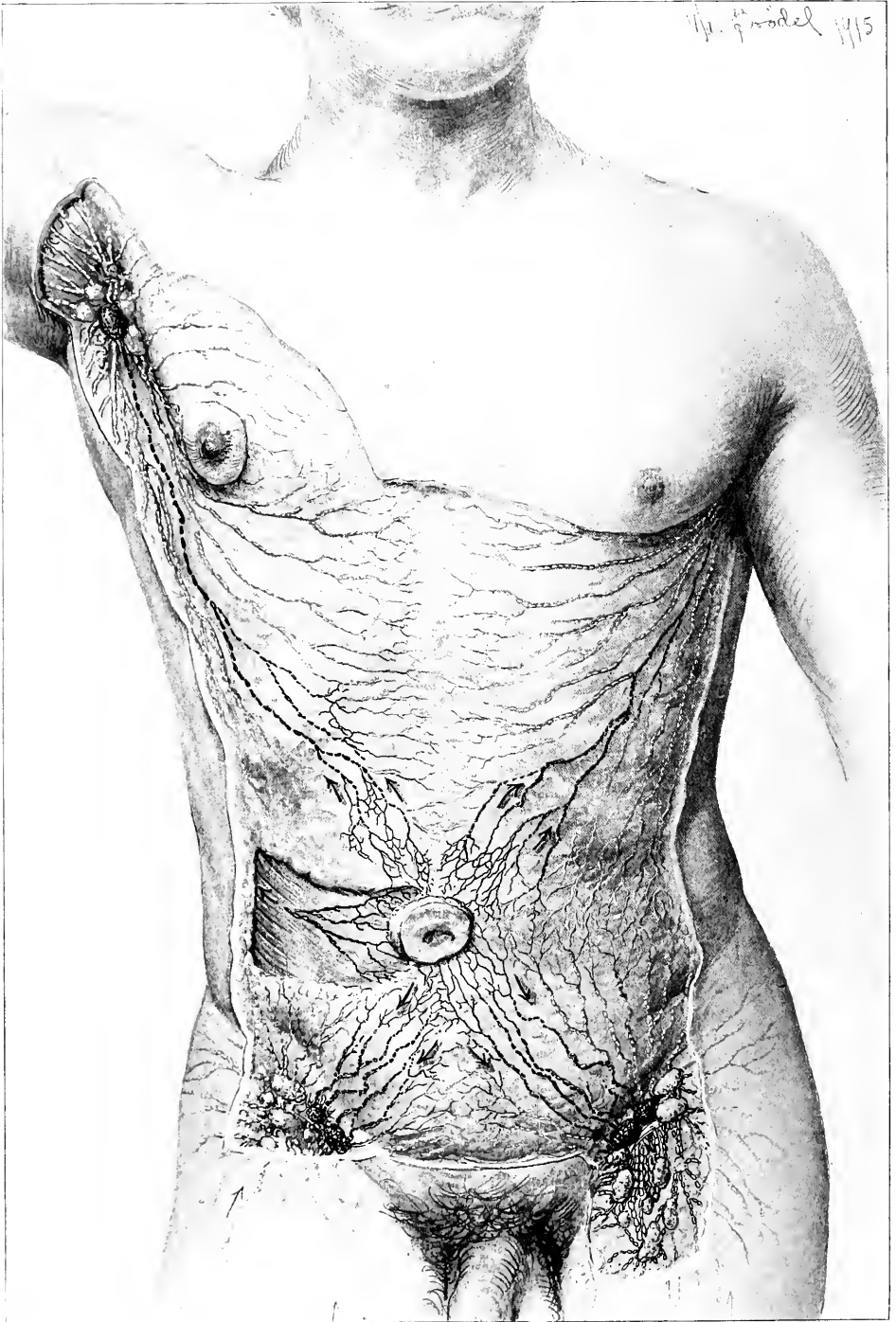


FIG. 58.—SUPERFICIAL LYMPHATICS OF THE UMBILICAL REGION.

This is a composite drawing based on the studies of Cunéo and Marcellé. The bulk of the lymph-channels pass in the subcutaneous fat and are seen to drain in four directions, the upper set passing to the axillary lymph-glands, while the lower empty into the external inguinal group. On the left side of the picture a small portion of the subcutaneous fat has been removed, showing branches of the deeper lymphatics resting on the muscular aponeurosis.

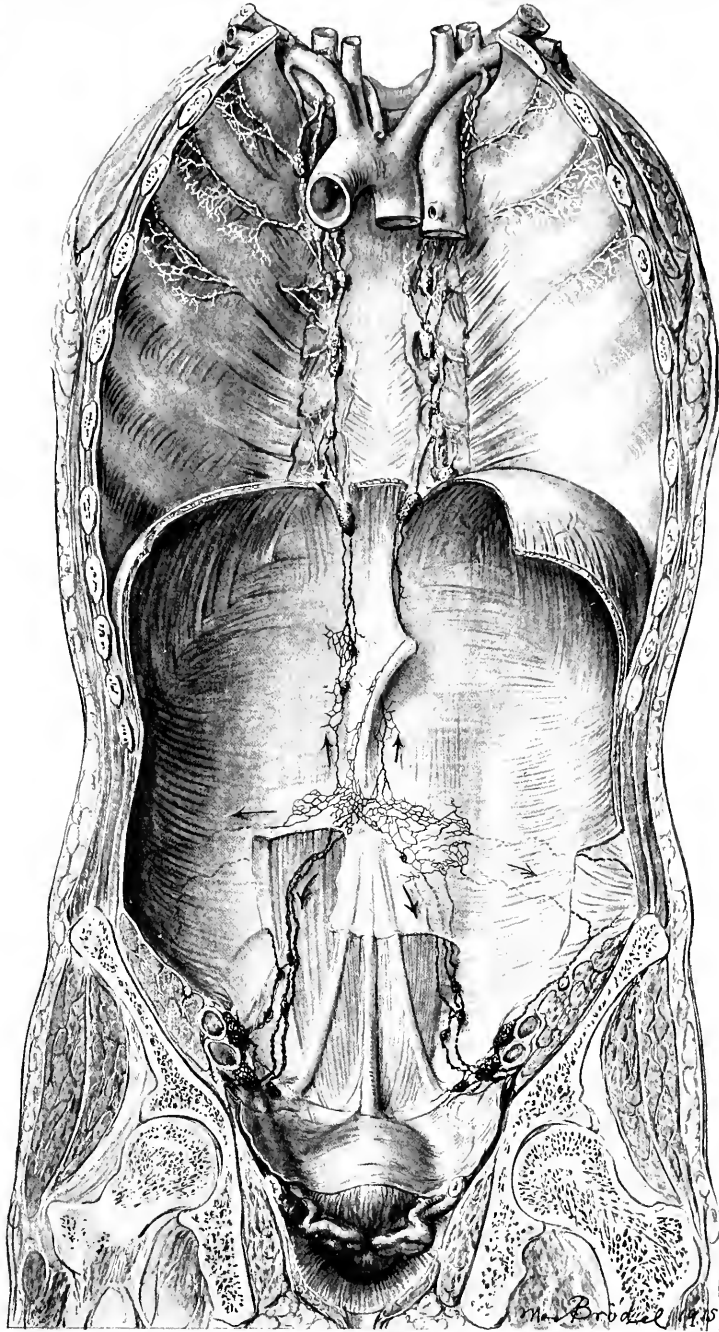


FIG. 59.—THE DEEP UMBILICAL LYMPHATICS AS SEEN FROM THE PERITONEAL SIDE.

This is a composite drawing, based on the studies of Cunéo and Marcille and Poirier. Like the superficial lymphatics, the deep likewise drain chiefly upward and downward. Those from the upper umbilical region pass on either side of the falciform ligament of the liver, pierce the diaphragm, and enter the anterior mediastinal glands. In their course small intercalated lymph-glands are occasionally found. An additional small lymph-channel is found along the course of the round ligament of the liver. It is along this channel that cancers of the stomach and gall-bladder find their way to the umbilicus. The lymphatics from the lateral portions of the umbilicus first pass outward and then, curving downward, reach the inguinal glands. The lymphatics from the lower portion of the umbilicus pass directly downward to the internal inguinal glands.

In the new-born the cutaneous lymphatics originate from the "umbilical serotum." They form a thin network which is difficult to inject. This network is continuous with that of the surrounding skin. From the umbilicus, four or five trunks pass in each direction immediately beneath the skin. They go downward and outward toward the fold in the groin, and terminate in two groups of glands—the superficial external and the superficial internal inguinal glands. It is unusual to see these lymph-trunks descending and passing over to the median line.

At the level of the umbilicus these authors were never able to inject a lymph-trunk that passed to the axillary glands.

The lymphatics of the fibrous cord were still more difficult to inject. From the fibrous cicatrix two or three lymph-trunks pass in each direction and disappear immediately in the sheath of the corresponding muscle.

The lymphatics of the aponeurosis of the umbilical ring are divided into two groups—the anterior and the posterior. The anterior lymphatics originate in the anterior or cutaneous surface of the corresponding sheath as a delicate network which encircles the umbilical ring. The resultant lymph-trunks are divisible into two groups. In the first and more important they run parallel to the sheath of the aponeurosis, disappear in it, and unite with those arising from the fibrous nodule. In the other the lymph-trunks pass outward parallel to the two obliques, and may be confused with those from the posterior aponeurosis.

The posterior lymphatics originate from a network attached to the posterior or peritoneal surface of the sheath. The collectors of this network may be divided into two groups. In the first the lymphatics pass upward and unite with the corresponding lymphatics, which, as we have seen, originate from the anterior part of the sheath of the muscle. These trunks follow their course in the sheath and terminate in the external iliac gland, resting on the anterior part of the iliac artery. The other trunks emanating from the posterior aponeurotic network pass downward in company with the vessels from the fibrous thickening, and usually accompany the epigastric artery, descending and terminating in the two external iliac glands immediately behind the crural arch. In the course of these lymph-trunks one may encounter from two to four glands, sometimes of small volume, which invariably accompany the epigastric artery. These are the epigastric glands of Gérota.

Cunéo and Marcille, in three out of ten cases, observed a small gland situated in the subperitoneal cellular tissue, 2 to 4 cm. below the umbilicus. This gland is always a little to one side of the median line. It was mentioned by Gérota in his work.

In one case they found two subperitoneal glands close to the umbilicus. They found that the lymphatics of the umbilicus anastomose with those of the liver and of the bladder by means of the lymphatic network which surrounds the umbilical vein and the network following the umbilical arteries and the urachus.

#### THE SENSORY NERVE-SUPPLY OF THE UMBILICUS.

Spiller reviewed the literature on this subject in the Philadelphia Medical Journal, February 8, 1902, and reported a case that he had had under observation.

Spiller and Weisenburg (1904) discussed the subject still further. Boettiger had been uncertain whether the umbilicus lies in the distribution of the ninth or of the tenth thoracic segment. Walton had put it in the distribution of the eleventh thoracic segment; Déjerine in the distribution of the tenth thoracic segment. Head had attributed to the tenth thoracic sensory segment the supply of the sub-umbilical region, and had described the upper border of the segment as passing directly through the umbilicus. Spiller and Weisenburg say: "From this review it will be seen that there is much to be said in favor of the situation of the umbilicus within the tenth thoracic sensory segment, but this is an opinion we are unable to accept." In a preceding paper Spiller had reported a case indicating that the umbilicus lies between the ninth and tenth thoracic sensory segments, and in a later paper a second case that was observed until death. From the data thus obtained Spiller and Weisenburg think that the umbilicus probably lies within the zone of the ninth thoracic segment. They say that the importance of this determination must be apparent on account of the prominence of the umbilicus as a surgical landmark.

#### THE SKIN UMBILICUS.

Runge, in his chapter on "Wound Infections of the New-Born" (p. 61), says that at the fetal end of the cord the amnion passes directly to the skin of the child. This point of transition occurs, as a rule, from 0.5 to 1 cm. out on the cord, and ends in a ring-shaped swelling. If the skin passes farther out on the cord, it is spoken of as a skin or flesh umbilicus. It is the antithesis of an amniotic umbilicus.

#### THE AMNIOTIC UMBILICUS.

Nicaise, in 1881, referred to this very rare condition. He said that, according to Widerhofer, it is characterized by an absence of skin around the umbilicus, the defect being replaced by amnion which is reflected upon the abdomen from the cord. In such cases the surrounding abdominal wall is usually intact. The amniotic umbilicus is small, and does not interfere with the health of the child. In the case mentioned by Nicaise the amniotic disc was gradually replaced by scar tissue and the umbilicus completely closed.

Runge, in 1893, when discussing this subject, said that in rare cases there is a preponderance of amnion and a lack of skin at the umbilicus. The amnion spreads out as a flat funnel around the umbilicus, and the condition is spoken of as an amnion umbilicus.

A careful study of Fig. 2, p. 2, Fig. 3, p. 3, Fig. 197, p. 462, will render clear the mode of development of the amnion.

#### ABSENCE OF THE UMBILICUS.

As pointed out by Nicaise, the umbilicus may be confounded with the upper portion of an exstrophy. In such a case it is more distinct behind than in front of the abdominal wall. Sometimes it is situated immediately above the exstrophy; more rarely it is 3 or 4 cm. distant from it. The umbilical vein may be longer than normal. The umbilical arteries are slender and shorter. The urachus is wanting

when the umbilicus corresponds to the upper portion of the exstrophy. In such cases there is no real absence of the umbilicus, but an unusual disposition of it, due to the exstrophy, which in turn is caused by the failure of the allantois and of the abdominal walls to close.

Evans, in 1895, referred to a young white man who virtually had no umbilicus—there was scarcely any depression, the parts being quite flush with the abdominal wall. As noted on page 62, there is no trace of the umbilicus in certain animals, and if the surgical treatment of the cord, as carried out by Dickinson, Flagg, and Buckmaster, were generally adopted, it would not be long before many adults would have but the faintest suggestion of an umbilicus.

#### THE UMBILICUS DURING PREGNANCY.

According to Nicaise, modifications of the umbilicus during pregnancy have been studied chiefly by Dubois, Cazeaux, and Stoltz. Catteau has also described them. Nicaise says that alterations in the umbilicus differ in the primipara and in the multipara. After the first and second months of the first pregnancy the umbilicus is drawn in a little; the patient has a sensation of a painful pulling at this point, and the umbilical region has an increased sensibility. At the third or fourth month the umbilicus is normal, but the umbilical area is slightly raised. In small patients the changes are more rapid and more marked. At term the umbilicus itself is generally raised a little above the surrounding parts, and its dimensions are increased. (Plate IV, 60, and Plate VI, 4.) Sometimes the umbilical ring is dilated and permits the introduction of the tip of the finger. The umbilical cicatrix is more easily depressed, and the umbilical furrow is less marked. Hernia of the intestine or of the omentum rarely follows a first pregnancy.

During the following pregnancies the modification of the umbilicus is more marked and more rapid, and the umbilicus is readily distended. At the ninth month the umbilicus itself has unfolded, and is even with the abdominal wall. Nicaise says that the umbilicus at this time is distinguished only by the white coloration above and by the fine character of the skin of the scar.

The umbilical areola, according to Nicaise, is rare. He quotes Montgomery, who says that a brownish zone at times completely surrounds the umbilicus, and forms an areola analogous to that of the breasts.

Evans, when discussing the subject in 1895, said that an umbilical areola is an unimportant secondary sign of pregnancy, for by the time that the condition has advanced sufficiently to cause bulging at the umbilicus, the diagnosis is usually clear.

#### LITERATURE CONSULTED ON ANATOMY OF THE UMBILICAL REGION.

- Bert, A., et Viannay, Charles: Étude sur la morphologie de l'ombilic. *Compt. rend. de l'assoc. des anatomistes*, 104, vi, 116.
- Catteau, J. F.: De l'ombilic et de ses modifications dans les cas de distension de l'abdomen. *Thèse de Paris*, 1876, No. 210.
- Cullen, Thomas S.: An Extra-abdominal Multilocular Ovarian Cyst. *Jour. Amer. Med. Assoc.*, October 14, 1911, lvii, 1251.
- Cunéo et Marcille: Lymphatiques de l'ombilic. *Bull. de la Soc. anat. de Paris*, 1901, année 76, 580.



- Evans, T. R.: Umbilical Freaks; Rationale of Umbilical Depression in Early Pregnancy. *Gaillard's Med. Jour.*, 1895, lxi, 28.
- Gauderon, A. E.: De la péritonite idiopathique aiguë des enfants; de sa terminaison par suppuration et par évacuation du pus à travers l'ombilic. Thèse de Paris, 1876, No. 148.
- Hertz, W. H.: Ueber einen Fall von Adenocarcinom des Nabels bei einer 58-jähr. Frau. Inaug. Diss., Würzburg, 1905.
- Küster: Die Neubildungen am Nabel Erwachsener und ihre operative Behandlung. *Langenbeck's Arch. f. klin. Chir.*, 1874, xvi, 234.
- Le Coniac, H. C. J.: Cancer secondaire de l'ombilic; consécutif aux tumeurs malignes de l'appareil utéro-ovarien. Thèse de Bordeaux, 1898, No. 19.
- Levadoux, Michel-Joseph: Variétés de l'ombilic et de ses annexes. *Fac. de Méd. et de Pharm. de Toulouse*, 1907, No. 711.
- Neveu: Contribution à l'étude des tumeurs malignes secondaires de l'ombilic, 4°. Thèse de Paris, 1890, No. 50.
- Nicaise: Ombilic. *Dictionnaire encyclopédique des sciences médicales*, Paris, 2. sér., xv, 1881, 140.
- Quénu et Longuet: Du cancer secondaire de l'ombilic. *Rev. de chir.*, 1896, xvi, 97.
- Runge: Die Wundinfektionskrankheiten der Neugeborenen. *Die Krankheiten der ersten Lebensstage*. Stuttgart, 1893, 56.
- Spiller, William G., and Weisenburg, T. H.: A Further Study of the Sensory Segmental Zone of the Umbilicus. *Review of Neurology and Psychiatry*, Edinb., October, 1904, ii, 680.

## CHAPTER III.

### UMBILICAL INFECTIONS IN THE NEW-BORN.

General considerations.

Autopsy findings.

Clinical history.

Gangrene.

An epidemic of erysipelas of the abdominal wall in new-born infants. Trousseau, 1844.

An epidemic of erysipelas and gangrene of the umbilicus. Meynet, 1857.

An epidemic of gangrene of the umbilicus. Bergeron, 1866.

Non-puerperal erysipelas of the new-born infant. Yot, 1873.

Runge on wound infection of the new-born.

Mild disturbances in healing of the wound of the umbilicus.

Omphalitis.

Gangrene of the umbilicus.

Diseases of the umbilical vessels.

Erysipelas in the first days of life.

Septic pyemia and infection of the umbilicus of the new-born. Cohn, 1896.

Umbilical sepsis in the new-born occurring in the nursery and child's hospital, New York, during 1896. S. W. Lambert.

Tetanus in the new-born.

Treatment of the umbilical cord. Dickinson's method.

Care of the umbilical stump—a bacteriologic study. Adair.

Persistent vitality of the umbilical cord.

UNTIL the advent of asepsis, myriads of children succumbed to umbilical infection within a few days or a few weeks after birth. To give a thorough digest of the literature of the subject here would be out of the question, and I shall confine myself to a consideration of the more important articles bearing on the subject.

Meynet, in his monograph published in 1857, mentions the fact that Hippocrates drew attention to umbilical infections. He also refers to the writings of Ambroise Paré, of Mauriceau in 1712, of Hamilton in 1785, of Underwood in 1786, and of Billard.

Personally I have derived much information on the subject of umbilical infections from the articles of Trousseau (1844), Bednar (1850), Lorain (1855), Meynet (1857), Bergeron (1866), Pollak (1869), Yot (1873), Nicaise (1881), Meyer (1891), Runge (1893), Gremillon (1895), Lambert (1896), Cohn (1896), Dickinson (1899), Hinsdale (1899), Pinkerton (1900), Tarnier and Budin (1901), Wassermann (1901), Porak (1901), Maygrier (1901), Salge (1904), Porak and Durante (1905), and Cumston (1905).

Umbilical infections may be frank or masked. Unmistakable evidences of inflammation, such as redness, swelling, and discharge, may be present, or the umbilicus may show little or no evidence of disease, superficial healing occurring even when an infectious process is going on in the underlying tissues.

The umbilical infections have been designated as erysipelas, puerperal fever of the new-born, or gangrene, according to the different clinical manifestations ex-

hibited. They are all due to infection through the umbilicus, and are usually caused by the same organisms.

#### AUTOPSY FINDINGS.

A careful study of the autopsy findings will not only give a clear idea of the general condition, but will also permit a correlation of the various symptoms with the avenues of infection concerned. Infection may occur before or at birth, but the symptoms usually first appear at some time between the third and the eighteenth day after birth.

**A p p e a r a n c e o f t h e U m b i l i c u s .**—In some cases the umbilicus looks perfectly normal; in others there is a small opening from which pus is seen escaping; or the umbilicus is represented by a small ulcerated area. The tissue surrounding the umbilicus is sometimes soft, sometimes red and indurated, and occasionally, by gently stroking the abdominal wall from the symphysis upward, one can express a few drops of pus from the umbilicus. This pus may be watery, yellowish or greenish-yellow in color, the difference depending in large measure upon the pathogenic organism present and the duration of the infection.

When we cut into the abdominal wall, we may find the umbilical vein and the umbilical arteries perfectly normal, although the surrounding tissue is infiltrated.

The umbilical arteries and the umbilical vein as they appear at birth are seen in Fig. 60. These vessels rapidly atrophy and become impervious cords, as indicated in Fig. 61.

Much controversy has arisen as to the mode of extension of the infection from the umbilicus. Some authors claim that extension of the disease takes place through the umbilical vein; others that the arteries are responsible for the dissemination of the purulent process, and still others that the virus is carried by the umbilical lymphatics. A careful study of the autopsy findings in numerous epidemics clearly shows that in some epidemics the vein, in other epidemics the arteries, often showed marked changes; in not a few cases, however, the arteries, vein, and lymphatics were all implicated. Practically it matters little along which avenue the infection travels, the chief thing to remember is that, in the past, infection through the umbilicus at birth has been very frequent and has led to most disastrous results. The umbilical arteries may show no change, or one or both may contain partially or completely organized clots. When it is infected, the vessel often contains purulent material, and in some cases, as a result of the accumulation of pus, presents a fusiform swelling. The surrounding tissue in such cases often shows a considerable amount of edema or even a purulent accumulation. When the umbilical vein is implicated, pus may be present in its umbilical portion; frequently, however, it contains here an organized thrombus, but in the neighborhood of the liver is filled with purulent material.

**I m p l i c a t i o n o f t h e V a r i o u s O r g a n s .**—**L i v e r .**—When the umbilical vein is partially or completely filled with pus, it is only natural that the liver should be implicated. Sometimes the organ is a little enlarged. It may contain small abscesses, and an acute inflammation of the veins of the hepatic lobules may be noted. As a result of the extension of the infection a subphrenic abscess may develop.

**L u n g s .**—In some epidemics the lungs have shown marked changes. Some-

times these took the form of a hemorrhagic pneumonia, multiple hemorrhagic foci being scattered throughout the lung. In other instances pulmonary infection manifested itself by blackish-green patches of gangrene, and in some cases scattered multiple abscesses as large as hazel-nuts were found in the lungs. As would naturally be expected, when these foci of consolidation had reached the surface of the lung, a pleurisy had developed.

**Heart.**—Only slight changes are the rule, but purulent endocardial exudates have been noted associated with a purulent pericarditis. In such cases the blood from the heart has been found to contain the organism responsible for the infection.

**Kidneys.**—Signs of a parenchymatous nephritis are sometimes demonstrable.

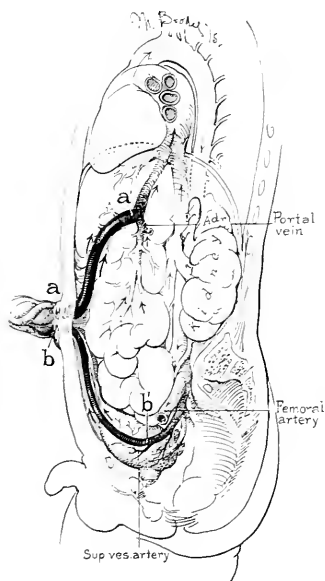


FIG. 60.—THE UMBILICAL VESSELS ABOUT THE TIME OF BIRTH.

The umbilical vein (*a*) conveys placental blood to the fetus. At *a'* it is joined by the portal vein, the combined trunk forming the ductus venosus. The arrows indicate the course of the blood to the heart. The blood passes from the fetus back to the placenta through the two umbilical arteries (*b* and *b'*), only the left of which is clearly seen in the picture. It was chiefly through the umbilical vein and the umbilical arteries that fatal infections of the child were so prone to occur in former years. As will be noted in Fig. 61, these vessels become obliterated after birth.

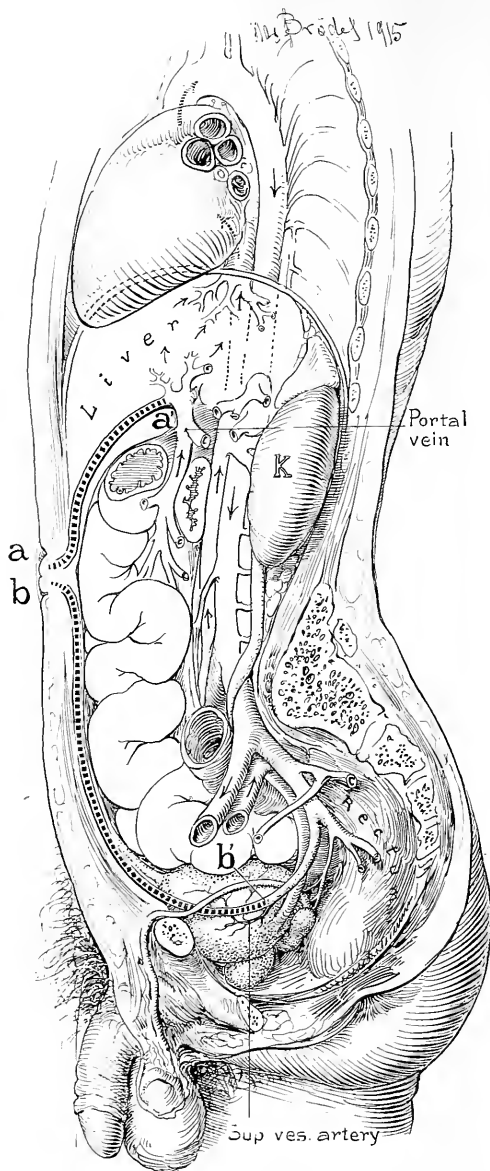


FIG. 61.—THE UMBILICAL VESSELS IN THE ADULT.

As soon as the cord is tied the usefulness of the umbilical arteries and of the umbilical vein is over, and these vessels become gradually transformed into solid cords. *a-a'* represents the situation of the obliterated umbilical vein from umbilicus to portal vein. The ductus venosus has vanished. The location of the left umbilical artery is indicated by the dotted line *b-b'*. The artery is obliterated from the umbilicus to the point of origin of the superior vesical artery. The umbilical artery is the continuation of the anterior division of the internal iliac.

**Brain.** — Occasionally a meningitis or multiple cerebral abscesses are present.

**Peritoneal Cavity.** — As a rule, there is little or no peritonitis unless there has been an extension of the infection directly through from the umbilicus to the peritoneum by continuity.

**Terminal Infections.** — Sometimes one of the first signs may be a circumscribed patch of erythema on the abdomen, buttock, cheek, eyelid, or the ear, or, in fact, on any part of the body. Swelling in the abdominal wall, between the umbilicus and symphysis, together with swelling of the testicle, with or without abscess formation, is not uncommon.

**Infection of various joints** — of the phalangeal joints, wrist, elbow, shoulder, hip, knee, ankle, and toes — has been noted in some epidemics. In such cases, when the process has been a very rapid one, a terminal joint has been found at autopsy to be the only one implicated, whereas when the disease had been of some duration, the pathologic process had extended toward the trunk. In some cases gangrene of the extremities had developed and the joints showed disorganization.

In the early days bacteriologic examinations, of course, were not made, and fortunately at the present time epidemics of umbilical infection are rare. The organisms most commonly found are *Streptococcus*, *Staphylococcus aureus* and *albus*, and *Bacillus coli*. Occasionally *Bacillus pyocyaneus* has been noted. Tetanus will be discussed elsewhere.

#### CLINICAL HISTORY.

As a rule, the child appears well for several days after birth, but then commences to lose weight. At a period varying from three to eighteen days it grows restless and cries frequently. Its symptoms strongly suggest an intestinal upset, but an examination of the umbilical region will often clear up the diagnosis. On the other hand, the umbilicus may appear to be perfectly normal. As the infection advances the child will in some instances develop a fatal pneumonia or a cerebral abscess; or a blush on the buttock, abdomen, cheek, or elsewhere, or the swelling of an index-finger or of one of the smaller joints, may be the first indication of a general infection. In such cases one should always think of the umbilicus, and once more carefully examine it, since we know that in the vast majority of cases this is the avenue through which the infection occurs.

There is no definite set of symptoms; the clinical phenomena will depend in a large measure upon the organ or organs of the body that are secondarily infected. If the infection be of a mild grade, the child may gradually recover, but where "massive infection" exists, great depression soon develops and the patient speedily dies.

#### GANGRENE.

In the description of the autopsy findings and clinical picture of umbilical infections I have purposely omitted a description of gangrene of the umbilicus, preferring to consider it separately, although it is only another manifestation of an umbilical inflammation and is undoubtedly caused by the same organism or organisms. In the former cases the local manifestations of the disease are often overshadowed partly or completely by those of the general infection, whereas in cases of gangrene the local condition receives the greater part of the physician's attention.

Several days after labor the skin in the umbilical region may be slightly raised and assume a yellowish tinge, while the tissue surrounding it shows some reddening and is indurated. This slough may come away, leaving a very superficial skin wound. In many cases, however, the area gradually increases in size and the central portion of the slough becomes black, while along its edges there appears a narrow, violet-colored line—the line of demarcation. Liquefaction takes place, and the slough gradually comes away in pieces.

If the septic absorption be abundant, the child soon shows signs of toxemia and death may rapidly follow. Bednar, in 1852, when this malady was relatively common, gave a most vivid description of the local conditions in the severe cases. He spoke of the grayish-black or gray appearance of the umbilical slough, and of the surrounding zone of inflammation, which was often as large as a dollar or even as the palm of a hand. In such cases the blood-vessels were filled with dark thrombi or with pus. The peritoneum in the vicinity was often of a dirty red color, markedly injected, and covered with a plastic, purulent exudate; and in some cases peritonitis developed. The general symptoms were naturally those of septic absorption, and in the severe cases the patients rapidly succumbed.

In rare instances the slough involves the entire thickness of the abdominal wall, and when it comes away, the intestines escape through the break. A most interesting case of this character was reported by Pollak. The patient (J. W.) was well developed, and, when eight days old, weighed  $6\frac{1}{2}$  pounds. When six weeks old he became very restless, and gangrene developed at the umbilicus. The tissue surrounding the umbilicus showed a grayish-brown appearance, was soft and foul-smelling, and surrounded by a zone of redness. The abdomen was markedly distended. By the end of two days the area of gangrene had become the size of a four-kreuzer piece. On the fifth day the gangrenous patch was as large as a thaler, and the child refused the breast and appeared to be dying. It revived, however, and two days later the abdomen opened at the umbilicus, a loop of bowel protruded, and a perforation occurred on the following day. The child died on the ninth day of the disease. By this time the slough had come away completely and there was a granulating surface.

After this brief discussion of the autopsy and clinical findings in cases of umbilical infection in the new-born, I shall briefly refer to some of the former epidemics, and describe somewhat fully some of their more interesting features, as from these one can obtain a graphic picture of the unfortunate conditions that formerly existed.

#### AN EPIDEMIC OF ERYSIPELAS OF THE ABDOMINAL WALL IN NEW-BORN INFANTS.

Trousseau, in 1844, reported a most disastrous epidemic that occurred in the months of September and October, 1843. As will be noted, the erysipelatous inflammation in most of the cases attacked the abdominal wall, and in nearly all instances there was an infection of the umbilicus or of the tissues immediately beneath it.

In the beginning of his article Trousseau quotes Paul Dubois as saying that he has never seen an infant recover from erysipelas during the first month of life. After discussing the subject of erysipelas in the nursing infant, he gives a short

report of a family of 19, including the servants, in which, in the space of six weeks, 10 people were affected by what appeared to be a form of erysipelas. He then gives reports of several cases in detail.

**C a s e 1 .** — A boy, forty days old, developed signs of acute peritonitis associated with erysipelas. He died forty hours after the commencement of the trouble. There was some slight suppuration at the umbilicus.

**C a s e 2 .** — When the cord came away on the fifth day, there remained at the umbilicus a small area of suppuration with a surrounding zone of inflammation. The health of the child at that time, however, was perfectly good. Erysipelas developed on the twentieth day and the child died.

**C a s e 3 .** — A boy, eight days old, was affected with erysipelas. Applications of mercurial ointment were made, but death took place eight days after the onset of the disease. The umbilicus was the seat of an abundant suppuration and the erysipelas had spread to the lower extremities.

**C a s e 4 .** — A boy, three weeks old, was suffering from phlegmonous erysipelas and developed peritonitis. Death took place fifteen days after the onset of the disease. The mother had a grave puerperal sepsis. A great many of the women had died from puerperal sepsis in the hospital about the time of this patient's birth. There was an erysipelas of the scrotum and of the symphysis, but the umbilicus showed no evidence of reddening or of suppuration. At autopsy the cellular tissue of the abdominal wall was found infiltrated with pus; there was a seropurulent fluid in the peritoneum, and a false membrane on the convex surface of the liver.

Trousseau says that these observations are sufficient to show the extreme gravity of erysipelas in the new-born.

#### AN EPIDEMIC OF ERYSIPELAS AND GANGRENE OF THE UMBILICUS.

In reporting this epidemic in 1857, Meynet points out that the disease was readily divisible into two groups. In the one an erysipelatous inflammation of the umbilicus was the dominant symptom; in the other, ulceration or gangrene of the umbilicus.

Zinc chlorid, in the form of Canquoin's paste (zinc chlorid with wheaten flour), yielded most unusual results in this epidemic.

Meynet, in the beginning of his article, draws attention to the remarks of Paré, who regarded this malady as being so grave that he warned the surgeon not to raise a hand for fear that he might be accused of causing the death of the infant. Following a lucid description of the literature on the subject, he gives an epitome of two epidemics. One began in April, 1856, and lasted throughout May and a part of June. Early in December of the same year a second epidemic occurred. It was one of great severity, and lasted until January of the following year. It was similar to the first epidemic in that it ceased abruptly as a result of the preventive measures which were employed.

Meynet says that after the epidemic and up to the month of March, when he left the service, they had not had another case in the Infirmary in Paris. During the first epidemic puerperal fever was not prevalent, but in the second the umbilical infection in children coexisted with puerperal fever in women.

**Symptoms.**—The progress and the termination of the disease were the same in both epidemics.

Of 230 infants received at the Maternity during the month of April and to the end of June of 1856, 17 were born dead, leaving 213 living infants. Of this number, 53 were attacked—14 in the month of April, 25 in the month of May, and 14 in the month of June. Thirty-six of the infants died.

In the second epidemic, which occurred in December and January, 175 children were delivered at the Maternity: 12 were born dead, 163 living. Of this number, 36 were attacked and 8 died. Meynet says nothing is more variable than the period of incubation in cases of this disease. In some, symptoms were noted a few hours after birth, in others about the fourth or fifth day. Only rarely did they appear after the eighth day. In these last cases the cord was black and horny, but had not separated from the umbilicus.

In both epidemics he describes the condition as nothing more than an exaggeration of an ordinary phlegmon, by which he means a moderate inflammation of the umbilicus accompanied by the dropping off of the cord. This inflammation was accompanied by ulceration at the base of the cord, and a more or less abundant suppuration, which retarded the dropping off of this appendage and the cicatrization of the umbilicus. Very soon this inflammatory condition became more intense, and the moderate inflammation was succeeded by an intense phlegmon. In the umbilical region could be noted a redness which became more and more marked; it disappeared upon pressure, and formed a circle around the umbilicus. At the same time there appeared numerous circumscribed swellings. The tissue around the cord became ulcerated, the margins were undermined, the ulceration extended deep downward, and the surface of the depression was covered with a false membrane, grayish white in color and soft, from which a bloody, purulent, thick, fetid discharge frequently exuded. The ulceration increased in size. The reddish zone also became larger and took on the color of wine-lees. The swelling became more and more voluminous and was hard. In a large number of cases the red areola was surrounded by a circle of small vesicles more or less confluent, dirty white, round, not umbilicated, and containing a seropurulent fluid. Sometimes there was a circle of erysipelatous redness, surrounded by numerous blebs containing a serosanguineous fluid. The blebs ruptured and exposed the skin, which readily became involved in the area of ulceration.

The general condition of the child was not affected at the beginning, but after a time the appetite diminished and was entirely lost. The child refused the breast or any nourishment and cried continuously. Its skin became dry and withered. The pulse was accelerated, and the general satisfactory condition of the infant was replaced by emaciation. The face was drawn from severe suffering, and the nasolabial folds became hollow; the tongue was dry and red at the tip; in some cases it showed a thick coating, and occasionally a coincident thrush. The abdomen was distended and an obstinate constipation, but more frequently a diarrhea, was present. The case progressed with alarming rapidity, and the little infant often died in from thirty-six to forty-eight hours. Sometimes the course of the disease was more gradual, but even then a fatal termination was frequent.

In other cases the clinical course was different. The cord was sometimes friable and soft; sometimes it was dry or ready to drop as the result of ulceration. The ulceration commenced at the margin of the cord, and proceeded from the center to the circumference. It occupied all the bottom of the cavity, and extended in different directions, sometimes destroying the attachment to the skin. It followed



along the umbilical vessels for quite a distance, transforming their interior surface into a vast focus of suppuration. Sometimes, on the contrary, it would jump over the cutaneous external ring and invade the abdominal wall, spreading over a large area. In form it was also irregular; its margins were sometimes undermined. Most frequently, however, its surface was dull, of a grayish-violet color, and exhaled a gangrenous odor; or it was covered with a false membrane, which was thick, soft, and very adherent—the condition being analogous to what is known as “hospital gangrene.” In such a case the reddish, circular area was less circumscribed, but livid in color. The swelling was less pronounced, the pustular eruption sometimes lacking. With an increase in the severity of the general symptoms the infant would pass first into a state of great agitation, but speedily into a condition of collapse and death would ensue.

**Duration.**—The duration of the disease was extremely variable. In certain cases the suffering lasted from thirty-six to forty-eight hours; in others it was prolonged to three or four days, but rarely longer.

**Recovery.**—Where recovery took place, it was slow. The inflammation diminished in intensity, the ulceration ceased to spread, the false membrane disappeared gradually, and granulation tissue took its place. The secretion gradually became of a healthier nature, and the redness and tumefaction disappeared little by little. At the same time the general symptoms improved, the skin recovered its moisture and lost its heat; and finally, after a more or less prolonged convalescence, the infant recovered.

Meynet says that it is easy to see that the disease presents two distinct forms: one is characterized by the erysipelatous inflammation and by swelling of the subcutaneous cellular tissue, with a pustular eruption and ulceration. The other, on the contrary, commences as an ulceration and presents the appearance of hospital gangrene. In several cases he observed an extensive ulceration which always occupied the center of the surface of the abdomen.

In all of Meynet's 18 autopsies the extent of putrefaction was carefully observed. Twenty-four hours after death the abdominal walls showed a greenish tint, the epidermis was raised as if undergoing maceration, the reddish color of the erysipelas was transformed into a blackish tint, and the abdomen was distended. Beneath the skin the cellular tissue around the umbilicus was thickened, indurated, more dense, and more friable. This induration was due to infiltration into the matrix of the tissue, sometimes with an amorphous plastic material, sometimes with serum.

Meynet says that he never found this process localized as a distinct focus, and he draws attention to the fact that his results coincide with those of Trousseau and Bouchet. The thickness and induration became more marked toward the margin of the umbilical ring. At this point the peritoneum sometimes presented a circumscribed redness, evidently due to vascular arborization, but in only two instances did Meynet find a well-developed general peritonitis.

In these two cases the peritoneum showed marked reddening and there was a false membrane, slightly adherent to the convex surface of the liver and spleen, and between the intestinal convolutions. In the two cases of general peritonitis there was phlebitis of the umbilical vein. The lumen of this vessel between the umbilicus and its termination was filled with thick, whitish pus; the inner surface of the vein was bright red, and did not present any ulceration. The inflammation terminated abruptly at the ridge at the portal vein.

In 10 cases there was a partial peritonitis, limited to the umbilical region. In three instances Meynet found inflammation of the umbilical arteries, with purulent material in their lumina. These arteries, which were formerly permeable from the umbilicus to the bladder, contained pus for a distance of from 1 to 2 cm.; in the remaining portion of their course they had been obliterated by fibrinous clots. In 6 cases he found only serous infiltration and seropurulent infiltration in the cellular tissue beneath the umbilicus.

In a résumé (p. 24) he again says there were two distinct forms of the disease noted in these epidemics, the one corresponding to erysipelas of the new-born, and characterized by its tendency to invade large surfaces; the other by malignant ulceration with a tendency toward putrefaction and gangrene.

It may be of interest to refer to the notes on the individual cases in these two epidemics.

The observations are divided into two groups—those with erysipelalous inflammation and those showing a marked tendency to ulceration.

#### GROUP 1.

C a s e 1. — The onset was marked on the third day after birth by an erysipelalous inflammation, followed by ulceration. Death occurred three days later. At autopsy there was a moderate degree of peritonitis; nothing in the umbilical vessels.

C a s e 2. — The child was stricken on the seventh day after birth. At the beginning ulceration was noted. The disease lasted three days and was fatal. There was general peritonitis and phlebitis of the umbilical vein.

C a s e 3. — The onset was noted six days after birth. There was an erysipelalous inflammation followed by ulceration. The actual cautery was used. The child died on the eighth day.

C a s e 4. — Invasion on the fourth day; erysipelalous inflammation followed by ulceration. The actual cautery was employed. Death on the seventh day.

C a s e 5. — The umbilicus was invaded on the third day. Ulceration took place. The actual cautery was used, but the child died three days after the beginning of the inflammation.

C a s e 6. — Invasion on the second day. The erysipelalous form was noted at the beginning, and later ulceration. The actual cautery was used. Death took place on the third day of the disease. At autopsy a general peritonitis and inflammation of the umbilical vein were noted.

C a s e 7. — Invasion on the fourth day. Erysipelas of the umbilicus followed by ulceration. The actual cautery was ineffectual. Later zinc chlorid paste was used. Convalescence by the fifteenth day.

C a s e 8. — Invasion on the third day. Ulceration took place. Cauterization with zinc chlorid paste; the child was convalescent in seven days.

C a s e 9. — Invasion on the fifth day, with ulcer formation. Zinc chlorid was employed; convalescence by the tenth day.

C a s e 10. — Invasion on the second day. Erysipelalous form. The wound was cauterized with zinc paste and the child was convalescent by the ninth day of the disease.

## GROUP 2.—IN WHICH ULCERATION WAS THE PROMINENT FEATURE.

Case 1.—Invasion on the third day. Erysipelas followed by ulceration. The wound was cauterized with zinc paste. The child was convalescent by the eighth day of the disease.

Case 2.—Invasion twelve hours after birth. Erysipelatous form. Wound cauterized with zinc paste. Healing by the ninth day of the disease.

Case 3.—Invasion on the fourth day and an ulcer formed. The wound was cauterized with zinc paste, and by the ninth day the child was convalescent.

Case 4.—Invasion on the third day. Erysipelas followed by ulceration. Cauterization with zinc paste; the child was convalescent by the eighth day. The mother of this child had puerperal fever.

Case 5.—Invasion on the fourth day. Erysipelas with coexisting ulceration. Cauterization with zinc paste; by the seventh day the child was convalescent. The mother had a severe, almost fatal, attack of puerperal sepsis.

Case 6.—Invasion on the second day. Erysipelas was first noted. Convalescence had ensued by the seventh day after the use of zinc paste.

Case 7.—Invasion on the seventh day. There was erysipelas in the beginning, and the cord was still adherent. There was ulceration of the outer part of the wound, and in this case the child had thrush. Zinc chlorid paste was employed, and healing had taken place by the tenth day after the commencement of the inflammation. The mother was suffering from a severe puerperal infection.

Case 8.—Invasion on the second day. Erysipelas of the umbilicus was soon followed by ulceration. The wound was cauterized with zinc paste, but death occurred on the sixth day of the disease. The mother had a moderately severe attack of puerperal infection.

Case 9.—Invasion on the third day. There was ulceration without apparent gravity at the beginning; the wound was cauterized with zinc paste on the third day, but death took place that evening.

Case 10.—On the third day there was ulceration of a grave character; at the base of the cord tumefaction and redness. The actual cautery was used, and four days later zinc paste was applied. Convalescence ensued on the seventh day.

Case 11.—L., born January 10th. The mother left the hospital in good condition on the eighth day, but the child on the third day after birth showed a reddish, erysipelatous tumefaction at the umbilicus. There was a pustular erysipelas, with ulceration at the base of the cord, but no general symptoms. The wound was cauterized with zinc paste. The child recovered and was sent to the country on the eighth day.

Case 12.—J. M., born January 12th. The mother had mastitis. The child was attacked on the third day with erysipelas and swelling at the umbilicus. The cord had ulcerated to some extent at its base. It was dry and adherent. The cord was cut, and the cautery applied to the surfaces. The child was well on the twenty-second of January.

Case 13.—A. P., born January 6th. The mother left the hospital on the eighth day in good condition. The child was attacked on the fourth day with an erysipelatous condition at the umbilicus, with ulceration of a serious aspect. Immediate cauterization with zinc paste; recovery by the ninth day.

Case 14.—Charles V., born January 8th. Mother in good condition.

The child was attacked on the second day after birth. There was erysipelas, with tumefaction in the umbilical region. On the third day ulceration of a severe nature was noticed in the base of the cord. The wound was cauterized with zinc paste. Convalescence ensued on the seventh day after the beginning of the disease.

C a s e 1 5 . — M. S., born January 15th, was attacked on the fourth day with marked ulceration of a severe character. There was a pseudomembrane with elevated margins, and the wound showed an erysipelatous character. It was cauterized on January 20th, and zinc paste applied. The child recovered and was taken to the country on January 27th.

C a s e 1 6 . — D., born January 21st. He was a fine, healthy child, but on the second day after birth developed an erysipelatous inflammation of the umbilicus. The cord was soft. On January 24th the ulceration involved the skin margins in the umbilical region. The wound was cauterized with zinc paste, and he was convalescent by January 28th.

Meynet said that he could multiply these examples, but that those given were sufficient to show the gravity of the disease. He dwelt upon the efficacy of cauterization with the chlorid of zinc paste.

#### AN EPIDEMIC OF GANGRENE OF THE UMBILICUS.

Bergeron discusses an epidemic which occurred in the Hospital Necker in 1865. Before taking up the description of his cases he discusses the writings of Hippocrates, Ambroise Paré, Mauriceau, Hamilton, Underwood, Billard, Trousseau, and Meynet. In speaking of his own cases Bergeron regrets the incompleteness of the pathology. In 11 cases he had 9 autopsies which yielded the following results. The portion of the gangrenous skin was black, moist, and situated at a lower level than that of the surrounding normal skin. It was separated from the normal skin by an irregular, slightly reddish zone. Sections through the affected part showed in the center a dry layer, which was easily detachable from the underlying tissue and was held in place by several filaments at its periphery. It was 2 mm. in thickness, and its margins seemed to conceal an underlying part of normal skin. The gangrene was always superficial, and penetrated only through the skin. The vessels surrounding the slough were obliterated, but in no case was phlebitis found in the umbilical veins or inflammation of the umbilical arteries. One important point was that the peritoneum was always healthy except in one case (Case 3), in which it was injected. These observations differ from those reported by Lorain. In the epidemic in 1865 Bergeron did not observe the second form of the disease noted in the one reported by Meynet.

**Symptoms.**—Gangrene of the umbilicus in the beginning usually presents a benign aspect, the only sign being a little redness at the umbilicus and at the inguinal folds. Sometimes there are fretfulness, a mild diarrhea, and a slight cough. The infant refuses the breast, and death soon follows, as a rule peacefully, without convulsions, but with marked pallor of the skin everywhere.

The local manifestations present certain special points of interest. The lesion usually appears at the umbilicus before the separation of the cord. There is moderate redness, or more frequently an erysipelatous erythema, which invades usually at the onset the region which is later occupied by the gangrene. By the following day the cellular tissue has become indurated. Later, as a consequence of the mor-

tification of the skin, there appears in the inguinal fold or in a fold of the skin surrounding the cord a yellowish plaque which has a tendency to extend. It is more or less bright in the center, and moist at the margins. The yellowish color sometimes changes to black in the center, and the black usually extends to the margin of the lesion in the last minutes of life. The skin surrounding this part is of a light violet color for a distance of 1 mm. The violet border follows all the contours of the slough, which is more or less irregular.

In the more favorable cases this violet strip disintegrates. The slough softens, separates at the margins, and comes away in small pieces, but is never detached in a single piece. It leaves behind it a more or less deep ulceration, covered over with granulation tissue, which is sometimes very pale. The depth of the ulcer varies. In certain cases it extends through the entire thickness of the abdominal wall, so that it would appear that the intestine must come out. This, however, does not occur. As a matter of fact, the necrosis is only skin deep. In more severe cases, which are very rapidly fatal, sloughing takes place not only at the umbilicus but also in the inguinal fold. Finally, occasionally sloughs occur over the malleoli, the scapulæ, from the ears or from any region where the skin is exposed to continued rubbing or to humidity.

In one of Bergeron's cases there was gangrene of the eyelids which occurred very early. He says that the abdomen was never distended, and, if there was swelling, its point of departure was chiefly in the abdominal wall, not in the cavity of the abdomen itself. The final symptoms were always those of profound weakness. Seeing the children in the last day of the disease, one would have been led to think that they had been ill for a long time.

**Diagnosis.**—It is hardly possible to confound gangrene of the umbilicus with any other affection. The prognosis is always very grave.

**Etiology.**—Bergeron says that gangrene of the umbilicus was epidemic, and he thinks it possible that the virus of gangrene belongs to the same family as that producing erysipelas, puerperal fever, and analogous conditions. In the beginning of the year 1865 there were in the Hospital Necker 8 cases of puerperal fever with 3 deaths. Several days after, 5 children showed multiple abscesses, and 3 deaths followed. Of the 5 infants, 4 had been with their mothers before the puerperal fever appeared. For the greater part of 1865 the sanitary state of the lying-in ward was excellent; only 4 children had erysipelas of the cord. In the later months of this year, however, 11 were attacked and only 2 recovered.

**Case 1.**—**Simple Erysipelas of the Umbilicus; Recovery.**—The girl was born May 26, 1865. On June 5th the mother noticed a small area of redness around the umbilicus, and the physician found a small round ulcer from which there was a slight suppuration. There was a reddish thickening which extended for several centimeters around the umbilicus. The umbilicus had cicatrized by about the fifteenth of July.

**Case 2.**—**Gangrenous Erysipelas of the Umbilicus.**—Gangrene of the skin at various points. Death after fifteen days' illness. The child was born October 23, 1865. The mother nursed the child, but did not have much milk. On November 3d a little redness was noted at the level of the umbilicus. The child was brought to the physician on November 5th. The cord had come away four days before, and at the point of detachment was seen an elevation and some swelling. In the umbilical depression was a sort of yellowish, adherent

membrane, which in reality was a slough of the superficial portions. The skin was loosened and rolled up at the margins. By the seventh the plaque at the umbilicus had increased in size, and the redness occupied a circle about 2 cm. in diameter. The slough was yellowish, 6 by 3 mm., and arranged transversely. The small patch in the left inguinal region had a yellowish point about the size of a pin-head. The right inguinal region commenced to show a slight erythema. On the ninth the umbilicus was in the same condition, but in the left inguinal region was a yellowish discoloration, about 4 mm. in diameter, and in the right inguinal region a small superficial ulcer without a slough. By the tenth the umbilical lesion had increased, and the epidermis was implicated over an area 3 cm. in diameter. The yellowish slough was 1 cm. in its transverse diameter and 0.5 cm. from above downward. The slough in the left inguinal region had increased, and the area of ulceration of the right inguinal region had a yellow discoloration. By the eleventh the gangrenous ulcer in the right inguinal region had increased in size, and at the lower angle of the scapula on the left side could be noted a redness, in the center of which was a small black point. There was likewise redness behind the right ear. The general condition of the child was not so good, although it continued to nurse. The umbilical slough had not increased, but in its center showed a little black point. By November 15 the child was much weaker. The area of induration at the umbilicus had increased. The slough in the inguinal region had become intensified in color, and the one at the scapula showed a similar change. The small plaques on the ears were brownish and had a gangrenous odor. The child died the same evening. The autopsy showed that the abdominal viscera were normal.

Case 3.—Spontaneous Multiple Gangrenous Erysipelas, Involving the Eyelids.—Female child, born on October 31. Two days later the lids of the left eye were seen to be inflamed and presented a marked yellowish color. On November 5 the conjunctival margins of the eyelids were covered with a false membrane, whitish gray in color. On the eighth, a gangrenous patch was noted at the umbilicus, and a livid redness at the level of the folds of the buttocks. The child died on November 10. At autopsy it was found that the sloughs were superficial. The one at the umbilicus was insignificant.

Case 4.—Gangrenous Erysipelas of the Umbilicus, Multiple Gangrene.—Female infant, born November 13, 1865. It must be mentioned that a child suffering from a similar affection had slept in the next bed in the same room and had died three days previously. On November 20 the mother brought the child to the physician. The cord had dropped off the day before. The surrounding skin was red. Palpation showed that there was induration, imperfectly outlined and occupying an area around the umbilicus. The epidermis had disappeared from over an area 1 cm. in diameter, and presented whitish or grayish patches, evidently sloughs. The right inguinal region presented a similar aspect. By November 22 the gangrenous plaques had become brownish and commenced to give off an odor of gangrene. The child died on November 22. At autopsy it was found that the slough hardly extended to the bottom of the skin. The umbilical veins were normal. The umbilical arteries had been transformed into hard cords and were surrounded by yellowish, plastic lymph. The peritoneum was not injected.

Case 5.—Male infant, born October 27, 1865. On the next day a moderate

degree of redness was noticed around the umbilicus. By the evening, the redness had increased and had a radius of 2.5 cm. By October 29 the redness had not increased, but the underlying cellular tissue was slightly indurated. In the umbilical fold was noted a yellowish plaque, 3 mm. broad and 5 mm. long. This was moist, and its margins were irregular. By October 30 the redness around the umbilicus had increased. In the inner fold in the groin a reddish plaque the size of a franc was noticed, in the center of which was a yellowish point about the size of a pin-head. The child improved, but was taken away by the mother before it was perfectly well.

Case 6.—Gangrene; Erysipelas of the Umbilicus and of the Inguinal Regions.—Male infant, born November 24, 1865. On November 30, the mother brought the child for examination. The cord was just about ready to drop off. On lifting it with the scissors the examiner found that the tissues were grayish and formed a small elevation where a slough with a gangrenous appearance had formed. There was a slight redness of the skin at the fold of the groin on the right side. The child was well nourished. The umbilicus presented a raised blackish point, and around it was an ulceration and a yellowish depression. At the internal malleolus on the left there was seen a plaque having a yellowish center and reddish margins. The nurse said that this had had the appearance of a boil, and that she had opened it with a needle. The child died on the fifteenth of December. The umbilical ulcer was black and the skin around it greenish.

Case 7.—Spontaneous Gangrene.—A male child, born November 27, 1865, at a time when cholera existed in the hospital. On December 2, the child was brought for examination. The cord had not come away completely, but around its base, and attached to the skin, was a blackish point and a noticeable elevation. The blackish area was surrounded by a yellowish circle; there was a diffuse redness, and the skin was indurated. There were no general symptoms, and the child was well nourished. By December 4, the tumor of the umbilicus appeared as a roundish nodule, the size of a franc piece. It had a reddish circumference and was yellowish in other portions. In its center was a small black slough, ready to separate. By December 11, the ulcer had practically healed. The child, however, died on December 12. At autopsy it was found that the ulcer at the umbilicus was insignificant, and that it had never extended beyond the skin. The peritoneum was intact, but adherent over a large area. There was no trace of peritonitis. The child had died of pneumonia.

Case 8.—Multiple Gangrene.—A female child, two months old, entered the hospital on November 27. About a month before, the mother had noticed a small reddish ulcer in the right inguinal fold. The umbilical cicatrix, which had never completely healed, was also the site of a small ulcer. Two or three days before her entrance the skin in the lower part of the abdomen had become reddened and there was some induration, as in erysipelas of the umbilicus of the new-born. On her admission, at the umbilicus was a deep fold. At the bottom it was grayish yellow. There was some slight discoloration at other points. The right inguinal fold presented a patch of the same color, about 1 cm. in diameter. The child died on December 1. The umbilical slough had reached a considerable depth. At the bottom, on a level with the umbilical vein, was a small mass of purulent material. The vein itself was perfectly healthy, free, without clots.

There was no trace of peritonitis. The iliac vein and arteries were free. The slough in the inguinal region was deeper than that of the umbilicus. The peritoneum was normal.

C a s e 9 . — Female child, born January 7, 1866. About the fifth day a slight redness was noted at the umbilicus, which extended for a distance of 2 cm. On admission to the hospital it was found that the left eye was the seat of a limpid secretion and contained several yellowish flocculi. The eyelids were a little swollen, but not red. At the umbilicus there was reddening and a little induration. The cord had probably come away only a few days before. At the site of the umbilical cicatrix, in a fold of the skin, was an ulcer, yellowish at the bottom, and about the size of a hemp-seed. In the left inguinal fold was an ulcer, 1 cm. in diameter, and yellowish at its bottom. On January 19 it was noted that the umbilical ulcer had increased, and pus was escaping from it. By January 28, the ulcer at the umbilicus had cicatrized, but the one in the inguinal region had made considerable progress. Its margins were marked by a fine black line, and the center was occupied by a dry yellowish plaque. This gangrenous ulcer was limited by the inguinal fold. The anterior surface of the left inguinal fold was red, indurated, and denuded of its epidermis for a distance of 2 cm. In the center was a yellowish crust. The child died on January 31. At autopsy it was found that the sloughs were superficial, and that they had implicated the skin only. The underlying cellular tissue was infiltrated. The peritoneum contained an abundance of fluid with a reddish tinge. There was no false membrane. The intestines were healthy.

C a s e 10 . — A female child, born January 19, 1866. On January 28 a redness was noted at the umbilicus. Poultices were applied, but by the next day the redness had increased. On January 30 an ulcer was noticed at the umbilicus. By February 4 the redness had diminished to the size of a five-franc piece. By the next day the crust had disappeared and there was an area of ulceration 0.5 cm. deep. The general condition was good. By March 1 the child was completely well.

#### NON-PUERPERAL ERYSIPELAS OF THE NEW-BORN INFANT.

Yot, in his thesis published in 1873, dealt with erysipelas of the new-born and described a number of cases. In a few instances the lesions started at the umbilicus.

C a s e 6 . — The child was brought into the hospital when it was nine days old with an erysipelas in the subumbilical region. The skin was of a reddish tint, and there was tumefaction of the parts. The inflammation extended to the symphysis and also to the inner parts of the thighs. On the right side it extended to the vertebral column, but on the left it had not gone beyond the fold of the inguinal region. The umbilical cicatrix presented at its center a small surface of ulceration which may have been the point of departure of the erysipelas. From the tenth to the seventeenth day the process ran the usual course. On the seventeenth day an abscess opened in the coccygeal region. By the twenty-eighth day the child was well.

C a s e 9 . — The child was brought into the hospital when it was five days old. An erysipelalous inflammation covered the entire umbilical region, the lower portion of the abdominal wall, the lumbar region, the scrotum, the penis, the right side of the thigh, and the right leg, except in front. The parts were livid, and the temperature was 38.8° C. The child died on the same day.



C a s e 11. — A female infant was brought to the hospital when it was twelve days old. The umbilical cicatrix was imperfect and showed a bloody discharge. There was an erysipelatous inflammation over the entire region below the umbilicus to the thighs and legs, and a large part of the anterior portion of the thorax anteriorly. The temperature was  $37.8^{\circ}\text{C}$ .; the pulse, 184. The child died the same evening. The umbilical vein was found to be normal. There was no trace of peritonitis. The thymus was enormous, and on incision there escaped a purulent liquid.

C a s e 13. — A boy, born December 6, 1867, entered the hospital on December 16, 1869, showing erysipelas around the umbilicus and in the suprapubic region. The scrotum, penis, and the inner portions of the thighs and legs were implicated and there was edema of the lower and lateral part of the abdomen. At the umbilicus was an area of sloughing, 20 cm. in diameter, which was blackish in color. Pulse, 144; temperature,  $36.6^{\circ}\text{C}$ . The child died on December 19. A general peritonitis was present. Under the gangrenous area the abdominal wall was adherent to the large intestine, which had likewise become gangrenous.

C a s e 14. — The infant was ten days old when it was brought to the hospital. She had thrush. There was an erythema and a purulent discharge from the umbilicus. The tissues around the umbilicus were covered with exfoliated epithelium. There were redness and tumefaction below the umbilicus, and to the right and on the anterior surface of the thigh on the right side. The labia majora were tumefied and reddish in color. The erysipelas had apparently started from the umbilicus. The child died on the next day, the temperature being  $30.5^{\circ}\text{C}$ . At autopsy small vegetations were found on the mitral valve. The umbilical vein and arteries were filled with pus, and there were signs of a general peritonitis. The kidneys contained coagulated blood-globules and pus. The calices contained a blackish material resembling coffee-grounds, and the papillæ were of a brownish color.

Yot then goes on to consider the nature of—(a) puerperal, (b) traumatic erysipelas. He discusses the symptoms and the complications. He concludes that there are two kinds of erysipelas in the new-born—one puerperal, epidemic, infectious, and fatal in its course, and terminating as puerperal infection in women who have recently been confined; the other he designates as an “inflammation.” He says the fatality in this group is nothing in comparison to that in puerperal erysipelas.

#### RUNGE ON WOUND INFECTIONS OF THE NEW-BORN.

Runge, in his “Wound Infections of the New-born” (1893), has given us the best monograph on the subject that we possess. On account of their importance I have given Runge’s findings and his interpretations somewhat fully, even at the risk of some repetition, as I am particularly anxious that the reader should be cognizant of his views, although these at times fail to coincide with those of others who have had much experience in the handling of these cases.

The umbilical wound is most frequently the point of entry of infective material. This was proved in 30 out of 36 autopsies. The pathologic lochia contain a pathogenic organism and can lead to very severe wound infection. The carrying of infective material to a wound in the new-born is almost entirely through contact, and infection through the air is, to say the least, doubtful. In the new-born the organisms most frequently found are streptococci and staphylococci (Runge, p. 58).

On page 65 he says that the portion of the cord remaining on the child beyond the point of ligature dies and becomes, as it were, a foreign body. A reactive inflammation occurs in the skin of the umbilicus. Death of the cord is usually by mummification; high temperature and dryness increase mummification. Moisture and exclusion of air hinder the extraction of the water and lead to a moist gangrene. Simultaneously with the mummification there begins an active inflammation at the umbilicus. A few hours after birth the capillary network is found markedly distended and filled. Then the redness spreads over the entire skin umbilicus. This swells, and the distal portion of the umbilical remains takes on a yellowish-white color. Microscopic examination shows emigrating white blood-corpuscles in abundant numbers. They soften the dead tissue, which is gradually loosened and falls off, leaving a granulating surface. The dropping off of the cord takes place, on an average, on the fifth day. In premature and in weak children it usually drops off later, because in such cases the energy of the inflammation is less marked. The amnion first loosens, then usually the arteries, and finally the vein. The granulation surface of the umbilical wound after the cord drops off is frequently at a deeper level than the abdominal wall, because the intra-peritoneal portion of the umbilical vessels has contracted. In those cases, however, in which the skin has been carried out for a long distance over the cord, the wound lies above the level of the abdomen and appears as a definite umbilical stump. By retraction of the umbilical vessels there is gradually formed an upper and a lower umbilical fold, *i. e.*, a duplication of the skin covers the deep-lying umbilical wound, and further retraction of the umbilical vessels goes on simultaneously. From the day that the cord drops off the redness and swelling begin to recede, and the healing process ends from the twelfth to the fifteenth day. The umbilical scar is usually covered over with folds of skin. As a result of adhesions of the endothelial surfaces the intra-abdominal portion of the umbilical vein closes and now forms the ligamentum teres. The degree of obliteration of the vein varies greatly. Baumgarten (quoted by Runge) says that the closure is never complete. A thrombosis of the vein is by most authors considered as pathologic.

Runge says that in the arteries the closure is due to the growing together of the arterial walls, especially of the intima. Small thrombotic plugs sometimes exist where the arteries bend in the bladder region.

Mild Disturbances in Healing of the Wound of the Umbilicus. — Runge says (p. 71) that the determination of the line between the healthy and diseased umbilical wound is difficult. The degree of reactive inflammation of the umbilicus depends on various conditions. With the dropping off of very succulent umbilical cords the reaction is more marked than in the case of those that are somewhat dry. In strong children the inflammatory reaction comes on earlier and is more intense; more cells are produced than in the weaker ones, and in the case of the latter the cord drops off later.

Runge quotes Widerhofer, who says that if the umbilical wound begins to be moist, it secretes "mucus" and pus. If the umbilicus takes on the character of a mucous membrane there is produced a condition termed by the authors "blennorrhœa of the umbilicus." In these conditions it becomes difficult to determine whether or not the wound is infected. When the umbilical wound increases in area and is covered with a whitish and necrotic layer, and when, in addition, it discharges an abundance of pus or purulent material, there can be no doubt that an

extensive local reaction exists and we have an "ulcer of the umbilicus." Ulcer of the umbilicus hardly ever exists if the process remains localized.

In all his autopsies on infants who had umbilical ulcer, Runge found either disease of the vessels of the umbilicus or a peritonitis to account for the death. If neither of these was present, he was able to find some other cause of death independent of the ulcer.

On page 81 he takes up the subject of **omphalitis** and says that it is characterized not so much by marked inflammation of the umbilicus as by an infiltration of the abdominal wall around it.

**Symptoms.**—In cases of well-marked omphalitis the umbilical region is markedly reddened and the umbilicus projects conically outward. The area is rarely cicatrized, but usually appears as a wound or a discolored ulcer. The redness and the inflammation extend beyond the raised portion and form a circle around it. The skin is tense and glistening; the folds have disappeared. On palpation a hard infiltration of the abdominal wall can be felt, and examination gives rise to a great deal of pain. The extent of the infiltration varies. It may be limited to the immediate vicinity of the umbilicus, or the greater portion of the abdominal wall may be implicated. It may extend deep down and take in the entire thickness of the abdominal wall as far as the peritoneum.

In every case of marked omphalitis the general condition of the child is affected. It is restless, does not take its nourishment, and has fever. There is pain with every movement of the body. The legs are stiff and drawn up on the lower abdomen. The breathing is costal in type. The markedly engorged and dilated veins of the stomach region sometimes appear as thick, bluish strings seen through the skin. The duration of the disease depends on its intensity. It may last several days or many weeks.

Healing is the rule where the phlegmon is small. The exudate is absorbed, the umbilical wound cicatrizes, or there may be several small abscesses which break outward and discharge a few drops of pus. Healing then takes place in a few days. If inflammation is associated with the phlegmon, it extends far out in the abdominal wall and healing is much less likely to occur. The most favorable outcome is obtained when there is rapid abscess formation before the infant has been prostrated by the fever. If the inflammation extends markedly inward, death from peritonitis is likely to follow. If an involvement of the umbilical vessels is found at autopsy, a general sepsis has existed. Another unfavorable termination is in gangrene. This is more apt to occur in weak children.

From the foregoing it is seen that all cases of wide-spread omphalitis are to be considered as dangerous to life. The younger the child, the more unfavorable the prognosis. Breast-fed children have a better chance than bottle children. Children suffering from some congenital cachexia—syphilis, scrofula—and children of tuberculous parents are predisposed to this disease.

**Gangrene of the Umbilicus.**—Runge, on page 84, says that gangrene may be the consequence of a pathologic umbilical wound, an ulcer, or of an omphalitis; or it may develop in cases of severe general infection. Gangrene as a localized infection of the umbilicus does not appear to be very frequent. Many authors, particularly Widerhofer, say that it develops from a severe omphalitis. Ill-nourished children and those born prematurely show a tendency toward the development of local gangrene. Severe diseases of the umbilicus, such as gangrene, which were of frequent

occurrence formerly, especially in foundling hospitals, have recently diminished greatly. Fürth, in the Vienna Foundling Hospital, before antiseptic days saw 191 infants suffering from gangrene of the umbilicus, and 169 of this number died.

*Symptoms.* — The wall of an inflammatory umbilical wound becomes discolored, breaks down, and shows more or less loss of substance; or there develops, especially as a result of an omphalitis, a blister with cloudy contents. This ruptures and a defect is produced. An area of moist gangrene then appears and extends rapidly, sometimes superficially, sometimes penetrating deeply. The cases in which the process goes inward are much more dangerous. The gangrenous area is surrounded by bright reddening of the skin and reactive inflammation. Gradually the gangrenous portion becomes loosened. It emits a fetid odor. Usually the fever is not high, but rapid collapse is unfortunately the rule. Where the child's constitution is good and the morbid process is not wide-spread, healing takes place at this stage, the reactive inflammation producing pus, which throws off the dead portion, a defect of greater or lesser extent being left, which heals by granulation. If the child's strength has been overtaxed, it dies before the loosening of the gangrenous area can occur. The average duration of the disease in fatal cases, according to Fürth, was 5.64 days. In several cases death took place on the second day. When the child recovered, the duration of the disease at the minimum was twelve, at the maximum thirty-seven days. Again, the gangrenous process may spread, and in certain cases reported two-thirds of the abdominal wall was implicated. Where the gangrene involves the whole thickness of the abdominal wall, intestinal loops may become adherent and perforate, with a resulting peritonitis or a fecal fistula. Gangrene may lead to general sepsis, in which either the peritoneum is directly involved or the septic material gains entrance through the umbilical vessels to the general system.

Much more frequently there is a second kind of gangrene affecting the umbilicus, which appears to be the result of general sepsis. According to Widerhofer, there is a gangrene which follows cholera infantum. In these cases a localized necrosis occurs, and gangrene is also found in other portions of the body, this condition being produced by emboli. This gangrene is characterized by its rapid development and the complete absence of reactive inflammation.

Often in the course of a few hours the gangrenous area reaches the size of a dollar. It is remarkable that this gangrene occurs not only in the first days of life, but also in well-nourished children several months old. Widerhofer observed secondary gangrene of the umbilicus in children suffering from cholera, in the foundling hospital in Vienna, 63 times within four years. In each case death occurred very quickly. The *prognosis* in cases of gangrene of the umbilicus, accompanied by cholera and sepsis, is absolutely fatal. Even in those of localized gangrene the outcome is doubtful and depends upon the resistance of the child. The absence of inflammatory reddening is proof positive of a fatal outcome.

#### DISEASES OF THE UMBILICAL VESSELS.

Runge says (p. 88) that where infection of the umbilical vessels exists, the disease first starts in the perivascular connective tissue, which becomes infiltrated with a serous fluid and shows evidences of edema. Often the process extends to the adventitia, and the vessel itself is involved. The inflammatory infiltration of the

vessel-wall causes a paresis of the muscularis and a dilatation of the vessels, or gives rise to a thrombus which soon breaks down. Runge regards the thrombus and its disintegration as a secondary manifestation. He draws special attention to the fact that the arteritis and phlebitis invariably start with an inflammation in the outer coats of the vessels.

He then quotes various authors who had made experiments, with results agreeing with those obtained from his own autopsies. In 55 cases from the obstetric clinic of the Charité Hospital in Berlin, in which autopsies were made on children dying of diseases of the umbilicus, Runge found arteritis in 54 cases—22 times in combination with pneumonia, 16 times with other evident septic complications. Only once could he determine a phlebitis, and in this instance it was associated with a very intense arteritis. As a result of these observations Runge concludes that of all the fatal diseases of the umbilicus, arteritis is the most frequent and most important. He says that this view as to the great fatality in infants from arteritis as compared with phlebitis has been corroborated by the more recent observations of Epstein, Monti, Birch-Hirschfeld, and of Lomer.

[Careful study of the various epidemics leads one to conclude that in some epidemics the arteries are more frequently involved, in others, the veins.—T. S. C.]

On opening the abdomen and throwing outward the right abdominal wall Runge found that the diseased arteries were to be seen as thick, tense, usually slightly brownish-tinged cords, with marked thickening and development of the vessels of the adventitia, and that there were also an edema and infiltration of the surrounding connective tissue. In several cases the arteries were implicated for their entire length from the umbilicus to the bladder.

Runge says that frequently remnants of the umbilical cord, after dropping off, leave the umbilical wound covered with crusts and changed into an irregular ulcer with bays running off from it. In other cases, on the contrary, the wound shows a perfectly normal appearance; in fact, it may have completely healed and yet an intense arteritis may still exist. If the remnant of the umbilical cord is still intact, it is usually completely mummified. In other cases the cord gives out a very foul odor. After the softening of the crust from the wound, one occasionally can see the gaping umbilical arteries and note that they are filled with pus or friable material. If an incision is made through the umbilical wound, it is sometimes possible to see with the naked eye that the infiltration at its base extends directly into the diseased perivascular connective tissue; and when the vessels are incised transversely, there is an escape of yellowish-green pus from them, or they contain a friable, cheesy material mixed with blood. The surrounding connective tissue often presents a glistening appearance.

An incision in the long axis of the arteries, that is, from the umbilicus toward the bladder, indicates the degree of extension of the pus, which usually is associated with an infiltration of the surrounding connective tissue. Occasionally, at the far end of the accumulation of pus in one of the arteries, a reddish-colored thrombus is found attached to the vessel-wall. The intima of the artery is cloudy; it has lost its brilliancy, and there may be numerous unevennesses, due to loss of substance in the vessel-wall. The dilatation of the arteries bears no relation to the intensity of the inflammation in the perivascular tissue. On the contrary, the inflammation

of the connective tissue may be enormous, and yet the lumen of the vessel may be hardly large enough to admit the passage of a probe.

Sometimes the dilatation of the vessels is marked throughout their entire course; or again, at certain points, sac-like dilatations occur in which an abundance of pus and caseous masses are found. In no case of phlegmonous infiltration, however, was he able to follow the vessel as far as the bladder. The extraperitoneal connective tissue and iliac arteries were always free.

*Pneumonia* is the most frequent complication. Runge says that in 55 cases of arteritis it was present 22 times. This occurred in two forms, either as a lobar pneumonia, often complicated with a fibrinous, serofibrinous, or purulent pleurisy; or there were numerous pea-sized and bean-sized foci scattered throughout the lung. Where these reached the surface, there was an accompanying circumscribed pleurisy.

Runge found hyperplasia of the spleen with marked softening of the tissue, cloudy swelling of the liver, parenchymatous nephritis, serofibrinous or seropurulent peritonitis, joint affections, periostitis, and finally phlegmonous inflammation of the subcutaneous connective tissue, with or without pus formation.

Erysipelas, when observed as a complication, usually extends from the umbilical wound outward; nevertheless, Runge says, it may be primary in the face or in other portions of the body.

Very frequently the bodies show a slight degree of jaundice, especially when the death occurs between the fourth and sixth days, although no direct connection between the arteritis and the jaundice can be traced. In such a case one is dealing with the so-called physiologic icterus of the new-born. When, as happens more rarely, there is an intense icterus, the complication is to be attributed to a parenchymatous hepatitis. Runge says that very frequently the lungs show partial atelectasis.

Bacteriologic investigations in cases of umbilical arteritis have been rare. Runge drew attention to those of Baginsky, Meyer, and Babes. The most frequent cause of the infection was found to be a streptococcus. In a case described by Baginsky *Streptococcus pyogenes* was found in the internal organs and there was a pyemia as a result of inflammation of the umbilical arteries.

Runge gives a table of 55 cases in which an autopsy was performed and an anatomic diagnosis of umbilical arteritis was made (p. 95). These 55 cases of umbilical arteritis were taken from a group of 340 autopsies. This means that 16.1 per cent. of the children who came to autopsy in the gynecologic clinic of the Charité Hospital in Berlin, from 1879 to 1882, showed inflammation of the umbilical arteries. From his table it is seen that in 9 cases arteritis only was found. This was undoubtedly the cause of the death. In 16 cases there were complications (syphilis, etc.) which apparently bore no relation to the arteritis.

In this group were 8 cases in which the complication, for example, hemorrhage of the brain, had been definitely the cause of death, and the arteritis in 5 cases was not marked. In 30 cases, however, there were complications which undoubtedly were dependent upon the arteritis. In 16 cases these were of a septic nature. In one case, in addition to the arteritis, there was an abscess of the vein in its lower portion.

These anatomic results are in opposition to the findings of Buhl, according to whom, in cases of arteritis, the secondary changes were found in the abdominal

cavity. Widerhofer and P. Müller emphasize the frequency of peritonitis. This complication Runge found only 5 times—in 9 per cent. of the cases. He never found a perforation into the abdominal cavity from the diseased vessels, as described by Bednar.

The pathogenesis is taken up on page 101. From the pathologic findings there can be no doubt that umbilical arteritis is a wound infection which has its point of origin in the umbilical wound and which gives rise to a general sepsis. Buhl explains the unfavorable effect produced by puerperal infection upon the umbilicus and upon the changes in the vessel-walls which had already existed in the intra-uterine life. Runge, in discussing the possibility of the transference of septic material through the placenta, draws attention to the fact that in the cases of 24 patients there was not a mother who during pregnancy or during or after labor had had any septic phenomena, and in the remaining cases only now and then had such symptoms been noted.

Symptoms. — A characteristic symptomatology is wanting (Runge). We have no clinical picture from which we can make the diagnosis in the living child. Usually the death is unexpected. The child appears perfectly normal. Suddenly it becomes restless, refuses nourishment, collapses, and dies. An accident may be thought of. The autopsy shows arteritis. In every case, however, the umbilical wound showed some inflammation; usually it was covered with pus, although the general condition of the child was not changed. Then there were sudden restlessness, crying, collapse, and death. Since most of these cases occur in groups, the diagnosis was finally reached without any special difficulty.

More rarely the course of the disease is prolonged. In these cases the indications of a severe general infection nearly always become evident. The children have fever, loss of weight, increasing weakness, and symptoms of collapse. That the severe symptoms are due to disease of the umbilical vessels there is at times no evidence, especially if, as is frequently the case, the umbilical wound shows little or no inflammation or has healed completely. If, on the other hand, an ulcer of the umbilicus is present, a diagnosis of a general infection due to an extension of the umbilical disease is readily made. In all cases, nevertheless, where there is disease of the umbilicus, the danger of inflammation of the arteries exists. The diseased organs do not always present the characteristic picture. A lobar pneumonia is easily recognized by percussion and auscultation. Small disseminated foci, however, Runge was never able to diagnose. Where marked distention and pain of the abdomen are noted, peritonitis is probable, but, according to Runge's experience, in the first days of life this is not easy to diagnose. Marked icterus indicates hepatitis, which may, however, prove to be not serious. From Runge's table it is seen that the eldest child dying of arteritis was eighteen days old, the youngest, four days. The largest number of deaths occurred on the eighth day.

Prognosis. — No positive data can be given. In the case of premature children, the outlook is very grave. Of the 55 children autopsied, 21 had been born prematurely. In 50 cases in which inflammation of the umbilical arteries was found, 21 (42 per cent) of the infants were premature. Runge says that premature children who develop arteritis nearly always die; in the case of a child born at term, the possibility of recovery exists.

Etiology. — Runge says that contact of the umbilical wound with septic material, but not necessarily only after the cord has come away, may be the cause

of the disease. The most virulent infection seen by Runge was in a case in which the cord had not yet been completely loosened. The infection has always been most prevalent in lying-in hospitals and foundling institutions, and has occurred in groups, whereas in private practice it is rare. Runge also draws attention to the fact that it was often associated with an epidemic of puerperal fever, but maintains that there may be an epidemic of inflammation of the umbilical vessels entirely independent of any puerperal infection. He had observed such an epidemic in the obstetric department of the Strassburg Hospital, in 1876, and in the obstetrical department of the Charité Hospital in 1880. In both instances the health of the mothers was splendid.

**Prophylaxis.**—Absolute cleanliness is essential. If arteritis is once established, little or nothing can be done.

In discussing inflammation of the umbilical vein Runge says that Bednar and Widerhofer consider phlebitis the more important and more frequent disease, whereas recent authors, such as Epstein, Birch-Hirschfeld, and others, dwell upon the preponderance of arterial infection. Birch-Hirschfeld, in 60 autopsies of septic infection which had extended from the umbilicus, found phlebitis 11 times, in 4 instances a simple thrombus of the vein; whereas in 32 cases the arteries alone, and in 3 cases both arteries and vein, were simultaneously affected. In all his autopsies Runge met with phlebitis only twice without arteritis; he regards phlebitis of the umbilical vessels as a much rarer affection.

**Autopsies in which inflammation of the veins was found.**—Runge says that the condition is usually similar to that found where arteritis exists. The perivascular connective tissue is edematous, the adventitia thickened, and the vessel tortuous; there are punctiform hemorrhages. On transverse section of the vessel, pus, bloody pus, or pus-like masses escape from the lumen. The longitudinal section of the vessel shows an extension of the disease into the inner surface. The intima is cloudy; in places it has been destroyed, and there are deep ulcers which have eaten out large areas of the vessel-wall. The disease extends usually along the entire length of the vein from the umbilicus to the liver, which may itself be implicated. According to Widerhofer, Glisson's capsule alone may be implicated; or the portal vein and its branches may show changes similar to those noted in the umbilical vein. Most writers on phlebitis draw attention to the fact that the perivascular tissue is first involved, and that the vessels are invaded secondarily. A general septic condition is the rule, and peritonitis and parenchymatous hepatitis are very frequent.

**Symptoms.**—Runge mentions fever and icterus, and agrees with Widerhofer that inspiration is short, expiration is prolonged, and the breathing more rapid than normal. The movements of the thorax are scarcely detectable. The abdominal musculature is nearly always contracted. The abdomen, particularly in the upper portion, is distended. Pressure in the region of the umbilical vein causes pain, which accounts for the drawing up of the legs. The child is restless, but more or less toxic.

In conclusion (p. 116), Runge gives a full bibliography on diseases of the umbilical vessels.

**Erysipelas in the first days of life.**—Runge (p. 158) says that in the earlier days erysipelas of the new-born was wrongly included with puerperal



infection of the new-born, and that some of the cases of septic erythema were classed as instances of erysipelas. Clinically, there are two forms of erysipelas in the new-born. One of them is a true erysipelas. In the table of children dying from umbilical arteritis, erysipelas was noted twice—once on the abdomen and once on the face. According to Gusserow, the course of such a double infection—erysipelas associated with septic inflammation—is always fatal. The second form of erysipelas attacks children that have heretofore been healthy. The infection spreads partly from the umbilical wound and partly from some slight injury of the genitals. Erysipelas in the new-born almost always causes death.

#### SEPTIC PYEMIA AND INFECTION OF THE UMBILICUS OF THE NEW-BORN.

Cohn, writing in 1896, says that although these diseases are not so common as formerly, they are not rare. He then goes on to report two interesting cases:

Case 1.—*Umbilical Phlebitis; Phlegmon of the Forearm; Spontaneous Rupture of the Purulent Phlegmon Through the Umbilicus; Recovery.*—A. S. was brought to the clinic when fourteen days old. On the second day the umbilical cord had been tied for a second time by the midwife because it was thought to be too large. On the fourth day it came away during the bath. About the thirteenth day the mother noticed that the left hand of the child was red and swollen. Local applications were made, but the swelling did not diminish. By the afternoon it had reached to the forearm, and by evening to the elbow, and early the next day up the arm. The child had fever, was very restless, and cried a great deal, especially on being disturbed. On admission it was found that the umbilicus was drawn in and in the depression was some slight secretion. The forearm was markedly reddened and swollen, and any movement caused great pain. Swelling and fluctuation were noticeable in the neighborhood of the wrist-joint. The back of the hand was edematous and swollen. At operation not much pus was evacuated, but the tissue of the forearm showed infiltration, which reached to the hand, so that it was necessary to lay open the musculature of the thumb and of the ball of the little finger. Further operations were subsequently necessary. Later on the mother noticed to her surprise that the umbilicus was fully a "segment of a finger" high, and that it was bluish red; that there was swelling for at least 5 cm. in the neighborhood of the umbilicus, and that it was edematous and painful. Pressure caused a discharge from the umbilicus of a thin, fluid pus. Following the introduction of a probe the escape of pus was much more free. The probe could be carried upward 4 cm. and beneath the abdominal muscles. From the mother it was now learned that the umbilicus had up to this time always shown a little purulent discharge. At the end of a year the child was well and the umbilicus was well drawn in.

Case 2.—*Umbilical Phlebitis; Phlegmonous Erysipelas; Suppurative Peritonitis; Death.*—Paul B. The cord came away on the fifth day, but as a piece, 2 cm. long, remained attached to the abdomen, it was tied off by the midwife with a white thread. After this the wound is said to have suppurated for about six days and then remained dry. Five days later, over the ankle-joint of the left leg definite swelling and redness were noted. Two days later redness was noted on the right leg; still two days later the scrotum and the surrounding parts were swollen, and it was with difficulty that the

child could urinate. On the following day it was found necessary to open the left ankle. The redness and swelling over the back and the extremities had extended. Four days later vomiting began. The abdomen was distended, being as hard as a board. The abdominal walls were glistening, and the veins were markedly distended. Any movement of the body occasioned pain. The umbilicus was closed, dry, and not prominent. The buttocks were covered with an erysipelatous inflammation, chiefly noticeable along its advancing margin. This extended to the nipple line and nearly to the scapula. Along the lower border of the scrotum was an ulceration the size of a five-pfennig piece, covered with yellow, smeary material. The child died.

At the autopsy, which was performed the same day, the umbilical wound was found healed. There was edema of the abdominal wall. The peritoneum was thickened and showed a purulent inflammation. When the abdominal cavity was opened, there escaped a yellowish, clear fluid, which contained white flocculi, seropurulent in character. From a quarter to half a liter of fluid lay between the distended intestinal loops. The umbilical vein was found markedly distended, especially in the neighborhood of the liver, where it was almost as thick as the little finger. It contained yellow pus. The purulent contents of the vein could be followed to the portal vein, and on section to the liver. Pus escaped from a large branch of the portal vein. The liver was enlarged and showed cloudiness. Cocci in chains were detected.

Cohn then refers to several other epidemics, and quotes Epstein, who wrote in 1888 from the Foundling Asylum in Prague. This author says that the mortality was 30 per cent in preantiseptic days, and that it had dropped to 5 per cent, but that, from January, 1887, to April 30, 1888, out of 116 children that had died from a total of 1816 that had been received, in not less than 36 (31 per cent) the histologic diagnoses showed that the sepsis had started as an inflammatory infection of the umbilicus and of the umbilical vessels. Miller, quoted also by Cohn, found that in the Moscow Foundling House from about 6 to 8 per cent of the children died of a purulent process, the great majority of these septic infections emanating from the umbilicus. From the Innsbruck Clinic, Ehrendorfer reported 1764 cases occurring from May 5, 1888, to the end of April, 1892. Of these infants, 95 died and 81 came to autopsy. Of this number, 16—about 20 per cent of the cases that came to autopsy—showed infection of the umbilical arteries or veins.

Eröss, also quoted by Cohn, found that, out of 1000 infants born in the Obstetric Clinic in Budapest, in over 320 (32 per cent) the mummification of the umbilicus took place normally. In 680 (68 per cent) there were not only deviations from the normal, but often marked pathologic changes at the umbilicus, such as inflammation and the formation of ulcers. Routine temperature observations further demonstrated that, of the 680 infants, 220 had a rise of temperature, and 5 of these died during their stay in the clinic.

Cohn speaks of the use of alum, of tannin, and of sugar, and comes to the conclusion, as a result of various investigations, that it is wiser to avoid bathing the child after the first day, until the cord has come away. He speaks of treating the cord by the dry method, not even allowing it to be exposed to the air.

UMBILICAL SEPSIS IN THE NEW-BORN OCCURRING AT THE NURSERY AND CHILD'S HOSPITAL, NEW YORK, DURING 1896.

S. W. Lambert, in his interesting description of an epidemic occurring in New York, says that the obstetric department of the Nursery and Child's Hospital lost five babies from umbilical sepsis during 1896. The epidemic occurred in July, August, and September. During the three months there were 40 children born, and of these, only 4 remained free from fever; the remainder developed a temperature of 100° F. or over. The real epidemic was characterized by a peculiar skin eruption and was coincident with the delivery in the ward of a woman who became very ill with a virulent sepsis from which she died. I shall briefly outline the fatal cases.

**C a s e 1 .** — The child lost weight from the date of birth to the fifth day and died on the twenty-second day. In this case the right foot became swollen and the heel and toes gangrenous. At autopsy the umbilicus appeared to be normal, but in the umbilical vein there was a fusiform clot, three inches in length, also small clots in the arteries, and beneath them small collections of pus in the tissues. Cultures from the pus in the tissues gave staphylococci.

**C a s e 2 .** — This child was born after a dry labor of fifty-eight hours, lost 17 ounces in three days, and died on the twentieth day. At autopsy, the umbilical vein appeared normal, but the right hypogastric artery was swollen and reddish for three-fourths of an inch from the umbilicus. On manipulation grayish-brown, grumous pus escaped from the umbilicus. A probe was readily introduced into the artery. The pus yielded pure cultures of *Staphylococcus aureus* and *albus*. The cord was still adherent.

**C a s e 3 .** — The infant had lost 14 ounces in weight by the fourth day, and was jaundiced during the first week. At autopsy there was noted a fusiform swelling of the right hypogastric artery just below the umbilicus. This contained bloody pus. The left artery and the umbilical vein were normal. The cord was attached to the umbilicus, and at its base was an excoriation extending an inch in each direction. No cultures were made.

**C a s e 4 .** — The labor was normal. The child had lost 12 ounces by the fourth day and died on the twelfth day. A pemphigoid eruption was noted on the neck on the fourth day, and spread rapidly over the shoulders. The cord came away on the sixth day. At autopsy the umbilicus, when opened, was found to contain a discolored, yellow, liquid mass, which seemed to extend through into the artery and vein.

**C a s e 5 .** — The cord came away on the tenth day. The umbilicus contained pus. There was no autopsy.

TETANUS IN THE NEW-BORN.

Prior to the aseptic treatment of the cord, children often developed tetanus through the umbilicus. The cases usually occurred singly, but now and then there was an epidemic with a high mortality. At the present time umbilical infection with this organism is rare, except in countries in which the natives have no medical attention and are accustomed to treat the cord in a very crude and primitive fashion.

Runge's description of the symptoms of tetanus in the new-born is so lucid that I will quote it in detail:

On page 145 he says: "In this vicinity it is not frequent, in fact in the obstetric

institutions, since the introduction of antiseptics, it has become very rare. On the other hand, in some places tetanus is endemic. The new-born in the tropics, and especially children of the colored races, are frequently attacked by it. The probability is that this infection is due to a lack of cleanliness." On page 148 he says that, within two years, according to Keber, in the practice of one midwife who cared for 308 infants, 99 died of tetanus. This was in the years 1863 to 1865.

**Symptoms.** — "The trouble manifests itself suddenly. The lower jaw remains stiff, and is kept only a short distance from the upper. The muscles are so strongly contracted that it is impossible to open the mouth. At the same time there is a change in the countenance. The forehead is markedly furrowed, the space between the lids smaller, the lips are pressed together and often drawn up in a snout-like fashion, showing radiating folds. There is marked drawing together of the musculature of the back, bringing the head backward and producing an opisthotonos. Owing to contraction of the abdominal muscles the abdomen becomes as hard as a board, and is usually deeply drawn in. The extremities are affected also by the contraction, but to a less extent. The arms are drawn up, the hands clenched to form fists. The legs are stretched, the toes abducted. In well-marked cases the body is as stiff as an iron plank (Soltmann). One can grasp the child and lift it up as one would lift a statue. The commencement of the tetanic convulsion, especially where the disease is advanced, may be brought about by any disturbance of the child, by an attempt at nursing, by a change in its position, or by a strong current of air. Later the intervals between attacks become shorter and shorter, and finally the contraction is continuous.

"The respiratory muscles are usually not markedly involved at first. As the disease progresses, however, dyspnea develops; the child becomes cyanotic, and, owing to contraction of the muscles of the throat, swallowing becomes impossible. The laryngeal muscles are often affected, so that the cries of the child are interrupted or it cannot give any vocal evidence of its great pain.

"The pulse-rate is usually increased, from 160 to 200; the temperature is elevated, and may reach 41° to 42° C. Defecation and urination are only rarely much disturbed. The course of the disease is usually unfavorable. The attacks increase in number, and finally the intermissions between them become very short. A severe grade of cyanosis supervenes, and as a result of the impossibility to take nourishment there is marked emaciation. Death may take place on the first or second day, but it usually occurs between the fifth and sixth days. Recovery is rare. In favorable cases the attacks gradually diminish in strength and in duration. Occasionally bones are broken, muscles are torn, and paralysis of individual muscles occurs."

#### REMARKS.

After reading the records of the appalling epidemics of fatal umbilical infections that occurred from the earliest days of medicine up to the era of asepsis, one instinctively turns back to those two modest scientific investigators, Louis Pasteur and Joseph Lister. More than any others, these two have been the direct means of saving the lives of thousands upon thousands of new-born babes, and have in a large measure removed the nightmare of childbed fever.

The above detailed report of the records of so many epidemics may seem somewhat superfluous, in view of the fact that in the future we shall, fortunately, have

little to fear from this quarter. Such reports, however, will serve to emphasize the powerlessness of the older physicians in the face of such emergencies. Moreover, it is clearly evident that even at the present time an insidious umbilical infection occasionally exists and that it may lead to the child's death, before the original focus of infection has ever been suspected. In every instance of illness in a new-born infant it should always be the rule to inspect and, if necessary, reinspect the navel.

#### TREATMENT OF THE UMBILICAL CORD.

This subject is dealt with so fully and satisfactorily in the text-books on obstetrics that it would be superfluous to discuss it in any detail. It will not be out of place, however, to consider a very interesting paper by R. L. Dickinson,\* entitled, "Is a Sloughing Process at the Child's Navel Consistent with Asepsis in Childbed?" Although the article was published in 1899, it has not received the attention it merits. "This paper is a plea for the application, in amputating the cord, of the surgical principles that govern other amputations. The following principles are directly opposed to the prevailing practice, but would seem to bear upon the matter:

"(1) Mass ligature should be avoided. Hemorrhage follows the present method occasionally, because shrinkage of the gelatin loosens the seizure. Ligatures belong on bared vessels.

"(2) A hernial opening should not be closed by a granulation scar. Primary union is readily substituted.

"(3) If the location of the future line of demarcation is known, removal should be practised at or beyond that point. In the case of the funis, one knows where the line of separation is to be.

"(4) That form of operation should be chosen which will do away with sloughing or pus production. Prevention of suppuration, of putrefaction in the stump, and of systemic infection has been attempted by means of numberless devices and dressings, spread through a voluminous literature of failure. Removal alone is prevention. The obstetric nurse will then no longer go from a pus dressing on the baby's abdomen to the fissured nipple, the perineal wound, the catheter, or, in small maternities, to the vulva of the woman in labor.

"And, conversely, septic maternal discharges will cease to endanger the child's open wound.

"To frankly sever the cord at the skin margin, with ligature of the vessels or suture, one or both, brings about safe, clean, prompt healing. Even the pressure of a pad and an adhesive strap may suffice. Thereby the navel of the second day looks like the navel of the tenth or fifteenth day under other methods. After succeeding with many cases of complete primary amputation, the writer found that Flagg had recently published the method in part."

Dickinson then gives a most painstaking and thorough review of the literature, draws attention to the large number of children that die of a sepsis starting from the umbilicus, when the family physician, even after the death of the child, is totally unaware that the infection commenced in the umbilicus or that the death was due to sepsis.

\* Dickinson, R. L.: Amer. Jour. Obstet., 1899, xl, 14.

He then describes his mode of amputating the cord: "Elaborate detail concerning the various methods classified above is hardly necessary. A typical example of each class may be given:

"Preliminaries to All Three Methods.—As the child's trunk makes its exit, a sterile or clean towel is so applied to the abdomen that the cord and the umbilical region make no contacts once outside the grasp of the vulvar ring. The trunk is wrapped in the towel as the baby is laid down or resuscitated. As soon as pulsation grows feeble, the cord is clamped beyond the towel between two Keith forceps and cut. Artery clamps have an insufficient bite for large cords. The child is laid aside until the placental stage is completed and the perineum has received attention.

"The material is prepared. The choice of method is made, and now the child is laid on a table. A towel is wound about its arms, and another about its legs, to keep it quiet and to insure a clean field. The towel is unwrapped from about the abdomen. The nurse draws the cord out by the forceps that has been placed six

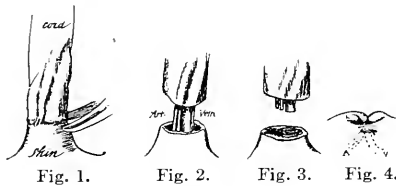


FIG. 62.—(After Dickinson.)

Fig. 1.—The scissors free the cord from the skin, and then push up the sheath and the jelly.

Fig. 2.—The trousers-leg slipped upward with the gelatin, exposing the vessels. The ligature is placed as low as possible.

Fig. 3.—After ligature and cutting away.

Fig. 4.—The stump rolls in at once.

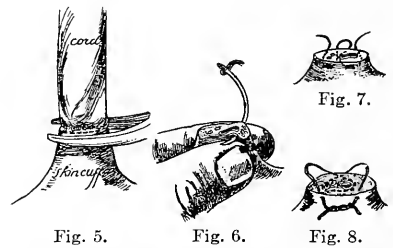


FIG. 63.—METHOD OF TREATING THE UMBILICAL STUMP AT BIRTH. (After Dickinson.)

Fig. 5.—Removal of cord at one snip of the scissors, the fingers holding the stump, as shown in the next cut.

Fig. 6.—The fingers still hold the stump while suturing.

Fig. 7.—One form of suture.

Fig. 8.—A suture ligature.

or eight inches away from the navel. Her hands need not be safe, but the operator's are prepared as for an operation.

"A. Simple Ligature.—With blunt-pointed scissors snip all around the skin margin, avoiding the place where the vein shows near the surface (Figs. 62 and 63). At this place it is not always easy to cut the sheath without opening the vein. The sheath and gelatin are stripped backward with as much jelly as possible. The vessels thus span the gap, standing alone. A fine silk or catgut ligature, around all three or about the vein alone, is placed. The ends of the vessels are cut short, and the cord is off. The stump tends to roll inward. No antiseptic solution should have been used unless one has ground for fearing gonococcus infection. No powder is to be used. A dry gauze pad under the binder suffices. Scissors, ligature material, and one or two forceps are needed, besides the gauze for sponge or dressing. Fine silk cuts itself out, the end of the tied vessel seeming to reorganize. This method is much more sure to control bleeding than mass ligature of a cord.

"B. Suture.—The cord is drawn upward by the nurse as before. The cuff of the skin is caught between the palmar surfaces of the left thumb and index-

finger, and one closure of the scissor-blades severs the cord through the capillary ring (Fig. 63). A reflux of blood comes from the cord. Without letting go with the left hand, an artery clamp pulls the vessels up; the needle is taken up in the right hand, and a simple continuous stitch is run across and its ends are tied together; or a subcuticular (Kendal-Frank) is put in place. If it is desired to ligate as well as to sew with the same silk, one loop of the stitch sweeps around the arteries and the other about the vein. Superficial bites may be taken in order that the little stitch of fine silk will cut itself out.

“Capillary oozing, or a few drops from the vein, are arrested by a little pressure from a plain sterile gauze dressing under a binder. Scissors, a sharp cutting needle to penetrate rather tough skin, fine black silk, gauze, and artery forceps are needed. The timid may place the stitch or stitches before cutting at all, as Dr. George R. Fowler suggested to the writer.

“**Objections to Complete Primary Amputation.**—(1) Increased danger of contact-infection, owing to operation on parts supplied with lymphatics, as compared with the ordinary ligation of vessels and jelly on parts having no nutrient capillaries or absorbents.

“(2) Lack of drainage in case of infection.

“(3) Danger of concealed secondary hemorrhage (hematoma) after the suturing method.

“(4) Inaccessibility of vessel-ends in case of bleeding, as compared with facile placing of second ligature where stump is long.

“(5) The risk of striking an umbilical hernia.

“(6) As this is surgery, it is not yet adapted to the general practitioner, and to the midwife only the pressure method can be trusted, if that method proves safe.

“To admit most of these objections is to confess that we, as instructors and surgeons, fail in our attempt to drill the student in hand cleaning and instrument boiling and avoidance of unclean contacts, and that, as to this generation of general practitioners, we give them up. Our method requires hands no cleaner than for a vaginal examination, and far less wound knowledge than for the repair of that perineal injury which zigzags through fascial and muscular planes, their anatomy disguised by stretching and edema.

“Even in the matter of secondary hemorrhage not controllable by pressure, any one can roll open a superficial wound, draw up its center with an artery forcep, and seize and ligate an oozing vessel end. A hernia at birth calls for closure of the canal by sutures in any case. Hernia is exceedingly rare at this time (Tarnier and Budin), though common enough a month or two later.

“**A f t e r - c a r e .**—A small square of plain gauze lies on the wound and may become adherent to it. Over this a larger dressing is placed, and a moderately snug binder is pinned or sewed on. As with any other clean wound, the dressing must not be changed except for cause. The baby is not tubbed for a week until union is secure.

“The first washing immediately after the operation has been just sufficient to get rid of any vernix caseosa that is present, and during the week no general washing is needed.

“Flagg speaks of his case healing under a scab. This is produced by the dermatol. It is better to permit drainage. Sanious oozing, as from any fresh wound, usually occurs. In some instances, on rolling the wound outward on the third or

fifth day, the inverted skin-cuff is found to be moist. It may be that there is a watery discharge from the gelatin within the ring of skin. Some of the inversion of the stump may be prevented, and a handsomer flush result secured by taking off part or all of the skin-cuff. Dry primary union is thus more certain. Most adult navels are dirt accumulators—accumulators not easy to clean. Deep inversion, with the line of union solidly fixed, 1 to 1.5 cm. below the level of the skin of the abdomen, may be found by the ninth day if the whole skin projection is used as flap.”

I wrote Dr. Dickinson asking what his experience had been in the ten years intervening since his paper, and received the following answer:

“Your query about my immediate amputation of the cord did me good. Nothing ever fell as flat and as hard as that proposition. The principles of surgery don’t apply to the only operation done on every living being, savage, civilized, or four-footed. I can be satisfied to wait, but the method will not be general till every practitioner can do a little clean work. Meanwhile I have gone straight on with the second procedure. The cord is lifted by nurse or assistant. A really sharp curved needle, armed with No. 0 or No. 1 catgut or fine silk or linen, is passed into the very tough skin, beginning below the navel, just where the skin-cuff rises from the belly-wall. It circles beneath the skin, and comes out above at the base of the skin-cuff. The needle reënters close to its first entrance and circles the remaining half, coming out near the original second entrance. It is an over and over stitch of a round space that sweeps about the circle as well, thus acting as suture and encircling ligature in two bites and one tie. The stitch is placed before the cord is cut.

“The cord is cut just at the skin margin, under a little traction, in order that most of the jelly may come away in the scissors. Then an anatomic forceps slips the loop of the middle part of the stitch over the center of the raw surface, and one ties. It falls out or is nipped out in two or three days.

“The only contraindications are unclean contacts between exit of child’s navel and operation, umbilical hernia, and a circulation badly started, so that there is back pressure in the vein.

“I have never seen oozing or temperature in my own cases. The only case I know of that did badly is a baby whose navel was sutured by an intern in a Brooklyn hospital, that died after some temperature, with a clean navel and no autopsy.”

Buckmaster, in 1906, suggested a treatment of the cord very similar to that carried out by Dickinson, although he was evidently unaware of the latter’s work.

Buckmaster in substance said that for several years he had been impressed with the idea that if the umbilical wound could be made to heal by first intention, it would be of great advantage. He made no claim to priority in suggesting a method by which this could be done, and said that he did not know who deserved credit for such a suggestion, since the more reasonable the plan, the more likely it is to occur to a number of men. He had tried the new plan in 8 cases: in 6 the results were all that could be wished for. In 2 cases of the 8 there was a slight trouble in the healing of the wound, but not enough to affect the general result. In all cases the wound was closed in ten days, and instead of a cicatrix, there was a slight linear scar. These children had been started in life without an umbilicus, and he has, therefore, used the term “anomphalosis” as the title of his article. His operation is as follows:

“With a sharp pair of scissors free the belly-wall, reflected on the cord like a cuff, and push it back. When this has been done, the cord may be divided. Sometimes



an artery may spurt a little, but torsion or a thin catgut ligature will quickly control the hemorrhage. It will be noticed that in cutting through the cord near the wall how much more fibrous tissue is found than one would expect.

"The condition now present is a circular pit surrounded by a ridge of skin, the top of which is raw. By drawing two points on opposite parts of the ridge from each other, the circle is changed to an ellipse. The sides of the ellipse are now drawn together by sutures, preferably silver wire, and in from six to ten days the wound is closed, practically by first intention.

"The condition is like an amputation of an arm: in both cases we have a flap which is made from the skin and which covers the stump. Since I first commenced to discuss this procedure among my friends who are interested in obstetrics I find that many have tried it. But while they have no good objection to the procedure, it did not seem to impress them favorably. I believe time will change all this. No anesthetic is necessary, because the child suffers next to nothing, but the operator should work quickly and not where the mother or non-professional spectators might, through their ignorance, fancy the child was maltreated."

**Simple Surgical Treatment of the Umbilical Stump.**—The method recommended by Nadory\* complies with the three requirements of Ahlfeld, *i. e.*, that there be positive prevention of an infection, protection against secondary hemorrhages, and no necessity for after-treatment. As soon as the pulsation of the umbilical cord ceases the cord is tied tightly with a heavy silk ligature at the line of demarcation between the skin and Wharton's jelly. The cord is then cut short. The stump and umbilical ring are painted with tincture of iodine. The child can be bathed daily if an application of the tincture of iodine is made after the bath. The umbilical stump will fall off on the second or third day. The umbilical funnel heals rapidly (J. Voigt).

#### CARE OF THE UMBILICAL STUMP—A BACTERIOLOGIC STUDY.

After briefly considering the clinical aspect of the infections and referring to the recent literature on the subject, Adair† gave the results of his bacteriologic examinations. "In order to prove the presence or absence of organisms on and around the umbilical cord immediately after birth, the following procedure was adopted:

"A platinum loop was used to scrape the cord and surrounding skin immediately after birth and before the cord was handled or manipulated in any way. Agar plate cultures were made from the material caught on the platinum loop. All these cultures were made under as nearly the same conditions as possible in the Elliot Memorial Hospital at the University of Minnesota. No attempt was made to isolate the anaërobic organisms.

"There were 65 cases examined in all. In 17 of these there was no growth. Non-pathogenic organisms were found independently of any pathogens in 33 cases, or over 50 per cent of those examined. Pathogenic organisms were found alone or associated with non-pathogens in 12, or 19.46 per cent. Some variety of staphylococcus was found in 8 instances, and some form of the *Bacillus coli* group in 4 cases.

\* Nadory, B.: Einfache chirurgische Versorgung des Nabelschnurrestes. Zentralbl. f. Gynäk., 1913, xxxvii, 765. Surgery, Gynecology and Obstetrics, November, 1913, 556.

† Adair: Jour. Amer. Med. Assoc., August 23, 1913, 537.

“The significance of this is evident. The cord and its surroundings show the presence of pathogenic organisms in nearly one-fifth of the cases immediately after birth. This is true where the cases are conducted amid the aseptic surroundings of a delivery room. The percentages might easily be much higher where less rigorous asepsis is carried out. This, of course, is no argument for carelessness in the subsequent handling of the cord, for it may be infected at any time.

“What are the essentials for the growth of organisms? (1) The presence of the germs; (2) the proper degree of temperature; (3) a suitable culture-medium and environs; and (4) the presence of moisture.

“It is evident that it will be very difficult to eliminate entirely the presence of bacteria, but we can avoid contaminating the parts with germs, and we can assist in their removal by the use of aseptic and antiseptic measures. The body heat furnishes the proper temperature, and, of course, cannot be interfered with.

“The devitalized tissue of the cord forms a fine medium for the growth and development of the organisms. This can be removed by ligating or clamping the cord close to the skin margin. It has been pretty well demonstrated that better results are obtained by leaving as little cord as possible. Doubtless the methods of amputation proposed by Dickinson, which in his hands have given almost ideal results, accomplish this most thoroughly.

“The presence of moisture may be controlled by having a small stump of cord and keeping it under conditions which favor rapid drying. Various experiments have been conducted along this line, and it has been found that exposure to air is one of the best means of accomplishing this end. Hygroscopic powders have been used with some success; good results have been obtained by the use of astringent and inert powders. Equally good, or better, results have been obtained without any dusting powder. Oily dressings have not given as good results. Dry occlusive dressings have been used. Gauze seems to permit of better and more rapid mummification than cotton.

“In order to fulfil these conditions, the new-born babies have been treated as follows at the University of Minnesota Hospital:

“After cessation of pulsation, the cords were clamped near the skin margin, the surrounding skin and cord cleansed with alcohol, and the clamp removed, to be replaced by a ligature in the groove made by the clamp. The end of the cord and the surrounding skin were painted with one-half strength tincture of iodine in some cases, and in others left untreated. A sterile gauze dressing was then tied over the end of the cord. The babies were oiled for three days, then washed, but no tub-baths were given until the navel was healed. Each day the stump and surrounding skin was washed with alcohol and the dressing changed when necessary.

“A study of the clinical courses of these cases subsequent to delivery may be of interest and profit.

“First in order is a consideration of those cases from which cultures were taken. In all there were 65 cases; one of these was a still-birth; there were 3 unsatisfactory cultures, which leaves 61 for study.

“There were 17 cases which showed no growth; of these, 4, or 23.5 per cent. showed a febrile reaction of over 100° F. There was one case with jaundice, and the average maximum weight loss was 209 gm.

“Of the 32 cases from which non-pathogenic organisms were recovered, there

were 8, or 25 per cent, with febrile reaction; 3 infants were jaundiced, and the average maximum loss of weight was 188 gm.

"There was a temperature rise in 3, or 25 per cent, of the 12 cases in which pathogenic organisms were found; one was jaundiced, and the average maximum weight loss was 202 gm.

"The figures are so close for the different groups that the only conclusion one could draw would be that, so far as this series is concerned, it made little difference whether or not the organisms were present at birth.

"There was no definite evidence of any serious infection of the navel. Two were somewhat reddened without any febrile reaction, jaundice, or marked loss of weight. There were two with some foul odor, one had a febrile reaction of 102° F. and a weight loss of 340 gm. The other had no reaction. Neither had any jaundice. A number of others did not heal so rapidly as usual, but showed no signs of infection. None of these babies died, and all left the hospital in good condition.

"Fifty-eight infants were treated, as outlined above, with alcohol and dry dressings. Of these, 14, or 24.13 per cent, had a rise in temperature to 100° F. or over; 8, or 13.08 per cent, were jaundiced, and of these 4 had fever and there was an average maximum loss of weight of 246.2 gm. The average loss of weight in the febrile cases was 314 gm. Five, or 8.6 per cent, had slight local evidence of navel infection, but none of them had a temperature rise to 100° F. The cord came off in five and one-half days on an average.

"In the second series of cases tincture of iodine was used to paint the cord and surrounding skin. Otherwise the treatment was the same as in the preceding series.

"There were 186 babies treated in this way. The temperature rose to 100° F. or above in 42, or 22.58 per cent, of these; 15, or 8 per cent, were jaundiced, of which 5 had a febrile reaction. The average loss of weight was 228.05 gm. In the cases with fever, this loss amounted to 285.19 gm. Ten, or 5.37 per cent, had slight local evidence of infection of the navel, only 3 of which had any fever. The cord came off in seven and one-half days on an average. None of the babies in either series had any evidence of serious or fatal infection originating at the navel. How many of these febrile cases were caused by absorption of some toxic substance or the entrance of organisms through the umbilicus it is not possible to state. Many conclusions cannot be drawn from this rather small amount of material.

"It is evident that some facts can be stated.

"1. The cord is contaminated with pathogenic or non-pathogenic organisms at or immediately after birth in a large percentage of cases.

"2. It is possible quite effectively to combat serious umbilical infections by comparatively simple methods, as shown by this report of over 200 cases with no mortality from this cause.

"3. There seems to be little choice between the two methods used in these cases.

"4. Jaundice in the new-born child is frequently associated with fever. It would not be illogical to suspect that this might originate by some agent introduced through the umbilical vein or lymphatics.

"5. Febrile reactions are common in the new-born infant, and are associated with other disturbances, such as a high primary weight loss and jaundice. They are due, no doubt, to many causes, but we, as obstetricians, should see that those due to infections entering at the umbilicus are reduced to an irreducible minimum."

## PERSISTENT VITALITY OF THE UMBILICAL CORD.

Occasionally the cord does not come away promptly. This is prone to occur if the cord has been tied at a point too far remote from the umbilicus. This phenomenon was very well shown in a case reported by Williams in 1880, and in cases described by Dorland in 1897.

Williams' patient was a child three weeks old. A fleshy outgrowth an inch long projected from the umbilicus. It was rigid, had a raw, granulating appearance, and bled on the slightest touch. It was sensitive and had a little central opening on its free extremity. The dressings were frequently changed on account of a watery oozing. The central depression did not lead into a canal. A strong silk ligature was applied to the base of the projection. The next day nothing was visible but a small shred of dead tissue, which was nipped off after three days. The child made a perfect recovery.

Dorland said that within a period of ten months he had two cases in which the cord did not come away readily. He mentioned a case in which the cord had not come away at the end of the eighth week, and was then amputated close to the umbilicus. In this case the tissue was almost cartilaginous. In Dorland's cases the cord did not separate until the ninth and sixteenth days respectively. In Case 1 there was fissuring of the cord close to the abdominal wall. The child, on the eighth day, developed convulsions, a persistent high temperature, and inflammation of the umbilicus. It died on the following day.

In the second case the cord was amputated on the sixteenth day. There was a slight oozing for two days, but the child recovered.

## LITERATURE CONSULTED IN THE PREPARATION OF UMBILICAL INFECTIONS IN THE NEW-BORN.

*No attempt has been made to cover the subject.*

- Adair, Fred. L.: Care of the Umbilical Stump. A Bacteriologic Study. Section on Obst., Gyn., and Abdom. Surg. of the Amer. Med. Assoc., at the Sixty-fourth Annual Session held at Minneapolis June, 1913. *Jour. Amer. Med. Assoc.*, August 23, 1913, 537.
- Bednar, A.: Die Krankheiten der Neugeborenen und Säuglinge. Wien, 1852, 168.
- Bergeron, H.: Une épidémie de gangrène de l'ombilic. *Thèse de Paris*, 1866, No. 59.
- Buckmaster, A. H.: Anomphalosis. *Trans. Amer. Gyn. Soc.*, 1906, xxxi, 306.
- Cohn, M.: Zur Lehre von den septico-pyämischen Nabelinfektionen der Neugeborenen und ihrer Prophylaxe. *Therap. Monatssehr.*, 1896, x, 130; 192.
- Cumston, C. G.: Infection of the Umbilicus in the Newly Born. *New York and Phila. Med. Journal*, 1905, lxxxi, 81.
- Dickinson, R. L.: Is a Sloughing Process at the Child's Navel Consistent with Asepsis in Child-bed? An Introduction to the Study of Complete Primary Amputation. *Amer. Jour. Obst.*, 1899, xl, 14.
- Dorland, W. A. N.: Persistence of the Umbilical Cord. *Phila. Polyclinic*, 1897, vi, 254.
- Gremillon: Anomalies et des complications de la cicatrisation de l'ombilic. *Thèse de Paris*, 1895, No. 453.
- Hinsdale, G.: Purulent Encephalitis and Cerebral Abscess in the New-born Due to Infection Through the Umbilicus. *Amer. Jour. Med. Sci., N. S.*, 1899, cxviii, 280.
- Lambert, S. W.: Umbilical Sepsis in the New-born Occurring at the Nursery and Child's Hospital, New York, during 1896. *Med. News, Phila.*, 1897, lxx, 557.
- Lorain, Paul: De la fièvre puerpérale chez la femme, le fœtus, et le nouveau-né. *Thèse de Paris*, 1855, No. 161.
- Maygrier, M. C.: Infection généralisée d'origine ombilicale probable chez un nouveau-né. *Bull. de la Soc. d'obst. de Paris*, 1901, iv, 146.

- Meyer: Puerperal-Infection eines Neugeborenen. St. Petersburger med. Wochenschr., 1891, xvi, 423.
- Meynet, C. H. P.: Épidémie d'érysipèle et d'ulcération de l'ombilic. Thèse de Paris, 1857, xi, No. 156.
- Nadory, B.: Einfache chirurgische Versorgung des Nabelschnurrestes. Zentralbl. f. Gynäk., 1913, xxxvii, 765; Surgery, Gynecology and Obstetrics, November, 1913, 556.
- Nicaise: Omphalic. Dictionnaire encyclopéd. des sci. méd. Paris, 2. sér., xv (1881), 140.
- Pinkerton, J.: A Case of Omphalitis, Umbilical, Closure of Ulcer by a Plastic Operation; Recovery with a Firm Cicatrix. The Lancet, 1900, i, 1656.
- Pollak: Nabelbrand, Darmfistel, Tod. Jahrb. f. Kinderheilk. u. phys. Erziehung, 1869-70, iii, 227.
- Porak: Infection généralisée chez un nouveau-né consécutive à une phlébite ombilicale suppurée. Bull. de la Soc. d'obst. de Paris, 1901, iv, 142.
- Porak, C., et Durante, G.: Infections ombilicales du nouveau-né. Arch. de méd. des enfants, 1905, viii, 449.
- Ribbert: Abscesse des Gehirns, veranlasst durch Embolien des Oidium albicans. Berl. klin. Wochenschr., 1879, xvi, 617.
- Runge: Die Krankheiten der ersten Lebensstage. Stuttgart, 1893, 56.
- Salge, B.: Ein Beitrag zur septischen Infektion des Nabels des Neugeborenen. Charité-Annalen, 1904, xxviii, 263.
- Tarnier et Budin: Traité de l'art des accouchements, 1901, iv, 728.
- Trousseau, M.: De l'érysipèle chez les enfants à la mamelle. Jour. de méd. et de chir., 1844, ii, 1.
- Wassermann, M.: Ueber eine Epidemie-artig aufgetretene septische Nabel-Infektion Neugeborener: ein Beweis für die pathogenetische Wirksamkeit des Bacillus pyocyaneus beim Menschen. Virchows Arch., 1901, clxv, 342.
- Williams, C. R.: Persistent Vitality of the Umbilical Cord. The Lancet, 1880, i, 701.
- Yot, E.: De l'érysipèle inflammatoire ou non-puerpéral des enfants nouveau-nés. Thèse de Paris, 1873, No. 240.

## CHAPTER IV.

### UMBILICAL HEMORRHAGE.

General consideration.

Causes of umbilical hemorrhage.

Treatment.

Instances of umbilical hemorrhage in the new-born.

Umbilical hemorrhage in patients after infancy.

Hematoma of the abdominal wall near the umbilicus.

To discuss thoroughly the enormous amount of literature on this subject would occupy many pages. I shall merely give the salient facts, and report enough cases to give a clear idea of the fatalities resulting from umbilical hemorrhage.

The manner in which umbilical hemorrhage is checked, even though no ligature be applied, is probably explained by Fig. 64. The inner longitudinal muscular coat contracts and thickens, thus tending to obliterate the lumen of the vessel. We know that in many animals, in fact in practically all, the cord is bitten or torn off, no ligature being applied.

Craig (1894), in his article on Umbilical Hemorrhage, quoted J. Foster Jenkins, who in 1858 published a monograph giving the histories of 178 cases, and mentions Grandidier, who had collected 202 cases. In about one-third of the cases the hemorrhage occurred in female children; in two-thirds, in male children.

Craig states that the time of greatest danger is when the cord comes away—from the fifth to the fifteenth day. As the chief causes of hemorrhage he mentions a faulty condition of the blood, pathologic conditions of the vessel-walls, hemophilia. He adds that a condition of ill health or anemia in the mother, due to any cause, produces, to a certain degree, a like condition in her offspring.

Without any premonition of the impending danger, the clothes are found soaked with blood. In 41 out of 175 of Craig's cases the hemorrhage was preceded by jaundice. The most dangerous hemorrhages occurred at night. About 90 per cent of the children die. Where jaundice and hemophilia are present, the condition is most hopeless (Craig).

Cumston, in 1905, writing on infections of the umbilicus in the new-born, says that certain accidents, such as late umbilical hemorrhages arising from the changes in the vessels, are often due to hemophilia, hereditary syphilis, and a kind of hereditary family predisposition. These conditions have been observed by Boissard.

Démelin (quoted by Cumston) divides umbilical hemorrhages occurring secondarily or spontaneously into the three following groups: (1) Hemorrhage due to an arteritis occurring about the time the cord falls off. (2) Hemorrhage occurring in acute degeneration of the infant, with icterus of infective origin. (3) Hemorrhage in cases of septicemia of the newly born, which is produced by the same mechanism as holds in cases of congenital syphilis following umbilical inflammation.

Gallant, in 1907, gave a good résumé of the subject of umbilical hemorrhage, and added an excellent table of the reported cases.

Runge (*op. cit.*, p. 197) says that cases of umbilical hemorrhage in which, on anatomic examination, no syphilis was present, have been reported by Wachsmuth, Weiss, Hryntshak, Fischel, and others.

According to Mraček, the hemorrhage is caused by disease of the small and large veins. In the walls, especially of the veins, is found a thickening due to multiplication of the nuclei. He found the lumen narrow, and in several cases completely closed.

Runge (p. 198) asserts that septic diseases of the new-born have been proved to be the cause of idiopathic bleeding by the observations of Weber, Ritter, and Epstein. Capillary hemorrhages are relatively common in septic cases, but in addition severe bleeding from various organs has been observed in septic diseases of the new-born, especially in foundling hospitals. Epstein found bleeding 24 times in 51 children suffering from a well-developed acute septicemia. Runge notes that, in cases in which bleeding took place, there was often gangrene of various parts of the surface of the body. In cases of general septicemia there is a tendency toward hemorrhage; various organs may be affected, and as a result we may have bleeding from the umbilicus.

The hemorrhage is sometimes noted a few hours after birth. In each of the three cases recorded by Kommerell the bleeding occurred a few hours after birth, but all the infants recovered.

In his first case the mother reported that her first child had had severe umbilical hemorrhages, and she had asked the midwife to be particularly careful. The midwife accordingly had tied the cord twice with firmness and extra care, and, when she left, it was in good condition. Later, however, a severe hemorrhage occurred. The bleeding ceased spontaneously and the child recovered.

In Kommerell's second case the midwife had tied the cord a second time and the father had seen that it was properly done. During the night the child was restless; in the morning it was very pale, and there had been severe bleeding from the cord. The hemorrhage stopped spontaneously and the child recovered.

The fact that these bleedings occurred several hours after birth, according to Kommerell, is easy of explanation. After being cut the blood-vessels contract,

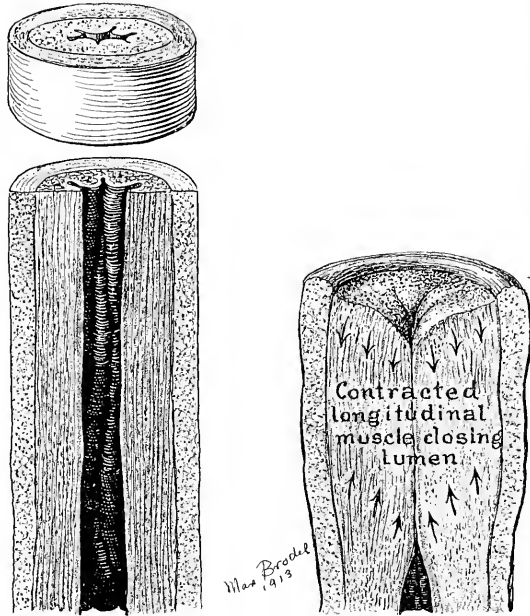


FIG. 64.—NATURE'S METHOD OF CHECKING BLEEDING FROM THE UMBILICAL ARTERIES.

On the left we have transverse and longitudinal sections of an artery showing the intima, the thick longitudinal muscular coat, and the outer circular coat. When the vessel is cut across in the living, the longitudinal muscle probably contracts, as indicated by the arrows, forming an effectual barrier to the further escape of blood. Were it not for some such mechanism as this, many animals would perish, since in their case the cord is left to take care of itself.

while at the same time the blood-pressure is diminishing. The intra-abdominal portion of the umbilical artery continues to pulsate after pulsation has ceased in the extra-abdominal portion. If, now, the soft mass within the umbilical pedicle loses in energy, while in the intra-abdominal part the umbilical vessels are still filled, hemorrhage can readily occur.

Kommerell reports another case in which, several hours after the midwife had tied the cord, fatal hemorrhage occurred. The midwife was sentenced to eight days in jail. Kommerell then goes on to discuss the responsibility in such cases. In Sibert's case the infant died of umbilical hemorrhage thirty hours after birth. The cord was three-quarters of an inch in diameter. On account of "unusual excitement" in the cord, tying was delayed. Sibert saw the child twenty hours after birth. It was pale and was bleeding from the umbilicus. The ligature was not found when the cord was examined. A second was applied. After a time the bleeding recurred. The mother's health during gestation had been bad. There was no history of a hemorrhagic diathesis.

The hemorrhage may occur two or three days after the birth of the child, or an interval of several weeks may elapse before bleeding is noted. In Craig's case, for example, oozing from the umbilicus was noted on the second day. There may be hemorrhages at irregular intervals, extending over a period of from a few hours to two or three days, or, as in Garcin's case, the hemorrhage may be so severe that the child dies in a few minutes after the bleeding has been detected.

In some cases the bleeding is intermittent, in others, constant. Stuart's description of the bleeding in his case is graphic: "It reminded one of the water bubbling through sand at the bottom of a spring; only the oozing and welling up from the stump of the cord were very deliberate and slow."

#### CAUSES OF UMBILICAL HEMORRHAGE.

The most frequent causes of umbilical hemorrhage appear to be heredity, infection, and syphilis.

**H e r e d i t y .** — Taylor, in 1893, reported three cases occurring in one family; the mother's first cousin had lost two children from umbilical hemorrhage.

**I n f e c t i o n .** — Umbilical infection, with its subsequent general infection and jaundice, evidently plays a very important rôle in the development of hemorrhage from the umbilicus. In Chapter III it has been noted that, before the days of asepsis, when outbreaks of puerperal sepsis developed and many mothers succumbed, there was a correspondingly large percentage of umbilical infections in the new-born. Fortunately, this is in large measure a thing of the past. Thus Garcin, in 1903, when reporting a fatal secondary hemorrhage from the umbilicus eight days after birth, could say: "I have never had one like it, although I have officiated or assisted in upward of a thousand obstetrical engagements."

**S y p h i l i s .** — Runge says that not only Grandidier, but also other authors, have noted syphilis in the parents of children that have developed umbilical bleeding. Several writers have described in detail the syphilitic changes that were present in the children during life and after death, and are inclined to regard this disease as the etiologic factor. Behrend described a "syphilis hæmorrhagica."

Runge says that this form of syphilis only rarely affects children. When the disease is noted at birth, it is most frequently encountered in premature children,



who, if not born dead, die almost immediately or live only a few hours, rarely a day. In these cases, in addition to the marked changes, which are usually those found in syphilis, can be noted numerous hemorrhages under the skin and in the internal organs. Sometimes there are hemorrhages into the stomach and intestine, into the peritoneal cavity and the meninges.

When such children live for a longer period, there occur new hemorrhages in the skin or in the various organs. Runge cites the case of a child showing marked syphilitic changes, in which hemorrhage occurred from the edges of the anus and from the tip of the tongue, and finally, on the eighth day, from the umbilicus. The blood came out of the skin, just as drops of sweat would do, and on the ninth day marked icterus developed and the child died. At autopsy extensive syphilitic changes were found in the internal organs.

#### TREATMENT.

Astringents, such as silver nitrate, tannic acid, and iron persulphate, have been used with little or no effect. Adrenalin has proved of little value.

Attempts have been made to check bleeding by encircling the umbilicus with a catgut or silk ligature, or by transfixing it with two straight needles placed at right angles, and tying a ligature beneath them. In this way temporary cessation of the bleeding has occasionally been effected, but it soon recurs. Our hope for the future seems to lie, in large measure at least, in bringing about a coagulation of the blood. The condition being, in some cases at least, analogous to melæna neonatorum, a practical line of treatment should be sought for along the same lines.

The following case recorded by Reichard is of interest, although the bleeding was not from the umbilicus, but from the bowel. It will be noted that a child of this mother had died of hemorrhage on the fourth day.

*S p o n t a n e o u s H e m o r r h a g e o f t h e N e w - b o r n , w i t h R e c o v e r y .* — V. M. Reichard\* reported the following case:

“Spontaneous hemorrhage of the new-born is so obscure and so fatal a disease that any experience pointing the way out is worth recording. All treatment detailed in the literature of the subject is so difficult a technic as to require either special skill or special apparatus or both. In view of these facts the following case is worthy of report:

“Mrs. R., aged forty-two, white, was delivered rapidly and easily of her ninth child at 4 P. M. August 26, 1912. She was not in labor more than thirty minutes, and the baby was born fully half an hour before the attendant's arrival. The child, a girl, weighed nine and one-half pounds and appeared perfectly well and normal. Of the eight children previously born, two had died, one, the first-born, of some bowel complication at four months; and one, the fourth, of hemorrhage on the fourth day. The ninth child was well for thirty-six hours, when the nurse found her listless and flaccid. On examination it was discovered that a large quantity of blood had been passed by bowel. Some of the blood was red, but a much larger part was dark and tarry-looking. I saw her at 9 A. M., August 28th. The child was then of a deep lemon color and in profound shock. She had vomited some blood. During the day she had half a dozen bloody stools, and at 9 P. M. the pulse was rapid and weak. She had been very languid and relaxed all the day, though she had taken the breast at three-hour intervals. At 9 P. M. she was given about 15 c.c. of

\* Reichard, V. M.: Jour. Amer. Med. Assoc., October 26, 1912, 1539.

normal horse serum subcutaneously. August 29th and 30th small amounts of blood were passed, but each time the amount was less, running possibly from half an ounce down to a teaspoonful. At 7 P. M. on the thirtieth the child was given 20 c.c. of normal horse serum, and from that time on there has been no blood. Both injections were made into the buttocks, one on each side. On September 1st the stools were the usual yellow color of a nursing infant, and have continued so ever since. On September 16th, when last seen, she was a splendid specimen of baby, skin clear and healthy, and nursing well, bowels regular, stools natural, and every evidence of perfect health.

"Twenty cubic centimeters is a fairly large subcutaneous dose for an infant, and in this case put the skin on the stretch decidedly. This tension subsided rapidly, and in an hour's time the tumor had disappeared."

In Reichard's case the employment of horse serum gave good results. Serum in another form was employed by Chartier in a case of umbilical hemorrhage, with recovery of the child.

It is also possible that the newer and simpler methods of transfusion may yield good results. These children are, as a rule, too far gone to permit of the linking-up of a vessel with that of a donor.

#### INSTANCES OF UMBILICAL HEMORRHAGE IN THE NEW-BORN.

Umbilical Hemorrhage in the New-born.\*—Hemorrhage occurred two days after the cord came away. During the first three days the weight of the child diminished from 2910 to 2480 gm. There were also vomiting and diarrhea. On the seventh day there was an umbilical hemorrhage and the child became blanched. The umbilicus was cauterized with nitrate of silver. The same evening another hemorrhage followed, and several drops of 1:1000 adrenalin were applied. The next morning free hemorrhage still persisted. The child was absolutely colorless, the pulse hardly perceptible. Thirty cubic centimeters of the serum were injected, and two hours later 20 c.c. of serum gelatin. On the next day another injection of 20 c.c. of serum gelatin was given. The child made a good recovery.

Chartier employed a sterilized solution of 25 gm. of gelatin in 1000 gm. of Hayem's serum.

Umbilical Hemorrhage. — C. F. Craig † reports a fatal case: "On the second day blood oozed from the umbilicus where the cord was attached. Compresses were applied, and the bleeding ceased. On the third morning the umbilicus appeared to be in good condition, but the child had vomited blood several times. On the following morning there had been no more vomiting, but the child was jaundiced. A few hours later there was more bleeding from the umbilicus and the child died in the course of a few minutes."

Hemorrhage from Umbilicus. — Fry ‡ reports the case of a colored child weighing seven pounds and four ounces. On the eighth day the cord came away. On the twelfth there was bleeding from the umbilicus. Compresses and

\* Chartier: Omphalorrhagie grave, traitement par le sérum gélatiné, guérison. Arch. de méd. des enfants, 1905, viii, 477.

† Craig, C. F.: The Medical News, 1894, lxxv, 569.

‡ Fry, Henry: Omphalorrhagia Neonatorum. Amer. Jour. Obst., 1907, lv, 856.

an abdominal binder were applied. On the following day a solution of 1:10,000 of adrenalin chlorid was used, and forty-eight hours later a purse-string of catgut was tried. The bleeding still continuing, two hours later two needles were passed through the umbilicus at right angles, the tissues were constricted with a silk ligature, and five grains of calcium lactate were given every four hours. A temporary cessation of the hemorrhage ensued. Styptic collodion was tried, and a compress of 10 per cent gelatin solution, changed every two hours. A dram of gelatin solution in two drams of normal salt solution was injected under the skin. The blood on the second day showed: Red corpuscles, 3,500,000; white corpuscles, 9000; hemoglobin, 70 per cent. The baby died four days after the onset of the bleeding.

**Fatal Secondary Hemorrhage From the Umbilicus Eight Days After Birth.**—In Garcin's\* case the hemorrhage from the umbilicus began on the eighth day after birth. The labor, which was uncomplicated, occurred on October 23, 1902, and the cord came away in a normal manner. On October 31, the child was bleeding to death from the umbilicus. The father discovered blood on the bed when going to work. On the doctor's arrival the child was just alive. The hemorrhage was promptly controlled by compresses of sterile gauze saturated with suprarenal extract. The child, however, died in a few minutes.

**A Case of Fatal Umbilical Hemorrhage.** †—The infant died of umbilical hemorrhage thirty hours after birth. The cord was three-quarters of an inch in diameter. On account of "unusual excitement" in the cord, tying was delayed. Sibert saw the child twenty hours after birth. It was pale and was bleeding from the umbilicus. The ligature was not found when the cord was examined; a second was applied. After some time the bleeding recurred and the child died. The mother's health during gestation had been bad. There was no history of a hemorrhagic diathesis.

**Three Cases of Umbilical Hemorrhage Occurring in the Same Family.** ‡—Case 1.—A female infant, thirteen days old, seen on September 29th. She was the eighth child of a healthy family. The mother's first cousin had lost two children from umbilical hemorrhage. The child was a fine large baby. The cord was very thick, and did not separate until the seventh day. Before the separation a visitor had seized hold of the front of the child's clothing, and after that time the navel had been inclined to weep. The bleeding was more severe on the thirteenth day. The umbilicus was dusted with tannic acid. On September 30th the bleeding continued. On October 1st the hemorrhage was profuse. The child died at 5 A. M. October 2d. During the illness it was noted that the elbows and ankles were becoming discolored.

Case 2.—A female child, eight days old, seen on December 19th. She was the tenth child. The umbilical cord had not come away. The clothes were stained with blood, and the child was blanched. Above the umbilicus for one inch the surface was red and the skin abraded. The blood was oozing from this area, and also welling from the umbilical scar. Styptics were of no avail. Two harelip pins stopped the bleeding. Two days later, however, the bleeding again commenced, and the child died three days after the onset of the hemorrhage.

Case 3.—November 10, 1887, male child, ten days old. This was the

\* Garcin, R. D.: Virginia Med. Semi-Monthly, vii, April, 1902–March, 1903, 376.

† Sibert, D. E.: Arch. of Pediatrics, 1884, i, 307.

‡ Taylor, James: Bristol Med. and Chir. Jour., 1893, xi, 237.

twelfth child. The cord came away on the seventh day. On November 10th a patch of dark-colored blood was noted on the dressing from the navel. On November 12th, a bruise was detected on the shoulder. In this case the child was well six years later.

Taylor says this disease appears to be more common in male children, and that the tendency to hemorrhage is transmitted through the female members of the same family.

**Fatal Umbilical Hemorrhage in the New-born.\***—A woman, who had been weakened greatly by several pregnancies occurring in rapid succession, developed jaundice, and her child was delivered four weeks too soon. The woman died several hours later from hemorrhage.

The child was weak. Forty-eight hours after birth it developed jaundice. It did not take the breast well. In the night between the third and fourth days bleeding came on in the umbilical region, from between the cord and the umbilicus. The child died.

**Hemorrhage From the Umbilical Cord on the Tenth Day.†**—The baby was ten days old. Two hours before Stuart saw him there had been a hemorrhage from the umbilicus. The cord in this case had come off on the fifth or sixth day, and blood was oozing and welling up drop by drop from the apparently non-ulcerated but healthy-looking stump. Stuart says: "It reminded one of the water bubbling through sand at the bottom of a spring; only the oozing and welling up from the stump of the cord were very deliberate and slow."

Monsel's solution, silver nitrate, powdered tannic acid with subsulphate of iron, and transfixion of the stump were tried, but with no result. The child died the next morning. Stuart says: "A remarkable feature of this case was the location of the collateral hemorrhage in the eyes, from the conjunctival mucous membrane, when the bleeding seemed to be controlled for a time at the umbilicus."

#### UMBILICAL HEMORRHAGE IN PATIENTS AFTER INFANCY.

We have records of two cases, one reported by Strecker and one by Colombe. Strecker's patient was a small, pale lad of eleven, who two days after jumping down a short distance was seized with bleeding from the umbilicus, associated with alarming abdominal symptoms. As the patient recovered, the cause of the bleeding was never discovered.

Colombe's patient was a woman thirty-six years old. She had a small nodule at the umbilicus, and from it severe bleeding took place. The bleeding ceased with the removal of the nodule.

**Umbilical Hemorrhage at Eleven Years of Age.‡**—John S., aged eleven, a small, pale, blond boy, on March 9, 1902, jumped from a porch floor to the ground,—about three feet,—but felt no ill effects. On March 11th he complained of pain at the navel, and blood was discovered coming from it. The umbilicus with the surrounding tissue for one inch was much higher than the rest of the abdominal wall. An elastic truss was applied. On March 12th there

\* Sadler: *Tödliche Blutung aus dem Umfange des Nabels bei einem Neugeborenen.* Schmidt's Jahrb., 1840, xxvii, 177.

† Stuart, A. R.: *The Medical News*, 1895, lxvi, 159.

‡ Strecker, J. E.: *The Medical World*, 1903, xxi, 211.

was another umbilical hemorrhage, and the abdomen was markedly distended, almost to the bursting point. Opiates were given. The patient vomited bile, mucus, and fecal matter, and was in a state of collapse. On March 13th the abdomen was less tense, but at 4 P. M. there was a still more alarming hemorrhage. Calcium chlorid was given. On March 15th an operation was contemplated, but was put off, as the patient was better. On March 25th the patient seemed well. In this case there may have been hemorrhage into the abdomen coming through the umbilical opening. As the patient recovered and no operation was performed, it is impossible to determine the nature of the case with absolute certainty.

**A Small Vascular Tumor at the Umbilicus; Hemorrhage. Recovery.\***—This patient was a woman thirty-six years of age. She was in good health and had had a child at nineteen. About ten years before admission the patient had noticed a small tumor, the size of a grain of wheat, at the umbilicus. This had gradually increased in diameter. It was purple, rather soft, painless, but inconvenient. About a week before her admission it was the size of the end phalanx of the little finger.

Two years before coming under observation there had been hemorrhage from the tumor. The blood had come in jets. This bleeding had lasted for two days, but had not been continuous, and had been controlled with iron perchlorid. Three days before admission she had had a second hemorrhage. Perchlorid of iron was again used. The volume of the tumor could be compressed to the diameter of the femoral artery, and the bleeding was intermittent. The patient was in a sea of blood. She was pale and apparently in a serious condition. Forceps were applied, and the area ligated *en masse*, but control was difficult, as the bleeding was from the bottom of the umbilicus. Seven days later bleeding occurred again. A new ligature was applied, and the bleeding stopped and never returned. The tumor disappeared. The origin of this condition remained unknown.

#### HEMATOMA OF THE ABDOMINAL WALL NEAR THE UMBILICUS.

This condition is exceptional. Hartz, after giving a splendid résumé of the various methods of treating the umbilical cord, says that Westphalen mentions a hematoma of the umbilicus due to a double rupture of the umbilical vein.

On January 10, 1903, in consultation with Dr. Thomas Linthicum, I saw a middle-aged woman who had a marked cardiac lesion, which had been associated with swelling of the extremities and with dropsy. She also gave a definite history of gall-stones. In April, 1902, she had had erysipelas which had lasted four weeks, and shortly afterward had had swelling of the wrists and noticed an abdominal enlargement. Two weeks later jaundice developed, which lasted three or four weeks. About this time cardiac symptoms were noted. Later on she was seized with a violent pain in the left leg, which lasted several hours and then extended to the right leg, reaching from the hip to the toes. Dr. Wells said that the circulation had stopped in the leg. When Dr. J. M. T. Finney saw her a few days later pulsation was again perceptible in the leg, but he agreed with Dr. Wells that the trouble was in the arterial circulation. The patient was ill for weeks, and when she was able to sit up, the limbs became markedly swollen. On December 15, 1902, she

\* Colombe: Tumeur vasculaire de l'ombilic; hémorrhagie, guérison. Gaz. méd. de Paris, 1887, lviii, 245.

was seized with a severe pain, which seemed to be in the region of the liver, and on December 18 she was thought to be dying. After the circulation stopped in the leg black spots, evidently subcutaneous hemorrhages, developed. These were noted from time to time, but were most marked in December. They varied in size from that of a cent to that of two hands. A gradual improvement followed, until she was admitted to the hospital for operation.

When I saw her, just above and to the right of the umbilicus was a deep-seated and apparently cystic mass, fully 16 cm. in diameter. On January 15th the patient was removed to Baltimore. She stood the journey poorly, but under ether the pulse became more regular.

An incision was made to the outer side of the right rectus, directly over the center of the cystic mass. The swelling was due to a large hematoma between the transversalis fascia and the peritoneum. The cavity was irregularly circular, and had numerous little bays running off in all directions. The walls and floor of the sac were thickened, and consisted of granulation tissue. The cavity was filled with dark, clotted blood. I packed this cavity loosely with iodoform gauze.

An incision was now made to the left of the median line, and curved upward to the right. After the gall-bladder adhesions had been separated two gall-stones, each about 5 mm. in diameter, were removed, and the gall-bladder was drained. The hematoma cavity rapidly granulated and closed completely. The gall-bladder wound also closed, and the patient was discharged in a relatively good condition.

I have given the symptoms somewhat fully in order that the reader may see that the cardiovascular system was in such a condition that a rupture of one of the blood-vessels was much more prone to occur than in a healthy individual. This hematoma had undoubtedly been due to a rupture of either an artery or a vein.

In a personal communication dated Sydney, Australia, March 14, 1911, Dr. Fiaschi tells me that his father had a very interesting case just before Christmas, 1910. A young woman developed a hematoma of the left rectus above the umbilicus during or just after labor. She came from the country, and Dr. Fiaschi and his father thought prior to operation that they might find a ruptured or suppurating hydatid of the abdominal wall or of the left lobe of the liver.

#### LITERATURE CONSULTED ON UMBILICAL HEMORRHAGE.

- Chartier: Omphalorrhagie grave, traitement par le sérum gélatiné, guérison. *Arch. de méd. des enfants*, 1905, viii, 477.
- Colombe: Tumeur vasculaire de l'ombilic; hémorrhagie, guérison. *Gaz. méd. de Paris*, 1887, lviii, 245.
- Craig, C. F.: Umbilical Hemorrhage, Etiology, Pathology, and Treatment. *The Medical News*, Phila., 1894, lxxv, 569.
- Cumston, C. G.: Infection of the Umbilicus in the Newly Born. *New York and Phila. Med. Jour.*, 1905, lxxxi, 81.
- Fry, Henry: Omphalorrhagia Neonatorum. *Amer. Jour. Obst.*, 1907, lv, 856.
- Gallant, A. E.: Disorders of the Umbilicus with Special Reference to the New-born and the Infant—III. Umbilical Infections. *Internat. Clinics*, 1907, 17th series, i, 151.
- Garcin, R. D.: Fatal Secondary Hemorrhage From the Umbilicus Eight Days After Birth. *Virginia Med. Semi-Monthly*, vii, April, 1902–March, 1903, 376.
- Hartz, A.: Abnabelung und Nabelkrankung. *Monatsch. f. Geb. u. Gyn.*, 1905, xxii, 77.
- Kommerell: Ueber Nachblutungen bei unterbundener Nabelschnur. *Aerztl. Rundschau*, München, 1896, vi, 627.

- Reichard, V. M.: Spontaneous Hemorrhage of the New-born with Recovery. Jour. Amer. Med. Assoc., October 26, 1912, 1539.
- Runge: Die Wundinfektionskrankheiten der Neugeborenen. Die Krankheiten der ersten Lebens-tage. Stuttgart, 1893, 56.
- Sadler: Tödliche Blutung aus dem Umfange des Nabels bei einem Neugeborenen. Schmidts Jahrb., 1840, xxvii, 177.
- Sibert: A Case of Fatal Umbilical Hemorrhage. Arch. of Pediatrics, 1884, i, 307.
- Strecker, J. C.: Umbilical Hemorrhage at Eleven Years of Age. Med. World, 1903, xxi, 211.
- Stuart, A. R.: Hemorrhage From the Umbilical Cord on the Tenth Day. The Med. News, 1895, lxvi, 159.
- Taylor, J.: Three Cases of Umbilical Hemorrhage Occurring in the Same Family. Bristol Med. and Chir. Jour., 1893, xi, 237.

## CHAPTER V.

### GRANULATION TISSUE OR GRANULOMA OF THE UMBILICUS.

General description.  
Differential diagnosis.  
Treatment.

WITHOUT doubt this is the most frequent umbilical abnormality met with, and probably every physician in general practice has at some time noted the presence of a small red mass in the umbilical depression shortly after the cord has come away.

In England attention has been drawn to the subject by Millar, in Germany by Ledderhose, Pernice, and others; in France the subject has been interestingly handled by Lannelongue and Frémont, Forgue and Riche, and by Florentin; in the American literature we find articles on the subject by Holt and by de Villiers.

Immediately or shortly after the cord comes away, a slightly purulent or yellowish discharge may be noted at the umbilicus, and on separation of the umbilical folds a small red tumor mass is seen on the umbilical floor. It is usually the size of a pea, more or less pedunculated, light or dark red in color, has a rather smooth, glistening surface, and, although sometimes firm, is generally soft and mushy and may bleed readily. It is nothing more than typical granulation tissue. It represents that portion of the umbilical cord distal to the ligature, which in the process of separation has not completely come away.

On histologic examination the entire mass is found to consist of young granulation tissue. Its blood capillaries are very abundant and scattered throughout the field are many small round-cells. In 4 out of 27 cases collected by Pernice the surface of the granulation was partly covered over with a delicate epithelium.

Millar has pointed out that the superficial cells of the granulation tissue may be so flattened that they produce a quasi-epithelial covering.

These small tumors, consisting of granulation tissue, were formerly often confused with another small umbilical tumor found immediately or shortly after the cord has come away. These nodules, however, are very firm, are not apt to disappear, and are remnants of the omphalomesenteric duct. With a little practice the two varieties can be readily differentiated clinically. The chief points of difference are discussed in the chapter on Umbilical Polyp (*cf.* p. 124).

I append the report of a case of a small granulation tumor at the umbilicus that came under my notice in consultation with Dr. George L. Wilkins, December 31, 1910:

**Granuloma or Granulation Tissue at the Umbilicus.**  
—Baby A. The child was two months old. The mother said that, when the cord was tied, the midwife noted that it was very much larger than usual at the umbilicus. After the cord came away there was an abundant discharge of what the mother said was corruption. This had been very free until a short time previously. The umbilical margins were raised fully 2 mm. from the surface (Fig. 65). In the center was a little red mass, globular in form, which showed a whitish mottling, just as if there were a mucosa with areas of skin covering it at certain points. It lay directly in the center of the umbilicus. Dr. Wilkins had from time to time applied nitrate of silver. The nodule had diminished somewhat in size. It was



removed without much difficulty, and found to be exceedingly friable. Histologic examination showed that it was composed entirely of granulation tissue. There was no evidence at any point of an epithelial covering.

**Treatment.**—In some cases it will suffice to snip off the excessive granulation tissue with the scissors, and then apply an astringent. On account of the smallness of the umbilical opening it is usually better merely to apply an astringent and then keep the parts dry. The granulation tissue then soon dries up and drops off. It is sometimes possible to tie off the granulation mass, but, as a rule, it is too mushy.

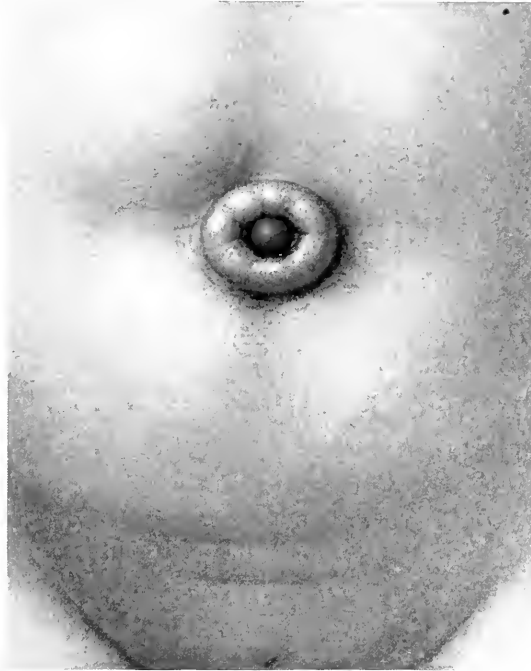


FIG. 65.—AN UMBILICAL GRANULATION.

The umbilical ring is unusually prominent, protruding at least 2 mm. above the abdominal wall. In the center is a small, globular, red mass. It was very friable, was readily removed, and did not recur. On histologic examination it was found to consist essentially of young granulation tissue rich in blood-capillaries. It contained no epithelial elements.

#### LITERATURE CONSULTED ON GRANULATION TISSUE OR GRANULOMA OF THE UMBILICUS.

- Florentin, P.: *Fungus de l'ombilic, chez le nouveau-né et chez l'enfant*. Thèse de Nancy, 1908-9, No. 22.
- Forgue et Riche: *Montpell. méd.*, 1907, xxiv, 145-169.
- Holt, L. Emmett: *Umbilical Tumor in an Infant formed by Prolapse of the Intestinal Mucous Membrane of Meckel's Diverticulum*. *Med. Record*, 1888, xxxiii, 431.
- Lannelongue et Frémont: *De quelques variétés de tumeurs congénitales de l'ombilic et plus spécialement des tumeurs adénoïdes diverticulaires*. *Arch. gén. de méd.*, 1884, 7e sér., xiii, 36.
- Ledderhose, G.: *Deutsche Chirurgie*, 1890, Lieferung 45b.
- Millar, W. Heptinstall: *Umbilical Polypi*. *St. Thomas's Hospital Reports, New Series*, xix, 287.
- Pernice, L.: *Die Nabelgeschwülste*, Halle, 1892.
- de Villiers, J. H.: *The Nature of Umbilical Growths of Infants and Young Children*. *Pediatrics*, 1897, iii, 337.

## CHAPTER VI.

### REMNANTS OF THE OMPHALOMESENTERIC DUCT.

General consideration.

Umbilical polyp.

Historical sketch.

Symptomatology.

Macroscopic appearance of the tumor.

Microscopic appearance of the tumor.

Multiple umbilical polyps.

Differential diagnosis.

Treatment.

Cases in which umbilical polyps have been noted.

THESE comprise one of the most interesting groups of pathologic conditions found in the umbilical region. The literature on the subject is abundant, many authors having studied and described more or less in detail remnants of one or more portions of the omphalomesenteric duct. Among the more important articles dealing with the subject are those of Cazin (1862), Roth (1881), Tillmanns (1882), Fitz (1884), Barth (1887), Zumwinkel (1890), Pernice (1892), Deschin (1895), Ophüls (1895), Kirmisson (1898), Morian (1899), and Florentin (1908).

In the following pages I shall discuss at some length the various remnants of the omphalomesenteric duct that have been described in the literature, and shall also deal with remnants of the omphalomesenteric vessels as they have been noted at operation or at autopsy. Barth, Zumwinkel, and Morian have each given a scheme, illustrating the various remnants of the omphalomesenteric duct that have been met with. After a thorough survey of the literature I have amplified to some extent the schemes heretofore published.

**Umbilical Polyps.**—The most common remnant of the omphalomesenteric duct is a small red polyp noted in the umbilical depression, when the cord has come away. It is bright red in color and secretes mucus. On microscopic examination its outer surface is seen to be covered with mucosa similar to that of the small bowel, and its center is composed of non-striped muscle. It may persist for years unless tied off or cut off.

There is a group of small umbilical polyps or umbilical fistulæ in which the outer covering, or the lining, as the case may be, consists of a mucous membrane that secretes a fluid more or less similar to gastric juice. The mucosa itself bears a striking resemblance to gastric mucosa. Only a few of these cases have been observed.

The outer portion of the omphalomesenteric duct may remain patent, there being evident at the umbilicus a small projection into which a probe can be passed for a variable distance. The projection, and also the canal extending into the depth, are covered or lined with mucosa similar to that of the small bowel.

Meckel's diverticulum is the patent inner end of the omphalomesenteric or vitelline duct. It usually arises from the convex surface of the bowel, but occa-

sionally projects from the mesenteric border. It may or may not be attached to the umbilicus. The various forms of Meckel's diverticulum will be considered, and then the complications that may be associated with its presence.

Intestinal cysts may develop in various ways. Those originating from a portion of the omphalomesenteric duct may be situated beyond the convexity of the bowel; occasionally they lie in the mesentery of the ileum. As they originate from the omphalomesenteric duct, they are lined with mucosa similar to that of the small bowel.

A review of the literature shows that, in a certain number of cases, as soon as the cord comes away, more or less discharge comes from an opening at the umbilicus. This is usually due to a patent omphalomesenteric duct. The opening at the umbilicus may lie in the umbilical depression, but quite frequently there is at the umbilicus a reddish projection, in the center of which is the opening of the duct. The amount of discharge depends, in a large measure, on the caliber of the duct. When this is small, just the faintest amount of colorless or brown, watery fluid may escape; on the other hand, if the opening be large, feces and gas escape. Occasionally the fistula develops on the side of the cord near the abdomen before the ligature drops off, and we have the record of one case in which the outer end of the omphalomesenteric duct opened into the abdominal cavity near the umbilicus. In this case Orth found feces in the abdominal cavity among intestinal loops.

When the patent omphalomesenteric duct is of relatively large caliber, there is a tendency for the small bowel to prolapse through the duct and turn inside out on the abdominal wall, forming a sausage-like mass on the exterior of the abdomen. The mass assumes various shapes, is bright or dark red in color, and at either end has an opening corresponding with the lumen of the bowel at the upper and lower end of the prolapsed loop. This prolapsus may occur within a day or two after birth or after several months. When this complication develops, death nearly always speedily follows.

In rare instances remnants of the omphalomesenteric duct have been found between the peritoneum of the abdominal wall and the muscles. They have occurred as small cysts which sometimes communicate with the umbilical depression. Naturally, they are lined with mucosa similar to that of the small bowel.

Sometimes, when all trace of the omphalomesenteric duct has disappeared, remnants of the omphalomesenteric vessels still persist. These may extend from the mesentery of the small bowel to the umbilicus, or be recognized as free filaments attached either to the umbilicus or to the mesentery. These remnants, by becoming adherent to some structure, occasionally cause intestinal obstruction.

After this brief summary dealing with the remnants of the omphalomesenteric duct or its vessels that may be found, we shall consider each abnormality in detail. The various remnants of the omphalomesenteric duct are as follows:

Umbilical polyps.

Gastric mucosa at the umbilicus.

A patent outer portion of the omphalomesenteric duct.

Meckel's diverticulum.

Intestinal cysts.

A patent omphalomesenteric duct.

A patent omphalomesenteric duct opening at birth on the side of the cord.

A patent omphalomesenteric duct with other intestinal lesions.

A prolapse of the bowel through a patent omphalomesenteric duct.

Cysts of the abdominal wall.

Remains of the omphalomesenteric vessels.

#### LITERATURE CONSULTED ON REMNANTS OF THE OMPHALOMESENTERIC DUCT IN GENERAL.

- Barth, A.: Ueber die Inversion des offenen Meckel'schen Divertikels und ihre Complication mit Darmprolaps. *Deutsche Ztschr. f. Chir.*, 1887, xxvi, 193.
- Cazin, H.: Étude anatomique et pathologique sur les diverticules de l'intestin. Thèse de Paris, 1862, No. 138.
- Deschin: Zur Frage der chirurgischen Behandlung bei dem Vorfall des Dotterganges. *Centralbl. f. Chir.*, 1895, xxii, 1154.
- Fitz, Reginald H.: Persistent Omphalomesenteric Remains; their Importance in the Causation of Intestinal Duplication, Cyst-formation, and Obstruction. *Amer. Jour. Med. Sci.*, 1884, lxxxviii, 30.
- Florentin, P.: Fungus de l'ombilic, chez le nouveau-né et chez l'enfant. Thèse de Nancy, 1908-09, No. 22.
- Kirmisson: Maladies congénitales de l'ombilic. *Traité des maladies chirurgicales d'origine congénitale*, Paris, 1898, 208.
- Morian: Ueber das offene Meckel'sche Divertikel. *Langenbeck's Arch. f. klin. Chir.*, 1899, lviii, 306.
- Ophüls, W.: Beiträge zur Kenntniss der Divertikelbildungen am Darmkanal. *Inaug. Diss.*, Göttingen, 1895.
- Pernice, Ludwig: *Die Nabelgeschwülste*, Halle, 1892.
- Roth, M.: Ueber Missbildungen im Bereich des Ductus omphalomesentericus. *Virchows Arch.*, 1881, lxxxvi, 371.
- Tillmanns, H.: Ueber angeborenen Prolaps von Magenschleimhaut durch den Nabelring (Ectopia ventriculi) und über sonstige Geschwülste und Fisteln des Nabels. *Deutsche Ztschr. f. Chir.*, 1882-83, xviii, 161.
- Zumwinkel: Subeutane Dottergangscyste des Nabels. *Langenbeck's Arch. f. klin. Chir.*, 1890, xl, 838.

#### UMBILICAL POLYPS.

Incomplete healing of the umbilical stump is not of very rare occurrence. The tissue is dull red in color, rather soft, and soon disappears after the use of astringents.

Now and again, after the cord has come away, a small, polyp-like mass is found in the umbilical depression (Figs. 66, 67, 68, and 91). This is brighter in color than the ordinary granulation tissue, and is unaffected by astringents.

Brun, in 1834, reported the case of a female child, three years old, who came under Dupuytren's care. When the cord came away on the eighth or ninth day, a tumor was noted. It was the size of a cherry and had a mucous surface. It was ligated at its base, and dropped off five days later; the wound healed. Brun says that this child's sister had a similar nodule at the umbilicus. The second child died when four and one-half years old. During the last eight months of her life she complained continually of abdominal pain.

Fabrège, in 1848, reported two cases. The first patient was a boy, one month old. The mother noticed a moisture at the umbilicus as soon as the cord came away. At the umbilicus was a reddish, pedunculated tumor the size of a pea. This was cut away with scissors and the base cauterized. The growth apparently returned. It was again treated in a similar manner, and the umbilicus then remained healed. His second case was in a baby girl three weeks old, who had a pea-sized nodule situated in the umbilical depression. It was red, bled readily on being

touched, and had a definite pedicle. It was gradually constricted with a ligature and dropped off on the third day.

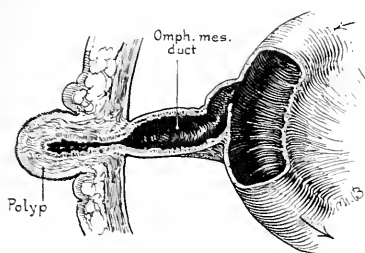


FIG. 66.—THE GRADUAL ATROPHY OF THE OMPHALOMESENTERIC DUCT. (Schematic.)

The outer end of the duct is closed and represented by a polyp-like projection which is covered over with intestinal mucosa. If this were ligated, when the ligature came away, a patent omphalomesenteric duct would undoubtedly result. The duct is patent from the intestine to the umbilicus. For the subsequent stages in the atrophy of the omphalomesenteric duct see Figs. 67, 68, 89, 90, and 91.

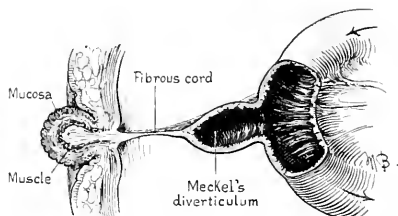


FIG. 67.—AN UMBILICAL POLYP CONNECTED WITH MECKEL'S DIVERTICULUM BY A FIBROUS CORD. (Schematic.)

The umbilical polyp is covered with intestinal mucosa and has a central stem composed of non-stripped muscle and fibrous tissue. The central portion of the omphalomesenteric duct is represented by a fibrous cord, the inner end by Meckel's diverticulum. This condition has been noted in a number of cases. For further atrophy of the omphalomesenteric duct see Figs. 68, 89, 90, and 91.

Simpson, in the *Obstetrical Memoirs and Contributions*, published in Philadelphia in 1856, referred to a case that he saw with Dr. Findlay. The umbilical excrescence resembled a cherry in size and color. It was apparently not painful to the touch, but blood oozed from its surface on handling. Silver nitrate was used several times, but with no effect. A few weeks later a ligature was applied around its base and it dropped off in a few days.

Virchow, in 1862, in referring to "fungus of the umbilicus," mentions two kinds: the more common one is rich in blood-vessels, bleeds easily, and is found after the cord comes away. It consists of granulation tissue. It soon disappears after the use of astringents. The second kind of tumor is a congenital growth.

Holmes, in his "Surgical Treatment of Children's Diseases," published in London in 1868, says that warty or nipple-like tumors projecting from the umbilicus are fairly often seen in children, and that they seem to be due to some morbid condition left by separation of the umbilical cord. He gives Athol Johnson credit for the first reference to this condition noted in the English language. Johnson speaks of it as a stout, nipple-shaped papilla or tubercle arising from the center of the main umbilical depression. Holmes says that these may attain the height of an inch. He saw several, but none as large as this. In his cases the tumors were ligated.

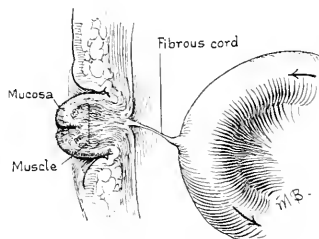


FIG. 68.—AN UMBILICAL POLYP ATTACHED TO THE SMALL BOWEL BY A FIBROUS CORD. (Schematic.)

The outer end of the omphalomesenteric duct is here represented by an umbilical polyp, which is covered over with intestinal mucosa and which consists in a large measure of non-stripped muscle. A slight depression in its tip is all that remains of the lumen of the duct. In the majority of the cases in which a polyp is found, all trace of the cavity has disappeared. In this case the intra-abdominal portion of the omphalomesenteric duct is represented by a cord extending from the umbilicus to the convex surface of the small bowel. It is the possible existence of this cord that must always be thought of in patients who have, or give a history of ever having had, an umbilical polyp.

While all the foregoing tumors were undoubtedly umbilical polyps, Kolaczek seems to have been the first to give us the complete picture of this disease. In 1871, under the title "Enteroteratoma of the Umbilicus," he reported the case of a boy four years old who had a small umbilical tumor. On microscopic examination it was found that the outer surface of the tumor was covered with cylindric epithelium, and opening on the surface were Lieberkühn's glands, while between the glands were lymphatic tissue and connective tissue. The center of the nodule was composed of smooth muscle.

In 1875 Kolaczek reported a second case, which presented a precisely similar picture.

Küstner, in 1876, reported a similar case. He examined a fungus removed from the umbilical depression of a three months old child, not expecting to find anything but granulation tissue, and was not a little surprised to note, instead of this simple structure, a relatively complicated picture. In the center was connective tissue; external to this were round cells and granulation tissue, and embedded in the periphery, numerous tubular glands. The tumor, which was the size of a pea, was covered with beautiful cylindric epithelium.

Parker, in the Archives of Clinical Surgery, published in New York in 1876, reported the findings in a boy two and one-half years old. Soon after birth the parents noticed that the navel did not heal. There was a hard mass situated at the connection of the cord with the abdominal wall, and to the right of the cord a naked, non-cicatrized surface discharging a thin mucous fluid. The area failed to cicatrize, and the tumor increased in size. When the boy was three years old an attempt was made to remove the growth, but only part was taken away, as it extended into the abdomen. Fifteen months later the tumor was harder and firmer and was increasing in size. An elliptic piece of the abdominal wall including the tumor was cut away, and the child made a good recovery.

Dr. Alonzo Clark made the microscopic examination and thought the growth was a cancer. It was, however, in all probability, an adenoma or polyp of the abdominal wall.

Since that time isolated cases have been recorded. Dr. William D. Booker, in a very large pediatric practice, tells me that he has observed only one case. As will be seen from the accompanying abstract of the literature, Gianì reports 4 cases and Hue 5 cases.

#### SYMPTOMATOLOGY.

Umbilical polyps are usually noted when the cord comes away. Some have come under observation during the first few weeks of the child's life; others have not been treated until the child was several months old, and in quite a number of instances not until it was from three to eight years of age. Walther's patient was eighteen years old; Hektoen's, fifteen years; Stori's, twenty years; Gernet's, twenty-four years; Hartmann's, twenty-nine years, and in a case reported by myself the patient was twenty years old.

Apart from a slight umbilical discharge and, where the tumor was rather large, some bleeding, the umbilical nodules have given rise to little or no discomfort.

#### MACROSCOPIC APPEARANCES OF THE TUMOR.

These small tumors in the majority of the cases are not larger than a pea, an olive-stone, a cherry, or a grape. In a few cases, however, the nodule has been large.

In Gernet's case it reached the size of a walnut, measuring 2.5 cm. x 2 cm. Hektoen's was 2.5 cm. long and 3 cm. in its greatest circumference (Fig. 70). Walther's patient had a tumor 2.5 cm. long and 2 cm. broad. In Kirmisson's patient the tumor reached 4 cm. in length.

These tumors are generally bright red in color, but occasionally of a darker hue. They are covered over with a smooth, velvety membrane which looks like intestinal mucosa. Where the tumor is small and protected by the umbilical folds, it is usually bright red and smooth, but when large, it rises above the level of the abdomen, and as a result of the rubbing of the clothing may become irritated.

The nodule often secretes a small amount of alkaline fluid. This is mucus. When irritation has occurred, the mucus may be mixed with a small amount of pus.

The nodule at its tip is usually rounded and intact, but occasionally, at its most prominent point, there is a depression into which a probe may be inserted for 2 mm. or more. In Sheen's case it could be carried one inch inward. The tumor on palpation is firm and elastic and cannot be reduced in size. Manipulation sometimes causes slight bleeding. Although some of these polyps are sessile, they are more apt to be attached to the center of the umbilical depression by a definite pedicle.

The skin surrounding the umbilicus is usually normal. In Capette and Gauckler's case, however, it was drawn up around the polyp, forming a definite prepuce. When there is much discharge from the polyp, the surrounding skin occasionally shows some reddening.

In Broca's case, and also in the one recorded by Capette and Gauckler, there was a small umbilical hernia and the polyp was seated upon the summit of the hernial projection.

#### MICROSCOPIC APPEARANCE OF THE POLYP.

The surface of the polyp is covered over with typical intestinal mucosa. The external layer is composed of cylindric epithelium, and opening on the surface are tubular glands (Fig. 74, p. 133; Fig. 75, p. 134; Fig. 76, p. 135; Fig. 123, p. 207). These resemble Lieberkühn's glands, but occasionally those of the Brunner type are also present, and now and then glands that bear a striking resemblance to those of the pyloric end of the stomach. The stroma between the glands is similar to that noted in the small bowel. The central portion of the polyp consists of non-striped muscle and connective tissue.

When the polyp has been of long standing, and on account of its size has been subjected to contact with the clothing, the surface epithelium may be lacking and the superficial layers of the mucosa replaced by granulation tissue.

The line of junction between the mucosa covering the polyp and the squamous epithelium of the umbilicus is usually abrupt, the normal skin beginning at the point where the intestinal mucosa ends (Fig. 75, p. 134; Fig. 81, p. 140).

In cases in which a channel occupies the center of the polyp this itself is lined with intestinal mucosa.

From the above it is seen that the umbilical polyp is covered over with typical

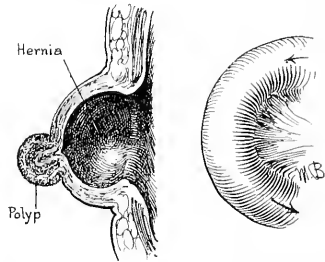


FIG. 69.—AN UMBILICAL POLYP ON THE PROMINENT PART OF AN UMBILICAL HERNIA. (Schematic.)

Small umbilical hernie are relatively common. Umbilical polyps are occasionally met with. The combination of a polyp on the top of a hernia has been noted, but is most unusual.

intestinal mucosa. It is a remnant of the outer end of the omphalomesenteric duct, which has persisted outside the abdominal cavity. When the cord has sloughed off, the remnant contracts down, producing the polyp.

Various names have been applied to these growths—fungus, enteroteratoma, adenoma, and polyp. Such a growth has a definite structure, and should not be called a fungus. Its mode of origin precludes the use of the term enteroteratoma, and, as Holt has pointed out, the name adenoma is not correct. Umbilical polyp seems to be the most suitable name, since there is no abnormality at the umbilicus except granulation tissue that can possibly be confused with it clinically.

#### MULTIPLE UMBILICAL POLYPS.

Henke reports a case in which a pea-shaped umbilical polyp, 5 mm. long, was divided into three small lobes. Kirmisson, in the examination of a child three years old, found a small umbilical tumor which also consisted of three lobes. These were situated in the umbilical cicatrix. The combined tumor was the size of a cherry.

This formation of several lobes is of no significance. The explanation is that the remnant of the vitelline duct has merely split off into several pieces instead of forming one sharply defined and intact nodule.

#### DIFFERENTIAL DIAGNOSIS.

GRANULATION TISSUE.	UMBILICAL POLYP.
Found only during the first few weeks.	May persist for years.
Dull red, or pink.	Bright red in color.
Soft.	Firm and resistant.
A purulent secretion is present.	Secretes mucus unless the surface has become irritated—then mucopus.
Disappears after the use of astringents.	Usually not affected by astringents.
Consists of typical granulation tissue.	Has an outer covering of intestinal mucosa and a center consisting of non-stripped muscle.
Usually disappears in a few months.	Persists until removed.

From this tabulation it is seen that, both clinically and histologically, the differences between granulation tissue and umbilical polyps are so sharp that a diagnosis can usually be readily made.

#### TREATMENT.

Silver nitrate and other caustics have often been used with no effect.

In many of the cases the tumor was simply ligated and dropped off in a few days; in others it was ligated and cut off at once. If only a portion of the growth is removed, the remainder will, of course, persist, and possibly increase a little in volume. In some of these polyps the omphalomesenteric artery still persists, hence the necessity for careful ligation of the pedicle of the polyp. This vessel persisted in Lannelongue and Frémont's Case 2.

In a certain percentage of the cases when an umbilical polyp is present, other portions of the omphalomesenteric duct also persist (Figs. 66, 67, 68, 90). In Löwenstein's case, for example, after the umbilical polyp had been cut away, it was found that the omphalomesenteric duct near the bowel was patent. Here it was 6 mm. in diameter.



In Hartmann's patient, a man of twenty-nine, a typical umbilical polyp was present. The man gradually developed definite signs of intestinal obstruction. Hartmann, on opening the abdomen, found the small bowel dilated and injected. The obstruction was due to a partially patent omphalomesenteric duct. Meckel's diverticulum was markedly compressed at its insertion into the small bowel. The diverticulum was 6 mm. in diameter and 4 cm. long. From that point to the abdominal wall it was continued as a fibrous cord which terminated in the umbilical polyp.

In every case of umbilical polyp it is the duty of the family physician or surgeon to explain carefully to the parents the possible coexistence of an intra-abdominal portion of the omphalomesenteric duct, which may be adherent to the umbilicus and later give rise to intestinal obstruction. The parents should be instructed to watch such children carefully, and if in later life the slightest sign of intestinal obstruction develops, an abdominal operation should be immediately undertaken, the surgeon making an incision encircling the umbilicus and looking immediately for an adherent Meckel's diverticulum.

#### CASES IN WHICH UMBILICAL POLYPS HAVE BEEN NOTED.

That the literature on the subject is relatively small is evidently due in part to the fact that these small polyps often give rise to but little inconvenience. Most of those who have had much to do with children have observed one or more cases.

**A Case of Umbilical Polyp.\***—A child, six months old, had a small growth at the umbilicus. It was deep red in color, had a granular-looking surface, and was attached to the umbilicus by a narrow pedicle. The growth was ligated by Dr. Falkiner and cut away. On microscopic examination Ball found that the pedicle consisted of muscle. Covering the outer surface was glandular tissue with adenoid tissue between the glands. The glands closely resembled those of the stomach. This case appeared to be one of simple umbilical polyp.

**An Umbilical Polyp.**—Bidone† reports the case of a child two years old, in which a small umbilical growth had been noted after the cord came away. This little growth was removed with the thermocautery. It was a typical intestinal polyp. Bidone gives very good pictures of the case, and also a résumé of the literature.

**Umbilical Polyp.**—Blanc and Weil‡ report two small tumors of the umbilicus. The larger was the size of a pea. Both were pedunculated. Many of the glands covering them resembled Lieberkühn's glands. The tumors were remains of the omphalomesenteric duct.

**Adenoid Tumors.**—With regard to the etiology, Blanc,§ working in

\* Ball, C. B.: *Illustrated Med. News*, 1889, iv, 149.

† Bidone, E.: *Enteroteratoma ombelicale*. *Bull. delle scienze med.*, Bologna, 1901, ser. S, i, 374.

‡ Blanc and Weil: *Paris Anatomical Society*, 1899. *Rev. in Centralbl. f. allg. Path. u. path. Anat.*, 1900, xi, 748.

§ Blanc, H.: *Contribution à la pathologie du diverticule de Meckel*. *Thèse de Paris*, 1899, No. 393.

Broca's service, says that in 16 cases there was granulation of the umbilicus, but after personal examination of two of the cases he found the tumors to be adenomatous, suggesting that they had originated from Meckel's diverticulum. They appeared in the umbilical region following birth, immediately after the cord had come away. Such tumors are congenital. They vary in volume from the size of a cherry to that of a pea. They are solid in consistence, and occupy the center of the umbilicus.

Blanc then goes on to report two cases that he had observed. These resembled in practically every particular the small glandular bodies so often noted. He ends with an able discussion of diverticula.

**A n U m b i l i c a l P o l y p .** — Dr. Wm. D. Booker,\* of Baltimore, said that in all his experience he had encountered only one case of adenoma or polypoid outgrowth from the umbilicus. A section showed that it was covered over externally with characteristic intestinal mucosa.

**P o l y p o f t h e U m b i l i c u s . †** — In Broca's clinic a boy, two months old, had a small polypoid mass the size of a pea implanted on the surface of an umbilical hernia. The hernia was about the size of the little finger. The tumor was segmented and projected about 2 cm. from the surface of the umbilicus; it was reddish in color. This polyp was noted on the fourteenth day, *i. e.*, three days after the cord had come away. Broca cut it off with scissors.

**A n U m b i l i c a l P o l y p . ‡** — A girl, three years old, came under Dupuytren's care. The cord came away on the eighth or ninth day, and the tumor, the size of a cherry, was then noted. It had a mucous surface but no fistulous opening. It was tied off with silk at its base. It dropped off on the fifth day and the umbilicus healed.

Brun says that this child's sister had had a similar nodule at the umbilicus. She lived for four and one-half years, but for eight months prior to her death she complained continually of pain in the abdomen. Brun drew attention to the fact that both children had the same abnormal congenital formation.

**U m b i l i c a l P o l y p . §** — An infant boy, born at term, had a large inguinal hernia and an umbilical hernia the size of a hazel-nut. On the surface of the umbilical hernia was a small, oval, red, engorged, and inflamed nodule, about the size of an olive-stone. One pole was free, the other lay in the umbilicus, the skin fold of which formed a prepuce for it. The nodule was cut off with scissors and cauterized, with satisfactory results. Microscopic examination showed that the nodule was a typical adenoma. These authors give Kolaczek credit for describing the first case of this character.

**U m b i l i c a l P o l y p .** — In Colman's|| case the polyp was the size of a split-pea, distinctly pedunculated, and was removed from just within the dimple of the umbilicus of a child two months old. It was first noticed when the child was two weeks old.

\* Booker: Personal communication.

† Broca, A.: Polype de l'ombilic. Jour. de méd. et de chir., 1904, lxxv, 172.

‡ Brun, L. A.: Sur une espèce particulière de tumeur fistuleuse stercorale de l'ombilic. Thèse de Paris, 1834, No. 238.

§ Capette et Gauekler: Note sur un cas d'adénome ombilical. Revue d'orthopédie, 1903, xiv, 271.

|| Colman, W. S.: Adenomatous Polyposus of Umbilicus. Trans. Path. Soc. London, 1888, xxxix, 110.

Microscopic examination of the polyp showed that it was composed of ordinary non-striated muscle, and that it was covered with a thick layer of mucous membrane which contained Lieberkühn's follicles and adenoid tissue, being exactly like the normal mucous membrane of the small intestine.

**An Umbilical Polyp or Enteroteratoma.**—Diwawin\* reports the case of a male child who had a pea-sized tumor situated to the left of the center of the umbilicus. It was red in color and painless. When examined, it was the size of a cherry and was freely movable. In its center was an almost imperceptible opening into which a small sound could be passed for 2 mm. The tumor secreted four or five drops of bloody mucus in the course of a day. It was removed under cocain. The growth was covered with intestinal mucosa.

**Polypoid Excrescences at the Umbilicus in New-born Infants.**—Fabrège† reported several cases.

**Case 1.**—In a small boy, one month old, the mother noticed a moisture at the umbilicus as soon as the cord came away. At the umbilicus was a reddish, pedunculated tumor, the size of a pea. This was cut away with scissors and the base cauterized. The growth apparently returned. It was treated in the same manner, and the wound healed. After a time, however, an abscess developed at the umbilicus. This was opened, and there escaped with the pus a piece of wild-oat straw which had evidently been the cause of the abscess.

**Case 2.**—A baby girl, three weeks old, was found to have a tumor the size of a pea lying between the umbilical folds. The polyp was red, bled readily on being touched, and had a definite pedicle. It was gradually constricted by a ligature and dropped off on the third day.

In neither of these cases was there any microscopic examination, but it must be remembered that these patients were operated upon more than sixty years ago.

**An Umbilical Polyp.**‡—A man, twenty-four years of age, came to the hospital on July 17, 1893. He had had a small tumor at the umbilicus as long as he could remember. It had never become any larger. It secreted a thin, somewhat sticky mucus, but a fecal discharge had never been noted. He had had no pain, but there was a certain amount of discomfort from moisture.

The patient had always suffered from constipation, and three years previously had had obstipation for three days, associated with great abdominal pain and with vomiting. Five days before admission he again had had sudden pain in the abdomen. He had had no stool, but had vomited. The pain had continued, but the vomiting had ceased.

The abdomen was markedly distended, and the entire umbilical region was moist. The skin was eczematous in appearance and was peeling off. The umbilicus was occupied by a moist, glistening, scarlet-red tumor the size of a walnut. The surrounding skin was thickened and in folds. The tumor was soft, elastic, and slightly movable on its pedicle.

**Operation.**—The abdomen was opened and the bowel found drawn up and adherent to the umbilicus in a tent-like manner. On being loosened, the small bowel

\* Diwawin, L. A.: Ein Fall von Enteroteratom des Nabels. Russ. med. Rundschau, 1904, ii, 590.

† Fabrège: Note sur les excroissances polypeuses de la fosse ombilicale chez les enfants nouveau-nés. Revue médico-chir., 1848, iv, 353.

‡ von Gernet, R.: Ein Enteroteratom. Deutsche Ztschr. f. Chir., 1894, xxxix, 467.

tore slightly. The wound in the bowel was closed. In separating the tissues from the ligamentum teres the operator found the umbilical vein patent. The abdomen was closed. The man made a good recovery. The tumor was 2.5 cm. broad and 2 cm. long.

On microscopic examination the outer surface of the tumor was found to be covered with mucosa. The glands of the mucosa were tubular, and the surrounding tissue showed marked inflammation. The gland epithelium was cylindric. Von Gernet failed to find goblet cells, but the glands resembled those of Lieberkühn. In the center of the tumor were delicate bundles of non-striated muscle. Von Gernet thought the case one of enteroteratoma due to prolapsus of the mucosa from remains of the omphalomesenteric duct.

**A N U m b i l i c a l P o l y p .** — Giani\* reports four cases of enteroteratoma or umbilical polyp, and gives excellent illustrations. These cases were noted in the pediatric clinic of Professor Bajardi.

**A C o n g e n i t a l M u c o u s P o l y p o f t h e U m b i l i c u s .** — Gould's† patient was a male, five months old. He had a bright-red, soft, pedunculated, smooth growth, about the size of a large currant, springing by a narrow pedicle from the umbilical cicatrix. At the upper end of this nodule was a small hole admitting a probe for one-eighth of an inch. The tumor was moistened with thin mucus, but there was no discharge of urine or feces. This small nodule was first noticed when the cord fell off. It was then nearly the same size. The nodule was ligated and cut off. Its surface was covered with branching glands and there was the typical interglandular substance. It was covered over with intestinal mucosa.

**I n t e s t i n a l O c c l u s i o n C a u s e d b y P e r s i s t e n c e o f t h e O m p h a l o m e s e n t e r i c D u c t . R e s e c t i o n o f t h e S t r a n g u l a t e d I n t e s t i n e . E n d - t o - e n d A n a s t o m o s i s . R e c o v e r y .** ‡ — A man, twenty-nine years of age, a carter, on June 12th had colic and had to go to bed. Gradually signs of obstruction developed. Five days later he was seen by Hartmann. At that time he had fecal vomiting and great distention.

On examination there was seen in the umbilical depression a granular-like nodule from which there was some discharge. A probe could not be introduced. No history as to the appearance of this nodule could be obtained from the patient.

Operation.—When the abdomen was opened, a large quantity of serous fluid escaped. The small bowel was dilated and injected. The point of obstruction was located, and the bowel was seen to be divided into three branches of equal volume. All three branches were distended. Remembering the appearance of the umbilicus, Hartmann at once thought of a patent omphalomesenteric duct. The abdominal incision was now extended, and the omphalomesenteric duct and the obstructed loop were brought out and removed. The bowel was brought together with an end-to-end suture and the patient recovered.

The diverticulum was noticeably compressed at its insertion into the small bowel. It was 6 mm. in diameter and 4 cm. long. It was continued as an apparently fibrous

\* Giani, R.: Per la casistica degli entero-teratomi dell'ombelico. *Clinica moderna*, 1902, viii, 498.

† Gould, A. Pearce: *Trans. Path. Soc. London*, 1881, xxxii, 204.

‡ Hartmann: Occlusion intestinale par un canal omphalo-mésentérique persistant. *Bull. et Mém. de la Soc. de chir. de Paris*, 1898, n. s., xxiv, 202.

cord, 3.5 cm. long and 4 mm. in diameter, which terminated in the granulation noted at the umbilicus. The patient made a good recovery.

**Vitelline Duct Remains at the Navel.\***—“In November, 1892, a boy, fifteen years old, was brought to me by his father because the navel, which he stated had never healed, had become a source of discomfort to his son, especially when walking. It was learned that there had been something wrong with the navel since birth, and the blame for this was placed on the midwife, who was supposed to have made a mistake in cutting the cord. There had been no special inconvenience felt until very recently, when it was noticed that the navel became tender and sore, particularly after walking or running; a little matter had also appeared, staining the clothes. It was noticed that the boy walked carefully, bending his body forward. The previous history was otherwise negative, and the father had no knowledge of any such or similar conditions in any of the other members of the family. Physical examination showed a well-developed boy, in good general health, whose body was free from all blemish except at the umbilicus, which presented the following appearance:

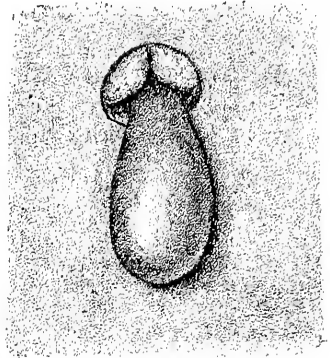


FIG. 70.—A POLYPOID OUTGROWTH FROM THE UMBILICUS. (After Hektoen.)

Histologic examination showed that it was a so-called adenoma of the umbilicus; in other words, remains of the omphalomesenteric duct. For the histologic picture see Fig. 71.

“Projecting from its lower third is a pedunculated, polypoid outgrowth (Fig. 70) 2.5 cm. in length and 3 cm. at its widest circumference, near the rounded, free end. This mass is of a uniform, deep-red color, its surface delicately smooth and velvety, covered with grayish, mucoid shreds. The narrow peduncle is apparently attached to the fibrous structures in the floor of the umbilical depression, as the volume cannot be diminished the slightest by pressure toward the abdominal cavity. In other words, this red mass is not reducible. There is no opening found upon the surface nor depression that might suggest the previous existence of any orifice or canal. The line of junction of the skin with the covering of the peduncle at the bottom of the umbilicus is even and abrupt. The pedicle crowds upward the folds of the integument covering the navel, and it is somewhat compressed as it escapes from the grasp between these folds and the circumference of the umbilicus below, upon which are small but exceedingly sensitive ulcers. The mass itself is not sensitive to the touch, but it bleeds readily, bright

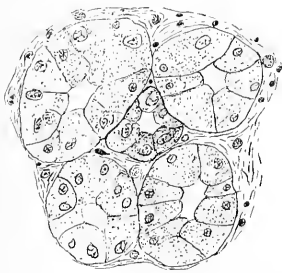


FIG. 71.—TUBULAR GLANDS FROM THE UMBILICAL POLYP SHOWN IN FIG. 70. (After Hektoen.)

These covered the outer surface of the specimen. The growth was evidently a so-called adenoma of the umbilicus.

red blood oozing out when handled a little roughly.

“A diagnosis of a so-called adenoma or diverticular prolapse at the umbilicus was made, a ligature was placed around the pedicle near its attachment, and the polypoid outgrowth was cut away with scissors. No hemorrhage followed. In a week

\* Hektoen, Ludvig: Amer. Jour. Obst., 1893, xxviii, 340.

the ligature fell off, and in a few weeks afterward the little red spot left was completely cicatrized.

"Immediately after its removal the mass was divided into numerous suitable pieces, fixed in Flemming's solution, washed in water, dehydrated in alcohol, embedded in paraffin, and microtomed. The sections thus obtained were stained in various fluids, and the microscopic appearances may be summarily described as follows: There are two principal layers to be taken into account—a peripheral or glandular zone, and an internal central mass consisting of smooth muscular fibers and connective tissue. The surface is lined or covered with tall, symmetrically nucleated, columnar cells without any demonstrable cilia, placed upon an unbroken, quite homogeneous basement membrane. Projecting from this surface are villous, club-shaped masses consisting of loosely meshed connective tissue, in which are many nuclei and small blood-vessels. Between these rather short, club-shaped villi are the openings of the gland tubules, which compose the glandular zone of the outgrowth. The tubules are lined with more or less cuboid epithelial cells, disposed in a single layer, with a tendency to assume the appearance of cylindric cells as the free surface is approached. The tubules terminate in blind extremities which are buried in the intertubular connective tissue deep down in the mass; their lumina are empty; the cells present distinct outlines, a granular protoplasm, and deeply stained nuclei. In many of the cells, both of those lining the tubules and the free surfaces, are seen typical karyokinetic figures in the sections prepared for the purpose of bringing them into prominence." In Fig. 71 is presented a portion of the deeper strata of the glandular zone with the tubules in transverse section. In Hektoen's next figure (which we have omitted) is a portion of the periphery, with a villous projection, which had been cut in a direction somewhat oblique with reference to the main or longitudinal axis of the outgrowth, and this fact will explain the presence in its center of hollow spaces lined with tall columnar cells. The intertubular tissue contains quite a number of blood-vessels of medium size, the majority containing blood; there are also a few foci of round-cell infiltration here and there, suggesting some inflammatory process.

"Internally, to the blind extremities of the tubules and the accompanying intertubular connective tissue, is a zone of smooth muscular tissue whose arrangement cannot be said to follow any definite plan, and in the very center of the whole mass is a quantity of rather firm, fibrillated connective tissue. No lymphatic gland structure was found in any part of the sections examined.

"The microscopic structure of the outgrowth consequently corresponds very closely with the structure of the mucous membrane of the small intestine, with its Lieberkühn follicles or the characteristic cylindric-cell lining of its exterior. The structure of the central part of the mass also reproduces the smooth muscular and the connective tissue found in the wall of the small intestine, although the arrangement of these tissues is not typical of that in the intestine. It is, therefore, plain that the polypoid umbilical outgrowth described is an instance of the so-called diverticular prolapse at the navel, which is somewhat unusual from the fact that, although congenital, it was first brought under observation fifteen years after birth."

On page 344 Hektoen gives excellent pictures of the nuclear division:

A Possible Umbilical Polyp.\* — In a boy, six weeks old, the

\* Henke: Zur Casuistik der vollkommenen Nabel-Darm-Fisteln durch Persistenz des Ductus omphalo-entericus. Deutsche Zeitschr. f. prakt. Med., 1877, iv, 486.

umbilical groove was filled with a fungus-like growth, 1.5 cm. in diameter. It had a glistening red color and was covered with a clear, whitish, sticky secretion. There was a slight erythema around the umbilicus. Nothing abnormal had been noted in the cord at the time of labor, but some days later clear fluid had escaped from the umbilicus and the nodule was detected. Astringents were used and it disappeared. From the history this may have been either an umbilical polyp or granulation tissue.

**A Probable Umbilical Polyp.\***—The boy was four weeks old. Springing from the umbilicus was a pear-shaped tumor, 0.5 cm. long, and divided into three lobes. Where the third lobe joined was a minute opening, from which a drop of white, opalescent fluid could be squeezed. Neither the pedicle nor the tumor bore any resemblance to granulation tissue. They were covered with a bright-red mucous membrane. The nodules were noted soon after the cord came away. They were cauterized and disappeared.

**An Umbilical Polyp.†**—The patient, a healthy boy three years old, had had a small umbilical tumor ever since the cord came away. This had bled severely recently. The umbilicus was prominent. In the umbilical groove was a pea-sized tumor with a dull-red surface. It was attached by a short pedicle and was covered with a mucus-like fluid. It was removed.

Microscopic examination showed that the surface was covered over with mucosa containing Brunner's and Lieberkühn's glands. The central portion consisted of non-striped muscle.

**Remains of the Omphalomesenteric Duct.**—Holmes‡ says that warty or nipple-like tumors projecting from the umbilicus are fairly often seen in children, and that they seem to be due to some morbid condition left by the separation of the umbilical cord. He gives Athol Johnson credit for the first reference to it in the English language. Johnson speaks of the tumor as a stout, nipple-shaped papilla or tubercle arising from the center of the main umbilical depression.

Holmes says that these may attain the height of an inch. He saw several, but none as large as this. They were ligated.

**Umbilical Tumor in an Infant Formed by Prolapse of the Intestinal Mucous Membrane of Meckel's Diverticulum.§**—The patient was seven months old. A bright-red mass,  $\frac{1}{4}$  of an inch in diameter, projected for  $\frac{3}{4}$  of an inch from the bottom of the umbilical cicatrix. This projection was cylindrical and slightly rounded at its extremity. It was pedunculated at its cutaneous attachment. Its surface resembled mucous membrane, and was smooth and shiny. At one point where the epithelium had been rubbed off there was capillary bleeding. The mass was solid, did not protrude more on coughing or crying, and had no opening.

In this case the cord had fallen off on the sixth day and the wound did not heal completely for six weeks. On one occasion there was hemorrhage from the umbilicus. The tumor was discovered six weeks after birth and was quite small. It steadily increased in size in spite of the use of astringents and caustics. From it

\* Henke: *Loc. cit.*

† Hollaendersky, Sara: Zur Kasuistik der Nabeltumoren. Inaug. Diss., Freiburg i. Br., 1905.

‡ Holmes, T.: *Surgical Treatment of Children's Diseases*, London, 1868, 181.

§ Holt, L. E.: *Med. Record*, 1888, xxxiii, 431.

there was a slight watery discharge, but no fecal masses and no fecal odor. The tumor was ligated and cut off.

Its outer surface was covered with mucosa similar to that of the small intestine. Here and there it was slightly necrotic.

Holt gives two good pictures of the condition. He holds that the term adenoma is unfortunate, misleading, and inexact. He credits Küstner with the first accurate description of these growths.

**Umbilical Polyps.**—Hue\* refers to Villar's article, published in 1886, and to that of Le Blanc, published in 1889. He then reports five cases.

**Case 1.**—A child, four years old, had a small tumor at the umbilicus which had been noticed eight days after birth, as soon as the cord came away. In the umbilical scar was a pedunculated tumor the size of a cherry (Fig. 72). The pedicle was fibrous and hard. The tumor was velvety, bright red in color, moist, but did not bleed, and there was no hernia. An elastic ligature was applied with good results.

**Case 2.**—The patient was four and one-half months old. After the cord dropped off, a tumor the size of a pea was noted at the umbilicus. It was red, velvety, and had a pedicle 3 mm. long (Fig. 73). It was ligated satisfactorily.

**Case 3.**—A child, three months old, had a tumor the size of a pea at the umbilicus. It was red and moist, but there was no suppuration. It was cut off with scissors and the child recovered completely.

**Case 4** presented practically the same picture.

**Case 5.**—The child was two years old. The tumor was similar in size and was noted when the cord came away. It was excised. Dévé, who made the microscopic examination (Fig. 74) of the specimen for Hue, found that it was covered with intestinal mucosa. The surface epithelium was cylindric. There were no papillary outgrowths. The glands of the mucosa varied considerably: some resembled Lieberkühn's glands, others those of the pylorus, and still others those of Brunner. Between the glands were lymph-follicles. The pedicle was made up of non-striped muscle and fibrous tissue. The mucosa joined the skin of the abdomen.

**An Umbilical Polyp.** †—The patient was three years old. The mother said that at birth nothing unusual was noted, but about the third week a small tumor made its appearance. The midwife advised the wearing of a bandage, and this had been done. Despite its use, however, there had been a good deal of bleeding from the tumor, which was about as large as a cherry, reddish, and consisted of three lobes implanted directly in the umbilical cicatrix. It looked as if it were covered with mucosa. Its surface was smooth and no orifices were seen. It was resistant

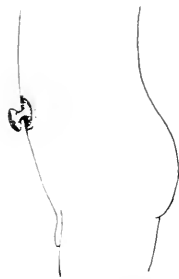


FIG. 72.—DIVERTICULAR TUMOR AT THE UMBILICUS. (From Hue's Case 1.)

A button-like growth protrudes from the umbilicus, being attached by a narrow pedicle.

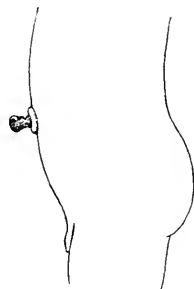


FIG. 73.—A GLANDULAR TUMOR FROM THE UMBILICUS. (From Hue's Case 2.)

Here we have a prominent projection growing from the umbilicus. The pedicle is rather broad.

\* Hue, François: Tumeurs adénoïdes diverticulaires. La Normandie méd., 1906, xxi, 165.

† Kirmisson, E.: Adénome diverticulaire de l'ombilic. Revue d'orthopédie, 1904, xv, 47.



and irreducible. Kirmisson says the diagnosis lay between granuloma and diverticular adenoma. At the same time he points out that a granuloma is softer and appears immediately after the cord comes away. This tumor, on the other hand, was not noted until the end of three weeks; it was firm in consistence, and was apparently covered with mucosa. It was excised without difficulty.

Microscopically, the center of the tumor was found to be composed of connective tissue and muscle; its outer surface was covered with mucosa. At the base of the pedicle the surface for a distance of 2 mm. was covered with squamous epithelium. The mucosa covering the tumor was of the type found in the small in-

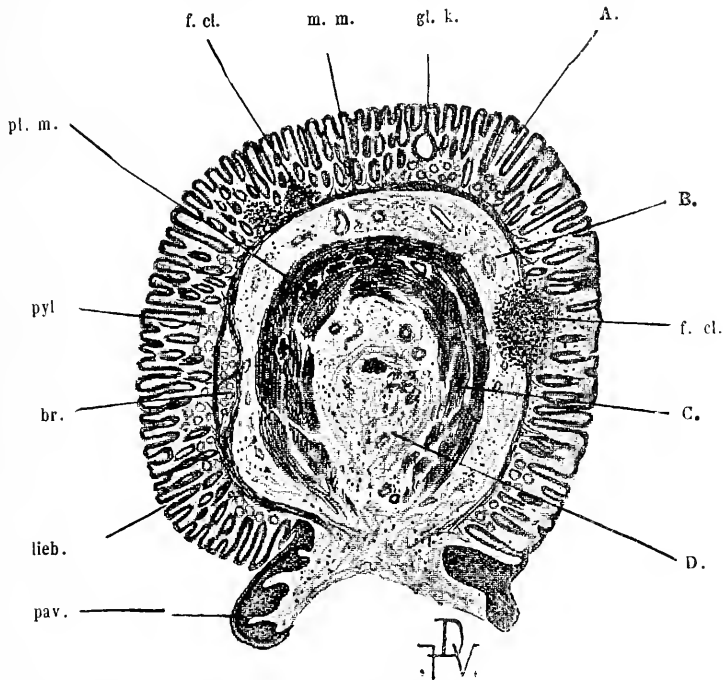


FIG. 74.—A GLANDULAR GROWTH AT THE UMBILICUS. (From Hue's Case 5.)

It is relatively round, and has grown from the umbilicus. Its line of junction with the skin is sharply outlined. *B*, The submucosa; *C*, the muscle; *D*, the cellular tissue. In the center of this is a nerve ganglion. *gl. k.*, a cystic Lieberkühn gland; *m. m.*, muscularis mucosae; *f. cl.*, a closed follicle; *pl. m.*, Auerbach's plexus; *pyl.*, pyloric glands; *br.*, Brunner's glands; *lieb.*, Lieberkühn's glands; *pav.*, the squamous epithelium. The line of junction between the squamous epithelium and the mucosa is sharply outlined.

testine. In Fig. 75 Kirmisson gives us an excellent example of a diverticular adenoma of the umbilicus—an umbilical polyp.

**An Umbilical Polyp.**—Kirmisson\* reports the case of a child eight days old. At the umbilicus was a raised tumor, reddish in color, irregular in form, smooth, and covered with a shiny mucus. This tumor was 4 cm. long and had several purulent pockets on its surface. It presented no orifice and was irreducible. Kirmisson said that it was without doubt of diverticular origin. Its surface was covered with mucosa containing glands.

**Umbilical Polyps.**—Case 1.—In 1871 Kolaczek† reported, in the Jour-

\* Kirmisson: Les tumeurs de l'ombilic. Rev. gén. de clin. et de thérap., Paris, 1907, xxi, 726.

† Kolaczek: Zwei Enteroteratome des Nabels. Langenbeck's Arch. f. klin. Chir., 1875, xviii, 349.

nal of the Pathological Institute of Breslau the following case: A boy four years of age had a small umbilical tumor. The hardened specimen showed a milky outer surface and a reddish center. On microscopic examination its surface was found to be covered with cylindric epithelium, and opening upon the surface were Lieberkühn's glands. Between the glands were lymphatic tissue and connective tissue. The center of the nodule was composed of smooth muscle. Kolaczek thought he was dealing with an enteroteratoma of the umbilicus.

Case 2.—Kolaczek, in 1874, saw a boy eighteen months old who had a cylindric tumor, 8 mm. by 4.5 mm. thick, at the umbilicus. The growth showed a

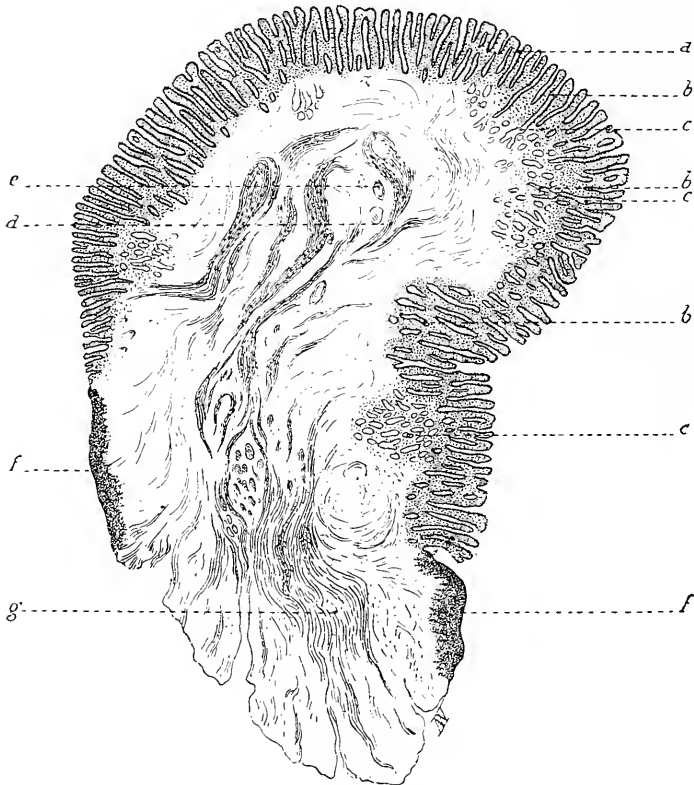


FIG. 75.—SECTION IN THE LONG AXIS OF A SMALL UMBILICAL GROWTH. (After Kirrnisson.)

*a*, The mucosa; *b*, glands of Lieberkühn; *b'*, indicates the superficial portion of the glands which can be traced through their entire length; *c*, the glands in their depth; *c'*, the dichotomous branching noticed in their depth; *d*, the muscular fibers; *e*, the vessels; *f*, squamous epithelium; *g*, the pedicle of the tumor.

small, granulation-like top. It was noted shortly after the cord came away, and was removed with the knife with satisfactory results.

Microscopically the picture was similar to that noted in the first case. There is no doubt that both of these tumors were remains of the omphalomesenteric duct.

An Umbilical Polyp.—Küstner\* says that about a year before he published his article he examined a fungus which had been removed from the umbilicus of a child three months old. He did not expect to find anything but granulation tissue, and was not a little surprised to find, instead of this simple structure,

\* Küstner, O.: Notiz über den Bau des Fungus umbilicalis. Arch. f. Gyn., 1876, ix, 440.

a relatively complicated picture. In the center was connective tissue, and outside of this were round cells and granulation tissue. Embedded in the periphery were numerous tubular glands. The tumor, which was the size of a pea, was covered with beautiful cylindric epithelium.

**Umbilical Polyps.** — Lannelongue and Frémont\* reported three cases.

**Case 1.** — The child was four months old. When the cord came away on the ninth day a small reddish tumor was noted at the umbilicus. It was cauterized with silver nitrate several times, but continued to grow. It was cuboid in form, red in color, firm and irreducible, and measured 8 mm. in diameter. It was cut off. Lannelongue and Frémont give a beautiful plate showing an outer covering of in-

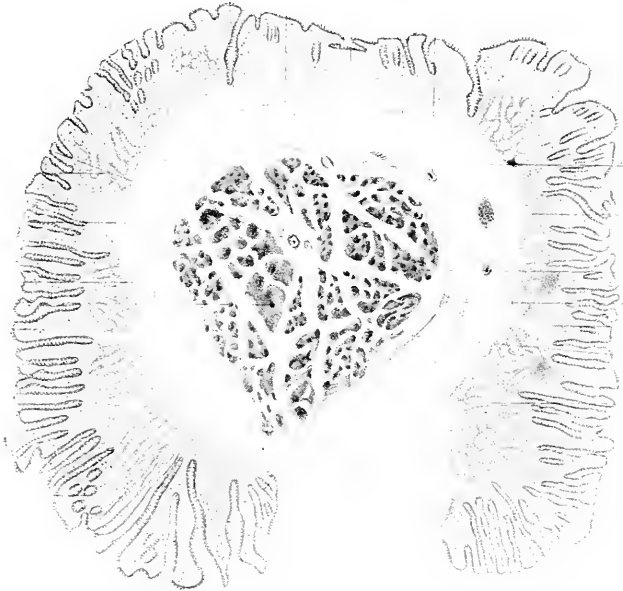


FIG. 76.—ADENOMA OF THE UMBILICUS. (After Lannelongue and Frémont.)

The specimen represents a transverse section through a so-called adenoma of the umbilicus. The central stem is made up of non-striated muscle-fibers cut transversely. Surrounding this is a zone of the fibrous tissue, and the outer surface is covered with a mucosa consisting essentially of glands of the small intestine (from Case 1).

testinal mucosa, and beneath a submucosa. The center was composed of non-striated muscle (Fig. 76).

**Case 2.** — The child was in its ninth month. At labor the cord looked normal, but when it came away on the eighth day there was left at the umbilicus a small tumor, over 1 cm. long and about 1 cm. in diameter. Silver nitrate was used several times without success. On examination the tumor was found to be solid, was bright red, and suggested the mucosa of a prolapsed rectum. It secreted a serous liquid. On one side was a slight depression. When the growth was cut off, a small artery spurted. On microscopic examination it was found to be covered with intestinal mucosa; the center was composed of non-striated muscle.

Their Plates 2 and 3, illustrating this case, are excellent.

\* Lannelongue et Frémont: De quelques variétés de tumeurs congénitales de l'ombilic et plus spécialement des tumeurs adénoïdes diverticulaires. Arch. gén. de méd., 1884, 7<sup>e</sup> sér., xiii, 36.

Case 3. — The record is incomplete, but the microscopic findings were similar to those of the other cases.

An Umbilical Polyp Associated with a Partially Patent Omphalomesenteric Duct.\* — The patient was a boy. On the eleventh day the cord came away and a cylindric tumor, with an elevation the size of one phalanx, was found at the umbilicus. This had a "wild-flesh" appearance, and discharged blood and pus. It was removed with a knife. At once a loop and then a large quantity of the small bowel came out of the wound. The omphalomesenteric duct near the bowel was patent, the lumen measuring 6 mm. in diameter. The opening was sutured, and the abdomen closed. The child made a good recovery. On microscopic examination the polypoid tumor was found covered with mucosa containing Lieberkühn's glands. Its central portion consisted of non-striped muscle.

[In this case there was a patent omphalomesenteric duct, open at its inner end, with slight obliteration in its middle portion; and in addition to this a remnant of the duct in the form of a polyp at the outer end.]

Congenital Umbilical Polyp. † — The boy was three years of age. An umbilical tumor had been noted since birth. It was the size of a small bean, and was bright red in color, soft and fleshy to the touch, perpetually moist, and tended to bleed on manipulation. There was no sinus. It had a narrow pedicle.

On microscopic examination it was found to present the typical appearance. It was covered with mucosa, which contained glands resembling those of Lieberkühn.

An Umbilical Polyp. — In Magnanini's ‡ case there was a small tumor at the umbilicus from which there was persistent hemorrhage. It was diagnosed as an adenoma. It belonged to the class of cases described by Küstner.

Umbilical Polyp. — In Morton's § case the child was seven months old. At the umbilicus was a bright-red, sessile growth, the size of a pea. Silver nitrate was used without effect. Later the growth was ligated and snipped off.

On microscopic examination the surface epithelium was absent, but in the underlying tissue were found Lieberkühn's glands.

Case 2. — The child was "a few years old." At the umbilicus was a red growth the size of a pea. It had a smooth, slightly moist, weeping surface and was pedunculated. Caustics were applied with but little effect. On microscopic examination Lieberkühn's glands were found; they lay in the center, however, instead of on the periphery of the tumor.

Probably an Umbilical Polyp. — Parker, || in his report of cases of excision of the umbilicus for malignant disease, reports the findings in the case of a boy twenty-nine months old. Soon after birth the parents noticed that the navel did not heal. There was a hard mass occupying the place where the cord joins the abdominal wall; and to the right of the cord a naked, non-cicatrized surface, discharg-

\* Löwenstein: Der Darmprolaps bei Persistenz des Ductus omphalomesentericus mit Mittheilung eines operativgeheilten Falles. *Langenbeck's Arch. f. klin. Chir.*, 1894-95, xlix, 541.

† Makins and Carpenter: A Case of Congenital Umbilical Polyp. *Illustrated Med. News*, London, 1889, ii, 268.

‡ Magnanini, N.: Tumor diverticular del ombligo. *Anales del circulo médico Argentino*, 1898, xxi, 449.

§ Morton, Charles A.: The Umbilical Growths of Infants and Young Children. *Pediatrics*, 1896, ii, 409.

|| Parker, Willard: Excision of Umbilicus for Malignant Diseases. *Arch. Clin. Surg.*, New York, 1876-77, i, 71.

ing a thin sanious fluid. This area failed to cicatrize, and the tumor increased in size. When the boy was three years old, an attempt was made to remove the growth, but only part was taken away, as it was found to extend into the abdomen. Fifteen months later the tumor was harder and firmer and increasing in size. An elliptic piece of the abdominal wall, including the tumor, was excised. The child made a good recovery. [Dr. Alonzo Clark, who made the microscopic examination, thought that the growth was cancerous. It was, however, in all probability an adenoma of the abdominal wall.]

**A d e n o m a o f t h e U m b i l i c u s . \***—The patient was a boy three months old. When the cord came away the mother noticed a small moist nodule at the umbilicus. It was the size of a pea, red, uniform, and covered with mucosa. It had no opening and was irreducible. It was removed, and on microscopic examination showed an outer surface of intestinal mucosa with non-striped muscle beneath. It was a typical adenoma. Phocas then gives a résumé of the literature on the subject.

**A n U m b i l i c a l P o l y p . †**—Simpson reported a case which he saw with Dr. Findlay. The excrescence was the size of a cherry, which it likewise resembled in color. It was apparently insensible to touch, but blood oozed from its red surface on slight handling. Silver nitrate was applied to it several times with no effect. After several weeks a ligature was passed around its base, and in a few days it dropped off.

**A n U m b i l i c a l P o l y p . ‡**—A boy twenty-one months old was admitted to Maas's clinic. After the cord came away a prominence, 1.5 cm. high and 5 mm. thick, was noted at the umbilicus. The tumor was reddish and suggested a red granulation, but the color was brighter. It was pedunculated and was noted when the cord came away. It had a slightly nodular surface and was rounded on the end. It was moist and secreted an alkaline fluid. There was no central lumen. It was removed with the cautery.

On microscopic examination it was found to be covered with mucosa containing Lieberkühn's glands. The surface epithelium had evidently been rubbed off. The center was composed of bundles of smooth muscle. It was a remnant of the omphalomesenteric duct.

**A n U m b i l i c a l P o l y p . §**—The patient was twenty years old. At the umbilicus moisture and a reddish, cupped tumor the size of a cherry were detected. Its surface was irregular and lobulated, and it was covered with a viscid secretion. It was removed.

Microscopically it resembled an adenoma, but Stori considered it a papillo-adenoma originating at the umbilicus from remains of the omphalomesenteric duct.

**A n U m b i l i c a l P o l y p . ||**—Tikhoff, in his Fig. 44, shows a polypoid projection from the umbilicus, and in Fig. 46, accompanying his article, the typical picture of an adenoma covered over with intestinal glands. The description of this case is in Russian.

\* Phocas: Adénomes de l'ombilic. Nord médical, 1898, iv, 52.

† Simpson, J. Y.: Obstetric Memoirs and Contributions, Philadelphia, 1856, ii, 423.

‡ Steenken, C.: Zur Casuistik der angeborenen Nabelgeschwülste. Inaug. Diss., Würzburg, 1886.

§ Stori, Teodoro: Contributo allo studio dei tumori dell'ombelico. Lo Sperimentale Archivio di biologia normale e patologica, 1900, liv, 25.

|| Tikhoff, P.: Khirurg. lyetop., Mosk., 1893, iii, 581.

**An Umbilical Polyp.**—Villar\* reports the case of an infant, four months old, who was admitted to the service of Nicaise in December, 1885. The report was communicated to him by Le Roy. Since birth this child had presented at the umbilicus a small, reddish elevation which had never changed much in volume. Nothing unusual was detected in the cord, but the mother noticed this little mass just as soon as the cord came away. The child had never had any intestinal trouble. At the umbilical cicatrix was a tumor the size of a small pea. It was spheric, and attached to the umbilical depression by an extremely short pedicle. It was dark red, smooth, and irreducible. It was removed.

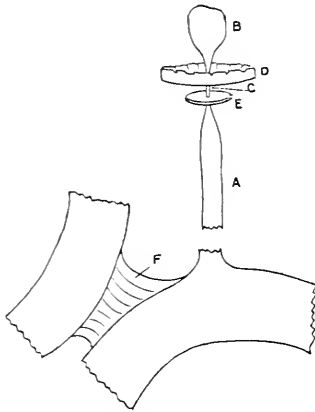


FIG. 77.—AN UMBILICAL POLYP ATTACHED TO MECKEL'S DIVERTICULUM BY A FIBROUS CORD. (After Walther.)

A, Meckel's diverticulum; B, adenoma of the umbilicus; C, the fibrous cord; D, the skin; E, aponeurosis; F, a serous band uniting the loop of small bowel from which the fistula springs with another loop of small bowel.

tumor. He refers to two of these cases, reported by Maunoir and Lawton.

**An Umbilical Polyp Associated with Meckel's Diverticulum, which was Attached to the Umbilicus by a Fibrous Cord.** ‡—A youth, eighteen years old, had a tumor at the umbilicus the size of a large cherry. It was about 2.5 cm. long and 2 cm. broad, was red, velvety, moist, and resembled intestinal mucosa. It was connected with the umbilicus by a pedicle. It secreted a serous fluid which became slightly purulent on account of irritation from the clothes. The skin in the vicinity was red and erythematous. There was no trace of an umbilical hernia. The boy had had this tumor since birth. It had grown very little.

An elliptic incision was made around the umbilicus, and it was found that this polyp was connected with Meckel's diverticulum by a solid fibrous cord (Figs. 77 and 78). Recovery took place.

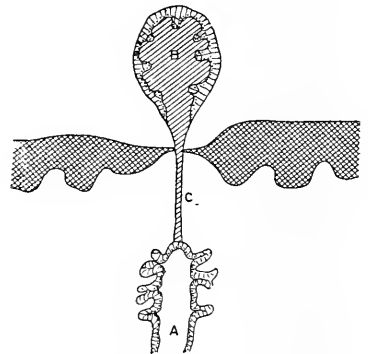


FIG. 78.—AN UMBILICAL POLYP ATTACHED TO MECKEL'S DIVERTICULUM BY A FIBROUS CORD. (After Walther.)

A, Meckel's diverticulum; B, adenoma of the umbilicus; C, fibrous cord. The transverse dark area indicates the abdominal wall.

\* Villar, Francis: Tumeurs de l'ombilic. Thèse de Paris, 1886, No. 19, obs. 28.

† Virchow, R.: Die krankhaften Geschwülste, 1862-63, iii, erste Hälfte, 467.

‡ Walther, C.: Tumeur adénoïde de l'ombilic et diverticule de Meckel. Revue d'orthopédie, 1904, xv, 23.

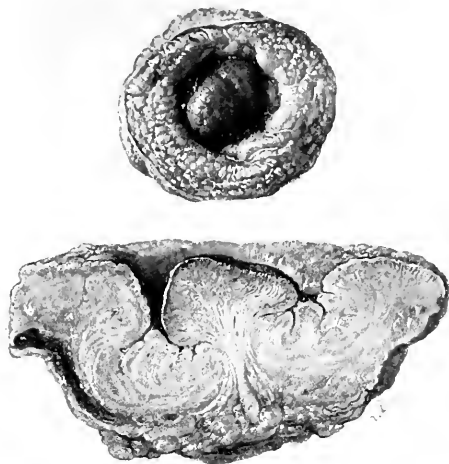
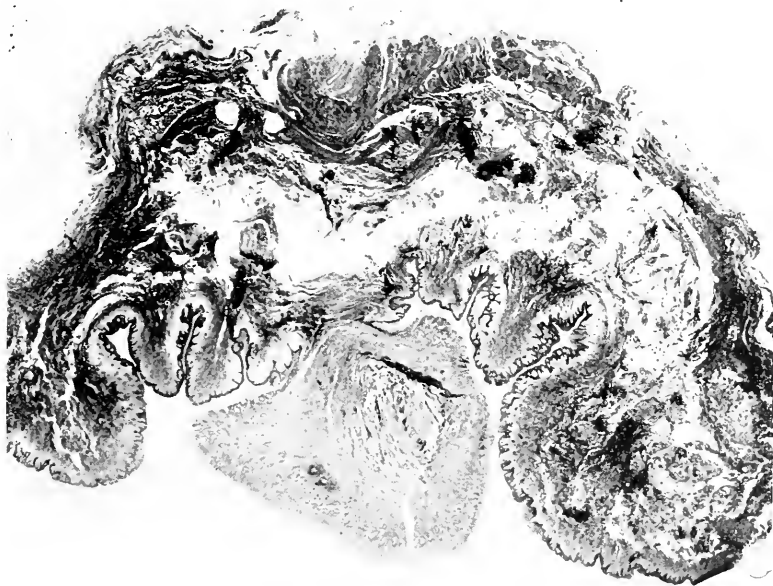

FIG. 79.—UMBILICAL POLYP.

Gyn.-Path. No. 16866. (Specimen sent by Dr. E. W. Meredith, of Pittsburgh. The patient was a young adult.) The upper picture shows the umbilicus with the smooth nodule springing from the umbilical depression. This nodule was covered with intestinal mucosa. The lower picture is twice the natural size, and shows the relation of the polyp to the umbilicus on cross-section. The mucous surface of the polyp merges directly with the skin surface of the umbilical depression. The center of the polyp consisted of non-striated muscle. For the low and high power pictures of the polyp see Figs. S0, S1, and S2.

FIG. S0.—A SMALL INTESTINAL POLYP ALMOST FILLING THE UMBILICAL DEPRESSION. ( $\times 5$  diam.)

The section is through Fig. 79. The squamous epithelium covering the umbilical depression is clearly visible, and beneath it one finds the rarefied stroma. The polyp is covered over with intestinal mucosa, which in the specimen is rather hazy. The dark areas in the polyp are aggregations of small round cells or lymph cells. For the higher power picture see Fig. S2.

Microscopic Examination.—The umbilical nodule was surrounded by inflamed skin. The nodule was covered with intestinal mucosa. The surface was necrotic. A cord consisting of fibrous tissue connected the polyp with Meckel's diverticulum.

#### A PERSONAL OBSERVATION.

An Umbilical Polyp in an Adult.—On October 7, 1911, I received the following from Dr. E. W. Meredith, from St. Margaret's Memorial Hospital, Pittsburgh, Pa.:

"I am forwarding to you a specimen of an 'Umbilical Tumor.' The patient is a healthy young man, twenty years of age. The tumor had been present since birth, was brilliant red in color, and secreted a clear mucoid fluid.

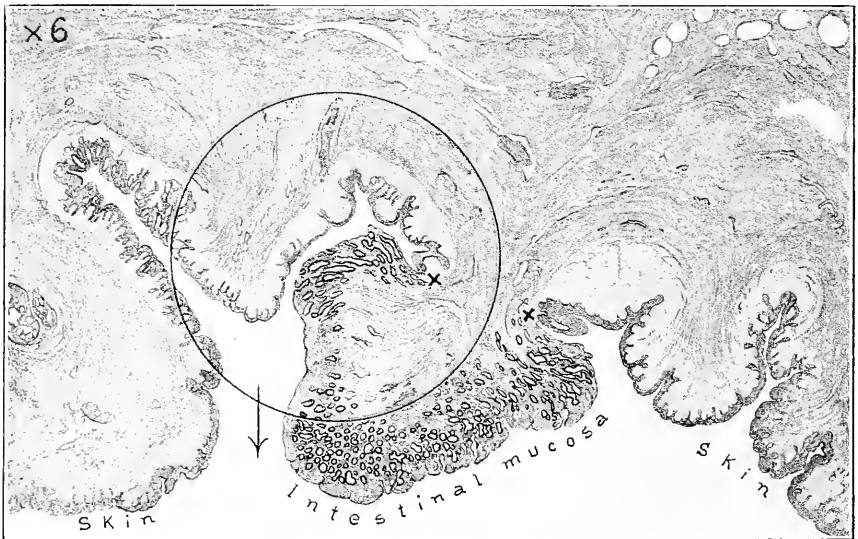

FIG. 81.—AN UMBILICAL POLYP.

Gyn.-Path. No. 16866. The photomicrograph (Fig. 80) gives the general relation of the polyp, but naturally lacks somewhat in detail. Mr. Brödel has given us a very clear drawing of the low-power findings. The polyp is covered with typical intestinal mucosa. The confines of the pedicle are indicated by X. It consisted in a large measure of non-striated muscle. The mucosa covering the polyp ends abruptly where the squamous epithelium of the umbilical depression begins. The squamous epithelium at some points is much thickened. Here the papillae are elongated. The area indicated by the circle has been enlarged and is shown in Fig. 82.

"It was largely on account of the constant moisture about the umbilicus that the patient sought operative relief. At the operation the umbilicus with its central tumor was removed, and a small opening made into the peritoneal cavity to explore the under surface of the umbilicus. This was found to be smooth and free of any adhesions. I have made a provisional diagnosis of an adenoma of omphalomesenteric duct origin."

Gyn.-Path. No. 16866.—The specimen consists of the umbilicus and of a small amount of the surrounding tissue. The umbilical opening is spheric, has a slightly undulating surface, and is about 1.3 mm. in diameter. Occupying the greater portion of the umbilical depression is a rounded polypoid growth. This has a smooth surface, is translucent, and reminds one in the hardened state of a section through intestinal mucosa (Fig. 79). The umbilicus was cut in two, and



it was found that this tumor sprang from the umbilical depression and had a fairly broad base (Fig. 80). Its surface was directly continuous with the skin surface of the umbilical depression.

**Histologic Examination.**—Numerous sections were made through the umbilicus and the growth. The skin covering the umbilicus in the outer portion of the section is perfectly normal (Figs. 81 and 82). As one approaches the umbilical polyp the squamous epithelium becomes somewhat thinner, but pro-

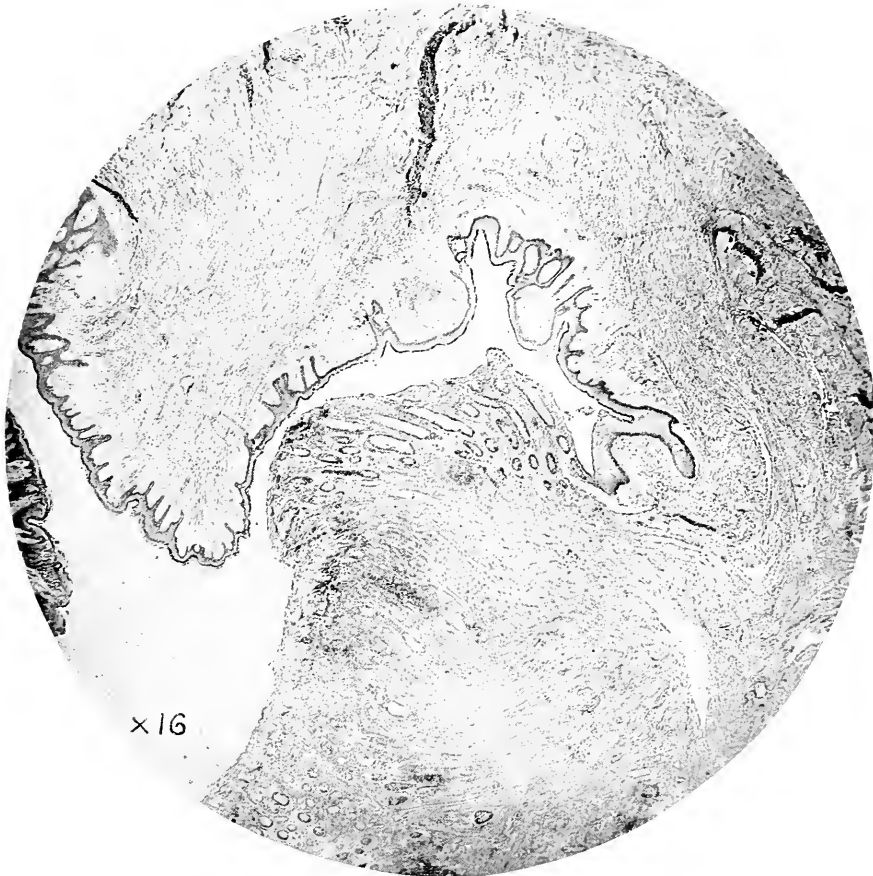

FIG. 82.—PORTION OF AN INTESTINAL POLYP PARTIALLY FILLING THE UMBILICAL DEPRESSION. ( $\times 16$  diam.)

In the upper part of the picture is seen the squamous epithelium, which is practically normal. The stroma beneath it shows much rarefaction. The squamous epithelium ends abruptly at the margin of the polyp, which consists of intestinal mucosa. The surface of the polyp consists almost entirely of granulation tissue due to irritation from the clothing.

longations of the epithelium are continued for a considerable distance into the depth. The squamous epithelium ends abruptly where the polyp begins. The stroma beneath the squamous epithelium near the umbilicus is normal, but nearer the umbilical depression there is a marked change; the stroma immediately beneath the squamous epithelium becomes rarefied, takes the bluish stain instead of the pink, and reminds one very much of myxomatous tissue. Scattered throughout it are a moderate number of small round cells.

The polyp filling the umbilical depression is covered over with intestinal mucosa. Where the squamous epithelium ends, the mucosa commences, or the squamous epithelium in some places slightly overlaps the intestinal mucosa. The mucosa resembles in almost every particular that of the small intestine. In the more prominent portions of the polyp, however, the surface epithelium has disappeared and fibrin covers the surface. The tissue immediately beneath shows many dilated capillaries; there is much small-round-cell infiltration and a moderate number of polymorphonuclear leukocytes. The intestinal glands are, however, seen opening directly on the surface, and the inflammatory reaction, without doubt, has been caused by exposure of the polyp to irritation from the clothing. The stroma forming the central portion of the polyp consists in large measure of smooth muscle-fibers. Here and there in the muscle, and also directly beneath the mucosa, are clumps of small round cells.

We have here a definite intestinal polyp originating from a remnant of the outer portion of the omphalomesenteric duct. The low-power picture of the entire umbilical growth is seen in Fig. 81. With the higher magnification the line of junction between the squamous epithelium of the umbilical depression and the intestinal mucosa is clearly seen in Fig. 82. Here also the rarefied condition of the stroma beneath the squamous epithelium is clearly visible.

#### LITERATURE CONSULTED ON UMBILICAL POLYPS.

- Ball, C. B.: Case of Umbilical Polyp. *Illustrated Med. News*, 1889, iv, 149.
- Bidone, E.: Enteroteratoma ombelicale. *Bull. delle scienze med., Bologna*, 1901, ser. 8, i, 374.
- Blanc et Weil: *Soc. anat. de Paris*, 1899. *Rev. in Centralbl. f. allg. Path. u. path. Anat.*, 1900, xi, 748.
- Blanc, H.: Contribution à la pathologie du diverticule de Meckel. *Thèse de Paris*, 1899, No. 393.
- Booker, W. D.: Personal communication.
- Broca, A.: Polype de l'ombilic. *Jour. de méd. et de chir.*, 1904, lxxv, 172.
- Brun, L. A.: Sur une espèce particulière de tumeur fistuleuse stercorale de l'ombilic. *Thèse de Paris*, 1834, No. 238.
- Capette et Gauckler: Note sur un cas d'adénome ombilical. *Revue d'orthopédie*, 1903, xiv, 271.
- Colman, W. S.: Adenomatous Polypus of Umbilicus. *Trans. Path. Soc. London*, 1888, xxxix, 110.
- Diwawin, L. A.: Ein Fall von Enteroteratom des Nabels. *Russ. med. Rundschau*, 1904, ii, 590.
- Fabrège: Note sur les excroissances polypeuses de la fosse ombilicale chez les enfants nouveaux-nés. *Revue médico-chir.*, 1848, iv, 353.
- Fox and MacLeod: Remains of the Omphalomesenteric Duct at the Umbilicus Giving Rise to Paget's Disease. *Brit. Jour. Dermatol.*, 1904, xvi, 41.
- von Gernet, R.: Ein Entero-teratom. *Deutsche Zeitschr. f. Chir.*, 1894, xxxix, 467.
- Giani, R.: Per la casistica degli entero-teratomi dell'ombelico. *Clinica Moderna*, 1902, viii, 498.
- Gould, A. P.: A Congenital Mucous Polypus of the Umbilicus. *Trans. Path. Soc. London*, 1881, xxxii, 204.
- Hartmann: Occlusion intestinale par un canal omphalo-mésentérique persistant. *Bull. et Mém. de la Soc. de chir. de Paris*, 1898, n. s., xxiv, 203.
- Hektoen, L.: Vitelline Duct Remains at the Navel. *Amer. Jour. Obst.*, 1893, xxviii, 340.
- Henke: Zur Casuistik der vollkommenen Nabel-Darm-Fisteln durch Persistenz des Ductus omphalo-entericus. *Deutsche Zeitschr. f. prakt. Med.*, 1877, iv, 486.
- Hollaendersky, Sara: Zur Kasuistik der Nabeltumoren. *Inaug. Diss., Freiburg i. Br.*, 1905.
- Holmes, T.: Surgical Treatment of Children's Diseases, London, 1868, 181.
- Holt, L. E.: Umbilical Tumor in an Infant Formed by Prolapse of the Intestinal Mucous Membrane of Meckel's Diverticulum. *Med. Record*, 1888, xxxiii, 431.
- Hue, François: Tumeurs adénoïdes diverticulaires. *La Normandie médicale*, 1906, xxi, 165.

- Kirmisson, E.: Adénome diverticulaire de l'ombilic. *Revue d'orthopédie*, 1904, xv, 47.
- Kirmisson: Les tumeurs de l'ombilic. *Rev. gén. de clin. et de thérap.*, Paris, 1907, xxi, 726.
- Kolaczek: Zwei Enteroteratome des Nabels. *Langenbeck's Arch. f. klin. Chir.*, 1875, xviii, 349.
- Küstner, O.: Notiz über den Bau des Fungus umbilicalis. *Arch. f. Gyn.* 1876, ix, 440; also *Virchows Arch.*, lxi, 286.
- Lannelongue et Frémont: De quelques variétés de tumeurs congénitales de l'ombilic et plus spécialement des tumeurs adénoïdes diverticulaires. *Arch. gén. de méd.*, 1884, 17. sér., 13, 36.
- Löwenstein: Der Darmprolaps bei Persistenz des Ductus omphalomesentericus, mit Mittheilung eines operativ geheilten Falles. *Langenbeck's Arch. f. klin. Chir.*, 1894-95, xlix, 541.
- Makins and Carpenter: A Case of Congenital Umbilical Polyp. *Illustrated Med. News*, London, 1889, ii, 268.
- Magnanini, N.: Tumor diverticular del Ombligo. *Anales del círculo médico Argentino*, 1898, xxi, 449.
- Morton, Charles A.: The Umbilical Growth of Infants and Young Children. *Pediatrics*, 1896, ii, 409.
- Parker, Willard: Excision of Umbilicus for Malignant Diseases. *Arch. Clin. Surg.*, New York, 1876-77, i, 71.
- Pernice, L.: Die Nabelgeschwülste, Halle, 1892.
- Phocas: Adénomes de l'ombilic. *Nord médical*, 1898, iv, 52.
- Sheen, W.: Some Surgical Aspects of Meckel's Diverticulum. *Bristol Medico-Chir. Jour.*, 1901, xix, 312.
- Simpson, J. Y.: *Obstetric Memoirs and Contributions*, Philadelphia, 1856, ii, 423.
- Steenken, C.: Zur Casuistik der angeborenen Nabelgeschwülste. *Inaug. Diss.*, Würzburg, 1886.
- Stori, Teodoro: Contributo allo studio dei tumori dell'ombelico. *Lo Sperimentale Archivio di biologia normale e patologia*, 1900, liv, 25.
- Tikhoff, P.: Case of anomalous prolapse of omphalomesenteric duct. *Khirurg. Iyotop.*, Mosk., 1893, iii, 581-594. 1 pl.
- Villar, Francis: Tumeurs de l'ombilic. *Thèse de Paris*, 1886, No. 19.
- Virchow, R.: Die krankhaften Geschwülste, 1862-63, iii, erste Hälfte, 467.
- Walther, C.: Tumeur adénoïde de l'ombilic et diverticule de Meckel. *Revue d'orthopédie*, 1904, xv, 23.

## CHAPTER VII.

### CONGENITAL POLYPS; FISTULÆ OR CYSTIC DILATATIONS AT THE UMBILICUS; WITH A MUCOSA MORE OR LESS SIMILAR TO THAT OF THE PYLORIC REGION OF THE STOMACH, AND SECRETING AN IRRITATING FLUID BEARING A MARKED RESEMBLANCE TO GASTRIC JUICE. PERSISTENCE OF THE OUTER PORTION OF THE OMPHALOMESENTERIC DUCT.

So-called gastric mucosa at the umbilicus.

General consideration.

Macroscopic appearance.

Microscopic picture.

The fluid secreted by the polyp or fistula.

Action of the fluid on the skin surrounding the umbilicus.

Symptomatology.

Origin.

Treatment.

Report of cases of congenital polyp or fistula at the umbilicus and having a mucosa resembling that of the stomach.

Persistence of the outer portion of the omphalomesenteric duct.

Report of cases in which the outer end of the omphalomesenteric duct remained patent.

TILLMANN'S, in 1882, made a most interesting observation on a boy thirteen years old. On questioning the parents it was learned that the umbilical cord was unusually thick, and that it had dropped off on the fourth day, leaving a tumor the size of a cherry. This grew slowly. When Tillmanns saw it, it was the size of a walnut, bright red in color, and covered with mucosa (Fig. 87). It had no central opening. It was attached to the umbilical depression by a thin pedicle. After the boy had eaten, the tumor would sometimes swell perceptibly; it would become redder, and its mucosa thicker.

This umbilical tumor secreted a tenacious mucus, which was especially abundant when the tumor was irritated. At such times 2 to 3 c.c. of fluid could be collected in fifteen minutes. The discharge was so copious that it was necessary to wear dressings, and even then it would at times saturate the boy's clothes.

The fluid secreted was acid, but when old, it became alkaline. The fluid digested fibrin in an acid solution at 39° C. A chemical examination, made by Dreschel, showed that it corresponded more or less closely with gastric juice.

Microscopic examination of the tumor revealed the fact that the mucosa was similar to that of the stomach.

The digestive action of the fluid secreted by this tumor had caused a maceration of the abdominal skin surrounding the umbilicus. The pedicle of the tumor was severed, and the wound soon healed (Fig. 88). No connection with the abdominal cavity was found.

The literature on this subject is rather scanty, but several subsequent observers have reported mucosa at the umbilicus that bore more or less resemblance to stomach mucosa. Cases have been recorded by Roser (1887), Siegenbeek van Heukelom

(1888), von Rosthorn (1889), Reichard (1898), Weber (1898), Lexer (1899), Strada (1903), Minelli (1905), and Denucé (1908).

#### MACROSCOPIC APPEARANCE OF THE UMBILICAL REGION.

In the majority of the cases the umbilical abnormality was observed just as soon as the cord had dropped off. The local picture varies considerably. It may be roughly classified as follows:

1. An umbilical polyp attached to the umbilical depression by a short pedicle.
2. An umbilical polyp with a cystic cavity opening on the surface of the polyp.
3. An umbilical fistula with or without a small projection.

The umbilical polyp in van Heukelom's case, and also in Reichard's case, was the size of a hazel-nut; and in Minelli's, Strada's, and Tillmanns' cases the tumor was considerably larger.

Roser's patient, a boy a year and a half old, had a bright-red swelling at the umbilicus, and opening on the surface of it was a cystic cavity 1 cm. in diameter.

In Denucé's, Lexer's, von Rosthorn's, and Weber's cases there was seen at the umbilicus a fistulous tract which extended directly inward for a distance of 1.5 to 2 cm.

In Lexer's case no nodule was found at the umbilicus, but in the other cases the cutaneous end of the fistula had raised margins, producing a small red thickening.

Where a polyp exists, it is bright red in color, covered with mucosa, and is attached to the umbilical depression by a definite pedicle. In those cases in which a fistula exists, and where it is wide enough to allow one to see its inner surface, it is found lined with mucosa.

#### THE MICROSCOPIC PICTURE.

The surface of the polyp is covered with mucosa, the glands of which resemble more or less closely those found at the pyloric end of the stomach. In certain cases, some of the glands look more or less atrophic. At times both Lieberkühn's glands and also pyloric glands have been noted in the mucosa.

The central portion of these polyps consists of non-stripped muscle, and occasionally a little adipose tissue is present.

The fistulae are lined with mucosa, which is for the most part similar to that of the pyloric region, but here also the mucosa at one point may contain Lieberkühn's glands, and at another, pyloric glands. This was particularly well shown in von Rosthorn's case. The outer walls of the fistulous tract are composed of non-stripped muscle.

#### THE FLUID SECRETED BY THE POLYP OR FISTULA.

The polyp or fistula, as the case may be, secretes a fluid which may be watery, clear, and stringy, or cloudy and tenacious. The amount varies greatly. In Denucé's case, 3 c.c. were secreted in thirty-six hours; in von Rosthorn's case, 5 c.c. were discharged in twenty-four hours, while in Tillmanns' case 2 to 3 c.c. were collected in fifteen minutes. In Weber's case the father estimated that half a wineglassful came away daily; so abundant was the flow that the child's clothes were soaked.

In Denucé's case, as soon as the child commenced to eat, the flow increased, and Tillmanns drew attention to the fact that irritation of the tumor in his case caused an abundant secretion.

The fluid is usually acid. In Weber's case, however, it was alkaline. In Tillmanns' case the fresh fluid was acid, but after it had been kept for some time it became alkaline.

Lexer said that in his case the fluid chemically resembled gastric juice. The fluid in Tillmanns' case digested fibrin in an acid solution at 39° C., and Drechsel found that it corresponded to gastric juice.

Von Jaksch made a careful chemical examination of the fluid in von Rosthorn's case, and found albuminous bodies, peptone, pepsin in small quantities, but no free hydrochloric acid. Denucé found free hydrochloric acid and peptone, but no pepsin. He describes the fluid as a "sort of gastric juice."

From these findings it is clear that the fluid secreted in these cases bears a strong resemblance to gastric juice.

**Action of the Fluid on the Skin Surrounding the Umbilicus.**—In von Rosthorn's case the abdominal wall around the umbilicus was slightly irritated.

In Tillmanns' case the skin in the vicinity of the polyp was macerated. In Denucé's case the skin surrounding the fistula was ulcerated for a certain distance. This ulcerated area was bright red in color, and the tissue surrounding it was tumefied. The total area of ulceration was about the size of a five-franc piece.

In Reichard's case, commencing just below the fistula and extending downward 6 cm. toward the pubes, was "a digestive ulcer" which had indurated margins. The ulceration was situated just where the fluid from the fistula trickled down the abdominal wall. The patient was a child five years old. He was able to walk around; hence the fluid flowed downward instead of irritating the parts all around the umbilicus.

Weber's patient was a boy three years old. Four months before coming under observation a canal-shaped wound developed. This commenced at the umbilicus and extended 4 cm. downward toward the symphysis. It was increasing in size and had callous walls. The umbilicus itself and the surrounding tissue over an area the size of the palm of the hand were markedly macerated. The umbilical region presented the typical picture of a digestive process.

The action of the fluid alone would make one strongly suspect the presence of gastric juice.

#### SYMPTOMATOLOGY.

These polyps or fistulae are more common in males than in females. They are congenital, and accordingly are usually noted at, or shortly after, the time the cord comes away. They are recognized by the appearance of a small red polyp or fistula at the umbilicus. The secretion from the navel varies in amount, is usually acid in reaction, and tends to increase at meal-times or when the polyp is mechanically irritated. In at least half of the cases there is more or less digestion of the abdominal wall in the umbilical region. This digestive action clearly differentiates these from ordinary umbilical polyps, and suggests the presence of mucosa identical with or strongly resembling that of the stomach.

#### ORIGIN.

Considerable speculation has been rife as to the origin of these so-called gastric polyps or fistulae. Naturally the easiest explanation would be that in embryonic life there has occurred a displacement of patches of gastric mucosa.

In Denucé's case the fistulous tract was removed without any opening into the peritoneum. The peritoneum was transparent, and it was possible to see a little to the left of the deep attachment of the fistula a cylindric cord, which passed from the umbilicus to a loop of bowel. This cord was evidently the remnant of the omphalomesenteric duct.

In Reichard's case the abdomen was opened and the tumor found to be cystic, bluish, and translucent. Sharply defined and passing from it was a very thin pedicle, which extended upward in the abdominal cavity. Further examination could not be made on account of the weak condition of the child.

Weber, in removing the umbilical fistulous tract in his case, opened the peritoneum. From the fistulous tract a thin cord passed upward and led to the under surface of the liver. He thought that this cord represented the remains of the umbilical vein.

We have no positive evidence in any of the cases that the umbilical growth was connected with the stomach. On the other hand, it is quite probable that in one of them it was connected with the small bowel by a fibrous cord.

Judging from the embryologic development of the umbilical region, one would naturally conclude that such growths are remnants of the omphalomesenteric duct. Furthermore, we learn, from the microscopic descriptions of the fistulæ, that in some parts the glands resembled intestinal glands; in other places glands of the pyloric region. Again, in Lexer's case (Fig. 85) the fistulous tract was almost continuous with a patent Meckel's diverticulum. The fistula was lined with what resembled a gastric mucosa; the Meckel's diverticulum, with a mucosa similar to that of the small bowel.

As is well known, the entire digestive tract develops from the yolk-sac. It has been claimed that, prior to the passage of the various fluids, such as bile and pancreatic fluid, over the intestinal mucosa, it is identical with or bears a strong resemblance to that of the stomach. Be that as it may, it is certain that we have a small group of cases in which polyps or fistulæ have developed at the navel, and that these are covered or lined with a mucosa that histologically closely resembles gastric mucosa; and that this mucosa secretes a juice that acts very much as gastric juice will do. Personally, I believe that these growths are remnants of the omphalomesenteric duct.

#### TREATMENT.

Where a polyp exists, it is only necessary to tie the pedicle and cut off the growth. In those cases in which a fistula exists, the umbilicus should be encircled, the abdomen opened, and the growth removed. If it be connected with the bowel, the intestinal stump should be treated as an appendix stump. In those cases in which much maceration exists, local alkaline applications should be employed until the skin is healthy, after which removal of the growth can be readily carried out.

#### CASES OF CONGENITAL POLYPS OR FISTULÆ AT THE UMBILICUS AND HAVING A MUCOSA RESEMBLING THAT OF THE STOMACH.

A Pseudopyloric Congenital Fistula at the Umbilicus.—Denucé\* speaks of a rare variety of fistula occurring at the umbilicus.

\* Denucé: *Fistules pseudo-pyloriques congénitales de l'ombilic*. *Revue d'orthopédie*, 1908, xix, 1.

A secretion is present, which gives an acid reaction, and on chemical examination is found to be practically identical with gastric juice. Moreover, the digestive action of this fluid manifests itself on the tissues surrounding the fistula. Histologic examination shows that the structure of the mucosa lining the fistulous tract is exactly similar to that of the stomach and the pyloric region.

Denucé saw a case of this character in the surgical clinic at Bordeaux, and the diagnosis was made before operation. The patient, a boy twenty-one months old, was admitted to the hospital on account of a congenital umbilical fistula. The umbilical cord in its outer aspect showed nothing abnormal at birth. When it came away, there was left what appeared to be a granulation at the umbilicus. This was cauterized. There was a discharge, which at first was slight, but later at times became very abundant. The fluid, as a rule, was colorless, but sometimes it had a hemorrhagic tint.

On admission the child's general condition was poor; the fistulous tract was painful. Methylene-blue was administered, but none was discharged from the fistula, showing that the latter was not urinary in character. Urination was normal. Digestion was normal and the bowels moved regularly. At the umbilicus was a small orifice from which there came a liquid discharge. The surrounding skin was ulcerated for some distance. This ulcerated area had a bright-red color, and the tissue around it was tumefied. At the summit of the ulceration was a fistulous orifice. The total area of ulceration at the umbilicus was about the size of a five-franc piece. A probe could be introduced into the fistula for about 1.5 cm. The fluid, when first examined, was clear, but when the child started to eat, there was an immediate increase in the quantity of the discharge from the umbilicus. In about thirty-six hours 3 c.c. of liquid were secured. An analysis of this fluid gave the following:

Glucose.....	0
Sulphocyanid.....	0
Albumin.....	+
Lactic acid.....	0
Free hydrochloric acid.....	+
Peptone.....	+
Lab ferment.....	0
Pepsin.....	0

Further examination of the "gastric juice" from the same patient showed an estimated total acidity of 2.4 gm. to the liter. The presence of free hydrochloric acid, peptone, and lab ferment was detected. The conclusions drawn were that this liquid might be considered as a sort of gastric juice.

The fistulous tract was removed without any opening into the peritoneum. The peritoneum was transparent, and it was possible to see a little to the left of the deep portion of the fistula the attachment of a cylindric cord, which, at its inner extremity, was inserted into one of the intestinal loops. It was easily recognized that this cord represented Meckel's diverticulum, which, at its distal extremity, was attached to the umbilicus. The umbilical fistula was ligated at its base and burned off with the thermocautery. The child made a good recovery.

Sections through the fistulous tract showed a mucous structure analogous to that of the stomach. Fig. 83 represents a transverse section of the fistulous tract. Owing to the presence of the villus-like projections the general appearance of this



tract reminds one somewhat of the Fallopian tube projections. The cavity contained granular remains, and round or oval cells. The fistula might be described as a sort of small cul-de-sac lined with a kind of gastric mucosa. Denucé speaks of this case as an instance of pseudopylorus, and says such cases are exceedingly rare. He then goes on to discuss the cases of Tillmanns and Roser, and considers the various hypotheses as to the origin of these fistulae. In young embryos, he points out, the intestinal tract is lined with epithelium which is the same throughout, and the differentiation between the epithelium of the stomach and that of the intestine is a later development.

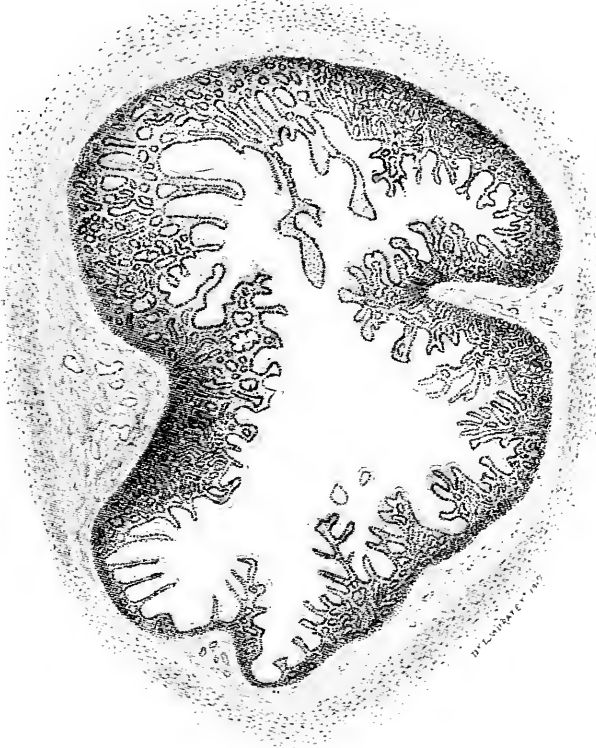


FIG. 83.—TRANSVERSE SECTION OF A PSEUDOPYLORIC CONGENITAL FISTULA AT THE UMBILICUS. (After Denucé.) The mucosa resembled somewhat that of the intestine, somewhat that of the stomach. The finger-like and papillary outgrowths are, however, unusually long. For the appearances under the high power see Fig. 84.

**Gastric Mucosa in a Persistent Omphalomesenteric Duct.**—Lexer\* says there is a small group of cases which, on account of their individual structure and the character of the mucous lining, are obscure. These cases have a mucosa that not only closely resembles that of the pyloric region but also secretes a fluid resembling gastric juice. He then refers to the cases of Tillmanns and Siegenbeek van Heukelom.

Lexer's patient was one year old. It had a congenital umbilical fistula, and the surrounding skin was eroded. The fluid which was collected for several hours was clear, stringy, contained no intestinal contents, was strongly acid, and chemically

\* Lexer: Magenschleimhaut im persistirenden Dottergang. Langenbeck's Arch. f. klin. Chir., 1899, lix, 859.

resembled stomach juice. It rapidly digested albumen (fibrin). At operation the fistulous tract was found attached to the convexity of the small bowel (Fig. 85). It closed at a point 1.5 cm. behind the umbilicus. Meckel's diverticulum was lined with intestinal mucosa, but that of the umbilical portion of the fistula was totally different, consisting of what Lexer termed pseudopyloric mucous membrane. The cylindric epithelium lining the outer portion of the fistula was high, and the mucosa itself resembled that of the pylorus, but was drawn out into finger-like projections.

According to Lexer, the picture as a whole demonstrated the persistence of the omphalomesenteric duct, the outer portion of which differed entirely from that communicating with the bowel. This variation in type, he thought, is probably due to an early severance of the outer portion of the fistulous tract from the inner portion.

An Umbilical Polyp.—Minelli\* gives a low-power picture showing a tumor which suggested an adenoma of the umbilicus. He then gives a résumé of the liter-

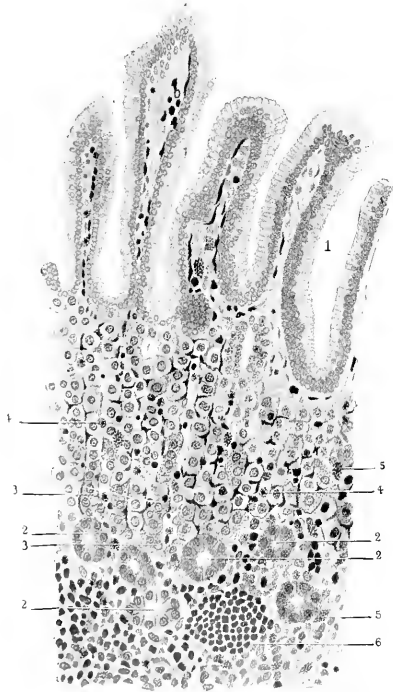

FIG. 84.—HIGH-POWER PICTURE OF A FISTULOUS TRACT AT THE UMBILICUS, SHOWING GLANDS RESEMBLING THOSE OF THE PYLORUS. (After Denucé.)

1, Excretory glands; 2, 2, 2, 2, acini; 3, 3, cells bordering acini; 4, 4, eosinophiles; 5, 5, mast cells; 6, island of lymphoid tissue.

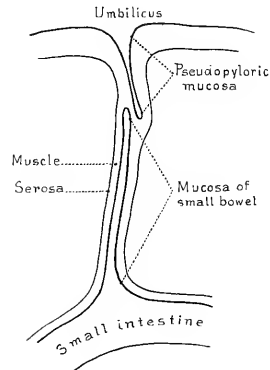


FIG. 85.—AN UMBILICAL FISTULA LINED WITH MUCOSA RESEMBLING THAT OF THE STOMACH. (After Lexer.)

This sketch is from Plate 16 accompanying Lexer's article. It shows the lack of continuity of the fistulous tract. The inner portion is from Meckel's diverticulum, and is lined with a mucosa like that of the small bowel. The outer portion of the tract was cut off entirely from the inner and was lined with mucosa resembling that of the pylorus.

ature. His was a congenital tumor, which later had increased to the size of a walnut. Histologically, it presented the picture of a gastric adenoma.

A Cystic Umbilical Tumor Secreting a Fluid that Tended to Digest the Abdominal Wall.†—In the case of a boy five years old, moisture had been noticed in the umbilical region since his birth. Four months before entering the hospital he developed a serpiginous ulcer, which extended from the umbilicus downward. On admission the child was pale. In the

\* Minelli, S.: Adenoma Ombelicale a struttura gastrica. *Gaz. med. Italiana*, 1905, lvi, 101.

† Reichard: *Centrbl. f. Chir.*, 1898, xxv, 587.

umbilical region was a tumor, the size of a hazel-nut, which showed a fine fistulous opening from which clear fluid escaped. The digestive ulcer extended down the abdominal wall for a distance of 6 cm. Its margins were indurated.

The abdomen was opened, and the tumor was found to be cystic, bluish, translucent, and sharply defined. Passing from it was a very thin pedicle which extended upward in the abdominal cavity. Further examination could not be made on account of the weak condition of the child. The entire umbilical area was removed, and the child recovered.

The cavity was lined with mucosa which microscopically seemed to be of the gastric type. Reichard says that this reminded him of Tillmanns' case, although neither inversion nor prolapsus of the tumor had occurred.

**An Umbilical Fistula.\***—The boy, a year and a half old, entered the hospital November 4, 1886. The umbilicus was swollen, and from it an acid, watery fluid escaped. The surrounding tissue was slightly macerated. The opening at the umbilicus was red and granular, and the walls were indurated and thickened. The cavity was 1 cm. in diameter.

**Operation.**—The thickened skin was cut out and the red, granulating mucosa removed with forceps and scissors. Roser thought that he had cut down to the subperitoneal connective tissue and did not enter the abdominal cavity. Several weeks later he noticed that some of the mucosa had been left behind, and a sound could be carried 3 mm. downward. The discharge was small in amount, but slightly acid in reaction. A small tampon saturated with a solution of zinc chlorid was placed in the cavity, and several weeks later all trace of the fistula had disappeared. The scar was hardly visible when the child left the hospital in December.

Microscopic examination by Professor Marchand showed that the mucosa was similar to that of the stomach. The tubular glands were closely packed, and beneath them was an abundant layer of smooth muscle.

Roser says that when one remembers that, in the early fetal life, the pylorus is in a different position to that which it occupies later,—that is to say, the stomach is perpendicular, and the pylorus is in the umbilical region,—one can surmise that a portion of the wall of the stomach may be detained at the umbilicus and when the stomach draws back, may be held there. In this way a diverticulum might form, and as a result a cyst would develop.

**A Congenital Umbilical Fistula.†**—A boy, seven years old, was admitted on account of an umbilical fistula. Its presence had been noted when the cord dropped off. On the fourth day a projection 4 cm. long and of about the thickness of a little finger was noted at the umbilicus. It was glassy in appearance and pale. In the course of a month a small opening developed in the center of it, from which came a continuous flow of clear, watery fluid. The projection gradually diminished until it disappeared, but the opening grew larger until its diameter reached that of a penholder. No feces, no fecal odor, and no urine were at any time detected at the umbilicus.

On admission the boy was strong and well nourished. At the umbilicus was a tumor the size of a hazel-nut. It was round, red, and glistening, 1 cm. in diameter,

\* Roser, W.: Zur Lehre von der umbilikalen Magencystenfelst. *Centrabl. f. Chir.*, 1887, xiv, 260.

† Von Rosthorn: Ein Beitrag zur Kenntniss der angeborenen Nabelfistel. *Wien. klin. Wochenschr.*, 1889, ii, 125.

soft in consistence, and had a velvety covering. Through the central opening a probe could be passed directly inward for 2 cm. The abdominal wall around the opening was slightly irritated.

The secretion from the umbilical tumor amounted to about 5 c.c. in twenty-four hours. It was acid in reaction. Von Jaksch made the chemical examination.

**Organic:** Albumin bodies, peptone and albumose, ferments and pepsin, in small quantity; sugar, urinary salts, bile-coloring matter, urobilin, absent.

**Inorganic:** Reaction for free hydrochloric acid negative. Chlorids in large quantities. No phosphates or sulphates.

Microscopic examination of the diverticulum, which extended to the peritoneum, showed typical Lieberkühn's glands; near the middle portion were glands with clear cells resembling closely those of the pyloric region.

**A Congenital Umbilical Fistula Lined with a Mucosa Possibly Resembling that of the Stomach.\***—The child, two and one-half years old, had had trouble at the umbilicus since the cord came away. The umbilical region was never dry, and in the depression was a tumor the size of a

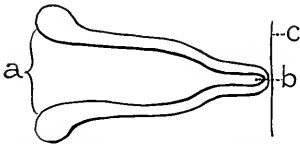


FIG. 86.—APPEARANCE OF THE UMBILICAL DEPRESSION IN VON ROSTHORN'S CASE.

a, the umbilical opening; b, the bottom of the depression; c, the peritoneum.

hazelnut, red in color, and with a granular, moist surface. It was attached to the umbilical depression by a short, thin pedicle. It looked like a typical granuloma of the umbilicus. The pedicle was cut, but so much oozing took place that the thermocautery was necessary to check the bleeding. On microscopic examination a transverse section of the polyp showed that the surface was covered with glands. The central portion consisted of adenoid tissue containing many smooth muscle-fibers. The epithelium and glands of the tumor resembled those of the intestine.

**An Umbilical Polyp.**—Strada† gives a short survey of the literature, and then reports the case of a young woman of twenty who had a tumor at the umbilicus. This grew slowly to the size of a walnut, was round, red, and covered with mucosa. It was attached by a short pedicle and was irreducible. It was removed.

On microscopic examination it was found to be covered with cylindric epithelium. The majority of the glands, according to Strada, were of the pyloric type; others resembled Lieberkühn's glands. In the center of the tumor was adipose tissue; surrounding it, non-striped muscle. Strada gives a splendid picture of this case, and then carefully reviews the cases in which the mucosa at the umbilicus resembled gastric mucosa.

**Congenital Prolapsus of Stomach Mucosa Through the Umbilical Ring.‡**—In July, 1881, August W., aged thirteen, was brought to Tillmanns. With the exception of an unusual condition at the umbilicus, the child was perfectly healthy, although somewhat anemic.

\* Siegenbeck van Heukelom: Die Genese der Ectopia ventriculi am Nabel. Virchows Arch., 1888, cxi, §475.

† Strada, Ferdinando: Adenoma Congenito Ombelicale a tipo gastrico. Lo Sperimentale Archivio di biologia normale e patologia, 1903, lvii, 637.

‡ Tillmanns, H.: Ueber angeborenen Prolaps von Magenschleimhaut durch den Nabelring (Ectopia Ventriculi) und über sonstige Geschwülste und Fisteln des Nabels. Deutsche Zeitschr. f. Chir., 1882-83, xviii, 161.

At the umbilicus was a bright-red tumor the size of a walnut (Fig. 87). It was painless on manipulation, but caused the patient some feeling of discomfort. The surface of the tumor secreted a cloudy, tenacious, mucus-like acid juice, which was especially abundant when the tumor was irritated. At no point was there any evidence of an opening downward, and no canal could be made out. The entire tumor was covered with mucosa. It was attached to the umbilicus by a thin pedicle. It was not increased in size by coughing or by pressure on the abdominal wall. The skin in the vicinity of the tumor had been macerated by the secretion.

The secretion was relatively abundant. It was possible, in the course of fifteen minutes, to collect from 2 to 3 c.c. and, when the tumor was mechanically irritated with the finger or a sound, the secretion increased. Tillmanns first thought that he was dealing with a Meckel's diverticulum with prolapse of the intestinal mucosa, or possibly that a urachal fistula existed. Thiersch also saw the boy and came to the same conclusion, but the acid reaction of the mucus, the experiments as to its power of digestion, and later the histologic examination of the tumor, made them conclude that they had to deal with stomach mucosa.

The secretion digested fibrin in an acid solution at 39° C. Pepsin was evidently present. The fresh secretion was strongly acid. That which had been secreted for some time and lay in the vicinity of the tumor in several instances gave an alkaline reaction. Professor Drechsel, of the Chemical Department, examined the secretion and found that it corresponded to that coming from the stomach.

The mother said that the cord dropped off about the sixth day, and that immediately a reddish tumor, about the size of a cherry, was seen at the umbilicus. The umbilical cord was unusually thick, and it was thought possible that the midwife had tied the cord too close to the umbilical ring. Several days after the cord had come away the tumor became more prominent. During the last few years it had grown very slowly, and in the four months previous to his admission there had been hardly any increase in size. After the boy had eaten, this tumor would sometimes swell perceptibly; it would become reddish, and the mucosa would increase in thickness. At this time it would also secrete abundantly. The discharge had been so copious that it was necessary for the patient to wear dressings. These would sometimes be saturated and his clothes would be wet. There was no evi-

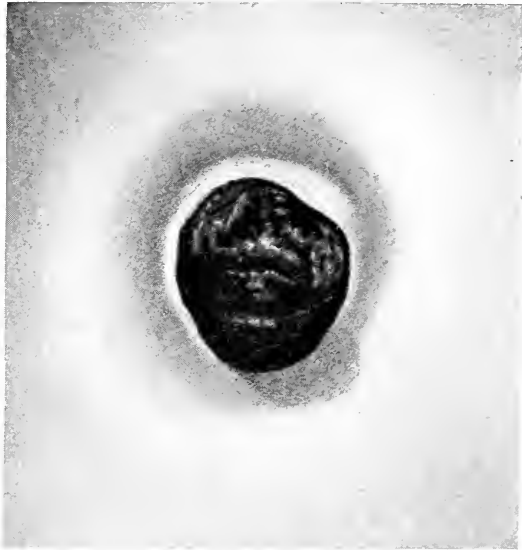

FIG. 87.—GASTRIC MUCOSA AT THE UMBILICUS. (After Tillmanns.)

Projecting from the umbilicus is a bright-red, velvety tumor mass. This was covered over with mucosa, which on histologic examination resembled mucosa of the pyloric region. It had an abundant secretion.

dence of fecal matter or of stomach-contents at the umbilicus. The boy had never suffered from indigestion, and his defecation was normal.

On account of the discharge the boy was anxious to have the tumor removed. This was readily accomplished. The pedicle was cut across, and the few small vessels were controlled with the Paquelin cautery. Within a few days all trace had disappeared, and the patient, up to the time Tillmanns reported the case, had been perfectly well (Fig. 88).

Microscopic examination of the tumor by Professor Weigert showed that it consisted of stomach-wall, all the layers being present. In the center was serosa, then came subserosa, then a layer of muscle, and covering the outer surface, mucosa. The glands were very abundant, but were in part atrophic. Several portions on casual examination might very readily have been mistaken for intestinal mucosa; but others at once indicated their origin from the pylorus.

Tillmanns says that, from the chemical and anatomic examination, it was evident that a portion of the stomach-wall in the vicinity of the pylorus had prolapsed

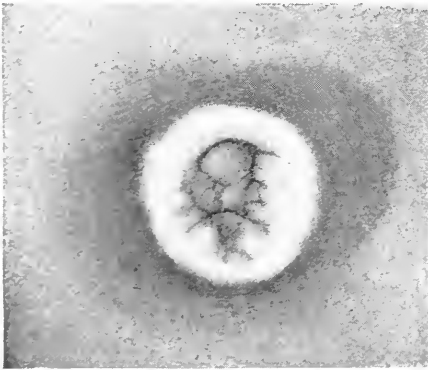


FIG. 88.—APPEARANCE OF THE UMBILICUS AFTER REMOVAL OF THE STOMACH MUCOSA SEEN IN FIG. 87. (After Tillmanns.)

The umbilical depression is very uneven, but perfectly intact. There was no opening into the abdomen.

through the umbilical ring in such a way that the mucosa was on the outer surface, while the muscular coats formed the center. He said he was unable to find a similar case reported in the literature. To explain the origin of the condition he supposed that there had probably been an umbilical hernia, in which a portion of the stomach diverticulum had been included; that the thick, funnel-shaped umbilicus had probably been tied too close to the umbilical ring, and in all probability a portion of the stomach diverticulum had been tied off with the cord. He added that, at the time of labor, the diverticulum of the stomach was probably no longer in connection with the stomach proper.

**An Umbilical Polyp Covered with Stomach Mucosa.\***  
—A boy, three years old, was admitted January 5, 1897. The labor had been normal, but the cord did not come away on time. When it did drop off, a small, red tumor was found at the umbilicus. This was cauterized by the attending physician. From that time it secreted a fluid which was whitish and contained brown flocculi or white clots, and occasionally mucous threads. There was never any indication of the escape of intestinal or stomach-contents. According to the father, about half a wineglassful of fluid escaped daily. The clothes and dressing were always soaked.

The flow increased at midday, and at that time was often accompanied by colicky pain. In the morning, on the other hand, the child was comfortable.

Four months before his admission a canal-shaped wound developed from the umbilicus downward. This would not heal, but continued to increase in size. The boy's appetite was good; the bowels were regular.

\* Weber, W.: Zur Kasuistik der Ectopia ventriculi. Beiträge z. klin. Chir., 1898, xxii, 371.

On admission the child was anemic. On separation of the umbilical folds a drop of clear, serous fluid escaped. Passing down the abdominal wall from this point was a canal-shaped, ulcerated area, about four cm. long, having callous walls. The wound itself and the surrounding epidermis over an area the size of the palm of the hand were markedly macerated. The umbilical region presented the typical picture of a digestive process.

Operation.—An incision including this area was made and the peritoneum opened. From the fistulous tract a thin cord passed upward and led to the under surface of the liver. The umbilical growth was sharply defined, bluish, and cystic. There was no connection with the intestine or with the stomach. The tumor was removed. In three weeks only two small areas of granulation remained.

The cystic tumor was lined with a thick mucosa, macroscopically resembling that of the stomach. The mucosa was alkaline in reaction. On microscopic examination it was found to be of the pyloric type. Beneath it was a submucosa, then layers of non-striated muscle. Weber says that, from this description and the microscopic picture, it is certain that we are dealing with normal stomach mucosa from the pyloric region. The microscopic examination was made in the Berlin Pathological Laboratory by Privatdocent Krause.

Weber thought that the cord passing to the under surface of the liver represented remains of the umbilical vein.

Although the secretion was alkaline, the free secretion at noontime, and the maceration, together with the anatomic appearance above noted, indicated that the growth had developed from the stomach. Weber gives a résumé of the literature on the subject.

**LITERATURE CONSULTED ON CONGENITAL POLYPS, FISTULÆ, OR CYSTIC DILATATIONS AT THE UMBILICUS, SHOWING A MUCOSA MORE OR LESS SIMILAR TO THAT OF THE PYLORIC REGION OF THE STOMACH, AND SECRETING AN IRRITATING FLUID BEARING A MARKED RESEMBLANCE TO GASTRIC JUICE.**

Denucé: *Fistules pseudo-pyloriques congénitales de l'ombilic.* *Revue d'orthopédie*, 1908, xix, 1.  
 Lexer: *Magenschleimhaut im persistirenden Dottergang.* *Langenbeck's Arch. f. klin. Chir.*, 1899, lix, 859.

Minelli, S.: *Adenoma Ombelicale a struttura gastrica.* *Gaz. med. Italiana*, 1905, lvi, 101.

Reichard: *Centralbl. f. Chir.*, 1898, xxv, 587.

Roser: *Zur Lehre von der umbilikalischen Magencysten fistel.* *Centralbl. f. Chir.*, 1887, xiv, 260.

Von Rosthorn: *Ein Beitrag zur Kenntnis der angeborenen Nabel fisteln.* *Wien. klin. Wochenschr.*, 1889, ii, 125.

Siegenbeek van Heukelom: *Die Genese der Ectopia ventriculi am Nabel.* *Virchows Arch.*, 1888, exi, 475.

Strada, F.: *Adenoma Congenito Ombelicale a tipo gastrico.* *Lo Sperimentale Archivio di biologia normale e patologia*, 1903, lvii, 637.

Tillmanns, H.: *Ueber angeborenen Prolaps von Magenschleimhaut durch den Nabelring (Ectopia Ventriculi) und über sonstige Geschwülste und Fisteln des Nabels.* *Deutsche Zeitschr. f. Chir.*, 1882-83, xviii, 161.

Weber, W.: *Zur Kasuistik der Ectopia ventriculi.* *Beiträge z. klin. Chir.*, 1898, xxii, 371.

**PERSISTENCE OF THE OUTER PORTION OF THE OMPHALOMESENTERIC DUCT.**

The picture presented is practically the same as where a simple umbilical polyp exists. (See Fig. 89.) Situated at the umbilicus is a red nodule, varying from a pea to a chestnut in size. Occasionally it may be longer, as in Wheaton's

case. In Chandelux' case it was 6 cm. long. This length, of course, is exceptional.

Occupying the center of the prominent part of the nodule is a canal, into which a sound can be introduced (Figs. 89, 90, and 91), sometimes only for a short dis-

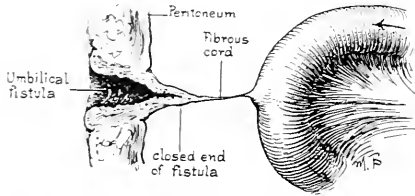


FIG. 89.—PERSISTENCE OF THE OUTER END OF THE OMPHALOMESENTERIC DUCT. (Schematic.)

The persistence of the outer end of the omphalomesenteric duct as a wide funnel is most unusual, but has occasionally been noted. The duct can be traced for about half its length, and then ends in a fibrous cord which extends to and is adherent to the convex surface of the bowel.

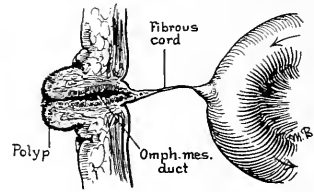


FIG. 90.—ATROPHY OF THE INNER END OF THE OMPHALOMESENTERIC DUCT. (Schematic.)

At the umbilicus is a polyp-like outgrowth covered with intestinal mucosa in the center of which is a canal—the outer end of the omphalomesenteric duct. The intra-abdominal portion of the duct is represented by a fibrous cord which extends from the umbilical region to the convex surface of the bowel.

tance, usually for from 1.5 to 2.5 cm. From the fistula a glairy mucus or a clear fluid escapes. In one of Florentin's cases the fluid coagulated, resembling apple jelly. In this case, in addition to the fistula, there was a pus-pocket, the size of a small mandarin orange, lying to one side of the fistulous tract. These projections, and also the fistulous tract, are covered with mucosa of the small bowel.

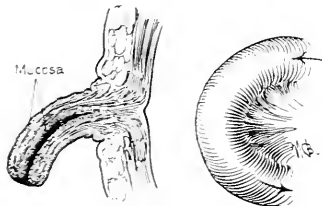


FIG. 91.—A LONG UMBILICAL POLYP AS A REMNANT OF THE OMPHALOMESENTERIC DUCT. (Schematic.)

A short, round umbilical polyp is the most common remnant of the duct noted clinically. Such a long penile projection as here depicted is exceptional. In such a case as this there is a long reddish projection springing from the umbilical depression. It is covered with intestinal mucosa. In its center is a fistulous opening into which a probe can be carried for a variable distance. Traces of the intra-abdominal portion of the duct may or may not be present.

The condition is usually noted at the time that the cord comes away, or shortly afterward.

When the abdomen is opened for the removal of the umbilical fistula, the abdominal end of the tract will usually be found to end in a fibrous cord, which is attached to the convex surface of the small bowel. When removing the fistula it is always wise to treat the stump at the bowel as a patent tube, as one never knows when a fistulous tract or a thick adhesion may contain a minute opening that connects with the lumen of the bowel.

#### CASES IN WHICH THE OUTER END OF THE OMPHALOMESENTERIC DUCT REMAINED PATENT.

Persistence of the Outer Portion of the Omphalomesenteric Duct.\*—A child, two and one-half years old, had had at the umbilicus, since birth, a projection, about 6 cm. long, resembling a portion of umbilical cord. When the child was admitted to the hospital, the growth was still about 6 cm. in length. Its extremity was free and somewhat enlarged. In its center was a slight depression which admitted a probe for a short distance. The

\* Chandelux, A.: Observation pour servir a l'histoire de l'exomphale. Arch. de physiol. norm. et pathologique, 1881, xiii, 2. sér., 93.



growth bore some resemblance to a penis. The surface was not smooth, but had a granular aspect and was reddish in color. Here and there were pale areas suggesting islands of skin. Its surface was covered with an abundant viscid discharge. This was never yellow, nor could a fecal odor be detected. Urination was normal. The nodule could not be reduced by taxis. The patient's health was good. This nodule was successfully removed. On histologic examination its outer surface was found to be covered with intestinal mucosa, and its central portion was made up of non-stripped muscle.

**A Partially Patent Omphalomesenteric Duct.**—Florentin\* refers to a boy, five weeks old, who came to Professor Froelich's clinic. The cord had been ligated 3 cm. from the umbilicus. Eight days after birth, when the cord came away, a small umbilical tumor was noted which discharged a clear liquid. The nodule did not change in volume and was not painful. When the child came to the clinic, the umbilicus looked somewhat tumefied, and in its center was a small pedunculated tumor about the size of a pea. It was dark red, firm, irreducible, and showed but little tendency to bleed. In its center was a small depression from which mucus escaped in small amount. A probe could be introduced for 2 cm. The fistulous tract was removed.

It was found to be continuous with a cord, which was implanted in the intestine. This cord was cut off near the intestine with the thermocautery, covered over, and the abdomen was closed. The child made a good recovery. The outer surface of the tumor was covered with Lieberkühn's glands, and the cord itself presented a lumen lined with cylindric epithelium. This tumor was a partially patent omphalomesenteric duct.

**A Partially Patent Omphalomesenteric Duct.**—Florentin† refers to an umbilical fungus in a child two months old in Froelich's clinic. Just as soon as the cord came away a small reddish mass, the size of a pea, was noted at the umbilicus. There was no history of intestinal trouble. The umbilical nodule did not increase in size. It was firm, hard, and did not resemble a simple granulation. It had a short pedicle. It was dark red in color, smooth, and only slightly painful. It was irreducible. At its summit was a fistulous tract from which a small amount of clear liquid without odor escaped. A probe could be introduced for 3 cm.

At operation it was found that the under portion of this fistulous tract was adherent to a cord, and that the base of it was attached to the intestine. This cord was burned off, and the base turned in as in an appendix operation.

Histologic examination showed that the outer or umbilical surface of the fistula was covered with glands, beneath which was muscle. The condition was due to a partially patent omphalomesenteric duct.

**Umbilical Polyp with a Partially Patent Omphalomesenteric Duct.**—Florentin‡ describes a fungous diverticulum with a fistula at the umbilicus and a pocket of pus, in a boy one year old. This patient was observed in Froelich's clinic. After the cord came away a tumor of considerable size was found at the umbilicus. It discharged a clear liquid similar to apple jelly. After the third month the fistula closed, but it reopened four months later,

\* Florentin, P.: Fongus de l'ombilic chez le nouveau-né et chez l'enfant. Thèse de Nancy, 1908-09, No. 22, p. 83.

† Florentin: Op. cit., 82.

‡ Florentin: Op. cit., 80.

at which time a little pus escaped from the orifice. The general health of the child was excellent.

At the umbilicus was a tumor the size of a large horse chestnut. It was solid in consistence and uniform in outline. Its surface was glistening, brilliant, and pink in color. At one point it was possible to introduce a probe for a short distance. On removal it was found that, at the bottom, the umbilical tissue was very firm and much thicker than usual. At a point 1.5 cm. beneath the cord-like thickening the operator opened into a pocket the size of a small mandarin orange, which contained bloody pus. The fistulous tract was about 3 cm. long. The tumor was removed, the pocket was cureted, and the wound healed thoroughly.

On histologic examination numerous tubular glands were found. Outside of these there were muscular tissue and connective tissue. The condition was undoubtedly due to remains of the omphalomesenteric duct.

**An Omphalomesenteric Duct Open in its Outer Portion but Closed at the Intestinal End.\***—The specimen was removed from a male infant ten weeks old. A small pink tumor had been noted at the umbilicus two weeks after the cord came away. It had steadily increased in size. It was the size of a filbert, one inch long and half an inch in diameter. It was attached to the umbilicus by a narrow pedicle. At the upper end of the tumor was a small orifice, situated in the middle of a depression. A probe passed into the abdomen for  $2\frac{1}{2}$  inches and then met an obstruction. The surface of the tumor was pink and velvety, and a mucoid fluid constantly flowed from it. It was removed by means of a ligature and the stump treated with silver nitrate.

**Microscopic Examination.**—The mucosa in the canal and also on the surface was found to resemble that of the intestine, except that the villi and solitary glands were lacking. The growth represented a partially patent Meckel's diverticulum, open almost to the bowel.

\* Wheaton, S. W.: Prolapse of Meckel's Diverticulum in an Infant, Forming an Umbilical Tumour. *Obst. Trans.*, London, 1892, xxxiv, 184.

#### LITERATURE CONSULTED ON PERSISTENCE OF THE OUTER PORTION OF THE OMPHALOMESENTERIC DUCT.

- Chandelux, A.: Observation pour servir a l'histoire de l'exomphale. *Arch. de physiol. norm. et pathologique*, 1881, xiii, 2. sér., 93.
- Florentin, P.: Fongus de l'ombilic chez le nouveau-né et chez l'enfant. *Thèse de Nancy*, 1908-09, No. 22, p. 83.
- Wheaton, S. W.: Prolapse of Meckel's Diverticulum in an Infant, Forming an Umbilical Tumour. *Obst. Trans.*, 1892, London, xxxiv, 184.

## CHAPTER VIII.

### MECKEL'S DIVERTICULUM.

Historic sketch.

Herniæ of the tip of Meckel's diverticulum.

A mesenteric diverticulum.

An accessory pancreas situated at the tip of the diverticulum.

Meckel's diverticulum in animals.

Intestinal obstruction due to Meckel's diverticulum.

Cases of intestinal obstruction caused by a Meckel's diverticulum adherent to the umbilicus.

Intestinal obstruction due to the tip of Meckel's diverticulum becoming adherent to a distant point.

Obstruction due to the passage of intestine through a hole in the mesentery of Meckel's diverticulum.

Inversion of Meckel's diverticulum into the bowel.

Treatment of obstruction due to Meckel's diverticulum.

PERSISTENCE of the intra-abdominal portion of the omphalomesenteric duct produces the so-called Meckel's diverticulum (Fig. 92). The subject has been so fully considered by many writers that I shall here give only a brief survey, not attempting to in any way give a full résumé of the literature. Kern, in his Inaugural Dissertation, says that, according to Morgagni, this diverticulum was first observed by J. H. Lavater, who in 1671 saw a case of this character with Bienaisius in Paris.

Fitz says: "The pouch-like formation of intestine occasionally seen projecting from the lower part of the ileum is universally known as Meckel's diverticulum. Not that this distinguished anatomist was its discoverer, for early in the eighteenth century Ruysch\* presented an admirable illustration of this malformation. Its frequent congenital nature was also recognized before the time of Meckel, and it seems probable that suggestions relative to its origin from the vitelline duct had been presented previous to the publication of this investigator.

"We owe to Meckel not only the almost universal acceptance of his theory of origin of the pouch in question, but are also indebted to him for calling conspicuous attention to its importance in the causation of serious disease."

In his "Darmanhang," published by Meckel in Leipzig in 1812, will be found a most careful and detailed description of the literature and of the anatomy of the diverticulum which now bears his name.

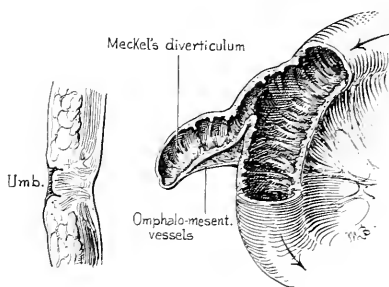


FIG. 92.—MECKEL'S DIVERTICULUM. (Schematic.)

The diverticulum may pass off from the convex surface of the bowel at right angles or on a slant as here. In the latter case, if the slant be very acute, a valve-like opening may be the result. The mucosa of the small bowel and of the diverticulum is of exactly the same character. The omphalomesenteric vessels originate from the superior mesenteric vessels and pass over or under the bowel to reach the duct.

\* Thesaurus Anatomicus, 1701.

Among the many contributions to the subject there may be mentioned those of King (1843), Struthers (1854), Schroeder (1854), Cazin (1862), Fitz (1884), Löwenstein (1894), Richardson (1894), Treves (1897), Blanc (1899), and Kelly and Hurdon (1905).

Fitz says: "There are certain well-recognized variations in the seat, size, and shape of this appendage to the ileum. Since the diverticulum is present in the earliest weeks of fetal life, it is obvious that its position with reference to the ileocecal valve must change with the growth of the intestine.

"The diverticulum is usually found in the vicinity of the valve. In the newborn child the distance between the two is about 12 inches, while in the adult the diverticulum is found sometimes three feet above the ileocecal valve. The limits within which it may be present are thus differently stated by various authors. Rokitansky\* found its seat to be one to two feet above the cecum, while Förster † extends the limit to upward of four feet."

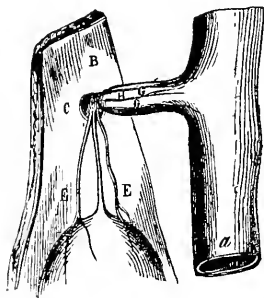


FIG. 93.—MECKEL'S DIVERTICULUM ATTACHED TO THE ABDOMINAL WALL AT THE UMBILICUS. (After Beck.)

The picture shows the inner surface of the anterior abdominal wall, to which Meckel's diverticulum has become attached. *a* is the small bowel; *B*, the inner surface of the abdominal wall; *C*, the umbilicus. In the lower part of the picture is seen the bladder. Passing upward from the vertex of this is the urachus. *E, E*, are the umbilical arteries seen on either side. Passing outward from the small bowel to the umbilicus is Meckel's diverticulum. *G, G*, represent the omphalomesenteric arteries; *H*, the omphalomesenteric vein.

Fitz says that Major ‡ described a diverticulum which arose from the jejunum. He also refers to a diverticulum, seven inches in length, which was found on the border between the jejunum and ileum. §

Fitz also says that Fagge || refers to a diverticulum which was 54 inches from the cecum and to another which rose above the middle of the ileum.

**Length.**—Fitz says that, although the diverticulum is commonly found to be less than 4 inches long, Rokitansky assigns to it a maximum length of 10 inches. One of the best descriptions of Meckel's diverticulum is to be found in Kelly and Hurdon's "Appendicitis and Diseases of the Vermiform Appendix" (p. 594).

This diverticulum projects from the convex surface of the intestine, and may be short or long; sometimes it is free, at other times attached to the umbilicus by a fibrous cord. Occasionally it extends in its continuity to the umbilicus (Fig. 93), and where it is attached to the intestine the two are often of the same diameter. The outer portion of the diverticulum may be of the same caliber and then end in a rounded extremity similar to the bottom of a test-tube; or the duct may gradually taper off toward its extremity.

The walls of the diverticulum are continuous with those of the intestine, and are similar to them both macroscopically and microscopically.

The diverticulum may or may not have a mesentery. Where none exists, the blood supply comes from the intestine. In those cases in which a mesentery is found, it naturally is on one side, the other being perfectly smooth. The blood-

\* Rokitansky: Lehrbuch der path. Anat., 1861, 3. Aufl., 182.

† Förster: Handbuch der path. Anat., 1863, 2. Aufl., 97.

‡ Major: The Lancet, 1839-40, i, 362.

§ Aerztlicher Ber. aus dem K. K. Allg. Krankenhause zu Wien, 1862, 221.

|| Fagge: Guy's Hospital Reports, 3. series, 1869, xiv, 359.

vessels come from the mesentery of the small bowel, pass over the ileum, and then spread out in a plexus over the diverticulum. Where the diverticulum is adherent to the umbilicus, its peritoneum may be continuous with that of the abdominal wall, and small vessels from the abdominal wall may extend over to the duct (Fig. 94).

If the diverticulum be free and the mesentery short, the former may be drawn down toward the bowel on one side, so that this appendage presents a curved or snout-like appearance. Löwenstein says that Riefkohl reported the cases of three children of one mother, each of whom had a Meckel's diverticulum.

The fibrous cords occasionally found extending from the tip of the diverticulum to the umbilicus are usually remnants of the omphalomesenteric vessels. These are referred to at length in Chapter XIV.

Herniæ of the tip of the diverticulum have been referred to by King, Fitz, Kelly and Hurdon, and others.

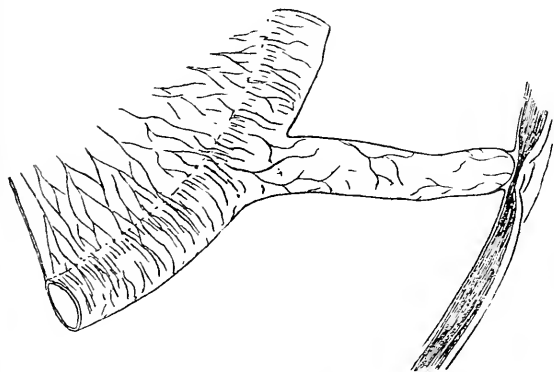


FIG. 94.—AN ABNORMALLY LARGE MECKEL'S DIVERTICULUM. (After Richardson.)

The Meckel's diverticulum here is practically as large as the small bowel. It is attached directly to the umbilicus.

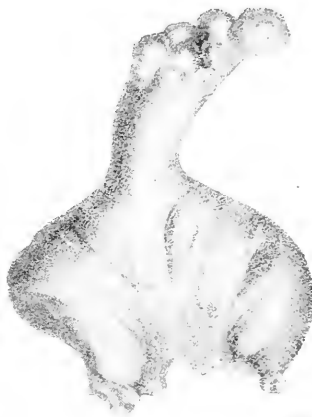

FIG. 95.—A MECKEL'S DIVERTICULUM WITH A LOBULATED EXTREMITY. (After King.) (Prep. 1818, Guy's Hospital Museum.)

Meckel's diverticulum has a diameter nearly as large as the small bowel from which it arises. The diverticulum ends in several round hernial projections.

King, in 1843, referred to a very interesting case of this character (Fig. 95). The tip of the diverticulum was free and ended in seven or eight rounded cystic dilatations.

Fitz, in the examination of the Meckel's diverticula in the Harvard Medical School (Improvement Collection, No. 1033), found a diverticulum with two rounded bulgings at its free end. These were large enough to suggest an incipient bifurcation.

Fitz quotes Hyrtl\* as saying that branched diverticula are extremely rare. In making an autopsy on a hemicephalic monster, Hyrtl found a diverticulum an inch long. This toward the end was divided into five parts.

Kelly and Hurdon† show a long diverticulum with several small, cyst-like dilatations or herniæ near its tip (Fig. 96).

The opening of the diverticulum into the bowel may be large and oval or round;

\* Hyrtl: Handbuch der topographischen Anatomie, 1860, i, 642.

† Kelly and Hurdon: The Vermiform Appendix and its Diseases, Fig. 314, p. 598.

occasionally it is valve-like. This last condition occurs where the diverticulum leaves the bowel tangentially.

Cazin, in 1862, referred to a case in which Meckel's diverticulum opened into the intestine by two orifices, separated by a bridge. The superior one was surrounded by a circular valve.

**A Mesenteric Diverticulum.**—Although diverticula usually spring from the convexity of the bowel, in rare instances they are noted at its mesenteric attachment.

King, in 1843, referred to a specimen in Guy's Hospital Museum (Fig. 97). The diverticulum was very short. It sprang from the mesenteric border of the

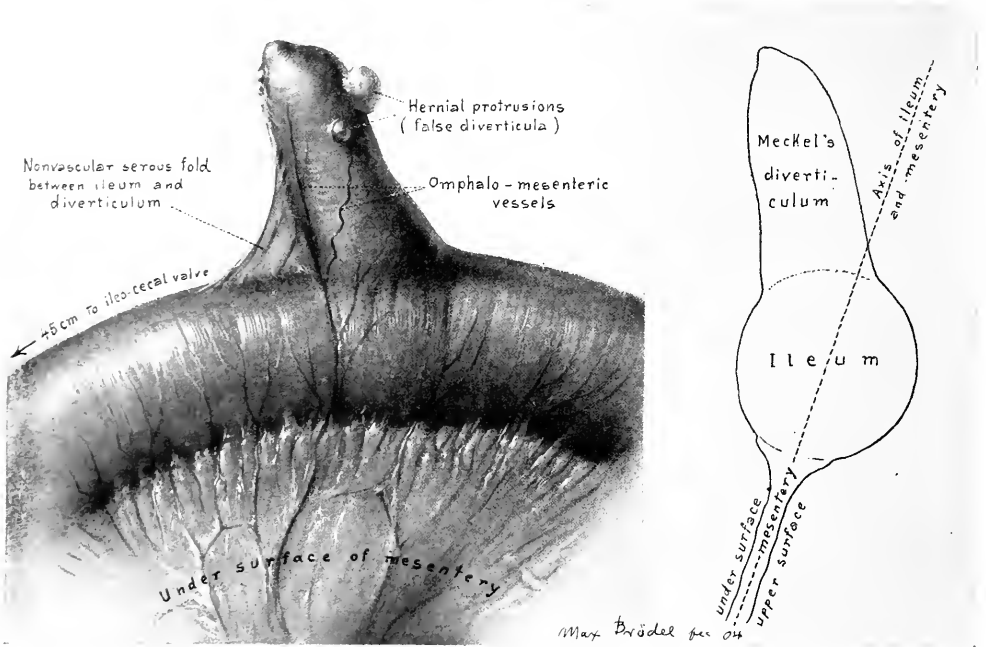


FIG. 96.—A MECKEL'S DIVERTICULUM WITH HERNIAL PROTRUSIONS FROM ITS SURFACE. (After Kelly and Hurdon.)

small bowel, and was adherent to the mesentery. This subject is considered at length in the chapter dealing with Intestinal Cysts.

**An Accessory Pancreas Situated at the Tip of the Diverticulum.**—Bize, in 1904, gave an interesting account of a case in which an accessory pancreas was found at the tip of a Meckel's diverticulum (Fig. 98). He gives both macroscopic and microscopic pictures of the case, and draws attention to the fact that cystic tumors may possibly develop from such accessory pancreases.

Dévy, in 1906, records a case in which Meckel's diverticulum was 7 cm. long. At its extremity was a thickening the size of a small bean. It was an accessory pancreas.

Denucé, in 1908, referred to a case reported by Albrecht. In this case Meckel's diverticulum had at its extremity a yellowish nodule the size of a pea. This nodule, on histologic examination, was found to consist of pancreatic tissue.

It will be interesting to see if, as Bize suggests, pancreatic cysts may possibly develop in the tip of the diverticulum. If such a condition were probable, one would naturally expect the literature to contain records of a few such conditions, but I have not been able to locate a cyst of Meckel's diverticulum that in any way suggested a pancreatic origin.

**Meckel's Diverticulum in Animals.**—Tillmanns says that the observations of Cazin have shown that true diverticula, having no connection with the abdominal wall, are regularly present in the water-hen, snipe, and swan.

Fitz quotes Morgagni as saying that he had observed the diverticulum on more than one occasion in geese.

Cazin, in his thesis on Intestinal Diverticula, published in 1862, reported an observation of Guobaux. Guobaux, on January 15, 1855, made an autopsy on a sheep. In the lower portion of the small intestine was a diverticulum 9 cm. in

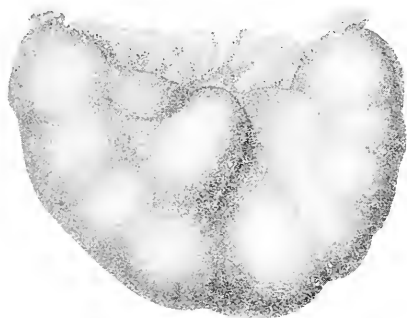


FIG. 97.—A SHORT MECKEL'S DIVERTICULUM SPRINGING FROM THE MESENTERIC ATTACHMENT. (After King.) (Prep. 1819<sup>60</sup>, Guy's Hospital Museum.)

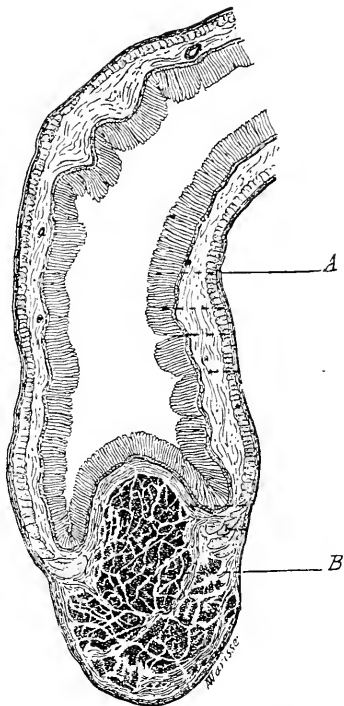


FIG. 98.—AN ACCESSORY PANCREAS IN THE TIP OF MECKEL'S DIVERTICULUM. (After Bize.)

Meckel's diverticulum (A) was dilated, and at its tip was a nodule the size of a small nut (B). This nodule on histologic examination was found to consist of pancreatic tissue.

length, and of a caliber equal to that of the small bowel. It had the same structure as the intestine. On examining this canal he found that a Peyer patch had extended a short distance into the interior of the diverticulum. Guobaux also referred to diverticula occurring in birds.

#### INTESTINAL OBSTRUCTION DUE TO MECKEL'S DIVERTICULUM.

As the reader is thoroughly familiar with obstructions of this character, and as the literature on this subject is so large, I shall not attempt to cover the subject, but shall merely give a few examples of some of the manifold ways in which a Meckel's diverticulum may occasion obstruction.

**A Case of Intestinal Obstruction in which Meckel's Diverticulum was Free.**—The following case gives a graphic picture

of what a free Meckel's diverticulum may do. The specimen was kindly placed at my disposal by Dr. Joseph C. Bloodgood: August L., aged forty-two, came under the care of Dr. H. Jones, of Irvington, Md., early on the morning of June 9, 1914.

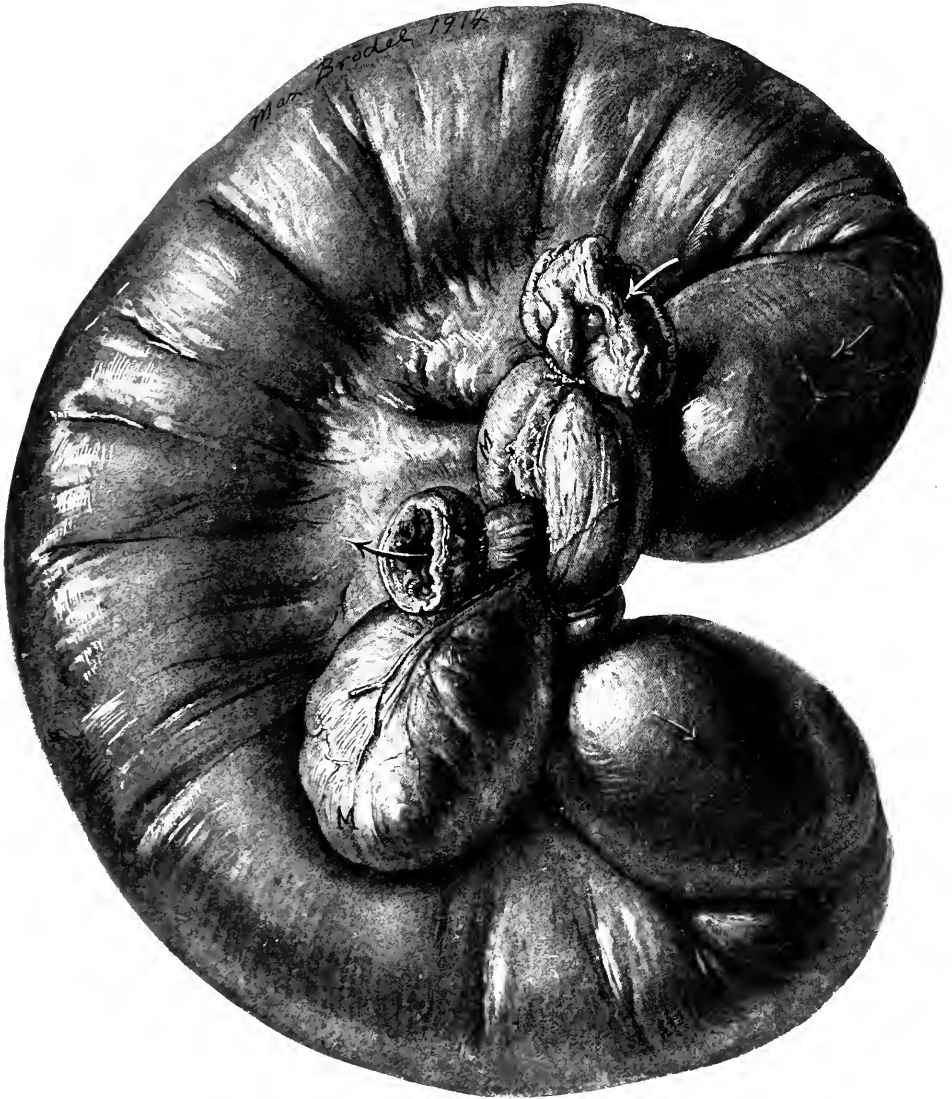

FIG. 99.—MECKEL'S DIVERTICULUM COMPLETELY TYING OFF A LOOP OF SMALL BOWEL.

This specimen was removed by Dr. George A. Stewart at St. Agnes' Hospital, Baltimore, June 9, 1914. The arrows indicate the cut ends of the bowel. The intestinal loop is greatly distended. The pear-shaped cyst is a Meckel's diverticulum. Its extremity is perfectly free, and on its upper surface its blood-vessels stand out prominently. It has in some manner become tied around the gut. (For the key, see Fig. 100.)

At 1 A. M. he had nausea and vomiting, and shortly afterward abdominal pain. His bowels had moved once, but later were obstinately constipated. Twelve hours later he had tenderness all over the abdomen.

Operation (at St. Agnes' Hospital).—Fifteen hours after the symptoms de-



veloped Dr. George A. Stewart opened the abdomen and found a large loop of bowel much distended and very dark. Its mesentery appeared to be gangrenous. The bowel was so knotted at one point that no attempt was made to unravel it, and the entire area was removed. The ends were closed, and a lateral anastomosis was made. The abdomen was closed without drainage. The patient made a good recovery.

Dr. Bloodgood, in his description, says: "The specimen consists of about 18 inches of small gut, dark brown in color, and of the hardness of paper. At one end there is a peculiar knot, which was the cause of the volvulus and thrombosis (Fig. 99). From the picture it is seen that the bowel is markedly distended. The ends of the resected gut are indicated by the arrows. The cystic mass (*M*) is the greatly dilated Meckel's diverticulum. It is perfectly smooth, and on its upper surface are its mesenteric vessels." From the picture it is very difficult to say just how the obstruction occurred.

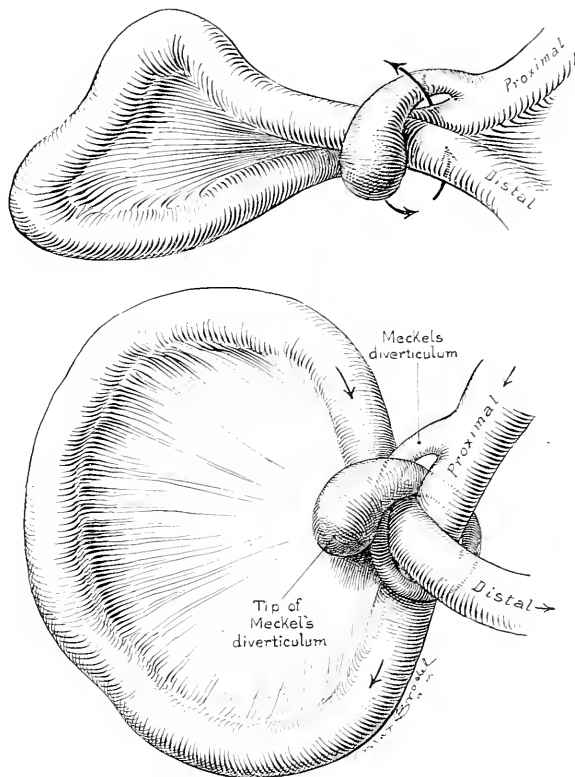


FIG. 100.—A DIVERTICULUM TYING OFF A LOOP OF SMALL BOWEL.

This indicates the manner in which the obstruction occurred (*cf.* Fig. 99). Meckel's diverticulum has dropped over a loop of bowel which has been partly twisted. After passing under the loop it curves upward and passes through the space between the base of the diverticulum and the adjacent small bowel. With the consequent distention of the constricted bowel, complete obstruction has resulted.

then passed through the space between its own base and the small bowel. As a result of the obstruction all the affected parts soon swelled up.

Early operation afforded the only hope of saving such a patient.

#### CASES OF INTESTINAL OBSTRUCTION CAUSED BY A MECKEL'S DIVERTICULUM ADHERENT TO THE UMBILICUS.

Intestinal obstruction is more likely to occur when the diverticulum extends to and is fixed to the umbilicus, or when it is attached to the umbilicus by a fibrous cord.

Strangulation of Meckel's Diverticulum Caused by Volvulus of the Ileum.\*—Elliot's patient was a man, aged thirty,

\* Elliot, J. W.: Trans. Amer. Surg. Assoc., 1894, xii, 217.

who was admitted to the Massachusetts General Hospital. He had been sick for four days. He gave a history of vomiting, chills, and abdominal pain. On admission his temperature was 103.6° F.; pulse, 160. The abdomen was distended and exceedingly tender, especially to the right of and below the umbilicus; there was free fluid in the abdominal cavity.

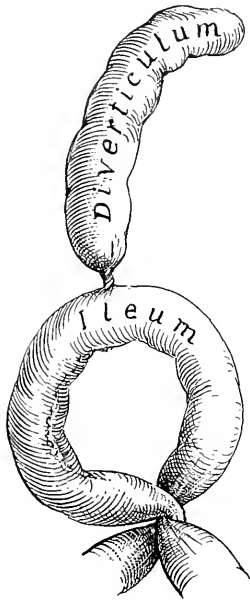


FIG. 101.—STRANGULATION OF MECKEL'S DIVERTICULUM CAUSING VOLVULUS OF THE ILEUM. (Redrawn after Elliot.)

The specimen was from a man aged thirty who had signs of intestinal obstruction. The abdomen contained turbid fluid. In the incision a mass presented which looked like a large, dilated gangrenous loop of intestine, but had no mesentery. It sprang from the lower part of the convex surface of the ileum, and was slightly twisted at its point of attachment to the bowel. It extended upward into a dense mass of adhesions, and was found to be attached to the under surface of the umbilicus. It was a strangulated and gangrenous Meckel's diverticulum. It was about seven inches long, and had about the same diameter as the ileum. The small bowel at this point was twisted on itself and held in position by adhesions. The gut was partially obstructed at the twist. The patient died on the second day after operation.

Examination of the section of the band which was removed showed clearly that it was the obliterated remnant of the vitelline duct.

Operation.—When the abdomen was opened, there was an escape of turbid fluid. The appendix was normal. The mass encountered looked like a large, dilated, and gangrenous knuckle of intestine, but without a mesentery. It sprang from the lower part of the convex surface of the ileum and was tightly twisted at its point of attachment to the bowel. (See Fig. 101.) It extended upward into a dense mass of adhesions, and was found to be attached to the under surface of the umbilicus. It was a strangulated and gangrenous Meckel's diverticulum, 7 inches long, and about the same size as the ileum. During dissection it ruptured. The ileum at this point was found to be twisted on itself and held in position by adhesions. The gut was not wholly obstructed by the twist. The diverticulum, having its outer end fixed at the umbilicus, was twisted and strangulated at its base by the turning over of this coil of ileum. The gangrene of the diverticulum was most intense near the ileum, the end at the umbilicus being only moderately inflamed. The patient died on the second day.

Fatal Intestinal Obstruction Due to Remains of the Omphalomesenteric Duct.\*—Mrs. M. C., aged twenty-four, admitted to St. Francis' Hospital, Pittsburgh, June 6, 1906. The patient had always been healthy until the onset of the present illness. Three days previous to admission she was seized with sudden severe pain in the abdomen. This was followed by vomiting. There was a slight elevation of temperature; the pulse was rapid.

The diagnosis of intestinal obstruction was made, and immediate operation advised. When the abdomen was opened, a gangrenous loop of ileum was found. This was twisted twice about a narrow band which was attached at one end to the umbilical site; at the other end, to the convex surface of the ileum, about six inches from the cecum. A resection of the bowel was made, but the patient died three days later of peritonitis.

\* Huggins, R. R.: Personal communication.

**Ileus Caused by Persistence of the Omphalomesenteric Duct.** \*—The patient, a man nearly twenty years of age, had always been strong and hearty. He was suddenly seized with vomiting and pain in the umbilical region. The vomiting was frequent, and two days later assumed a fecal character. The abdomen, particularly in the lower half, was much distended.

**Operation.**—When the abdomen was opened, a part of the bowel was found distended; the rest was contracted. One loop of bowel was green and gangrenous. The gangrene had been caused by a half-turn made by a cord the size of the little finger passing from the umbilicus. This cord was inserted in the gangrenous loop. It was an omphalomesenteric duct. The gangrenous loop of small bowel was 1.1 meters long, and reached to within 7 cm. of the ileocecal valve. A resection was made but the patient died almost immediately.

**Fatal Intestinal Obstruction in Consequence of a Twist in the Mesentery and the Falling of Some Folds of Intestine over a True Diverticulum.** †—The patient, a strong, robust boy, was seized with a violent pain in the abdomen after drinking a cup of hot coffee. He had no movement of the bowels for six days. General peritonitis developed, and he died on the ninth day.

**Autopsy.**—On section, general peritonitis was found. The mesentery of some loops of the small bowel was twisted on itself. The intestines were deeply injected and quite black. Loops of intestine had fallen over a diverticulum, which extended from the small gut to the linea alba, about one inch below the umbilicus. The diverticulum was 5 inches long and 34 inches distant from the cecum.

**Strangulation of Intestine by Diverticulum Ilei.** ‡—Eliza W., aged ten, was admitted with symptoms of strangulated bowel. Peritonitis developed, and she died in a few hours. The symptoms had begun ten days before death, with an attack of sickness attributed to the eating of some indigestible fruit.

**Autopsy.**—On section, an acute peritonitis was found. When the abdominal wall was lifted up, a band was seen passing from the umbilicus to the lower part of the ileum, to which it was attached. The portion of the gut above was much distended; the part below was contracted. The constricting band was found to be a diverticulum of the ileum which had become obliterated at the umbilicus. At its origin it was of the same caliber as the contracted portion of the ileum below it.

“The only practical consideration arising from such a case is to remember that, in an exploratory operation in a case of obstruction, a cord passing to the umbilicus is very likely to be a diverticulum of intestine.”

Wilks says that, in the Guy's Hospital Museum, there are four specimens of this malformation causing obstruction of the intestine. In one case the patient had reached forty-three years of age. In another, a child, the patient had previously undergone a successful plastic operation for a fecal discharge from the umbilicus.

\* Jordan, Max: Ueber Ileus verursacht durch den persistirenden Ductus omphalo-mesaraicus. Berlin. klin. Wochenschr., 1896, xxxiii, 25.

† Ward, Nathaniel: Trans. Path. Soc. London, 1856, vii, 205.

‡ Wilks, Samuel: Trans. Path. Soc. London, 1865, xvi, 126.

**INTESTINAL OBSTRUCTION DUE TO THE TIP OF MECKEL'S DIVERTICULUM  
BECOMING ADHERENT TO A DISTANT POINT.**

The following case reported by Sheen is a very good example of this group of cases:

**Fatal Intestinal Obstruction Due to Meckel's Diverticulum.\***—Case 2.—A. L. W., male, aged forty-one. Admitted to the Cardiff Infirmary, November 7, 1899.

“History.—Loss of flesh for one year. Present illness began with an attack of abdominal pain after supper nine days ago. Since then absolute constipation and constant vomiting, which has been fecal for the last six days. Has had two enemata without effect. Abdominal pain and latterly hiccough have been constant.

“Present Condition.—The man looks very ill, with cold extremities; pulse, 72, feeble; temperature, 97° F. Has vomited a little brown fluid matter, smelling fecal. Abdomen moderately distended, flanks and hypochondriac region somewhat flattened; some dulness above pubes; remainder resonant, peculiar hollow, high-pitched note over position of sigmoid flexure; no visible peristalsis; splashing sounds on manipulation; rectal examination negative; pain referred to umbilicus.

“The patient was given ether immediately, and the abdomen opened in the left iliac region. The colon was found empty; some distended coils of small intestine presented themselves, and the hand could feel something like a band on the right side, and apparently near the pelvic brim. The closure of the wound was commenced with a view to opening in the middle line, when, somewhat suddenly, the patient, whose condition was extremely serious throughout, collapsed and died. The trachea was opened, and various measures resorted to to restore animation, but without effect.

“Postmortem (Twelve Hours After Death).—Abdomen only opened through a crucial incision. No peritonitis. Small intestine distended and injected. Without disturbance, the seat of obstruction was at once seen in the form of a diverticulum of the bowel passing downward and outward from the median line, at a point about opposite to the third lumbar vertebra, toward the pelvic brim. On examination the diverticulum, which was devoid of a mesentery, was found to be about four inches long, bulbous at its commencement, then narrowing suddenly, but patent to its extremity. It sprang from the posterior aspect of the ileum, about two feet above the ileocecal valve, curved forward and inward round the bowel from which it came, and passed downward and inward, to be attached by its apex to the small intestine again, about five inches from the ileocecal valve. The obstruction of the ileum took place at the point of attachment of the apex of the diverticulum, which attachment was made by a few short, firm adhesions. The bowel was very near perforation at this point. The gut was also pressed upon somewhat at two points above the actual seat of obstruction: (1) Where the diverticulum wrapped itself around the ileum at its point of origin; (2) where a loop of bowel passed under the diverticulum. It was evident that the more distended the bowel became, the more would the diverticulum pull upon and kink its point of attachment.”

\* Sheen, William: Some Surgical Aspects of Meckel's Diverticulum. Bristol Medico-Chir. Jour., 1901, xix, 310.

OBSTRUCTION DUE TO THE PASSAGE OF INTESTINE THROUGH A HOLE IN THE  
MESENTERY OF MECKEL'S DIVERTICULUM.

I have not found the record of a similar case in the literature. The mesentery of the diverticulum, as a rule, is very slender and narrow, and even if a hole existed, the bowel would tend to pass not through but over it.

Umbilical Polyp; Intestinal Obstruction Due to Hernia through the Mesentery of Meckel's Diverticulum. Death.\*—“E. T. L., male, aged one year, nine months, admitted to the Cardiff Infirmary April 22, 1897.

“History.—Swelling at the navel since birth. The confinement was not attended by a doctor. The swelling has always been the same size. About a half-pint of glairy fluid comes from it in twenty-four hours, staining and stiffening the linen. The general health has always been good.

“Present Condition.—A healthy, well-nourished child. Attached to the center of the navel is a bright-red, bluntly lobulated, pedunculated tumor the size of a grape, with skin reaching only to its margin. The surface resembles intestinal mucous membrane and exudes a viscid fluid of alkaline reaction. In the center is a channel one inch deep. Through the parietes a cord the thickness of a cedar pencil can be felt passing backward for about  $1\frac{1}{2}$  inches. Urination and defecation are normal.

“After admission the fluid was collected as far as possible in a small glass vase strapped to the child's abdomen. The total amount in twenty-four hours was 10 to 15 c.c.; on two occasions, 22 c.c.; sometimes there were only 5 c.c., but then some was lost. It was a colorless, viscid fluid, and could be poured from vessel to vessel like a thin jelly; it was alkaline in reaction and contained a little albumin. It had no digestive action on fibrin or starch. So far as our examination went, therefore, it resembled succus entericus. On July 31st the tumor was removed with scissors and the base cauterized, the procedure being quite a slight one. The child vomited continuously after the anesthetic. On August 3d a simple enema was given, and the bowels moved twice; on the following days the child was fretful and became thinner; the milk was peptonized, but the vomiting continued, the vomitus consisting of undigested milk; the abdomen was distended and tender. The child grew worse. On August 7th a blood-streaked motion is stated to have been passed after an enema, but it was not saved by the nurse. Nutrient enemata were given toward the end, but the child died at 5 p. m. on August 7th, one week after operation. The cause of death was thought to be peritonitis.

“August 8th, Postmortem.—No peritonitis. Death was found to be due to intestinal strangulation. The parts involved were removed for separate examination. In the specimen removed were the lower part of the small intestine, cecum, appendix, and a small piece of ascending colon. Connected with the small intestine was a Meckel's diverticulum, patent to within an inch of the umbilicus, to which it was attached by a solid cord (Fig. 102). The skin around the umbilicus was removed by an elliptic incision.

“On dissection the following points were made out: (1) The bowel is strangulated by being herniated through a hole (A) in the mesentery of the diverticulum ilei. (2) The constricted bowel is 25 inches in length. (3) Practically all the bowel

\* Sheen, W.: Op. cit.

between the origin of the diverticulum and the ileocecal valve is strangulated. (4) The strength of the constricting cord of mesentery is largely due to a vessel traversing it. (5) The bowel is twisted within the ring and near perforation at its proximal end. (6) The diverticulum is bulbous in shape, and its lumen is much narrowed where it joins the intestine.

"Fig. [102] shows the condition, the strangulated loop represented as being turned out of the constricting ring (A). The polypus is shown. The position of the appendix was interesting. It lay against the diverticulum, with its apex pointing toward the liver.

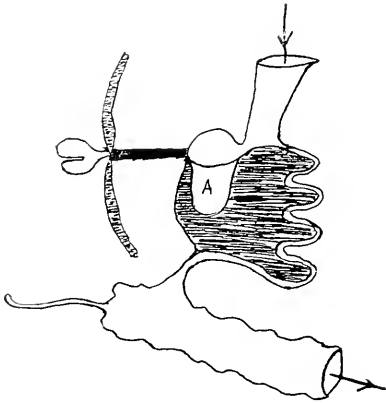


FIG. 102.—FATAL INTESTINAL OBSTRUCTION DUE TO THE PASSAGE OF THE BOWEL THROUGH A HOLE IN THE MESENTERY OF A MECKEL'S DIVERTICULUM. (After Sheen.)

Attached to the umbilical depression was a bright red, bluntly lobulated, pedunculated tumor the size of a grape. Its surface was covered with mucosa. In the center was a channel one inch deep, and through the abdominal walls a cord the size of a lead-pencil could be felt extending backward into the abdomen. The child developed intestinal obstruction and died. At autopsy 25 inches of small bowel were found to have passed through the hole (A) in the mesentery of Meckel's diverticulum. Practically all the bowel between the diverticulum and the ileocecal valve had become strangulated. The strength of the constricting cord of mesentery was due largely to a vessel traversing it. Meckel's diverticulum was bulbous in shape and much narrowed where it joined the small bowel.

previously, when she suddenly showed signs of intestinal obstruction. There was fecal vomiting for five days. The patient then improved, but did not get perfectly well. Three days before her admission the symptoms returned and rapidly grew worse. At operation the peritoneum was found to be markedly injected. The intestines were covered with fibrin and were lightly adherent, and in the pelvis was a thin, odorless fluid. Part of the small intestine was dilated, and the rest collapsed. No obstruction could be found, and there was no evidence of perforation. The fluid was wiped out, and an anastomosis made between the dilated and collapsed bowel. A drain was left in the lower angle of the wound. The patient died three days later.

"Microscopic examination of the polypus showed a connective-tissue basis, with a layer of intestinal glands—exactly like Lieberkühn's follicles. In places the intestinal glands were proliferating, so as to produce a mass resembling an ordinary intestinal adenoma.

"Clinically disappointing, this case is of great interest pathologically. The writer has been able to find no other record of a case of strangulation through the mesentery of a Meckel's diverticulum."

#### INVERSION OF MECKEL'S DIVERTICULUM INTO THE BOWEL.

The following case, recorded by Küttner, is a very rare one. The diverticulum had turned inside out, just as when one inverts the finger of a glove. It projected into the bowel and had caused obstruction and subsequent intestinal perforation.

Ileus Due to Intussusception of Meckel's Diverticulum.\*—This case was observed by Bruns. A woman, forty-nine years of age, had always been well up to eight weeks pre-

\* Küttner, H.: Ileus durch Intussusception eines Meckel'schen Divertikels. Beiträge zur klin. Chir., 1898, xxi, 289.

Autopsy.—The peritonitis had progressed. About 90 cm. from the beginning of the jejunum was an area of thickening 4 cm. long. Here there was a polyp-like structure 7 cm. long, having at its base a breadth of a thumb. It was a Meckel's diverticulum that had turned inside out and projected into the bowel (Fig. 103). The intestinal lumen at this point was somewhat narrowed. The portion of the bowel at the point of the insertion of the diverticulum had also become drawn into the lumen. Near the base of the diverticulum was a gangrenous spot and a small perforation.

Küttner then gives the report of seven other cases which he had collected from the literature. These were those of Maroni, Ewald, St. Bartholomew's Hospital, Adams, and three recorded by Heller.

#### TREATMENT OF OBSTRUCTION DUE TO MECKEL'S DIVERTICULUM.

Fitz, who devoted to this subject a most thorough and exhaustive study in 1884, arrives at the following conclusions:

"1. Bands and cords as a cause of acute intestinal obstruction are second in importance to intussusception alone.

"2. Their seat, structure, and relation are such as frequently to admit their origin from obliterated or patent omphalomesenteric vessels, either alone or in connection with Meckel's diverticulum, and oppose their origin from peritonitis.

"3. Recorded cases of intestinal strangulation from Meckel's diverticulum, in most instances, at least, belong in the above series.

"4. In the region where these congenital causes are most frequently met with, an occasional\* cause of intestinal strangulation, *viz.*, the vermiform appendage, is also found.

"5. It would seem, therefore, that, in the operation of abdominal section for the relief of acute intestinal obstruction not due to intussusception, and in the absence of local symptoms calling for the preferable exploration of other parts of the abdominal cavity, the lower right quadrant should be selected as the seat of the incision. The vicinity of the navel and the lower three feet of the ileum should then receive the earliest attention. If a band is discovered, it is most likely to be a persistent vitelline duct, Meckel's diverticulum, or an omphalomesenteric vessel, either patent or obliterated, or both these structures in continuity. The section of the band may thus necessitate opening the intestinal canal or a blood-vessel of large size. Each of these alternatives is to be guarded against, and the removal of the entire band is to be sought for, lest subsequent adherence prove a fresh source of strangulation."

"The chief practical conclusion thus reached in this article is essentially the same

\* If Reginald Fitz were living today and rewriting this paragraph he would, remembering his epoch-making studies on appendicitis, replace "occasional" by the word "frequent."

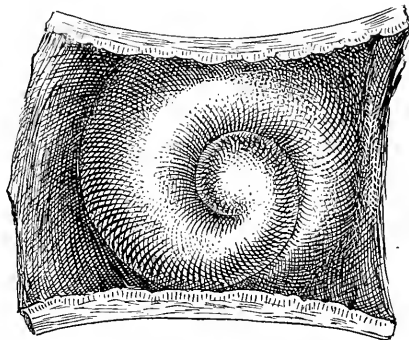


FIG. 103.—INVERSION OF MECKEL'S DIVERTICULUM INTO THE LUMEN OF THE BOWEL. (Redrawn after Küttner.)

The patient was a woman aged forty-nine. In this case Meckel's diverticulum was virtually turned inside out, and is seen lying in the bowel. The condition produced obstruction and death.

as that of Nélaton.\* This surgeon advised that the incision through the abdominal wall for the relief of intestinal obstruction should be made a little above Poupart's ligament, preferably in the right side. The knuckle of intestine first presenting was to be united to the edges of the wound and incised, an intestinal fistula being thus established. His recommendation was based upon the applicability of this operation—enterotomy—to all cases of intestinal obstruction, since it is usually impossible to make a differential diagnosis of the cause of ileus. The place was selected because a loop of small intestine above the seat of obstruction is likely to be found in this part of the abdomen, and it is also likely to be so far from the stomach that a sufficiency of intestine for digestive purposes will be left intact.

“The due appreciation of the relative frequency of congenital causes of intestinal obstruction acting in the region recommended by Nélaton as the place of operation adds force to his arguments. The operation of enterotomy in the best favored position is still available, provided the above causes of obstruction are not found.”

These suggestions, made by Nélaton in 1857, and by Fitz in 1884, are in thorough accord with the surgical views of to-day. Thirty years have elapsed since Fitz wrote his article. To-day the cases are, fortunately, often recognized early. The surgeon will make a right rectus incision, which can be extended upward or downward and the obstruction relieved or the cause removed, as the case may be. In addition to this, due consideration must be given to the question whether the partly paralyzed bowel can expel its contents even after the obstruction has been removed. If there is any doubt on this point, it is the duty of the surgeon to bring up a loop of bowel above the point where obstruction has existed, attach it to the abdominal wall, and open it a few hours later.

In the late cases, when the patient is too weak for any prolonged operation looking to the relief of the obstruction, a loop of the distended bowel should be brought up into the incision and an enterostomy made with the hope that in a few days the patient will be strong enough to withstand the more radical procedure.

\* Nélaton: *L'Union médicale*, 1857, xi, Nos. 89, 91, 93.

#### LITERATURE CONSULTED ON MECKEL'S DIVERTICULUM.

- Beck, B.: Ueber das angeborne Divertikel des Krummdarms. *Illustr. Med. Zeitung*, München, 1852, ii, 294.
- Bize: Étude anatomo-clinique des pancréas accessoires situés à l'extrémité d'un diverticule intestinal. *Revue d'orthopédie*, 1904, xv, 149.
- Blanc, H.: Contribution à la pathologie du diverticule de Meckel. Thèse de Paris, 1899, No. 393.
- Cazin, Henry: Étude anatomique et pathologique sur les diverticules de l'intestin. Thèse de Paris, 1862, No. 138.
- Denucé: Fistules pseudo-pyloriques congénitales de l'ombilic. *Revue d'orthopédie*, 1908, xix, 1.
- Dévé, F.: Des tératomes "entéroïdes." A l'occasion d'un cas de "tumeur entéroïde pancréatique." *La Normandie méd.*, 1906, xxi, 169.
- Elliot, J. W.: Strangulation of Meckel's Diverticulum Caused by Volvulus of the Ileum. *Trans. Amer. Surg. Assoc.*, 1894, xii, 217.
- Fitz, R. H.: Persistent Omphalomesenteric Remains: their Importance in the Causation of Intestinal Duplication, Cyst-formation, and Obstruction. *Amer. Jour. Med. Sci.*, 1884, lxxxviii, 30.
- Huggins, R. R.: Personal communication.
- Jordan, Max: Ueber Ileus verursacht durch den persistirenden Ductus omphalo-mesaraicus. *Berlin. klin. Wochenschr.*, 1896, xxxiii, 25.
- Kelly and Hurdon: *The Vermiform Appendix and its Diseases*. W. B. Saunders Co., 1905.



- Kern, T.: Ueber die Divertikel des Darmkanals. Inaug. Diss., Tübingen, 1874.
- King, T. W.: A Feculent Discharge at the Umbilicus from Communication with the Diverticulum Ilei. *Guy's Hospital Reports*, 1843, i, 2. series, 467.
- Küttner, H.: Ileus durch Intussusception eines Meckel'schen Divertikels. *Beiträge zur klin. Chir.*, 1898, xxi, 289.
- Löwenstein: Der Darmprolaps bei Persistenz des Ductus omphalo-mesentericus, mit Mittheilung eines operativ geheilten Falles. *Langenbeck's Arch. f. klin. Chir.*, 1894-95, xlix, 541.
- Meckel, Johann Friedrich: *Handbuch der pathologischen Anatomie*, 1812, i, 553.
- Richardson, W. G.: A Case of Abnormally Large Meekel's Diverticulum found Postmortem. *Quart. Med. Jour.*, 1894-95, iii, 267.
- Schroeder, G.: Ueber die Divertikel-Bildungen am Darm-Kanale. Inaug. Diss., Augsburg, 1854.
- Sheen, W.: Some Surgical Aspects of Meekel's Diverticulum. *Bristol Medico-Chir. Jour.*, 1901, xix, 310.
- Struthers, John: *Anatomical and Physiological Observations*, Edinburgh, Part I, 1854, 137.
- Tillmanns, H.: Ueber angeborenen Prolaps von Magenschleimhaut durch den Nabelring (Ectopia Ventriculi) und über sonstige Geschwülste und Fisteln des Nabels. *Deutsche Zeitschr. f. Chir.*, 1882-83, xviii, 161.
- Treves, Frederick: *Allbutt's System of Medicine*, 1897, iii, 802.
- Ward, N.: Fatal Intestinal Obstruction in Consequence of a Twist in the Mesentery and the Falling of Some Folds of Intestine over a true Diverticulum. *Trans. Path. Soc. London*, 1856, vii, 205.
- Wilks, Samuel: Strangulation of Intestine by Diverticulum Ilei. *Trans. Path. Soc. London*, 1865, xvi, 126.

## CHAPTER IX.

### INTESTINAL CYSTS.

Classification.

Intestinal cysts developing from the omphalomesenteric duct or Meckel's diverticulum.

1. Intestinal cysts lying relatively free in the abdomen.
2. Intestinal cysts lying between the layers of the mesentery.
3. A cyst of the central portion of the omphalomesenteric duct.

Symptoms of intestinal cysts.

Treatment.

INTERESTING cases of intestinal cysts were recorded by Cazin in 1862, and by Hennig in 1880, but it is to the splendid article of Roth, published in 1881, that we are indebted for the first clear and exhaustive presentation of the subject.

Fitz, in his monograph in 1884, dealt with intestinal cysts at length.

Runkel reported an interesting series of cases in 1897, and his admirable article should be read by all who desire to acquire a full knowledge of the subject. In addition to his own cases he reported the observations of Roth, Tscherning, Ditt-rich, Nasse, Buchwald, Kulenkampff, Hüter, Rimbach, and Löhlein.

In 1906 Colmers published an article upon intestinal cysts and their treatment. He says that Raesfeld was the first to describe an enterocystoma, and that he drew attention to the fact that it developed from what we now call Meckel's diverticulum.

Roth says that these sacs are filled with fluid, and that the structure of their walls resembles more or less that of the intestinal canal. He divides intestinal cysts into two groups:

**Group I.**—Those in which the originally normally formed intestinal tract is divided into several isolated cystic sacs. The division of the intestine occurs usually as a result of a peritonitis, and according to Rokitansky, occasionally as a result of a twisting of the mesentery. In such cases the nipping-off of the bowel into isolated segments naturally severs its continuity and soon causes the death of the child.

**Group II.**—To the second group belong the intestinal cysts which originate from an abnormal development of the intestinal tract. The cysts are present, but we also have a permeable intestinal canal; consequently from this standpoint the life of the child is not in danger.

Roth subdivides Group II into three varieties:

**A.** Superfluous and cystically dilated portions of the intestine belonging to rudimentary twin pregnancies, as in Case E of Schärer-Klebs, in Klebs' *Handbuch der spec. path. Anat.*, i, 1013.

**B.** Intestinal cysts occurring in combination with abnormal deposits, and occasionally with growing organs and portions thereof. In this group he included a case of Säger and Klopp. In this connection it may be of interest to refer to a case observed by Simmons and reported by Cazin in 1862. The patient was a well-formed female child, two years old. At autopsy a tumor was found situated at the base of the vertebral column. It consisted of fat, bones, etc., and also contained a

large quantity of intestine, part of which belonged to the ileum and part to the colon, the appendix being attached to the latter.

[Several years ago, while opening a dermoid cyst the size of a child's head at the Johns Hopkins Hospital, I found that it contained a relatively large cavity partly filled with fluid. This cavity also contained a perfectly formed loop of small bowel (Fig. 104). The tumor was opened immediately after its removal and while still

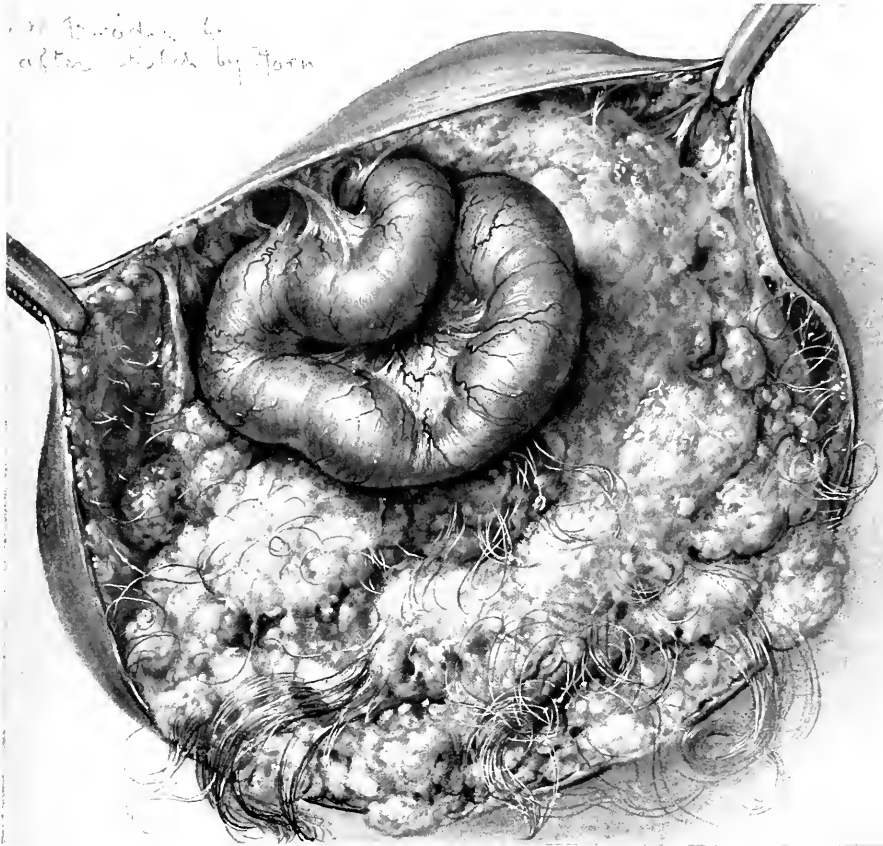


FIG. 104.—A WELL-DEVELOPED LOOP OF SMALL BOWEL IN A DERMOID CYST OF THE OVARY.

Gyn. No. 14118. Path. No. 11728. The patient was a white woman, twenty-eight years old, who had a cyst of the left ovary about 16 cm. in diameter. When the cyst was opened, a large cavity, partly filled with sebaceous-like material and hair, was found, and at one side was a well-developed loop of small bowel. This had a well-defined mesentery, and on being handled the bowel contracted, showing a definite peristalsis. August Horn at once made a sketch of this rare condition. The specimen has disappeared, and Mr. Brödel has made the drawing from Horn's original sketch.

warm. It was easy to follow the wave of contraction in the bowel, just as in the normal intestine.]

C. A simple intestinal cyst developing from the adherent normal lateral appendages of the intestine, most frequently from Meckel's diverticulum.

A full discussion of the entire subject of intestinal cysts does not come within the province of this book. We must, however, carefully consider Class C, in Roth's Group II, to which belong intestinal cysts probably arising from remnants of the omphalomesenteric duct or from Meckel's diverticulum.

## INTESTINAL CYSTS DEVELOPING FROM THE OMPHALOMESENTERIC DUCT OR MECKEL'S DIVERTICULUM.

From a survey of the recorded cases it is perfectly clear that these cysts may be divided into two groups:

1. Intestinal cysts lying relatively free in the abdomen.
2. Intestinal cysts lying between the layers of the mesentery.

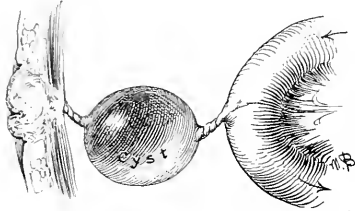


FIG. 105.—AN INTESTINAL CYST. (Schematic.)

Most of the intestinal cysts found have been due to partial or complete torsion of Meckel's diverticulum, which had taken place so gradually that no gangrene occurred. In rare instances both the outer and inner ends of the omphalomesenteric duct become obliterated, while the central portion remains patent. The accumulation of the secretion from the mucosa in time produces an intestinal cyst. The above is a schematic representation of a small intestinal cyst of this nature.

The tumor was attached to the convex surface of the small bowel.

In Rimbach's case the tumor was the size of a man's head, wrapped up in omentum, and attached to the small bowel by a solid cord.

In Roth's case the tumor measured 6.2 x 5.3 x 3.6 cm.; it was cystic and enveloped in omentum. It sprang from the mesenteric attachment of the bowel by a twisted pedicle. The pedicle had a lumen which was patent.

It is evident that in these cases the cystic tumor had originated from a Meckel's diverticulum (Fig. 105).

The tumor tends to become adherent to the omentum and to the neighboring structures (Fig. 106). The inner surface of the cyst is lined with intestinal mucosa, which may be somewhat inflamed.

The character of the cyst contents will depend on whether or not there is a connection with the intestinal cavity. In those cases in which the cyst has been cut off before meconium has had a chance to get into it, the contents will be glairy mucus mixed with exfoliated epithelium and sometimes with a little pus and blood.

\* A *Linie* varied from one-twelfth to one-tenth of an inch.

## INTESTINAL CYSTS LYING RELATIVELY FREE IN THE ABDOMEN.

Tiedemann, Carwardine, Hendee, Rimbach, Roth, and Fitz have reported cases of this character. In Tiedemann's case, published in 1813, a pear-shaped cyst, 14.5 x 7 *Linien*,\* was attached to the convex surface of the bowel by a pedicle 3.5 *Linien* long. The cyst communicated with the bowel through the pedicle.

In Carwardine's case the tumor occupied the right upper abdomen and was twisted. Its pedicle was attached to the small bowel. The cyst was densely adherent.

In Hendee's case the tumor consisted of two portions. One portion lay in an inguinal hernia.

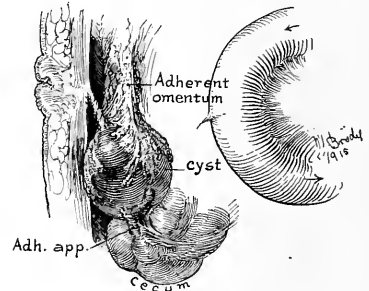


FIG. 106.—AN INTESTINAL CYST ATTACHED TO THE UMBILICUS BY A PEDICLE BUT NOT CONNECTED WITH THE BOWEL. (Schematic.)

On comparing the cyst with the bowel, it is found to be several centimeters in diameter. It is attached to the umbilicus by a well-developed and twisted pedicle. The omentum is plastered over its surface, and below it is adherent to the appendix and cecum. The small bowel has a tag projecting from it, possibly at the point where the omphalomesenteric duct formerly existed. The picture is a schematic representation of a condition very rarely noted.

An Intestinal Cyst Developing from a Meckel's Diverticulum. — Tiedemann,\* quoted by Roth,† in examining a male fetus at term with a double-sided harelip and an accessory little finger on each hand, observed an umbilical hernia the size of a large walnut. In this lay a portion of intestine. It showed a pear-shaped, bladder-like formation, 14.5 *Linien*‡ long and 7 *Linien* in its transverse diameter. It had a pedicle 3.5 *Linien* long, and lay attached to the convex surface of the intestine by a narrow canal which admitted a probe. The bladder-like projection contained whitish-yellow fluid, and had originated through a canal communicating with the cavity of the intestine.

Volvulus of Meckel's Diverticulum. § — The patient was a child, two days old, who had intestinal obstruction and greenish vomiting. There was no fecal matter passing by the bowel and no discharge from the umbilicus. The abdomen was much distended. Rectal examination was negative. The child was watched for six hours, but nothing passed by the bowel.

When the abdomen was opened, the small intestine was found to be very much distended and covered with lymph. The colon was not larger than a crow's quill, whitish-yellow in color, and non-sacculated. A mass could be felt to the right of the umbilicus. Here the gut was much distended, and there were so many adhesions that the bowel could not be brought out. The source of the obstruction could not be determined, but at autopsy was found to be due to an anomaly of Meckel's diverticulum.

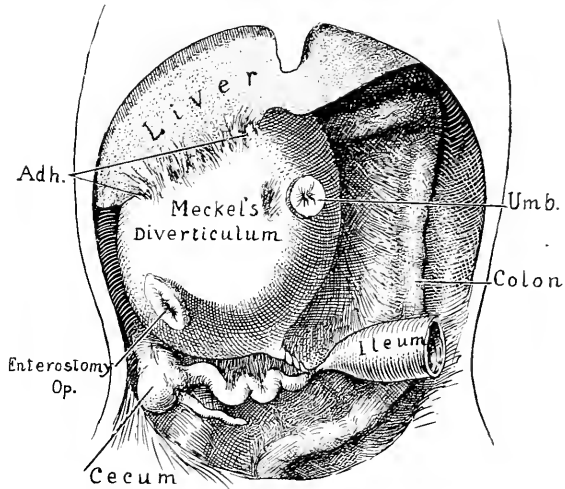


FIG. 107.—VOLVULUS OF MECKEL'S DIVERTICULUM. (Redrawn after Carwardine.)

The child was two days old and had passed nothing by the bowel. There was no discharge from the umbilicus. The abdomen was markedly distended. At operation a large sac was detected and opened, but the child died twenty-four hours later. The cyst was a greatly distended Meckel's diverticulum. This had twisted three times, and an impervious cord connected it with the bowel. The lower end of the small bowel was empty and tortuous. The colon was small and sacculated. No meconium had ever reached the rectum.

An artificial anus was made, and several ounces of meconium escaped. The cecum and ascending colon were found to be hard and small. The child died twenty-four hours later. The cyst was made up of a greatly distended Meckel's diverticulum with three twists (Fig. 107). Only a fine, impervious cord connected it with the bowel. Carwardine noted the following as the points of interest in this case: (1) An acute commencement of peritonitis before birth; (2) the occurrence of a volvulus of Meckel's diverticulum *in utero* during late fetal life, so that a meconium-contain-

\* Tiedemann: *Kopfloße Missgeburten*, 1813, S. 66, Taf. 4.

† Roth: *Virchows Arch.*, 1881, kxxvi, 371.

‡ A *Linie* varied from one-twelfth to one-tenth of an inch.

§ Carwardine, T.: *Brit. Med. Jour.*, 1897, ii, 1637.

ing cyst was segmented off from the ileum, and consequently the obstruction was not relieved by an opening into the distended diverticulum; (3) the lower 12 inches of small bowel were empty and tortuous. The colon was small and non-sacculated. No meconium had ever passed into them; yet the cecum and appendix were well formed.

**A Solid Tumor\* Probably Developing from Remnants of the Omphalomesenteric Duct.†**—In an inguinal



FIG. 108.—AN INTESTINAL CYST DEVELOPING FROM MECKEL'S DIVERTICULUM. (After Roth.)

The cyst in front and above has omentum adherent to it. From the ileum a sound has been carried into the hollow pedicle; the latter is crossed by a small mesentery.

a short, completely solid pedicle. The cyst was not lined with mucosa, but in its walls were two definite layers of muscle.

**An Intestinal Cyst Developing from a Diverticulum of the Ileum and Continuing with the Bowel; Beginning Peritonitis Due to Torsion of the Pedicle.‡**—A boy,

hernia there was a small cylindrical tumor. This communicated with a second mass, which lay in a chronically inflamed omentum and was connected by a cord the size of a penholder. The median portion of the last-named tumor was attached to the small intestine on its convex side, 32 cm. above the ileocecal valve. This could be traced to the submucosa of the bowel. Both tumors and the cord were completely solid, and consisted of connective tissue with numerous deposits of chalk. Colmers said that Hendee's case affords a good example of the difficulty of making an anatomic diagnosis of the remains of the omphalomesenteric duct.

**An Intestinal Cyst Due to Dilatation of Meckel's Diverticulum.**—In Rimbach's‡ case there was a cyst the size of a man's head. This was wrapped up in omentum and attached to the small bowel by

\* This tumor, although solid, was at first probably cystic, and is accordingly included here.

† Hendee, cited by Colmers: *Arch. f. klin. Chir.*, 1906, lxxix, 132.

‡ Rimbach, quoted by Colmers: *Loc. cit.*

§ Roth, M.: *Ueber Missbildungen im Bereich des Ductus omphalomesentericus*. *Virchows Arch.*, 1881, lxxxvi, 371.

sixteen months old, up to a month and a half before admission, had always been healthy. His stools became irregular, constipation and diarrhea alternating. About three weeks before admission the child had to remain in bed for two weeks, and for three days had marked vomiting. He died with definite signs of intestinal obstruction. At autopsy the abdomen was found distended above the umbilicus, where the intestinal loops were prominent. Below the umbilicus, in front of the mesentery, was a transverse, oval, reddish, moderately distended tumor (Fig. 108).

This tumor was 6.2 cm. in its transverse diameter, 5.3 cm. in its vertical, and 3.6 cm. in its anteroposterior diameter. It was for the most part smooth, but above and to the left it was firmly adherent. Above the anterior surface and to the right were delicate adhesions to the greater omentum. In the omentum large vessels were seen. On the under and right margin of the tumor was a pedicle 11 mm. long. This passed to the concave surface of the ileum, close to the insertion of the mesentery. The cyst was situated 66 cm. above the ileocecal valve. The pedicle consisted of two portions, one of which was conic in shape and measured 11 mm. in breadth at the ileum, whereas at the tumor it was only 4 mm. broad. Along the base the intestine had become twisted from right to left. The second portion of the pedicle, which was connected with the first, passed upward and to the left and extended to the base of the tumor. The pedicle ended in the mesentery, and was covered with peritoneum. It consisted of fatty tissue and of several vessels which passed to the wall of the tumor; in other words, this was the mesentery of the tumor. When the tumor, which was otherwise free, was turned from the left forward and to the right for 90 degrees, the torsion of the conic portion of the intestine at its crossing with the mesentery was released. The lower portion of the abdominal cavity contained a few drops of turbid yellow fluid. When the cyst was opened, air and 32 c.c. of thick, brownish-red fluid mixed with mucus and reddish flocculi escaped. The fluid consisted almost entirely of pus-cells intermingled with red blood-corpuscles and cylindrical cells.

The reddish threads proved to be hemorrhagic infiltration. The wall of the cyst was 2 mm. thick, and at every point was as well developed as that of the ileum. The inner surface was partly ulcerated, but for the most part had a lining of a soft, velvety, dark-red membrane. The latter showed, on microscopic examination, a lining of cylindrical cells and Lieberkühn's glands. Beneath the mucosa came the sub-mucosa, then the ring muscle, and then the outer longitudinal muscle. In the sub-serous connective tissue were large vessels and an abundance of fat-cells, and then, covering the cyst, was peritoneum. In the lower part of the cyst, in the swollen, dark-red mucosa, was a minute opening not larger than a linseed, through which a sound could be passed into the ileum. The conic-shaped portion of the pedicle was not larger than a bean. This lay parallel with the long axis of the intestine near the mesenteric border, but on the concave side of the intestine.

From the above it is seen that the abdominal cyst corresponded to the end of the diverticulum, which still communicated with the intestine and which had a mesentery. This diverticulum showed a distinct intestinal structure. It was covered over with an inflammatory deposit and adherent omentum. The peritonitis was, without doubt, due to torsion of the pedicle.

A Cyst of Meckel's Diverticulum. — Fitz,\* in the Warren Museum, found the following record in the manuscript catalogue (under No. 4903):

\* Fitz, R. H.: Amer. Jour. Med. Sci., 1884, lxxxviii, 30.

**Diverticulum from the Small Intestine.**—The specimen was obtained at autopsy from a patient dead of chronic pleurisy. There were no symptoms during life to call attention to its existence. It was given off from the small intestine about 1 meter above the ileocecal valve. It was 3 cm. in length and about 1 cm. in diameter. There was no apparent communication with the lumen of the intestine. This specimen was a cyst of the diverticulum, the origin of which was near the mesenteric attachment. Its walls consisted of a peritoneal envelope with loose subperitoneal connective tissue, both continued directly from the intestine. There was a dense middle coat, resembling in appearance the muscular layer of the intestine, although elongated nuclei were not to be made out; finally, an inner membranous lining, upon the free surface of which occasional club-shaped stunted villi were found to project. Pouch-like depressions with circular openings upon the free surface were found scattered throughout this membrane. Epithelium was not present. The middle and internal coats were in the closest proximity to the corresponding layers of the ileum.

Fitz speaks of cysts noted in the region of the duodenum, and cites a case of a cyst of the esophagus observed by Wyss. He mentions cases reported by Roth and Hennig in which there were cysts in the vicinity of the esophagus.

#### INTESTINAL CYSTS LYING BETWEEN THE LAYERS OF THE MESENTERY.

Cases of this character have been recorded by Buchwald, Hennig, Kulenkampff, and others. The cysts are situated in the mesentery of the bowel, usually a short distance from the ileocecal valve. They may be round or pipe-shaped. They show a peculiar tendency to form sickle-like contractions on their inner surface. The cyst is, accordingly, partially divided into separate chambers. These partial divisions may completely block off a portion of the cyst, giving rise to an isolated and walled-off secondary cyst. The cysts may or may not communicate with the lumen of the bowel. They are lined with intestinal mucosa. Where they are completely shut off from the bowel, they may be filled with clear fluid, as was noted in Hennig's case, in which the tumor reached large proportions, measuring 22 x 14 x 10 cm.

**A Large Intramesenteric Enterocystoma.\***—The patient had a large intramesenteric double cyst. This at one point showed an epithelial lining. It communicated with the bowel.

**Intestinal Cyst and an Esophageal Cyst in a New-born Infant.†**—In this case the labor was a very difficult one, and the child died before delivery. A hook was introduced into the chest and then a perforation was found advisable. Pressure on the abdomen caused a discharge of about 3000 c.c. of clear fluid from the child. The mother made a good recovery. The length of the child's body was 45 cm. In the abdomen was a sac which had not been injured, and reminded one of a partially filled stomach of a grown person. Passing to it were numerous large blood-vessels, which behind and in front of it went to the ileum.

The ileum lay peripherally to the sac, near the point where it passed over into

\* Buchwald: (Colmers, *Loc. cit.*).

† Hennig, C.: *Cystis intestinalis, Cystis citra œsophagum bei einem Neugeborenen.* *Centralbl. f. Gyn.*, 1880, iv, 398.



the cecum. There was no communication between the ileum and the sac. The sac was 22 cm. long, 14 cm. broad, and 10 cm. thick. It contained about 100 c.c. of almost clear, slightly reddish, somewhat sticky fluid, which was suggestive of intestinal fluid. The large bowel was empty and much contracted. (We have purposely omitted a description of the esophageal cyst.)

Microscopic examination showed that the intestinal cyst was lined with cylindrical epithelium; in its walls intestinal glands were demonstrable. The sac was a large intestinal cyst which lay in the mesentery. This specimen was examined by Weigert.

**A N I N T E S T I N A L C Y S T ; D E A T H F R O M I N T E S T I N A L O B S T R U C T I O N . \***—The patient, a poorly developed boy three years old, had died with signs of intestinal obstruction. At autopsy a cyst was found in the mesentery of the small bowel, 40 cm. from the ileocecal valve. It was the size of a man's fist, had very thin walls, and was almost translucent. It had several sickle-like constrictions, partially dividing it into semi-spheroid sacs. There was no communication with the bowel. The cyst was filled with very thin, chocolate-colored fluid. Kulenkampff refers to Roth's article. In this case no microscopic examination was made.

In the following case, recorded by Roth,† there was not only a cyst attached to the bowel, but also one in the mesentery and another in the thorax:

**A C O N G E N I T A L I N T E S T I N A L C Y S T S E P A R A T E D F R O M A D I V E R T I C U L U M S I T U A T E D I N T H E M E S E N T E R Y ; I N A D D I T I O N , I N T E S T I N A L C Y S T S O F T H E A B D O M I N A L A N D T H O R A C I C C A V I T I E S ; C O M P R E S S I O N O F T H E A I R - P A S S A G E S .**—The specimen and the history came from Roth's colleague, J. J. Bischoff. Elsie B., aged nineteen years, was delivered easily. Immediately after there was an escape of 3000 c.c. of amniotic fluid. The child, a male, was small. Movement of its extremities was noted, and an attempt to breathe was detected. The abdomen was markedly distended. Notwithstanding artificial respiration, the child died in ten minutes. The body was 42 cm. long. There was marked edema of the umbilical cord; on the left side was a hydrocele. When the greatly enlarged abdomen was opened, a large, thin-walled cystic tumor with numerous vessels covering it was found beneath the liver. This tumor covered the stomach and the duodenum. A few loops of small bowel lay over the tumor; others lay to the left, and through the walls of the latter a small quantity of meconium could be seen.

A more careful examination of the tumor showed that it consisted of two parts: the one on the left and in front was the size of a hen's egg (Fig. 109, *b*); the other (*b'*) was only a third as large. The latter lay in the cecal region, and the cecum was pushed over to the median line. The stomach was in the normal position, and contained a little tenacious, yellowish mucus. The spleen, adrenals, kidneys, and bladder showed nothing unusual. The thymus gland was the size of a hazel-nut. The lungs were atelectatic. The pleuræ showed ecchymotic spots. The foramen ovale was the size of a pea. Near the right lung, and covered by it, was

\* Kulenkampff, D.: Ein Fall von Enterokystom. Tod durch Darmverschlingung. *Centralbl. f. Chir.*, 1883, x, 679.

† Roth, M.: Ueber Missbildungen im Bereich des Ductus omphalomesentericus. *Virchows Arch.*, 1881, lxxxvi, 371.

a fluctuating tumor which sprang from the vertebral column and was covered by the costal pleuræ. The esophagus passed obliquely above the left half of the tumor, and was easily dissected from it (Fig. 109, *c*).

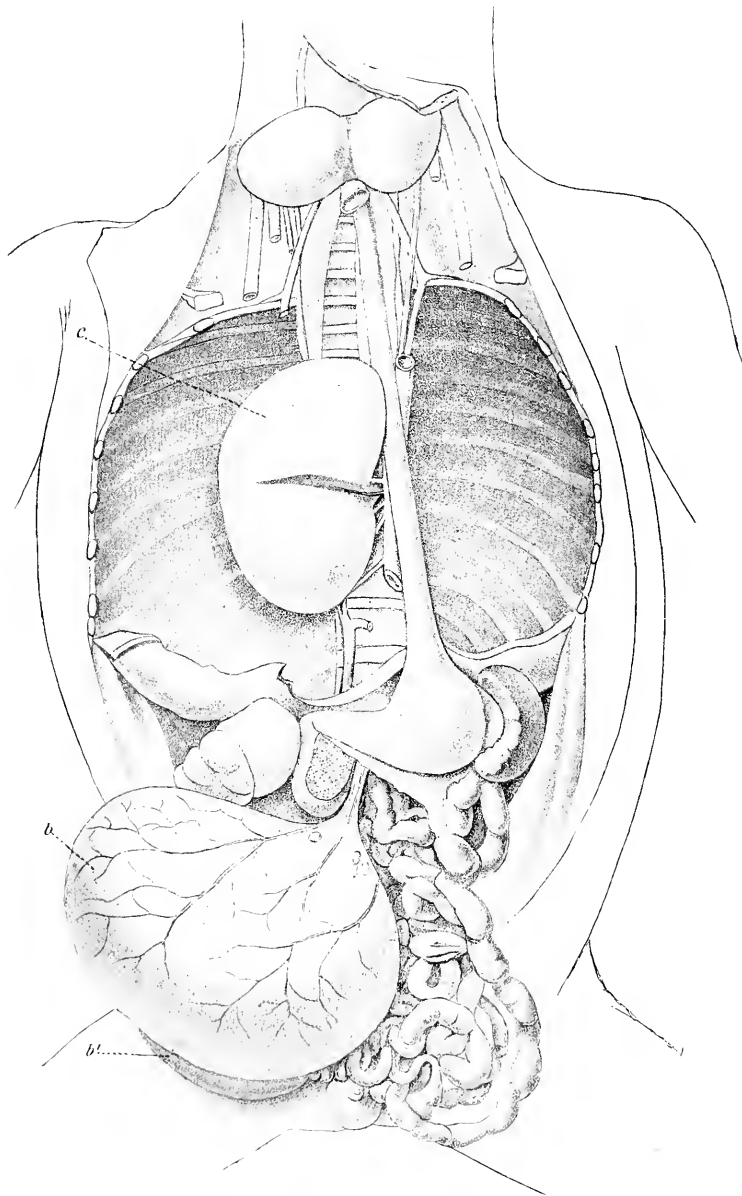


FIG. 109.—INTESTINAL CYSTS IN THE ABDOMINAL CAVITY. (After Roth.)

The heart, lungs, and liver have been removed. The ascending colon has been thrown to the left, and the pedicle of the cysts (*b* and *b'*) has been freed. On the upper surface of the cyst (*b*) are several lymph-glands. The spleen, stomach, duodenum, and the right kidney are visible; also remnants of the diaphragm. To the left of the cyst (*c*), which lay in the thoracic cavity, are the esophagus and the doubly cut aorta.

There was a marked swelling over the left temporal vein, and numerous ecchymoses were encountered in the dura. The pia mater was edematous, and the vessels

were engorged and tortuous. The ventricles were dilated and contained bloody fluid.

In the abdominal cavity, in addition to the above-mentioned tumors (Fig. 109, *b* and *b'*), there was still another which lay between the layers of the mesentery and close to the lower portion of the ileum. This was a sausage-shaped cyst (Fig. 110, *a*), which lay close to the concave wall of a loop of the ileum. The mesenteric vessels passed on the top of, over, and beneath the tumor to the intestinal canal, and from these vessels numerous small branches went into the cyst. This mass itself resembled a sausage and was somewhat club-shaped. Its upper end was directed toward the jejunum, and it had a knob-like end, 13 mm. broad. Here the tumor had a greater diameter than the small intestine. The smaller, lower end terminated in an extremity having a diameter of over 5 mm.

When the ileum was opened, it was seen that the lower end of the mesenteric tumor projected into the intestine and then opened into it through a roundish aperture (Fig. 110, *x*). The opening followed the direction of a very acute angle. In the picture the edges of the opening have been spread with a glass rod, and in this way the original prominence has been much exaggerated. The opening was situated at a point 14.5 cm. above the ileocecal valve. The length of the club-shaped tumor was 10 cm. A sound introduced into the intramesenteric diverticulum encountered several ring-like narrowings through which only a bristle could be passed. The swollen end of the diverticulum (Fig. 110, *a*) did not admit the sound. On being opened, it was seen that in this portion was a cyst the size of a bean that had been completely cut off from the remaining portion of the diverticulum. The diverticulum contained no yellowish material, but in the lower portion was mucus. The small cyst contained thick masses which, on microscopic examination, showed numerous glistening round-cells without nuclei.

The walls of the diverticulum were similar to those of the intestinal canal, and the inner surface was lined with a single row of cylindric goblet-cells with Lieberkühn's glands beneath. The small cyst was different in structure. The outer coats were similar to those of other portions of the diverticulum. The septum between the cyst and the diverticulum did not contain longitudinal muscle in the subserous layers. The mucosa was very thin. The upper surface was partly flat. Lieberkühn's glands were entirely wanting. The inner surface was lined with ciliated epithelium.

The abdominal cyst, which consisted of two apparently separate sacs (Fig. 109,

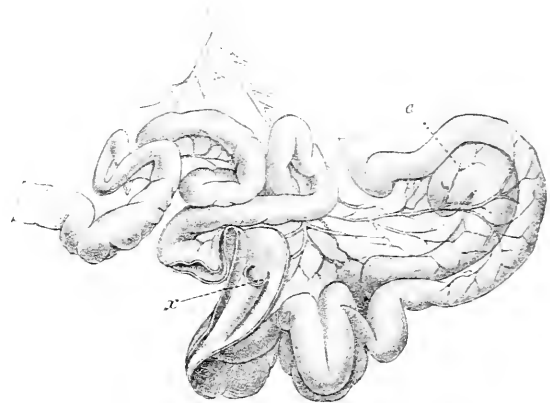


FIG. 110.—AN INTRAMESENTERIC CYST. (After Roth.)

The specimen shows the lower portion of the ileum, with the mesentery, vermiform appendix, and ascending colon. The anterior fold of the mesentery has been removed. The branching of the superior mesenteric vein and the larger portion of the diverticulum lie on the concave side of the intestine and have been dissected free. *a* is the outer cyst, which has been but incompletely developed from the diverticulum. *x* indicates the ostium, which has been made visible through the splitting open of the intestine.

*b* and *b'*), anteriorly, above, and below was covered with a glistening peritoneum, and occupied a large portion of the middle of the right abdominal cavity. Both sacs were easily moved on one another in various directions. Only in the region of the pancreas and on the lower portion of the duodenum were they fixed. On dissection it was found that there was a short pedicle, 1 cm. long, between the anterior round and the lower sausage-like mass. The pedicle was 2 mm. broad, and had a canal 0.5 mm. in diameter, which joined the two cavities. There was no open connection between the intestinal canal and the cysts. The whole tumor, on its posterior and left side, was attached by a rather firm connective tissue to the superior mesenteric artery from its point of origin beneath the pancreas. There was no direct connection with the vertebral column.

The superior mesenteric artery was 1.6 mm. thick, and formed in its middle course three ring-shaped anastomoses. It gave off from its right side, 9 mm. below the art. colica dextra, the art. ileo-colica, which was 1 mm. in diameter. The largest branch of this supplied the cyst (*b*). Eleven millimeters further on, it gave off a branch which supplied the small cyst (*b'*).

On the upper surface of the cyst these vessels formed an extensive network which, on the one side, anastomosed with the arteriæ intestinales, and on the other side with the arteria colica dextra. The veins had relations similar to those of the arteries. There were numerous nerves and also veins over the surface of the cyst (*b*).

Lymph-glands were also present under the serosa.

Thus the large abdominal cyst was retroperitoneal in the right portion of the mesentery, and had pushed the mesentery in a pouch-like manner before it. It was supplied by two branches of the superior mesenteric artery. The portion (*b*) contained 34 c.c. of tenacious, somewhat flocculent fluid. The fluid gave a reaction for mucin. The inner surface of the cyst was smooth. The thickness of the wall varied: near the vertebral column it reached a maximum of 1.5 to 2 mm. On microscopic examination all the layers of the intestinal wall could be identified. The mucosa, however, was very thin, and only where the inner surface was rough were there villus-like elevations. The inner surface was lined with cylindric epithelium, but the mucosa was hardly sufficiently developed to form glands. The portion (*b'*) corresponded in the main with (*b*) and only differed in that the walls were thinner and there were more folds. The surface was lined with cylindric cells and goblet-cells, and here and there in the depth were real gland-like spaces. The sac contained 7.5 c.c. of fluid. Lining the canal between the two sacs were cylindric cells. In all three portions there was a lack of perfect development of the mucosa, whereas the muscular layers were hypertrophied.

The cyst in the mediastinum (Fig. 109, *c*) extended from the third to the tenth dorsal vertebra. It was 5.5 cm. long, 3.7 cm. in its transverse diameter, and 4 cm. in thickness. It had thick walls, was opaque, distended, and elastic. The tumor was firmly connected with the vertebral column. From above downward it was only slightly movable; from side to side, somewhat more so. It lay to the right of the esophagus.

The tumor, as shown in the hardened specimen, had produced much pressure on the thoracic organs. The left lung, just behind and below the hilum, presented a flat surface. The right lung had a deep groove, 4.3 cm. long and 1.5 cm. broad, which extended over the entire lower lobe.

The cyst contained 12 c.c. of tenacious, mucilaginous fluid, in which cylindric

cells and goblet-cells were found. It was divided into three chambers, which were entirely separated from one another. The walls showed an intestinal structure, but with more marked development of the muscular layers, while the mucosa was everywhere thin and in most places devoid of folds or glands. Here and there, however, were irregular folds between which small glands opened.

In summing up the findings Roth says: "In the first place, the intramesenteric position of the diverticulum is perhaps unique. Usually the diverticulum springs from the convex surface of the intestinal canal; not infrequently, however, it is situated near the mesenteric attachment. Interest is also attached to the small intestinal cyst, which is separated from the diverticulum at the matrix; it has the same longitudinal muscular layers and the same serosa." He refers to the cyst as a diverticulum.

Roth said he knew of only one similar case in the literature, that of Raesfeld, in which the entire diverticulum had been transformed into a cyst, but in that case the cyst was seated on the free circumference of the intestinal tract.

#### A CYST OF THE CENTRAL PORTION OF THE OMPHALOMESENTERIC DUCT.

Most of the schematic pictures illustrating the various points at which remnants of the omphalomesenteric duct may be found represent cysts developing midway between the intestine and the umbilicus (Fig. 105, p. 176). Theoretically, one might expect to find them in such a position, but the following case, recorded by Schaad,\* is the only example of such a condition that I have found in the literature.

**An Abdominal Cyst Originating From a Remnant of the Omphalomesenteric Duct.**—The patient was a married woman, thirty-two years of age. Nothing is known of the appearance of the umbilicus at birth. She gave a history of two normal labors. At the last labor a tumor was noted below the umbilicus. This patient was supposed to have had a severe inflammation of the bowels seven years previously.

Several fingerbreadths below the umbilicus one could feel an elastic tumor which was sharply outlined and was the size of a child's head. This could be pushed in all directions.

Operation.—A cyst the size of a five-franc piece was found about two fingerbreadths below the umbilicus, and attached to the abdominal wall in the median line. It had been separated from the peritoneum and drawn out of the abdomen. Omental adhesions were tied off and cut. The cyst was adherent to the appendix. The left ovary was hard and atrophic; the right ovary was normal. The patient made a good recovery.

The cyst was oval in form, 7.5 cm. long, 6 cm. broad, and 4.5 cm. in thickness. Its walls varied from 2 to 4 mm. in thickness. Its inner surface resembled mucosa and was light yellow in color, with dark spots. On the right side of the cyst was a secondary cyst, which communicated with the larger one by an opening the size of a pin-head. The inner surface of the cyst was smooth, and its walls were in places 0.5 mm. thick.

The large cyst contained about 200 c.c. of a chocolate-colored, tenacious fluid, with an abundance of cholesterin detritus and fat-droplets. The smaller cyst had

\* Schaad, T.: Ueber die Exstirpation einer Cyste des Dotterganges. *Corr.-Bl. f. Schweizer Aerzte*, 1886, xvi, 345.

similar but thicker contents. The wall of the large cyst consisted of connective tissue and of a large quantity of smooth muscle arranged in bundles, which ran in all directions. The inner surface was lined with high cylindric epithelium. Glands also opened on the surface. The epithelium and glands were in places missing.

The small cyst was lined with granulation tissue, in which were found giant-cells, some containing 20 to 30 nuclei, arranged at the margin or irregularly scattered in the center. [This finding reminds one of foreign-body giant-cells.]

Schaad says there is no doubt that the cyst represented a remnant of the omphalomesenteric duct. A portion of the duct had remained open and caused a retention cyst.

#### SYMPTOMS OF INTESTINAL CYSTS.

Some of the children were born dead. Carwardine's patient lived two days, Roth's patient lived a year and four months, and Kulenkampff's patient, three years. In each of these cases the death was apparently due to intestinal obstruction.

Schaad's patient, a woman of thirty-two, recovered. In this case the tumor apparently had no connection with either the bowel or the mesentery. It was removed.

Fitz says: "The clinical importance of these intestinal cysts obviously depends upon their size and situation. Large abdominal cysts may interfere with the birth of the child, as in Hennig's case and in that reported by Sanger and Klopp. Although the actual cyst or cysts in each instance were not the sole cause of obstructed labor, for an associated ascites was present, they were an important element.

"In Hennig's case, puncture of the abdominal cavity was necessary before the child could be delivered, and some three liters of a relatively clear fluid escaped. The cyst was not injured. Even if the child is born, the cyst may remain as a constant source of danger, and, as in the case reported by Roth, may prove fatal by a twisting of its pedicle. The possible effect of an intrathoracic cyst is shown by this observer, who found evidence of marked pressure upon the lungs and bronchi. The possibility that cysts of the abdominal wall may become of considerable size is suggested by the history of the urachus cysts sometimes found between the muscle and peritoneum and extending from the navel to the symphysis pubes."

#### TREATMENT.

If these cysts were recognized early and before the obstruction was marked, it would, of course, be possible to remove those arising from the free margins of the bowel. Where the cyst is located in the mesentery, the danger of injuring the blood-supply of the intestine would naturally materially increase the risk.

#### LITERATURE CONSULTED ON INTESTINAL CYSTS.

Buchwald: (Colmers, *Loc. cit.*).

Carwardine, T.: Volvulus of Meckel's Diverticulum. *Brit. Med. Jour.*, 1897, ii, 1637.

Cazin, H.: tude anatomique et pathologique sur les diverticules de l'intestin. Thèse de Paris, 1862, No. 138.

Colmers, F.: Die Enterokystome und ihre chirurgische Bedeutung. *Arch. f. klin. Chir.*, 1906, lxxix, 132.

- Dittrich: (Runkel, Op. cit.)
- Fitz, R. H.: Persistent Omphalomesenteric Remains; their Importance in the Causation of Intestinal Duplication, Cyst Formation, and Obstruction. Amer. Jour. Med. Sci., 1884, lxxxviii, 30.
- Hendee: (Colmers, Loc. cit.)
- Hennig, C.: Cystis intestinalis, Cystis citra œsophagum bei einem Neugeborenen. Centralbl. f. Gyn., 1880, iv, 398.
- Hüter: (Runkel, Op. cit.)
- Kulenkampff, D.: Ein Fall von Enterokystom. Tod durch Darmverschlingung. Centralbl. f. Chir., 1883, x, 679.
- Löhlein: (Runkel, Op. cit.)
- Nasse: (Runkel, Loc. cit.)
- Rimbach: (Colmers, Loc. cit.)
- Roth, M.: Ueber Missbildungen im Bereich des Ductus Omphalomesentericus. Virchows Arch., 1881, lxxxvi, 371.
- Runkel, A.: Ueber cystische Dottergangsgeschwülste. Inaug. Diss., Marburg, 1897.
- Tiedemann: (Roth, Loc. cit.)
- Tscherning: (Runkel, Op. cit.)
- Schaad, L.: Ueber die Exstirpation einer Cyste des Dotterganges. Corr.-Bl. f. Schweizer Aerzte, 1886, xvi, 345.

## CHAPTER X.

### A PATENT OMPHALOMESENTERIC DUCT.

Historic sketch.  
Appearance of the umbilicus.  
Condition of the child.  
Treatment.  
Cases of patent omphalomesenteric duct.

IN 1817 Poussin reported the case of a child three years old. On the fifth day after birth the nurse made traction on the cord, as it had not yet come away. "Inflammation" followed, and a small opening developed at the umbilicus. Sometimes this would close for three weeks or more, but never for a much longer period; from time to time the child passed round worms through it. At the umbilicus was a projection the size of a hazelnut, which showed at its center an opening from which feces escaped. The fistula was due to a patent omphalomesenteric duct.

Brun, in 1834, published a remarkably clear article on this subject, and described several cases that had been observed by Dupuytren.

King, in 1843, reported a case observed by Parsons and Gunthorpe. In this case a portion of the small bowel had turned inside out through the fistula, and lay as a sausage-like mass on the abdomen. This case is reported in detail on page 233.

Eves, in 1845, reported the case of a child, one month old, who had a red, fungus-like tumor, about the size and shape of a raspberry, attached to the umbilicus. At its apex was a small opening, from which occasionally feculent liquid would issue in jets and through which a probe could be passed directly backward for two inches. On investigation it was found that the cord had separated at the end of a week, and fecal matter had then commenced to come from the umbilicus.

Schroeder, in his inaugural dissertation on the formation of intestinal diverticula, published in 1854, said that in the Pathological Museum of Prague is the record of a six-months-old child who showed an embryonic omphalomesenteric duct which passed from the umbilicus to the ileum as a canal of gradually increasing size.

Lannelongue and Frémont, in their treatise on the varieties of congenital tumors, said that umbilical fistulæ of this origin had been observed by Sandifort, F. Schulze, Tiedemann, Ludwig, and Tilling.

A patent omphalomesenteric duct is by no means common, but Brun was able to publish three cases from Dupuytren's clinic, and Quaet-Faslem five cases from Petersen's clinic. A fairly complete summary of the cases scattered throughout the literature will be found toward the end of this chapter.

*S e x .* — In 13 of the cases here recorded we have no data as to the sex, but of the remaining 35, 31 were in males and only 4 in females, showing conclusively that the patent omphalomesenteric duct occurs almost exclusively in the male.

*A g e .* — For the 35 cases in which we have data as to the age at which the patient came under observation we have the following figures:

Under one year old. . . . .	22
Between one and ten years old. . . . .	8
From ten years of age and over. . . . .	5



Holmes' patient and the one observed by Leisrink and Alsberg were ten years old. Fitz's patient was twenty-one years of age, and Kehr's, twenty-eight years old. Park's patient was an athlete, his exact age not being given.

**The Umbilical Cord.**—In many cases no mention is made of the condition of the cord at birth, but in quite a number the records show that the cord was very large at its base, in some cases being fully twice as thick as usual near the abdomen. Pratt, for instance, said that for an inch and a half from the abdomen the cord was double its usual thickness. Many of the cases were handled by midwives and no definite records made. I feel sure that future reports will demonstrate that the cord near the umbilicus is invariably thicker than usual, when a patent omphalomesenteric duct is present.

In Hansen's case the cord was very large, bluish green, and abnormally broad. It came away on the eighth day.

In the cases in which the cord has been very thick, as a rule, the ligature has been applied farther away from the abdomen than usual.

#### APPEARANCE OF THE UMBILICUS.

When the cord comes away, an abnormal condition at the umbilicus is generally detected at once. The umbilical depression is occupied by a bright-red nodule. This may not be larger than a pea, but is frequently the size of a hazelnut (Fig. 121, p. 206) or of a cherry. In some instances it is much larger. In Ardouin's case, for example, its diameter was as large as that of the little finger, and the growth was 2.5 cm. long (Fig. 115, p. 192). In Hansen's case it was cylindric, snout-like, and curved. On its convex surface it was 3 cm., and on its under and concave surface 2 cm., in length. In Battle's case it was 1½ inches long. In Shepherd's case it looked like a penis and was 1½ inches long. In Roth's case it formed a cylindric tumor 2 cm. in length (Fig. 120, p. 205). In Morian's case, when the cord came away, a red, sausage-like mass was left (Fig. 119, p. 202); in Deschin's case a mushroom-shaped mass the size of a walnut was found. Figs. 111, 112, 113, and 114 give a very good schematic representation of the various forms of a patent omphalomesenteric duct.

In Jacoby's case, when the cord dropped off, the umbilicus was occupied by a raw area the size of a silver dollar. In Quæet-Faslem's case of a boy, nine days old, there was a long, pear-shaped tumor, 8 to 10 cm. in length. These tumors, whether large or small, are bright or dark red in color, and are covered over with typical intestinal mucosa. This occasionally, as was noted in one of Weiss's cases, may be covered over with brownish crusts. On examination of the summit of the tumor, an opening will be found. This may be exceedingly fine, or several millimeters in diameter. A probe introduced into the fistula can be passed directly into the small bowel.

On microscopic examination the surface of the projection or of the fistulous tract will be found to be covered with mucosa similar to that of the small bowel (Fig. 75, p. 134; Fig. 123, p. 207; Fig. 125, p. 209).

In these cases the omphalomesenteric duct has remained open, as it was in the early months of fetal life (Fig. 3, p. 3; Fig. 5, p. 5). Consequently, the appearance of the umbilical growth after the cord has come away will depend on how far away from the abdomen the cord has been ligated. The greater the amount of

omphalomesenteric duct left behind, naturally, the longer will be the protrusion. In those cases in which a large, relatively flat area of mucosa is found, the duct has probably been present as a cystic dilatation, and this has flattened out when the cord ligature has cut through.

In this connection the case observed by Prestat and cited by Ledderhose is of interest. In an autopsy on a male infant at term, Prestat demonstrated an intact

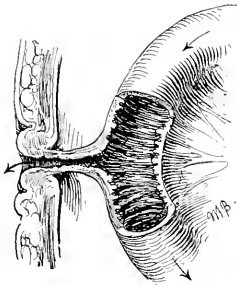


FIG. 111.—A PATENT OMPHALOMESENTERIC DUCT. (Schematic.)

The lumen is of rather small diameter, and yet occasionally the bowel may prolapse through a lumen even smaller than this.

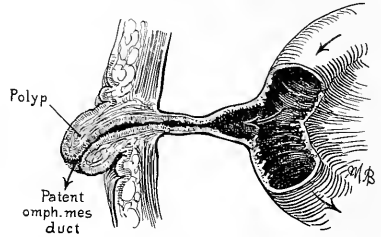


FIG. 112.—A PATENT OMPHALOMESENTERIC DUCT WITH A POLYPOID FORMATION AT THE UMBILICUS. (Schematic.)

The lumen of the duct diminishes markedly in size a short distance from the small bowel. Its outer end projects more than a centimeter beyond the surface of the abdomen. The outer surface of this polypoid projection is covered over with mucosa, which is directly continuous with that lining the omphalomesenteric duct and the small bowel.

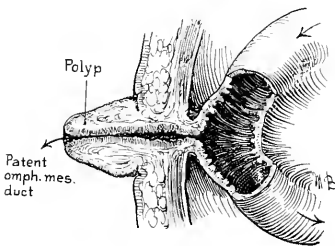


FIG. 113.—A VERY SHORT OMPHALOMESENTERIC DUCT. (Schematic.)

Usually the convex loop of small bowel is several centimeters away from the umbilicus, but occasionally, when the duct is very short, it may be almost directly attached to it. In the sketch here shown the greater part of the duct lies in the abdominal wall, and in the center of the polypoid nodule which projects outward from the umbilical depression.

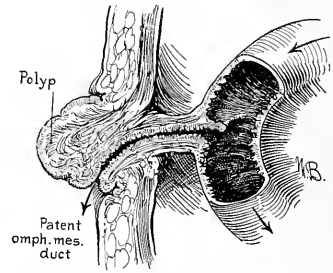


FIG. 114.—A PATENT OMPHALOMESENTERIC DUCT WITH A POLYP-LIKE FORMATION AT THE UMBILICUS. (Schematic.)

The omphalomesenteric duct is relatively short, and at its intestinal end is a sort of valve. Just above the umbilical opening of the duct is a polyp covered over with intestinal mucosa which, on the one side, is continuous with the skin, and on the inner side with the mucosa lining the omphalomesenteric duct.

umbilical cicatrix. On opening the abdomen he found a cord the size of a goose-quill. This was  $2\frac{1}{2}$  inches long, and communicated with the small bowel. On pressure fecal matter passed into the fistula, and at the umbilicus a small tumor projected from the cicatrix. This opened, and on moderate pressure fecal matter escaped. In this case there was nearly a fistula. If the patent omphalomesenteric duct had extended just a little farther out, it would have been constricted by the ligature and left open when the cord dropped off.

**The Discharge From the Fistula.**—This varies greatly. When the opening is very small, a little mucus may come away. In some cases this has a fecal odor; in other cases, as in Salzer's case, this is lacking.

Where the fistula is a little larger, liquid feces may escape every day, or, as noted in Pratt's case, every three or four days. In some cases the escape of feces was detected only when the child cried or when pressure was made upon the abdomen. In other cases the bowel contents escaped in large quantities from the umbilicus. The amount of the umbilical discharge will depend almost entirely on the size of the fistulous opening.

**Skin.**—The skin around the fistula often shows irritation. This again will depend on the amount of feces escaping, and on the irritating or non-irritating qualities of the contents of the particular intestine. Furthermore, the nearer the diverticulum is to the cecum, the less irritation one would expect.

#### CONDITION OF THE CHILD.

In many cases the children were in good physical condition, but others were weak and frail.

Billroth's patient was very weak; Broadbent's had congenital syphilis; Morian's child cried a great deal and lost weight; Leisrink and Alsberg's patient frequently had abdominal pain; Nicaise's patient was pale and emaciated, as was also one of those observed by Quaet-Faslem; Weiss's patient had had abdominal pain, diarrhea, and vomiting; Roth's patient died suddenly when six months old.

#### TREATMENT.

Various methods have been adopted to effect a closure of the umbilical opening. The most satisfactory results have been obtained from the use of caustics or the actual cautery, or from the application of a ligature to the umbilical growth. Many of the fistulae closed permanently; others opened up again as a result of coughing, as in Weiss's case. Leisrink and Alsberg's patient was operated upon and died of intestinal obstruction. King's patient underwent a plastic operation, which successfully closed the umbilical end of the fistula, but the child died later of intestinal obstruction.

Removal of the umbilicus and the fistulous tract has given the best permanent results. This is the only method to be considered at the present day. An incision should be made encircling the umbilicus down to and through the peritoneum; if traction is then made, the fistula and the loop of small bowel can be readily brought out of the abdomen. The fistula should then be removed in precisely the same manner as in dealing with an appendix.

#### CASES OF PATENT OMPHALOMESENTERIC DUCT.

Other cases of patent omphalomesenteric duct are referred to in Chapter XI (p. 214), on Prolapsus of the Bowel Through a Patent Omphalomesenteric Duct; and in Chapter XXI (p. 328), on Worms.

**Radical Operation in a Case of Persistent Omphalomesenteric Duct.**—Alsberg's\* patient was eighteen weeks old. When

\* Alsberg, A.: Ueber einen Fall von Radicaloperation eines persistirenden Ductus omphalomesentericus. Deutsche med. Wochenschr., 1892, xviii, 1040.

the cord came away, healing did not occur, a red, moist area remaining. This became more prominent, and a small, horn-like projection, 1 cm. long, developed. This projection was red in color and had an opening from which yellow fluid escaped.

On admission the child was found to be well developed. At the umbilicus was a flat tumor, the size of a bean, with an abundance of fluid escaping from an opening in it. The line of junction between the skin and mucosa was sharp. A bougie could be passed for 20 cm. into the opening.

Operation.—The omphalomesenteric duct was cut off near the small bowel and the stump turned in. The child died on the twelfth day from peritonitis.

**PATENT OMPHALOMESENTERIC DUCT. EXTIRPATION. RECOVERY.\***—The child was born September 14, 1906, and was seen on October 5th. He was then twenty-one days old, and presented a fecal fistula at the umbilicus. The parents thought that the woman, who had had charge of the tying of the cord, had applied this ligature to an intestinal loop, but the history shows that there was no room for criticism of the midwife. The boy was well nourished.

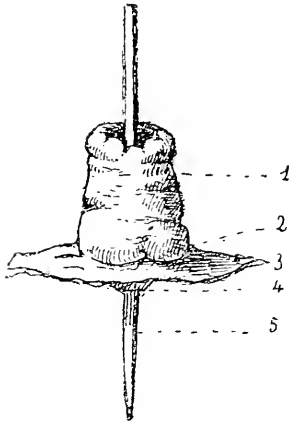


FIG. 115.—A PATENT OMPHALOMESENTERIC DUCT. (After Ardouin.)

A probe has been introduced into the tract in order to show its permeability. 1, the diverticulum; 2, the umbilicus; 3, the surrounding collar of skin; 4, the point of attachment of the diverticulum to the intestine; 5, the probe passing through the length of the fistulous tract.

At birth the person who tied the cord, 5 or 6 cm. from the umbilicus, noted that it was large at its base. In the course of three days the cord came away, and in its place was a tumor the size of a little finger in diameter, and 2.5 cm. in length. It was red in color, and from it a few days later there was a considerable amount of hemorrhage.

On October 1st, the sixteenth day, the family noticed for the first time an escape of intestinal material and gas. At the same time the bowels moved regularly.

Ardouin saw the child five days later, and the tumor presented the picture seen in Fig. 115. It was red, like a cherry, and resembled intestinal mucosa which had been irritated. The tumor was limited at its base by a cutaneous elevation at the umbilicus. The surrounding skin was reddened and ulcerated at some points. At the summit of the tumor was a depression, from which fecal material and gas escaped. Ardouin recognized the condition as one of persistent omphalomesenteric duct. There were no other malformations.

Operation.—A lozenge-shaped incision encircling the umbilicus was made and the peritoneum opened. The tract was clamped off at the point of junction with the intestine, and cut across with the thermocautery, just as in the removal of an appendix. The opening in the bowel was closed, and the child made a perfect recovery.

**EXTROVERSION OF MECKEL'S DIVERTICULUM.**—Battle's † patient was a girl eighteen months old. She was fairly well nourished, but had

\* Ardouin, P.: *Persistence du Diverticule de Meckel ouvert à l'ombilic. Fistule stercorale. Omphalotomie. Extirpation du diverticule, guérison.* Arch. prov. de chir., Paris, 1908, xvii, 1.

† Battle, W. H.: Clin. Soc. Trans., London, 1893, xxvi, 237.

a pear-shaped tumor at the umbilicus. This was noted shortly after birth, and had been increasing in size.

It was one and a half inches long, and covered with red, smooth mucosa, which bled on manipulation. There was a sharp line of demarcation between the tumor and the skin. At the free end the diameter equaled that of a cherry, and at its narrowest point was reduced by one-half. At its extremity was a hole through which a probe could be passed inward for two inches. There was a thin, rather feculent discharge, and the tissues surrounding the tumor were eczematous. The stools were normal. The protrusion could be reduced only very slightly by pressure. It increased in size when the patient cried or stood erect.

Operation.—The abdomen was opened; the diverticulum was cut through transversely, and the stump invaginated. The next day scarlet fever developed, and the child died on the eleventh day.

At autopsy the abdominal condition was found to be perfectly normal. The death was due to scarlet fever. The distance of the diverticulum from the ileocecal valve was ten inches.

A Patent Omphalomesenteric Duct.\*—The boy, fourteen weeks old, had had a fecal umbilical fistula since birth. Projecting from the umbilicus was a growth half an inch in length from which a small amount of fecal matter escaped from time to time. Billroth thought that this represented an omphalomesenteric duct that had remained open (Fig. 116).

The growth was tied off with the hope that the fistula might close, but when the suture came away, it remained open. Billroth thought of closing the fistula later with sutures, but the child was very weak, and was taken home by its parents. It soon died.

A Patent Vitelline Duct.—Broadbent † showed the specimen. The child had occasionally passed fecal matter from the umbilicus, but as it was a subject of congenital syphilis, no surgical procedure was undertaken. At autopsy a coil of intestine was found in contact with the umbilicus, and there was a slender tube passing from the intestine to it.

A Patent Meckel's Diverticulum. ‡—A boy, six months old, was brought to the hospital June 3, 1894. He had a pear-shaped tumor 4 cm. long, with a pedicle about 1 cm. in diameter, at the umbilicus. Its surface was

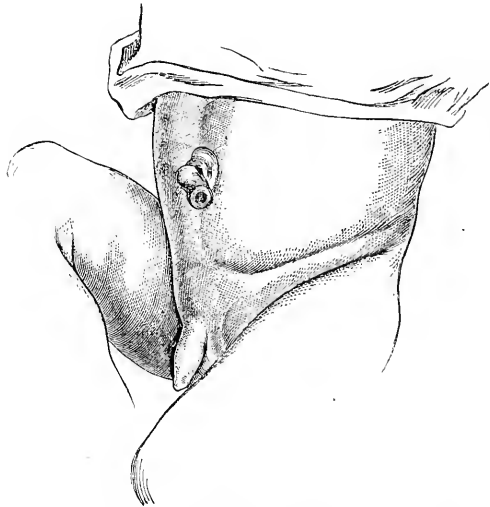


FIG. 116.—A PATENT OMPHALOMESENTERIC DUCT. (After Billroth.)

The patient was a boy, fourteen weeks old, who had had an umbilical fecal fistula since birth. Projecting from the umbilicus was a growth, half an inch in length, from which a small amount of fecal matter escaped from time to time.

\* Billroth: Chirurgische Klinik, Berlin, 1869, 294.

† Broadbent: Med. Times and Gaz., 1866, ii, 45.

‡ Broca: Persistance du diverticule de Meckel ouvert à l'ombilic et invaginé au dehors. Revue d'orthopédie, 1895, vi, 47.

covered with a bright-red mucosa, resembling that of a prolapsed rectum. In the center was an orifice from which there escaped a mucous liquid. Nothing resembling fecal matter had ever been noted. A probe was easily introduced into the center of the orifice, and passed into the abdomen.

Operation, June 9, 1894.—Broca made a circular incision around the umbilicus, going down to the peritoneum. The growth communicated with the intestine by an opening that would admit a probe. The opening in the ileum was closed, and the child made a good recovery.

PATENT OMPHALOMESENTERIC DUCT.—Bureau records another observation made by Broca.\* A boy, aged ten months, was admitted to the hospital on October 21, 1897. In the center of the umbilicus was a small red tumor, about 2 cm. long, consisting of the everted diverticular mucosa. At its summit was an orifice into which a probe could be passed. There was a serous discharge from the fistula. On October 21st the fistulous tract was resected. The child made a good recovery.

PROLAPSUS OF THE OMPHALOMESENTERIC DUCT.—Bureau † says that diverticular entero-umbilical fistulæ are always due to the persistence of Meckel's diverticulum or to remains of the omphalomesenteric duct. Open diverticula at the umbilicus are rare, and prolapsus of the diverticulum complicating the fistula is still rarer. Broca observed one case in 12,000 patients examined at the Hôpital Trousseau during two years.‡ The danger is from intestinal occlusion. The modes of treatment are compression, ligation, cauterization; laparotomy followed by resection of the diverticulum and closure of the bowel should be employed.

PATENT OMPHALOMESENTERIC DUCTS.—Brun's § article, published in 1834, is a remarkably clear one. He records three cases coming under the care of Dupuytren and a fourth observed by Poussin. In three of the four cases there was an umbilical fecal fistula, and in the other there was no fistula. Brun said that Dupuytren had never seen a case before 1833, and then in short succession the three patients were admitted.

CASE 1 came under Dupuytren's care. The child was twenty-eight days old. At the umbilicus was a tumor the size of a cherry, red, and covered over with mucosa. The tumor was irreducible; it was narrowed at its base and had a perforation in its center from which fecal matter escaped. In this case the cord had dropped off on the fifth or sixth day, and shortly afterward the condition had been noted. The child's general health was good. A sound could be carried one and a half inches into the fistula. Finally the growth was tied off with a silk ligature. It sloughed off after fifty-four hours and the wound healed.

CASE 3. A boy, who came under Dupuytren's care, had a large cord at birth. This was tied at a point five fingerbreadths from the umbilicus. At the end of the fifth day the cord had not yet come away, and a new ligature was applied nearer to the abdomen. On the ninth day, when the cord sloughed off, there were two small red tumors at the umbilicus. These were about

\* Broca (Quoted by Bureau): Thèse de Paris, 1898, No. 257, 32.

† Bureau, J.: Prolapsus ombilical du diverticule de Meckel. Thèse de Paris, 1898, No. 257, 14.

‡ Broca: Rev. d'orthopédie, 1895.

§ Brun, L. A.: Sur une espèce particulière de tumeur fistuleuse stercorale de l'ombilic. Thèse de Paris, 1834, No. 238.

the size of a finger-tip, and projected half an inch. They were roundish and covered over with mucosa. The one was opposite the other, and both were in the same horizontal plane. The right was smaller than the left. The left one was perforated in its center, having an opening one *ligne* (2.25 mm.) in diameter. A probe could be carried for more than an inch into this opening, and fecal matter escaped from it. The child also had normal stools. Neither of the tumors was reducible on pressure. Both were tied with silk and dropped off on the third day, with perfectly satisfactory results, the fistula remaining closed.

A Patent Omphalomesenteric Duct.\*—Deschin's patient was a boy five months old. A tumor was noted at the umbilicus when the cord came away. To the left of the umbilicus was a walnut-sized, mushroom-like tumor, bright red in color, and reminding one of the mucosa of the large bowel. In the middle was an opening which led into the bowel. Feces escaped from it. The surface of the growth was alkaline in reaction.

The abdomen was opened, and the fistulous tract found to be 3 to 4 cm. long. It passed to the small bowel. The tract, together with the umbilicus, was removed. The child took the anesthetic badly and died several hours later. At autopsy it was found that the fistula was 49 cm. above the cecum. It was lined with intestinal mucosa.

A Case of Diverticulum Ilei Communicating with the Umbilicus.†—W. D., aged one month and four days, had a red, fungus-like tumor, about the size and shape of a raspberry, attached at the umbilicus. At its apex was a small opening from which occasionally feculent liquid would issue in jets and through which a probe passed directly backward for two inches. The child was in good health and the bowels moved in a natural way.

On investigation it was found that the cord had separated at the end of a week, and fecal matter had then commenced to come from the umbilicus.

A ligature was tied firmly around the base of the umbilical projection. This sloughed off in a few days. The canal became obliterated, and the discharge ceased completely. Eves refers to his case as one particularly favorable for palliative treatment.

Intestinal Obstruction Due to a Patent Omphalomesenteric Duct.—Fitz‡ refers to a case observed by Dr. John Homans, of Boston. A man, twenty-one years of age, met with a severe fall February 8, 1884. He had always been healthy, with the exception of a congenital umbilical sinus, which was vaguely supposed to communicate with the intestine. His mother was confident that portions of food (seeds and the like), after being swallowed, had escaped at times from the sinus, and that the latter had been closed since October, 1882.

"Four days after the fall he was seen by Dr. John O. Dow, of Reading, Mass., who found him suffering from absolute intestinal obstruction, tympanites, tenderness, and pain. Three days later—a week after the accident—frequent vomiting of an offensive, so-called fecal, material took place. Dr. Homans was summoned

\* Deschin: Zur Frage der chirurgischen Behandlung bei dem Vorfall des Dotterganges. *Centralbl. f. Chir.*, 1895, xxii, 1154.

† Eves, A: *The Lancet*, London, 1845, i, 101.

‡ Fitz, R.: Persistent Omphalomesenteric Remains, their Importance in the Causation of Intestinal Duplication, Cyst-formation and Obstruction. *Amer. Jour. Med. Sci.*, 1884, lxxxviii, 30.

in consultation, after another interval of three days, and found the patient vomiting, every few minutes, an exceedingly offensive brown fluid. The abdomen was distended, tympanitic, and tender. The eyes were bright, and the countenance intelligent. Pulse feeble, about 130.

"A dark-colored urine was drawn from the bladder and a director introduced into the sinus. A little fecal matter seemed to escape. The opening was enlarged laterally, especially to the left, sufficiently to admit the finger. The incision may have been an inch and a half long, and the finger entered the peritoneal cavity. No obstruction was felt near the umbilicus within reach of the finger. A loop of intestine was seized, sewn to the skin, and an opening, about half an inch in length, was made through its wall. No fecal or intestinal contents escaped until after the junction was completed, when an offensive, brownish fluid material and gas were freely discharged.

"On the day following the operation the temperature was 100.4° F.; the pulse, 108. The vomiting had ceased, and there was some relish for food. Occasional twinges of pain in the right groin were complained of. There was but little abdominal distention, and Dr. Dow was able to detect a circumscribed enlargement in the vicinity of the ileocecal valve. Two days later the temperature was normal; pulse, 108. The swelling and tenderness in the groin were much diminished, and there were no twinges of pain. Solid food was desired. On the next day the temperature was 96.2° F., pulse, 120. Restlessness, distress in the back, and ringing in the ears were the prominent symptoms, and were attributed to insufficient nourishment. Injections of beef-tea were given, and were followed by marked relief, the pulse falling to 108 and the temperature rising to normal. His strength gradually failed, however, notwithstanding that food was given by the mouth and rectum. The temperature became persistently lower, and the pulse weaker, with increasing frequency. His death took place one week after the operation. On the day preceding a passage from the bowels occurred, although Dr. Dow was of the opinion that the contents of the stomach never passed beyond the intestinal fistula.

"An autopsy was made twenty-six hours after death by Dr. G. E. Putney, of Reading, who has furnished the following interesting report:

"He found the body considerably emaciated and the abdomen flat. A probe inserted into the congenital opening passed downward, forward, and to the right, at an angle of 40 degrees with the median line.

"The parietal peritoneum was glistening, of a dark, reddish-slate color. Its blood-vessels were prominent, especially around the umbilicus, within a radius of four inches. There was no lymph. The small intestine was of a very dark, drab-red color. The large intestine and the colon were of about two-thirds the normal size. The artificial opening into the intestine was 52 inches below the pylorus. Its edges were thickened, ragged, and sloughing, and had failed to unite with those of the abdominal wound.

"A diverticulum four inches long and half an inch in diameter arose from the ileum four feet above the ileocecal valve, and extended to the umbilicus. The ileum below its origin was three-quarters of an inch in diameter. The tissues of the diverticulum appeared normal, with the exception of the muscular coat of the distal three-quarters of an inch, which was thrice the normal thickness. A tendinous cord the size of a darning needle and 4 inches long proceeded from the mesentery



along the diverticulum and became lost in the tissue surrounding the umbilical opening. In its course along the diverticulum it appeared as if ensheathed.

"The contents of the small intestine resembled dark pea-soup; those of the large intestine were pultaceous, resembling yeast. There was no evidence of any existing constriction at the time of autopsy."

"There seems to be no reasonable doubt that the above case is one of intestinal obstruction from persistent omphalomesenteric remains. The autopsy gives no evidence of the manner in which the obstruction occurred."

Fitz's article is one of the most readable in the English language.

A Patent Omphalomesenteric Duct.\* — The boy was five years old. When the cord came away, an enlargement the size of a hazelnut was noted at the umbilicus. This nodule was red and discharged a clear liquid, which at times was blood-tinged. Up to the fifth year the tumor had occasioned no serious

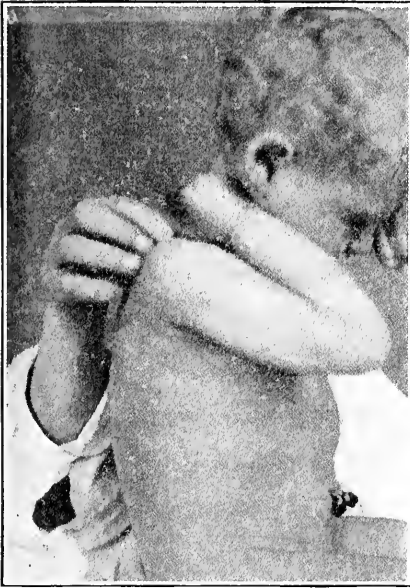


FIG. 117.—A PATENT OMPHALOMESENTERIC DUCT. (After Froelich.)

The umbilicus was particularly prominent, owing to a definite projection. This had existed since the cord came away. For its relative size and position see Fig. 118.

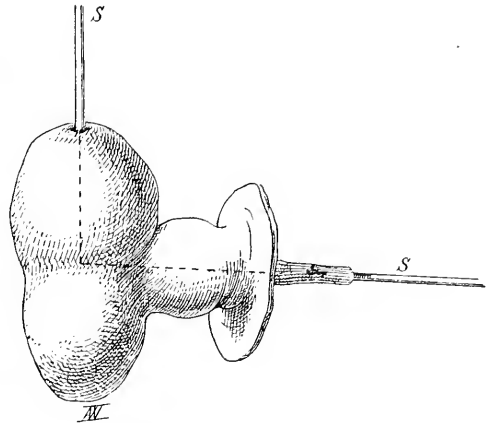


FIG. 118.—A PATENT OMPHALOMESENTERIC DUCT. (After Froelich.)

The umbilical growth seen in Fig. 117. *S, S*, is the sound, which passed down a certain distance and then directly into the abdomen, as indicated by the dotted line. The entire growth was removed. Its inner portion was continuous with a pervious cord which opened into a loop of small bowel.

trouble. When the child came under observation, an elongated projection was noted at the umbilicus (Fig. 117). At its center was an opening from which a clear liquid escaped. The tumor was bright red and resembled intestinal mucosa. It was soft in consistence, but on pressure could not be reduced in size. The patient's movements did not cause any alteration in its size. A probe introduced into this fistula could be carried downward and came in contact with the lower part of the mass, but a curved probe directed toward the umbilicus passed into the abdomen. The fluid escaping was alkaline. The condition was one of patent omphalomesenteric duct with partial eversion of the outer portion.

\* Froelich, R.: Du fungus ombilical du nouveau-né, à l'occasion d'une opération de prolapsus ombilical du diverticule de Meckel. Rev. mens. des maladies de l'enfance, Paris, 1902, xx, 517.

The omphalomesenteric duct was excised from a point about 0.5 cm. from the intestine, and the stump turned into the bowel. Microscopic examination showed that the surface of the umbilical nodule was covered with intestinal mucosa.

**A Patent Omphalomesenteric Duct.\***—The patient was a boy two and one-half years old. From the time that the cord had come away fecal matter had been noted at the umbilicus. In time a granular tumor the size of a cherry developed at this point. There was some prolapse of the mucosa of the fistulous tract.

The fistulous tract was dissected free as far as the bowel and then removed. The patient made a good recovery.

**A Patent Omphalomesenteric Duct.†**—At birth the cord was very large near the umbilicus. It was bluish-green in color, and fell off on the eighth day. There remained a red, snout-like mass, 2 cm. in length. This secreted much pus, and, when the child cried, there was some bleeding. Later on gas-bubbles and feces escaped.

At examination there was noted at the umbilicus a cylindrical, somewhat conic, snout-like mass, which hung downward and to the left. The left, which was the under side, was 2 cm. long. The right, the upper side, was 3 cm. long. At the bottom the growth was 2 cm. in diameter.

The skin was drawn upward upon the surface of the tumor on the right side for a distance of 1.5 cm.; on the left for a distance of 0.75 cm. The remainder of the tumor was covered with bright-red mucosa. In the center was a funnel-shaped opening. A sound passed upward and to the right 7 cm.

**Operation.**—Two threads having been passed through its base to prevent its giving way, the tumor was excised. Three small vessels were caught. On account of the friable mucosa it was impossible to suture it, and the stitches were taken at some distance away. The peritoneum was not seen. The skin ring of the umbilicus was removed, and this area was drawn over the stump and closed. The child made a good recovery. The wound healed perfectly, and the umbilical ring, which was previously 2.5 cm. in diameter, contracted down until it was very small.

The microscopic picture showed typical intestinal mucosa. The condition was due to a patent omphalomesenteric duct.

**A Fecal Concretion Discharged at the Umbilicus.‡**—Heaton presented a patient in whom, after a short illness, a large fecal concretion had been discharged from the umbilicus. This patient, before his illness and since he left the hospital, had been in perfect health. There was no history nor any evidence of tuberculosis. Heaton suggested that perhaps a concretion had become impacted in Meckel's diverticulum, had set up an ulceration there, and, fortunately for the patient, had been discharged from the umbilicus.

**Probable Persistence of the Omphalomesenteric Duct.§**—The patient was a female child, four months old, who had a red, velvety, cylindrical projection at the umbilicus. This was three-quarters of an inch

\* Gevaert, G.: *Fistule ombilicale diverticulaire chez un enfant*. *Ann. de méd. et de chir.*, 1892, iv, 1.

† Hansen, J. A.: *Ein Beitrag zur Persistenz des Ductus omphalo-entericus*. *Inaug. Diss.*, Kiel, 1885.

‡ Heaton, G.: *Brit. Med. Jour.*, 1898, i, 627.

§ Hickman: *Persistent Vitelline Duct*, *Trans. Path. Soc. London*, 1869, xx, 418.

long, stiff and tense, and constricted at its base. Its end was covered with a thin slough. It bled readily, but no aperture could be detected. It had existed since the cord had come away. The mother said she had noticed a little moisture having the odor of feces, but no fecal matter could be detected.

Hickman says that usually, in these cases, eversion of the mucous membrane leaves a canal extending into the bowel through which the feces occasionally pass. In this case no canal could be found.

[The fact that there was a fecal odor here seems to indicate clearly that an opening existed, although Hickman did not find it. A reference to other cases will show that, although no definite connection with the bowel was detected, at operation the canal was found to be patent.]

*P a t e n t O m p h a l o m e s e n t e r i c D u c t .*—Holmes\* had a patient who gave a history of having had a warty growth at the umbilicus during his first year. This was ligated. Holmes saw him when he was ten years old, and at that time he had a constant but not copious discharge from the umbilicus. This fluid, macroscopically and chemically, resembled bile. Later vegetable matter escaped, showing that a definite fecal fistula existed.

*A P a t e n t O m p h a l o m e s e n t e r i c D u c t .* †—The patient was a poorly developed male. The midwife, when tying the cord, noticed its unusual breadth, but nevertheless put the ligature at the usual point. When the cord dropped off on the third day there was left a raw area, the size of a thaler, which was prominent and moist and from which fluid escaped. Within a few days the surrounding parts became erythematous, and on the sixth day the mother observed feces coming from the umbilicus. The greater part of the intestinal contents, however, still passed by the rectum. The child had no pain in the lower abdomen, but the parents were greatly distressed.

After several physicians had treated the child without success, an old nurse put on an occlusion apparatus and then applied pressure. As a result the feces were held back and the ring closed rapidly and became flatter. By the sixth week the child had improved greatly and soon only a small amount of feces escaped from the umbilicus. Three or four weeks later the umbilicus had healed completely and the child was strong and healthy.

*A P a t e n t O m p h a l o m e s e n t e r i c D u c t .* ‡—The patient was a man, twenty-eight years old, who had a patent omphalomesenteric duct. At the umbilicus was a reddish mass, the size of a cherry, showing at its top a depression from which a mucous secretion escaped; no feces, however, were noted. The patient had suffered from obstipation, and felt as if there were something in the umbilical region which prevented the feces from passing. He had had severe colic. On account of the foul odor his comrades avoided him, and his condition had rendered him melancholic.

Operation.—The duct was removed at the bowel and the opening in the ileum closed with two rows of sutures. The patient made a good recovery, but three weeks after operation he committed suicide at his home.

\* Holmes, T.: *Surgical Treatment of Diseases of Children*, London, 1868, 181.

† Jacoby, M.: *Zur Casuistik der Nabelfisteln*. Berlin. klin. Wochenschr., 1877, xiv, 202. Jacoby also reported this case in *Jahrb. f. Kinderheilk. u. phys. Erzieh.*, 1878, xii, 144.

‡ Kehr, H.: *Ueber einen Fall von Radicaloperation eines persistirenden Ductus Omphalomeseraicus*. Deutsche med. Wochenschr., 1892, xviii, 1166.

**A Patent Omphalomesenteric Duct.\***—The child was six months old. At the umbilicus was a red, smooth, moist tumor, the size of a hazelnut. When the child cried or when pressure was made on the abdomen, the tumor increased in size. At its most prominent part was an opening, hardly the size of a linseed, into which a sound could be introduced for from 5 to 8 cm. There escaped from the fistula a clear green fluid, with a slightly yellowish tint. Under light narcosis the surface was seared with the cautery and a bandage was applied. At the end of eight days nothing but a small opening remained. It was suggested that the child be taken home for a time. When Kern reported the case, the child was more than one year old and had improved, but a fistula remained.

Operation.—Professor Kraske later excised the diverticulum and the child made a good recovery.

**A Patent Omphalomesenteric Duct.**—Kirmisson† says that persistence of Meckel's diverticulum with an opening at the umbilicus is a rarity. His patient was five and one-half months old. The father was not a strong man. When the cord came away on the third day the mother noticed a whitish swelling, which, eight days later, became reddish in color. The swelling was the size of a strawberry. Its mucosa was smooth, and on its surface were two small, teat-like projections, and in its upper portion a small orifice into which a probe could be carried 3.5 to 4 cm. The mucosa of the nodule merged directly into the skin surrounding the umbilicus. When the child cried or moved, the tumor became larger and larger. Feces were not detected.

The tract was dissected out and removed. It communicated with the small bowel. The fistula was about 5 cm. long and tapered off; its larger end was at the bowel, the smaller, at the umbilicus. The child made a good recovery.

Microscopic Examination.—The mucosa at the umbilicus resembled that of the intestine. Its surface was covered with cylindric epithelium and the glands were tubular.

**A Patent Omphalomesenteric Duct.**—Körte‡ quoted Deschin as saying that 1.8 per cent. of autopsies in children have shown remains of the omphalomesenteric duct. He then reports the case of a boy, fifteen months old, who had at the umbilicus a tumor resembling a penis. When the child cried, this became larger than a finger. Its reduction was difficult. Usually the nodule was the size of the tip of a finger.

The child suffered with intestinal catarrh. Attributing this to the open umbilicus, Körte inserted an iodoform drain into the fistula. Later he resected it down to the bowel. The child made a good recovery.

**Patient Omphalomesenteric Duct.**—Lannelongue and Frémont§ refer to the cases of fistulæ observed by Sandifort, Schulze, Tiedemann, Ludwig, and Tilling, all of which were analyzed by Cazin.

They also say that Bruce reported several instances in which a small hernia of

\* Kern: Ueber das offene Meckel'sche Divertikel. Beiträge z. klin. Chir., 1897, xix, 353.

† Kirmisson, E.: Persistance du diverticule de Meckel ouvert à l'ombilic avec prolapsus de la muqueuse intestinale. Revue d'orthopédie, 1901, xii, 321.

‡ Körte: Ein Fall von Extirpation des persistirenden Ductus omphalo-mesentericus. Deutsche med. Wochenschr., 1898, xxiv, 103.

§ Lannelongue et Frémont: De quelques variétés de tumeurs congénitales de l'ombilic et plus spécialement des tumeurs adénoïdes diverticulaires. Arch. gén. de méd., 1884, 7. sér., xiii, 36.

the umbilicus was included in the cord, and when the cord dropped off, a small orifice was left from which feces and gas escaped; later, granulation developed at the umbilicus, and after a variable time these openings closed. After considering all the facts Duplay (they say) came to the conclusion that these were hernial diverticula.

**I n t e s t i n a l O b s t r u c t i o n D u e t o a P a t e n t O m p h a l o - m e s e n t e r i c D u c t . \***—The patient was a boy, ten years of age, who was said to have had an open umbilicus. The physician who saw the boy first when he was three years old said it was nearly closed at that time. Nevertheless, it would become prominent, finally flatten, and discharge a few drops of yellowish fluid (odor not given). The child had good health, but frequently complained of abdominal pain.

After eating three apples he was suddenly seized with abdominal pain, signs of obstruction developed, and an operation was performed fourteen days later.

**O p e r a t i o n .**—When the abdomen was opened, a cord was found passing from the umbilicus back into the abdominal cavity. It resembled intestine, and was the size of a finger. Near the umbilicus it looked fibrous, but in the deeper portion resembled bowel. It had encircled a loop of distended bowel and completely occluded it. Peritonitis followed, and the patient died. The cord was found to be the omphalomesenteric duct, which was adherent to the umbilicus.

**C a s e o f P e r f o r a t e U m b i l i c u s . †**—The patient was a male child. Projecting from the umbilicus was a tumor the size of a hazel-nut. It was bright red in color, and was perforated at its apex by an orifice from which there was a continuous mucous discharge. This opening led into a long canal. There was no escape of urine. The fluid looked like and smelled like fecal contents. The mucous membrane was dissected away and the wound closed.

Marshall said that, although the outer opening could be closed, there would always be a risk of some of the contents of the intestine passing into the canal and setting up irritation and suppuration in the region of the umbilicus.

**A P a t e n t O m p h a l o m e s e n t e r i c D u c t . ‡**—The boy was born with an umbilical hernia. On the fourth day, when the cord came away, a red, sausage-like tumor was seen, from which feces and air escaped in small quantities. The boy also passed stools by the rectum. He cried and lost weight. The tumor was covered with mucosa, was the thickness of a thumb, and projected, somewhat like a twisted horn, 3 cm. from the distended umbilicus (Fig. 119). A sound could be introduced into it for 6 to 7 cm. and passed obliquely upward.

When the child was five weeks old, the abdomen was opened and the diverticulum removed. The child made a good recovery. Morian gives a table of the cases of patent omphalomesenteric duct.

**A P a t e n t O m p h a l o m e s e n t e r i c D u c t .**—Nicaise§ reports an observation made by Patry. After ligation of the cord the child cried, was greatly

\* Leisrink und Alsborg: Einklemmung seit 14 Tagen, Laparotomie. Einschnürung durch einen offen gebliebenen Ductus omphalo-mesaraicus; Resection des eingeschnürten Darmstückes mit dem schnürenden Strang; Darmnaht. Tod nach 6 Stunden. Langenbeck's Arch. f. klin. Chir., 1882, xxviii, 768.

† Marshall: Med. Times and Gaz., 1868, ii, 640.

‡ Morian: Ueber das offene Meckel'sche Divertikel. Langenbeck's Arch. f. klin. Chir., 1899, lviii, 306.

§ Nicaise: Ombilic. Dictionnaire encyclopédique des sciences médicales, Paris, 1881, 2. sér., xv, 159.

agitated, vomited, and suffered from constipation and abdominal distention. These symptoms persisted for four or five days and did not cease until the ligature of the cord came away, leaving a large aperture through which an abundance of greenish liquid escaped. The child seemed to be very much relieved. Patry saw the infant for the first time at the eighth month. He was then much emaciated. The umbilical opening easily admitted a probe. It was surrounded by a collar of mucosa the margins of which were raised, round, and reddish in color. From the opening there escaped a quantity of fecal material almost equal to that passed by the rectum. After feeling assured that the fecal material could all escape by the intestine, Patry closed the umbilical orifice. He was able to obtain healing of the fistula by cauterization and compression after a term of two months.

**A Patent Omphalomesenteric Duct.\***—The patient was a child thirteen days old. At birth an unusually thick cord was noted. When it came away on the ninth day a red, moist surface was left behind. This rolled out

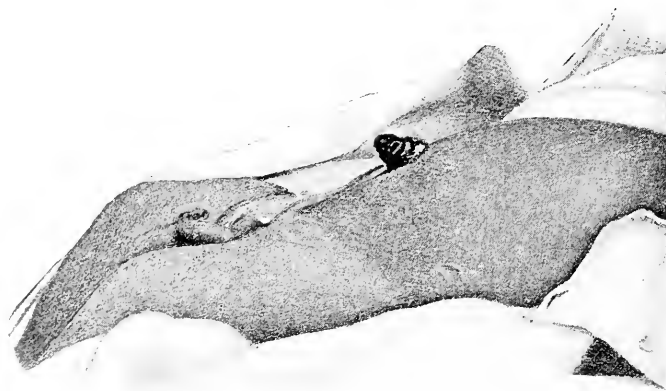


FIG. 119.—A PATENT OMPHALOMESENTERIC DUCT. (After Morian.)

The boy was born with an umbilical hernia. On the fourth day, when the cord came away, a red, sausage-like tumor was seen. It projected 3 cm. from the umbilicus, and was covered with mucosa. It was a patent omphalomesenteric duct, with some prolapsus of its mucosa.

during the next two days. Projecting from the umbilicus, which was prominent, was a red growth 1 cm. long, and covered with mucosa. At the tip of the projection was a small opening the size of a pin-head, into which a probe could be introduced for 8 cm. A mucoserous fluid escaped, but no feces.

The condition was diagnosed as a persistent omphalomesenteric duct with slight prolapsus of the everted intestinal wall. It was not thought to open into the bowel.

**Operation.**—The abdomen was opened and the duct was found attached to the convex surface of the small bowel. It was severed, and, with the umbilicus, removed intact. The child made a good recovery.

**A Patent Omphalomesenteric Duct.**—Park's† patient (Case 2) was a college athlete who gave a history of always having had some discharge from the navel. A probe could be passed downward through a small opening for

\* Neurath, Rudolf: Zur Casuistik des persistirenden Ductus omphalomesaraicus. Wien. klin. Wochenschr., 1896, ix, 1158.

† Park, Roswell: Clinical Lecture on Congenital Fistulae and Sinuses at the Umbilicus. Med. Fortnightly, 1896, ix, 9.

a distance of three inches. A median abdominal incision was made, and the operator found a tubular communication with a loop of small bowel. The fistula was excised and the opening in the bowel closed. The patient made a good recovery.

**A Patent Omphalomesenteric Duct.** — In Pernice's Case 142\* it was noted at birth that there was an abnormal thickening of the umbilicus. The cord came away on the ninth day. The umbilicus did not contract down and close as usual, but a greenish, thick discharge from it was noted; this gradually became yellow and then whitish and turbid. When seen at seven months of age, the boy had at the umbilicus a growth suggesting "proud flesh," which was open in its center. The umbilicus swelled out markedly whenever the child cried. The skin in the vicinity was reddened and excoriated, and the skin papillæ were somewhat enlarged. In the middle of the umbilicus was a broad-based, reddish, mucus-like excrescence, and in the vicinity a funnel-like depression which also had a reddish wall. A probe could be passed down this funnel for 6 cm. toward the pelvis. The canal was broad and easily admitted a No. 12 bougie. When the child cried, the funnel filled with a secretion resembling mucus, which was turbid, alkaline in reaction, and contained particles of fecal matter.

The inner surface of the canal was lined with cylindric cells. The canal was curetted with a sharp spoon several times, and after five weeks it remained closed.

**A Patent Omphalomesenteric Duct.** † — The patient was a male child, three years old. His parents were in good health. On the fifth day after birth the nurse made traction on the cord, as it had not come away. "Inflammation" followed, and a small opening developed. Sometimes this opening would close for three weeks or more, but never for a much longer period.

On examination the mother was surprised to see a worm, half an inch long, crawling along the child's abdomen. The child, who had been ill, rapidly recovered. Several weeks later two worms similar in character were extracted from the umbilical fistula.

Between intervals of abdominal pain the child enjoyed good health, except for occasional pain due to the worms. At the umbilicus was a slight projection the size of a hazelnut, with an opening in the center which discharged contents resembling feces.

On several occasions a physician was called to see the child when in great pain and removed lumbricoid worms from the fistula.

**A Patent Omphalomesenteric Duct.** ‡ — The umbilical cord was unusually thick, for an inch and a half from the abdomen, being more than double the caliber of the rest of the cord. The ligature was applied distally to this thickening, the resultant stump being unusually tense and hard. On the ninth day the covering at the top sloughed, revealing a red, granular projection. At the end of a month the outer covering had disappeared, and a firm, smooth, red tumor remained. This was one and a half inches long, pyriform in shape, and attached to the umbilicus by a short but thick pedicle. Its outer extremity pre-

\* Pernice, L.: Die Nabelgeschwülste, Halle, 1892.

† Poussin: Observation sur l'expulsion de l'abdomen, par une ouverture a l'ombilic, de plusieurs vers ascarides-lombricoïdes. Jour. de méd., 1817, xl, 81.

‡ Pratt, J. W.: A Remarkable Case of Umbilical Tumor. The Lancet, London, 1884, ii, 1142.

sented a central orifice from which a watery fluid exuded more or less constantly. There was no evidence of hernia. The growth was not painful, but bled when handled, unless treated gently with oiled fingers. It became vascular when the child cried. Toward the end of the third week after birth fecal matter commenced to escape. This phenomenon was noted every three or four days during the following month. The child's general health was good.

When the child was seven weeks old, a strong silk ligature was tied around the pedicle of the growth. Three days later, on removal of the dressing, the growth was found detached. The raw area was dressed with zinc ointment and a pad applied. In a few days nothing but an induration was noted around the umbilicus. The child was well a few days later. There was no return of the fistula.

**An Omphalomesenteric Duct so Nearly Patent that Moderate Pressure was Sufficient to Force Intestinal Contents Through the Umbilicus.**—In a male infant at term Prestat\* demonstrated an intact umbilical cicatrix. On opening the abdomen he found a cord the size of a goose-quill,  $2\frac{1}{2}$  inches long, and communicating with the small intestine. This opening was oblique and passed from the convex side of the bowel. When pressure was exerted on the small bowel, fecal matter passed along the fistula and caused a pouting out of the umbilical cicatrix. This readily yielded, allowing feces to escape, thus demonstrating conclusively that the omphalomesenteric duct was practically patent along its entire course and merely sealed over at the umbilicus.

**A Series of Patent Omphalomesenteric Ducts.**—Quaet-Faslem† gives a very good résumé of the literature on the origin of the omphalomesenteric duct, and then reports five cases of persistent patency. The first case had been already recorded by Hansen in his inaugural dissertation (Kiel, 1885).

In Case 2 of his series a boy, nine days old, was admitted to the hospital, on January 4, 1888, because feces were escaping at the umbilicus. At the navel was a long, pear-shaped tumor, 8 to 10 cm. long, with an opening in the center. A sound could be passed through it into the abdomen.

The tumor was cut off with scissors and the opening closed with catgut. The boy made a satisfactory recovery. The fistula was a patent omphalomesenteric duct.

Case 3 (1892). A ten-months-old male child presented a prominent umbilicus with a small opening from which mucus escaped. The tumor was removed and the wound successfully closed.

Case 4 (1885) was that of a boy two days old in whom a blackish-green cord still remained. There was also a conic, red umbilical tumor, showing at its summit a small opening from which mucus escaped. When the child coughed or moved, small fecal masses came away. The tumor was removed and the lumen closed, with good results.

Case 5 (1895). A girl, five years old, was admitted because the umbilicus had never healed and secreted fluid. Around the umbilical opening was a reddening, and at the umbilicus was a hernia the size of a nut, from the center of which a

\* Prestat (quoted by Ledderhose): *Chirurgische Erkrankungen des Nabels*. Deutsche Chirurgie, 1890, Lief. 45 b.

† Quaet-Faslem: *Das Offenbleiben des Ductus omphalo-mesentericus*. Inaug. Diss., Kiel, 1899.



yellowish secretion escaped. The child was very thin and pale. A diagnosis of persistence of the omphalomesenteric duct was made.

Operation.—The tract was dissected out, cut off, and the hole in the bowel closed. The results were satisfactory. It is unusual to find so many cases reported from the same clinic (Petersen's). The cases, though perfectly clear, are fragmentary.

**A Patent Omphalomesenteric Duct with the Central Portion Partially Closed, Preventing the Further Escape of Feces.\***—The patient (L. P.), eleven months old, had a small, smooth projection half an inch long and one-eighth of an inch in diameter at the umbilicus. This was red, cylindric, and covered with mucosa. There was no aperture leading to the abdominal cavity. The mother stated that for some months after the birth of the child there had been a very foul discharge from the navel. This was fecal in character. Now there was no escape of feces, and only occasionally moisture.

The projection was ligated and nipped off, and the child left the hospital three days later in good condition.

On microscopic examination the umbilical polyp was found covered with intestinal mucosa. In some places the covering had been rubbed off. Railton comments on the closure of part of the fistulous tract, thereby shutting off the escape of feces. The closure was probably caused by new connective-tissue formation.

**A Patent Omphalomesenteric Duct.**—Roth (p. 383),† in the description of Case 3, refers to a boy, nearly a month old, who exhibited an unusual outgrowth at the umbilicus after the cord came away. The tumor was cylindric, red in color, and about the size of the last phalanx of a small finger. The cord was unusually large and came away on the eighth day.

When the child was brought to the hospital, this projection was 2 cm. long, and a sound could be introduced 4 cm. downward. The surface of the tumor was velvety. From the fistula bile, yellow grumous masses, and vegetable matter escaped, showing conclusively that it was a fecal fistula. The child died suddenly when six months old.

From a loop of small bowel the diverticulum extended to the umbilicus. From the mesentery a delicate fold passed over the intestine and was adherent to the umbilical ring (Fig. 120, *b*). In this fold several vessels were seen. The diver-

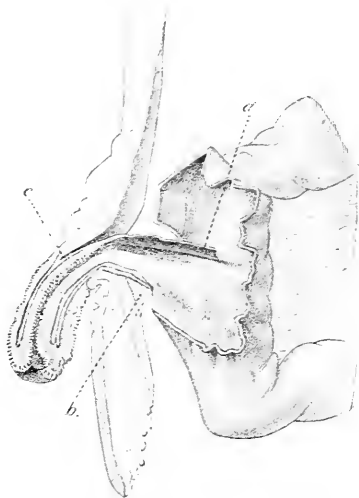


FIG. 120.—A PATENT OMPHALOMESENTERIC DUCT. (After Roth.)

A longitudinal section through the patent duct and the surrounding tissues. *a* is the valve-like flap of mucosa where the omphalomesenteric duct opened into the small bowel. *b* indicates the point of attachment of the duct to the peritoneum of the anterior abdominal wall. Just beneath it is the omphalomesenteric artery. *c* is the edge of the peritoneal fold just above the diverticulum. It will be noted that the outer portion of the duct really formed a penile projection extending downward from the surface of the abdomen.

\* Railton, T. C.: Prolapse of Meckel's Diverticulum (Omphalo-mesenteric Duct). *Brit. Med. Jour.*, 1893, i, 795.

† Roth, M.: Ueber Missbildungen im Bereich des Ductus omphalo-mesentericus. *Virchows Arch*, 1881, lxxxvi, 371.

ticulum was 58 cm. above the ileocecal valve. It gradually became smaller as it passed from the small bowel to the umbilicus. There was a definite valve (Fig. 120, *a*) where the diverticulum passed from the intestine outward.

**A Patent Omphalomesenteric Duct.\***—In May, 1903, a strong five-months-old girl was brought to the clinic with a history that, soon after the dropping off of the cord on the sixth day, there had been observed a small red tumor at the umbilicus. An odor had been detected only a little while before admission. The tumor had an opening at its tip, and from this now and then drops of clear mucus were discharged. It had not increased in size, but when the child cried or when pressure was exercised, it became a little more prominent.

The umbilical nodule was about the size of a pea. It was reddish and velvet-like, with a fistulous opening in the middle through which a sound could be easily passed for 2 cm. into the abdominal cavity (Fig. 121). The tumor was somewhat pedunculated. The mother said that there had never been any discharge of fecal matter from the fistula, and that the child's

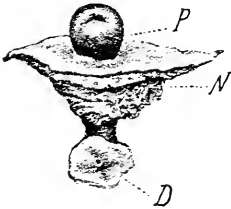


FIG. 121.—A PATENT OMPHALOMESENTERIC DUCT. (After Salzer.)

*P* is the tumor; *N*, the attachment to the abdominal wall; *D*, the opening into the bowel. For the low-power picture see Fig. 122. For the high-power see Fig. 123.

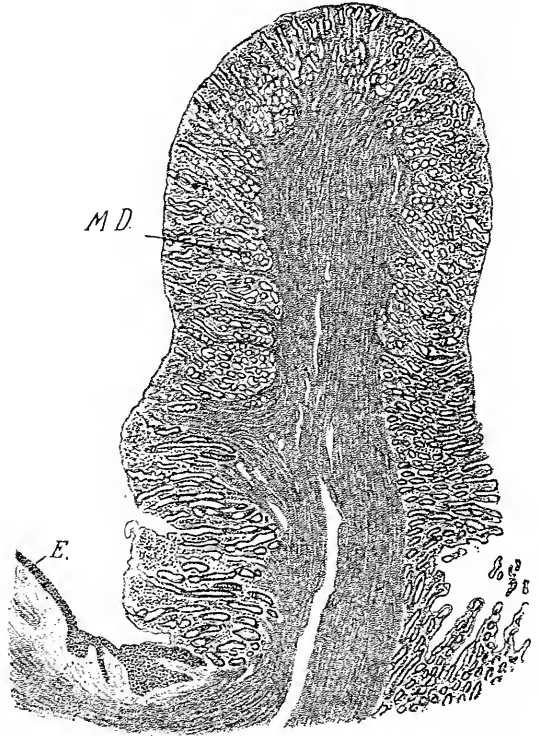


FIG. 122.—PART OF A PATENT OMPHALOMESENTERIC DUCT. (After Salzer.)

Fig. 122 shows a longitudinal section of Fig. 121, on one side of the fistulous tract. The entire outer surface of the tumor is covered over with typical intestinal mucosa. *MD* indicates a point where the glands show some branching. *E* shows the squamous epithelium. The line of junction between the skin and the mucosa is sharply defined. For the high-power picture see Fig. 123.

stools had always been regular. From the history there was no doubt that the condition was due to persistence of the omphalomesenteric duct. The only question was as to whether the fistula was complete or partial.

Operation, June 26, 1903.—An elliptic incision was made, encircling the umbilicus, and a cord was found passing from the navel to the convex side of the small bowel. This cord was 2 cm. long and 0.5 cm. thick. It was covered with

\* Salzer, H.: Ueber das offene Meckel'sche Divertikel. Wien. klin. Wochenschr., 1904, xvii, 614.

peritoneum on all sides. Blood-vessels passed from the mesentery over the bowel to this cord.

The diverticulum was cut off at the bowel; the bowel was closed, and the child made a perfect recovery.

The tumor was hardened in Müller formalin solution and then in alcohol of different strengths and embedded in paraffin. Serial sections were cut in such a manner that they ran parallel with the course of the diverticulum throughout. In some sections it was possible to see that the lumen of the intestine was open and

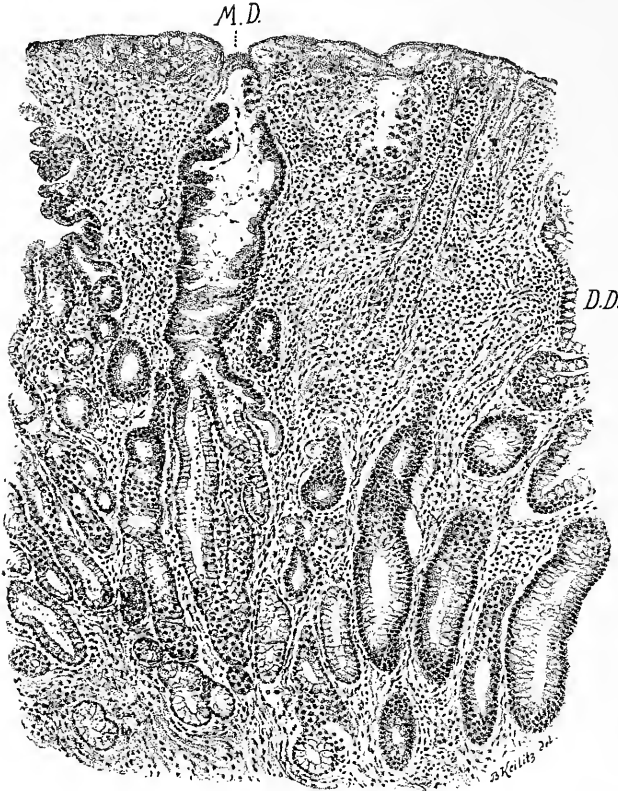


FIG. 123.—INTESTINAL MUCOSA COVERING THE CUTANEOUS OR UMBILICAL END OF A PATENT OMPHALOMESENERIC DUCT. (After Salzer.)

Fig. 123 shows a small portion of Fig. 121. At *M.D.* is a large gland. On being followed downward, its branches are clearly seen. *D.D.* indicates goblet-cells. The surface of the mucosa shows some degeneration, evidently on account of coming in contact with the clothing.

communicated with the umbilical fistula. Some of the sections were stained with hemalum-eosin and some by the van Gieson method. The peritoneal covering of the diverticulum was seen to be directly continuous with that of the intestine as far as the abdominal wall.

The nerve elements of Meissner's and of Auerbach's plexus were found in their normal positions in all portions of the diverticulum. The mucosa of the diverticulum presented points of much interest. In its free abdominal portion, as well as in the region of the abdominal wall, it was identical with the normal mucosa of the small intestine. But where it lay free on the surface of the prolapsus on the

abdomen, the character of the glands was markedly changed. The gland tubules were smaller than Lieberkühn's crypts. They often showed bifurcation or numerous branches and were tortuous (Fig. 123). The gland-cells were clear, finely granular, polygonal in shape, and showed a nucleus resting on the base. They took the eosin weakly, and the glands themselves did not pass as deeply as those of Lieberkühn.

Professor v. Ebner and Professor Schaffer, who examined the specimens, said that all these glands bore some resemblance to those of the cardiac end of the stomach. At the point where the mucosa passed into the skin, the Lieberkühn glands with numerous goblet-cells were again visible (Fig. 122). A portion of the duct resembled, as Professor Ebner said, the mucosa of the large bowel.

Salzer says that, to epitomize the findings, we have a case of a patent omphalomesenteric duct.

**A Patent Omphalomesenteric Duct.\***—J. W., about ten months old, was brought to the clinic on February 27, 1896. On the fifth day after the cord had come away a granulation was noted at the umbilicus. This had an opening the size of a darning-needle. It was surrounded by reddish walls, and by making pressure the midwife could bring away sausage-like masses of fecal matter from the umbilicus. The reddish walls became higher and thicker, and as the fecal discharge did not cease, the child was brought to Dr. Noder, July 31, 1895. Noder was able to introduce a sound fully 10 cm. into the abdominal cavity, and at once greenish, soft fecal matter and greenish-colored fluid escaped. By gradually pressing inward, as one would do with a prolapsed anus, he could diminish the size of the tumor. As a result of four applications of the cautery, the fistula became so constricted that only mucus and watery fluid escaped from it.

As the child was not in very good physical condition, he was brought to the hospital. Projecting from the umbilicus was a sausage-like body, 4.5 cm. long, which spread out over the abdomen (Fig. 124). From its form and also its color it was easily seen that it was divided into two portions. The first was in intimate connection with the abdominal wall (Fig. 124, *a*). It was 2.5 cm. long, about the thickness and roundness of a man's finger, and covered over with a prolongation of the abdominal skin. Sitting on this like a cap was a second portion. It was red, strawberry-shaped (Fig. 124, *b*), and covered over with a shiny red mucosa which secreted an abundant quantity of mucus. Where the first mass joined the second, there was a rather deep depression. No opening could be made out. There was, however, at the top of the red tumor a slight depression (Fig. 124, *c*), but a probe could not be introduced.

On pressure the two portions of the tumor were found to differ in consistence; the first was hard and cord-like; the second was softer and could be pressed together somewhat, but, nevertheless, was firm and uniform. On pressure both developed some gurgling and could be reduced in size. When the child took a long breath the entire mass was pushed outward and then receded again.

The abdominal walls were excoriated. Digestion and defecation were normal. The fluid was alkaline in reaction and contained mucin. There was no evidence whatever of urine at the umbilicus. The case was diagnosed as one of a Meckel's

\* Sauer, Felix: Ein Fall von Prolaps eines offenen Meckel'schen Divertikels am Nabel. Deutsche Zeitschr. f. Chir., 1896-97, xlv, 316.

diverticulum reaching to the umbilicus and originally communicating with the surface.

Operation.—When the peritoneum was opened, it was found that the tract had communicated with a loop of the small bowel. The diverticulum was cut off, the end turned in, and the growth removed. The diverticulum was 3 cm. in length. The child developed peritonitis and died on the third day.

Sauer then goes on to give a careful description of the microscopic findings. He sums up as follows: At a point 53 cm. above the ileocecal valve is the Meckel diverticulum which extends through the umbilical ring. After the dropping off of the um-

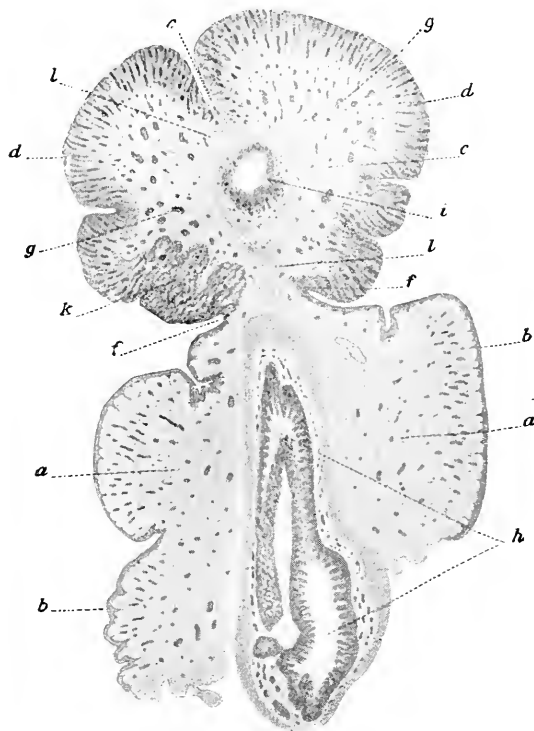


FIG. 125.—LONGITUDINAL SECTION THROUGH THE ENTIRE CENTER OF A PARTIALLY CLOSED OMPHALOMESENTERIC DUCT. (After Sauer.)

For the general appearance of the umbilical tumor see Fig. 124.

*a*, a portion of the tumor lying on the abdominal wall. The tumor, *b*, is covered over with skin and consists of tissue of the abdominal wall; *c*, the tumor covered over with mucosa; *d*, the prominent hypertrophied mucosa of the diverticulum; *e*, the depression where communication with the diverticulum opening into the bowel had formerly taken place; *f*, line of junction between the skin and the mucosa; *g*, blood-vessels; *h*, the portion of Meckel's diverticulum communicating with the bowel; *i*, a portion of Meckel's diverticulum has been nipped off and scar tissue has formed as a result of cauterization; *k*, marked thickening of the mucosa; *l*, scar tissue where the lumen formerly existed.

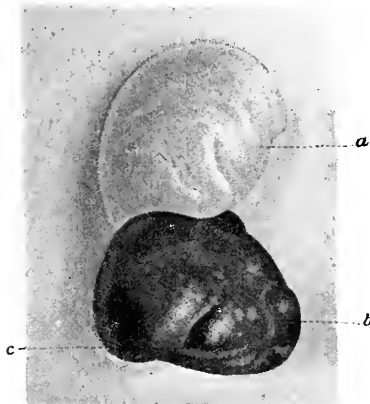


FIG. 124.—AN UMBILICAL POLYP AND A FIBROUS NODULE AT THE UMBILICUS. THERE WAS ORIGINALLY A PATENT OMPHALOMESENTERIC DUCT. (After Sauer.)

*a* is a portion of the prolapsus covered with skin; *b*, the outer end of the omphalomesenteric duct, covered over with mucosa and formerly opening into the bowel; *c* indicates the depression whence the fecal matter had at one time escaped. The opening was closed by means of the thermocautery. For the microscopic picture see Fig. 125.

bilical cord the diverticulum becomes adherent to the abdominal ring. Through mechanical pressure feces escape, then prolapsus of the diverticulum takes place.

By means of the thermocautery the outer portion of the opening was closed. Fortunately, there was no prolapse of the intestine. The opening was still closed at the end of about three months. The solid portion of the tumor is shown in

Figs. 124 and 125, and consists of fibrous tissue. The reddish tumor is covered with typical intestinal mucosa.

**A Patent Omphalomesenteric Duct.**—Schroeder\* says that in the Prag. Path.-anat. Museum (Protocol 479, 1849) is the record of a child six months old. The embryonic omphalomesenteric duct was present. It passed from the umbilicus to the ileum as a canal increasing in size until it joined the bowel.

**A Patent Omphalomesenteric Duct.** †—The patient was a strong, healthy boy three months old. He was admitted to the hospital with a fecal fistula at the umbilicus. At birth the cord was thicker than usual. The ligature came away on the fifth day, and on the following day the nurse noticed flatus escaping from the umbilicus; later, feces were discharged in large or small quantities. A few days after the cord came away the umbilical growth protruded more markedly.

At the site of the umbilicus was a protrusion which was the size of, and had the appearance of, a child's penis. This projection was  $1\frac{1}{2}$  inches long and had at its extremity an opening which looked very much like a preputial orifice. The growth was covered over with mucosa and bled easily. For three or four inches around the umbilicus the skin was raw, red, and eczematous. A probe could be introduced into the projection, and feces escaped. The fistulous tract was large enough to admit easily a pair of artery forceps.

**Operation.**—The abdomen was opened; the diverticulum was cut off, and the hole in the bowel closed. The child made a good recovery.

**A Patent Omphalomesenteric Duct.** ‡—A boy, aged seven, was brought to the hospital on account of a lumbricoid worm which was protruding from the umbilicus. MacSwiney says: "I at once proceeded to deliver it in an artistic way, and I had to exercise some caution in the operation lest it should break, as there was considerable tension on the creature, and it was evident that its body was tightly compressed in a tract or sinus through which it was slowly making its way out."

The father said that since birth there had been a fistula at the umbilicus and that it constantly discharged. There was never, however, any sign of blood, bile, or feces. The discharge was clear yellow matter with no fecal odor. MacSwiney, and his friend, Dr. Kelly, thought the case to be one of an unclosed vitelline duct.

**A Patent Omphalomesenteric Duct.** §—A male child, two months old, was admitted June 1, 1896. The labor had been normal. The old midwife said that in her long experience she had never seen so large an umbilicus in the new-born.

When the cord came away, the mother had noticed at the umbilicus a reddish tumor from the point of which intestinal contents were discharged. Since birth the tumor had grown but very little. The child was well developed and healthy. At the umbilicus was a tumor the size of a hazel-nut. In form it resembled a penile

\* Schroeder, G.: Ueber die Divertikel-Bildungen am Darmkanale. Inaug. Diss. (Erlangen), Augsburg, 1854.

† Shepherd, F.: Umbilical Fecal Fistula in an Infant Cured by Radical Operation. Arch. of Pediatrics, 1892, ix, 55.

‡ MacSwiney, S. M.: Ascaris Lumbricoides extracted from an Umbilical Fistula. Proc. Path. Soc. of Dublin, 1873-75, vi, 251.

§ Stierlin, R.: Zur Casuistik angeborener Nabelfisteln. Deutsche med. Wochenschr., 1897, xxiii, 188.

gland. It was dark red in color, velvety, glistening, and reminded one of intestinal mucosa. At the point of the tumor was an opening which admitted a sound; at the base was a ring of indurated tissue, 4.5 mm. broad, which surrounded the tumor as a cuff. When the child cried, the tumor was a little more prominent. If pressure was made on the abdomen, there escaped a small quantity of gas and fluid fecal matter from the umbilicus. A metallic sound passed 6 to 8 cm. downward; an elastic catheter, 25 cm. and farther, without any difficulty. Defecation and urination were normal. Stierlin came to the conclusion that he had to deal with a diverticulum.

The skin ring at the umbilicus was split upward and downward. It was then easy to separate the tumor from the surrounding structures. On making traction and continuing the dissection Stierlin found that the fistula passed to the convex side of the small bowel. The diverticulum was 6 cm. long (Fig. 126).

While the dissection was being made, it was noted that an artery had been injured. This was isolated, tied, and dropped back into the abdomen. It was a persistent omphalomesenteric artery. The base of the diverticulum was now clamped, and the diverticulum removed. The opening in the bowel was closed with two continuous silk sutures. The child made a good recovery.

**Strangulation of Intestine by Diverticulum Ilei.**—Wilks\* reported a case of obstruction caused by Meckel's diverticulum. The child had previously undergone a successful plastic operation for fecal fistula at the umbilicus.

**A Patent Omphalomesenteric Duct.** †—Peter M., three weeks old, had an umbilical fistula which had been noted soon after the cord came away. A great deal of fecal matter escaped. Surrounding the opening was a small fungous wall. Caustics were applied to the fistulous tract, and a bandage was put on, but without success. Several years later the child was brought back. The fistula had become smaller, but fecal matter still escaped. Caustics were again tried, this time with success.

**A Patent Omphalomesenteric Duct.** ‡—Frederick W., seen by Wernher, was a twin child eleven weeks old, and well formed. The parents said that the child had had intestinal obstruction. At other times there would be abdominal pain and diarrhea. He cried a good deal and vomited. On examination the umbilicus was found to be prominent. Surrounding the margin of the fistula was a fleshy wall which bled readily and was covered with brownish crusts. Wernher lost track of the child, but it was brought back three months later. The

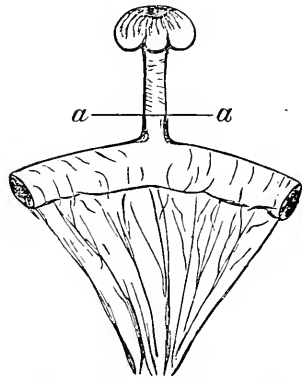


FIG. 126.—A PATENT OMPHALOMESENTERIC DUCT. (After Stierlin.)

A diverticulum springing from the convex surface of a loop of small bowel. It was 6 cm. long, and ended in a mushroom-like extremity. It was cut off at the line indicated by *a-a* and inverted just as one would do with an appendix.

\* Wilks, Samuel: *Trans. Path. Soc. London*, 1865, xvi, 126.

† Weiss, Eduard: *Ueber diverticuläre Nabelhernien und die aus ihnen hervorgehenden Nabelfisteln*. Inaug. Diss., Giessen, 1868.

‡ Weiss, Eduard: *Op. cit.*

projection at the umbilicus was hard, and when the child cried, a few drops of brownish fecal matter escaped. Cauterization was tried and the amount of fecal discharge diminished. Eight days later the opening was closed and the bowels were regular.

Six months later the child was again admitted. A week before admission it had coughed a great deal, and as a result of the coughing a prominence was noticed at the umbilicus. The digestion had been disturbed for some time, and there were diarrhea and colic. As a result of severe coughing the umbilical scar broke and yellowish fecal matter and some blood escaped. The child soon died.

Autopsy.—A Meckel's diverticulum was found extending from the convex side of the bowel; it had a mesentery of its own. The mucosa of the diverticulum of the ileum was much injected. It opened at the umbilicus by a small passage.

#### LITERATURE CONSULTED ON PATENT OMPHALOMESENTERIC DUCT.

- Alsberg, A.: Ueber einen Fall von Radicaloperation eines persistirenden Ductus omphalo-meseraicus. *Deutsche med. Wochenschr.*, 1892, xviii, 1040.
- Ardouin, P.: Persistence du diverticule de Meckel ouvert à l'ombilic, fistule stercorale, omphal-ectomie, extirpation du diverticule, guérison. *Arch. prov. de Chir.*, 1908, xvii.
- Barth, A.: Ueber die Inversion des offenen Meckel'schen Divertikels und ihre Complication mit Darmprolaps. *Deutsche Zeitschr. f. Chir.*, 1887, xxvi, 193.
- Battle, W. H.: Extroversion of Meckel's Diverticulum. *Clin. Soc. Trans.*, London, 1893, xxvi, 237.
- Billroth: *Chir. Klinik*, Berlin, 1869, 294.
- Broadbent: Patent Vitelline Duct. *Med. Times and Gaz.*, 1866, ii, 45.
- Broca, A.: Persistence du diverticule de Meckel ouvert à l'ombilic et invaginé au dehors. *Revue d'orthopédie*, 1895, vi, 47.
- Bureau, J.: Prolapsus ombilical du diverticule de Meckel. *Thèse de Paris*, 1898, No. 257.
- Brun, L. A.: Sur une espèce particulière de tumeur fistuleuse stercorale de l'ombilic. *Thèse de Paris*, 1834, No. 238.
- Deschin: Zur Frage der chirurgischen Behandlung bei dem Vorfall des Dotterganges. *Centralbl. f. Chir.*, 1895, xxii, 1154.
- Eves: A Case of Diverticulum Ilei Communicating with the Umbilicus. *The Lancet*, London, 1845, i, 101.
- Fitz, R.: Persistent Omphalomesenteric Remains, their Importance in the Causation of Intestinal Duplication, Cyst-formation, and Obstruction. *Amer. Jour. Med. Sci.*, 1884, lxxxviii, 30.
- Froelich, R.: Fongus ombilical du nouveau-né, prolapsus ombilical du diverticule de Meckel. *Étude de chir. infantile*, Paris, 1905, 85. Du Fongus ombilical du nouveau-né, à l'occasion d'une operation de prolapsus ombilical du diverticule de Meckel. *Rev. mens. des mal. de l'enfance*, Paris, 1902, xx, 517.
- Gevaert, G.: Fistule ombilicale diverticulaire chez un enfant. *Ann. de méd. et de chir.*, 1892, iv, 1.
- Hansen, J. A.: Ein Beitrag zur Persistenz des Ductus omphalo-entericus. *Inaug. Diss.*, Kiel, 1885.
- Heaton, G.: Fecal Concretion discharged at the Umbilicus. *Brit. Med. Jour.*, 1898, i, 627.
- Hickman: Persistent Vitelline Duct. *Trans. Path. Soc. London*, 1869, xx, 418.
- Holmes, T.: Surgical Treatment of Diseases of Children, London, 1868, 181.
- Jacoby, M.: Zur Casuistik der Nabelfisteln. *Berlin. klin. Wochenschr.*, 1877, xiv, 202; *Jahrbuch für Kinderheilkunde und phys. Erzieh.*, 1878, xii, 144.
- Kehr, H.: Ueber einen Fall von Radicaloperation eines persistirenden Ductus omphalomeseraicus. *Deutsche med. Wochenschr.*, 1892, xviii, 1166.
- King, T. W.: Fæculent Discharge at the Umbilicus from Communication with the Diverticulum Ilei. *Guy's Hospital Reports*, 1843, i, 2. series, 467.
- Kern: Ueber das offene Meckel'sche Divertikel. *Beiträge z. klin. Chir.*, 1897, xix, 353.
- Kirmisson, E.: Persistence du diverticule de Meckel ouvert à l'ombilic avec prolapsus de la muqueuse intestinale. *Revue d'orthopédie*, 1901, xii, 321.



- Körte: Ein Fall von Extirpation des persistirenden Ductus omphalomesentericus. Deutsche med. Wochenschr., 1898, xxiv, 103.
- Lannelongue et Frémont: De quelques variétés de tumeurs congénitales de l'ombilic et plus spécialement des tumeurs adénoïdes diverticulaires. Arch. gén. de méd., 1884, 7. sér., xiii, 36.
- Leisrink und Alsberg: Einklemmung seit 14 Tagen, Laparotomie. Einschnürung durch einen offen gebliebenen Ductus omphalo-mesaraicus; Resection des eingeschnürten Darmstückes mit dem schnürenden Strang; Darmnaht. Todnach 6 Stunden. Langenbeck's Arch. f. klin. Chir., 1882, xxviii, 768.
- Marshall: Case of Perforate Umbilicus. Med. Times and Gaz., 1868, ii, 640.
- Morian: Ueber das offene Meckel'sche Divertikel. Langenbeck's Arch. f. klin. Chir., 1899, lviii, 306.
- Nicaise: Ombilic. Dictionnaire encyclopédique des sciences médicales, Paris, 1881, 2. sér., xv, 159.
- Neurath, R.: Zur Casuistik des persistirenden Ductus omphalo-mesaraicus. Wien. klin. Wochenschr., 1896, ix, 1158.
- Park, Roswell: Clinical Lecture on Congenital Fistulae and Sinuses at the Umbilicus. Med. Fortnightly, 1896, ix, 9.
- Pernice, L.: Die Nabelgeschwülste, Halle, 1892.
- Poussin: Observation sur l'expulsion de l'abdomen, par une ouverture à l'ombilic, de plusieurs vers ascarides-lombricoïdes. Jour. de méd., 1817, xl, 81.
- Pratt, J. W.: A Remarkable Case of Umbilical Tumor. The Lancet, London, 1884, ii, 1142.
- Prestat: Ledderhose, Chirurgische Erkrankungen des Nabels. Deutsche Chirurgie, 1890, Lieferung 45 b.
- Quaet-Faslem: Das Offenbleiben des Ductus omphalo-mesentericus. Inaug. Diss., Kiel, 1899.
- Railton, T. C.: Prolapse of Meckel's Diverticulum (Omphalo-mesenteric Duct). Brit. Med. Jour., 1893, i, 795.
- Roth, M.: Ueber Missbildungen im Bereich des Ductus omphalo-mesentericus. Virchows Arch., 1881, lxxxvi, 371.
- Salzer, H.: Ueber das offene Meckel'sche Divertikel. Wien. klin. Wochenschr., 1904, xvii, 614.
- Sauer, F.: Ein Fall von Prolaps eines offenen Meckel'schen Divertikels am Nabel. Deutsche Zeitschr. f. Chir., 1896-97, xlv, 316.
- Schroeder, G.: Ueber die Divertikel-Bildungen am Darmkanale. Inaug. Diss. (Erlangen), Augsburg, 1854.
- Shepherd, F.: Umbilical Faecal Fistula in an Infant Cured by Radical Operation. Arch. of Pediatrics, 1892, ix, 55.
- MacSwiney, S. M.: Ascaris Lumbricoïdes extracted from an Umbilical Fistula. Proc. Path. Soc. of Dublin, 1873-75, iv, 251.
- Stierlin, R.: Zur Casuistik angeborener Nabel fisteln. Deutsche med. Wochenschr., 1897, xxiii, 188.
- Wilks, S.: Strangulation of Intestine by Diverticulum Ilei. Trans. Path. Soc. London, 1865, xvi, 126.
- Weiss, Eduard: Ueber diverticuläre Nabelhernien und die aus ihnen hervorgehenden Nabel fisteln. Inaug. Diss., Giessen, 1868.

## CHAPTER XI.

### A PATENT OMPHALOMESENTERIC DUCT—(Continued).

The opening of a patent omphalomesenteric duct on the side of the umbilical cord before the cord drops off: Report of cases.

Prolapsus of the bowel through a patent omphalomesenteric duct opening on the side of the umbilical cord.

Escape of meconium into the liquor amnii through the umbilicus.

An omphalomesenteric duct opening into the abdomen and discharging feces into the abdominal cavity.

A patent omphalomesenteric duct associated with defective development of the rectum or anus.

In this chapter are considered several cases of patent omphalomesenteric duct that presented some rather unusual features.

#### THE OPENING OF A PATENT OMPHALOMESENTERIC DUCT ON THE SIDE OF THE UMBILICAL CORD BEFORE THE CORD DROPS OFF.

A GLANCE at Fig. 10, p. 10, Fig. 11, p. 11, Fig. 12, p. 12, in the chapter on Embryology, will show that in the early months of fetal life a large part of the intestine lies in the exocoelomic cavity of the cord. As the embryo develops nearly all the intestine is found in the sac, but finally the bowel recedes into the abdomen and this sac becomes obliterated.

That the sac occasionally remains open, and contains a patent omphalomesenteric duct, is clearly demonstrated by the following cases:

Peake, in 1811, in a new-born child observed a tumor at the umbilicus. It was larger than a walnut, and the skin grew over it for a quarter of an inch. The tumor had the appearance of intestine protruding into the umbilical cord. The cord was ligated at a point three or four inches from the umbilicus. At the lower part of the tumor Peake noticed a fissure, and soon a thin, dark material escaped from the opening. The child died on the third day, and at autopsy the ileum was found protruding at the umbilicus.

Auvard, in 1889, observed a tumor at the umbilicus in a newly born child, Accordingly the cord was tied at a point 8 cm. from the umbilicus. The tumor measured 3 x 4 cm. In the anterior portion of the cord, 3 cm. from the umbilicus, was an opening which had everted margins and measured 3 to 4 mm. It was reddish in color, and meconium escaped from it. Both the mother and the midwife said this opening existed when the child was born (Fig. 127, p. 216, Fig. 128, p. 216). The child's bowels moved regularly, but it sometimes vomited fecal matter.

When the cord came away, a red tumor the size of a walnut remained, which was continuous with the opening. At autopsy a patent omphalomesenteric duct was found (Fig. 129).

Gampert, in 1893, reported a case in which the cord was larger than usual. It was accordingly tied at a point 9 cm. from the umbilicus. Five days later, although the cord was still attached, yellowish material began to escape from its base. The

cutaneous umbilical orifice was prominent, and formed a collar around the tumor occupying its center. This tumor was 1 cm. in diameter and irreducible, and in its center was an orifice from which gas and feces escaped. A sound could be carried for 3 or 4 cm. into the fistula. The surrounding skin was slightly irritated. On the tenth day a slight prolapse of the mucosa occurred. Fearing prolapsus of the bowel, Gampert cauterized the canal, applied a ligature to the tumor, cut off the excess, and applied pressure. In this way the fistula was successfully closed.

Guthrie, in 1896, recorded the case of a child that had had no movement for three days after birth. Feces then began to escape from an opening in a colorless, bladder-like projection, which had existed at the umbilicus since birth. This protrusion was attached to the cord. It became red and inflamed, ulcerated, and then disappeared.

For a month after birth some feces were passed by the rectum, and then all escaped through the umbilicus. Later there occurred a prolapse of the bowel through the opening, which, however, finally disappeared spontaneously. At autopsy the patent omphalomesenteric duct was found at a point 12 inches above the ileocecal valve.

#### CASES IN WHICH THE OMPHALOMESENTERIC DUCT OPENED ON THE SIDE OF THE UMBILICAL CORD.

A Patent Omphalomesenteric Duct Opening to the Side of the Umbilical Cord.\*—In this case the midwife noticed a tumor at the umbilicus. The cord was tied distally to this, at a point 8 cm. from the insertion at the umbilicus. When the child was seen by Auvard, there was a cylindric tumor, measuring 3 x 4 cm., at the umbilicus. This was included in the membranes of the cord and covered with amnion. The cord was free for about 6 cm. from the umbilicus. In the anterior portion of the cord, at a point 3 cm. from the umbilicus, was an opening, the margins showing an eversion. This opening was reddish in color; it measured 3 x 4 mm., and from it there escaped a greenish liquid, rather thick, and of the character of meconium. The midwife and the mother said that this opening had existed at the time of the child's birth (Figs. 127 and 128). The bowels moved regularly. All the generative organs were normal.

This boy was transferred on the fourth of January to La Charité. By January 8th the cord had not yet come away, but a small quantity of greenish liquid was escaping from the opening. The discharge was sometimes yellowish. The patient vomited frequently, and the fecal matter was sometimes green. On January 10th the cord came away, leaving a red tumor, the size of a walnut, continuous with the opening above described. A sound introduced could be passed into the cavity without difficulty, and carried inward 6 cm. The child's weight continually diminished.

On January 12th the child was presented at the Obstetrical and Gynecological Society of Paris. The members present, particularly Lucas-Championnière, were of the opinion that the tumor represented a hernia of the diverticulum of the intestine. The child's weight continued to diminish, and he died on February 3d, apparently from weakness. The umbilical tumor had diminished in size. At autopsy it was not larger than a pea. When the abdomen was opened, a loop of

\* Auvard: *Travaux d'obstétrique*, 1889, Paris, i, 331.

small bowel was found extending toward the umbilicus, and a diverticulum opened from the loop through the umbilicus (Fig. 129). The diverticulum entered the small bowel at a point 42 cm. from the cecum.

**A Patent Omphalomesenteric Duct Opening on the Side of the Umbilical Cord.\***—The cord at the umbilicus was larger than usual. The ligature was applied at a point 9 cm. from the umbilicus. On February 15th, five days after birth, the midwife called Gampert, because the cord did not come away and because at its base a yellowish material was escaping. This discharge resembled fecal matter. The stools passed normally by the rectum.

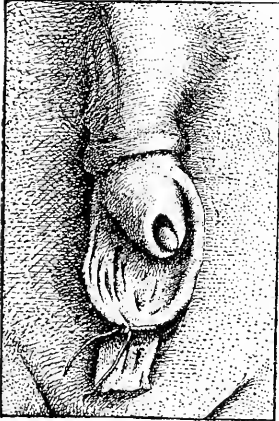


FIG. 127.—A PATENT OMPHALOMESENTERIC DUCT OPENING AT THE BASE OF THE UMBILICAL CORD. (After Auvard.)

This sketch was made four days after the birth of the child. The cord was ligated at a point about 8 cm. from the umbilicus. In the anterior part of the cord, 3 cm. from the umbilicus, was an opening admitting the little finger. The margins were raised, and there was some eversion, the everted portion being reddish in color. From the orifice a greenish material, having the characteristics of meconium, escaped. There was frequent vomiting.

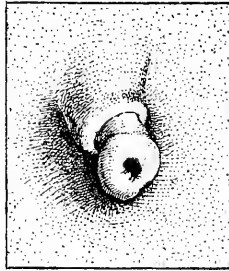


FIG. 128.—A PATENT OMPHALOMESENTERIC DUCT. (After Auvard.)

This picture was obtained eleven days after birth. The cord came away on the seventh day, and left a pinkish tumor the size of a walnut, with the opening as shown. The child became weaker, and died after a month. For the appearance four days after birth see Fig. 127. For the intra-abdominal picture see Fig. 129.

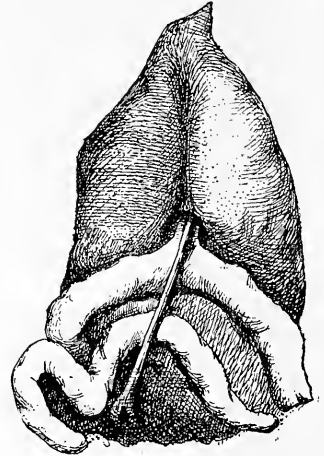


FIG. 129.—A PATENT OMPHALOMESENTERIC DUCT AS SEEN FROM THE ABDOMINAL CAVITY. (After Auvard.)

This picture was obtained at autopsy. A loop of small bowel lies near the inner umbilical opening, and from it a diverticulum passes directly to the umbilicus. It opened on the surface. Passing from the mesentery over loops of small bowel to the umbilicus was a fine fibrous cord, evidently a remnant of an omphalomesenteric vessel.

When seen, the child was large and well developed, and the cord was still adherent to one-half of the circumference of the umbilicus. The cutaneous umbilical orifice was prominent, and formed a large collar around the tumor which occupied the center. This tumor was about the size of the little finger, and cylindric in form and shape. It was 1 cm. in diameter and irreducible. It had in its center an orifice from which yellowish material and gas escaped. A sound could be carried in to a depth of 3 or 4 cm. The skin around the umbilicus was slightly irritated.

On the tenth day, when the child cried, a slight prolongation of the mucosa showed at the orifice. Fearing prolapsus of the bowel, Gampert cauterized the

\* Gampert: *Fistule entéro-ombilicale diverticulaire chez un nouveau-né*. *Rev. méd. de la Suisse romande*, 1893, xiii, 356.

canal and used pressure. The tumor diminished, and tannic acid powder and vaselin were used. A silk ligature was applied, and the excess of tissue was cauterized. When the ligature came away, the opening was closed and remained so.

**A Case of Patent Meckel's Diverticulum into which the Posterior or Distal Wall of the Ileum Became Intussuscepted, Forming an Umbilical Tumor; Death.\***—A male infant, six weeks old, was admitted to the Paddington Green Hospital on April 25, 1892. At birth it weighed seven pounds and three ounces. After three days, during which there was no stool, the child began to defecate through an opening in a colorless, bladder-like projection, which had existed from birth at the umbilicus and to which the cord was attached. The cord separated on the ninth day.

The colorless protrusion subsequently became red and inflamed and finally ulcerated; it disappeared a few days before admission. For about a month after birth some portion of the feces came from the rectum, but later all passed through the umbilicus. Micturition was normal.

On admission the child was puny and emaciated. Protruding from the umbilicus was an elongated mass,  $1\frac{1}{2}$  inches long by 1 inch in breadth. It was of a dull red color, and had the appearance of intestinal mucosa. Near its superior extremity there was an opening through which feces were discharged, and a catheter could be passed upward and to the right. There was also a small dimple on the inferior end of the protrusion. This would not admit a probe.

On April 29th the protrusion increased to the length of six inches. It became somewhat tightly constricted at the umbilicus. It was much congested, and resembled an intussusception. Taxis failed.

As the patient was too weak, the hernia was let alone. Two days later it disappeared spontaneously, but the child died of exhaustion May 2d.

**Autopsy.**—The fistula was 12 inches above the ileocecal valve. The upper opening led to the somewhat dilated ileum; the lower opening to the collapsed small and large bowel. The entire large bowel was not bigger than a lead-pencil. The cecum was reduced to the size of the first joint of the little finger. The large bowel apparently had never contained feces. There had been a prolapsus of the bowel through the patent omphalomesenteric duct.

**Case of Preternatural Anus Found in a Portion of Ileum Protruded at the Umbilicus.**—J. Peake,† a member of the Royal College of Surgeons, London, found, on delivering a woman of a healthy-looking boy, that the child had a tumor at the umbilicus. This was larger than a walnut, and the skin grew over it for a quarter of an inch. At the upper part the umbilical vessels passed over the tumor but seemed altogether distinct from it. A ligature was tied around the cord where it appeared normal, that is, at a point three or four inches from the umbilicus.

Peake goes on to say that the tumor had the appearance of a protruding portion of the intestine within the umbilical cord, and at its lower part he could observe a fissure. Soon a thin, dark material escaped from this opening; it was probably meconium.

Shortly after birth the child vomited frequently, and was evidently ill. It

\* Guthrie, L. G.: *Pediatrics*, 1896, ii, 1.

† Peake, J.: *Edinb. Med. and Surg. Jour.*, 1811, vii, 52.

had many convulsions, and died on the third day. The food that was given it was either directly brought up again or afterward passed through the aperture at the navel. Nothing seemed to pass along the regular course of the intestine. Just before death a little mucus and meconium escaped by the rectum.

Autopsy.—The passage from the stomach to the umbilicus was normal. A portion of the ileum protruded at the umbilicus. The bowel below was much smaller than normal.

#### PROLAPSUS OF THE BOWEL THROUGH A PATENT OMPHALOMESENTERIC DUCT OPENING ON THE SIDE OF THE UMBILICAL CORD.

Prolapsus of the bowel through a patent omphalomesenteric duct is discussed at length in Chapter XII. The case recorded by Gibb is the only example known to me in which prolapsus of the bowel occurred on the side of the cord during the first few hours of life. In Guthrie's case the omphalomesenteric duct opened on the side of the cord, but prolapsus did not occur until several weeks after the cord came away.

Unique Congenital Malformation, Associated with Umbilical Hernia and a Pendulous Artificial Anus.—Gibb\* reports a rather unusual condition noted a few hours after the child's birth. The upper part of the cord had dilated, forming an umbilical hernia containing intestine. Attached to the side of the sac was a blood-red body with villous surfaces, looking like intestinal mucous membrane. Meconium passed from both ends of this body. From the anus feces passed on the third day. At autopsy the large bowel was found to be diminished in size. Gibb thought that the mass was a portion of the cecum and the ileum. [This picture (Fig. 130) presents the appearances typical of a prolapse or inversion of the small bowel through the patent omphalomesenteric duct in association with an umbilical hernia.]

#### ESCAPE OF MECONIUM INTO THE LIQUOR AMNII THROUGH THE UMBILICUS.

If Auvard had been present when the child, whose case he reported, was born, he would probably have found meconium in the liquor amnii, as the omphalomesenteric duct lay open on the side of the cord. In other words, at birth there was a direct connection between the lumen of the small bowel and the amniotic cavity.

The only case in which it is definitely stated that meconium escaped through the cord into the liquor amnii is the one mentioned by Brindeau.

A Patent Omphalomesenteric Duct, with Fecal Matter Escaping into the Liquor Amnii. †—The patient, an eight months child, died on the fifth day after birth. Its weight was two pounds and three ounces. Meckel's diverticulum was 22 cm. above the cecum. The omphalomesenteric duct was open, and traction had drawn the gut outward at a sharp angle. The portions of the intestine immediately above and below the duct were thus easily drawn together, like the barrel of a fowling-piece.

Meconium before birth had passed into the liquor amnii. The intestine above the diverticulum was dilated; below, it was very small.

\* Gibb: Trans. Path. Soc. London, 1856, vii, 216.

† Brindeau: Nouv. arch. d'obstét. et de gyn., Février 25, 1895, 45.

AN OMPHALOMESENTERIC DUCT OPENING INTO THE ABDOMEN AND DISCHARGING FECES INTO THE ABDOMINAL CAVITY.

Weiss\* said: "Notwithstanding the fact that in dead-born children diverticula are found in the umbilical cord, there has been no example of death due to an out-

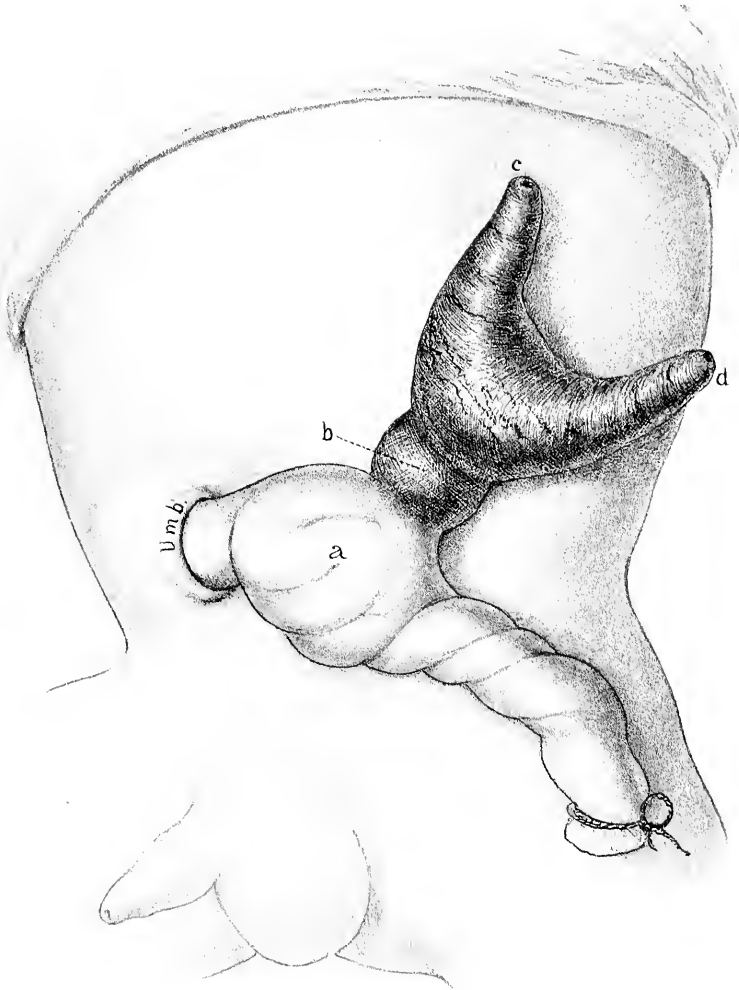


FIG. 130.—INVERSION OF THE BOWEL THROUGH A PATENT OMPHALOMESENTERIC DUCT OPENING ON THE SIDE OF THE UMBILICAL CORD. (Redrawn after Gibb.)

At *a* is a hernial dilatation of the cord. This sac was filled with intestines. At *b* is the opening of a patent omphalomesenteric duct. Through this the small bowel had prolapsed, turning inside out. At *c* and *d* are the bowel openings. As the bowel had turned inside out, its mucosa was, of course, congested and dark red.

pouring of fecal matter into the abdominal cavity." This was probably true at that date, but Orth † says: "I recently made an autopsy on a new-born child and found a diverticulum split longitudinally below the umbilicus and adherent to the

\* Weiss: Inaug. Diss., Giessen, 1868.

† Orth: Lehrbuch der spec. path. Anatomie, Berlin, 1887, i, 765.

anterior abdominal wall in such a manner that meconium could escape into the abdominal cavity. A large quantity of meconium lay between the abdominal wall and the thickened omentum."

LITERATURE CONSULTED ON THE OPENING OF THE PATENT OMPHALOMESENTERIC DUCT ON THE SIDE OF THE UMBILICAL CORD OR IN THE ABDOMINAL CAVITY.

Auvard: *Travaux d'obstétrique*, 1889, Paris, i, 331.

Brindeau: *Nouv. arch. d'obstét. et de gyn.*, Février 25, 1895, 45.

Gampert: *Fistule entéro-ombilicale diverticulaire chez un nouveau-né*. *Rev. méd. de la Suisse romande*, 1893, xiii, 356.

Gibb: *Unique Congenital Malformation Associated with Umbilical Hernia and a Pendulous Artificial Anus*. *Trans. Path. Soc. London*, 1856, vii, 216.

Guthrie, L. G.: *A Case of Patent Meckel's Diverticulum into which the Posterior or Distal Wall of the Ileum became Intussuscepted, forming an Umbilical Tumor*. *Death*. *Pediatrics*, 1896, ii, 1.

Peake, J.: *Case of Preternatural Anus found in a Portion of Ileum protruded at the Umbilicus*. *Edinburgh Med. and Surg. Jour.*, 1811, vii, 52.

Weiss, E.: *Ueber diverticuläre Nabelhernien und die aus ihnen hervorgehenden Nabelfisteln*. *Inaug. Diss.*, Giessen, 1868.

A PATENT OMPHALOMESENTERIC DUCT ASSOCIATED WITH DEFECTIVE DEVELOPMENT OF THE RECTUM OR ANUS.

Anderson's patient was a child born at the seventh month. There was no anus, and the rectum and sigmoid were lacking. The omphalomesenteric duct was patent.

Cheyne's patient was a three-weeks-old child. The omphalomesenteric duct was patent. The anus ended in a blind pouch, one inch within the sphincter. The child was still alive when the case was reported to the medical society.

Nicolas's patient was a child six days old. The omphalomesenteric duct was patent. The anus was open, but an obstruction was found several inches above it.

*A Case of Fecal Fistula at the Umbilicus with Non-development of the Sigmoid Flexure and Rectum.\** — The patient was a male child delivered at the seventh month. After tying and cutting the cord, the physician noticed a red tumor of nevoid aspect at the line of section, and perceived that the proximal end of the cord was considerably enlarged. On the following day meconium escaped from the umbilical stump. There was no trace of an anal orifice. The edges of the umbilical orifice became red and everted. The child lost flesh, and died on the twenty-third day after birth.

At autopsy prolapsus of the ileum through the umbilicus was found. This was  $1\frac{1}{4}$  inches from the cecum. The short portion of the ileum extending to the cecum was empty. The sigmoid and rectum were wanting.

[The opening undoubtedly represented a patent omphalomesenteric duct.]

*A Patent Omphalomesenteric Duct Associated with an Imperforate Rectum.* — Mr. Cheyne † showed an infant, aged three weeks, with congenital umbilical fecal fistula, and asked for suggestions as to treatment. The child was rapidly losing weight. The anus was present, and a sound

\* Anderson, William: *Trans. Path. Soc. London*, 1891, xlii, 128.

† Cheyne, Watson: *Umbilical Fecal Fistula*. *Brit. Med. Jour.*, 1892, i, 815.



passed in about an inch. The umbilical aperture seemed to lead into a canal. The general impression seemed to be that operative intervention was undesirable.

**P a t e n t O m p h a l o m e s e n t e r i c D u c t A s s o c i a t e d w i t h a n I m p e r f o r a t e S i g m o i d .**—Nicolas\* (Obs. 12) refers to a boy six days old who was observed in Marjolin's clinic. At birth there was a purulent discharge from the umbilicus, and nothing had passed by bowel. The child had vomited fecal matter several times. On rectal examination the anus was found to be patent, but there was an obstruction at a point several centimeters higher up, so that not even gas could be expelled by the rectum. Two days later an artificial anus was made, but the child died forty-eight hours later.

**Autopsy.**—The small bowel was large for so young a child. At a point 80 cm. from the pylorus it was  $2\frac{1}{2}$  times the normal in diameter. It suddenly dilated and became 4 to 5 cm. in diameter. Meckel's diverticulum was 3 cm. long.

Had it not been for the open omphalomesenteric duct these children would have succumbed a few days after birth. The open duct was in reality a safety valve. For those desiring a more extended knowledge of the subject of patent omphalomesenteric duct associated with faulty development of the bowel, a careful perusal of Ahlfeld's splendid monograph is to be recommended.

In these cases it would be necessary to establish the continuity of the bowel before attempting to remove the omphalomesenteric duct.

\* Nicolas, P.: Sur deux variétés de fistules ombilicales, Paris, 1883.

#### LITERATURE CONSULTED

##### ON PATENT OMPHALOMESENTERIC DUCT ASSOCIATED WITH DEFECTIVE DEVELOPMENT OF THE RECTUM OR ANUS.

- Anderson, Wm.: A Case of Fecal Fistula at the Umbilicus with Non-development of the Sigmoid Flexure and Rectum. Trans. Path. Soc. London, 1891, xlii, 128.  
 Cheyne, Watson: Umbilical Fecal Fistula. Brit. Med. Jour., 1892, i, 815.  
 Nicolas, P.: Sur deux variétés de fistules ombilicales, Paris, 1883.  
 Ahlfeld: Zur Ätiologie der Darmdefecte und der Atresia ani. Arch. f. Gyn., 1873, v, 230.

## CHAPTER XII.

### PROLAPSUS OF THE BOWEL THROUGH A PATENT OMPHALOMESENERIC DUCT.

Historic sketch.

Prolapsus of the bowel.

Results.

Findings at autopsy.

Cases of prolapsus of the bowel through a patent omphalomesenteric duct.

IN 1843 King reported an observation made by Parsons and Gunthorpe in which the small bowel had prolapsed through a patent omphalomesenteric duct and was recognized as a sausage-like mass lying on the abdomen in the umbilical region. From time to time since then an isolated case has been observed. We shall now refer briefly to certain conditions which may be found associated with this abnormality.

**The Cord.** — In some of these cases, when the child is born, the cord near the umbilicus is unusually thick. In one case, reported by Gesenius, this thickened area gave a crackling sensation when it was grasped between the fingers.

**Age.** — The condition has been noted as early as the third day and as late as six months after birth. In nearly half of the cases it occurred within the first two weeks. In Löwenstein's case the child was three months old; in Helweg's, four months; in Kölbinger's, nineteen weeks; in Hüttenbrenner's and in Weinlechner's case, five months, and in Blin's case, six months.

**Development of the Umbilical Fistula.** — In considering these cases we must remember that the omphalomesenteric duct has remained patent from the intestine through the umbilicus, and out for a variable distance into the cord. If it has remained open to the point where the cord has been tied off, of course, a fecal fistula will be present just as soon as the cord drops off. When the fistulous tract is very small, it may be impossible for feces to escape for some days. Should the duct be patent just to the umbilicus, a small umbilical polyp may present itself in the umbilical depression and no fistula will for the time being be noted.

It may be interesting to trace the development of the fistula in the individual cases.

In Barth's case, when the cord came away, there was a red nodule 1 cm. in diameter at the umbilicus, and in the center of this a fistula, into which a probe could be introduced for 4 cm.

In Gesenius's case a small polyp was noted when the cord came away. Next day this showed an opening in its center, and two days later the projection had increased in size and looked like a raspberry. The opening now admitted a catheter for six or seven inches, and feces escaped from it.

In Gevaert's and in Golding-Bird's cases the fistula was noted when the cord came away.

In Basevi's case, when the cord dropped off, it was apparent that the umbilicus had not healed, a reddish, moist wound remaining. Feces did not escape until later.

In Löwenstein's case, after the cord came away, an "inflammation" was noted at the umbilicus. On the fourteenth day a fistula developed. Löwenstein urged operation, which was refused. Later the opening became as large as a 50-pfennig piece, and three weeks after this as large as a plum.

In Arndt's and in Ophüls's case a small umbilical polyp was found in addition to the fistula, and in Blin's case there were two small polyps as well as a minute fistulous opening.

In Théremin's Case 1 the cord came away on the eleventh day. In the center of the umbilical ring was a reddish tumor, conic in form, and resembling an umbilical polyp. There were small ulcers on the surface of the tumor, and on the twenty-third day a superficial hemorrhage occurred.

In Théremin's Case 2 the cord came away on the eighth day, leaving at the umbilicus a conic red polyp, 1.5 cm. long and 1 cm. broad. There was no vestige of an opening. Twelve days later the polyp had receded; it was not over 5 mm. long, but had an ulcer in its center, from which a few drops of blood escaped. On the following day the polyp showed a small central opening.

In Holmes' patient, who was born prematurely, the umbilical cord bifurcated three inches from the abdomen. It was tied off below the bifurcation. A fecal fistula was noted after two weeks.

In the following cases a small reddish tumor had been noted at the umbilicus, but the fistula did not develop until this umbilical polyp had been tied off.

Helweg's patient, a boy four months old, had a penis-like tumor at the umbilicus. This was not present at his birth. It was covered with mucosa, and had in its center a canal into which a sound could be introduced, but no feces escaped from it. The tumor was tied off with silk. It became necrotic in four days; shortly after prolapsus of the bowel was noted.

In King's case an umbilical polyp was removed by means of caustics. When it came away feces escaped.

In Kölbing's case a polyp existed at the umbilicus. This was tied off and removed. Later there was prolapsus of the bowel through the patent duct.

From the evidence here adduced it is perfectly clear that in some cases the fecal fistula develops just as soon as the cord comes away. If the opening be of sufficient caliber, feces escape readily, but if very small, only mucus may be discharged for a time. In other cases the outer end of the omphalomesenteric duct has not extended to the point at which the cord has been ligated, but as a result of ulceration or gangrene the intervening barrier may be broken down and the fistula established. In a few cases the removal of the umbilical polyp has been sufficient to establish a patent vitelline duct.

#### PROLAPSUS OF THE BOWEL.

Inversion of the bowel does not necessarily follow when a patent omphalomesenteric duct exists. This will be clearly seen if the reader refers to Chapter X on Patent Omphalomesenteric Duct (p. 188). In that chapter are recorded a large number of cases in which the bowel manifested no tendency to prolapse.

Several factors are probably necessary to bring about prolapsus: (1) a duct

that is of good caliber throughout, or at least at its intestinal attachment; (2) an excessive amount of abdominal pressure, such as is produced by crying or by the paroxysms of whooping-cough, as was noted in Hüttenbrenner's case, or by the cough of a bronchitis, as was noted in the case recorded by King. Whether a

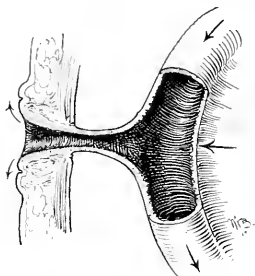


FIG. 131.—PATENT OMPHALOMESENTERIC DUCT OF LARGE DIAMETER

The lumen of this duct is directly continuous with that of the small bowel, and at the umbilicus its intestinal lining extends out a short distance upon the surface of the umbilicus. When the lumen of the omphalomesenteric duct is wide, there is always great danger of the bowel prolapsing and turning inside out through the duct, following the direction indicated by the arrows. For the subsequent stages of such a prolapsus see Figs. 132, 133, 134, and 135.

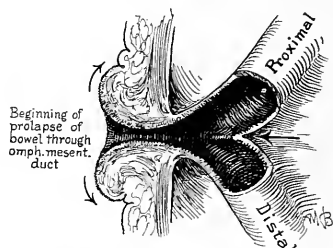


FIG. 132.—COMMENCING PROLAPSUS OF SMALL BOWEL THROUGH PATENT OMPHALOMESENTERIC DUCT.

The lumen of the duct is large, and the small bowel, on its mesenteric side, is forming a wedge, as indicated by the arrow. This wedge will gradually pass out through the duct, as shown in Figs. 133, 134, and 135.

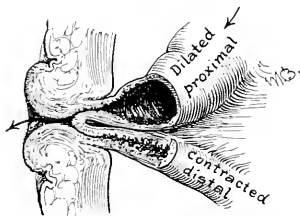


FIG. 133.—PARTIAL PROLAPSUS OF THE SMALL BOWEL THROUGH THE OMPHALOMESENTERIC DUCT.

The wedge of small bowel has extended partly through the abdominal wall. The loop is now divided into two definite portions, the dilated and proximal, and the contracted and distal portion. The proximal portion is naturally dilated, because there is already a barrier to the adequate escape of the fecal contents. The distal portion is, of course, contracted, because nothing is passing into it. For the subsequent steps of the prolapsus see Figs. 134 and 135.

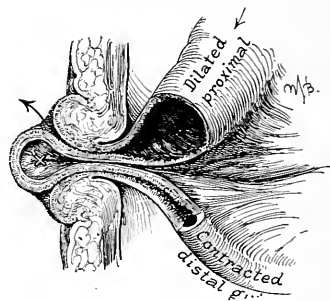


FIG. 134.—PROLAPSUS OF THE SMALL BOWEL THROUGH THE PATENT OMPHALOMESENTERIC DUCT.

The small bowel has prolapsed still farther through the omphalomesenteric duct. The proximal loop has become more distended, and the distal loop has become contracted still more. The lumina of both loops can be traced out to the surface of the abdomen. The mucosa of the bowel has now extended out so far that it forms a definite, roundish projection, elevated above the surface of the abdomen, and naturally covered over with intestinal mucosa, because it is the inner surface of the small bowel. Between the proximal and distal contracted loops of bowel the peritoneum is carried outward beyond the level of the abdomen, as indicated by *x*. At this stage only a small amount of fecal matter can escape from the umbilicus, and signs of obstruction will soon develop. For complete prolapsus see Fig. 135.

weakly and emaciated child is more prone to the prolapsus is problematic, as some of the patients were strong, others very frail.

Just prior to the prolapsus some of the children have had stoppage of the bowel for several days. In other cases the first intimation of alarming trouble was the presence of the inverted bowel on the abdomen. A careful study of Figs. 131, 132, 133, 134, 135, and 136 will clearly show the reader the various stages in the

development of the prolapsus of the bowel through the patent omphalomesenteric duct.

A glance at Fig. 137, p. 227, Fig. 138, p. 228, Fig. 140, p. 230, and Fig. 141, p. 232, will give a very good idea of the prolapsed bowel. Lying on the surface of the abdomen is a red or dark-red, sausage-like mass. This may lie transversely on the abdomen; it may be S-shaped, or appear as two horns forming a semicircle, as in Théremin's Case 1. The mass varies in length from a few inches to one and a half feet, as noted in Violbing's case. As the tumor is nothing more than a portion of the small bowel that has turned inside out through the fistula, its surface consists of intestinal mucosa. At each end is an opening; these represent the upper and

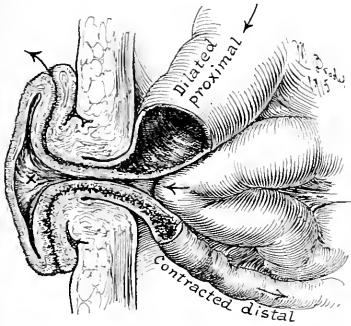


FIG. 135.—COMPLETE PROLAPSUS OF THE BOWEL THROUGH THE PATENT OMPHALOMESENTERIC DUCT.

For the early stages of the prolapsus see Figs. 131, 132, 133, and 134. The proximal loop of bowel is now markedly distended, and the distal loop is correspondingly small. Lying on the surface of the abdomen is a sausage-shaped mass. This is naturally reddish or dark red in color, because it is covered over with the mucosa of the small bowel. It has an upper opening corresponding to the lumen of the proximal loop of small bowel, and a lower opening—the lumen of the distal loop of bowel. A loop of small bowel is trying to pass outward in the chink between the proximal and distal loops, as indicated by the arrow. That this can take place is shown in Fig. 136.

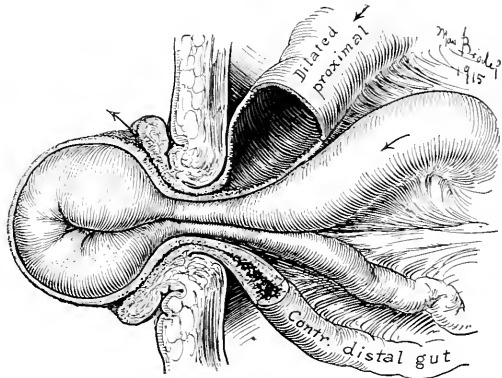


FIG. 136.—PROLAPSUS OF THE SMALL BOWEL THROUGH THE PATENT OMPHALOMESENTERIC DUCT, AND AN UMBILICAL HERNIA BETWEEN THE LOOPS OF PROLAPSED BOWEL.

In order that the reader may satisfactorily unravel this picture, he should consult Figs. 131, 132, 133, 134, and especially 135. The loop of small bowel that in Fig. 135 was near the chink between the distal and proximal loops has now succeeded in passing between them and occupies the cavity (x) noted in that picture. The lumina of the distended and contracted loops are visible, and the now enlarged and rounded mass would give a note of tympany. The interloping loop of bowel, as a result of its constriction, now has a distended and contracted portion.

lower ends of the lumen of the bowel. Usually the openings are very small, but in Weinlechner's case they were large enough to admit the tip of the finger. Where the prolapsus is small, the picture reminds one very much of a prolapsus of the rectum or of an intussusception. The tumor is usually elastic to the touch and tends to bleed on manipulation.

If the child lives long enough, the mucosa covering the prolapsed bowel may become necrotic. The children, however, usually soon go into a state of collapse, and die in from a few hours to two or three days. After the prolapsus has developed, nothing but mucus escapes by the rectum. There is in reality complete obstruction of the bowel, as practically nothing can escape through the constricted abdominal tumor.

**RESULTS.**

Some of the children were so ill that no operation could be undertaken. Others were operated upon, the abdomen being opened, the bowel drawn back, and the fistula closed. All these died. In only one case have we any record of a success. This was in King's case, in which no operation was undertaken. The bowel was reduced, and the fistula cauterized. Finally it closed. The child died later, probably of pulmonary tuberculosis.

**FINDINGS AT AUTOPSY.**

In Basevi's case Chiari found a fibrinopurulent exudate at the umbilicus, and a small abscess between intestinal loops.

In Gesenius's case, in which no operation had been performed, the omentum and intestine were adherent near the umbilicus. The intestinal loops were adherent and covered with a reddish exudate.

In Théremin's Case 1, no inflammation existed in the abdomen, but the prolapsed bowel was markedly infiltrated.

The variability in the location of the omphalomesenteric duct was very clearly brought out. In Löwenstein's case it was just above the ileocecal valve; in Gesenius's case the diverticulum was 1 cm. long and 9 inches above the valve; in King's case, 5 inches long and 18 inches above the valve; in Blin's case, 3 to 4 cm. long and 25 cm. above the valve; in Ophüls's case, 35 cm. above the valve, and in Théremin's Case 2, 60 cm. above the ileocecal valve.

**TREATMENT.**

A careful study of these cases clearly demonstrates that when the omphalomesenteric duct is patent, the wisest plan is at once to make an incision encircling the umbilicus, draw out the loop of bowel, and treat the fistulous tract as one would an appendix.

Newly born children are only fair risks, yet, on the other hand, if one waits until prolapsus has occurred, death is almost certain, as the child has so little reserve force.

In those cases in which prolapsus has already occurred the same procedure may be adopted, but in such a case, after the fistula has been closed, a loop of bowel just above the attachment of the diverticulum should be drawn out and opened, even if there be a remote possibility of prolapsus occurring through this enterostomy wound. We are all familiar with cases of strangulated hernia in which the bowel has been obstructed for several days. In these, even if the obstruction is relieved, death is liable to follow from the absorption of products of decomposition that have been accumulating in the bowel. The same principle also applies here, and we must allow free drainage of the bowel contents.

**CASES OF PROLAPSUS OF THE BOWEL THROUGH A PATENT OMPHALOMESENTERIC DUCT.**

Three other cases of prolapsus of the bowel through the vitelline duct, those of Gibb, Guthrie, and Peake, are recorded in Chapter XI.

A Case of Prolapsus of the Small Bowel Through the Patent Omphalomesenteric Duct.—Arndt\* reports the case of a boy sixteen days old. The midwife was struck by the thickness of the umbilical cord at the time of labor. The father said that, shortly before admission, when the child vomited, “pus” escaped in a stream from the umbilical region. The child was poorly nourished, and at the umbilicus was a tumor the size of a walnut, reddish in color, which on manipulation bled slightly. It was apparently covered over with mucosa. On the right and also on the left upper portion of the umbilical projection was an opening, into which a sound could be passed for a long distance. From both openings intestinal contents escaped when pressure was made, or if the child cried. Because of the prolapsus a diagnosis of patent omphalomesenteric duct was made. Three days later there was stool by bowel. Five days after admission two tumors could be seen—one was sausage-shaped, the other round. The former was 9 cm. long (Fig. 137). It doubled in length in four days, became S-shaped, and both ends had openings. The opening in the upper end was about the size of a pea; the lower opening was half as large. Pressure on the child’s abdomen increased the size of the tumor. The second tumor was situated in the upper margin of the umbilical ring. It was solid and as large as a hazelnut.

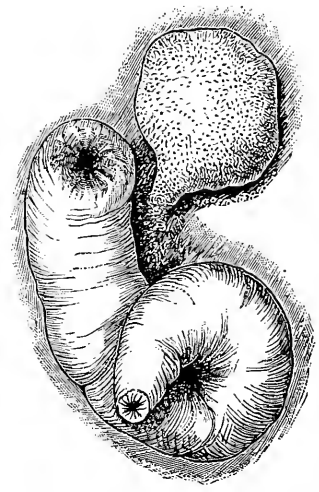


FIG. 137.—PROLAPSE OF THE SMALL BOWEL THROUGH AN OPEN OMPHALOMESENTERIC DUCT. (After Arndt.)

The sausage-like mass was 9 cm. long. It had doubled its length in four days. At both ends were openings. These represented the lumen of the bowel. The smaller, polyp-like mass, seen in the upper part of the picture, was covered with mucosa and attached to the upper part of the umbilical ring. Histologic examination showed that it was covered over with intestinal mucosa. It was a so-called adenoma or umbilical polyp.

At operation Professor Runge found that the tumor with the two openings was an inverted portion of the small bowel that had passed through the patent omphalomesenteric duct. When the bowel was replaced in its normal position, a hollow channel was found passing from the small bowel to the umbilicus. This opening was about the size of a pea. The fistulous tract was removed. The child unfortunately died of peritonitis, as the sutures did not hold properly.

Arndt says: “In this case we have to do with prolapsus of the small bowel through the omphalomesenteric duct.” Microscopic examination of the solid umbilical tumor showed that it was an enteroteratoma (an umbilical polyp).

This case was also reported by Ophüls in his monograph.

Prolapsus of the Small Intestine Through a Patent Omphalomesenteric Duct.—Barth’s† patient was a child, nine days old, who was brought to the clinic on account of a tumor at the umbilicus. The mother said that this tumor was noted immediately after the cord came away: The cord itself did not present anything unusual, so far as the mother or midwife could

\* Arndt, C.: Ein Fall von Dünndarmprolaps durch den offen gebliebenen Ductus omphaloentericus. Arch. f. Gyn., 1896, lii, 71.

† Barth, A.: Ueber die Inversion des offenen Meckel’schen Divertikels und ihre Complication mit Darmprolaps. Deutsche Zeitschr. f. Chir., 1887, xxvi, 193.

tell, but through the opening at the umbilicus fecal matter had been discharging for several days. The bowels in the meantime had moved regularly, and the urination was normal.

The child was a well-formed boy, and apart from the umbilical trouble was apparently normal. At the umbilicus was a tumor about 1 cm. long. This was of a blood-red color, and was covered with injected mucosa. On its surface was an opening. The tumor was 1.5 cm. in breadth and firmly fixed at the umbilicus. A sound could be passed into the canal without difficulty for 4 cm. There was no change noted in the tumor when the child cried. Barth, having seen a similar case in Danzig, came to the conclusion that this was an inversion and prolapsus through a patent Meckel's diverticulum. The small tumor was covered with iodoform gauze, a compression band was applied, and the child was brought to the polyclinic daily. For the next few days there was no change. The child digested well, and there was very little discharge from the umbilicus.

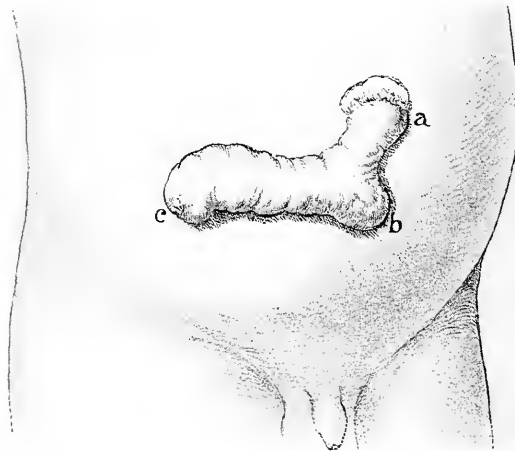

FIG. 138.—PROLAPSUS OF THE BOWEL THROUGH A PATENT OMPHALOMESENTERIC DUCT. (After Barth's Fig. 1. Redrawn by August Horn.)

*a* is the point at which the bowel has prolapsed and turned inside out through the umbilicus; *c* and *b* are the points at which probes could be introduced into the bowel lumen.

Five days later Barth was surprised to see that the small tumor had been transformed into a reddish, sausage-like tumor, as shown in Fig. 138. At the umbilical ring there was now a tumor 2.5 cm. long and 1.75 cm. thick. This was continuous with the sausage-shaped cylindrical tumor *b-c*, which was 7 cm. long and varied from 1 to 1.5 cm. in thickness. The entire tumor, pedicle, and sausage-like mass were dark red and covered over with a slightly hemorrhagic mucosa. At *b* and *c* the mucosa was continuous in the openings. The opening (*b*) led through a canal into the pedicle (*a*), and through the umbilical ring into the abdominal cavity. From the opening (*b*) fecal matter escaped. The opening (*c*) led into a canal toward (*b*), but nothing came out of it. When a sound was introduced, a wall could be made out between the two openings.

From this description it is seen that there was a prolapsus of the inverted intestine. The child was at once brought to the hospital. His general condition was good. There was no pain, and the child's digestion was good. From the open-



ing yellowish fecal matter escaped. From the rectum nothing but mucus came. Dr. Schmid, who saw the patient, thought of reducing the prolapsus. Just as soon, however, as this was attempted, the child commenced to cry and more loops of the intestine came out at the umbilicus. These were seen to be covered with peritoneum. Other loops now presented themselves (Fig. 139).

Operation.—One of the intestinal loops passed directly into the prolapsed and inverted bowel. When traction was made on it, it could be drawn back. The intestine was supported only by a small pedicle. This was cut and the bowel was reduced. When reduction had been effected, the intestine showed an oval opening 1.5 cm. long. One of the assistants who was holding the intestine tore it, and fecal matter came out. The wound was at once closed with catgut. The diverticulum was removed, and the intestine closed. The child died on the third day after operation. The autopsy showed a small abscess in the upper portion of the abdominal wall and a circumscribed adhesive peritonitis. A short convolution of small intestine had become attached to the abdominal wall.

**Prolapsus of the Bowel Through a Patent Omphalomesenteric Duct.\***—A well-nourished child, twelve days old, came under observation on account of non-healing of the umbilicus. At the umbilicus was a reddish, moist wound. The surrounding tissue was normal. In this case the cord was thicker than usual and had come away on the tenth day. On the nineteenth day, when the child cried, a reddish cone, 4 cm. high, appeared. This showed no opening, and there was stool by the bowel daily. A few nights later the child suffered from discomfort; the tumor increased in size, gradually became necrotic, and the child died. In this case there were prolapsus and inversion of the small bowel through a patent omphalomesenteric duct (Fig. 140).

On opening the abdomen Dr. Chiari, who made the autopsy, found the small bowel attached to the umbilicus by a fibrinopurulent exudate, and there was an abscess the size of a walnut between intestinal loops.

**Prolapsus of the Bowel Through a Patent Omphalomesenteric Duct.†**—A child six months old was brought to the Hôtel

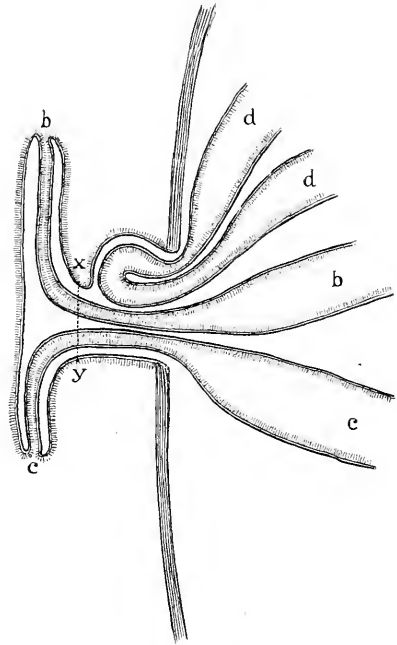


FIG. 139.—PROLAPSUS OF THE BOWEL THROUGH A PATENT OMPHALOMESENTERIC DUCT, WITH SECONDARY COMPLICATIONS. (After Barth's Fig. 3. Redrawn by August Horn.)

This illustration by Barth is a diagrammatic representation of a hernial protrusion that may be associated with the prolapsed omphalomesenteric duct. *b* is a proximal portion of the bowel that has prolapsed; *c*, the distal portion of the loop. The portion lying on the abdomen has turned inside out, and is naturally covered with mucosa. A probe can be readily introduced into the extra-abdominal portion, either from above or from below. At *x-y* the bowel has been markedly constricted by the abdominal wall. The loop of bowel (*d*) has prolapsed to a certain extent through a small hernial opening above the omphalomesenteric duct.

\* Basevi, Settimio: *Jahrb. f. Kinderheilk. u. physische Erziehung*, 1878, xii, 275.

† Blin: *Diverticulum de l'intestin iléum chez un enfant de 6 mois; anus contre nature à l'ombilic, issue d'une anse intestinale par l'orifice ombilical; étranglement; débridement; mort; autopsie.* *Mém. de la Soc. de biol., Paris*, 1853, 1. sér., iv, 131.

Dieu (Jobert's clinic). At the umbilicus was a cylindric tumor lying transversely on the abdomen. This tumor was reddish brown and was evidently an intestinal loop. Below this were two small elevations, the size of peas. These were not so red as the large tumor; they were resistant on pressure and adherent to the skin.

The mother said that these two small nodules had been noticed since the cord came away, and that below one of the small nodules was a minute opening from which a little fecal matter escaped at first, but later only mucus. Suddenly, on the day of admission, during straining, the tumor noted escaped from the abdomen.

Reduction was impossible. An incision was made in the ring, but the child died in two days.

At autopsy a diverticulum, 3 to 4 cm. long and of the diameter of a penholder, was found. This was 25 cm. above the cecum.

**Inversion of the Small Bowel Through a Patent Omphalomesenteric Duct.\***—The patient was a well-nourished boy. The umbilical cord near the abdomen was thicker than usual, and on pressure a rumbling, crackling sound was heard. The abdominal wall below the cord presented a furrow, as if the muscles had not come together properly. The cord was tied about four inches from the umbilicus, and came away on the ninth day; the umbilicus then appeared to be normal. On separation of the folds, however, a small, red, fleshy wart, resembling an umbilical polyp, was seen. On the following day, instead of the elevation, there was an opening with reddish walls, and two days later, after the



FIG. 140.—PROLAPSUS AND INVERSION OF THE INTESTINE THROUGH A PATENT OMPHALOMESENTERIC DUCT. (After Basevi.)

A square piece of the anterior abdominal wall, with the umbilical ring in its middle, has been removed. Above and to the left is the cecum, with the valve-like opening passing into the small bowel. On the right is the ileum. The bowel has become inverted through the patent omphalomesenteric duct, forming a somewhat sausage-like mass on the surface of the abdomen. At either end is an intestinal opening. The one on the left shows up clearly.

child had cried a good deal, a projection the size of a raspberry was noted. This had at its summit an opening which admitted a catheter for from six to seven inches. From this opening a little yellow fluid escaped. The child took the breast well. The urine passed normally, and the stools were regular. About eight days later the child was brought back, but the condition was greatly changed. It was very fretful, and cried continuously. For three days it had had no stool. At the umbilicus was a brownish-red, glistening tumor, which was distended like a sausage. It was three inches long, with blunt ends, and attached to the umbilicus by a sort of pedicle. Its covering was undoubtedly intestinal mucosa, and at either end was an opening into which a sound could be introduced for nearly an inch.

\* Gesenius: Inversion des Dünndarmes durch ein am Nabel offen gebliebenes Divertikel. Jour. f. Kinderkrankh., 1858, xxx, 56.

Around the so-called pedicle was a reddish ring, firmly fixed and preventing the introduction of a sound at this point. There was evidently a diverticulum with an inversion through it.

The child became more restless, collapsed, and died after forty-eight hours. At autopsy, after the omentum and intestine near the umbilicus had been loosened up, the intestine could be pulled back and there remained a diverticulum, 1 cm. long, 9 inches above the cecum. The intestines around it were stuck together by a reddish exudate. In this case there was a patent omphalomesenteric duct, through which the intestine had prolapsed.

**Prolapsus of the Bowel Through a Patent Omphalomesenteric Duct.\***—This child was six weeks old. At the umbilicus was an elongated cylindric tumor, tense and reddish purple in color. It was 12 cm. in length, soft and elastic. In this case, when the cord came away, a fecal fistula existed at the umbilicus. There was an inversion of the intestine through the fistula, like an inversion of the uterus or prolapsus of the bowel through the anus.

**Operation.**—The bowel was reduced and the fistula closed, but the child died ten hours after operation.

**A Case of Intussusception Through a Patent Meckel's Diverticulum.†**—A male infant, four weeks old, when seen, was almost in collapse. When the cord had separated four days after birth, the stools had begun to pass through the navel. During all this time there was a red lump or projection at the umbilicus, and it was through the end of this that the discharge took place. Twenty-four hours before admission a more pronounced protrusion was observed, and the bowels ceased to move by the rectum, discharging only at the umbilicus, and not through the apex of the projection, but at its base, where it seemed to emerge from the original swelling.

The tumor was elongated and about the size and length of a little finger. It depended from the umbilicus, and was inclined toward the left groin. It was covered with bleeding mucosa. It was firm, and looked like an intussusception. Around its base was a rolled collar or cuff of mucous membrane, out of which emerged the protrusion described. The protrusion was separated from the collar by a sulcus, from one part of which yellow fecal matter exuded. A probe inserted into the apical opening passed in three inches and met with an obstruction. A probe, inserted into the basal groove, whence yellow fecal contents were coming out, passed without obstruction for several inches. There was in this case a prolapsus or intussusception of some of the small bowel through a patent omphalomesenteric duct. The child was too ill for operation and died.

**Prolapse of the Bowel Through an Originally Partially Patent Omphalomesenteric Duct.‡**—A boy, four months old, had a penis-like tumor at the umbilicus. This projection was not present at the time of his birth. It was covered over with mucosa, sharply differentiated from the umbilical skin, and at its end was a canal, into which a sound

\* Gevaert, G.: *Inversion intestinale à travers l'ombilic*. Chirurgie infantile, Charon et Gevaert, deuxième édition, Bruxelles, 1895, 251.

† Golding-Bird, C. H.: *Clin. Soc. Trans.*, London, 1896, xxix, 32.

‡ Helweg, Kr.: *Aabent Diverticulum ilei, Invagination, Prolaps, Inkarcération*. Hosp. Tidende, 1884, ii, 705.

could be introduced for one inch beyond the abdominal wall; nothing escaped from the opening. The stools were normal.

The tumor, which was hard at its base, was tied off with a silk ligature. It became necrotic in four days. As a result of violent coughing, prolapse of an S-shaped piece of intestine with a dark-red mucous lining took place (Fig. 141). It was attached to the umbilicus by a short pedicle. The portion of intestine

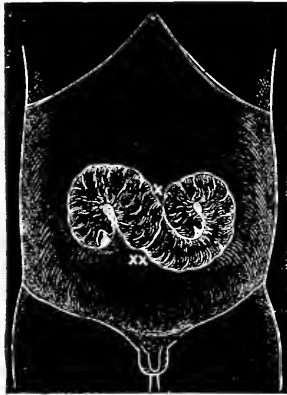


FIG. 141.—PROLAPSE OF THE BOWEL THROUGH THE PATENT OMPHALOMESENTERIC DUCT. (After Helweg.)

A boy, four months old, had a definite projection at the umbilicus. This was covered over with mucosa and was sharply differentiated from the abdominal skin. A sound could be passed for a certain distance into the abdomen. The tumor was tied off at its base with a silk ligature. It became necrotic in four days.

As a result of violent coughing an S-shaped piece of intestine with a dark-red mucosa escaped through the umbilical opening. It was attached to the umbilicus by a short pedicle. At each end was a canal. After the tumor had been loosened at the umbilicus, it was found that two pieces of small bowel had passed out of the umbilical ring and terminated in each horn of the prolapsus. In other words, the bowel had turned inside out through the patent omphalomesenteric duct. The child died a few hours after operation.

the child did well for several days, but the bowel came out again and death occurred. In this case, until prolapse of the bowel took place, the feces passed by the rectum.

[The history of the case leaves no doubt that a patent omphalomesenteric duct existed and that the nurse was in no way responsible for the injury.]

\* Holmes, T.: *Surgical Treatment of the Diseases of Infancy and Childhood*, London, 1868, 182.

lying on the abdomen was eight to nine inches long, and as thick as the small intestine of an adult. At both free ends was a canal. After loosening up the tumor at the umbilicus the operator found that two pieces of small bowel had passed out of the umbilical ring into the horns of the prolapsus. After making traction on the intestine he was able to draw back both horns, but there remained an opening in the bowel the size of a mark. This communicated with the umbilicus and was the patent omphalomesenteric duct. The bowel was closed. The child died a few hours later.

At autopsy a beginning peritonitis was found around the umbilical region. The omphalomesenteric duct was 18 inches above the ileocecal valve.

**Prolapse of the Bowel Through a Patent Omphalomesenteric Duct.**—Holmes\* described a specimen that had been sent to him by Dr. H. Whiteman. It was from a male infant which had been born prematurely with a bifurcated cord. The bifurcation began three inches from the abdomen. The cord was tied below it. At the end of two weeks feces were coming from the umbilicus, and the surrounding tissues were inflamed. The intestine rolled out, and, when Holmes saw the patient, a loop was hanging out of the abdomen and feces were coming from it. There was evidently some defect in the closure of the umbilical opening, probably due to a fissured cord, and Holmes thought that the nurse had probably retied the cord after Dr. Whiteman had tied it well away from the abdomen, and that she had tied off the end of the bowel. Attempts were made to push the bowel back in order to use Dupuytren's clamp method. The

**Prolapsus of the Small Bowel Through a Patent Omphalomesenteric Duct.\***—A boy, twelve days old, was supposed to have a persistence of Meckel's diverticulum. The midwife had tied off the cord well away from the body. When Hue saw the child, there was a sausage-like projection, about the size of an adult's thumb, and about 10 cm. long, lying on the abdomen. It was evidently covered with mucosa, and bore some resemblance to a prolapsed rectum in a child. It was deep red in color, livid, and had two orifices on its surface. The first was situated near the middle of the tumor, and from it gas and partly digested intestinal contents escaped. The second was situated at the end of the tumor, and from this neither gas nor feces came.

For the first three days stools were passed by the rectum. After that nothing escaped by the normal route. An enema of water and milk returned without escaping through either of the abdominal openings.

At autopsy it looked as if there had been a prolapse of Meckel's diverticulum. There was a persistence of the left omphalomesenteric artery. Dévé, in the discussion of Hue's case, reported a case in which this also had persisted.

**Prolapsus of the Bowel Through a Patent Omphalomesenteric Duct.**—Hüttenbrenner† saw a child who, as a result of an attack of whooping-cough in the fifth month, had a prolapse of nine inches of bowel from the umbilicus. The prolapsed portion lay as a transverse tumor on the abdomen, and on each side had an opening. The condition was diagnosed as an invagination of the bowel through a patent omphalomesenteric duct. After removal of the prolapsus death followed as result of pneumonia.

**A Patent Omphalomesenteric Duct with Prolapse of the Intestine Through it.‡**—A male child was seen on the eighth day. Occupying the umbilicus was a fungoid growth supposed to have been caused by the nurse pulling on the cord and cutting it off too short. The fungus was removed by means of caustics. When it came away, feces escaped. The child was greatly emaciated; it developed a bronchitis, and a piece of bowel four inches long protruded through the umbilicus. During a fit of coughing feces were seen escaping from its open extremity. At the same time feces passed by the bowel. The wound was closed by cicatrization in about a year, but the child died a little later on, probably of tuberculosis.

**Autopsy.**—The diverticulum, which was five inches long, was found 18 inches above the cecum, and extended from the convexity of the ileum to the umbilicus, to which it was firmly attached. The umbilicus itself appeared to be fairly normal. There was in its center an area of granulation the size of a pea.

**A Patent Omphalomesenteric Duct with Prolapse of the Bowel Through it.§**—The patient was a boy who had at the umbilicus a reddish tumor the size of a strawberry. This was thought to be telangiectatic, and was accordingly tied off and removed. Kölbing saw the child when nineteen weeks old. Projecting through the umbilicus was a piece of red and distended intestine. The child was operated on at once, but died in thirteen hours. The

\* Hue, François: Prolapsus ombilical diverticulaire. *La Normandie méd.*, 1906, xxi, 162.

† Hüttenbrenner, A.: *Allgem. Wien. med. Zeitung*, 1878, Nr. 23, 225, 235.

‡ King, T. W.: *Guy's Hospital Reports*, 1843, 2. sér., i, 467.

§ Kölbing, A.: Beschreibung einer auf dem Nabel eines neugeborenen Kindes befindlichen röthlichen Geschwulst, besonders wegen ihrer Folgen merkwürdig. *Neue Zeitschr. f. Geburtsk.*, 1843, xiv, 443.

small intestine had grown to the lower end of the umbilical opening, and through the opening the intestine had inverted.

[Tillmanns said the case was one of prolapsus in the usual sense, namely, through inversion of the bowel.]

*Prolapsus of the Bowel Through a Patent Omphalomesenteric Duct.\**—A personal communication from Karewski. The patient was a three-months-old boy who was in good health. On the fourteenth day there was "inflammation" of the umbilicus, and a spontaneous opening appeared from which a thin yellow fluid escaped. Dermatitis developed, and on the surface of the prominence of the umbilicus a pea-sized opening was seen. This was lined with a very red mucosa, and from it there escaped a feces-like discharge. Operation was refused. In consequence of ulceration the opening soon became the size of a 50-pfennig piece, and the child grew very weak. In three weeks the opening had increased to the size of a plum. The child cried a good deal and had stoppage of the bowels for several days. Strong pressure was applied to the umbilicus. Finally a prolapsus took place at the umbilicus, and a small piece of bowel, 5 cm. long, came down through the open omphalomesenteric duct. An abdominal incision was made, and the prolapsus was easily reduced. The open omphalomesenteric duct was situated just above the ileocecal valve. It was tied off and removed. The child, however, died twenty-four hours later.

At the present time in such a case an immediate laparotomy would be indicated; the diverticulum should be tied off, the umbilicus removed, and probably a temporary enterostomy made.

*Prolapsus of the Bowel Through an Open Omphalomesenteric Duct.*—Ophüls † gives the autopsy report on a three-weeks-old boy. The clinical diagnosis was peritonitis following a laparotomy. This operation had been performed on account of prolapsus of the bowel through an open Meckel's diverticulum, 10 to 15 cm. of the bowel having prolapsed. In this case the bowel had been reduced and the diverticulum removed. In the vicinity of the umbilical fistula was a small tumor the size of a hazelnut. It was roundish and firm in consistence, and covered over with mucosa. It was entirely independent of the bowel.

Autopsy showed that the intestinal suture had not held, and that fecal matter had escaped into the general abdominal cavity. The closure in the bowel was found to be 35 cm. above the ileocecal valve, and on the side opposite the mesentery.

*Prolapsus of the Bowel Through a Patent Omphalomesenteric Duct. ‡*—A recently born child showed moisture at the umbilicus, which was found to be unusually prominent and firm. There was a groove in the middle where cicatrization had not occurred. Here there was still moisture, and yellow fluid and gas-bubbles escaped. Siebold thought the condition was due to lack of closure of the vitelline duct. At the end of the third week a small, black, gangrenous area was noted. When the child cried, the small bowel was forced out

\* Löwenstein, L.: Der Darmprolaps bei Persistenz des Ductus omphalo-mesentericus mit Mittheilung eines operativ geheilten Falles. *Langenbeck's Arch. f. klin. Chir.*, 1894-95, xlix, 541.

† Ophüls, W.: Beiträge zur Kenntnis der Divertikel-Bildungen am Darmkanal. *Inaug. Diss.*, Göttingen, 1895, 36.

‡ Siebold, quoted by G. Schröder: Über die Divertikel-Bildungen am Darm-Kanale. *Inaug. Diss.* (Erlangen), Augsburg, 1854.

from right to left from the gangrenous opening, forming two horns, like sausage-skins filled with air; and when the child cried, both ends lengthened. A small opening was made at the umbilicus, and the intestine reduced. The child died in a few hours. Autopsy revealed a diverticulum three-quarters of an inch in length, which had opened at the umbilicus.

*Prolapsus of the Bowel Through a Patent Omphalomesenteric Duct.\**—The patient was a well-developed boy. At birth it was noted that the umbilical cord was remarkably large at its base. It came away on the eleventh day. In the center of the cutaneous umbilical ring was a reddish tumor, conic in form, and resembling a fungus of the umbilicus. There were small ulcers on the surface of the tumor, and on the twenty-third day superficial hemorrhage occurred. The small intestine prolapsed through a fistula in the form of two horns, each 5 to 6 cm. in length, which were curved, forming a semi-circle. They were covered over with mucous membrane. Attempts at reduction were made, without result. Two days later the child died.

The autopsy showed a true diverticulum of the small intestine adherent to the umbilical ring, and a prolapse of the bowel through it. There was no trace of inflammation of the peritoneum or of the intestine that had remained in the abdomen, but there was marked infiltration of the prolapsed portion of the bowel.

*Prolapsus of the Bowel Through a Patent Omphalomesenteric Duct.†*—A boy was born on February 26, 1884, and admitted to the hospital on February 29th. The cord came away on the eighth day, and at the umbilical orifice was a small tumor which resembled a fungus. This was conic, red, and measured 1.5 cm. x 1 cm. At its base there was no vestige of an opening. By March 16th, twelve days after the cord had come away, the fungus had receded somewhat and was not over 5 mm. high, but there was a small ulcer in its center, from which a few drops of clear blood escaped. On the following day, while the bandage was being changed, the child cried, and there emerged from the summit of the tumor a mass resembling granulation. This was covered with mucosa and had a small central opening. On March 21st there was an intestinal prolapsus for a length of 10 cm. The mucosa was red and a yellow mucus escaped from the central opening. Gas and fecal matter also came away when the child cried. The general condition was not satisfactory, and it was impossible to reduce the prolapsus. Later the prolapsus receded in part, leaving a prominence measuring only 5 mm. The child died of gastro-intestinal catarrh on April 29th.

At autopsy there were signs of an acute enteritis with engorgement. The mesenteric glands were tumefied, reddish, and softened. The intestinal prolapsus had been reduced completely. The diverticulum was 60 cm. above the cecum. It was inserted into the umbilical ring. The mucosa reached the umbilical opening. There was atelectasis in the posterior part of both lungs.

*Prolapse of the Bowel Through a Patent Omphalomesenteric Duct.‡*—The patient was a well-formed boy. After the dropping off of the umbilical cord a small, rather prominent, tumor, resembling a wild strawberry, was noted at the umbilicus. The physician raised it and tied it

\* Théremin, E.: Sur les fistules entéro-ombilicales diverticulaires. Rev. mens. d. mal. de l'enfance, 1885, 558.

† Théremin: Loc. cit., Case 2.

‡ Violbing: (Quoted by Bureau, op. cit.).

off at its base. When the child was nineteen weeks old there occurred a prolapsus of the intestine  $1\frac{1}{2}$  feet in length through the umbilicus. It came out as two cornua; these were covered with mucosa. Death soon followed. At autopsy a diverticulum was found opening into the bowel.

**Prolapse of Intestine Through a Patent Omphalomesenteric Duct.\*** — J. G., five months old, was admitted to the hospital on March 23, 1873. The umbilicus had been open since birth, and occasionally mucus had escaped, but no feces. During a severe coughing spell the day before his admission a bright-red, two-horned tumor had appeared at the umbilicus. The left horn was 4 cm. long, the right 11 cm. long, with several furrows on its concave side. At the end of each horn was an opening which admitted the tip of a finger. No feces escaped from these openings. The prolapsed tumor was constricted at the umbilicus.

The tumor was dark red, and undoubtedly covered with mucosa. The surface was covered with mucus and bled readily.

The abdomen was markedly distended; the child was very pale and breathed with difficulty. There was no vomiting.

The growth was cut off, a short stump and two lumina being left. The child died thirty hours later.

\* Weinlechner: Vorfalldes Dünndarms durch den offen gebliebenen Ductus omphalomesaraiicus. *Jahr. f. Kinderheilk. u. physische Erziehung*, N. F., 1874-75, viii, 55.

#### LITERATURE CONSULTED ON PROLAPSUS OF THE BOWEL THROUGH A PATENT OMPHALOMESENTERIC DUCT.

- Arndt, C.: Ein Fall von Dünndarmprolaps durch den offen gebliebenen Ductus omphalentericus. *Arch. f. Gyn.*, 1896, lii, 71.
- Barth, A.: Ueber die Inversion des offenen Meckel'schen Divertikels und ihre Complication mit Darmprolaps. *Deutsche Zeitschr. f. Chir.*, 1887, xxvi, 193.
- Basevi, Settimio: *Jahr. f. Kinderheilk. u. physische Erziehung*, 1878, xii, 275.
- Blin: Diverticulum de l'intestin ileum chez un enfant de 6 mois; anus contre nature à l'ombilic, issue d'une anse intestinale par l'orifice ombilical; étranglement; débridement; mort; autopsie. *Mém. de la Soc. de biol., Paris*, 1853, 1. sér., iv, 131.
- Bureau, J.: Prolapsus ombilical du diverticule de Meckel. *Thèse de Paris*, 1898, No. 257.
- Gesenius: Inversion des Dünndarmes durch ein am Nabel offen gebliebenes Divertikel. *Jour. f. Kinderkrankh.*, 1858, xxx, 56.
- Gevaert, G.: Inversion intestinale à travers l'ombilic. *Chirurgie infantile*. Charon et Gevaert, deuxième édition, Bruxelles, 1895, 251.
- Golding-Bird, C. H.: A Case of Intussusception through a Patent Meckel's Diverticulum. *Clin. Soc. Trans.*, London, 1896, xxix, 32.
- Helweg: Aabent Diverticulum ilei. Invagination, Prolaps, Inkarcération. *Hosp. Tidende*, 1884, ii, 705.
- Holmes, T.: *Surgical Treatment of the Diseases of Infancy and Childhood*, London, 1868, 182.
- Hue, François: Prolapsus ombilical diverticulaire. *La Normandie méd.*, 1903, xxi, 162.
- Hüttenbrenner, A.: *Allgem. Wiener med. Zeitung*, 1878, xxiii, 225, 235.
- King, T. W.: Feculent Discharge at the Umbilicus From Communication with the Diverticulum Ilei. *Guy's Hospital Reports*, 1843, 2. sér., i, 467.
- Kölbng, A.: Beschreibung einer auf dem Nabel eines neugeborenen Kindes befindlichen röthlichen Geschwulst, besonders wegen ihrer Folgen merkwürdig. *Neue Zeitschr. f. Geburtsk.*, 1843, xiv, 443.
- Löwenstein: Der Darmprolaps bei Persistenz des Ductus omphalomesentericus, mit Mittheilung eines operativ geheilten Falles. *Langenbeck's Arch. f. klin. Chir.*, 1894-95, xlix, 541.



- Ophüls, W.: Beiträge zur Kenntnis der Divertikelbildungen am Darmkanal. Inaug. Diss., Göttingen, 1895, S. 36.
- Siebold: (Quoted by G. Schröder, Über die Divertikel-Bildungen am Darm-Kanale. Inaug. Diss. (Erlangen), Augsburg, 1854.)
- Théremin: Sur les fistules entéro-ombilicales diverticulaires. Rev. mens. mal. de l'enfance, 1885, 558.
- Violbing: (Described in Bureau's article, Op. cit.)
- Weinlechner: Vorfall des Dünndarms durch den offen gebliebenen Ductus omphalo-mesaraicus. Jahrb. f. Kinderheilk. u. physische Erziehung, N. F., 1874-75, viii, 55.

## CHAPTER XIII.

### CYSTS IN THE ABDOMINAL WALL DUE TO REMNANTS OF THE OMPHALOMESENTERIC DUCT.

Historic sketch.

Cysts developing between the peritoneum and muscles.

Subcutaneous cysts.

Report of cases.

Wyss and Colmers have each reported a case in which a small cyst was found lying between the peritoneum and the abdominal muscles. Zumwinkel observed a cyst lying external to the abdominal muscle.

Wyss's cyst was the size of a bean; Colmers' was as large as a hen's egg and divided into two cavities; Zumwinkel's was the size of a cherry-stone.

As will be noted from the histories, in each case the inner surface of the cyst at some point was lined with cylindric epithelium, and in Colmers' and Zumwinkel's

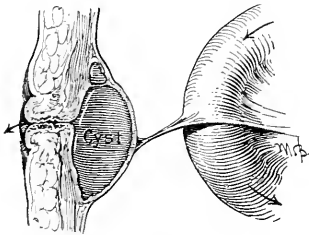


FIG. 142.—A SMALL CYST OF THE UMBILICUS DUE TO A REMNANT OF THE OMPHALOMESENTERIC DUCT.

This is a schematic representation of a small cystic remnant of the omphalomesenteric duct lying just external to the peritoneum and communicating with the umbilicus. Passing from it to the bowel is a fibrous remnant of an omphalomesenteric vessel.

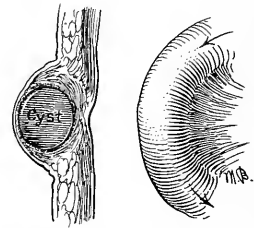


FIG. 143.—SMALL CYST OF THE ABDOMINAL WALL DUE TO A REMNANT OF THE OMPHALOMESENTERIC DUCT.

In rare instances a small cyst may be found in the abdominal wall in the umbilical region. This cyst is lined with a mucosa resembling to a more or less marked degree intestinal mucosa. This is a schematic representation of such a cyst.

cases Lieberkühn's glands were demonstrable. In these two cases the walls of the cyst also contained non-striped muscle.

In Zumwinkel's case the cyst was connected with the umbilicus by a fine opening, and in Colmers' case the patent omphalomesenteric vessels were still present in the cord passing from the cyst to the umbilicus. These cysts, without a doubt, were due to remnants of the omphalomesenteric duct.

In Figs. 142 and 143 we have schematic representations of cysts developing just externally to the peritoneum and in the umbilicus itself.

A Small Cyst Between the Peritoneum and Muscle, Probably Remains of the Omphalomesenteric Duct.\*—At autopsy, about an inch above the umbilicus and a little to the side of the linea

\* Wyss, Hans v.: Zur Kenntniss der heterologen Flimmercysten. Virchows Arch., 1870, li, 143.

alba, Wyss found a cyst, the size of a bean, between the muscle and peritoneum. This contained turbid and tenacious mucus, which was grayish yellow in color. The cyst was lined with cylindric, ciliated epithelium, an epithelium that had undergone colloid change. Wyss thought the cyst might represent embryonic remains. The findings strongly suggest remains of the omphalomesenteric duct.

**An Enterocystoma Developing Between the Peritoneum and the Recti Muscles.**—Colmers\* considers enterocystoma of the abdominal wall, but before giving his own case, mentions those reported by v. Wyss, Roser, and Schaad.

Colmers, in 1903, saw Frau K. O., aged forty-six. She had always been healthy and was the mother of 12 children. Her illness commenced in the summer of 1903. In August she noticed that every movement of the body excited pain in the abdomen. No further trouble was noted until October, when there were digestive disturbances. When admitted to the hospital (November 17th) the woman was fairly well nourished, but the skin was pale. The abdomen was firm. On careful palpation an indefinite resistance could be felt around the umbilicus. The mass was the size of an egg, firm in consistence, and very movable.

Operation.—When the abdomen was opened, a fluctuating tumor, the size of a small hen's egg, was found in the umbilical region. It was attached to the abdominal peritoneum and partly nipped off from a small one about the size of a hazel-nut. This was also in the abdominal wall. Passing from the tumor to the umbilicus was a short, thick cord. The tumor was dissected out of the abdominal wall without difficulty. The stomach, intestine, and mesentery, as well as the uterus and adnexa, were normal. A somewhat enlarged gland from the greater curvature of the stomach was removed. This, on histologic examination, showed a simple hyperplasia. The extirpated tumor lay between the peritoneum and the sheath of the rectus. With the latter it had formed a broad adhesion.

The tumor contained a thick yellowish fluid, which had colorless masses, resembling mucus, scattered through it. The fluid contained numerous fat-droplets, many cholesterin crystals and fatty acid needles, as well as cells closely resembling fatty epithelium. The walls of the large cyst had on the inner surface numerous calcareous particles. These were attached to the wall or lay free in the cyst cavity. The wall of the portion of the cyst lying beneath the peritoneum was not over 0.2 mm. in thickness, and in places only 0.1 mm. thick. Near it were little bays or depressions running out in various directions. Here the walls reached a thickness of 0.5 mm.

These cysts communicated with each other by a small opening through which a sound could pass. The cord extending from the small cyst to the umbilicus appeared to be solid. The free walls of the cyst, that is, the portion lying beneath the peritoneum, contained connective tissue, in the inner layers of which calcareous deposits were found. No epithelial lining could be detected.

The small cyst was similar to the larger one. Here, however, the calcareous deposit was not marked. At one point at the base of the cyst were two small bays. These communicated with the main cyst by a small opening. The two small cysts, as indicated in Fig. 144, *a*, *b*, were lined with a beautiful, very high cylindric epithelium. This contained definite Lieberkühn's glands, although

\* Colmers, F.: Die Enterokystome und ihre chirurgische Bedeutung. Arch. f. klin. Chir., 1906, lxxix, 132.

these were low and often irregular. Sometimes papillæ were found projecting into the lumen of the cyst. This glandular layer covered a definite muscularis mucosæ in which bands of smooth muscle-fiber were seen. The glands were not regular, but in some places they were arranged at right angles to one another. At a few points there were evidences of Auerbach's plexus.

The cord passing from the small cyst contained the omphalomesenteric vessels. Two of them had remained open and were surrounded by smooth muscle-fibers. The diagnosis was not difficult. The cysts had developed from remains of the omphalomesenteric duct.

**A Subcutaneous Cyst Originating From the Omphalomesenteric Duct.\***—The patient was a child seven years old. Since birth there had been a small opening at the umbilicus, which secreted a slimy fluid. In the right abdominal wall in the umbilical region was a roundish, ulcerated, hard

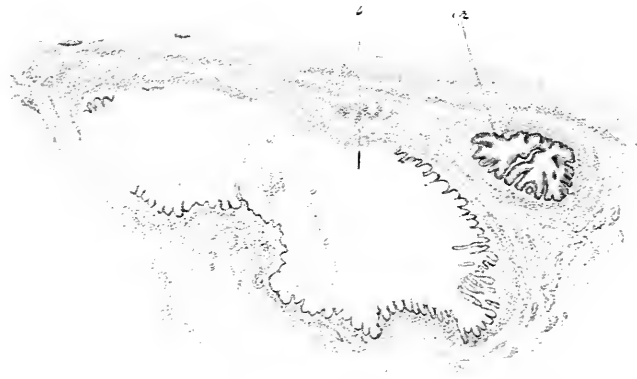


FIG. 144.—A SMALL INTESTINAL CYST LYING BETWEEN THE PERITONEUM AND THE RECTI. (After Colmers.)

This picture represents one of the small bays running off from the large cyst, and communicating with it by a fine opening. At *a* we have Lieberkühn's glands, some with well-developed papillary folds. The cyst space (*b*) in some places is lined with mucosa. At other places the epithelium is somewhat flattened or has disappeared completely. Surrounding the glands is non-striated muscle cut longitudinally and transversely.

nodule, 1.25 cm. in diameter. In the middle was a fine opening through which a sound could be passed 1 cm. into a cavity.

At operation a cyst the size of a cherry-stone was found. This was round, bluish in color, and easily loosened by blunt dissection from the underlying tissue.

The inner surface of the cyst was lined with cylindric epithelium, intestinal folds, and Lieberkühn's glands. Outside of this was a muscular zone. In some places this was cut lengthwise; at others, transversely. It consisted of two layers. The mucosa was not normal. The folds or papillæ were high and broad, and sometimes had several projections, suggesting a papilloma. The glands were more abundant. The muscle was especially thick. At only one point did the sac show normal mucosa.

The squamous epithelium in the vicinity of the cyst was increased in thickness. In some places it was ten times as thick as normal. The papillæ of the skin were also much lengthened.

\* Zumwinkel: Subcutane Dottergangscyste des Nabels. Langenbeck's Arch. f. klin. Chir., 1890, xl, 838.

Zumwinkel says that in Roser's case the cyst lay behind the navel, just extra-peritoneally, whereas his cyst lay in front of the closed navel.

In Zumwinkel's case the skin surrounding the umbilicus was greatly thickened, the squamous epithelium in places being fully ten times as thick as normal.

In a case seen by Fox and MacLeod, and cited on page 268, there was a definite Paget's disease, due undoubtedly to the irritating discharge from skin remnants of the omphalomesenteric duct. Fox and MacLeod's patient was a sailor, sixty-five years of age, who came under the care of Mr. W. Turner, surgeon to the Dreadnought Hospital at Greenwich. In the umbilical region was a rounded, eczematoid patch, two inches in diameter, which had been forming gradually for eleven years.

On microscopic examination the outlying portion of the umbilicus showed the typical picture of Paget's disease. The central portion showed a covering of cylindrical epithelium, and contained glands resembling those of Lieberkühn. In this case there evidently had been remains of the omphalomesenteric duct at the umbilicus, and the continued discharge had set up a proliferation of the squamous epithelium. This case is reported in detail in Chapter XVII.

#### LITERATURE CONSULTED ON CYSTS IN THE ABDOMINAL WALL DUE TO REMNANTS OF THE OMPHALOMESENTERIC DUCT.

- Bondi, J.: Zur Kasuistik der Nabelcysten. *Monatsschr. f. Geb. u. Gyn.*, 1905, xxi, 729.  
 Colmers, F.: Die Enterokystome und ihre chirurgische Bedeutung. *Arch. f. klin. Chir.*, 1906, lxxix, 132.  
 Fox and MacLeod: A Case of Paget's Disease of the Umbilicus. *Brit. Jour. Dermatol.*, 1904, xvi, 41.  
 Wyss, Hans v.: Zur Kenntniss der heterologen Flimmercysten. *Virchows Arch.*, 1870, li, 143.  
 Zumwinkel: Subcutane Dottergangscyste des Nabels. *Langenbeck's Arch. f. klin. Chir.*, 1890, xl, 838.

## CHAPTER XIV.

### PERSISTENCE OF THE OMPHALOMESENTERIC VESSELS.

Historic sketch.

Remnants of the omphalomesenteric vessels at the mesentery.

Omphalomesenteric vessels accompanying Meckel's diverticulum or a patent omphalomesenteric duct.

Persistence of the omphalomesenteric artery in the bases of umbilical polyps.

An omphalomesenteric vessel lying perfectly free in the abdomen.

Fatal obstruction due to remnants of the omphalomesenteric vessels.

IN the earliest stages of the embryo the omphalomesenteric arteries are two in number. They arise from a plexus of from two to four small vessels, coming directly from the aorta, and pass out one on each side of the yolk-sac.

The left artery disappears, the right persists and follows the omphalomesenteric duct, to terminate in a network which covers the entire yolk-sac. The proximal portion of the right omphalomesenteric artery later becomes the superior mesenteric artery.

The omphalomesenteric veins, in the beginning, are two in number. The right disappears, but the left collects the blood from the entire yolk-sac and from the omphalomesenteric duct, and in the liver anastomoses with the left umbilical vein. Before entering the liver it receives tributaries from the intestine—from the superior mesenteric vein (Fig. 7).

A reference to Fig. 6, p. 6, Fig. 7, p. 7, Fig. 8, p. 8, Fig. 10, p. 10, Fig. 11, p. 11, Fig. 12, p. 12, Fig. 13, p. 13, Fig. 14, p. 14, Fig. 15, p. 15, and Fig. 33, p. 32, will serve to give a very clear idea of the origin and course of the omphalomesenteric vessels during the various months of fetal life.

The omphalomesenteric vessels, as a rule, totally disappear, but occasionally persist, sometimes independently, sometimes associated with remnants of the omphalomesenteric duct (Fig. 145). When one realizes that in every human being these structures were at one time present, it is remarkable that remnants of them are not more frequently found.

According to Fitz, Meckel was familiar with remnants of the omphalomesenteric vessels.

An observation made by Ruge in 1877 is of interest. He reports the discovery, in the body of a new-born child, of a cord the thickness of a linen thread for 2 cm., and then of hair-like thinness for 1.5 cm.; it ran between the mesentery of the small bowel and the tissue around the right umbilical artery, just before its entrance into the abdominal wall. Ruge further described the projection of a delicate, thread-like process with a knobbed end, from the mesentery near the intestine, and a short distance above the cecum. He then makes the statement that floating threads with rounded ends may often be found on the mesentery or near the navel, and are derived from the omphalomesenteric vessels or the duct.

Tillmanns, in 1882, said that occasionally remains of the fetal omphalomesenteric

vessels are seen as strings of various forms—threads or canals extending from the inner surface of the umbilicus, not to the point of the diverticulum, but directly to the mesentery. Thus, Schroeder had relatively often observed such pictures in new-born cats, dogs, and rabbits, although he acknowledged that they are more rare in man.

Fitz, writing in 1884, said that the vitelline duct is not only composed of layers of tissue equivalent to those forming the coats of the intestine, but is also accompanied by blood-vessels. These are the omphalomesenteric or vitelline arteries and veins, which course along its surface and ramify over the walls of the umbilical vesicle. Coincidentally with the atrophy of the vitelline duct these vessels also become atrophied and eventually disappear, with the elimination of the former. The progressive shrinkage and eventual disappearance of the vitelline duct, however, do not necessitate the atrophy of these vessels.

In Fig. 21, p. 20, from a human embryo 12 cm. long, is seen a small filament attached at one end to the umbilicus, and at the other end lying perfectly free. It is a remnant of the omphalomesenteric vessels.

Remnants of the Omphalomesenteric Vessels at the Mesentery.—Fitz says that soon after his attention had been drawn to persistence of the omphalomesenteric vessels he examined the body of a man who had died of chronic tuberculosis at the Massachusetts General Hospital. There were two tuft-like projections from the upper surface of the mesentery, each half an inch long and about half an inch apart. They were about two inches distant from the portion of the ileum lying some three feet above the ileocecal valve. The peritoneum covering them was normal in appearance, and the mesentery elsewhere was free from all abnormal changes. The peritoneum in the vicinity of the navel was examined, but with negative results. Fitz says that since then repeated examinations have been made with reference to what might be regarded as vitelline remains, but with indifferent success.

Omphalomesenteric Vessels Accompanying Meckel's Diverticulum or a Patent Omphalomesenteric Duct.—Fig. 25, p. 24, and Fig. 26, p. 24, show very clearly the relation of the omphalomesenteric vessels to Meckel's diverticulum. Fig. 27, p. 24, represents the same vessels passing from their point of origin to the umbilicus, when no trace of the vitelline duct remains.

Fitz says that the existence of the omphalomesenteric vessels, their relation to the omphalomesenteric duct, and their occasional persistence, entire or in part, were well known to Meckel. Their transformation into fibrous cords was likewise familiar to this author. He quotes Meckel\* as saying: "Quite recently I found them in a child of three months, arising, as usual, from the superior mesenteric

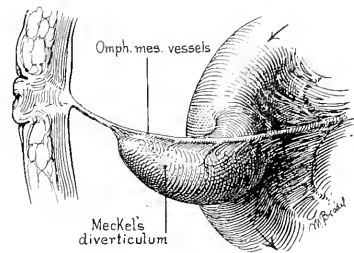


FIG. 145.—AN OMPHALOMESENTERIC DUCT ORIGINATING FROM THE CONCAVE SIDE OF THE BOWEL AND ATTACHED TO THE UMBILICUS BY A FIBROUS CORD. (Schematic.)

This picture illustrates a condition that occasionally exists. The diverticulum, as a rule, springs from the outer or convex surface of the bowel. The origin of the omphalomesenteric vessels from those of the mesentery is clearly seen. Where the omphalomesenteric duct is attached to the umbilicus by a fibrous cord, this usually represents the obliterated portion of one of the omphalomesenteric vessels.

\* Meckel: Arch. f. d. Physiologie, 1809, ix, 439.

artery and vein, running along the entire length of the diverticulum, and converted at its end into a solid thread several inches long and hanging free.”

Hue, when making an autopsy on a child dead of prolapsus of the bowel through a patent omphalomesenteric duct, found a persistence of the omphalomesenteric artery. Duvé, who took part in the discussion on Hue's case, mentioned a case in which the artery also persisted. Stierlin, while removing a patent omphalomesenteric duct, noted that an artery was injured. It was isolated, tied off, and dropped back into the abdomen. It was a patent omphalomesenteric artery.

#### PERSISTENCE OF THE OMPHALOMESENTERIC ARTERY IN THE BASES OF UMBILICAL POLYPS.

Quite frequently, when these small growths are being cut off, a vessel spurts, which is undoubtedly a patent omphalomesenteric artery. In Case 2, recorded by Lannelongue and Frémont, when the polyp was cut off, there was hemorrhage from a small artery. Pestalozza, in 1889, reported a case in which the omphalomesenteric vein in the cord of a child at term was still patent.

#### AN OMPHALOMESENTERIC VESSEL LYING PERFECTLY FREE IN THE ABDOMEN.

One of the most interesting cases of this character was reported by Spangenberg\* in 1819. In the body of a young man, twenty years old, he found what he regarded as an open omphalomesenteric vessel. It could be followed to within half an inch of the navel, where it became a delicate ligament and was lost in the umbilical ring. It descended from the navel between the epigastric veins, on the posterior surface of the peritoneum, to which it was united by fibrous tissue, to nearly midway between the umbilicus and pubes; then, leaving the wall of the abdomen as a thin round cord, it crossed the abdominal cavity between the coils of small intestine, passed beneath the intestines toward the spine, somewhat to the left, and emptied into a bifurcation of the main trunk of the superior mesenteric vein. The vessel was wholly free throughout its entire course, nowhere adhering to the intestine, and was enveloped in a fibrous sheath. It was open to within two inches of the navel, and a small quantity of thin blood from the mesenteric vein was admitted as far as its middle. Its walls for three inches from its origin from the mesentery were collapsed, like those of any other vein, but from this point onward the vessel was of denser structure and very smooth externally. It had no branches, and in texture it resembled in all respects the umbilical vein, which later was found open through half its course. The appearance of the navel as seen from without did not vary from that of other normally formed umbilical depressions.

From the cases just cited it is perfectly clear that one or both of the omphalomesenteric vessels may persist in part or as a whole.

#### FATAL OBSTRUCTION DUE TO REMNANTS OF OMPHALOMESENTERIC VESSELS.

Falk, King, and Mahomed have each recorded a case in which the remnant of an omphalomesenteric vessel appeared to be the cause of intestinal obstruction.

Fitz referred to the case reported by Falk† in 1835. The patient was a man,

\* Spangenberg: *Deutsches Arch. f. d. Physiologie*, 1819, v, 87.

† Falk: *De Ileo e Diverticulis, adiecta Morbi Historia*, 1835, 18.



twenty years of age, who had a diverticulum  $4\frac{1}{2}$  inches long. Two feet above the ileocecal valve a solid, pseudomembranous ligament,  $1\frac{1}{2}$  inches long, ran from its apex to the abdominal wall, an inch from the umbilicus. Uniting the diverticulum and the mesentery was a band, and this apparently had caused an intestinal obstruction. Falk states that diverticula in themselves are not of much importance in producing disturbances of the intestine. But where the umbilical vessels are still adherent and hang off as threads in the abdominal cavity, they may become agglutinated to the organs of the abdomen and thus cause volvulus.

In 1843, King described a case of fatal intestinal obstruction in which an adventitious cord was found passing from the mesentery to Meckel's diverticulum. The patient was a boy fourteen months old. After the cord came away on the eleventh day there was a thin, yellow, slightly odorous discharge from the umbilicus. Poulitices were used for three months, and caustics were applied to destroy the surface. The edges of the fistula were pared and strapped. The opening communicated with a deep sinus into which a probe passed two inches, evidently into the small bowel. About seventeen days later there was an escape of feces.

An ovoid incision was made, and the parts were brought together with pins and plaster. The child was well in a little over two weeks. He died later of intestinal obstruction. At autopsy the diverticulum was found to be three inches long and adherent to the umbilicus. An adventitious cord had apparently compressed the ileum just below its connection with the diverticulum.

Fig. 146 is from another case recorded by King. This patient also died from intestinal obstruction apparently due to a remnant of an omphalomesenteric vessel.

Mahomed's case, published in 1875, leaves absolutely no doubt that the omphalomesenteric artery was responsible for the fatal obstruction.

The patient was a boy eighteen years old who was admitted to the hospital with signs of obstruction, after having eaten a meal of badly cooked potatoes. He died with typical signs of intestinal obstruction eleven days after the illness began.

Autopsy.—A fibrous band was found extending from the middle of the abdominal wall, midway between the pubes and the umbilicus, backward toward the right iliac fossa. It had carried out with it from the abdominal wall a triangular fold of peritoneum. The cord was found passing amid the distended coils of small intestine to the lower part of the ileum, where it formed a noose encircling a loop of ileum 33 inches in length. It had passed one and a half times around the gut at the point of constriction, and was then found to extend to the mesentery of the ileum, about

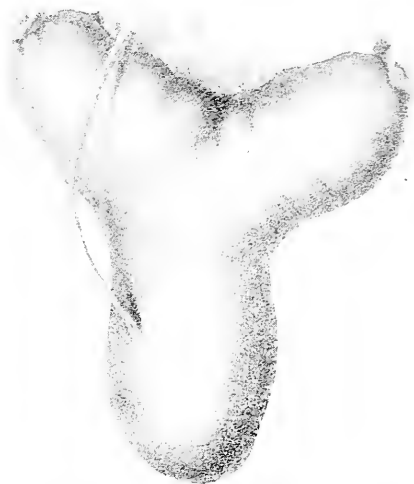

FIG. 146.—A REMNANT OF AN OMPHALOMESENTERIC DUCT CAUSING FATAL INTESTINAL OBSTRUCTION. (After King.)

The figure represents a Meckel's diverticulum attached to the convex surface of a loop of small bowel. An adventitious cord extends from the mesentery over the small bowel to the side of the diverticulum. It represents what remained of one of the omphalomesenteric vessels. It was the cause of fatal intestinal obstruction.

three feet from the ileocecal valve. On being traced between the layers of peritoneum forming the mesentery, the cord was discovered terminating in the large branch of the ileocolic artery.

In its course forward the fibrous cord was found to bifurcate at the apex of the triangular fold of peritoneum, which it had carried out from the abdominal wall. One branch ascended to the umbilicus, accompanying the obliterated hypogastric artery of the right side; the other branch descended toward the bladder and terminated in the left superior vesical artery.

The "committee" were of the opinion that the case was one of persistence of the fetal omphalomesenteric artery, which sends off branches of communication with the left superior vesical or hypogastric artery, the latter having been probably smaller than normal, and having its distribution supplemented by the former.

On page 169 is a very interesting account of a case of fatal intestinal obstruction coming under the care of Sheen. A large quantity of small bowel had passed through a hole in the mesentery of a Meckel's diverticulum, and become strangulated (Fig. 102, p. 170). A note was made that the strength of the constricting cord of mesentery was largely due to the presence of a vessel that crossed it. This, of course, was one of the omphalomesenteric vessels.

From the preceding cases it is clearly evident that remnants of the omphalomesenteric vessels are from time to time found, and that these may lead to fatal intestinal obstruction.

#### LITERATURE CONSULTED ON PERSISTENCE OF THE OMPHALOMESENTERIC VESSELS.

- Fitz, R. H.: Persistent Omphalomesenteric Remains. Their Importance in the Causation of Intestinal Duplication, Cyst-formation, and Obstruction. *Amer. Jour. Med. Sci.*, 1884, lxxxviii, 30.
- Falk, J.: *De Ileo e Diverticulis, adiecta Morbi Historia*, 1835, 18.
- Hue, F.: Prolapsus ombilical diverticulaire. *La Normandie médicale*, 1906, xxi, 162.
- King: Feculent Discharge at the Umbilicus from Communication with the Diverticulum Ilei. *Guy's Hospital Reports*, 1843, 2. series, i, 467.
- Mahomed, F. A.: Case of Intestinal Obstruction Produced by the Abnormal Remains of a Fetal Vessel. *Trans. Path. Soc. London*, 1875, xxvi, 117.
- Pestalozza, E.: Persistenza di un vaso onfalomesenterico nel cordone ombelicale di un feto a termine. *Bull. della soc. medico-chir. di Pavia*, 1889, 11.
- Ruge, C.: Ueber die Gebilde im Nabelstrang. *Zeitschr. f. Geb. u. Gyn.*, 1877, i, 7.
- Spangenberg, G.: Beitrag zur Entwicklungsgeschichte des Darmkanals. *Deutsches Arch. f. d. Physiologie*, 1819, v, 87.
- Tillmanns, H.: Ueber angeborenen Prolaps von Magenschleimhaut durch den Nabelring (*Ectopia ventriculi*), und über sonstige Geschwülste und Fisteln des Nabels. *Deutsche Zeitschr. f. Chir.*, 1882-83, xviii, 161.

## CHAPTER XV.

### UMBILICAL CONCRETIONS ASSOCIATED WITH INFLAMMATORY CHANGES IN THE ABDOMINAL WALL.

Historic sketch.

Symptoms.

Cause.

Treatment.

Cases with umbilical concretions.

Umbilical concretions frequently diagnosed as dermoids.

Cases of umbilical horn.

Other foreign substances in the umbilical depression.

THIS subject has been very carefully considered by Blum, Nicaise, Villar, Foulerton, Ledderhose, and Pernice. Umbilical concretions seem to be much more frequent in men than in women, and usually occur during the period of life in which the patient is most actively engaged in work, namely, between the twentieth and sixtieth year. They are exceptional in children and not common in the aged.

As a rule, the patient is unaware of any trouble until abdominal pain is felt. This is usually referred to the umbilical region, and may be increased on muscular exertion, on defecation, or on pressure upon the abdomen. On visual examination sometimes nothing is detected. Later induration is noted in the umbilical region, the umbilical opening becomes very small, and the surrounding tissue feels hard. The overlying skin may or may not be reddened. At this stage the patient may have excruciating abdominal pain, followed by the escape of a foreign body, together with some blood and pus. A speedy disappearance of the symptoms usually follows.

In the majority of cases the umbilical depression is the center of the trouble, but occasionally the swelling and induration are situated a short distance from it. This was noted in Williams's case. The tumor, the size of an egg, was situated one inch above the umbilicus, whereas the discharge came from the umbilicus itself.

The umbilical opening, as a rule, is very small, and suggests the mouth of a fistula. Its margins are usually flat, but occasionally the opening is surrounded by a zone of granulation tissue, as noted in cases reported by Foulerton, Nicaise, Polaillon, Richelot, Roques, Shattock, and Tremontani.

On examination the umbilical cavity is invariably found distended and filled with pus and a concretion or cheesy material. The cavity itself may be several centimeters in diameter. In Nicaise's case the umbilical depression opened through a very narrow aperture into a second cavity, which contained the concretion.

In Taylor's case, when opened up, the umbilical cavity was found to contain an ounce of foul-smelling pus, and this cavity communicated with a second filled with a softened, cheesy material and some hair.

Walters, under the title "An Umbilical Pocket," reports a very instructive

case. A man, aged thirty-four, had complained of mild periodic attacks of abdominal pain. The umbilical depression led to a second pocket, containing a yellowish mass, which the patient said had been there for years. The mass consisted of sebaceous material and felted hair. The pocket was two inches in diameter and three-quarters of an inch deep.

Probably one of the most interesting and instructive cases is that reported by Foulerton. Protruding from the umbilical site was a smooth, solid, round, reddish growth, the size of a cherry, from which there was a slight discharge. Surrounding this was a zone of induration. Cancer was suspected. Under local freezing the growth was cut off flush with the abdominal wall, opening up an abscess sac which contained pus and a concretion the size of a cherry-stone. The red nodule proved to be granulation tissue around the mouth of a small fistulous opening, and the abscess sac was nothing more than the occluded umbilical depression. Healing was complete in two weeks.

Although the induration in the abdominal wall is usually uniform, there may be marked local elevation. In one instance the swelling was as large as a hen's egg, and in the one described by Gueterbock it reached the dimensions of a child's head, a large collection of pus being present. The umbilical discharge may be small in amount or very free. Sometimes it is seropurulent, but usually most offensive, and of an odor suggesting decomposing smegma.

The umbilical concretions are variously recorded as being the size of a pea, bean, almond, sparrow's egg, or pigeon's egg. They have reached 1.5 to 2.5 cm. or more in diameter. They may be whitish yellow, brown, or pearly in color. Sometimes they appear to consist almost entirely of sebaceous material, and are exceedingly friable. Other concretions are much firmer, have a laminated structure, present a pearly appearance, and constitute what Coenen has termed *cholesteatomata*. The surface of these concretions may be perfectly smooth, or small hairs may be seen projecting from their surfaces. These hairs may be colorless or correspond in color to those of the patient. The cheesy material sometimes contains, in addition, other foreign material, such as wool or cotton fibers from the patient's clothing and particles of such matter as clay, coal, or stone, according to the occupation of the individual. On histologic examination the cheesy material is seen to consist of fatty desquamated epithelium, and in some cases keratin, fatty débris, and cholesterin crystals are also found.

The cause of these umbilical inflammations is easy to explain. Owing to lack of cleanliness or to an unusually deep umbilicus, particles of hair or wool accumulate deep in the umbilical depression. These form a small ball, which in turn, by its irritation, causes exfoliation of the squamous epithelium. This adheres to the mass and gradually increases its size. Finally, as a result of the constant irritation, there ensues a mild inflammation of the tissue surrounding the umbilicus, which gradually narrows the umbilical opening until it becomes but little larger in diameter than a fistulous tract. Pus accumulates and dilates the umbilical depression, and an abscess cavity containing a concretion results.

This condition rarely leads to serious consequences. In one of Volkmann's\* cases, however, it would seem that the long-continued irritation of the concretion had induced a primary carcinoma of the umbilicus.

The history of these cases is characteristic, and there should be little difficulty

\* Volkmann (Cited by Pernice): *Die Nabelgeschwülste*, Halle, 1892.

in establishing the diagnosis. In Foulerton's case, however, the condition was supposed to be one of carcinoma of the umbilicus.

**Treatment.**— This consists in widely dilating the fistulous tract with the full knowledge that in the depth a concretion or caseous material or both will be found. Thorough removal of the foreign substance is invariably followed by prompt recovery, but as long as portions remain there will be a discharge.

Occasionally an umbilical concretion may be present without producing any inflammatory reaction. On June 4, 1910, I saw a patient ninety-seven years of age at the Church Home, Baltimore. The umbilicus was exceedingly small; projecting from it, and completely filling the opening, was a small black mass (Fig. 147). The house officer suspected a malignant growth. On making pressure I forced the mass farther out. The deeper portions presented the characteristic cheesy character of a concretion. The superficial portion had become hard and black on account of exposure to the light, air, and dust.

While analyzing this group of cases the following case came under my care: Mr. S. W., aged thirty-two, was seen on March 31, 1913. This patient had been ill for two weeks; previous to this time he had been perfectly well. On examination I found the umbilicus pouting out like a snout. It projected out about 1 cm., and from its center there was a discharge of creamy pus. The opening from which this pus escaped was about 2 mm. in diameter. The abdominal wall on each side was indurated over an area of about 3 cm., and there was a distinct flush.

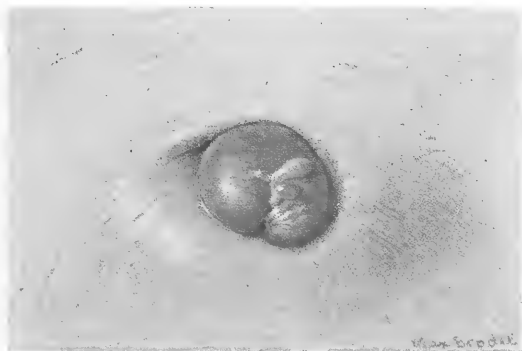


FIG. 148.—ACUTE INFLAMMATION OF THE UMBILICUS DUE TO AN ACCUMULATION OF SEBACEOUS MATERIAL.

The umbilical depression is raised and tense. Near its center pus is seen escaping from a small orifice. The surrounding abdominal wall is swollen, red, and indurated. The small opening was stretched considerably, and the cavity evacuated. A large quantity of cheesy material was curetted away. The cavity was packed with gauze. The inflammation speedily subsided, and in a few weeks the umbilicus presented the normal appearance.



FIG. 147.—A SMALL UMBILICAL CONCRETION.

From a woman, ninety-seven years of age, seen at the Church Home June 4, 1910. The umbilical opening was small; completely filling it was a small black mass, which on pressure was partly forced out. It consisted of cheesy material. The superficial portion had become black as a result of exposure to the light, air, and dust.

Fig. 148 is a water-color sketch of the condition. On pressure the parts were found to be indurated and there was a good deal of discomfort. I felt sure that we were dealing with an accumulation of sebaceous material, and that this had caused an acute inflammation.

Bichlorid compresses were applied for forty-eight hours. The patient was then brought to the operating-room, and with a pair of Kelly forceps the opening at the umbilicus was stretched. We then used a sharp curet and brought away quantities of sebaceous material. The

cavity was packed with iodoform gauze. From day to day the wound was washed out with hydrogen dioxid. The patient was discharged on April 5, 1913. On April 21st the umbilicus presented the normal appearance, and there was not the slightest trace of inflammation or of discharge.

#### CASES WITH UMBILICAL CONCRETIONS.

In some cases I have given an exact translation of the original title, although on careful examination of the description of the case it is evident that the patient was suffering from an umbilical concretion and not from a dermoid cyst, as diagnosed by the individual author.

*Tuberculosis of the Umbilicus* [?].\*—Ten days before the patient had had cramp-like pains in the abdomen, followed in three days by a discharge from the umbilicus, accompanied by tenderness and soreness in that region. His sisters had died of tuberculosis. There was a purulent discharge from the umbilicus and slight swelling to the right and below it, apparently in the deeper portion of the abdominal wall.

At operation the umbilical opening was enlarged, and over an ounce of "typical tuberculous" granulation tissue removed. The cavity, the size of a walnut, internal to the abdominal wall was exposed and packed with iodoform gauze.

Smears of this showed numerous "tubercle bacilli" in some specimens, none in others. Bouffleur questioned whether he was dealing with a primary tuberculosis of the blind urachus or Meckel's diverticulum or with a primary umbilical tuberculosis.

[The history of the case and the findings at operation would rather suggest an accumulation of sebaceous material at the umbilicus than any tuberculous process. The acid-fast organisms found were possibly smegma bacilli.—T. S. C.]

*Umbilical Concretions*. †—In two cases of phlegmonous inflammation of the umbilical region with fistula, Bufalini found at the bottom of the abscess stony concretions which consisted of fatty and gritty particles, of carbonic acid chalk, exfoliated epithelium, and threads from clothing.

*Cholesteatomata of the Umbilicus*.—Coenen‡ said that in the last two years two cases of "pearl tumor" of the umbilicus had been seen in Küttner's clinic. The first had already been reported in Brun's Beiträge, Bd. lviii, Hft. 3.

*Case 1*.—The patient, forty-nine years old, had a purulent discharge and a general phlegmonous condition in the region of the umbilicus. Slight jaundice developed and the umbilicus became very prominent. An incision was made, and an abscess cavity the size of a hen's egg was found at the umbilicus. This contained a tumor the size of a pigeon's egg (Fig. 149). It was made up of concentric layers of glistening mother-of-pearl tissue. These layers were arranged just as the various layers of an onion, and consisted of hornified epithelium. The process was complicated by suppuration.

*Case 2*.—A man of strong build, aged twenty-five, a few days before admission

\* Bouffleur: Clinical Review, Chicago, 1898, ix, 329.

† Bufalini, G.: Jahresbericht der gesamt. Med., 1887, ii, 497.

‡ Coenen, H.: Ueber das Cholesteatom des Nabels. Beiträge zur klin. Chir., 1908, lviii, 718; Münch. med. Wochenschr., 1909, lvi, II, 1583.

to the hospital had noticed at the umbilicus a swelling from which purulent fluid escaped. At the umbilicus was a smooth, pea-sized elevation, reddish in color, soft in consistence. When slight pressure was made on the umbilical funnel, there escaped a body the size of an acorn (Fig. 150). It had a mother-of-pearl, glistening appearance, was composed of horny layers, and at once brought to mind the previous case of cholesteatoma of the umbilicus. With the patient anesthetized, the posterior surface of the umbilical ring was found adherent to the gastrocolic ligament. These adhesions, together with the ligamentum teres and the obliterated urachus, were cut through. The umbilicus, which contained a small tumor the size of a hazel-nut, was removed. The abdomen was closed, and healing took place without difficulty.

Histologically, the tissue lying in the umbilical funnel consisted of markedly proliferating fibrous tissue with abundant small-round-cell infiltration and cells around the blood-vessels. Covering the surface of the fibrous tissue was a very thick layer of epithelium. This had exfoliated quantities of horny epithelium, so that in the space between this projection and the wall of the umbilical ring there was a large amount of horny epithelium. The connective tissue itself showed marked subepithelial cell proliferation, just as is seen in the vicinity of carcinomatous prolongations. Nevertheless, no carcinomatous infiltration by the epithelium could be definitely made out.

Sections from the cholesteatoma stained with Gram were intensely blue. The cells showed keratin bodies. In the umbilical funnel there was a knob-like fibroma (Figs. 151 and 152). There was marked proliferation of its epithelial covering, and there had been a continual throwing off of layers of epithelium into the umbilical depression. This desquamated epithelium was held in the umbilicus, the fibroma acting as a cork to the umbilical opening. In layer after layer the exfoliated epithelial cells had accumulated into a large plaque, forming the cholesteatomatous mass. Probably this process had existed for years, but was only noted by the patient when an abundant purulent discharge took place.

According to Coenen, the primary cause in this second case of cholesteatoma of the umbilicus was without doubt the presence of the fibrous tumor in the umbilical depression. The continuous irritation of the products of the cholesteatoma in the umbilical ring could now easily lead to an eczematous inflammation of the skin of the umbilicus, to abscess formation, and to phlegmon.

*C h o l e s t e a t o m a o f t h e U m b i l i c u s .*—Coenen\* described a case from Küttner's clinic. A woman, sixty-two years old, had a pendulous abdomen and lax abdominal walls. When the varicose folds were drawn away from one another, there was seen in the umbilicus the characteristic pearly, glistening epithelial exfoliation noted in a cholesteatoma. The growth could be lifted out with a spoon and appeared as small balls the size of a pea or of a bean.

If the material had remained longer, it would have developed into a cholestea-

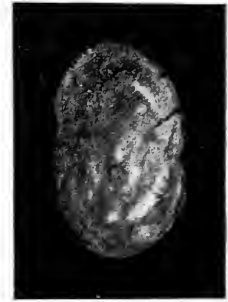

FIG. 149.—CHOLESTEATOMA FROM THE UMBILICUS IN CASE 1. (After Coenen.)

From the description, this is apparently the natural size. It was described as being the size of a pigeon's egg.



FIG. 150.—CHOLESTEATOMA FROM CASE 2. (After Coenen.)

It was the size of an acorn.

\* Coenen, H.: Loc. cit.

toma. In this case there was a desquamative omphalitis with an accumulation of cholesteatomatous masses in the umbilical ring. Coenen calls attention to the analogy between cholesteatoma of the umbilicus and cholesteatoma of the ear.

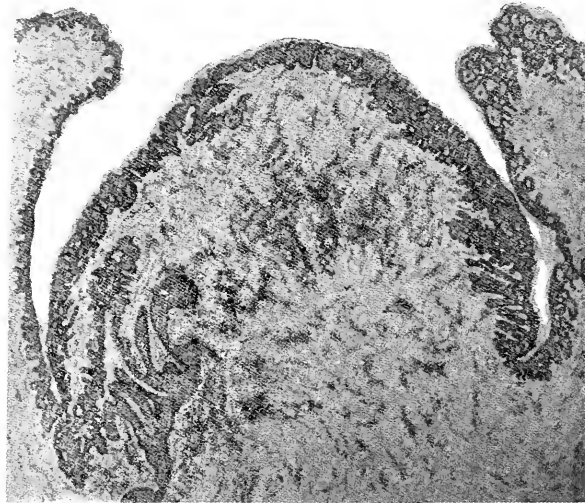


FIG. 151.—THE CONNECTIVE-TISSUE PROJECTION REALLY REPRESENTS A SMALL FIBROMA IN THE FLOOR OF THE UMBILICUS. (After Coenen.)

It consists of fibrous tissue showing marked small-round-cell infiltration. The covering consists of many layers of squamous epithelium, superficial portions of which are horny.

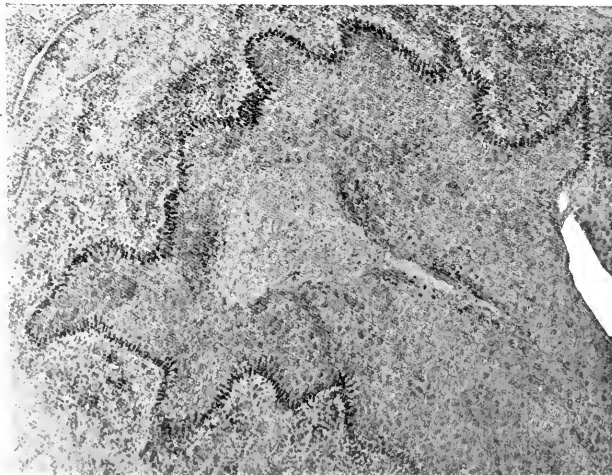


FIG. 152.—ENLARGEMENT OF FIG. 151. (After Coenen.)

The excessive thickening of the squamous epithelium in the umbilical depression is shown. The center of the epithelial areas shows hornification. The underlying tissue shows small-round-cell infiltration, particularly well seen around the capillaries.

**Fistulous Abscess of the Umbilicus.** \* — A digger, forty-six years of age, had always been healthy except for a pleurisy at four years of age. He said that fifteen days before coming under observation he had had pain in the

\* Derville, L.: Absès fistuleux de l'ombilic. Jour. d. sci. méd. de Lille, 1894, ii, 320.



umbilical region, and at the same time a serous discharge from the umbilicus. The pain increased greatly, and after the application of poultices a grayish piece of stone the size of a pea came away. A probe was passed to a depth of 2 cm.

**A Sebaceous Umbilical Tumor.\***—At autopsy on a stout woman, seventy-five years of age, a small, elongate tumor at the umbilicus, with a little opening, was found. A probe introduced into this opening was arrested by a yellow, very hard body. An incision showed that the cavity was continuous with the skin. The body in this cavity was ovoid in form, the size of an almond, whitish yellow, and sticky. It had the odor of infected smegma.

On microscopic examination it was found to consist of cholesterin and an accumulation of exfoliated epithelium.

**Growths from the Umbilicus.†**—A dockyard laborer, aged forty-nine, had protruding from the site of the umbilicus a smooth, solid, round growth the size of a cherry. This had a covering resembling mucous membrane, and from it there was slight discharge. Its base was somewhat constricted, but there was no definite pedicle, and no sulcus could be detected between the growth and the surrounding skin. Around the growth was a zone of uniform induration extending for an inch and a quarter in every direction, involving the skin and subcutaneous tissue. The skin over the indurated region was of the natural appearance, adherent to the subcutaneous tissue, and extremely tender. The patient thought that his umbilicus had always been smaller than usual, but had noticed nothing else until three weeks previously, when a very painful lump had suddenly appeared there. The lump was considerably smaller when he first saw it than on admission. The pain had been extreme and continuous. The surgeon who sent him to Foulerton had diagnosed cancer, and, as a matter of fact, the growth had every appearance of epithelioma. The pain had been, however, too acute in its commencement and in its intensity. The growth was removed at the level of the skin under the ether spray, and a cavity was exposed. This contained some thin, purulent fluid, and a hard mass of inspissated sebaceous material the size of a cherry-stone. The cavity admitted the tip of the finger; it was laid open, scraped out, and a poultice was applied. Four days later the induration was gone and the wound healed up in two weeks. Foulerton draws attention to his article in the *Lancet* of July 7, 1888, in which he described four intractable umbilical sinuses due to concretions. No microscopic examination was made in this case.

**Dermoid Cysts of the Umbilicus[?].‡**—A man, thirty-five years of age, entered the hospital for umbilical suppuration. About five months before a small tumor had been noted at the umbilicus. This had reached the size of a walnut and was slightly painful. It had been incised a month before admission, and a caseous mass and a tuft of hair had escaped. Gonard found the umbilicus indurated and red; the orifice was very small, and from it drops of pus escaped. A probe was passed 2 cm. into the depth, and the sac dissected out. Gonard thought it was a dermoid cyst on account of the hair and the inner lining.

[Probably the case was one of inflammation due to the presence of a foreign body.—T. S. C.]

\* Féré, C.: Tumeur sébacée ombilical. *Bull. Soc. anat. de Paris*, 1875, I, 622.

† Foulerton, A. G. R.: *Illustrated Med. News*, 1889, iv, 161.

‡ Gonard, G.: *Des kystes dermoïdes*. Thèse de Montpellier, 1906, No. 31.

A Dermoid Tumor of the Umbilicus [?].\* — A girl of sixteen had noticed a swelling in the abdomen fourteen days before coming under observation. During the last eight days this had rapidly increased in size. On admission it was the size of a child's head, round, and at several points markedly nodular. It was situated in the mid-line, was easily grasped, was firm, not very elastic, somewhat movable, and slightly painful on pressure. Three days later fever developed, and after two days more redness and fluctuation were noted. On the following day there was an abundant quantity of thin pus coming from an irregular hole in the tumor. Sebaceous masses and portions of a thin membrane were then removed. The tumor, after its contents had escaped, became markedly smaller and gradually disappeared. Microscopic examination showed free nuclei, granules, cholesterin crystals, and fat.

[If it had been a dermoid, why had it appeared so suddenly and why did it disappear completely, although all the wall was certainly not removed? Was it not more probably an abscess?—T. S. C.]

An Umbilical Concretion the Size of a Pigeon's Egg. — Hahn † says concretions of the umbilicus occurring as a result of cleanliness are not rare. His patient, a joiner, forty-three years old, fourteen days before he came under observation had noticed a painful swelling at the umbilicus. The skin was unchanged. For four days before Hahn saw him pus had been escaping from the umbilicus. On examination a swelling on the right side of the umbilical depression was found, and a tumor the size of a walnut, circumscribed, smooth, firm, and painful on manipulation. There was an escape of thick, greenish, foul pus in small quantities. The sound passed 2 cm. downward and to the right. After a few days there was edema of the skin and a slight elevation of temperature.

A transverse incision was made to the right. Pus with whitish, friable particles escaped. In the depth was a roundish, whitish, glistening tumor, the size of a pigeon's egg, which was easily removed. It was 3 cm. long and 2 cm. broad. It was yellowish white, rather firm, and friable. It had an outer covering 3 to 4 mm. thick, with a blackish central portion. On histologic examination it was found to be composed of horny epithelium, fat, sebaceous masses, dirt, and particles of coal. The dark center had the same constituents and also contained wool fibers. Hahn draws attention to the fact that such concretions are often confused with suppurating dermoids.

An Umbilical Concretion. — According to Ledderhose, ‡ Gilbert described a concretion which was composed of lamellæ. It showed amorphous and crystalline fat, leukocytes, and fragments of chalk.

An Umbilical Concretion. § — Duplay's patient was a stout, elderly woman. At autopsy, at the umbilical level there could be felt a small, elongate tumor directed obliquely downward and then backward. This occupied a fatty pocket. The upper portion of the umbilical wall was intact. When the

\* Gueterbock, P.: Ueber einen Fall von Dermoidgeschwulst des Nabels. Deut. Zeitschr. f. Chir., 1891, xxxii, 319; Deutsche med. Wochenschr., 1891, xvii, 1079.

† Hahn, Otto: Ein Nabelkonkrement von Taubeneigrösse. Beiträge z. klin. Chir., 1900, xxvi, 80.

‡ Ledderhose, G.: Chirurgische Erkrankungen des Nabels. Deutsche Chirurgie, 1890, Lief. 45 b.

§ Nicaise: Ombilic. Dictionnaire encyclopédique des sci. méd., Paris, 2. sér., xv, 1881, 140.

margins of the cutaneous depression were separated, at the bottom could be seen a small opening a little over 1 mm. in diameter. A probe introduced impinged upon a foreign body which was yellowish in color. An incision was made, and at the umbilical cicatrix was found a sac-like formation containing a hard, homogeneous body the size of an almond and consisting of sebaceous material.

**An Umbilical Concretion.**—Nicaise\* reports the following case, seen by Notta, in which an accumulation of sebaceous material had given rise to an inflammation of the umbilicus. A shoemaker, aged fifty-six, had previously had excellent health. Two years before he had noticed at the umbilicus a hardness without any change in color of the skin and without any discharge. This hardness had increased in volume very slowly, and only later had become painful. At last he could not bear the clothes to come in contact with the part, and his work naturally augmented the pain. He was not able to hold the shoe against his umbilicus, as is the custom with shoemakers, but was obliged to work with it applied to another part of the abdomen. About June 10, 1878, the pain had become more severe, the skin had reddened, ulceration had occurred in the center of the umbilicus, and a small amount of pus had escaped until a fragment of a sebaceous calculus, the size of a filbert, had come away spontaneously, and the pain had ceased. His physician later had extracted several fragments. When called in consultation, Notta found the umbilicus tumefied and the skin red and indurated for a distance of from 12 to 15 cm. around it. In the center was an area of ulceration 15 mm. in diameter, at the bottom of which, bathed in pus, was a whitish mass. After enlarging the opening Notta extracted the whitish mass, the size of a walnut, which consisted of hard sebaceous material. Linseed poultices were applied for twenty-four hours, and later lint steeped in aromatic wine. The umbilicus healed rapidly. The cause of this affection, according to Notta, was very simple. Sebaceous material had accumulated in the deep folds of the umbilicus, and little by little had condensed to form a mass having the appearance of a calculus. This had produced an inflammation which had caused the elimination.

**Inflammation in the Umbilical Depression.**—Park's† patient was thirty years old, and for two or three years had had a slight but constant discharge from a small opening at the umbilicus. At no time had this had a fecal or urinary odor. It was seropurulent in character, and excoriated the parts.

The cavity was slit open with a probe as a guide. It had the diameter of an almond, and had glistening walls; it contained no hair or epithelial products. Park thought it was a dermoid. The cavity was scraped out, packed, and partly closed. Healing took place.

[In this case there had evidently been a simple inflammatory condition.—T. S. C.]

**Umbilical Concretion.**—Pernice‡ reports a case of Longuet's.§ A young woman had a swelling at the umbilicus for three weeks. At first there was no pain. Later it began to suppurate. Three days after the patient's entrance

\* Nicaise: *Op. cit.*

† Park, Roswell: *Clinical Lecture on Congenital Fistulae and Sinuses at the Umbilicus.* *Med. Fortnightly*, 1896, ix, 9.

‡ Pernice, L.: *Die Nabelgeschwülste*, Halle, 1892.

§ Longuet: *Bull. Soc. anat. de Paris*, 1875.

to the hospital, as a result of the introduction of a sound, a foreign body was expelled. It was the size of an almond, hard, made up of epithelial masses and fatty crystals.

**Umbilical Concretions.**\*—A man, forty years of age, after muscular exercise had felt something give way in the region of the umbilicus, and after that had had pain there. The umbilicus was red, swollen, and projected 3 cm. from the abdomen. From it there escaped a foul-smelling discharge. On pressure two bodies the size of beans were forced out. They consisted entirely of matted hair.

**Suppurating Dermoid Cyst of the Umbilical Region** [?]. †—A woman, thirty years of age, presented a tumor in the umbilical region. When one year old, she had had a blow on the umbilicus. For several days, during the six weeks before she was admitted, her abdomen had continually come in contact with the wash-tub. For about three days she had had pain in the umbilical region. A few days later she had noticed a discharge from the umbilicus and a swelling for a distance of 2 cm. around the umbilical region. Squeezing caused a moderate amount of pus to escape from the umbilicus. On admission there was an elevated area of proud flesh the size of a pigeon's egg. The umbilicus was red and thickened; fluctuation was evident. An incision evacuated pus and grumous material. A probe passed 4 cm. downward. The cavity was irrigated. About two weeks later a sebaceous-like mass, the size of a walnut, escaped.

[The condition suggests a foreign body or a concretion rather than a dermoid.—T. S. C.]

**Subumbilical Tuberculous Abscesses** [?]. ‡—Case 1. A man, thirty-five years old, had complained of swelling in the umbilical region for about a month. He had vomiting, and pain at the umbilicus. Following this there had developed a painful swelling, but when his physician, thinking it was a hernia, had attempted to reduce the mass by taxis, pus had escaped from the umbilicus. Since then there had been a fistulous opening and a phlegmonous induration of the region. The patient's general condition was good. The tumefaction was exactly in the median line and symmetric. A probe could be introduced only with difficulty, except when curved. A sound passed 7 or 8 cm. below the umbilicus, both to the right and left.

The tumor opened toward the right side, and one day a large mass of caseous material came away. The opening closed, and the patient left the hospital. Six months later there was pain in the abdomen, but nothing was noted at the umbilicus.

Ten years before the patient had had inflammation of the left lung and a pleuropneumonia on the right side five years later, but never a hemorrhage. Auscultation was negative.

[The history of the case and the character of the discharge strongly indicate an accumulation of sebaceous material in the umbilicus. Had tuberculosis existed, one would hardly have expected the cavity to have closed so satisfactorily.—T. S. C.]

Case 2.—Richelot reports a personal communication from Verneuil. A Sister of Charity, who had had scrofula as a child and also an old coxalgia, received a contusion beneath the umbilicus when using a good deal of force in closing a drawer.

\* Pernice, L.: *Op. cit.* Labalbary: *Gaz. des hôp.*, 1862, 443.

† Polaillon: *Kyste dermoïde suppuré de la région ombilicale.* *Gaz. méd. de Paris*, 1886, lvii, 435.

‡ Richelot, L. G.: *Abcès tuberculeux sous-ombilical.* *L'union méd.*, 1883, xxxv, 61.

Several weeks later a fluctuating tumor was noted at the umbilicus. It was incised, and a large quantity of milk-like fluid escaped. A fistula developed several months later; she began to cough, and finally died of tuberculosis.

**A n U m b i l i c a l C o n c r e t i o n .\***—The patient, fifty years old, had been previously in good health. The umbilicus formed a deep cul-de-sac surrounded by a red and tumefied zone. It was painful on pressure. The pain was increased on movement or on defecation. Applications were made, and later there was a discharge of seromucous fluid and a small body came away. The symptoms rapidly subsided. This nodule was spheric, the size of a hazelnut, and hard. On section it showed black and white areas. The black particles occupied the center; the whitish areas were soluble in ether.

[There were evidently foreign bodies associated with an accumulation of epithelium.—T. S. C.]

**A n U m b i l i c a l C o n c r e t i o n .†**—A soldier, thirty-two years of age, complained of pain at the umbilicus for fifteen days. The pain was extreme and there was a certain amount of heat in the depth of the tissue. Surrounding the umbilicus was a tumefied and red area. When a probe was introduced, a sensation of a hard body in the depth could be made out and an abundant amount of sebaceous material escaped. At the end of five days a probe could be introduced 7 cm. On the twentieth day there were violent contractions, accompanied by severe pain, and a foreign body escaped with half a glass of pus and blood.

This body was the size of a sparrow's egg, pearly in color, and had a sebaceous odor. Its center was hard and consisted of a piece of clay containing several particles of grit and several hairs of the same color as those of the patient. He was a stone-cutter, and particles had evidently dropped into the umbilical cavity.

**T w o S p e c i m e n s o f U m b i l i c a l C a l c u l i .‡**—**C a s e 1.**—A man, twenty-three years of age, had noticed a discharge from the umbilicus for eight weeks. The surrounding abdominal wall was indurated and tender. Later a calculus was extracted. The sinus and a granuloma which had formed around its margins rapidly disappeared. The concretion was 1.5 cm. long, oval in form, and consisted of closely packed squamous epithelial cells with a certain number of hairs.

**C a s e 2.**—A man, thirty years old, had had a discharge from the umbilicus for five years, associated with a granuloma. Around the sinus was granular tissue which formed a tumor the size of a cherry. The sinus was opened and found to be burrowing in various directions. An oval concretion, 2.5 cm. long, was found. Over certain areas this was smooth and had a silvery exterior. From the surface projected the ends of fine hairs, and a section presented traces of laminations. In the center was a small piece of flocculent material—cotton fiber. The concretion consisted of closely packed, flattened, and wrinkled epithelial cells.

**D e r m o i d C y s t i n t h e A b d o m i n a l W a l l o f a M a n [ ? ] .§**—A man, twenty-two years of age, four weeks before coming under observation had noticed a small mass in the median line of the abdomen directly below the umbilicus. It had gradually increased in size until it was as large as an egg, hard and tender.

\* Rouget: *Gaz. des hôp.*, 1862, 259.

† Roques: *Kyste occasionné par la présence d'un fragment de terre dans l'ombilic.* *Gaz. des hôp.*, 1862, 314.

‡ Shattock, S. G.: *Trans. Path. Soc. London*, 1900, li, 282.

§ Taylor, Wm. J.: *Annals of Surgery*, 1896, xxiii, 296.

He had had some purulent discharge from the umbilicus before entering the hospital. This had increased in quantity.

An incision was made over the swelling, and about an ounce of foul-smelling pus was evacuated. The probe passed from the umbilicus into the abscess cavity. At the bottom of the cavity, and communicating with it, was a depression containing soft, cheesy material and a small amount of hair. Taylor considered the nodule as a small dermoid that had become infected. It was limited strictly to the abdominal wall. The abscess cavity and cyst were curetted freely; the umbilicus was dissected away. The cavity was filled with iodoform gauze. Prompt recovery ensued.

[In all probability this was an abscess due to retained material. Had a dermoid existed, it would have been almost impossible to curet and completely remove the cyst-wall.—T. S. C.]

**Dermoid Cyst of the Umbilicus** [?].\* — A man, twenty-nine years of age, had a tumor the size of a walnut at the umbilical cicatrix. This was bright red in color, moist, and translucent. On the surface it was firm in consistence; it did not pulsate, was irreducible, and had a short pedicle. The pedicle was smaller than the top of the umbilicus, and there was a discharge of seropurulent fluid, yellowish in color and of an offensive odor. The tumor was dissected out, but returned rapidly. Histologic examination showed a membrane of fibrous tissue; the contents were cholesterin crystals, numerous epithelial cells, and colorless hairs. Tremontani thought the tumor was a dermoid.

[It strongly suggests an accumulation at the umbilicus.—T. S. C.]

**Umbilical Pocket.** † — A man, thirty-four years old, complained of periodic attacks of mild stomachache with a slight discharge from the umbilicus. The umbilical depression led to a skin pocket containing a yellowish mass which the patient said had been there for years. The mass was readily detached by careful probing, and proved to consist of felted hairs and sebaceous material. The pocket was about two inches in diameter and three-quarters of an inch deep, with an opening half an inch in diameter. No hernia was present. The man was of cleanly habits, accustomed to take much exercise, and habitually wore a home-made belt of flannel, from which the hairs were derived.

**An Umbilical Concretion.** ‡ — One inch above the umbilicus there was a tumor the size of a small egg. Pus escaped from the umbilicus. A flaxseed poultice was applied. Suddenly a small amount of blood and a concretion escaped. The wound healed up at once. The mass weighed only four grains, and appeared to be felted together like a concretion of ear-wax.

The two cases which follow are also in all probability instances of abscess due to an accumulation of foreign material at the umbilicus.

**An Umbilical Sinus.** § — The woman was twenty-five years of age, married, and very stout. Two years before she had noticed some discharge from the umbilicus. Eighteen months before admission there were signs of abscess,

\* Tremontani, E.: *Sopra un caso di granuloma ombelicale da cisti dermoide in un adulto.* Il Morgagni; *Giornale Indirizzato Al Progresso Della Medicina*, 1903, xlv, Parte 1; *Archivio*, 387.

† Walters, F. R.: *Brit. Med. Jour.*, 1893, i, 173.

‡ Williams, F. H.: *Amer. Med. Jour.*, St. Louis, 1907, xxxv, 295.

§ Chislett, H. R.: *Umbilical Sinus.* *The Clinique*, Chicago, 1905, xxvi, 167.

with pain, swelling, and redness. An incision was made. The sinus was an inch deep; the pocket extended to the peritoneum and contained thick pus. The abscess was evacuated, and the granulation tissue cureted away. Iodin was applied and the cavity packed with iodoform. She made a good recovery.

**A Subumbilical Tumor.**—Fischer\* said he operated on a woman who had a fistula to the right of and below the umbilicus, near the linea alba. This fistula was deeply seated and led to a fixed tumor the size of an apple, which extended from the umbilicus 8 cm. downward and was 5 cm. in breadth. On pressure there escaped pus and cheesy, tenacious masses and hair. The patient had noticed the tumor for only five weeks, and then, on account of the inflammation and swelling that had developed. It had ruptured fourteen days before admission. As the tumor was nowhere adherent to the peritoneum, it was removed without difficulty.

#### CASES OF UMBILICAL HORN.

This condition is evidently very rare, as I could find records of only two cases, those of Hennig and Nagel. Unfortunately, the data relating to these are not very clear.

In Hennig's case the horn was about 2 cm. long, 1 cm. in diameter, and slightly bent, while in Nagel's case it was 1 cm. long. The consistence is not mentioned in either case. Both dropped off spontaneously.

It is difficult to understand how a horny growth can appear in this situation. In 1910 I saw a woman over ninety years of age with a small, dark mass protruding from a very small umbilical depression. This mass was black and hard in consistence. When pressure was made around the umbilicus the mass protruded fully 1 cm. from the level of the abdomen. Further pressure caused still more protrusion, and the mass dropped out. It was an umbilical concretion. On account of the exposure to the air the superficial portion had become very hard and was black, whereas the part lying more deeply in the umbilicus was whitish yellow and cheesy (see Fig. 147, p. 249). It will be noted that the superficial portion of Nagel's specimen was also black. It is just possible that in both of these cases the horns were in reality hardened umbilical concretions and not true umbilical horns.

**A Case of Horn of the Umbilicus.**—Pernice† says that Hennig saw a healthy American who from her childhood had had a horn at the umbilicus. It was about 2 cm. long, 1 cm. thick, cone-shaped, and slightly bent. In the eighth month of her first pregnancy the horn dropped off, partly as result of the unfolding of the umbilicus, "partly as a result of diminished nourishment."

**A Small Horn at the Umbilicus.**—In a letter to Dr. Kelly Prof. F. W. Nagel mentions the case of Frau H., who was born in Berlin, December, 1878. On the eighth of June, 1907, she was delivered for the first time by Nagel. About the middle of the pregnancy a little prominence, the thickness of a match, was noticed at the umbilicus. This was more and more visible toward the end of pregnancy. It formed a horn 1 cm. long. At the beginning it was gray; later on it dried up and became black. After labor the horn drew in and disap-

\* Fischer, H.: Die Eiterungen im subumbilicalen Raume. Volkmann's Samml. klin. Vorträge, Neue Folge, Nr. 89 (Chir. No. 24), Leipzig, 1890-94, 519.

† Pernice, L.: Die Nabelgeschwülste, Halle, 1892.

peared. Nagel examined the patient on December 10, 1910, and by separating the umbilical folds was able to see the points of the now yellowish-white horn.

#### MAGGOTS IN THE UMBILICUS.

In a letter dated December 9, 1910, Dr. John S. Fulton gave me an account of a rather unusual umbilical condition. Several years previously a baker had come to his clinic at the University of Maryland complaining of some umbilical trouble. Fulton watched the man undress, and at once recognized his occupation by three rings of dough—"waist deep, midarm deep, and elbow deep." On examining the umbilicus he found it inhabited by six maggots. Their removal was followed by complete relief of the patient.

The only other case I know of in which a similar condition was noted was furnished by E. L. M.\* in 1899. He was called to see an infant eight days old. The cord had come off on the fifth day. On examination the umbilicus was found filled with maggots. A few drops of chloroform were dropped into the umbilicus, and 24 dead maggots were washed out with sterilized water. Boric acid was then dusted in and there was no further trouble.

Escape of a Piece of Wild-oat Straw From an Umbilicus. †—The patient was one month old. The mother had noticed much moisture at the umbilicus ever since the cord had come away. At the umbilicus was a reddish, pedunculated tumor the size of a pea. This was cut away with scissors and cauterized. It recurred, but on being again treated in a similar manner, did not reappear. Some time later an abscess developed at the umbilicus. It was opened, some pus and a piece of wild-oat straw escaping. The fact that there was continual moisture at the umbilicus after the cord came away strongly suggested a remnant of either the omphalomesenteric duct or the urachus.

\* E. L. M.: Maggots in the Umbilicus. Med. Council, Philadelphia, 1899, iv, 364.

† Fabrège: Note sur les excroissances polypeuses de la fosse ombilicale chez les enfants nouveau-nés. Rev. méd. chir., 1848, iv, 353.

#### LITERATURE CONSULTED ON UMBILICAL CONCRETIONS ASSOCIATED WITH INFLAMMATORY CHANGES IN THE ABDOMINAL WALL.

- Blum, A.: Tumeurs de l'ombilic chez l'adulte. Arch. gén. de méd., Paris, 1876, 6<sup>e</sup> sér., xxxviii, 151.
- Bouffleur: Tuberculosis of the Umbilicus. Clin. Review, Chicago, 1898, ix, 329.
- Bufalini, G.: Jahresber. der gesamt. Med., 1887, ii, 497.
- Coenen, H.: Ueber das Cholesteatom des Nabels. Beiträge z. klin. Chir., 1908, lviii, 718.
- Chislett, H. R.: The Clinique, Chicago, 1905, xxvi, 167.
- Derville, L.: Absès fistuleux de l'ombilic. Jour. des sci. méd. de Lille, 1894, ii, 320.
- Féré, G.: Tumeur sébacée ombilicale. Bull. Soc. anat. de Paris, 1875, l, 622.
- Fischer, H.: Volkmann's Sammlung klin. Vorträge, Neue Folge, Nr. 89 (Chirurg., No. 24), Leipzig, 1890-94, 519.
- Foulerton, A. G. R.: Form of Umbilical Sinus Occurring in Adults. The Lancet, 1888, ii, 16.
- Foulerton, A. G. R.: Growths From the Umbilicus. Illustrated Medical News, 1889, iv, 261.
- Gonard, G.: Des kystes dermoïdes. Thèse de Montpellier, 1906, No. 31.
- Gueterbock, P.: Ueber einen Fall von Dermoidgeschwulst des Nabels. Deutsche Zeitschr. f. Chir., 1891, xxxii, 319.



- Hahn, Otto: Ein Nabelkonkrement von Taubeneigrösse. Beiträge z. klin. Chir., Tübingen, 1900, xxvi, 80.
- Ledderhose, G.: Chirurgische Erkrankungen des Nabels. Deutsche Chirurgie, 1890, Lief. 45 b.
- Nicaise: Ombilic. Dictionnaire encyclopédique des sci. méd., Paris, 1881, 2. sér., xv, 140.
- Park, Roswell: Clinical Lecture on Congenital Fistulae and Sinuses at the Umbilicus. Med. Fortnightly, 1896, ix, 9.
- Pernice, L.: Die Nabelgeschwülste, Halle, 1892.
- Polailon: Kyste dermoïde suppuré de la région ombilicale. Gaz. méd. de Paris, 1886, lvii, 435.
- Richelot, L. G.: Abscess tuberculeux sous-ombilical. L'union méd., 1883, xxxv, 61.
- Rouget: Gaz. des hôp., 1862, 259.
- Rouges: Kyste occasionné par la présence d'un fragment de terre dans l'ombilic. Gaz. des hôp., 1862, 314.
- Shattock, S. G.: Two Specimens of Umbilical Calculi. Trans. Path. Soc. London, 1900, li, 282.
- Taylor, Wm. J.: Dermoid Cyst in the Abdominal Wall of a Man. Annals of Surgery, 1896, xxiii, 296.
- Tremontani, E.: Spora un caso di granuloma ombellicale da cisti dermoïde in un adulto. Il Morgagni; Giornale Indirizzato al Progresso della Medicina, Parte I, Archiv, 1903, 45, 387.
- Villar, F.: Tumeurs de l'ombilic. Thèse de Paris, 1886, No. 19.
- Walters, F. R.: Umbilical Pocket. Brit. Med. Jour., 1893, i, 173.
- Williams, F. H.: An Umbilical Concretion. Amer. Med. Jour., St. Louis, 1907, xxxv, 295.

## CHAPTER XVI.

### ABSCESS IN THE SUBUMBILICAL SPACE.

Description of Heurtaux's observations.

Fischer's injections of the subumbilical space.

An empyema opening into the subumbilical space.

A liver abscess opening into the subumbilical space.

An appendix abscess opening into the subumbilical space.

An echinococcus cyst in the subumbilical space.

Actinomycosis in the subumbilical space.

Résumé.

HEURTAUX,\* in 1877, described what he called a phlegmonous subumbilical inflammation deep in the anterior abdominal wall. He said that, up to that time, so far as he knew, this condition had never been reported. The affection is characterized by the presence of an inflammatory tumor, which is sharply circumscribed and is in the median line. It is symmetric and oval in form; its base occupies the umbilicus. The tumor is deep-seated. On examination it will be found to have

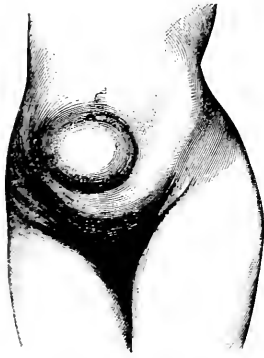

FIG. 153.—SUBUMBILICAL PHEGMON. (After Heurtaux.)

According to Heurtaux, the swelling is sometimes visible with the naked eye, and appears as an oval tumefaction, slightly prominent, and shading off into the surrounding tissue.

developed exactly at the umbilicus (Fig. 153). It varies from 6 to 10 cm. in diameter, is immobile, firm in consistence, and after a few days may give deep fluctuation. When suppuration commences, the tumor becomes prominent and the umbilicus may be reddened and perforate, the quantity of escaping pus varying from 120 to 150 c.c. In Heurtaux' cases there never was any escape of gas. A sound sometimes entered toward the pubes for 6 cm., and to the right or left for 3 cm. In three acute cases, fluctuation was detected in from nine to seventeen days after the onset; in subacute cases, after a period varying from four to five weeks.

In all of the six cases reported by Heurtaux the phlegmon terminated in suppuration. In four it opened spontaneously, the opening being in the umbilical cicatrix in two of these. According to Heurtaux, the lesion is always found in the same situation and the prognosis is good.

An analysis of Heurtaux' cases shows that the youngest patient was six and one-half years, the oldest, fifty-five. Nearly all of them had been ill before. Three were males and three females. In Case 2 a labor had occurred three weeks before the abscess developed; in Case 3 it followed a pleurisy; in Case 6 it developed in the course of measles, and a severe broncho-pneumonia also complicated matters. In Case 1 the patient was in the second

\* Heurtaux, A.: Phlegmon sous-ombilical. Bull. et Mém. de la Soc. de chir. de Paris, n. s., 1877, iii, 641.

stages of syphilis, and in Case 4 the patient had recovered from a grave attack of typhoid fever. In four of the cases the symptoms were acute; in two, subacute. In the acute cases there were severe pain, sensitiveness in the umbilical region, and a tendency toward constipation. In some cases there was vomiting.

The observations of Heurtaux seem in a large measure to have been overlooked, and it was not until the work of Fischer\* that we again hear much on this subject. Fischer wrote a most extensive article in which he discussed acute subumbilical phlegmon, chronic abscess in the subumbilical space, and the breaking through of purulent collections into the subumbilical space. In the beginning he refers to the work of Heurtaux, and says that Joüon and Heurtaux in 1877 studied the anatomy and pathology of the subumbilical region and found on each side of the linea alba a triangular space. He says that Charpy, in 1888, found that the subumbilical space was in part retroperitoneal, in part prefascial.

Fischer tried to fill the subumbilical space by injecting colored gelatin with a syringe introduced through an incision in the lateral wall of the rectus, the needle being directed inward and between the sheath of the rectus and the peritoneum. By this procedure he was able to produce a tumor, heart-shaped in form, with its base at the umbilicus and the apex about 6 cm. below it (Fig. 154). It was most prominent laterally, and diminished toward the linea alba, where it was represented by a fine furrow. At its base it was 14.6 cm. broad; at its apex, 1.6 cm.; its greatest length was from 8 to 9 cm. In men and women, in young and old, in fat and thin, the space was always the same size. Above it was closed partly by the umbilical scar, partly by firm adhesions between the peritoneum and the sheath of the rectus, at the outer side and below only by adhesions between the peritoneum and the sheath of the rectus. Joüon said that there was no definite walling-off below, but that a loose connective tissue existed through which the space communicated with the cavity of Retzius.

On page 523 Fischer says that suppurations which start in the subumbilical space run either an acute or a chronic course, and whereas some develop in the space, others wander in. He then goes on to describe briefly the clinical picture.

In speaking of acute subumbilical phlegmon, he says that he had five definite cases of subumbilical inflammation, such as were described by Heurtaux, and that in all he found the same characteristic picture. Fischer's tumors developed in men from seventeen to thirty-four years of age, who, apart from a gonococcal infection, had always been well. None of them had had a definite trauma nor was there any evidence of such a condition having existed.

The affection commences with a chill, and there is fever during the entire course of the disease, the temperature varying from 38.5° to 39.5° C. There is marked pain on attempting to straighten out the legs and on pressure on the abdomen. The pain commences at the umbilicus and spreads in all directions. The patient accordingly lies perfectly flat on the back, with the legs drawn up and the abdomen tense. In addition there is constant vomiting of slimy, pale-stained masses, the effort naturally increasing the amount of abdominal pain. The vomiting increases, and there is a feeling of faintness. The patient becomes pale and shows signs of collapse. The extremities, however, remain warm. The pulse is quick and the expression anxious. These symptoms are so pronounced at times that peritonitis

\* Fischer, H.: Die Eiterungen im subumbilicalen Raume. Volkmann's Samml. klin. Vorträge, n. F., No. 89 (Chir. No. 24), Leipzig, 1890-94, 519.

is thought of and a bad prognosis is given. Nevertheless, after the distressing symptoms have lasted two to four days the vomiting disappears. The bowels move again and flatus is expelled. The pain becomes more marked in the umbilical region, and a faint reddening and edema are noted in this situation. On palpation one can now feel a dense but movable infiltration, triangular in form,

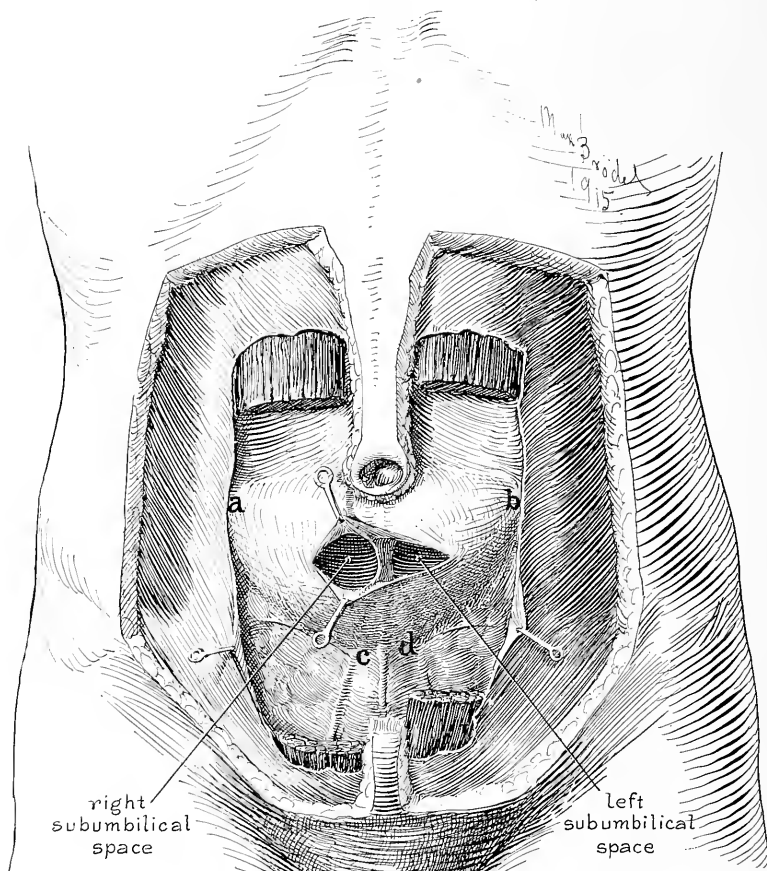


FIG. 154.—THE SUBUMBILICAL SPACE. (Schematic.)

Heurtaux has described a series of cases in which abscesses have developed just below the umbilicus. He speaks of these as subumbilical abscesses. Fischer has attempted to outline these spaces by using injections of gelatin. This sketch has been drawn after the description and measurements of Fischer. The umbilicus is seen in the midline. On each side of this the fascia and muscle have been removed. The space is situated just below the umbilicus, and lies behind the rectus muscles. The base of the space is indicated by a line drawn between *a* and *b*. The apex of the space is at *c* and *d*. The space is usually partially or completely divided by a septum which extends from the umbilicus above to the apex below. The anterior wall of the space is composed of the sheath of the rectus, its posterior wall, of peritonium. The distance between *a* and *b* averages 14.6 cm. The distance between the umbilicus and *c* averages 8 or 9 cm. The distance between *c* and *d* averages 1.6 cm.

limited by the outer walls of the recti, and with its base directed upward. The skin can be pushed over, but is not gathered up into folds. There is dullness on percussion.

In the course of from nine to twelve days, with the gradual disappearance of the general disturbances, there develops on both sides of the linea alba a firm, elastic tumor below the umbilicus. This, as was pointed out by Heurtaux, is of the size

and form of the urinary bladder. Not infrequently a definite long furrow can be traced downward from the umbilicus. This is the linea alba, which partially or completely divides this space into two parts. Finally, this tumor rises 5 or 6 cm. above the level of the abdominal wall. Under chloroform narcosis the recti muscles can be pushed over the tumor. The fluctuation becomes more and more evident. Fischer, contrary to the observations of others, has never noted spontaneous rupture either outward or into the peritoneal cavity.

Fischer says that in four of the cases, after making the incision, he found that he was dealing with a single abscess cavity, although there are two subumbilical spaces separated from each other by the linea alba. It could very readily happen he decides, that in these cases one portion of the cavity might be infected and the inflammation extend to the opposite side. Fischer, in one case, was able to carry his finger from the first cavity over to the second through an opening, a dividing partition still persisting.

**Differential Diagnosis.**—The differential diagnosis in this group of cases is not always perfectly clear. Fischer mentions the fact that in two cases he found flat epithelial cells in the pus contents. Their presence would be against the existence of a subumbilical abscess. Where flat epithelial cells are found in such an abscess the inflammatory process is usually of urachal origin. This group is a very characteristic one, and is described on page 567.

#### ABSCESSES BREAKING THROUGH INTO THE SUBUMBILICAL SPACE.

Fischer, after describing the subumbilical space, records three cases in which a purulent accumulation from distant points found its way into the subumbilical space. One was an empyema, another a liver abscess, and the third an appendix abscess. In each of these cases the subumbilical space was involved secondarily.

##### AN EMPYEMA OPENING INTO THE SUBUMBILICAL SPACE.

Fischer, on page 535, mentions the case of a Russian girl, eight years of age, who had a left-sided empyema which reached as high as the scapula. In addition there was a fluctuating, egg-shaped tumor below the umbilicus, and to the left of the linea alba. When the patient coughed, this swelling increased in size at the subumbilical space. Fischer resected several ribs and found that water would flow through the entire space as far as the umbilicus. The child finally recovered. In this case there was a fistulous opening from the pleural cavity downward to the subumbilical space.

##### A LIVER ABSCESS OPENING INTO THE SUBUMBILICAL SPACE.

Fischer and Biermer, in 1876, treated a patient suffering from liver abscess, which, however, gave no characteristic symptoms. The patient was twenty-seven years of age. There was a history of injury, followed some time later by an irregular fever. The liver dulness was increased. Six months after the injury, when Fischer saw the patient, there was an oval tumor to the right of and below the umbilicus, with the base directed upward and the apex downward. The tumor was soft and fluctuating and increased in size when the patient coughed. On pressure it could be made smaller. It was 8 cm. in length and 9 cm. in its greatest breadth. It was incised, and there escaped a yellowish-tinged, foul-smelling pus in which liver substance could be detected. The abscess cavity had the size and form of a subumbilical

space. As the fever persisted Fischer made an incision parallel to the margins of the ribs, and opened into a large retroperitoneal abscess which had been shut off on all sides. From this an opening extended downward into the subumbilical space. The patient improved slowly and gradually recovered.

#### AN APPENDIX ABSCESS OPENING INTO THE SUBUMBILICAL SPACE.

Fischer says that an appendix abscess occasionally opens into the subumbilical space. On page 536 he reports the case of a woman, twenty-seven years of age, who came to the Breslau clinic on account of a fecal fistula below and to the right of the umbilicus. Ten months previously she had had severe abdominal pain, vomiting, and obstruction. After six weeks of much suffering an egg-shaped tumor had developed and a fistula had followed. First there had escaped foul-smelling pus and then fecal matter. On splitting the abdominal walls Fischer noticed a cavity lined with granulations. The abscess in position, form, and size corresponded exactly with the subumbilical space. In its posterior wall in the lower and outer angle was a fecal fistula which had arisen from an ulcerated vermiform appendix. In its lumen was a cherry-stone. After removal of the stone, resection of the appendix, and cureting of the abscess cavity, healing took place.

#### AN ECHINOCOCCUS CYST IN THE SUBUMBILICAL SPACE.

This condition is evidently rare, as I have found but one case recorded. Fischer said that he operated on a man, thirty-two years of age, in whom a fluctuating, smooth, painless, immovable tumor, the size of a fist, had developed beneath and to right of the umbilicus, near the median line. It had been noted for six years. The patient during this time had often vomited, but otherwise had been healthy. For three weeks the tumor had been painful and increasing in size. Fever had been present, and the skin had become reddened and edematous. In size, form, and position the tumor corresponded with the subumbilical space. Fischer made an incision at the outer wall of the rectus and into the subumbilical space. There was a densely adherent echinococcus sac, which could not be extirpated on account of firm adhesions binding it to the peritoneum. It was split, scraped out, and packed. The patient made a good recovery and remained apparently well.

#### ACTINOMYCOSIS IN THE SUBUMBILICAL SPACE.

Fischer furnishes the only record of such a case that I am familiar with. The patient was a man in whom an actinomycotic infiltration was noted as a firm, circumscribed tumor the size of an apple in the subumbilical space. It gave the patient little discomfort. The skin was movable over the tumor and was not altered. At first there was no fever. Later, at intervals, there appeared an inflammatory but painless swelling. Four months after the patient first noticed his trouble, edema developed, and there were thickening and reddening over the tumor, which broke through the skin at several points. The escaping pus contained a few actinomycotic bodies. On the third day feces escaped. The fistulæ lay below the umbilicus, one on each side of the linea alba, and communicated with each other. In attempting an extirpation and clearing-out of the sinuses, Fischer found a

sieve-like fistula representing the points at which the intestine had broken through. The patient died fourteen days after the operation.

**R é s u m é .** — From the foregoing it is clearly evident that below the umbilicus there is a definite, heart-shaped cavity—the subumbilical space—about 8 cm. in length and 14 cm. broad. This is situated between the peritoneum and the sheaths of the muscles. It is often divided longitudinally into two cavities by the *linea alba*, which forms a septum between the muscle-sheath in front and the peritoneum behind. This subperitoneal space can be definitely outlined by injection methods.

There is no doubt that subumbilical abscesses can develop. The symptoms in the early stages strongly suggest a peritonitis; later the general abdominal symptoms subside, and a localized tumor can be detected just below the umbilicus. When opened, the abscess is found to lie between the muscle-sheath and the peritoneum. Usually the septum between the two sacs disappears, leaving only one abscess cavity.

Whether all the hitherto reported cases were really abscesses in the subumbilical spaces or not is problematical. Those cases in which epithelial elements were detected probably represented abscesses resulting from infection of remnants of the *urachus*.

That the subumbilical space may be secondarily involved seems to be clearly shown by the cases of empyema and liver abscess reported by Fischer. The possible presence of *echinococcus* cysts and *actinomycosis* in the subumbilical space is proved by the cases above described.

**T r e a t m e n t .** — As soon as these abscesses are diagnosed, they should be opened and drained. Not much force should be used in the packing, as the posterior wall of the abscess consists merely of the thickened peritoneum. Recovery promptly follows evacuation of the pus.

## CHAPTER XVII.

### PAGET'S DISEASE OF THE UMBILICUS.

Fox and MacLeod's case.

Milligan's case.

The results with radium in a case of Paget's disease of the umbilicus.

Eczema of the umbilicus.

THE first case of this character found in the literature is that recorded by Fox and MacLeod and published in 1904. In 1911, W. A. Milligan reported a case. As the condition is very rare, these cases will be cited here somewhat in detail.

A Case of Paget's Disease of the Umbilicus.\*—The patient under consideration appeared before the Dermatological Society of London on November 13, 1901, and a microscopic section of a portion of the diseased tissue was demonstrated. At the meeting of the society on March 12, 1902, further microscopic specimens were exhibited, confirming the diagnosis of Paget's disease. The following detailed account is given by Fox and MacLeod:

"The patient, a seafaring man of sixty-five years, came under the care of Mr. W. Turner, surgeon to the Dreadnought Hospital at Greenwich, and assistant surgeon to the Westminster Hospital. The man possessed a good constitution, and there was nothing of moment to note in his personal history, and no family history of cancer. In the umbilical region was a rounded, eczematoid patch of about two inches diameter [Fig. 155] which had gradually been forming for about eleven years, but the applicant had not been much bothered by it, and exact details as to the history of the patch were not forthcoming. The central part of the patch was of a brilliant red color, exulcerated, and exuding serum, but silvered over in spots with epithelium. This raw center passed peripherally into a well-marked, raised, smooth, broad border, which terminated abruptly, and over which the cuticle was intact. The whole of the patch felt considerably infiltrated.

"Mr. Turner was struck by the objective features of the patch, and by its chronicity and steady eccentric progression. The man was under treatment for a considerable time, and as the patch proved quite intractable to all treatment tried short of destruction or removal, Mr. Turner very kindly brought the patient to the Skin Department of the Westminster Hospital, with the suggestion that the case was one of Paget's disease. Histologic examination after a biopsy confirmed the diagnosis, and thereupon Mr. Turner removed the diseased skin, and was kind enough to hand it to us for investigation and to allow us to record the case.

"Histologic Changes Present in the Case.—As the whole of the diseased patch was excised, an abundance of material was obtained for purposes of histologic examination. A quadrant of the excised tissue was cut out, and from this, longitudinal sections were made. As a reference to the above clinical description will show, the patch was roughly circular and had a clearly defined

\* Fox and MacLeod: Brit. Jour. Dermatol., 1904, xvi, 41.



raised border and an excoriated central portion. The sections of the quadrant thus included the border and the healthy tissue outside it and a portion of the central excoriated area. These sections were about an inch in length. The tissue was fixed and hardened in alcohol, embedded, and cut in paraffin, and the sections were stained with various dyes, such as borax-methylene-blue, polychrome-methylene-blue, safranin, and water-blue, to demonstrate the finer structure of the cells of the epidermis, the pseudococcidia, and the cellular and fibrous elements of the corium.

"1. Changes in the Epidermis.—With the low power the epidermis of the outer extremity of the section showed a slight proliferation in a downward direction by a regular elongation and widening of the interpapillary processes and a rounding of their extremities. This proliferation became very much more pronounced in the middle third of the section, which corresponded to the raised edge. Here the processes had become twice the length of those in the outer third, and were far more irregular in their shape and width. Some were clubbed at the extremities, others broad and rounded, and a few were conic and tapered. Here and there, owing to the obliquity of the section of the ridge-net system, the familiar appearance of irregular islands of the corium situated in the epidermis was produced. But in spite of the irregularity in shape and size of these interpapillary processes, they all ended at about the same level in the corium, and did not spread down irregularly into it as in condyloma and epithelioma. In the outer two-thirds of the section the epidermis had an imperfect stratum corneum, which showed a tendency to desquamate and was unusually thin. Here and there it extended down in small plugs or formed concentric horny pearls where a depression existed on the surface. The basal layer was present in this situation, and although it was not perfectly regular, still it remained unbroken. The epidermis did not stain regularly, and the lower ends of the processes especially stained faintly as if they were edematous. Irregular spaces were present in the Malpighian layer, but the interepithelial lymphatics were not uniformly distended with edematous fluid as they are in psoriasis and eczema. Another peculiar feature of the epidermis noticeable with the low power was the presence in it of a number of darkly stained, more or less rounded bodies, some of which were several times larger than a prickle-cell. These were irregularly distributed in the epidermis, some being situated superficially near the horny layer, others deep down toward the basal layer, but the majority being in about the middle of the epidermis. These were arranged singly or in clusters, and occasionally they were grouped together in a concentric manner, forming variously shaped figures. They were situated among the prickle-cells, and only a few of them could be detected at the edges or lying free in the irregular spaces already referred to. These rounded structures are the "coccidia" of Darier and Wickham.

"Toward the middle of the section the ordinary epidermis stopped abruptly, and was replaced by a single layer of columnar epithelium, which extended over the surface and dipped down at intervals to form a lining for a number of glands similar in appearance to Lieberkühn's follicles of the small intestine. These follicles extended down into the underlying fibrous stroma, and some of them reached to a lower level than the longest interpapillary process. This showed that in this case a portion of Meckel's diverticulum had been included in the umbilicus, an occurrence which occasionally takes place. A reference to [Fig. 156] will serve to show the general appearance of the section as seen under a low power. Only a portion (about

three-fifths) of the section is there depicted, the outer fifth and inner fifth being left out in the drawing.

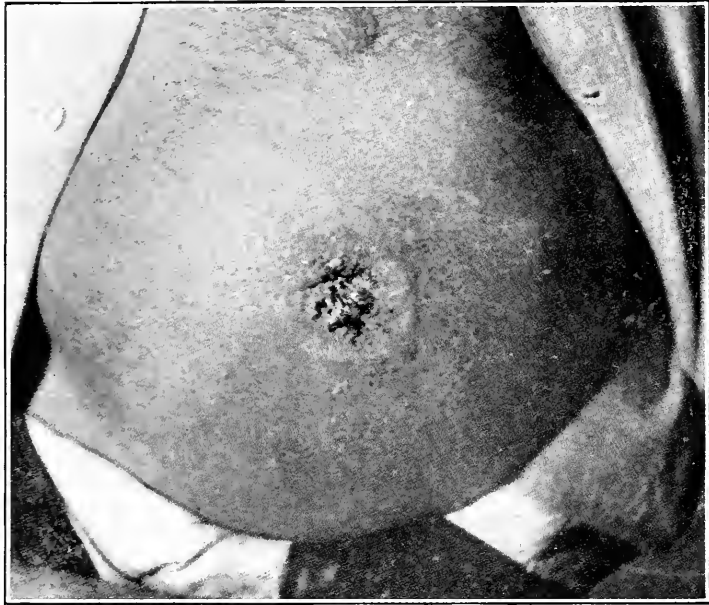

FIG. 155.—PAGET'S DISEASE OF THE UMBILICUS. (After Fox and MacLeod.)

The umbilicus as such is not recognizable, but its site presents a somewhat worm-eaten appearance. For the histologic picture see Figs. 156 and 157.



FIG. 156.—PAGET'S DISEASE OF THE UMBILICUS. HISTOLOGIC APPEARANCES IN FIG. 155. (After Fox and MacLeod.)

Drawing of the central three-fifths of one of the longitudinal sections referred to in the text. It shows the raised border and the central mucous portion. *a*, Imperfect stratum corneum; *b*, proliferating epidermis; *c*, small cornified cell-nest; *e*, columnar epithelium lining the surface, the remains of Meckel's diverticulum; *f*, tubular glands lined with columnar epithelium; *g*, dense infiltration, consisting chiefly of plasma-cells; *h*, dilated blood-vessel. [This has been reduced so much in size that the finer details are lacking.—T. S. C.]

“With the high power (Oc. iv, Obj.  $\frac{1}{12}$ , Oil imm., Leitz) the explanation of the peculiar changes in the epidermal cells already referred to was apparent. Even at the outer margin of the section, but far more marked toward the center, the prickle-

cells at the lower parts of the interpapillary processes were found to be swollen, their protoplasm faintly stained, and their nuclei frequently situated in spaces within the cells. The cells were evidently edematous, and though toward the surface they stained more naturally, yet the edema was still present sufficiently to interfere with the process of cornification, and there were scarcely any cells in the position of the granular layer in which even a trace of keratohyalin could be detected. The stratum lucidum was also absent, and the horny layer was unusually thin and tended to desquamate. The cornification thus took place without the formation of keratohyalin, as it does in the red portion of the lips [Fig. 157]. In spite of the edema of the cells, however, a number of nuclei in the process of

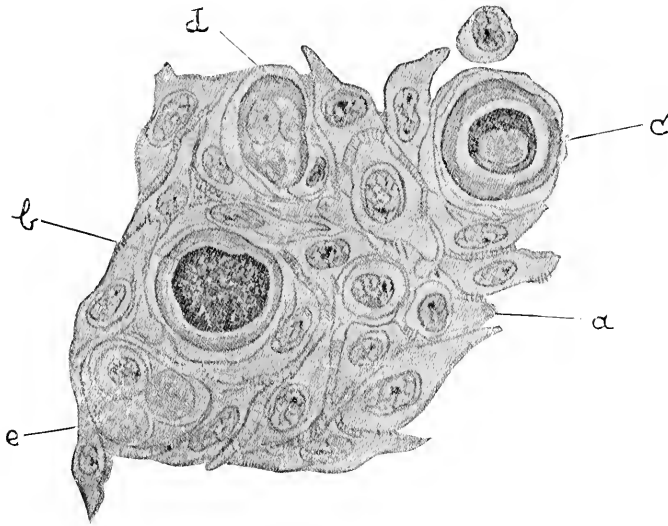


FIG. 157.—PAGET'S DISEASE OF THE UMBILICUS. (After Fox and MacLeod.)

Drawing of a portion of the epidermis with the raised border of the umbilical growth seen in Fig. 155. *a*, Prickle-cells; *b*, edematous cell, partially cornified and globular, prickles lost, protoplasm homogeneous, granular center through degeneration of the nucleus; cell much swollen; *c*, cell similarly affected with edema, and showing a hardened ectoplasm with an edematous nucleus; *d*, multinuclear edematous cell; *e*, multinuclear edematous cells; one of the nuclei has become surrounded with protoplasm, forming a round cell.

karyokinesis were observed, and the cells of the basal layer and those immediately above it showed numerous mitotic figures.

“The interepithelial edema was not pronounced in the middle and upper portion of the epidermis, though here and there it was sufficient in degree to allow of leukocytes making their way between the cells toward the basal layer. Wide, irregular spaces were present, in which were deformed prickle-cells, leukocytes, and debris. A number of prickle-cells were found to have lost their fibrillary skeleton, the spongioplasm and its continuations into interepithelial fibrils had disappeared, and the protoplasm had become homogeneous. In this way the cells had assumed a globular appearance. Many of these cells lying immediately beneath the stratum corneum had become surrounded by a hardened, probably keratinized, covering.

“Several types of these degenerated cells were formed in this way, and these were variously grouped, *e. g.*:

“(a) Round, swollen cells with a finely granular, almost homogeneous proto-

plasm, and a darkly stained nucleus lying in a space or surrounded by a halo of fluid protoplasm, which stained faintly.

“These nuclei had chromatin bodies and a good intranuclear network.

“(b) Round or oval cells with a faintly stained nucleus, but a more defined and darkly colored ectoplasm, which stained similarly to that of the cells of the stratum corneum. These cells had a slight resemblance to coccidia.

“(c) Cells in which, in spite of the edema, an active nuclear division had taken place, but in which the division of the protoplasm of the cell had not kept pace with that of the nuclei, and so multinucleated cells containing several oval, faintly stained nuclei had been produced.

“(d) Groups of cells in which the nuclei had become flattened and crescentic in form, and a great variety of shapes had resulted. It is unnecessary to describe in detail these different groups and figures. Occasionally a leukocyte had become impacted in such a group and further complicated it.

“The single cells, or ‘pseudococcidia,’ could be demonstrated by any of the ordinary stains, such as methylene-blue, hematoxylin, and picric acid (Banti), but the most satisfactory specimens of them were obtained by staining the protoplasm of the cell with water-blue and the nuclei with safranin.

“The columnar epithelial cells lining the surface of the central portion and the follicles which dipped down from it were seen under the high power to be very regular in shape, and to have oval nuclei situated near the base of the cell. These cells appeared to be perfectly healthy, and showed no evidence of edema or other degenerative process.

“2. Changes in the Corium.—The most noticeable feature in the corium when examined under the low power was a dense sheet of cellular infiltration, which occupied the papillary and subpapillary layers and the upper portion of the reticular layer. This infiltration was densest in the middle third of the section, especially where the raised border existed, and in this situation it was peculiarly diffuse and ended abruptly below in an almost straight line. It was not quite so dense in the papillæ, and about the blood-capillaries the cells tended to be collected in foci. At the outer end of the section it was less diffuse, and was arranged in foci around the papillary and subpapillary blood-vessels, while in the center, beneath the columnar epithelium, it was also less dense and more irregular, and spread farther down into the underlying stroma.

“With the high power the infiltration was found to consist largely of plasma-cells, with a few leukocytes and connective-tissue nuclei. These plasma-cells were perfect in shape and showed no tendency to special grouping or to form giant-cells. This cellular infiltration was thus more than a simple inflammatory infiltrate, such as is met with in eczema, psoriasis, or any acute inflammatory condition of the skin. It was more closely allied to that which occurs in certain of the ‘infective granulomata,’ such as syphilis and yaws, and suggested a chronic inflammatory process. Unna described it as a singularly pure ‘plasmoma,’ and Karg has likened it to a bulwark against the cancerous invasion.

“The papillæ were edematous and swollen, especially in the middle of the section. The fibrous elements of the corium were affected only in the area of infiltration. There the collagen stained faintly, especially in the edematous papillæ, but showed no basophilic degeneration. The elastin was also affected in that it stained badly, was swollen, and formed an imperfect supporting skeleton.

"The blood-vessels of the papillary and subpapillary layers were much dilated, and there were a few dilated capillaries in the corium beneath the infiltration."

(A brief résumé of the literature of Paget's disease follows.)

"Remarks on the Histology of our Case and Conclusions. — There are several points of interest in connection with the microscopic changes present in our case which, although they can hardly be said to settle this controversy, still are worthy of consideration:

"1. Although the affected epidermis was that of the umbilicus and not the areola of the nipple, still, the changes present in it, the peculiar degenerated prickle-cells, the occurrence of the dense sheet of plasma-cells infiltrating the underlying papillary layer of the corium, in short, the whole histologic architecture, was similar in every detail to that which has been repeatedly described in the typical cases of the disease. These initial peculiar cellular changes in the epidermis, allied somewhat to those which occur in Psorospermosis follicularis vegetans (Darier's disease), could no longer be mistaken for those of chronic eczema or psoriasis, and it is unnecessary to repeat any labored details with regard to the histologic diagnosis from these affections. It would seem that the histologic changes in the epidermis in Paget's disease are characteristic and pathognomonic, whether the affection occurs in the nipple, the umbilicus, or the genitalia.

"2. In this case there was no evidence of definite malignant change in the epidermis. The degree of proliferation was limited, and the basal layer was intact. It has been asserted that the peculiar change of the epidermis is malignant from the first. This does not seem to us to be so any more than that ordinary warts, the warty growth in xeroderma pigmentosum, or pigmented nevi (moles), are malignant from the outset. They may all be described as precancerous lesions of the skin which have a potentiality more or less certain of becoming malignant.

"3. The inclusion of a portion of Meckel's diverticulum in the center of the umbilicus, in this the only case of Paget's disease which has been recorded in that situation, may be a coincidence, but it is a suggestive one. Cases have been recorded in which the cancer grew from the epithelial cells of mucous glands, and, had malignancy supervened, it is possible that it might have taken its origin in the cells lining the follicles in the cut-off portion of gut in the umbilicus. Still, in the sections the columnar epithelium on the surface and lining these follicles seemed perfectly healthy, although the neighboring epidermis was markedly affected."

[The causative factor in Fox and MacLeod's case is clearly evident. From Fig. 156 it will be seen that some of the tubular glands which were similar to those of the small intestine opened directly on the surface, and naturally produced some secretion which would keep the parts moist and tend to irritate them. The nature of the man's occupation favored lack of systematic bathing. During early and middle life nature was able to resist any active cell changes, but when he reached the period at which atypical cell changes are prone to occur, the first symptoms manifested themselves. From the history it is seen that he was fifty-four when this process was first noted, and that it had gradually increased until he came under observation eleven years later.

In the case reported by Milligan, and later by Pinch, the patent urachus was evidently the exciting factor. It is particularly interesting that in both of the recorded cases the cause was a congenital umbilical defect.—T. S. C.]

Paget's Disease of the Umbilicus Cured by the Application of Radium.\* — "Mrs. W., aged thirty-one, came complaining of a smelly discharge from the navel, accompanied by an eruption around the navel. The trouble had begun four years previously, with a smarting pain around the waist and a redness toward the right side of the umbilicus.

"Ordinary remedies were tried, but with no success, the condition steadily getting worse. The patient was then subjected to x-ray treatment—four applications of ten minutes each. This apparently cured it, but very shortly afterward it broke out again. For twelve months or so ordinary remedies were resorted to, but with no result. Again x-ray treatment was tried,—six applications,—but this time it got worse instead of better.

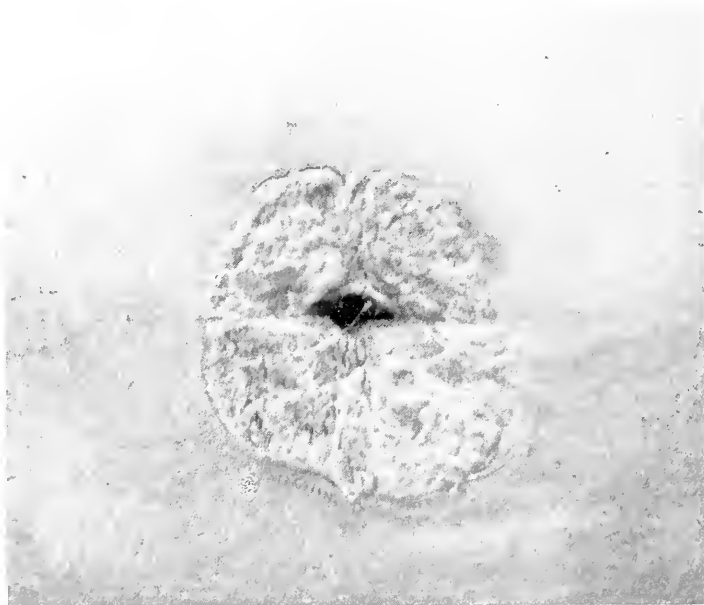


FIG. 158.—PAGET'S DISEASE OF THE UMBILICUS. (After Milligan.)

The small opening in the umbilicus is clearly seen. Surrounding this is a granular, sharply circumscribed, raised area, involving the abdominal wall on all sides. The appearance of the umbilicus after the use of radium is seen in Fig. 159.

"Sir Malcolm Morris saw the patient in consultation about the middle of June last, and he advised either total excision or radium treatment. Accordingly, small doses of radium were applied around the edge of the eruption, which now had a radius of about two inches from the umbilicus. The radium was applied in successive places around the edge, and each place had an exposure of four hours. This certainly had a good effect, although it did not cure it. Finally, on August 21, 1911, at the Radium Institute, the patient had a treatment of 70 mg. of pure radium for one and one-half hours direct on the skin, there being no intervening screen. For ten days nothing was felt by the patient, and then she had a burning sensation around the waist, and the discharge got worse. This lasted for two weeks, and then the skin healed, leaving only a small sore spot on the right side.

"The condition prior to the last application of radium is well shown in the

\* Milligan, W. A.: Proc. Roy. Soc. Med. (Dermat. Section), November, 1911, v, No. 2, 30.

photograph [Fig. 158], and consisted of a raised, indurated edge all around, with a raw weeping surface extending into the umbilicus.

"The condition is now apparently cured [Fig. 159], although there is still some discharge, and the question arises as to whether there may or may not be a patent urachus. This has not been conclusively proved, although at times the discharge has an ammoniacal smell. It is interesting to note the large dose of radium used by Mr. Pinch at the Radium Institute, a dose corresponding to 2,000,000 activities."

Mr. A. E. Hayward Pinch, when referring to the same case, said that a slight

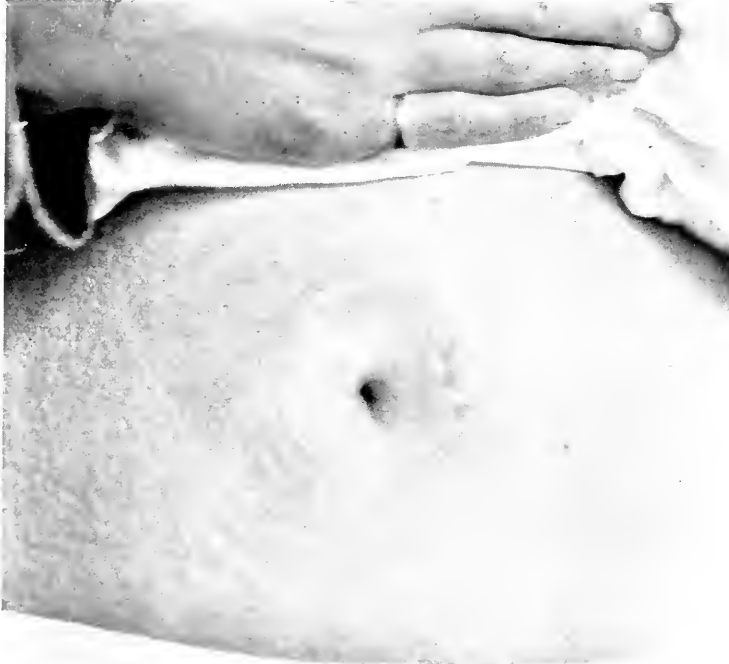

FIG. 159.—THE APPEARANCE IN A CASE OF PAGET'S DISEASE OF THE UMBILICUS AFTER TREATMENT WITH RADIUM.  
(After Milligan.)

The umbilicus is relatively smooth, but somewhat paler than the surrounding tissue. The line of demarcation of the tumor is still clearly evident. The skin around the umbilicus looks normal, but to the (patient's) left there apparently is still a little thickening. For the appearance of the umbilicus before treatment see Fig. 158.

recurrence took place early in September, 1912. The same treatment was adopted, with an equally good result, and the patient since then had remained perfectly well.

Sir Malcolm Morris, chairman of the meeting, said that a case of Paget's disease of the umbilicus was shown years ago before the old society by Mr. Marmaduke Sheild.

In 1912 I wrote Dr. Milligan asking if it would be possible for him to send me photographs of his case, as the reproductions in the Proceedings of the Royal Society were not very satisfactory. Dr. Milligan complied with my request and sent me the photographs here reproduced.

## ECZEMA OF THE UMBILICUS.

This condition is by no means rare, although the literature on the subject is very meager. In the new-born, during the process of cicatrization of the cord, there may be slight irritation of the umbilicus without any evidence of infection. In an adult with a very delicate skin there may be a slight irritation of the umbilicus and some cracking of the skin, notwithstanding the utmost cleanliness and care. This is prone to occur in stout individuals when the weather is excessively warm and the patient perspires a great deal. The most common cause of an eczematous condition around the umbilicus is the existence of an umbilical concretion, which, on account of the contracted condition of the umbilical opening, is frequently overlooked. Cantrell,\* in 1897, and Morris,† in 1895, briefly discussed eczema of the umbilicus. Umbilical concretions are discussed in detail on p. 247.

Recently I saw a mild case of eczema of the umbilicus in consultation with Dr. Frank Sladen in the Johns Hopkins Hospital. The patient was eighteen years old. From time to time there had been an irritating discharge from the umbilicus. On examination I found an eczematous condition in this situation. There was a little depression at the side of the umbilical depression. There was no evidence of a concretion.

\* Cantrell, J. A.: Eczema Umbilici and its Treatment. *Therap. Gaz.*, 1897, xxi, 82.

† Morris, R.: Lectures on Appendicitis and Notes on other Subjects, 1895, 93.



## CHAPTER XVIII.

### DIPHTHERIA OF THE UMBILICUS; SYPHILIS OF THE UMBILICUS; TUBERCULOSIS OF THE UMBILICUS; ATROPHIC TUBERCULID COMMENCING AT THE UMBILICUS.

- Diphtheria of the umbilicus.
  - General consideration.
  - Report of cases.
- Syphilis of the umbilicus, at or shortly after birth.
  - Report of cases.
- Syphilis of the umbilicus in the adult.
  - Report of cases.
- Tuberculosis of the umbilicus.
- Atrophic tuberculid starting at the umbilicus.

IN this chapter are grouped several diseases which are very uncommon and which do not belong to the subjects considered in any other chapter.

#### DIPHTHERIA OF THE UMBILICUS.

We have records of only two cases in which the umbilicus was the seat of a primary diphtheritic deposit. The first case was described by Pitts in 1897, the second by Gertler in 1898. As one might naturally expect, the umbilicus became involved shortly after birth and before the umbilical stump had had time to cicatrize.

Pitts's patient was first seen on the fourteenth day after birth. The child's brother had just died of diphtheria, and its mother was ill with the same disease. Diphtheria bacilli were cultivated from the umbilical lesion. The child died, and at autopsy the diphtheritic deposit was found to be limited to the umbilicus, the respiratory tract being free from membrane.

Gertler's patient first came under observation when he was four weeks old. On the eighth day the cord, which had not come away, was cut off with a pair of scissors and the child was circumcised. When Gertler saw the patient, the umbilicus and the penis presented the characteristic diphtheritic deposits. Both lesions yielded the specific bacillus and promptly healed after the use of antitoxin.

Diphtheria of the Umbilicus.\* — A child, fourteen days old, was admitted for an inflammation of the umbilicus. The cord had separated on the eighth day, and the resulting wound had continued to discharge extremely offensive pus. When seen on February 20th, there was a brawny, red, indurated area around the umbilicus, about the size of a five-shilling piece. From this area the epidermis had peeled off. The umbilicus itself was the seat of a dirty-looking, wash-leather slough, and was discharging offensive pus from an opening into which a probe could be passed for about an inch. The child's general condition was otherwise good. It had, however, an occasional inspiratory crow, and with it some slight cyanosis. The next day it was learned that the brother of the child had been

\* Pitts, B.: The Lancet, London, 1897, i, 953.

removed to a hospital suffering with diphtheria during the previous week, and had died on the morning the child was first examined. The mother had been taken to a hospital also suffering from diphtheria.

A culture from the umbilicus examined on February 22d showed diphtheria bacilli. The child had some vomiting, became weaker, and died on the same day. After death nothing abnormal could be found in the larynx or pharynx, nor had the condition at the umbilicus extended to any of the deeper structures.

*Diphtheria of the Umbilicus.* \* — The umbilical cord had not come away normally, but had been cut off on the eighth day with a pair of scissors and the child had been circumcised. The physician could not tell whether the trouble had started first in the umbilicus or on the penis. The illness had lasted three weeks.

The child, four weeks old, was moderately well developed. In the umbilical region was an infiltration of the skin and underlying tissue, and surrounding it was a sharp line of demarcation which extended downward to the symphysis. Immediately around the umbilicus was a small, grayish-yellow deposit, and when pressure was made over the skin below the umbilicus, purulent fluid escaped.

The penis was swollen, and on the right side of the glans was a flat ulcer, likewise covered with a grayish-yellow, diphtheroid deposit. The inguinal glands on both sides were hard, and the subaxillary glands on the right side were enlarged. The pulse was 96; the temperature, 37.8° C. Cover-slips at once suggested diphtheria, and twenty-four-hour cultures gave a pure Löffler bacillus. The diagnosis of diphtheria of both the penis and the umbilicus was certain. On October 27th the serum was given, and on the following day the temperature was 38.2° C. and the local condition was better. The area of redness, which had extended to the symphysis, had narrowed down to 2.5 cm. around the umbilicus, and the infiltration of the skin was less.

On October 29th the skin infiltration in the umbilical region had disappeared. The skin was drawn up into folds, and a grayish-yellow membrane came away after the use of a 3 per cent. boric acid solution, leaving a superficial ulcer which did not bleed.

By October 30th the swelling in the umbilical region had become slightly smaller, and there was no membrane over the area of ulceration. The ulcer of the penis had dried up entirely.

On October 31st the umbilicus presented the normal appearance, and the ulcer of the penis had healed completely.

#### SYPHILIS OF THE UMBILICUS.

The literature on this subject is very meager, but lues of the umbilicus has been mentioned by Blum (1876), Villar (1886), Runge (1893), Bertherand and Merklen (1900), Hutinel (1903), Bondi (1903), Hartz (1905), and Chiarabba (1906).

Cases of syphilis of the navel are divided into two groups:

1. Syphilis of the umbilicus at or shortly after birth.
2. Syphilis of the umbilicus in the adult.

\* Gertler, N.: Beitrag zu den Krankheiten des Nabels der Neugeborenen. *Klin. therapeut. Wochenschr.*, Wien, 1898, v, 1234.

## SYPHILIS OF THE UMBILICUS AT OR SHORTLY AFTER BIRTH.

Bertherand and Merklen in 1900 drew attention to the fact that in a certain number of children presenting symptoms more or less characteristic of congenital syphilis, such as a purulent coryza, a tendency for the finger-nails to drop off, fissure in ano, etc., ulcerations of the umbilicus existed. They were inclined to think that the umbilical ulceration was part of the syphilitic process. In order that the reader may gain a clear idea of their findings and draw his own conclusions, they will be cited here somewhat fully.

Bertherand and Merklen observed, in the service of Hutinel, a variety of umbilical ulcers and thought these had not been previously mentioned. They state that Professor Hutinel a long time before had said that these infections suggested syphilis. The ulceration was situated at the umbilicus, and appeared shortly after birth. All the patients examined by Bertherand and Merklen were less than one month old. The exact date of the appearance of the ulcer could not be determined, as all the patients were brought to the hospital with the lesion already present. The youngest child was nine days old. An ulceration of this character may reach the size of a five-franc piece. The base of the ulcer is grayish, sometimes yellow, and there is a secretion of mucopus. The ulcer is red, irregular, has raised margins, and one of the cases showed appearances of gangrene. The ulceration may be accompanied by redness of the skin with desquamation, but without any evidence of inflammatory reaction. The authors further say that, of the four children observed, three died of hereditary syphilis, and that the ulceration still persisted at the time of their death. The fourth child survived and the ulceration cicatrized.

C a s e 1. — L. A., nine days old. The child had a purulent coryza which suggested syphilis. There was an ulceration at the umbilicus which had completely obliterated the umbilical depression and extended beyond it. The base of the ulcer was grayish, and covered with a little pus. Around the umbilicus was a little reddening, but only a slight reaction. The child was cachectic, lost weight, and died ten days after entering the hospital. At autopsy nothing of moment was detected in the lungs or in the digestive tract. The brain was normal, but the liver was large and congested, and the spleen was increased in size. The testicles were hard and sclerotic, but on section did not show anything of any moment. A longitudinal section of the femur showed that the bone-marrow was altered, especially in the upper and lower part. The spongy tissue of the bone was yellowish, and showed less color than normal.

[In this case it is possible that syphilis existed, but the history is in no way conclusive. One might very readily think of an ulcer at the umbilicus due to simple infection, possibly associated with syphilis.—T. S. C.]

C a s e 2. — D. E. This child was admitted to the hospital when eleven days old. He had a purulent coryza, a marked fissure at the anus, and erythema of the buttocks. No change was noted in the testicles, and there was no inflammation of the nails. At the umbilicus was an ulcer suggesting gangrene. It was deep, had irregular margins, and discharged a little mucopus. A few days later it had increased in size, become deeper, and was larger than a five-franc piece. The child was cachectic, developed bronchopneumonia, and soon died.

At autopsy evidences of bronchopneumonia were found in both lungs. The liver was red and slightly enlarged, but showed little on section. A longitudinal

section of the left humerus gave a marked discoloration of the bone-marrow at both extremities.

[In this case the coryza and the fissure at the anal margins point to syphilis, but the area of ulceration at the umbilicus and the erythema of the buttocks might equally well have been due to gangrene or simple ulceration of the umbilicus. The case is not clear.—T. S. C.]

CASE 3. — N. S., thirteen days old, was suffering from a purulent coryza. The diagnosis of hereditary syphilis was thought probable from the existence of an umbilical ulcer which was as large as a five-franc piece. The surface of this ulcer was covered with a greenish, clear pus. The margins were a little elevated and desquamated, and they were also red, but showed no induration. There was but little loss of tissue. The child developed an intestinal infection. The general condition became alarming, and the umbilical ulcer increased in size. Nearly a month after the child's admission to the hospital an inflammation of the extremities of the nails of the fingers was noted, and there was a tendency for the nails to become detached. The coryza continued without any new manifestations of syphilis except the inflammation of the nails. The child died a week later of bronchopneumonia.

At autopsy, in addition to the bronchopneumonia, on histologic examination, a periportal sclerosis and an obliterative endarteritis were found. At certain points the obliteration was complete. The small hepatic veins were thickened. The hepatic cells were a little opaque. The left kidney was pale. The right kidney was pale, and there was a tendency to fusion of the cells. At the upper extremity of the kidney was a white, pearly gumma, much paler than the rest of the renal tissue. The convoluted tubules and the loops of Henle were the seat of a degeneration, and the glomeruli were congested. The arteries of the glomeruli showed a slight degree of endarteritis, and some of the arterioles contained thrombi. A section of the superior extremity of the humerus demonstrated that the spongy tissue of the bone was yellowish and less colored than normal.

[In this case the purulent coryza was suggestive of syphilis, but the ulceration might very readily have been due to an ordinary infection. Inflammation of the extremities of the fingers also points toward syphilis. The report says that there was a gumma in the right kidney, but the description of the gumma is not at all conclusive. This is another case in which we cannot say absolutely that the umbilical condition was syphilitic.—T. S. C.]

CASE 4. — C. C., one month old. At the umbilicus was an ulceration the base of which was grayish in color and covered with mucopus. The ulceration was surrounded by a reddish, desquamated zone, which was about the size of a two-franc piece. Two weeks later the child commenced to improve and the ulcer tended to diminish. Shortly afterward the child showed the characteristic purulent coryza, which tended to confirm the idea of hereditary syphilis. The ulcer gradually healed under simple local treatment. The coryza, however, persisted with the same intensity, and the child was sent to the country.

Bertherand and Merklen, in describing these cases, say that the histories showed that they were dealing with hereditary syphilis, causing a variety of ulcers of the umbilicus. The appearance of the lesion, the absence of general reaction, and the coexistence of further signs of syphilis, as coryza, fissure in ano, and inflammation of the nails, and examination of the testicles would permit one, according to their view, to decide in favor of the specific nature of the umbilical ulcer.

Hutinel, in 1903, wrote a very interesting article on the same subject. He said that during the thirteen years in which he had been a physician to the Hôpital des Enfants-Assistés he had observed this peculiar umbilical lesion about a dozen times. From its appearance and mode of development and its anatomic characteristics he attributed the umbilical trouble to hereditary syphilis. His description of the local condition is very similar to that given by Bertherand and Merklen. Appended to his paper are several interesting cases.

C a s e 1 . — Rena M., born January 28, 1902, and admitted to the hospital on February 18th. This child had a purulent coryza, a lorgnette nose, and erythema of the buttocks. The diagnosis of hereditary syphilis seemed certain. Redness and swelling were present, and a phlegmonous appearance, forming a circle around the umbilicus and extending 4 cm. in all directions. This area of tumefaction was not hot nor painful on pressure, and had not the definite margin characteristic of erysipelas; there was no fever. In the center of the area was a small ulcer from which there was a slight discharge. At the end of two days the reddish circle had retracted somewhat, but the ulceration had increased in size and deepened. The surrounding tissue was hard, red, and raised, but there was no fever. The coryza persisted, and the characteristic papules were noted on the buttocks. On the following days the redness around the umbilicus gradually took on a livid tint, and in the center was a crater-like depression, yellowish black and bloody, and several red plaques appeared on the abdomen. On March 3d the umbilical ulcer formed a pit with precipitous margins, and at the bottom the surface was covered with a grayish exudate. The margins were indurated and violet-colored. The area of ulceration was about 1.5 cm. in diameter, and the pit measured 1 to 1.2 cm. in depth. Hutinel says that on March 7th the ulcerated area presented the picture of a gumma. This had increased in size and its base was yellowish in color. Its margins were precipitous, but the peripheral infiltration had diminished and had gradually lost its phlegmonous aspect. On March 10th the area of ulceration still retained its principal characteristics; the base, however, was enlarged, and the cutaneous orifice had diminished in size.

On March 14th the temperature, which had been absolutely normal, reached 38.2° C., the respirations became accelerated, and the child was very restless. A bronchopneumonia was evident. Death occurred on the following day. At autopsy the peritoneum at the umbilicus was found to be normal. In the angle formed by the urachus and the umbilical arteries there was a yellowish nodule. In a transverse section of the abdominal wall this was found to be 1.4 to 1.5 cm. in thickness at the site of the umbilical ulcer. The abdominal muscles on the right, in the vicinity of the ulcer, were pale and scarcely recognizable, and the subperitoneal connective tissue was thickened and presented a hyaline appearance. The peritoneum did not contain any liquid, and there were no omental or intestinal adhesions. Bronchopneumonia was the cause of death.

From a transverse section through the center of the umbilical cicatrix it was found that the floor of the ulcer consisted of a granular substance which resisted the action of the staining fluid. In the interval between elastic fibers could be recognized remains of leukocytes, and beneath this zone, where the necrosis had been less complete, there was an infiltration of round cells, and sometimes a few leukocytes which stained poorly. In the middle of the area the arterioles appeared thickened, and in some places had been completely obliterated; there existed an

endarteritis and sometimes a peri-arteritis. In some places the infiltration had invaded the adipose tissue.

[The general picture in this case strongly suggests a mild umbilical infection. The histologic picture also is suggestive of the same thing. While one cannot say positively that syphilis did not exist, the evidence in favor of it is not particularly strong.—T. S. C.]

C a s e 5 . — On p. 90 Hutinel reports the case of a small girl, S. P., eight weeks old. She was born on March 9, 1903, and admitted to the hospital on May 5, 1903. An examination of this child was made by Budin. The labor had been normal; but the father of the child had manifested symptoms of syphilis and appeared to have tuberculosis. The child at birth weighed 3600 grams. On March 11th, after the expulsion of meconium, the child's weight dropped to 3400 gm., but by March 15th it had risen to 3650 gm. On March 20th, when the mother left the clinic, the child had not gained a gram in weight, and it was noted that the umbilicus was diseased. It was red and raised, and a superficial ulcer was noted above and to the right. The child had coryza. Sublimate baths were prescribed, and the umbilical ulcer was painted with iodine, and afterwards with silver nitrate; in addition, the child was given mercurial frictions. She remained in the clinic until April 30th, when the area of ulceration appeared to be healing. It did not heal, however, and on May 5th, when the child was brought for examination, the ulcer was found to be large and deep. The mother said that from the beginning the umbilicus was swollen and red over an area the size of a five-franc piece, and that it had become eaten out and had suppurated, after which the redness had disappeared. The swelling had been replaced by a depression, and there had remained at the umbilicus a triangular ulcer. The margins of the ulcer were sharply defined, the skin was red around the orifice, and a pinkish, serous fluid escaped. The child was very pale and had a yellowish, waxy tint that led one to suspect syphilis. The head was large, the nose lorgnette-shaped. There were no fissures of the lips and no inflammation of the nails. There was an erysipelas of the legs and arms and some papules on the buttocks. The epiphyses were a little enlarged, but there was no bone malformation. There was some thickening of the cranial bones. The liver was slightly enlarged, and the spleen was somewhat increased in size. On May 9th the umbilical ulcer, which had resisted treatment for six weeks, contracted and tended to disappear. Hutinel says that the fact that syphilis existed in this case is undeniable, and that the mother, on May 22d, presented in the throat a very characteristic papulo-erosive syphilitic eruption.

Some of the cases reported by Bertherand and Merklen and by Hutinel were in all probability instances of congenital syphilis, but whether the umbilical lesions were directly caused by the spirochete or not is another question. Runge, in speaking of wound infections of the new-born, said that when the syphilitic manifestations make their appearance at birth, usually in premature children, these children are born dead, die almost immediately, or live only a few hours, rarely a day. He further says that, in addition to the usual syphilitic changes in these cases, there are numerous hemorrhages under the skin and in the internal organs.

Bondi says the diagnosis of hereditary syphilis in the new-born is very difficult. He covers the literature well, gives a large number of cases, and also presents some excellent pictures. His conclusion is excellent: "There were present the exudate with an inflammatory appearance, the edematous infiltration of the vessel-

walls, with migration of polymorphonuclear leukocytes, and in one case a pouring-out of fibrin and in two cases abscess-like formations in the vessel-walls, and sometimes necroses. In one case there was a deposit of chalk." He says that the changes are due to an arteritis and phlebitis; that the picture presented is not specific or characteristic, but the changes described have been those observed only in syphilis, and that, in the absence of proof to the contrary, we can with a moderate degree of certainty describe these as the pathologic findings in syphilis.

The umbilical pictures presented by the cases here recorded are so similar to those due to the umbilical infection formerly so frequent shortly after birth that, anatomically, they show little or no difference; and even the histologic pictures of these supposedly syphilitic lesions of the umbilicus are by no means conclusive. If syphilis existed in these cases, the lowered vitality of the child would naturally render it more susceptible to any umbilical infection. While our knowledge of this subject is meager, careful examinations of umbilical ulcers for the *Spirochæta pallida* will, in the future, speedily determine whether these ulcerations are syphilitic or not.

#### SYPHILIS OF THE UMBILICUS IN THE ADULT.

Blum, in his article on Tumors of the Umbilicus in the Adult, published in 1876, when speaking of syphilis, mentions the case of a man, aged thirty-six, who had a fetid discharge from the umbilicus for two years. The umbilicus was prominent and formed a tumor. Its margins were swollen and possibly slightly ulcerated. Dupuytren considered the probability of a fecal fistula, but Breschet, who had seen several analogous cases, prescribed a specific treatment, and the patient was cured. From the clinical picture this case might equally well have been one of umbilical concretion, particularly if any local treatment was given.

Rille, in 1912, collected eight cases of primary syphilis of the umbilicus, and in 1914 referred to three others. In the latter article he shows the picture of a lesion in a young girl coming under the care of Lassar. At the umbilicus was an elongated, oval ulcer the size of a five-pfennig piece. The ulcer was deep, and its surface brownish red and glistening. Its margins were sharply defined and infiltrated. Surrounding the ulcer was a pale red, inflammatory zone.

The following case, observed by Fiaschi, was so carefully studied that I shall report it in detail:

*Syphilitic Chancre of the Umbilicus.*—In 1911 I received the following from Dr. P. Fiaschi, of Sydney, Australia:

"178 PHILLIP ST., SYDNEY, AUSTRALIA, March 14, 1911.

... "As you are busy with your paper on the umbilicus, I thought you might like the following: Some three weeks ago I found a young man with a chancre of the inner aspect of the right lower quadrant of the prepuce and a chancre of the umbilicus (Fig. 160). He gave a history of an incubation of fourteen and seventeen days.

"I may say that my father concurred in the diagnosis of genital and extragenital primitive infection of the young man. The ultramicroscopic examination gave me one of the finest specimens of spirochetes I have managed to get from any lesion in any case I have examined so far. Inasmuch as you are interested in this work, you might look up the classic monograph of our distinguished master, M. Le Professeur Fournier. You will find the report on page 284 and subsequent pages. Fournier, in a personal observation of 110 extragenital chancroids, in a total of 10,000 chancres that he has observed in private practice, found only 16 of the abdomen. They are evidently not common.

“The result of the injection of salvarsan was very striking. Both lesions had cicatrized in five days, so that even after vigorously using an ophthalmic curet I could not get any spirochetes.”

On May 25, 1911, Dr. Fiaschi writes:

“The young man took it into his head, after seeing his lesions healed, to leave this city and go to a country town, telling me that he knew he was cured, judging by the reports that he had read in magazines and newspapers. He did this notwithstanding my remonstrations not to fool himself, but to place himself under the usual methodic mercurial treatment. I wanted to present him to a clinical meeting of our local medical society, and I wrote him to come to Sydney, and he did so the day before the meeting. On presenting himself I found that both lesions had

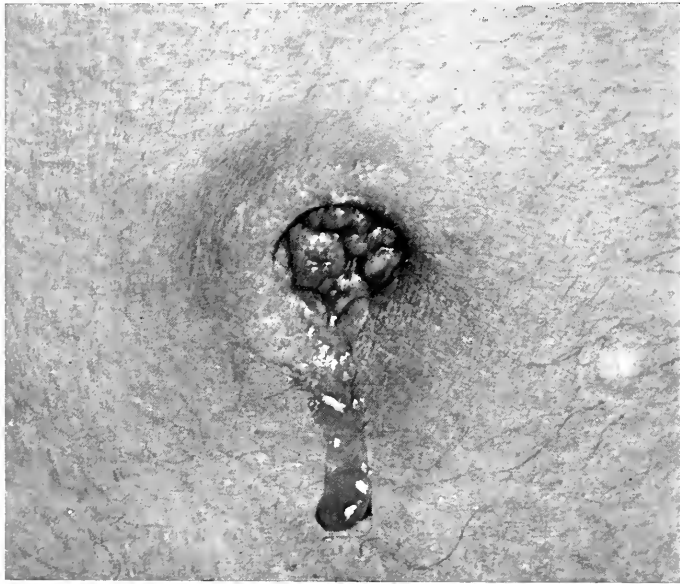

FIG. 160.—SYPHILIS OF THE UMBILICUS. (Fiaschi.)

The umbilical depression is filled with dome-like elevations of various sizes, and trickling from the umbilical orifice is a watery discharge. Spirochetes were obtained from the umbilicus and also from a chancre of the prepuce. Both lesions yielded promptly to salvarsan. The patient did not keep up the necessary treatment, and returned two months later with a mucous patch on the upper lip.

remained healed, but that he had a mucous patch on the upper lip, the size of a nickel, from which I obtained numerous spirochetes under the ultramicroscope, of the giant form, such as are frequently found in mucous patches. I had this mucous patch photographed, and am pleased to write you that I am now mailing you, under registered cover, four photographs, two of the chancre and one showing the result five days after intramuscular injection of salvarsan, and the fourth showing the relapse with mucous patch. The young man told me that he had noticed this two weeks before seeing me.”

#### LITERATURE CONSULTED ON SYPHILIS OF THE UMBILICUS.

- Bertherand et Merklen: Sur une variété d'ulcération ombilicale de nature sypilitique. Bull. de la Soc. de pédi. de Paris, 1900, ii, 248.  
 Blum, A.: Tumeurs de l'ombilic chez l'adulte. Arch. gén. de méd., Paris, 1876, vi. sér., xxviii, 151.



- Bondi, Josef: Die syphilitischen Veränderungen der Nabelschnur. Arch. f. Gyn., 1903, lxi, 223.
- Chiarabba, U.: Contributo alla Conoscenza della sifilide ombelicale (Flebite proliferativa gommosa della vena ombelicale). Annali di ostetricia e ginecologia, 1906, Anno 28, i, 190.
- Fiaschi, P.: Personal communication.
- Fournier, A.: Les chancres extra-génitaux, Paris, 1897, 326.
- Hartz, A.: Abnabelung und Nabelkrankung. Monatschr. f. Geb. u. Gyn., 1905, xxii, 77.
- Hutinel, V.: L'ulcère syphilitique de l'ombilic chez les nouveau-nés. La Syphilis, Paris, 1903, i, 81.
- Pernice, Ludwig: Die Nabelgeschwülste, Halle, 1892.
- Rille: Ueber den syphilitischen Primäraffekt am Nabel. Festschr. f. E. Lesser, Arch. f. Derm., 1912, cxiii, 865.—Ein weiterer Beitrag zur Kenntnis des syphilitischen Primäraffektes am Nabel. Dermatol. Wochenschr., 1914, lix, 1271.
- Runge: Die Wundinfektionskrankheiten der Neugeborenen. Die Krankheiten der ersten Lebensstage, 2. Aufl., 1893, 194.

### TUBERCULOSIS OF THE UMBILICUS.

Bouffleur,\* in 1898, reported a supposed case of tuberculosis of the umbilicus. The patient had been complaining only for ten days. He first had cramp-like pains in the abdomen, followed three days later by a discharge from the umbilicus with tenderness and soreness in the umbilical region. The discomfort was so marked that he had to stop work.

Several sisters had died of tuberculosis, but the patient, apart from repeated chancreoid infections and an occasional attack of colicky pain followed by diarrhea, after drinking beer, had been perfectly well.

On examination a purulent discharge was noted at the umbilicus, and to the right and below the umbilicus was a slight swelling, apparently situated in the deeper part of the abdominal wall. The purulent tract was enlarged, and with a curet over an ounce of typical tuberculous granular tissue was removed. A cavity the size of a walnut, internal to the abdominal wall, was exposed. It was packed with iodoform gauze. Some of the smears yielded large numbers of tubercle bacilli; others contained none.

Bouffleur asks whether this was a case of tuberculosis of a blind urachus or of Meckel's diverticulum.

[The clinical picture is strongly suggestive of a soft umbilical concretion.—T. S. C.]

In 1911, in the course of a conversation with Dr. A. L. Stavely, of Washington, he referred to an interesting case which had come under his observation. On March 26, 1904, he sent the specimen to Dr. J. R. Mohler, of the Bureau of Animal Industry, who, in reply to an inquiry from me, reported as follows:

“Slides were prepared which showed numerous tubercle bacilli with the Ziehl-Nielsen stain. Two guinea-pigs were inoculated with the material, and both developed tuberculosis.

“No sections of the umbilicus were made, but we still have slides prepared from the pus in the fistulous tract, which show the presence of tubercle bacilli, somewhat faded as a result of nine years' preservation.”

Tuberculosis of the umbilicus is, to say the least, exceedingly rare. One might expect occasionally to find it in those rare cases in which a tuberculous bowe becomes adherent to and opens through the umbilicus.

\* Bouffleur, Albert I.: Tuberculosis of the Umbilicus. Clin. Rev., Chicago, 1898, ix, 329.

## A CASE OF ATROPHIC TUBERCULID.\*

The patient was a boy, aged twelve, who had been under Bunch's care for five years at the Queen's Hospital for Children, and before that under Dr. Adamson's care at the same hospital. The latter had shown him before the Dermatological Society of London on May 9, 1906. The eruption had begun, when the child was aged four, as a single red patch at the navel, on which small red nodules had developed later. The nodules were slightly raised, somewhat papular in character, and distinctly infiltrated. They had a tendency to necrose, and always left a superficial, shallow scar about  $\frac{1}{8}$  inch to  $\frac{1}{3}$  inch in diameter.

In 1906 there were about 30 such scars around the umbilicus, and scattered



FIG. 161.—ATROPHIC TUBERCULID STARTING AT THE UMBILICUS. (After J. L. Bunch.)

Scattered over the lower abdomen and right thigh and over the region of the right shoulder are elevations, oval or round in form. They were first noted at the umbilicus.

among these were about a dozen raised red papules, ranging in size from a millet-seed to a split-pea. During the succeeding years similar necrotic papules had made their appearance in the inguinal region, on the thighs, on the upper part of the buttocks, in front of and behind both axillæ, and on the shoulders and back (Fig. 161).

Attention was called to the fact that the nodules and scars were always preceded by a circumscribed, irregular, dry, scaly, red dermatitis, such as had been described in 1906 for the inner side of the thigh and arm, where there were now the characteristic scars. Similar appearances had preceded the atrophic tuberculid elsewhere, and there was now a very well-marked patch of such a dermatitis on the right shoulder, which probably denoted the appearance of the nodular eruption within the next year or two.

\* Bunch, J. L.: Proc. Roy. Soc. Med. (Dermatological Section), November, 1911, v, 21.

## CHAPTER XIX.

### THE ESCAPE OF RETROPERITONEAL AND ABDOMINAL FLUID FROM THE UMBILICUS; THE OPENING OF AN APPENDIX ABSCESS AT THE UMBILICUS; ABSCESS OF THE LIVER OPENING AT THE UMBILICUS; PERITONITIS WITH THE ESCAPE OF PUS FROM THE UMBILICUS; THE PIECEMEAL REMOVAL OF A SUPPURATING OVARIAN CYST THROUGH THE UMBILICUS.

The escape of retroperitoneal fluid from the umbilicus.

A prostatic abscess opening at the umbilicus.

A thoracic abscess opening at the umbilicus; report of cases.

A broad-ligament abscess opening at the umbilicus.

Cases of broad-ligament abscess opening at or near the umbilicus.

An abscess of the umbilical vein in an adult.

The opening of an appendix abscess at the umbilicus.

Abscess of the liver opening at the umbilicus.

Peritonitis with the escape of pus at the umbilicus, clinical picture; causes of the peritonitis; differential diagnosis; report of cases.

The piecemeal removal of a suppurating ovarian cyst through the umbilicus.

Localized jaundice of the umbilicus with the presence of free bile in the abdominal cavity.

#### THE ESCAPE OF RETROPERITONEAL FLUID FROM THE UMBILICUS.

AN effusion of fluid into the retroperitoneal tissue will tend to loosen up the peritoneum from the underlying adipose or muscular tissue by a process of dissection, the process gradually extending for quite a distance. For example, in February, 1912, I saw with Drs. Smouse, Fay, and Priestley, in Des Moines, Iowa, a patient giving the history of the sudden development of a more or less globular tumor to the left of and above the umbilicus. The man passed into a state of collapse and was thought to be dying. A few days later his condition was much improved, and an exploratory abdominal operation was deemed advisable. On opening the abdomen I could palpate a mass, about 10 cm. in diameter, in the region of the pancreas. The peritoneum of the right abdominal wall was bluish in color, and the mesoecum much thickened. I at once closed the abdomen and made a gridiron incision in the right iliac fossa, pushing the peritoneum toward the median line. The discoloration of the peritoneum was due to the action of old blood which had dissected this membrane from the underlying structures. As I passed my fingers upward toward the right renal pocket I found that between the peritoneum and the lateral abdominal wall there was a space, fully 2 cm. broad, which was filled with clotted blood. Surrounding the right kidney there was also a very large blood-clot. A drain was laid in the pelvis and in the right renal pocket, care being taken not to dislodge the clots. The man did well for over a week and then died suddenly.

At autopsy an aneurysm of the abdominal aorta was found (Fig. 162). This had perforated posteriorly and on the left side, producing the tumor that had suddenly appeared on the left of the median line. This blood had gradually passed over the vertebral column and gradually dissected free the peritoneum on the right

side of the abdomen, a fact which accounted for the disappearance of the tumor on the left. The sudden death had been due to rupture of the aneurysm into the duodenum. Careful examination at autopsy showed that the peritoneum on the right lateral abdominal wall, as a result of the hemorrhage, had been dissected from the underlying structures as far as the right internal inguinal ring.

If blood under pressure can find its way extraperitoneally from one part of the abdominal wall to another, there is no reason why pus under pressure should not do the same thing. In a psoas abscess we have a good example of the extraperitoneal burrowing of pus.

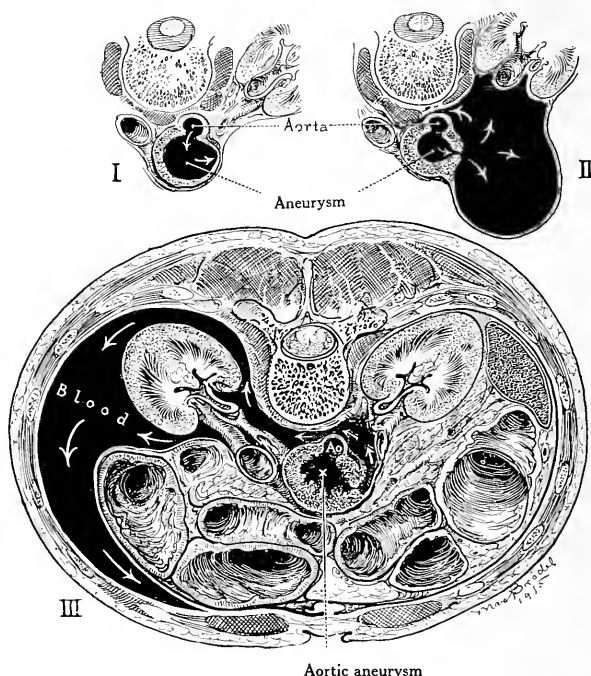


FIG. 162.—LEAKAGE FROM AN ABDOMINAL ANEURYSM PRODUCING A TEMPORARY ABDOMINAL TUMOR; SUBSEQUENT ESCAPE OF THE BLOOD INTO THE RIGHT RENAL POCKET.

H. S. W., February 16, 1912. In I, we see an aneurysmal dilatation of the aorta. In II, the aneurysmal sac has given way, with the escape of blood retroperitoneally. This caused the tumor that was noted clinically. The pressure of the escaping blood gradually dissected the peritoneum free, and the blood, following the line of the arrows, gradually passed over into the right renal pocket, as noted in III. At operation I found the peritoneum over the lateral wall of the lower abdomen bluish black. This was due to the presence of old blood lying between the peritoneum and the muscles of the lateral abdominal walls. At autopsy it was found that the blood had dissected its way extraperitoneally as far as the right internal inguinal ring.

#### A PERIPROSTATIC ABSCESS OPENING AT THE UMBILICUS.

Nicaise refers to the case of a patient under the care of Castaneda. A periprostatic abscess gradually extended and opened at the umbilicus. In Fig. 163 is indicated the manner in which a periprostatic abscess may reach the navel.

#### THORACIC ABSCESS OPENING AT THE UMBILICUS.

Both Blum and Nicaise refer to a case reported by Curran in the *Lancet* in 1872. A young boy in the beginning had symptoms of a right-sided pneumonia. Resolution failed to take place, and cachexia soon developed. The boy looked as if he had tuberculosis. At the end of six months an elevation, which was exceedingly

painful, developed just above the xiphoid and extended to the umbilicus. It soon opened, and an enormous quantity of pus escaped, the purulent discharge from the umbilicus continuing for fourteen days. The pulmonary symptoms disappeared, and the boy was able to go back to his occupation permanently cured. The abscess in this case had evidently been walled off by the cellular tissue between the attachment of the diaphragm and the sternum. Whether an abscess of the lung had

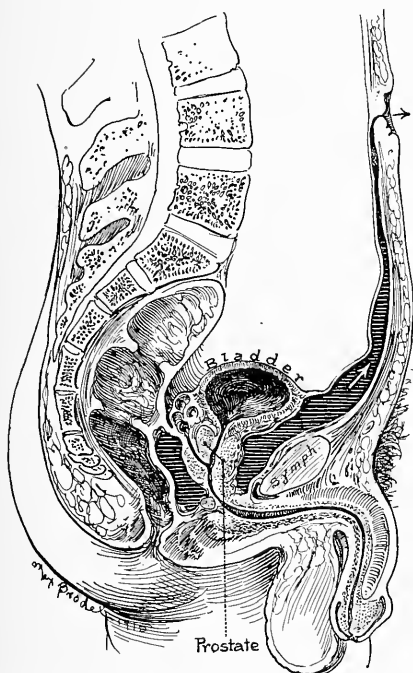


FIG. 163.—THE MANNER IN WHICH A PERIPROSTIC ABSCESS MAY OCCASIONALLY ESCAPE AT THE UMBILICUS.

The periprostic abscess may gradually dissect free the peritoneum of the lateral and anterior abdominal wall and reach the umbilicus. This has occurred in a few instances, but it is unusual, the abscess, as a rule, tending to empty itself into the bowel, bladder, or externally.

existed or whether there had originally been an accumulation of pus in the pleural cavity could not be determined.

Fig. 164 depicts in a schematic way the manner in which an empyema, after perforating the diaphragm, may travel downward and forward until it reaches the umbilicus.

#### A BROAD-LIGAMENT ABSCESS OPENING AT THE UMBILICUS.

According to Nicaise, Féréol was the first to describe a case of this kind; Bernutz and Guerin had also reported cases of phlegmon of the broad ligament opening at the umbilicus.

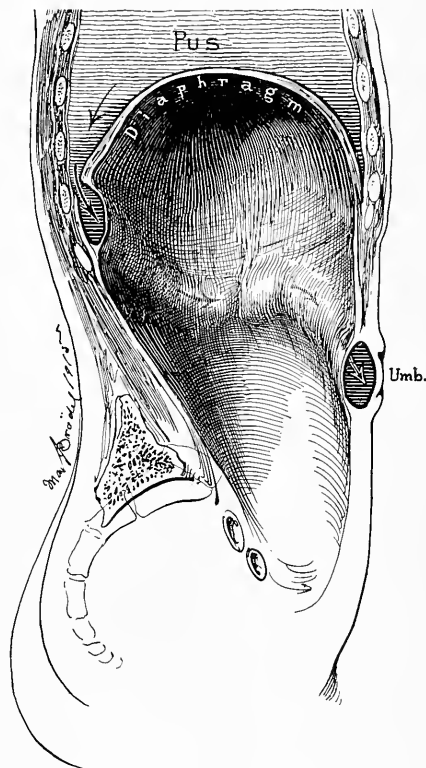


FIG. 164.—ESCAPE OF PLEURAL FLUID FROM THE UMBILICUS.

This is a schematic representation of the manner in which a purulent accumulation in the pleural cavity may break through the diaphragm, gradually dissect free the peritoneum over a limited area, and finally escape at the umbilicus. In some cases, after the pus has broken through the diaphragm, a fistulous tract has been found extending intraperitoneally down over the liver to the umbilicus.

Probably the most interesting articles on the subject are those of Vaussy, published in 1875, and of Gauderon, published in 1876.

We are all familiar with the induration that is occasionally found in one or both

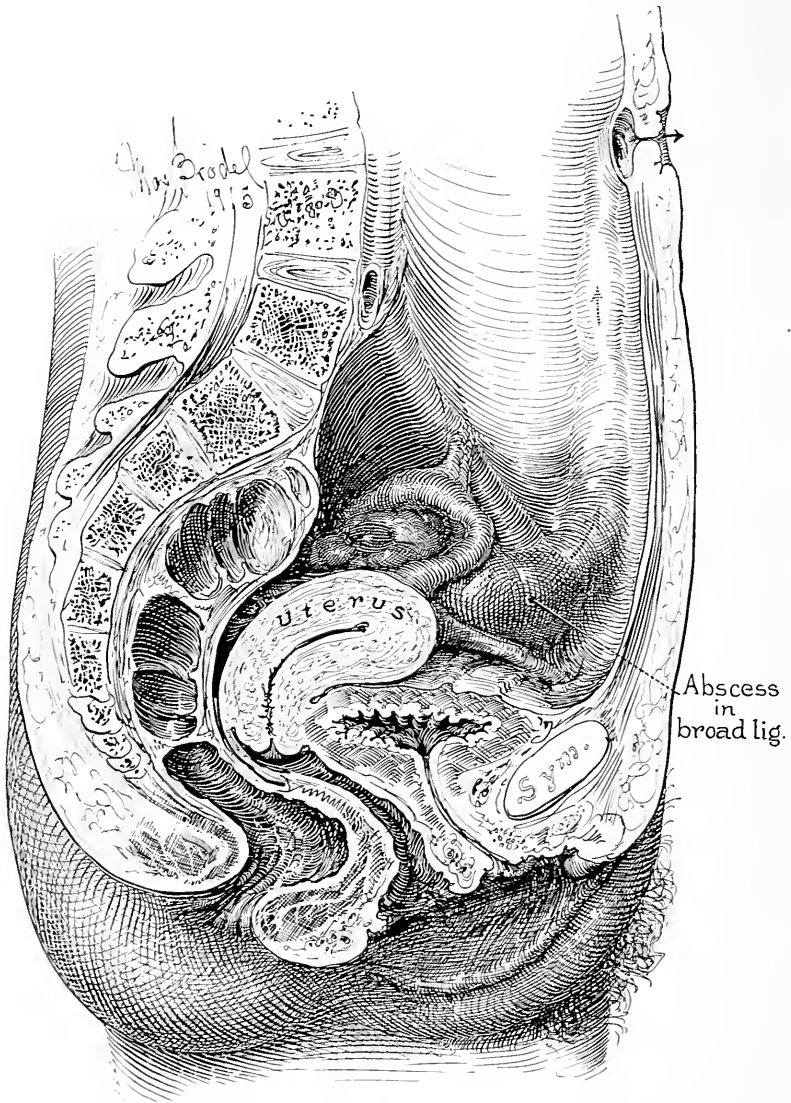


FIG. 165.—THE OPENING OF A BROAD LIGAMENT ABSCESS AT THE UMBILICUS. (Schematic.)

Broad ligament abscesses are most frequently observed after postpuerperal infections. Occasionally they form definite hard or boggy masses that can be readily palpated in one or both iliac fossæ. In rare instances the infection extends beyond the confines of the broad ligament. The pus dissects the peritoneum of the lateral and anterior abdominal wall free over a limited area, and finally escapes through the umbilicus, following the course roughly outlined by the arrows.

broad ligaments, and which, as a rule, has resulted from an infection following labor. Although such an inflammation is usually limited to the uterus, it may gradually separate the folds of the broad ligament and appear as a more or less indurated nodule in the right or left iliac fossa, and occasionally in both. If the tendency

toward suppuration continues, a further lifting up of the peritoneum may occur, and in this manner the pus may travel up to the umbilicus (Fig. 165).

In nearly all the reported cases the patients have given a history more or less typical of a mild puerperal sepsis. After a period varying from a few days to several months' induration was noted at or near the umbilicus. This was in some instances accompanied by marked induration of the abdomen between the umbilicus and pubes. The center of the umbilical induration gradually softened. In some cases it opened spontaneously; in others it was opened before rupture had time to occur. The amount of pus escaping varied greatly, depending in large measure on the size of the broad-ligament abscess. The umbilical opening usually remained patent until the abscess-sac ceased to drain. In Vaussy's Case 1, however, it would temporarily close, only to discharge again. In the cases reported by Féréol and by Sottas, and in Vaussy's Case 6, the abscess also opened into the vagina. None of the patients died as a direct result of the abscess.

**Treatment.**— Sometimes it is possible to make counter-drainage, as in Sottas' case, in which a rubber tube was carried from the umbilicus to the vagina. If the abscess is large, it may be possible to enter the broad ligament from the vagina, but much care must be exercised to avoid injuring the ureter or uterine artery. When vaginal drainage does not seem feasible, the ordinary gridiron incision, as for an appendix operation, should be made; the peritoneum should be gradually pushed toward the median line until the broad ligament is reached and the abscess evacuated.

#### CASES OF BROAD-LIGAMENT ABSCESS OPENING AT OR NEAR THE UMBILICUS.

The following cases were encountered in looking up the literature on diseases of the umbilicus. There have doubtless been other cases recorded in the general obstetric and gynecologic literature. The number here cited is, however, sufficient to give a clear idea of the direction which abscesses in the broad ligament may occasionally take.

**Fistula at the Umbilicus Following Suppuration in the Left Broad Ligament.**— Nicaise said the first observation of this kind was mentioned by Féréol.\* Inflammation of the left broad ligament followed the labor. There then developed a local peritonitis, which later became general. At the same time the left side of the abdomen became tumefied and there was dulness on percussion. Toward the fifteenth day a small tumor appeared above and to the left of the umbilicus. It was hard, fluctuating, and opened spontaneously. Floods of pus escaped, soaking several draw-sheets during the night. Several days after another perforation took place, this time into the vagina. The umbilical fistula cicatrized in the course of six weeks.

**Phlegmon of the Left Broad Ligament and of the Right Broad Ligament; Subperitoneal Escape of Pus by the Rectum; Escape of Pus Below the Umbilicus; Healing.** †— Marie Noël, twenty-two years of age, was the mother of two children, one born in March, the other in December, 1875. After the labor she

\* Féréol (Quoted by Nicaise): *Ombilic*. Dictionnaire encyclopédique des sci. méd., Paris, 1851, 2. sér., xv, 140.

† Gauderon, E.: De la péritonite idiopathique aiguë des enfants; de sa terminaison par suppuration et par évacuation du pus à travers l'ombilic. Thèse de Paris, 1876, 148.

came under the care of Siredey. On December 20th a phlegmon of the left broad ligament was noted, and on February 5th there was a similar condition in the right broad ligament. About February 20th a thickening was made out in the anterior abdominal region, commencing three fingerbreadths beneath the anterior superior spine on the right, and reaching almost to the umbilicus. Pus had been discharged by rectum on February 12th. The abdominal tumor persisted and progressed toward the median line, apparently following the direction of the urachus toward the umbilicus. Pressure caused severe pain below the umbilicus. On February 11th fluctuation had been noticed below the umbilicus, and an opening had been made at this point which allowed the escape of a large quantity of creamy, thick pus. The umbilicus was never distended in the manner indicating the presence of a hernia.

**Suppuration of the Tube and Ovary, with Opening at the Umbilicus.\***—A woman, twenty-four years of age, was admitted to Viannay's clinic in August, 1910, on account of an abscess which had opened at the umbilicus. She had had a child twenty-three months before, but no miscarriages. Forceps were used at the labor. No fever followed. When she commenced to get up, pain was noted in the right iliac fossa. Some time later the abdomen was opened by Dr. Blanc for a salpingo-oöphoritis. Recovery followed, but when the menses returned, pain was noted in the iliac fossa. There was a periodic purulent discharge from the uterus and pain in the lower abdomen. Little by little she developed a purulent accumulation around the umbilicus. This opened spontaneously and discharged an abundance of purulent material.

When admitted to the hospital, a small abscess the size of a walnut was noted in the lower part of the umbilical cicatrix. This had a punctiform orifice. The disproportion between the small size of the abscess and the great abundance of the umbilical discharge was very striking. On vaginal examination an induration was found in the right lateral cul-de-sac.

**Operation.**—The umbilical opening was increased in size and an abscess found in the subcutaneous tissue. The fistulous tract passed down the median line behind the muscle and the aponeurosis. The median incision was continued to within two fingerbreadths of the symphysis. A finger was introduced into the fistulous tract, and counter-palpation made through the vagina. Finally the abdominal finger opened up an abscess, which was drained from above. The vagina was not opened. The patient made a good recovery.

[This would appear to have been a broad-ligament abscess.—T. S. C.]

**Umbilical Fistula Following Puerperal Sepsis.**—Nicaise† cites the case of one of Pujol's patients. The peritonitis developed in a woman shortly after confinement. A little later there was pain at the umbilicus and a small tumor formed, with a soft swelling around it. It was opened with a lancet and pus escaped. A sound introduced into the tract did not pass to the peritoneum. On the fourth day, in the depth, another tumor could be felt passing from the primary abscess. It opened spontaneously through the same opening, and a large quantity of pus escaped. The fistula closed in about six months.

\* Maurin: Salpingo-ovarite suppurée, ouverte à l'ombilic. *La Loire médicale*, 1910, année 29, 495.

† Nicaise (Pujol): *Op. cit.*



Subperitoneal Phlegmon of the Anterior Abdominal Wall Spontaneously Opening at the Umbilicus; Purulent Pleurisy, Followed by Recovery.\*—Case 1.—This patient was twenty-one years of age and was admitted in May, 1875. Fourteen days previously she had had a normal labor, and four days later a chill, and the lochia had ceased. The abdomen increased in size, but there was no vomiting or nausea. On March 17th the umbilicus became red, projected somewhat, and showed a whitish point in its center. During the night of the eighteenth this ulcerated and there was a discharge of greenish liquid containing grumous material. During the evening the opening increased in size. By March 21st the discharge at the umbilicus had diminished. On April 3d it was very slight, but on the ninth the umbilicus opened again spontaneously and two liters of grumous, greenish pus escaped. The patient continued to have an appetite. There was some fever at night. By November 12th the patient had improved very much and was convalescing. During the first few months recovery was retarded by a purulent pleurisy. It was supposed that this patient had had a purulent peritonitis, and for that reason she was admitted to the hospital. Vaussy, however, was not certain that the condition was not due to inflammation of the perimetrium, with extension to the umbilicus.

[The latter explanation would seem to be the more rational one.—T. S. C.]

Inflammation of the Left Broad Ligament Following Labor; Local Peritonitis, Mammary Abscess, Inflammation of the Femoral Vein, Spontaneous Perforation of the Abdominal Wall in the Neighborhood of the Umbilicus, also Opening into the Vagina. Cicatrization of the Umbilical and Vaginal Fistulæ. Death Due to Tuberculosis of the Lungs.†—P. R., aged twenty-four, a healthy woman, was delivered on October 26, 1859. The labor was difficult. On October 31st the lochia ceased; the patient had a chill for half an hour. The abdomen became painful in the left inguinal region. The pulse was small, thready, frequent, and there was much thirst. The next day the lochia reappeared in small quantities. The abdomen was tympanitic, painful in the lower left side, where a tumefaction could be felt in the broad ligament. On November 2d the chills were constant and prolonged. The abdomen was swollen and painful. Pressure was intolerable. There was nausea without vomiting, and the face was pale and drawn. The pulse was small and frequent, and the skin hot and dry. On November 20th a phlebitis appeared in the left limb. On November 28th a small tumor was felt in the neighborhood of the umbilicus. It was immediately below and a little to the left, and was the size of a pigeon's egg. It was hard, although fluctuant. On November 30th an abscess presented in its center, a small plaque about the size of a 20-centime piece, from which a serous, transparent fluid was discharged. On December 1st a considerable quantity of greenish, serous pus escaped, which had a rather fetid odor. The abdomen diminished in size, and the tumor in part disappeared. On December 5th there was diarrhea, and the patient had a left intermammary abscess. She also suffered pain in the left lower abdomen.

\* Vaussy, F.: Des phlegmons sous-péritonéaux de la paroi abdominale antérieure. Thèse de Paris, 1875, No. 445.

† Vaussy, F.: Op. cit., Case 6.

The night preceding she had been inundated with pus that had escaped from the vagina. On the seventh the diarrhea continued; the discharge from the vagina diminished, but was abundant from the umbilicus. The chills appeared every day about 2 or 3 o'clock. There were definite signs of pulmonary tuberculosis. In the early part of January some improvement was noted. The fistula closed completely, the appetite returned, and the patient seemed to be on the point of recovery. Toward the end of January both lungs were found to be involved, and the patient died on February 24, 1860. At autopsy it was found that the intestinal loops were bound to one another by an old false membrane. Both lungs were infiltrated with tubercles.

In this case a woman, several days after labor, had a phlegmon of the broad ligament, which was extraperitoneal. It invaded the iliac fossa and the anterior abdominal wall, and there formed in this region, extraperitoneally, a large, purulent collection which reached to the umbilicus. The peritoneum was in contact with the abscess and became inflamed, whence there resulted a circumscribed adhesive peritonitis. Four weeks after labor the tumor opened at the umbilicus, and several days later a new opening took place spontaneously into the vagina. This latter opening was at the dependent portion of the abscess. The patient commenced to improve, but pulmonary tuberculosis suddenly developed. The autopsy demonstrated an old peritonitis, but no trace of any recent pus.

**Suppurative Pelvic Peritonitis Opening Spontaneously at the Umbilicus.**—Vaussy\* reports a case observed by Sottas, an intern in the service of Marrotte, and published in *L'Union médicale*, June 2, 1864. R. A., aged twenty-three, was delivered of a child in the eighth month. After labor the patient had fever but no pain and no abdominal distention. There was nothing to indicate peritonitis. She left the hospital on April 22d, and three days later returned with all the symptoms of pelvic peritonitis. At that time an abscess is said to have opened into the vagina. In the course of two months she was again admitted to the hospital. She complained of pain in the left iliac fossa, and said that she had a tumor. In the month of September the swelling disappeared and the patient left the hospital in good health. She entered the hospital again on December 14, 1863. In the hypogastric region was an ovoid tumor, fairly firm, and painful on pressure. In the iliac fossa was an irregular solid tumor. The illness was attributed to a relighting up of the old pelvic inflammation. On January 2d fluctuation was noted in the hypogastric region, but this was so superficial that it was thought to be subcutaneous. The hypogastric region was prominent, and occupying it was a round tumor. At the umbilicus it was possible to feel the superior portion of the tumor, which was round and fluctuating. On examination the cervix was found to be back against the sacrum. Between the uterus and the symphysis was a round, soft tumor. Examination was painful, and the skin of the abdomen was red and suggested a phlegmon. On the night of January 5th a small nodule which had formed just below the umbilicus opened; there was a free escape of pus, and the hypogastric region became flatter. Later Bernutz and Gosselin saw the patient; a probe introduced at the umbilicus passed down toward the vagina. On the tenth Gosselin dilated the umbilical orifice, punctured the vagina, and brought the probe through. A rubber tube was then passed from the umbilicus through into the vagina. On the nineteenth the urine escaped from the

\* Vaussy, F.: *Op. cit.*, Case 7.

umbilicus, and colored matter injected into the bladder escaped from the vagina and also from the umbilicus.\*

The discharge of urine gradually ceased from the umbilicus, and on February 1st the patient voided without a catheter. The suppuration from the umbilicus and from the vagina had ceased. On February 6th the patient had chills and fever and the pain in the abdomen reappeared. On February 13th the umbilical fistula opened again, and a seropurulent discharge came away. On February 20th it was noted that the discharge had ceased for several days and the patient was in good condition. In the left iliac fossa could be felt an indurated tumor, but the patient remained well.

[In this case there was probably a broad-ligament abscess. Peritonitis cannot be absolutely excluded.]

#### AN ABSCESS OF THE UMBILICAL VEIN IN AN ADULT.

This case hardly belongs in this chapter, but can be better considered here than elsewhere. As a rule, the umbilical vein has long since disappeared, but from Dr. Barlow's description it seems quite probable that the abscess here described developed in a partially patent umbilical vein.

An Abscess of the Umbilical Vein in an Adult. †—The patient was a male, white, aged forty. At the age of fifteen he began to have sporadic attacks of pain, cramp-like in character, very severe, and coming on nearly always at night, after retiring. These attacks, as a rule, were of short duration. Two or three days after the pain was over the patient was apparently perfectly well again until the next attack.

On the evening of January 14, 1915, the patient was taken with severe pain involving the whole right abdomen. The pain was so severe that it caused him to draw his knees up and to cry out. He had no chills and was not jaundiced; temperature, 101° F.; nausea and vomiting once. Dr. E. C. McGehee, the family physician, examined him thoroughly and made a diagnosis of acute infection of the gall-bladder. One-quarter of a grain of morphin failed to relieve the pain, and it was necessary to allow him to inhale chloroform before any relief could be obtained. Dr. Barlow saw him in consultation next morning. At that time the temperature was 100° F.; the entire abdomen was distended; the acute pain was subsiding; the area of tenderness was localizing between the umbilicus and the liver, and the patient was sensitive under the right costal arch. Immediate operation was advised, but the patient did not consent until a week later.

Operation.—The usual gall-bladder incision was made, but as he was opening the peritoneum Dr. Barlow entered an abscess which he thought was the gall-bladder. Exploration with the finger disclosed the fact that it was not the gall-bladder but a well-walled-off abscess containing about one and one-half ounces of pus. This abscess in shape resembled a bottle-gourd, the larger portion being toward the umbilicus, the smaller or handle-like end extending into the fissure of the liver. This abscess was firmly fixed to the abdominal wall, to the upper border of the liver above the gall-bladder, and to the hepatic flexure of the colon.

After this sac had been dissected free from these attachments it was still found

\* We would now administer phenolphthalein, which would give the reddish discharge from the vagina and also from the umbilicus.

† Dr. E. E. Barlow, Dermott, Ark. Personal communication.

anchored to the fissure of the liver by the handle-like portion of the sac, which proved to be the umbilical vein. This was patulous within an inch of its bifurcation. It was ligated above the patulous portion and removed.

The stomach, duodenum, pancreas, gall-bladder and its ducts were examined and found to be normal. The portion of the hepatic flexure of the colon that was adherent to the sac was somewhat lacerated, and in the presence of infection Dr. Barlow did not feel justified in attempting to repair it. There was no evidence of ulceration at this point, the damage being due, as Dr. Barlow says, to an extensive dissection. A large coffer-dam drain was laid down between the liver and intestine. This was removed on the fifth day. Two days later a fecal fistula appeared but closed after five or six days. The patient made an uneventful recovery, and at the time of the report was apparently well.

#### LITERATURE CONSULTED ON THE ESCAPE OF RETROPERITONEAL FLUID FROM THE UMBILICUS.

- Féréol: Nicaise: Ombilic. Dictionnaire encyclopédique des sci. méd., Paris, 1881, 2. sér., xv, 140.
- Gauderon, E.: De la péritonite idiopathique aiguë des enfants; de sa terminaison par suppuration et par évacuation du pus à travers l'ombilic. Thèse de Paris, 1876, No. 148.
- Maurin: Salpingo-ovarite suppurée, ouverte à l'ombilic. La Loire médicale, 1910, année 29, 495.
- Nicaise: Op. cit.
- Vaussy, F.: Des phlegmons sous-péritonéaux de la paroi abdominale antérieure. Thèse de Paris, 1875, No. 445.

#### THE OPENING OF AN APPENDIX ABSCESS AT THE UMBILICUS.

An appendix abscess, in the vast majority of cases, naturally is intra-abdominal, and hence there is little opportunity of its passing upward in the abdominal wall unless the abscess has destroyed the peritoneum of the anterior abdominal wall over the abscess area, or unless, as happens very rarely, the appendix from the beginning has been retroperitoneal. In an experience extending over twenty years I have never seen the umbilicus involved in an appendix case. In the literature I have, however, found several cases which seem to indicate an extension to the umbilicus.

Vaussy\* reports a very interesting case: A girl, sixteen years of age, was admitted on October 27, 1875. Seven months previously she had suddenly vomited, had had diarrhea, but no abdominal pain. Three months later the pain had become severe in the hypogastric region and the patient had noticed a tumor occupying the right iliac fossa. This was painful on pressure. She had had no chills, no nausea or vomiting. In the course of two months this tumor had increased in size, and the pain had become more severe, lancinating in character, and insufferable. The patient had lost her appetite and had fever, and her general condition was much altered. The tumor had become fluctuant. Two incisions were made, and about 500 c.c. of pus escaped. Several days later a small red plaque appeared below the umbilicus, and there was a tumor the size of a cherry. This opened spontaneously with the passage of a certain amount of pus. There was also a discharge of pus from the umbilicus. Toward the end of September the opening cicatrized. When seen on October 27th the patient was again pale, and there was a purulent

\* Vaussy: Op. cit., Obs. 3, p. 27.

discharge from the umbilical region and also from the site of the incision. By November 11th the patient was in excellent condition and looked as if she were getting well. [While one cannot say that this was primarily a case of appendicitis, the picture strongly indicates it.—T. S. C.]

Gauderon, in his thesis in 1876, refers to the same case.

Bryant and Hine, in 1878, reported a case in which the escape of pus was in all probability appendiceal in origin, as indicated by the perforated cecum detected at autopsy. A boy, aged thirteen, had pain in the lower abdomen and also soreness at the umbilicus, together with a fecal fistula at that point. He had been delicate since an attack of scarlet fever when three years old. His legs were scalded when he was eleven years old, and since then he had lost weight. His bowels had always been loose. Three weeks before admission he had sudden pain in the abdomen, and a week later his umbilicus began to swell, became purple, and in a few days burst, discharging a quantity of matter with a distinctly fecal odor. The boy died.

At autopsy the cecum was found to have ulcerated through, and the ulceration had extended along the abdominal wall to the umbilicus. The symptoms in this case strongly suggested appendicitis or an inflamed Meckel diverticulum.

Kelly and Hurdon report an interesting case coming under the care of R. L. Payne, of Norfolk, Va. The patient, a colored woman twenty years old, after repeated attacks of appendicitis, developed a tumor at the umbilicus. When an incision was made in the mid-line, just beneath the umbilicus, half a pint of fetid pus escaped and the appendix floated out. The patient recovered, but a fistula persisted.

We have here considered only those appendix cases in which an abscess was present, and in which no general peritonitis existed. For a description of the umbilicus in cases of peritonitis see p. 299.

#### LITERATURE CONSULTED ON THE OPENING OF AN APPENDIX ABSCESS AT THE UMBILICUS.

Bryant and Hine: Fecal Umbilical Fistula. *Med. Times and Gaz.*, 1878, i, 460.

Gauderon, E.: De la péritonite idiopathique aiguë des enfants; de sa terminaison par suppuration et par évacuation du pus à travers l'ombilic. Thèse de Paris, 1876, 148.

Kelly and Hurdon: The Vermiform Appendix and its Diseases. Phila., W. B. Saunders Co., 1905, 202.

Vaussy, F.: Des phlegmons sous-péritonéaux de la paroi abdominale antérieure. Thèse de Paris, 1875, No. 445.

#### ABSCESS OF THE LIVER OPENING AT THE UMBILICUS.

Bérard, in 1840, wrote on abscess of the liver opening at the umbilicus.

Leguelinel de Lignerolles, in 1869, said that hepatic fistulæ opening at the umbilicus might be due to a calculous tumor, to hydatids, or originate from an abscess of the liver. He then reported in detail several cases in which biliary calculi and echinococci escaped at the umbilicus, but has little to say regarding hepatic abscesses opening at the umbilicus.

Nicaise, when summing up the subject, says that abscess of the liver does not, as a rule, tend to open externally, and that, judging from the statistics of Rendu, the majority of these abscesses do not open spontaneously. When rupture takes place, the pus tends to pass toward the thoracic more frequently than into the

abdominal cavity. In those rare cases in which the abscess tends to escape externally the point of exit is liable to be in the region of the right hypochondrium, beneath the costal margin, where the abscess becomes walled off and then ruptures. Nicaise says that he knew of but one case, that of Ronis, in which a liver abscess opened directly at the umbilicus. Judging from a casual glance over the literature one would infer that an escape of the contents of a liver abscess from the umbilicus was not rare, but when we come to analyze the cases, it will be found that in nearly every instance the umbilical fistula was due to an infected gall-bladder which had become adherent to and opened at the umbilicus, as evidenced by the escape of gall-stones with the pus.

The opening of a liver abscess at the umbilicus is a very rare occurrence.

#### LITERATURE CONSULTED ON ABSCESS OF THE LIVER OPENING AT THE UMBILICUS.

Bérard, P. H.: *Fistules de l'ombilic.* Dict. de méd., Paris, 1840, xxii, 64.

Nicaise: *Op. cit.*

Leguelinel de Lignerolles, H.: *Quelques recherches sur la région de l'ombilic et les fistules hépatiques ombilicales.* Thèse de Paris, 1869, No. 6.

#### PERITONITIS WITH THE ESCAPE OF PUS AT THE UMBILICUS.

From time to time isolated cases of peritonitis with escape of the pus from the umbilicus have been recorded. Among the earlier writers on the subject were Bricheteau in 1839, Cazaban in 1845, Aldis in 1848, and Baizeau in 1875. The most exhaustive treatise that we possess is the excellent thesis of Gauderon, published in 1876, and even to-day this monograph contains the most illuminating discussion of the subject. Nicaise, in 1881, gave a very complete review of the literature, and Cameron, in the Proceedings of the Royal Society of London, February, 1912, adds some very interesting data.

#### CLINICAL PICTURE.

As pointed out by Gauderon, this disease occurs almost exclusively in girls. Boys, however, are occasionally attacked. Of the cases described here more or less in detail, and where the sex was mentioned, 12 occurred in girls and 1 in a boy.

*A g e .* — The youngest child was a year old, the oldest, seventeen. In 15 cases in which we have data as to the age, 14 of the patients were under twelve years of age.

*S y m p t o m s .* — The child is usually attacked suddenly with severe abdominal pain. When seen, the legs are drawn up, the face has an anxious expression, the pulse is rapid and small, the temperature elevated; the tongue is often red, and the skin hot. As the disease progresses there may be much vomiting associated with diarrhea. In fact, in Baizeau's case the gastro-intestinal symptoms were so accentuated that cholera was suspected. The exact condition is often very obscure. In Cameron's Case 6 appendicitis was first suspected, and later the child was supposed to be suffering from pneumonia. In Cameron's Case 7 the symptoms strongly suggested typhoid fever.

As the disease progresses the child may become delirious, as noted in Aldis' and Baizeau's cases, and emaciation become marked. After a period varying from a few days to several weeks fluid is detected in the abdomen, and a little later the umbilicus becomes prominent. Thus, in Triboulet's case, referred to by Gauderon, for

example, on the eighth day a small, elevated tumor formed at the umbilicus. This was diagnosed as an umbilical hernia, and an attempt made to reduce it. In Cameron's Case 6, on the other hand, it was ten weeks before any umbilical swelling was noted. There is usually an unfolding, as it were, of the umbilicus, and a tumor is formed. The umbilical skin may be normal or somewhat thinned out. The tumor contains free fluid, and when this has been forced back into the abdomen, the hernial ring can at times be easily felt. This forcing back of the fluid into the abdomen is sometimes accompanied by a considerable amount of gurgling. As a rule, there is little or no evidence of inflammation at the umbilicus. In Cazaban's case, however, there was a phlegmonous inflammation at the umbilicus, and in Triboulet's case the umbilicus was indurated.

Gauderon says that pus may escape from the umbilicus as early as the twelfth day, but that, as a rule, it comes away between the twentieth and thirtieth days. In some cases the umbilical prominence became red and opened in its center; in other cases, after the application of poultices, there was a sudden discharge of pus, much to the surprise of the physician or attendant. If there has been much abdominal tension, the pus will naturally escape in jets until the pressure has been relieved. It varies greatly in appearance. In some cases it was spoken of as a purulent fluid; in others, as that of a serous peritonitis, while in several cases it was thick and green in color. In some cases it was odorless; in others, foul-smelling. The amount of pus also varied greatly. In some cases it was estimated that several liters escaped.

Sometimes the fistula would remain open for weeks and then close. In other cases it would seal over and open up again, only to repeat this procedure several times.

In some cases it was found necessary to irrigate the abdominal cavity frequently before the purulent secretion could be checked. The earliest permanent closure was in eight days—in Cazaban's case. In one case the fistula remained open seven and one-half months. Gauderon said that, on an average, the fistula closed in a month.

In a few cases the umbilical swelling was incised before it had time to rupture, thus facilitating the escape of the pus.

**C o m p l i c a t i o n s .**—In Triboulet's case a friction-rub developed at the base of the right lung. In West's case there was a purulent pleurisy with effusion, and in Baizeau's case a pleuropneumonia developed.

**R e c o v e r y .**—As pointed out by Gauderon, nearly all the children in whose cases the peritonitis opened at the umbilicus recovered. Those dying succumbed to lesions in no way dependent on the peritonitis.

#### CAUSES OF THE PERITONITIS.

These cases have usually been spoken of as instances of idiopathic peritonitis, and as most of the reported cases occurred before bacteriologic examinations were made, we have no way of determining absolutely their mode of origin. According to Ledderhose, Hensch's patient had been trampled on by a large dog and the peritonitis had soon followed. Cameron's Case VI, reported in 1912, was due to the pneumococcus, and in his Case VII there was probably a similar origin. From a careful study of these cases one gathers the impression that the pneumococcus may be responsible for the majority of the cases of so-called idiopathic peritonitis.

## DIFFERENTIAL DIAGNOSIS.

These cases of peritonitis are occasionally simulated by deep-seated inflammations between the umbilicus and pubes. These are usually due to an infection of remnants of the urachus. If the inflammation occurs in young children, for the first few days it may be impossible to differentiate between it and a general peritonitis, the symptoms being identical (p. 567), but after an interval of four to five days the abdominal swelling diminishes, the abdomen becomes flat, and a localized tumor is felt between the umbilicus and pubes, whereas in a peritonitis the intra-abdominal fluid is still evident.

## CASES OF GENERAL PERITONITIS OPENING AT THE UMBILICUS.

These cases are of interest from a historic standpoint, showing, as they do, how nature may liberate a purulent peritoneal accumulation. In the future we shall expect to see still fewer of these cases, since, with the operative facilities that we now possess, abdominal drainage will be adopted early in the disease.

**Purulent Peritonitis with Spontaneous Evacuation Through the Umbilicus; Healing.\***—A girl, aged seven years and four months, was visited by Dr. Aldis on June 5, 1846. She lay on her right side; the face was emaciated and drawn, and the expression was anxious. The extremities were atrophied. The urine was scanty, the abdomen was distended, and there was a projection at the umbilicus; fluctuation was manifest. About eleven weeks before, the child had been seized with chills and fever, vomiting, and pain in the abdomen; on the following day she was delirious. An examination of the abdomen failed to reveal any induration. On June 7th an opening occurred spontaneously in the tumor, and over 2000 c.c. of purulent material escaped from the abdomen. The child complained of pain in the hips. The urine was abundant and pale. On the following days pus continued to escape. On June 12th the abdomen was perfectly flat, and the child was visited for the last time. On September 30th she was in good condition. The abdominal girth was only 20 inches in the region of the umbilicus, and the opening was closed by a solid cicatrix.

**Probably a Peritonitis, with Escape of Pus From the Umbilicus.**—Bricheteau† reported a case in which a large abscess of the abdomen, simulating an acute peritonitis, opened at the umbilicus. A girl, aged seventeen, of lymphatic constitution, on May 17, 1839, complained of abdominal pain. The abdomen was sensitive, and she could not bear to be touched with the hand. The skin was hot, the pulse somewhat accelerated. There was very frequent vomiting. The expression was anxious, but the general abdominal contour was not altered. Prolonged baths were given, but eight or ten days later the abdominal pain returned and was associated with tension. The patient could not sit up. Vomiting reappeared and there was diarrhea. Thirst was marked, and there was much heat of the skin and an increase of fever. The abdomen was distended and tympanitic on the left side, and the patient lay continuously on her right side. On June 12th Bricheteau noted that the skin of the umbilicus

\* Aldis: *Gaz. méd. de Paris*, 1848, 733. Cited by Gauderon: *De la péritonite idiopathique aiguë des enfants; de sa terminaison par suppuration et par évacuation du pus à travers l'ombilic*. Thèse de Paris, 1876, No. 148; obs. 25.

† Bricheteau: *Des abcès dans le tissu cellulaire sous-péritoneal*. *Arch. gén. de méd.*, 1839, vi, 435.



was thin and raised, and two days later, on removal of a poultice, a jet of pus was seen escaping from the umbilicus and an enormous quantity came away. It was thick in consistence, without odor, and resembled the serous pus of peritonitis. The suppuration continued for several days, after which the opening closed. It opened again and finally closed permanently. The patient for a long period had digestive troubles with vomiting, and was not permanently cured until after a sojourn of three months in the country.

*Purulent Peritonitis; Spontaneous Rupture at the Umbilicus; Abscess of the Parotid; Pleurisy; Recovery.\**—The patient was a boy, twelve years of age, in good health and of a strong constitution. Suddenly he complained of pain in the abdomen and fever developed. The abdomen became distended, ballooned out, and was very sensitive. The slightest pressure could not be made except near the hypogastrium. The facial expression was altered. The radial pulse was 110. The skin was burning. There was excessive thirst and incessant vomiting. The diagnosis did not offer any difficulties, but the cause of the peritonitis was not easy to determine. He showed no signs of external violence, and nothing indicating intestinal perforation. Twenty leeches were applied to the abdomen and were then replaced by fomentations. The abdomen had diminished in size by the next day, except in the region of the umbilicus, where the swelling had increased. The general condition remained the same; the fever and vomiting continued. Applications of leeches were again made. On the fifteenth day there was some improvement. The abdomen remained distended, but was less sensitive on pressure. The pulse was 100; the vomiting had ceased. There had been no movement of the bowels for two days. On the eighteenth day there was a marked change. After dinner an intense pain developed in the right hypochondriac region, reaching to the shoulder. The child cried, and the suffering was extreme. The vomiting returned, and the pulse reached 115. A right pleuropneumonia developed. The point of greatest intensity was at the right nipple. This new affection progressed. On March 15th pain was noted in the right parotid region and a large parotid abscess was opened. About March 20th the abdominal pain reappeared without appreciable cause. It was easily possible to make out an abundant quantity of fluid in the peritoneum. The umbilicus was pushed out by the fluid, and formed a small external tumor. On April 2d this broke, and several liters of greenish pus with thick, grumous material escaped. The discharge lasted for several days and improvement was noted. A drainage-tube was introduced, and an injection of lukewarm water made. The suppuration diminished. At the same time, in the right nipple region, a fluctuating tumor was punctured. On April 10th about six quarts of pus escaped from the umbilicus. Toward the end of May the thoracic fistula closed. About June 21st there was severe pain in the region of the right shoulder, reaching to the lung, and accompanied by intense fever. In the course of several days a fluctuating tumor was detected, and on puncture an abundance of pus escaped. A drainage-tube was introduced and an injection of iodine was employed. The chest fistula closed on October 1st; that of the abdomen, on December 20th. The abdomen was soft and pliable. The respirations were normal.

\* Baizeau: Arch. gén. de méd., 1875, 163. Quoted by Gauderon, A. E.: De la péritonite idiopathique aiguë des enfants; de sa terminaison par suppuration et par évacuation du pus à travers l'ombilic. Thèse de Paris, 1876, No. 148, observation xx.

**Purulent Peritonitis; Spontaneous Opening at the Umbilicus.** \*—The subject of this observation was a young girl of ten who had a good constitution and had previously been well. For a month preceding her illness she had spent her time quietly with her parents. On May 31, 1872, she had constant pain in the abdomen, accompanied by nausea and vomiting. The eyes were sunken and the face was drawn. There were several liquid stools, and the patient had cramps in the legs. The case suggested cholera. On the following day, at 9 A. M., the vomiting, which had been frequent during the night, stopped. The patient commenced to complain of pain in the head. This became more and more violent, and was accompanied by delirium. Ice was applied to the head. The cerebral trouble for some time completely overshadowed the lesion in the abdomen. The delirium disappeared in the course of four or five days, but the fever continued. There was great thirst, and the tongue was covered with sordes. The abdomen was also painful and distended, and a certain amount of fluid could be detected in the peritoneal cavity. On the following day the pain was referred principally to the right hypochondriac region, and some complication in the liver was thought of. The child complained continually of suffocation and palpitation of the heart. The abdomen increased in size, and was in marked contrast to the extremities, which were greatly emaciated. This condition persisted for a month without any amelioration. The digestive troubles were more and more pronounced; very frequently there was vomiting of bile and a diarrhea. For some unknown reason a plaster was applied to the abdomen, and when it was drawn back in one of the early days in July, it was noted that the umbilicus was distended by the abdominal fluid. It was red and very thin in its center. On the following day it opened spontaneously, and about 4 liters of purulent, greenish fluid escaped. The discharge continued that night and for several days in great abundance. The child felt relieved and slept; the appetite returned, and there was a marked change for the better. This, however, did not last; the fever returned, the nights were bad, and the digestion again became disordered. Baizeau was called in consultation on July 14th. He found the infant very much emaciated and feeble, and with a continuous fever. The abdomen was markedly distended, and there was an escape of grayish, thick pus, with a strong odor, and containing greenish streaks indicating its hepatic origin. This greenish material, which escaped in large quantities, yielded biliverdin. The abdomen was painful, and at times the child complained of severe pain. The pus was secreted by the peritoneum and escaped incompletely. The umbilical opening was too narrow for the introduction of a drainage-tube. The orifice was dilated with rubber, and on the third day a drain was introduced. Injections were made morning and evening with tepid water, and the fluid appeared to pass into all parts of the abdomen. The fever ceased, and a very favorable change in the general condition was noted. The activity of the stomach returned, and the child, who had been fretful and depressed, became lively. The abdomen was more supple and less painful. Suppuration stopped, and the drainage-tube was taken out on August 28th. Three days later the umbilicus was completely closed. The child had not completely recovered her usual buoyancy, but the general condition was markedly improved. The abdomen was supple and looked normal. The abnormal sensibility had entirely disappeared, and the digestive functions were regular. About September 15th she left Algiers for Paris, where she continued to improve.

\* Baizeau: Quoted by Gauderon, op. cit., obs. 22.

**Purulent Peritonitis; Escape of Pus at the Umbilicus; Persistence of the Umbilical Hernia; Healing.\***—The patient was a child of five years who had been healthy. On January 4th the child presented symptoms of catarrhal fever. On January 6th signs of peritonitis had developed. Under treatment the fever diminished, but the abdomen was painful and much distended. Percussion showed that the distention was not due to the presence of air in the intestine, but to an effusion of fluid in the peritoneal cavity. The child refused absolutely to take medicine. On January 22d the umbilicus was prominent, semitransparent, and red. By the following day the tumor had increased in size to that of a hen's egg, and the skin had become thinner. The presence of fluid could be distinctly made out. On January 25th the tumor ruptured and fluid escaped in a stream the size of a goose-quill. The fluid was semipurulent; about enough to fill a "bottle and a half" came away. On the following day the discharge was moderate in amount and the abdomen was sensitive. The febrile symptoms did not disappear. About February 12th the condition of the patient commenced to improve, but the umbilical fistula still persisted. Dr. Beonhardy attended the patient until September 15th. At that time the fistula had closed, but the child still continued to wear a bandage on account of the umbilical hernia. The destruction of the cellular tissue closing the umbilicus had favored the production of a hernia.

**Pneumococcal Peritonitis Present at Umbilicus.†**—Case VI.—A girl, aged five years, was admitted on April 5, 1911. Six weeks before, she had had an acute illness. At first appendicitis had been diagnosed, and later pneumonia. After a week the abdominal pain had disappeared, but the child had remained without appetite. Before admission the presence of free fluid in the abdominal cavity had been recognized. A diagnosis of tuberculous peritonitis was made, and the child was kept out-of-doors. The opsonic index to tuberculosis was 1.2. On April 30th a swelling appeared at the umbilicus and became so prominent that it was decided to operate. As soon as the peritoneum was opened pus poured out, three pints being collected. A pure growth of pneumococcus was obtained. Recovery followed, and the child was discharged well on July 8th.

**Probable Pneumococcal Peritonitis Opening at the Umbilicus.‡**—Case VII.—A girl, aged eight, was admitted July 9, 1903, under Dr. Taylor's care. On April 20th she had suddenly complained of abdominal pain, and an acute illness of many weeks' duration had followed. It was supposed to be typhoid fever. In the fourth week she was still ill. On July 7 Dr. Taylor saw the child and admitted her to the hospital. The abdomen was swollen and contained fluid. On the day before her admission a fistula formed at the umbilicus. Mr. Lane operated, and one and one-half pints of greenish-yellow pus escaped. The child recovered and was discharged September 3, 1903. When heard from in March, 1905, she was well.

**Abdominal Abscess Simulating Ascites; Spontaneous Opening at the Umbilicus. Recovery.§**—A girl, five

\* Beonhardy: Brit. and For. Med. Rev., xiv, 549. (Cited by Gauderon, op. cit.)

† Cameron, Hector Charles: The Relative Value of Immediate and Delayed Laparotomy in Pneumococcal Peritonitis. Proc. Roy. Soc. Med., February, 1912, v, No. 4, 123.

‡ Cameron, H. C.: Op. cit.

§ Cazaban: Abscès abdominale simulant une ascite; ouverture spontanée par le nombril; guérison. Jour. de chirurgie, 1845, iii, 252.

years old, of weak constitution, was suddenly seized with pain in the abdomen. The bowels did not move, but blood and mucus escaped by the rectum. The pulse was rapid and small, the tongue red, the skin hot, and there was pain on pressure, chiefly in the hypogastric region. On her way to the hospital there were several inclinations to stool, but only tenesmus resulted. This condition kept up for eight or ten days. The symptoms of dysentery disappeared, but the abdomen was painful and the fever persisted. The child appeared to suffer less and seemed to be improving, but the abdomen remained sore. Local applications were used, but during September the child grew thinner, and the abdomen continued to distend. In October the abdomen was much larger and was oval in form.

It was decided to puncture, but this procedure was delayed five or six days. Meanwhile a phlegmonous erysipelas developed at the umbilicus. The cicatrix became prominent, and finally, in one day, more than four liters of whitish-yellow, creamy but odorless pus escaped from the umbilicus. The abdomen still remained painful after the fluid came away. Eight days later the umbilical opening had closed completely, the fever was gone, and the child was convalescing; in one month she was perfectly well.

*Peritonitis with Escape of Pus from the Umbilicus.\**  
 — This case was observed in the service of Triboulet. Maria M., aged six and one-half years, entered the hospital on April 29, 1874. Without apparent cause she had become seriously ill on April 18th. At the beginning there had been pain in the abdomen and excessive vomiting, which had lasted for twenty-four hours. For several days there had been some ten diarrheal stools daily, but without a trace of blood or pus. The diarrhea had not disappeared entirely when the child entered the hospital. She had high fever, and lay immobile in her bed. Applications were made to the abdomen. On April 26th a small, elevated tumor was noted at the umbilicus, and when he saw her, on April 28th, the physician made a diagnosis of umbilical hernia. On admission to the hospital an attempt was made to reduce the supposed hernia. There were also signs of some thoracic affection. She was transferred to Triboulet's service. The facial expression was that of peritonitis—the eyes were sunken, the facial lines drawn; the respirations were 32 to the minute. Percussion of the lungs was negative, but a friction-rub could be heard at the base of the right lung and in front. The pulse was 140, the skin moderately hot. On April 30th signs of peritonitis still persisted. The tongue was red, and its epithelium was dropping off. There was an escape in a jet of about 1500 c.c. of a yellowish, odorless pus from the umbilicus. After the flow ceased, the umbilical cicatrix could be made out; it was distended and indurated, and at the top was a small orifice from which the pus had escaped. The child had some diarrhea after this, but no vomiting, nausea, or hiccups. By the same evening the facial expression had become better, and by the next morning the child wanted something to eat. There was no vomiting, and not the slightest trace of pus by bowel. A moderate amount of discharge still issued from the umbilicus. On May 3d a certain quantity of pus escaped. By the following day the diarrhea had ceased completely, and on June 1 the child was taken to a convalescent home. She was completely cured, and the umbilical fistula had closed. At no point in the abdominal wall was there any trace of induration.

\* Gauderon: Op. cit.

**General Peritonitis Cured by Incision of the Protruding Umbilicus.** — Under date of June 3, 1910, Dr. W. D. Haggard, of Nashville, Tenn., wrote me concerning the history of a patient suffering from general peritonitis. The fluid had been evacuated through an incision into the protruding umbilicus. The patient was a girl twelve years old. She had had a violent attack of appendicitis with great initial prostration. At the end of three weeks she had improved considerably, but the temperature would reach 100° F. in the afternoon, and the abdomen, which had originally been hard and distended, was now soft and fluctuating, and showed a protruding, red, and thinned-out umbilicus. This was incised under ethyl chlorid inhalation, and fully three quarts of purulent fluid were evacuated. The umbilicus had to be reopened on account of an accumulation of a small quantity of fluid. Dr. Haggard told me that the patient was well two months later, but that an interval removal of the appendix had been advised.

**Peritonitis with the Escape of Pus From the Umbilicus.** — Ledderhose\* says that Henoeh described in his text-book the case of a girl, ten years old, who, after having been trampled upon by a large dog, had acute peritonitis which terminated by a breaking through at the umbilicus. Ledderhose adds that in grown people acute peritonitis has no tendency to break through at the umbilicus.

**Purulent Peritonitis Following Scarlatina in an Infant Thirteen Months Old.** † — This was the case reported by Dr. West. ‡ A small, well-nourished girl had scarlet fever when eight months old. The eruption was not marked, but after its disappearance the child did not recover her health, continued to be restless, and had fever. Sometimes she would vomit, and the eyelids at times were swollen. Fifteen days after the appearance of the eruption she had two violent attacks of convulsions. She remained sick until she was ten and a half months old, when her mother noticed puffiness of the eyelids and swelling of the legs and of the abdomen. When the child came under West's observation there were still edema of the legs and distinct fluctuation in the abdomen. The urine was scanty and showed some pathologic changes. Three weeks later her general condition was considerably improved. The urinary secretion was more abundant, and the abdominal circumference was 4 cm. less than before. She had an attack of convulsions without any apparent cause. For a week seropurulent material escaped at the umbilicus and continued to do so, the amount varying from 150 to 200 c.c. This event was followed by improvement in the patient's condition, but after eleven days the fever and dyspnea increased and there was a dulness on percussion over the right lung and absence of the respiratory murmur in front. The discharge ceased for a week, at the time that the thoracic symptoms were most intense. Afterward there was again some discharge which was small in amount. The child at this time was very feeble and much emaciated. She was given stimulants, but forty-eight hours later died without any signs of convulsions, just five and a half months after the scarlet fever and two months after coming under observation. At autopsy a purulent pleurisy

\* Ledderhose, G.: *Deutsche Chirurgie*, 1890, Lief. 45 b, 122.

† Gauderon (West): *Op. cit.*, obs. 23.

‡ West, Charles: *Lectures on the Diseases of Infancy and Childhood*. Fifth Am. Ed., Phila., 1874, 107.

was found on the right side and an effusion of about 180 c.c. of pus in the right pleural cavity. About 1250 c.c. of a similar liquid was found in the abdomen.

**Umbilical Abscess Following General Peritonitis.**—Gauderon\* gives the abstract of a case published by Vetu in the *Jour. de méd., chir., pharmacie et de méd. vétérinaire de la Côte d'Or*, 1846. The patient was a small girl of four years who was convalescing from acute peritonitis. A tumor the size of an almond was noted in the umbilical region on May 14th. This was soft and elastic, and there was no change in color in the skin. It was depressible, and when it had disappeared, in the depression the finger could make out clearly the hernial ring, but when the pressure was released, the tumor reproduced itself. When the child cried or moved about, it became prominent. Vetu diagnosed the condition without hesitation as an umbilical hernia. On May 18th the tumor was larger, being the size of an elongated walnut. Vetu did not notice anything extraordinary in the aspect of the abdomen. Applications were made to the abdomen, and on May 22d, four days later, the physician was not a little surprised to find the child literally bathed in creamy pus. On removal of the dressing, it was found that the tumor had disappeared and that pus was escaping from the umbilicus, the total amount being estimated as 1500 to 2000 c.c. After the pus had stopped running, an opening which admitted the extremity of the finger was noted at the umbilicus. There was not a trace of hernia. In the course of ten days the ring was completely closed and the child recovered.

#### LITERATURE CONSULTED ON PERITONITIS WITH THE ESCAPE OF PUS AT THE UMBILICUS.

Aldis: *Gaz. méd. de Paris*, 1848, 733.

Baizeau: *Arch. gén. de méd.*, 1875, 163.

Bricheteau: *Des abcès dans le tissu cellulaire sous-péritonéal.* *Arch. gén. de méd.*, 1839, vi, 435.

Cameron, H. C.: *The Relative Value of Immediate and Delayed Laparotomy in Pneumococcal Peritonitis.* *Proc. Roy. Soc. London*, February, 1912, v, No. 4, 123.

Castel, J.: *Considérations sur la pathogénie des fistules ombilicales.* *Thèse de Paris*, 1884, No. 56.

Cazaban: *Abcès abdominal simulant une ascite; ouverture spontanée par le nombril; guérison.* *Jour. de chir.*, 1845, iii, 252.

Gauderon, A. E.: *De la péritonite idiopathique aiguë des enfants; de sa terminaison par suppuration et par évacuation du pus à travers l'ombilic.* *Thèse de Paris*, 1876, 148.

Haggard, W. D.: *General Peritonitis Cured by Incision of the Protruding Umbilicus* (personal communication).

Ledderhose, G.: *Chirurgische Erkrankungen des Nabels.* *Deutsche Chirurgie*, 1890, Lief. 45 b.

Nicaise: *Ombilic.* *Dictionnaire encyclopédique des sciences médicales*, Paris, 1881, 2. sér., xv, 140.

Vaussy, F.: *Des phlegmons sous-péritonéaux de la paroi abdominale antérieure.* *Thèse de Paris*, 1875, No. 445.

#### THE PIECEMEAL REMOVAL OF A SUPPURATING OVARIAN CYST THROUGH THE UMBILICUS.

From the following history it is clearly evident that the patient had an ovarian cyst. The suppuration was, no doubt, in a measure due to infection following the last abdominal puncture, and it is remarkable that the patient recovered. The woman came under observation over thirty years ago at a period when one hesi-

\* Gauderon: *Op. cit.*, obs. 17.

tated a long time before opening the abdomen. Now, of course, the cyst would be promptly removed.

**Inflammation of an Ovarian Cyst, Abscess Formation, Opening at the Umbilicus. Recovery.\***—Madame F., aged forty-seven, was the mother of several children. When examined on September 10, 1878, she had signs and symptoms of an ovarian cyst of three years' duration. Between September 10, 1878, and November 20, 1879, the abdomen was punctured 11 times and 170 liters of a clear, serous fluid were removed. Shortly afterward there were signs of acute inflammation in the abdomen, distention, high fever, a small pulse, vomiting, and the characteristic facial expression. It was thought that she would die. Four days later the patient was still alive, and redness was noted at the umbilicus over an area 3 by 4 cm. In six days there were signs of fluctuation, and three days later between two and three liters of pus came away from the umbilicus. Trépan pulled out and cut off with the scissors a large amount of necrotic tissue. About eighteen months after his first visit he found the patient perfectly well and she remained so.

#### LOCALIZED JAUNDICE OF THE UMBILICUS IN THE PRESENCE OF FREE BILE IN THE ABDOMINAL CAVITY.

In April, 1915, Dr. Joseph Ransohoff drew my attention to a most unusual condition, namely, localized jaundice at the umbilicus when bile exists free in the abdomen.

In the Transactions of the Southern Surgical and Gynecological Association for 1905 Dr. Ransohoff reported the case of W. B., merchant, fifty-three years old, who had had typhoid fever six years before coming under observation. In April he had what was supposed to be a mild attack of indigestion, and in August was seized with severe colicky pain in the umbilical region. The pain disappeared in five days. Ransohoff saw him in October. The patient had had a sudden chill during the night; he had had pain in the right hypochondrium, and on the next day had complained of abdominal distention and excruciating pain in the right lower abdomen.

On admission to the hospital it was noted that the patient was a large-framed man, with every indication of intestinal obstruction from peritonitis. He had an anxious facial expression; the pulse was 130; the temperature, 100° F. Examination of the abdomen revealed extreme tympany, with the liver dulness very much pushed up and reduced in area.

On inspection of the abdomen marked jaundice at the umbilicus was noted. The navel was of a distinct, saffron-yellow color, in strong contrast with the skin over the rest of the abdomen. There was no evidence of jaundice elsewhere. Tenderness was extremely marked over McBurney's point. It seemed probable that a peritonitis was present in the appendicular region. At operation the subperitoneal fat was found to be yellow, and when the abdomen was opened, a quart or more of bile mixed with serum was found. The common duct was ruptured behind the gastrohepatic ligament, the opening being large enough to admit the

\* Trépan: Kyste de l'ovaire; inflammation des parois et issue des membranes par l'ouverture ombilicale; guérison. *Gaz. méd. de Picardie, Amiens, 1883-84, ii, 168.*

tip of a finger. After removal of the abdominal fluid and draining of the common duct the man made a good recovery.

Dr. Ransohoff, after reviewing the case, says: "I wish here to call attention to a sign which was adverted to in the case of ruptured duct before the incision was made, and one to which I believe attention has never before been directed. It is the localized jaundice of the umbilicus. Although a single case is not usually sufficient to warrant the assumption that something new has been observed, this feature was so marked that I cannot refrain from believing that further observation will give to this localized jaundice some value as a sign of free bile in the peritoneal cavity. In the case presented this feature gained in interest as the staining of the subperitoneal fat with bile was observed in the incision through the abdominal wall. The jaundice is doubtless purely the result of imbibition. It makes itself manifest, first, in the integument of the navel, because this part is thinner than the rest of the abdominal wall. It is possible, of course, that, by reason of the anatomic relations of the round ligament of the liver to the transverse fissure, there is a retrograde flow of bile through the lymphatics toward the navel."



## CHAPTER XX.

### FECAL FISTULÆ AT THE UMBILICUS.

Historic sketch.

Fecal fistulæ at the umbilicus due to wide-spread ulceration of the large and small intestine.

Fecal fistulæ at the umbilicus due to gangrene.

Fecal fistulæ at the umbilicus due to external injury.

Umbilical fecal fistulæ due to burns.

Tuberculous peritonitis followed by a fecal fistula at the umbilicus; report of cases.

Umbilical fistula (not fecal) due to tuberculosis of the vas deferens.

UMBILICAL fistulæ may be due to a patent omphalomesenteric duct, to inflammatory changes commencing in the intestine and extending to the umbilicus, to carcinoma of an abdominal organ, usually of the stomach, reaching to and breaking through the umbilicus, to inflammatory conditions of the umbilicus extending to and involving the intestine, and to external injuries. All except the last two groups have been dealt with elsewhere. In the present chapter I shall refer briefly to certain cases of obscure abdominal lesions followed by fecal fistula at the umbilicus, and then describe those cases in which the fecal fistula was due to external injury of the umbilicus.

Le Cat, in 1775, reported a case of fecal fistula at the umbilicus. This case has also been recorded by Schrötter. The patient was a ten-year-old girl who had fecal masses escaping from the umbilicus. For a year before she came under observation the bowels had been sluggish. She had a poor appetite, associated with abdominal distention, and soon died. At autopsy the peritoneum was found to be as thick as a finger. The intestines were attached to the anterior abdominal wall. Below the umbilicus at one point there was an intestinal perforation, the opening communicating with the umbilicus. Between intestinal adhesions there was a considerable quantity of pus and fecal masses, and live lumbricoid worms were seen in the bowel. The mesenteric glands were enlarged, indurated, and suppurating. The intestines were ulcerated.

[At that date, of course, no histologic examination was made. The enlarged suppurating glands would naturally suggest tuberculosis.—T. S. C.]

Winiwarter, in 1877, recorded a case of fecal fistula at the umbilicus. A boy, eight months old, had suffered from boils on several occasions. Fourteen days before admission to the hospital two of these had been opened. On September 20, 1875, the child looked badly; there was an infiltration, 9 cm. in diameter, in the umbilical region. This area, which was hard and covered with reddish, hot skin, formed a conic tumor with the umbilicus in the center. Poultices were applied, and after three days the swelling opened. On September 25th the opening was the size of a linseed, and from it yellowish, grumous, intestinal contents escaped. After this nothing passed by the rectum, for a time all the fecal contents being evacuated through the umbilicus. The child died on October 25th. At autopsy a localized

peritonitis was noted at the umbilicus. Beneath the umbilicus was a hole, the walls of which were composed of intestinal loops. The fecal opening was in the colon.

As a possible cause, Winiwarter considered phlegmon of the abdominal wall. This, he said, might have tended to a localized peritonitis causing adhesions of intestinal loops. He says that an abscess in the abdominal wall may have broken into the abdomen prior to opening externally; the large bowel might thus have opened into the abscess cavity. Another explanation suggested by him was that there might have been a primary enteritis, and then a peritonitis with abscess formation near the anterior abdominal wall. No mention is made of tuberculosis, and the fact that the opening was in the colon would suggest that the original cause might possibly have been appendicitis.

Trélat, in 1883, and Nicolas in the same year, also report cases of fecal fistulæ. Trélat's patient was a girl, seventeen years of age. When the child was three years old, her mother noticed a swelling with redness and an opening at the umbilicus. As the wound would open and close from time to time, the child wore a bandage. When the umbilicus first opened the discharge had a fecal odor. The fistula was evidently of intestinal origin. There was no history of any operation. Nicolas' patient was also seventeen years of age, and it looks very much as if Trélat and Nicolas have recorded the same case. In none of these cases was it possible to determine the primary cause of the umbilical fistula.

#### FECAL FISTULÆ AT THE UMBILICUS DUE TO WIDE-SPREAD ULCERATION OF THE LARGE AND SMALL INTESTINE.

Knecht, in 1875, published the history of a strongly built man, twenty-nine years old. In 1873 he had had catarrh of the stomach which had become chronic, and, as a consequence, he had become anemic and had lost strength. After an acute attack of typhlitis there was some improvement, but after ten days the symptoms became severe again and there was a mild degree of peritonitis. After about three months immediately beneath the umbilicus there appeared a circumscribed, painful area of infiltration the size of a two-thaler piece. In addition there were several isolated areas of hardness in the right inguinal region and also above the umbilicus. Some time later an abscess in the mid-line opened and there escaped a large quantity of pus which had a fecal odor. After eight days a new abscess developed in the umbilical region. This opened spontaneously into the original abscess cavity. After about six weeks all the abscesses had united, forming one cavity. The overlying skin sloughed off, and the abdominal fascia lay free over an area the size of the palm of the hand. In the region of the umbilicus were numerous openings. The patient died a short while afterward. At autopsy there was a marked degree of emaciation and edema of the feet, together with much distention of the abdomen. In the mid-line was an ulcerated area, 17 cm. broad and 15 cm. long. This had raised and eaten-out margins, and in the center were the remains of the umbilicus. In the floor of the ulcer were openings with gangrenous walls which had led to an irregular cavity through destruction of the recti. Pressure upon it caused the escape of foul-smelling bubbles of gas. When the abdominal cavity was opened, about 10 liters of serum escaped. The abdominal contents were much displaced. The anterior surface of the cecum, the first fourth of the transverse colon, as well as a portion of the jejunum, had grown fast to the abdominal

wall on the inner side of the ulcer, and were also adherent to the posterior abdominal wall. The intestinal loops had grown fast to one another, as well as to the abdominal wall. Just above the ileocecal valve the mucosa of the ileum contained several ulcers which showed partial healing. In one of the intestinal loops adherent to the anterior abdominal wall was an opening through which a sound could be introduced from the outside. In the upper portion of the transverse colon were ulcers which communicated by a perforation with the anterior abdominal wall. There was a similar ulcer in the floor of the cecum, which communicated with a hole, lying behind the abdominal wall, and filled with pus and necrotic tissue. This cavity reached upward to the margin of the kidney and extended along the large vessels. The iliacus muscle on the right side had disappeared. In the apex of the left lung were several scars, but no fresh tubercles.

From the above history it is impossible to determine the exact starting-point of the disease. The evidence is, however, strongly suggestive of appendicitis or tuberculosis as the exciting factor.

The following case, reported by Martin, resembles in some particulars the one described by Knecht:

**Abscess of the Umbilicus; Gangrene and Intestinal Perforation; General Peritonitis. Death.**—This case was originally reported by Dr. M. E. Martin.\* L. L., aged seven, entered the hospital on December 27, 1871, and died February 28th of the following year. The child, according to her mother, had coughed for about a year, and for the last three months a swelling had been noted at the umbilicus. From time to time the child had complained of pain, and on her entrance to the hospital a tumor was detected which occupied the region of the umbilicus. This tumor was soft and fluctuating and there was redness of the skin. During January the child showed a considerable change for the worse, and on palpation an accumulation was detected deep in the abdomen and to the right of the umbilicus. On percussion dulness was noted over this area. During the process of inflammation the child complained of pain in the region of the umbilicus and in the right flank. On February 13th there was considerable distention; pain was severe on abdominal pressure, and the child vomited greenish material. The temperature rose to 39° C., the pulse to 140. The vomiting and peritonitis persisted, accompanied by diarrhea and greenish stools, for three days. On January 16th a seropurulent discharge with a definite fecal odor was noted from an orifice immediately beneath the umbilicus. On the seventeenth and eighteenth there was abundant discharge, and on the nineteenth pus, similar in character to that coming from the umbilicus, escaped from the rectum. On January 21st semisolid fecal matter commenced to escape from the umbilicus, and the fistulous opening and the tissue around the fistulous opening began to slough. On January 24th the area of sloughing had increased; the tongue was covered with sordes, and the extremities were cold.

On the following day the slough came away, and on January 27th all fecal matter was being passed by the umbilicus. The child became thinner and very weak, and died on February 28th.

**Autopsy.**—The lungs and heart were normal. At the umbilicus the area of sloughing was the size of a five-franc piece. The abdominal organs were bound to

\* Martin, M. E.: *Abcès de l'ombilic; gangrène et perforations intestinales; péritonite généralisée; mort.* Bull. de la Soc. anat. de Paris, 1872, xlvii, 148.

one another by a false membrane, and the peritoneum was intimately adherent to the abdominal wall in the right flank. There was an intestinal perforation 60 cm. from the pylorus. A portion of the ascending colon was slightly adherent to the umbilical opening, and six other perforations were noted in various portions of the intestine.

#### FECAL FISTULÆ AT THE UMBILICUS DUE TO GANGRENE.

Prior to aseptic days gangrene of the umbilicus was not infrequently observed in infants a few days old (page 73). At the present time it is seldom seen, and in the adult is a rarity. Ledderhose, in 1890, considered this subject somewhat fully. Gangrene of the umbilicus has followed the continuous use of the ice-bag, and has been associated with infectious diseases of the umbilicus. Ledderhose referred to a case reported by Fischer. An ice-bag was applied to the abdomen of an anemic patient. Twenty-four hours later the skin showed a slight bluish color, and forty-eight hours later, after further applications of ice-bags, the tissues were deep blue and there was a sensation of burning. In the course of three weeks 150 c.cm. of gangrenous skin came off. Skin-grafts were employed over the raw area, and the patient recovered. Undoubtedly the anemia favored the development of gangrene.

Ledderhose mentions two cases of puerperal infection under Thiede's care. Ice-bags were kept on the abdomen for fifteen days in one case and for twenty days in the other. Gangrene of the abdominal wall developed in each instance. Thiede did not think that the ice-bag was responsible for the gangrene, but that the causative factor was rather to be sought in the squeezing and probable injury of the abdominal wall which was produced every time the uterus was emptied or washed out.

Ledderhose further says that gangrene of the umbilicus may develop during the course of infectious diseases of the navel or after exhausting diseases involving the stomach or intestinal tract. Sometimes only the superficial abdominal walls are involved; in other cases the gangrene extends to the deeper layers of the abdominal wall and leads to a peritonitis and perforation into the intestine or bladder. The prognosis is, in general, unfavorable, but even in severe cases recovery may ensue.

#### FECAL FISTULÆ AT THE UMBILICUS DUE TO EXTERNAL INJURY.

Fecal fistulæ as a result of external injury at the umbilicus are evidently very rare. Murchison, in 1858, recorded a very interesting case that he saw with Keith, of Aberdeen. The patient was a woman with a family history replete with nervous and mental defects. She feigned illness and tried to have her arm amputated. Later, when discovered, she made believe that she had a cardiac lesion. Finally, she produced an opening between the skin and the stomach. Through this gastric fistula some interesting experiments were made. Murchison collected the cases in which the stomach opened upon the abdomen and found that the break seldom, if ever, occurred at the umbilicus.

Grawitz and Nicolas both record examples of an umbilical fistula due to a cut, and Frömmüller tells of a fistula due to injury produced by a long finger-nail.

Grawitz showed a specimen coming from a Pole, who, in 1849, was wounded in the umbilical region with a scythe. A fecal fistula developed and persisted for the remaining thirty years of his life. The patient during his late years grew thin and

very weak, and finally died of marasmus. Several attempts were made to close the opening, but without success. (This was before 1878.) There was a defect in the abdominal wall as large as the palm of the hand. The opening was in the small bowel, about 1 meter from the stomach.

Nicolas refers to a patient who had been examined by Fromantin.\* The patient was a soldier who had received a cut in the umbilical region. The opening was small, and Fromantin thought little of it, although it occasioned much pain. On the tenth day there was some discharge with a fecal odor. The opening was dilated, and a quantity of fecal matter escaped. The fistula gradually diminished in size and closed.

Fronmüller reported the case of a man, forty-eight years of age, who had long finger-nails and was of rather uncleanly habits. After an attempt to remove some foreign body from the umbilicus with his finger-nail, pain and swelling in the umbilical region came on gradually. When seen fourteen days later the patient had a yellowish discharge from the umbilical depression. The umbilicus was rather tense, red, and half-moon-shaped on its right side and painful on pressure. On the floor of the umbilicus was a large, red, fleshy mass, and fluid was seen coming from a very fine opening. A sound introduced passed two inches into the adherent bowel. When the patient lay on his right side, the amount of the discharging fluid increased. The patient had a feeling of tension in the umbilical region. Three days later silver nitrate was applied, followed by a second treatment after two days. Four days after the second treatment a pinkish-red tumor developed in the left side of the umbilicus. This was accompanied by much pain. It broke two days later and a yellowish-white, foul-smelling fluid escaped. A second fistulous opening now formed into which a sound could be carried three and one-half inches. From time to time other fistulæ developed until six were counted.

When the patient was seen four and one-half months later, all these fistulæ had healed, and the man was in good condition. Fronmüller reported this case on account of its unusual character and as an example of a fistula due to injury from without and not from within.

#### UMBILICAL FECAL FISTULÆ DUE TO BURNS.

In the course of a conversation with Dr. Jesse W. Hirst, of the Severance Hospital, Seoul, Korea, he told me that in Korea the most frequent umbilical lesion is a fecal fistula. This is due to the common mode of treatment in cases of abdominal pain or peritonitis.

The natives take a piece of cotton-wool and some dried fungus, roll the two into a small lump, and lay it on the painful area. A match is applied and the roll is allowed to burn. The result is a sore about three-quarters of an inch in diameter, and usually only skin deep. The desired result, namely, a running sore, is obtained. This application is made in some instances three or four times. If there is pain or swelling in the umbilical region, the application is made over the umbilicus and frequently the surface of an umbilical hernia is burned.

Dr. Hirst observed about 15 cases in which such applications had been made at the umbilicus, and in three a fecal fistula developed. The cause of the fistula is

\* Fromantin: *Mém. d. l'Acad. de chir.*, Paris, 1743, i, 602.

evident. The burning is sufficient to set up a localized peritonitis, intestinal loops become adherent, and a fistula results.

#### LITERATURE CONSULTED ON FECAL FISTULA AT THE UMBILICUS.

(See also literature at end of this chapter.)

- Fronmüller, G.: Kothfistel im Nabel. *Memorabilien*, Heilbronn, 1866, xi, 273.
- Gauderon: De la péritonite idiopathique aiguë des enfants; de sa terminaison par suppuration et par évacuation du pus à travers l'ombilic. Thèse de Paris, 1876, No. 148.
- Grawitz: Berlin. klin. Wochenschr., 1878, xv, 9.
- Knecht: Ausgebreitete Ulcerationen im Dick- und Dünndarm, mit Perforation der vorderen Bauchwand. *Arch. d. Heilkunde*, 1875, xvi, 539.
- Le Cat: Sur un engorgement par congestion dans toute l'étendue du péritoine devenu suppuratoire, compliqué d'adhérence et d'ulcération des intestins avec issue des matières fécales par l'ombilic. *Jour. de méd.*, 1755, ii, 356. Also reported by Schrötter: *Arch. f. Kinderheilk.*, 1902-03, xxxv, 398.
- Ledderhose: *Deutsche Chirurgie*, 1890, Lief. 45 b.
- Martin, M. E.: Abcès de l'ombilic. Gangrène et perforations intestinales; péritonite généralisée, mort. *Bull. de la Soc. anat. de Paris*, 1872, xlvi, 148.
- Murchison, C.: Communication with the Stomach through the Abdominal Parietes Produced by Ulceration from External Pressure. *Med. Chir. Transactions*, London, 1858, xli, 11.
- Nicolas, P.: Sur deux variétés de fistules ombilicales. Thèse de Paris, 1883.
- Trélat: Fistules ombilicales. *Jour. d. conaiss. méd. pratiques et de pharm.*, 1883, l, 364.
- Winiwarter, A.: Fistula stercoral. umbilic. *Jahrb. f. Kinderheilk. und physische Erziehung*, N. F., 1877, xi, 193.

#### TUBERCULOUS PERITONITIS FOLLOWED BY A FECAL FISTULA AT THE UMBILICUS.

As pointed out by Feulard, the opening at the umbilicus of a tuberculous process in the peritoneum is not rare. Fischer observed three cases, in two of which there was a fistulous opening between the bowel and the umbilical depression. The subject has been carefully considered by Nicaise, Ledderhose, Tillmanns, Ziehl, Owen, and others.

When a tuberculous peritonitis exists in children, there seems to be a definite tendency for it to open at the umbilicus. Helmreich (quoted by Schrötter) claimed that of all known cases of abdominal fistula, three-fourths developed at the umbilicus. This seems to tally with the experience of other observers. Heinrich, in 1849, drew attention to several cases in which the opening was in the abdominal wall near the umbilicus.

Ziehl, in 30 cases of abdominal fistula following tuberculous peritonitis in children, found that in 18 cases the opening was at the umbilicus.

In order that we may get a clear idea of this class of cases I have assembled a group which depicts the salient features of the disease. No attempt has been made to collect all the cases recorded in the literature. We here have records of 19 cases. Sixteen of the patients were children. The youngest was one year old. Eleven were under ten years of age, and five between ten and sixteen years of age, these figures being in accordance with the claims of previous writers that fecal fistula at the umbilicus due to tuberculous peritonitis is most common in childhood; only 3 of the 19 patients were adults.

Symptoms.—The previous history in these cases, as a rule, is colorless, but in a

few instances is of value. Crooke's patient had previously complained of pain in the hip, and was of a scrofulous diathesis. Clairmont's gave a history of a previous pulmonary affection. One of Ziehl's patients had suffered from rickets, and another from tuberculosis of the lungs. Rachford's patient also gave a similar history.

The children usually first complain of abdominal distention, with or without pain. This increases, the appetite gradually diminishes, and emaciation follows. Constipation develops, and may or may not alternate with diarrhea. As the disease advances the temperature frequently rises. The pulse becomes rapid and small, the tongue is coated, and the breath fetid. Chills may accompany the fever, and, if the lungs be involved in the tuberculous process, severe coughing and night-sweats may be present, and pleurisy may be detected.

The abdominal enlargement continues to increase, and it may be possible to detect solid masses or an accumulation of abdominal fluid. Occasionally the diagnosis of tuberculous peritonitis may be rendered more definite by a rectal examination. In two of Schmitz's cases he was able, with his finger in the bowel, to detect small nodular masses in the pelvis.

After a varying length of time the umbilicus may become altered in appearance. The changes may occur in a few months, but, as in a case recorded by Nicaise, a year and a half may elapse before the slightest difference can be detected. The picture varies considerably. In Catteau's case a tumor, 3 cm. in diameter, and forming a semicircle, was noted. There was discoloration of the skin and the tumor was transparent. In Baginsky's case there was a half-moon-shaped thickening with the convexity directed downward. The skin was tense and edematous; reddening followed, and later a fistula developed, pus and fecal matter escaping. Ziehl's patient, who was nearly four years old, had a circumscribed edema at the umbilicus, and immediately around the depression were small, shot-like nodules in the skin. The umbilicus ruptured, and a large quantity of fluid escaped. The abdomen collapsed, and later a round worm was passed through the umbilical opening. In Vallin's case there was marked abdominal reddening for a distance of 5 to 6 cm. around the umbilicus. The tissue was edematous, and the umbilical folds were distended. This condition persisted for two months. The redness then disappeared, and a nodule the size of a walnut and containing gas and fluid appeared at the umbilicus. In Crooke's case there was a marked prominence at the umbilicus, followed by the escape of pus and feces. In Rintel's case the umbilical ring opened and pus escaped with great force. In Schmitz's eleven-year-old patient the umbilical walls were exceedingly thin, and gas and fluid could be seen through the skin. Bertherand's patient had a conic umbilicus and a prominence the size of an almond. The overlying skin was mottled. The tumor contained fluid with gas, and could be reduced.

From the foregoing it will be noted that the inflammatory changes at the umbilicus are of slow development, and that the abdominal fluid reaches the surface by two methods—either by gradual disintegration of the abdominal wall or by distention of the umbilical opening, which allows the fluid to escape into the hernial protrusion. In addition to the opening at the umbilicus a secondary one may develop in the vicinity.

The tuberculous process gradually advances, and, if the lungs have not already been involved, they are apt now to be implicated. The child grows weaker and weaker, and usually dies a few weeks after the umbilicus has opened.

**A u t o p s y F i n d i n g s .**— At the umbilicus the fistula found varies from one to several millimeters in diameter. The surrounding skin may or may not show marked irritation, depending upon the situation of the opening into the bowel and on the irritating character of the discharge. In some cases the skin, fascia, muscle, and peritoneum are so intimately blended as a result of the inflammation that it is almost impossible to separate them.

When the abdomen is opened, a loop of small or large bowel is often found firmly fixed to the opening at the umbilicus, and it is from this that the feces escape. Sometimes two or more loops are adherent to the umbilicus. In those cases in which the umbilicus was distended and gas and feces could be distinctly made out, there was usually a cavity of considerable size lying immediately beneath the umbilicus. At one or more points the lumen of the small bowel or of the large bowel, or the lumina of both, communicated with the cavity. The walls of the cavity were composed of intestinal loops alone, or of intestinal loops, one or more of the abdominal organs, the omentum, and the abdominal wall. When the intestinal perforation occurs, the surrounding tissue naturally tends to wall it off at once if adhesions have not already formed. The cavity may be small, or occupy fully half the abdomen. Its inner surface resembles granulation tissue, and it contains pus and fecal matter. Definite tuberculous masses have in some cases been noted in the wall of the sac. The intestinal loops throughout the abdomen are usually adherent, and between them are tubercles, accumulations of serous or flocculent material, or pus, according to the stage of the disease and the presence or absence of a mixed infection.

In those cases in which sudden death has occurred, as in those of Bertherand and Vallin, the walls of the cavity have given way, allowing fecal matter to escape into the general abdominal cavity. With the patient in an already weakened condition, the shock has been sufficient to occasion sudden death.

An associated pulmonary tuberculosis is often noted at autopsy.

**D i f f e r e n t i a l D i a g n o s i s .**— In making the diagnosis it is necessary to exclude the possibility of an umbilical concretion, carcinoma, other forms of peritonitis opening at the umbilicus, and other umbilical fistulæ. Umbilical concretions occur during the active working period of life; tuberculous fistulæ preponderate in childhood. Carcinoma is also a disease of middle life or of old age, and is thus readily excluded. Any form of peritonitis followed by an escape of pus, and possibly feces, at the umbilicus may at first be confused with tuberculous peritonitis. The onset of a purulent peritonitis is, however, usually very acute; the disease runs a rapid course, and the child either speedily dies or rapidly recovers. Umbilical fistulæ due to round worms escaping through the bowel and passing out through the umbilicus may for a time occasion some confusion, but with the escape of the worms the fistula may close, while in cases of tuberculous peritonitis the condition goes from bad to worse.

**T r e a t m e n t .**— With the early recognition of tuberculous peritonitis and its appropriate treatment—laparotomy—cases of umbilical fistula will naturally diminish in number. As emphasized by Tillmanns, poultices are to be strenuously avoided. As has been said, the umbilicus may be reddened for months without the formation of a fistula, but once feces commence to escape by this channel, the fistula remains open until death.



CASES OF TUBERCULOUS PERITONITIS WITH A FECAL FISTULA  
DEVELOPING AT THE UMBILICUS.

Umbilical Fecal Fistula Due to Tuberculous Peritonitis.\*—A boy, one year and three months old, was admitted to the hospital on December 23, 1879, for an otitis purulenta. He was fairly well nourished and showed no signs of rickets. The abdomen was hard and distended. At the umbilicus was a half-moon-shaped thickening, with the convexity directed downward; the overlying skin was tense and edematous. The condition remained the same until February 9, 1880. At this time examination of the thorax was negative. Around the umbilicus, especially in the lower portion, there were edema and reddening. There was definite fluctuation. The abdomen itself was hard and distended, but no palpable tumor could be detected. On February 12th an opening, the size of a bean, was detected at the umbilicus, and from this a considerable quantity of fecal material and purulent fluid escaped. When the child was raised up, these fecal masses escaped readily. He died on February 13th.

At autopsy the body was markedly emaciated and anemic. The lower lobe of the right lung was reddish gray. The costal pleuræ and the diaphragm and pericardium were covered with grayish miliary tubercles. The diaphragm, liver, and spleen were completely adherent to the abdominal wall. The purulent cavity beneath the umbilicus was walled off by these and the omentum, and the cavity extended into the pelvis. The pelvis was filled with feces and purulent fluid, and the intestinal convolutions of the lower abdomen were covered with a greenish, necrotic deposit, and at several points were perforated. Through one perforation the little finger could be passed into the small bowel. At this point the vermiform appendix had ulcerated. On the left side of the transverse colon were numerous ulcers, some of which had extended only through the mucosa. At other points they had perforated the entire thickness of the bowel, opening into a cavity situated at the vertebral column. The mesenteric glands were markedly swollen and caseous. In the spleen were numerous nodules.

Intestinal and Peritoneal Tuberculosis with Perforation and the Formation of a Fecal Reservoir Opening at the Umbilicus.†—A soldier came under observation on September 21, 1851, on account of obstinate diarrhea. On February 16, 1852, he had severe abdominal pain and dysuria. On May 12th of the same year for the third time he presented the picture of marked disturbances of nutrition. His pulse was rapid and small, and there was marked emaciation. Diarrhea was present, and he had a dry cough and night-sweats. The abdomen was very painful and distended. From the pubes to a point above the umbilicus was a doughy, immovable tumor of nodular character. All indications pointed to a chronic mesenteric inflammation. On June 10, 1852, there developed beneath the umbilicus a conic prominence the size of a large almond. The skin over it was mottled. The tumor was reducible and filled with fluid and gas. A few days later the prominence was incised, and there escaped blood, pus, foul-smelling gas, and a little later fecal matter. Fecal

\* Baginsky: Zur Demonstration eines Präparates. Verhandl. d. Berl. med. Gesellschaft, Jahrg. 1879–80, xi, 90.

† Bertherand, A.: Observation d'entéro-péritonite tuberculeuse avec perforations intestinales, formation d'un réservoir stercoral sous la paroi abdominale; fistule ombilicale. Gaz. méd. de Strasbourg, Novembre, 1852, douzième année, 572.

matter also passed through the rectum. During the night of June 18th the patient raised himself suddenly and died with a loud cry.

At autopsy it was found that there was a deep pus-cavity behind the umbilicus. This was filled with old pus and tuberculous masses. The anterior wall of the cavity appeared to be formed of the posterior surface of the transversalis muscle and remains of the peritoneum. The posterior wall was bounded by two thick layers of large omentum, which laterally was adherent to the peritoneum, thus fastening the intestinal loops together. The inner irregular cavity communicated behind and above with the transverse colon through two holes, 15 and 18 mm. in diameter. At the end of the ileum were three openings with sharp margins, probably resulting from freshly broken-down tubercles. From these had escaped the fresh fecal masses which were found in the abdomen, and thus the sudden death is explained. There was a direct connection between the umbilical opening and the pus-sac.

In this case there was also a pulmonary tuberculosis.

**Tuberculous Peritonitis with Dilatation of the Umbilical Ring.**\*—A man, forty-one years of age, had a peritoneal tuberculosis. At the umbilicus was a transparent tumor, 3 cm. in diameter, forming three-quarters of a circle. There was no discoloration of the skin. The tumor was easily reducible, and the finger could be carried into the abdomen. [This was evidently a small umbilical hernia containing ascitic fluid. It is recorded here to show the early umbilical changes before a fecal fistula has developed.—T. S. C.]

**Fecal Fistula Probably Due to Tuberculous Peritonitis.**†—A boy, fifteen years old, in 1897 had inflammation of the lungs and also of the abdomen. In June of the same year he complained of pain in the abdomen and noticed a swelling. Owing to increased pain and fever the patient went to bed in September. In October pus was found escaping from the umbilical region. After this the pain eased up, but a fistula persisted, and there was a varying degree of pain. In April, 1898, the pain became severe in the right side. In June, 1898, the boy appeared to be well developed and showed no definite changes in the chest, but the abdomen in the umbilical region was still distended. At the umbilicus the fistula still secreted a little, and occasionally a small amount of fecal matter escaped.

**Operation.**—Under ether below the fistula a resistant area, about the size of a five-mark piece, could be felt. Pressure on this caused a discharge of pus. The fistulous tract was dissected out, and during the manipulations a second loop of bowel was opened up, but was closed immediately. The opening in the bowel was about the size of a five-pfennig piece, and the walls of the bowel at this point were infiltrated. In addition, there were numerous loops of small bowel adherent to the anterior abdominal wall in the region of the umbilicus. The portion of the bowel forming the fistula was resected. Extraperitoneally and to the left of the umbilicus was a caseous focus, 4 cm. long and 2 cm. broad. This was drained. At operation the ends of the bowel were held in place by a Murphy button, which came away on the eleventh day.

[This case seems to be one of tuberculous peritonitis.—T. S. C.]

\*Catteau, J. F.: De l'ombilic et de ses modifications dans les cas de distension de l'abdomen. Thèse de Paris, 1876, obs. 10.

†Clairmont, Paul: Casuistischer Beitrag zur Radicaloperation der Kothfistel und des Anus præternaturalis. Klinik, Prof. v. Eiselsberg, Königsberg. Langenbeck's Arch. f. klin. Chir., 1901, lxiii, 691.

**Tuberculous Peritonitis Followed by Perforation at the Umbilicus.**\*—An eleven-year-old boy with a definite scrofulous diathesis had suffered for eighteen months from vomiting and from pain in the hip. At the umbilicus there was also pain. The child lay with his thighs drawn up. Some time later marked diarrhœa was noted and severe pain in the umbilical region. This, in the course of six weeks, became markedly prominent as a result of abscess formation. About three weeks later there was a spontaneous opening at the umbilicus, with the escape of purulent fecal masses. A month later a similar tumor developed, two and a half inches below the umbilicus. This broke at three points. From the upper opening fecal matter escaped, while the lower discharged serous material. The bowels were regular, and the appetite was good. In the course of six weeks the abdomen became flattened and the pulse small; the appetite was poor. There was marked pain at the umbilicus. Three months later the child died.

At autopsy the omentum was found adherent to the abdominal wall. The underlying intestines had grown fast to one another. Tubercles were found in the left iliac region, under the descending colon, and also beneath the peritoneum of the anterior stomach-wall. In the lower part of the ileum, about six inches from the cecum, were the remains of a large tubercle which had broken down. Here it was found that the intestine had become adherent to the umbilicus and communicated with the opening from the bowel. In the peritoneum itself were several minute tubercles. The spleen was enlarged, and the mesenteric lymph-glands were hard and gritty.

**Tuberculous Fistula at the Umbilicus.**†—This case came under Habershon's observation. The patient was a small girl, six years old, who had had chronic peritonitis for a year. Six months before her death a tumor appeared at the umbilicus. This opened, and a fistula resulted from which pus mixed with fecal matter escaped. At autopsy pulmonary and peritoneal tuberculosis was found. The intestines were adherent; several loops had perforated, and a fecal fistula had formed, with an exit at the umbilicus.

**Probable Tuberculous Fistula at the Umbilicus.**‡—The patient was a small Italian child. There was a fecal discharge from the umbilicus, through several openings. The child died of tuberculous peritonitis.

**Artificial Anus Established Spontaneously Through the Umbilicus.**§—A boy, nine years old, had been under treatment for six months on account of a peritoneal and pulmonary tuberculosis. In February, 1891, the umbilical region was found to be sensitive, red, and more prominent than the already distended abdomen. On February 13th the boy's father came and said that the abdomen had flattened out and that the stools were coming from the umbilicus. Eight pressure was made on the abdomen, and gas and fecal matter escaped through an opening, and the boy felt as well as usual. Six hours later his temperature was 99° F., and fecal matter and gas continued to escape from the

\* Crooke, E. G.: On a Case of Tubercular Peritonitis Followed by Perforation of the Abdominal Parietes. *The Lancet*, 1849, ii, 668.

† Nicaise: *Ombilic*. *Dictionnaire encyclopédique des sc. méd.*, Paris, 1881, 2. sér., xv, 140.

‡ Park, Roswell: *Clinical Lecture on Congenital Fistulæ and Sinuses at the Umbilicus*. *Med. Fortnightly*, 1896, ix, 9.

§ Rachford: *Arch. of Pediatrics*, 1891, viii, 680.

umbilicus. From the rectum no stools passed. By means of a bandage the feces could be entirely controlled. After the perforation at the umbilicus the boy felt better and developed an appetite, and his night-sweats disappeared. On March 10th he complained of sudden pain in the abdomen, collapsed, and died the next day.

Autopsy.—Only the abdomen could be examined. The intestines had been transformed into a large, hard tumor, as a result of tuberculous masses. In the transverse colon was a round perforation the size of a ten-cent piece, with thick margins. On the outer side of the intestine, around the opening, was a rough, red circle about an inch and a half in diameter, where the intestine had been adherent to the abdominal wall around the umbilicus. The umbilical opening passed into a cavity which was filled with fecal matter. From this, one opening was found entering the ileum and another the ascending loop of the transverse colon. Scattered throughout the peritoneum were tubercles. Some showed definite inflammation, others had gone on to suppuration.

The bowel had evidently torn partly loose from the abdominal wall, allowing the fecal matter to escape into the general cavity. This explains the faintness with the pain and collapse that followed.

A Case of Tuberculosis of the Intestine with Perforation of the Duodenum and Cecum into the Peritoneal Cavity. Fecal Fistula at the Umbilicus.\*—A three-and-one-half-year-old girl complained of pain in the abdomen and of loss of appetite. Over the surface of the distended abdomen bluish, dilated veins were noted. There was free fluid in the abdomen. In the inguinal region on both sides the glands were enlarged. After two months pain and severe fever developed, and two days later the umbilical ring opened and there was an escape, with great force, of a purulent fluid having a foul odor and mixed with yellow fecal matter. Fecal matter continued to escape from this opening and also from the rectum until the child's death. Emaciation increased; the urinary secretion stopped almost completely. The child died a month after the umbilical opening appeared.

At autopsy the abdomen was markedly distended, especially in the vicinity of the umbilicus, where there was an opening the size of a pin-head. On pressure, clear, yellow, thin fecal material escaped drop by drop.

A fine sound could be passed directly downward to the vertebral column. On palpation very hard nodular masses could be felt around the umbilicus. When the abdomen was opened, the anterior wall above the umbilicus was found adherent to the omentum. On the opposite side the wall was united with the transverse colon by thick, firm adhesions. Here had formed the cavity that communicated with the umbilicus through the canal mentioned, and through an opening into the duodenum the size of a Groschen (five-cent piece). Just below the opening of the bile-duct there was another perforation into the colon. The cavity produced was filled with fecal masses, and the small intestine was involved in the exudate. In the cecum was an ulcer which extended almost to the peritoneal surface, and directly at the ileocecal valve was another perforation. The vermiform appendix had also been destroyed. The upper part of the cecum and the lower part of the ileum were firmly glued to the wall of the cavity. There were numerous ulcers throughout the intestines. Both lungs were normal.

\* Rintel: Ein Fall von Darmtuberculose mit Perforation des Duodenum und Cæcum in's Cavum peritonæi. Berlin. klin. Wochenschr., 1867, iv, 332.

**Tuberculous Fecal Fistula at the Umbilicus.\***—A girl, fourteen years old, at first complained of severe abdominal pain in the hypogastric, hypochondriac, and umbilical regions. Several months later she returned to the hospital with a round opening at the umbilicus. Its margins were slightly excoriated, and fecal matter was escaping. Her constitution had been weakened, and general tuberculosis had existed for six months.

At autopsy pelvic peritonitis was found. The intestinal loops were adherent to each other, and between them were purulent foci. A loop of small bowel had opened at the umbilicus.

**Cases of Fecal Fistula at the Umbilicus Due to Tuberculous Peritonitis.†**—Case 1.—A girl, eleven years of age, had been ill for three or four months. She had had abdominal distention with diarrhea and was emaciated. On admission the abdomen was much distended. At the umbilicus there was sensitiveness on pressure. The umbilicus was covered over with very thin skin, and immediately beneath were gas and fluid. The patient's temperature was subnormal.

An incision was made opening up a fecal abscess, at the bottom of which was an intestinal fistula. The child died on the tenth day.

At autopsy the organs of the lower abdomen were found grown together and forming a tangled mass. Between them were numerous caseous foci. Opening into the posterior wall of the umbilical abscess were several small holes which communicated with the intestine. There was a total adhesive pericarditis.

Case 2.—A boy, six years old, for two and one-half months had had fever, pain in the abdomen, and vomiting. For one month he had had obstinate constipation. The abdomen had increased in size, and emaciation had become marked. For one week there had been a reddening at the umbilicus. The mesogastrium and hypogastrium were filled with nodular tumors. On rectal examination minute hard nodules could be felt. The child had intermittent fever.

Operation.—Beneath the umbilicus was a large, foul-smelling accumulation of pus. The abdomen was studded with tubercles. The omentum was markedly adherent. When the bandages were changed, an abundant quantity of fecal matter came out of the cavity. The fever continued, and the patient died three weeks later.

Autopsy.—Folds of the peritoneum were adherent to one another at many points. Between them were isolated and confluent tuberculous nodules. Similar nodules were also found in the omentum. In the ascending colon was a perforation admitting the tip of the finger. About 20 cm. above this point was a small group of miliary tubercles in the mucosa. In the lower portion of the large bowel were several flat ulcers with thickened margins. The remaining portion of the intestinal tract was normal. In the pelvis, between intestinal loops, was an isolated abscess, and the liver and spleen were covered with adhesions. There was a pleurisy on the left side. The pleuræ of both lungs were studded with tubercles. The bronchial glands were swollen.

Case 3.—A girl, nine years old, from September, 1892, had had acute

\* Rombeau: Anus contre nature, suite de péritonite. Bull. de la Soc. anat. de Paris, 1851, xxvi, 366.

† Schmitz, A.: Ueber Bauchfelltuberculose der Kinder. Jahrb. f. Kinderheilk., 1897, xlv, 316.

abdominal pain, fever, and obstipation, and there had been a gradual increase in the size of the abdomen. In May, 1893, a swelling at the umbilicus associated with redness was noted. The mass was of the size and form of a fist. It broke, and feces escaped. In July the patient was markedly anemic and the abdomen was enlarged and painful. At the lower margin of the umbilicus was a fecal fistula, which was discharging the contents of the small bowel. The inguinal glands were swollen. By the rectum several flat nodules could be felt.

Operation.—The omentum was adherent to the small intestine and to the parietal peritoneum. Numerous hard nodules, some as large as a pea, were found. The umbilical fistula led to a fecal opening the size of a walnut. This communicated with a loop of small bowel by an opening, 3 cm. in diameter. The patient died five days later.

At autopsy general adhesions of the intestine with the parietal peritoneum, the omentum, and liver were found. There were also numerous peritoneal tubercles. In the capsules of the liver and spleen were tubercles. The uterus was increased in size; its cavity was dilated and filled with cheesy pus, and the mucosa was covered with a cheesy membrane. In the ileum was a perforated ulcer, 1.5 cm. in diameter. The fistula in the ileum had been closed tightly at operation. The mesenteric glands had undergone caseation. The mucosa of the intestine was swollen, but free from tuberculous ulcers.

**Tuberculosis of the Umbilical Region.\***—A boy, sixteen years of age, was said to have had a fall in the latter half of 1895. Before admission the abdomen had become much distended. Immediately before the operation it was noted that, for his age, he was larger than usual and very thin. The abdomen was markedly and uniformly distended; the umbilicus was pushed forward somewhat like a bladder. The skin was of the thinness of paper. Surrounding the umbilicus the tissue was red and painful on pressure, and over the entire abdomen there were dulness and a sensation of fluctuation.

On April 17, 1896, an incision was made extending from the ensiform cartilage through the umbilicus to three fingerbreadths above the symphysis. There escaped between 10 and 12 liters of very cloudy, odorless fluid, which contained numerous white, grayish flocculi and a membranous network. The greater amount of fluid was found in the anterior portion of the sac. On pressure and when the patient was turned on his side, however, an abundance of fluid escaped from the posterior portion. Schrötter thought he was dealing with tuberculosis, but no tubercle bacilli were found and no tissue that histologically gave that picture. [In this case no fistula existed.—T. S. C.]

**Umbilical Fecal Fistula Due to Tuberculous Peritonitis.**—Schrötter† (p. 415) reports an observation by Jung.

The patient was a scrofulous, emaciated child, three years and nine months old. The abdomen was distended, especially around the umbilicus, where, after the application of poultices, an abscess formed. This broke, and feces, pus, and blood escaped. The child died, and at autopsy the intestines were found adherent to one another and to the peritoneum. The intestine at one point had perforated.

\* Schrötter: Zur Kenntnis der Tuberculose der Nabelgegend. Arch. f. Kinderheilk., 1902-03, xxxv, 398.

† Schrötter: Op. cit., p. 415. Rhein. Generalbericht. Ref. Canstatt's Jahresbericht, 1842, ii.

**Peritoneal Tuberculosis with Fæcal Fistula at the Umbilicus.**\*—An eight-year-old girl had swelling of the abdomen. Her tongue was coated, the breath was fetid, and she had a severe cough. Her skin was of a dark brownish color. She had diarrhea, and there was edema in the lower part of the abdomen and in the legs. Indefinite fluctuation could be made out in the lower abdomen. Later on the lower abdomen presented a conic form, the umbilicus forming the point of the cone. It opened, and from it escaped brownish fecal material of a very foul odor. No feces passed through the rectum from that time. Three weeks later the patient died.

At autopsy the intestines were found adherent to one another and to the abdominal wall, except in the lower right side, where, between the anterior wall and the intestine, fecal masses were found. The whole of the peritoneum, both that covering the abdominal wall and that of the viscera, was riddled with tubercles, some of which had become caseous. The mesenteric glands were enlarged and tuberculous.

In this case there was tuberculous disease of the mesenteric glands with a healthy intestinal mucosa.

**Umbilical Inflammation Following Tubercular Peritonitis.** †—A soldier, twenty-two years of age, who is said to have been previously healthy and strong, a month before admission noticed a swelling of the abdomen. His appetite diminished, he had obstipation alternating with diarrhea, but never vomited and had no cough. On December 8, 1867, there was abdominal distention. Palpation, however, was not painful. In the hypogastric region was a definite fluctuation. On December 20th he noticed a marked reddening around the umbilicus. The skin in the umbilical region, for a distance of 5 or 6 cm., was edematous, and the umbilical folds were distended. There was no pain, and the overlying skin was not sensitive. The reddening and edema remained unchanged for two months. At the end of January the exudate in the abdomen had disappeared, but the distention had increased and the patient was cachectic. He had fever, a dry, hot skin, and marked night-sweats. The umbilicus remained the same. Commencing February 16th a pleurisy was noticed, and the weakened condition of the patient increased. There was diarrhea. The skin at the umbilicus was not so red, but for fourteen days had taken on a yellowish color, and at the umbilicus there was a small, irreducible tumor the size of a walnut, which contained gas and fluid. On February 27, 1868, at 4 o'clock in the morning, the patient felt something tear. The umbilicus broke, and there was an abundant discharge of cloudy fluid with a feculent appearance. He died an hour later.

At autopsy marked emaciation was noted. The abdomen was sunken. The umbilical scar on the left side was irregular and torn, and there escaped on light pressure a yellow, diarrhea-like fluid. The anterior abdominal wall was difficult to loosen on account of extensive adhesions to the intestine and omentum. The muscle, aponeurosis, and skin were thickened, and had grown fast to one another, so that their separation was possible only by careful dissection with the knife. The liver, stomach, and transverse colon were firmly united to the abdominal wall.

\* Scott, John: Perforation of the Intestine with External Opening. *Edinburgh Med. and Surg. Jour.*, 1835, xliii, 97.

† Vallin, E.: De l'inflammation périombilicale dans la tuberculisation du péritoine. *Arch. gén. de méd.*, 1869, xiii, 558.

Several loops of small bowel, which were tied to one another by a pseudomembrane, had been invaded by softened tubercles. These were adherent to the abdominal wall at the point mentioned. Between the umbilicus posteriorly and the ulcerated intestinal wall was an irregular cavity, through which fecal masses had passed outward into the abdominal cavity. A transverse section through the abdominal cavity at this point allowed one to see the intimate relation between the parietal peritoneum, the aponeurosis of the transversalis, and the recti muscles. In this case the omentum and mesentery were matted together with tubercles in all stages. The mesenteric glands were markedly enlarged and some had softened. The intestinal mucosa as a whole was normal, and, as far as could be seen, not ulcerated. One could readily see that the perforation of the intestine had been from without inward. The mucosa at this point was markedly pigmented and infiltrated with blood. It was through this cavity that the intestinal contents during life had passed out at the umbilicus.

*Tuberculosis of the Umbilical Region.\**—Case 1.—St. W., aged six, was small and gave evidence of having outgrown rachitis. When admitted to the hospital on April 30th the child showed marked emaciation. The abdomen was greatly distended and balloon-shaped. At the level of the umbilicus the girth was 60 cm. Above the symphysis there was dulness for a handbreadth. There was no free fluid and no fever. The appetite was good. On May 16th the patient complained of pain in the lower abdominal region, and redness was noted at the umbilicus. Three days later the reddening became marked and there was some fever. On May 23d the pulse became weak and the lower part of the abdomen was painful. On the twenty-seventh, in the median line at the umbilicus, there was noted a perforation from which fecal matter and yellow fluid escaped. The abdominal measurement had diminished. On June 3d the abdominal distention had again increased somewhat and there was only a slight discharge. On the seventeenth the patient felt hot, and an accurate examination could not be made on account of severe pain. The discharge from the umbilicus contained remnants of digested food and had an acid reaction. The patient suffered from diarrhea. He died on June 22d.

At autopsy, twenty-four hours later, there was a bluish discoloration of the abdominal wall and marked emaciation. At the umbilicus was a bluish-red point, and in the center of this a fistulous opening the size of a goose-quill. When pressure was exerted on the lower abdominal wall, yellow fecal masses escaped. A sound could be passed inward for 2 cm. The discoloration of the abdominal wall indicated a cavity which extended downward from the umbilicus and occupied the greater part of the lower abdomen. It was lined with reddish gray, partly granular walls, which contained numerous nodules. Through softened places in the sac-wall a sound could be passed into the intestinal lumen. In the posterior wall of the cavity was a membrane which covered the indefinite intestinal loops. The cavity contained fluid, solid fecal masses, caseous products, and round worms. The intestinal follicles were markedly swollen and here and there ulcerated. The mesenteric and retroperitoneal glands were enlarged, and at certain points ulcerated to the extent of perforation.

\* Ziehl: (Cited by Schrötter: Zur Kenntnis der Tuberculose der Nabelgegend. Arch. f. Kinderheilk., 1902-03, xxxv, 398.) Ueber die Bildung von Darmfisteln in der vorderen Bauchwand infolge von Peritonitis tuberculosa. Heidelberger Dissertationschrift, 1881.



Case 2. — K. A., three years and nine months old. In January there was vomiting accompanied by swelling of the abdomen. The abdomen was markedly distended, the circumference at the umbilicus being 68 cm. There was tuberculosis of the lungs, slight edema of the lower extremities, and fluid in the lower abdomen. On March 31st the abdominal girth was 71 cm. and the inner abdominal wall appeared to be infiltrated. On April 6th the child had measles, accompanied by a mild cough without expectoration. Nine days later the skin beneath the umbilicus showed circumscribed edema. On May 8th, after the use of santonin, round worms were expelled through the rectum. On May 9th it was noted that the lower abdomen was the seat of what appeared to be a rather large tumor. It began a finger-breadth below the free margin of the ribs on the left, and extended within two finger-breadths of the symphysis. It was resistant and had a nodular surface. The child had attacks of fever and chills. The stools were normal. On September 13th around the umbilicus were noted small tumors, which felt like shot. In the hypogastrium was a definite tumor which impinged on the liver and which, on the left, was connected with the umbilical swelling. On October 19th the abdomen was painful, the umbilicus ruptured, and there was an escape of an abundance of purulent fluid with a fecal odor. On the following day the flow of fluid still continued, and the fistulous opening was the size of a linseed. The abdomen collapsed and was very sensitive; there was diarrhea, and the patient's appetite was very poor. On the twenty-sixth there was still a free discharge, and a round worm passed through the fistulous opening, the margins of which were reddened and inflamed. On the twenty-ninth there was vomiting of bitter masses. The skin was cool. The child died on October 30th.

At autopsy, thirty-two hours later, the abdominal walls were of a bluish-green color. At the umbilicus was a fistulous opening into which a sound could be introduced downward and to the right; on pressure there escaped yellow masses with a fecal odor and mixed with gas.

In the lower lobes of the lungs nodules were detected. The intestines were more or less firmly attached to the peritoneum of the anterior abdominal wall. In the umbilical region was a portion of intestine running transversely and intimately attached to the abdominal wall, so that its liberation was impossible. These loops communicated with the umbilical fistula. The stomach, liver, spleen, and large and small intestine had grown together and the individual loops were firmly adherent to one another. Between them was a purulent exudate. In the intestinal serosa were numerous nodules, but in the mucosa itself no tubercles. Scattered throughout the small intestine were numerous ulcers.

#### UMBILICAL FISTULA DUE TO TUBERCULOSIS OF THE VAS DEFERENS.\*

While discussing the subject of umbilical diseases with Dr. Ramon Guitéras, of New York, he told me of a case of tuberculosis of the vas deferens which had opened at the umbilicus. I have not found the record of a similar case in the literature. Dr. Guitéras kindly sent me his notes on the case. Although no fecal fistula existed, it can be best considered in this chapter.

Umbilical Fistula Due to Tuberculosis of the Vas Deferens. †—J. G., an Italian laborer aged thirty, was first seen by Dr.

\* Although this fistula was not fecal in character it can be best considered here.

† Guitéras, Ramon: Personal communication.

Guitéras in the Columbus Hospital. He was cachectic in appearance, although fairly well nourished. His breathing was more rapid than usual, owing to an old pleurisy on the left side. He entered the hospital on account of suppuration from the umbilicus. On examination a probe entered a sinus an inch long in the lower part of the umbilicus. There was a small, blind pouch of the same length on the right side of the scrotum, although there was no evidence of communication between the two. The case was a very obscure one. Dr. Guitéras expected to find either an abscess of the urachus or necrosis of the under surface of the pelvic bone.

After the patient was anesthetized, the probe, bent in a certain way, was passed downward and outward nearly to the anterior superior spine of the ilium. An incision was made through the abdominal wall over the point of the probe, which corresponded to the site of the appendix, and Dr. Guitéras expected to find a sinus leading to an old appendiceal abscess; but such was not the case. He introduced a probe through the incision and found that it extended down to the inguinal canal. He then continued the incision down to the canal, opened it, and found that the vas deferens was tuberculous. A portion of the diseased cord was excised, the upper part of the wound was closed, and the inguinal canal was packed and drained. Dr. Guitéras, in referring to the case, thought that he might have to do a more extensive operation on the vas deferens, but ten days afterward the patient had an attack of apoplexy and died in three days.

#### LITERATURE CONSULTED ON TUBERCULOUS PERITONITIS FOLLOWED BY FECAL FISTULA AT THE UMBILICUS.

- Baginsky, A.: Zur Demonstration eines Präparates. Verhandl. der Berlin. med. Gesellschaft, Jahrg. 1879-80, xi, 90.
- Bertherand, A.: Observation d'entéro-péritonite tuberculeuse avec perforations intestinales, formation d'un réservoir stercoral sous la paroi abdominale; fistule ombilicale. Gaz. méd. de Strasbourg, Novembre, 1852, douzième année, 572.
- Catteau, J. F.: De l'ombilic et de ses modifications dans les cas de distension de l'abdomen. Thèse de Paris, 1876, No. 210.
- Clairmont, Paul: Casuistischer Beitrag zur Radicaloperation der Kothfistel und des Anus præternaturalis. Klinik, Prof. v. Eiselsberg, Königsberg. Langenbeck's Arch. f. klin. Chir., 1901, lxiii, 691.
- Crooke, E. G.: On a Case of Tubercular Peritonitis Followed by Perforation of the Abdominal Parietes. The Lancet, 1849, ii, 668.
- Feulard: Fistule ombilicale et cancer de l'estomac. Arch. gén. de méd., 1887, 7e sér., xx, 158.
- Fischer, H.: Die Eiterungen im subumbilicalen Raume. Volkmann's Samml. klin. Vorträge, n. F., No. 89 (Chir. Nr. 24), Leipzig, 1890-94, 519.
- Heinrich: Ueber beschränkte sogenannte äussere oder tuberculöse Peritonitis bei Kindern, oder über Entzündung der Subkutanenschicht der Bauchwand und über die Bildung von Abscessen und Verhärtungen daselbst. Jour. f. Kinderkrankh., 1849, xii, 6.
- Nicaise: Ombilic. Dict. encyclopédique des sc. méd., Paris, 1881, 2. sér., xv, 140.
- Ledderhose, L.: Chirurgische Erkrankungen des Nabels. Deutsche Chirurgie, 1890, Lief. 45 b.
- Owen, E.: Surgical Diseases of Children, third ed., London, 1897, 269.
- Park, Roswell: Clinical Lecture on Congenital Fistulæ and Sinuses at the Umbilicus. Med. Fortnightly, 1896, ix, 9.
- Rachford, B. K.: Artificial anus established spontaneously through the umbilicus. Arch. of Pediatrics, viii, 680.
- Richelot, L. G.: Abscess tuberculeux sousombilical. L'Union méd., 1883, xxxv, 61.
- Rintel: Ein Fall von Darmtuberculose mit Perforation des Duodenum und Cæcum in's Cavum peritonæi. Berlin. klin. Wochenschr., 1867, iv, 332.
- Rombeau: Anus contre nature, suite de péritonite. Bull. de la Soc. anat. de Paris, 1851, xxvi, 366.

- Scott, John: Perforation of the Intestine with External Opening. *Edinburgh Med. and Surg. Jour.*, 1835, xliii, 97.
- Schmitz, A.: Ueber Bauchfelltuberculose der Kinder. *Jahrb. f. Kinderheilk.*, 1897, xliv, 316.
- Schrötter, E.: Zur Kenntniss der Tuberculose der Nabelgegend. *Arch. f. Kinderheilk.*, 1902-03, xxxv, 398.
- Tillmanns, H.: Ueber angeborenen Prolaps von Magenschleimhaut durch den Nabelring (*Ectopia ventriculi*) und über sonstige Geschwülste und Fisteln des Nabels. *Deutsche Zeitschr. f. Chir.*, 1882-83, xviii, 161.
- Ziehl: Cited by Schrötter.
- Vallin, E.: De l'inflammation périombilicale dans la tuberculisation du péritoine. *Arch. gén. de méd.*, 1869, xiii, 558.

## CHAPTER XXI.

### THE ESCAPE OF ROUND WORMS FROM THE UMBILICUS.

Historic sketch.

Symptoms.

Cause of the fistula.

Treatment.

Tapeworm escaping from the umbilicus.

Detailed report of cases in which round worms escaped from the umbilicus.

THE passage of worms from the umbilicus is uncommon, but, as pointed out by Leuckart, it is mentioned in the Hippocratic writings, and in the literature from time to time illustrative cases have been described. One of the early ones was that of Marteau, in 1756. Then followed the articles of Hamilton (1786), Ossiander (1795), Poussin (1817), Borggreve (1841), Hecking (1842), v. Siebold (1843), Nicolich (1846), Bottini (1855), Richter (1855), Bédel (1856), Diez (1858), Davaine (1860), Weiss (1868), Kern (1874), Leuckart (1876), Nicaise (1881), Ledderhose (1890), and others. Since 1890 very little has been written on the subject. This is but natural, as with the perfecting of surgical methods abdominal lesions have, as a rule, been treated in the early stages, thus to a large extent limiting the incidence of fecal fistulæ, which were usually necessary for the escape of worms. Nevertheless, it must be mentioned that in a few cases the escape of worms from the umbilicus has not been preceded by or followed by that of fecal matter. The best articles that we possess on the subject are those of Davaine, Weiss, and Nicaise. Weiss, in his inaugural dissertation, published in Giessen in 1868, reports several very interesting cases and then gives a short historic sketch.

Weiss cites cases observed by various authors. In Capallaria's case, worms escaped from the umbilicus. In a case observed by Petrus Forestus the patient was a woman, forty years of age, who had a tumor at the umbilicus. The tumor broke and feces and several worms escaped. The later history of this patient is not given.

Frincavello's patient, a boy five years old, passed worms from the umbilicus. Cladus reported the case of a patient who passed plum-stones and worms from the umbilicus.

Creulin's patient was a girl who had an umbilical tumor, which ruptured and three worms escaped from it. Healing followed.

Boire's patient was a young girl from whose umbilicus seven worms escaped.

Weiss next reports the observations of Hamilton and Dregogirone, made on small children. In these cases worms escaped from the umbilicus. Weiss says that similar observations had been made by Pouspin\* and by Cappola. He then refers to a report by Beilman,† under whose observation was a child that vomited worms. They also escaped by the rectum and from an abscess at the umbilicus. Weiss further mentions that similar cases had come under the observation of Paul of Ægina, Alix Traller, Avicenna, Feli-Plater, and Bianchi.

\* Pouspin: Jour. de Corvisart, 1817, xi.

† Beilman: Bull. d. sc. méd., 1831, xxv.

Finally he reports the observation of Ambroise Paré. The patient was a woman who had an ulcer at the umbilicus, from which a number of worms escaped. The fistula remained open for a long time, and a fecal discharge persisted. Finally it closed and healing took place.

#### SYMPTOMS.

The majority of these patients have symptoms of a gastro-intestinal disturbance, and after a period varying from a few days to a couple of weeks develop a soreness at the umbilicus. The center of the umbilicus gradually becomes softened, and the surrounding portions are thickened and edematous. In Sanchez' case the swelling became as large as a child's head.

In the course of a few days, usually as result of the use of poultices, the abscess breaks and there is an escape of pus. Sometimes this is accompanied by fecal matter or round worms or both; occasionally fecal matter is not detected at all, the wound closing up after the pus and worms have escaped. The worms may be alive or dead. Occasionally only one worm escapes, but, as a rule, several come away at once. Closure of the wound may occur temporarily, only to be followed by more pain and the expulsion of more worms.

In two cases, those of Beilman and Heer, cited by Weiss, the patients not only passed round worms by the umbilicus and the bowel, but also vomited them.

The majority of the patients recover, but the outcome depends in a large measure on the cause of the fistula.

#### CAUSE OF THE FISTULA.

Davaine, in his excellent work published in 1860, gives a table of 47 cases in which worms passed through the abdominal wall. According to these figures, the point of exit was: the umbilicus in 19 cases; the groin in 21 cases; other regions in 7 cases—thus demonstrating that it is at the points, where herniæ are most prone to occur, that worms escape.

He also draws attention to the fact that in children the worms usually escape from the umbilicus, whereas in adults the inguinal region is the most common site of exit. His table gives the following:

From the umbilicus in patients less than fifteen years of age. . . . .	15 cases
From the umbilicus in patients more than fifteen years of age. . . . .	4 cases
From the inguinal region in patients less than fifteen years of age. . . . .	2 cases
From the inguinal region in patients more than fifteen years of age. . . . .	19 cases

The reason for this difference is obvious: in the child the umbilicus represents the weakest point in the abdominal wall, but as the child develops into adult life the umbilicus usually becomes firmly knit and the inguinal region is the area most prone to give way.

Where tuberculosis of the intestine exists, it is readily seen that an ulcerated area may become adherent to the umbilicus and that, with masses of round worms lying in the intestine, these might readily injure the friable walls, causing an abscess and the escape of fecal matter from the umbilicus. Again, where typhoid fever has recently been present, as in Diez's case, the ulceration may have extended deep into the intestinal wall, thus rendering the outer or peritoneal surface of the intestine liable to become adherent to the surrounding structures. If it becomes adherent to the umbilicus, abscess formation might readily occur. We have, however,

only one example of such an occurrence. In the majority of the cases the patient first had gastro-enteric symptoms, which were followed by localized tenderness at the umbilicus.

In the older literature a spirited controversy arose as to whether the lumbricoid worm could penetrate the normal intestinal wall, some claiming that it could, others that it was not capable of doing so. Davaine, from his observations, concluded that lumbricoids do not perforate the healthy intestine, but he would not deny that a soft, ulcerated intestine might yield and perforate as a result of pressure exerted by the head of the *Ascaris lumbricoides*.

If a large fecal concretion is capable of causing ulceration and perforation of the intestine, it does not seem difficult to understand how masses of round worms might cause ulceration of the intestine with subsequent perforation.

In the cases reported by Hamilton, Poussin, and MacSwiney, the previous histories were strongly suggestive of the existence of a patent omphalomesenteric duct. In such cases it was only natural that the worms should escape along the preëxisting fistulous tract to the umbilicus. In some cases the patent omphalomesenteric duct was so small that no fecal matter escaped until a worm was seen projecting through the umbilicus or was noted crawling on the abdomen.

#### TREATMENT.

This will, of course, depend on the cause of the fistula. As will be seen from a study of the appended histories, worms were expelled from time to time. Accordingly, it will be advisable, after the patient has gained in strength, to give an anthelmintic. When the bowel shows no further trace of worms, and when the umbilical induration has disappeared, nothing but a fistulous tract remaining, the abdomen should be opened and the hole in the bowel closed. If a patent omphalomesenteric duct has been the cause of the fistula, it can readily be removed, the same technic being employed as for an appendix operation. If the previous history suggests an appendix abscess with escape of feces, abscess formation, and the escape of its contents through the umbilicus, the appendix region should also be explored, provided the dangers of a general peritoneal contamination are not too great.

In some of those cases, in which the worms seemed to escape from an intestinal loop which had become directly adherent to the umbilicus, the wound closed spontaneously after all the worms had been expelled. Where a fistula still persists, it can be readily closed by operation. In case the perforation has been followed by an abdominal abscess and this has later opened at the umbilicus, the bowel opening at the bottom of an abscess may be lined with granulation tissue. In such a case closure of the hole in the bowel is not only a difficult procedure, but, on account of the necessary drainage, is apt to be followed by failure or by a general peritonitis.

In those cases in which the fecal fistula is of tuberculous origin, one should hesitate long before attempting to close it, as on account of the friable character of the tissues the end-result may be worse than that present at the time of operation.

#### TAPEWORMS ESCAPING FROM THE UMBILICUS.

From the foregoing we have seen that round worms may occasionally escape from the umbilicus. If a fecal fistula exists in this situation and the intestine contains a tapeworm, there is no reason why it should not escape in a similar manner.

Siebold, in 1843, reported such a case. In April, 1841, Siebold saw at the clinic in Erlangen a man, aged twenty-two, who had had scrofula in childhood and who had had numerous abscesses. At the umbilicus was an elevation. One day, after the patient had been given a certain decoction, a physician was called because there was something alive at the umbilicus. Six inches of a *tænia solium* were protruding from the umbilical opening. Traction was exerted, and the head came away. Several meters of the lower portion were drawn out; in other words, the entire worm was extracted with ease. No fecal matter or gas escaped. The man did not improve, but died of pulmonary tuberculosis.

Richter, in 1855, reported a case in which a tapeworm escaped from the anterior abdominal wall. A man, thirty years of age, had had an abdominal inflammation of unknown origin. Poultices were applied for months, and an abscess developed in the abdominal wall to the right of the mid-line. A fistulous tract passed upward toward the liver. The fistula discharged pus. Feces were never observed. From time to time living portions of tapeworms, however, escaped.

Tillmanns, in his article on Congenital Prolapsus of the Stomach Mucosa through the Umbilicus, says that v. Siebold had spoken of two cases in which tapeworms had escaped through the abdominal wall. One case was reported by Monleng, and the condition was associated with a definite fecal fistula. The second was reported by Spöring. [We have the record of only one case, namely, that of Siebold, in which a tapeworm escaped from the umbilicus itself.]

#### DETAILED REPORT OF CASES IN WHICH ROUND WORMS ESCAPED FROM THE UMBILICUS.\*

Escape of Round Worms From the Umbilicus.†—Bédel mentions two cases related to him by his uncle, Dr. Bédel. The patients were two brothers, one eleven, the other thirteen. Each passed round worms from the umbilicus within one month.

Escape of Round Worms From the Umbilicus.‡—The patient was a boy, four years old. The umbilicus had been transformed into a "pus-bladder," and around it was a reddening. When the child was put to bed for examination, he turned suddenly and the abscess broke. A worm was found projecting from the umbilicus. The next day the family showed the doctor three more worms. With the use of bandages and applications of carbolic acid the wound healed. Berner thought there must have been a diverticulum in this case.

Escape of a Worm Through the Umbilicus.—Weiss § reports a case observed by Blanchet.|| An adult male had severe pain in the umbilical region. The umbilicus commenced to increase in size, and eight days later fluctuation was detected. At the most prominent part of the tumor a painful dark point developed. The abscess was opened, and much fluid and one worm escaped. Fourteen days later the wound had healed completely.

\* I wish to express my thanks to Dr. Charles W. Stiles, of Washington, for his kindness in supplying me with the more recent references on this subject.

† Bédel: *Bull. de thérapeutique*, 1856, li, 550.

‡ Berner, H.: *Entleerung von Spulwürmern aus dem Nabel. Aertzliches Intelligenzbl.*, München, 1876, xxiii, 238.

§ Blanchet (Cited by E. Weiss): *Ueber diverticuläre Nabelhernien und die aus ihnen hervorgehenden Nabelfisteln. Inaug. Diss.*, Giessen, 1868.

|| Blanchet: *Acad. méde.*, Paris, 1827.

**Escape of Round Worms Through the Umbilicus.**— In 1833 Borggreve\* saw a five-year-old boy who, for fourteen days, had had pain in the umbilical region associated with general symptoms suggesting worms. Examination later showed an opening at the umbilicus, and projecting from this was the snout of a round worm. The worm was carefully grasped with forceps and drawn out. It was eight inches in length. An appropriate vermifuge was given, and 21 large worms passed from the umbilicus and five from the rectum. The umbilical opening later closed spontaneously.

**Escape of Round Worms Through the Umbilicus.** †— A ten-year-old boy, who had always been healthy, developed severe gastro-enteritis. On the fourth day the umbilical region was raised and surrounded by a red zone. Warm applications were made. The umbilicus opened, and three round worms escaped. Two more came away from the umbilicus the same evening. On the fifth day the general symptoms disappeared and feces escaped from the opening. A compression bandage and frequent cauterization brought about healing in one month.

**Escape of Round Worms From the Umbilicus.**— Casali‡ reports a case in which round worms escaped from the umbilicus.

**Escape of Worms From the Umbilicus.** §— A woman, sixty years of age, had had symptoms of enteritis. An abscess developed at the umbilicus and 36 worms escaped. Weiss, when speaking of this case, compares the observation to those of Borggreve, Glos, Bottini, Diez, and Finger.

**Round Worms at the Umbilicus.** ||— A nine-year-old girl, in April, 1855, had a severe attack of typhoid fever, and during convalescence a small tumor developed at the umbilicus. Its formation was accompanied by much pain, and the skin was red. Poultices were applied, and pus having the odor of feces escaped. There was no doubt that the abscess communicated with the bowel. Daily applications of caustics caused the opening to close in fourteen days. Nine months later the child had sudden pain and the umbilicus opened in a few hours. A live round worm appeared. This was pulled out, its removal occasioning much pain. In the course of the next fourteen days nine more worms came away. The opening then closed without treatment.

In 1857 the umbilicus, which in the mean time had been closed, again opened, and in three days nine live round worms escaped. After the giving of appropriate medicine six more worms were passed, this time by the rectum. The fistula closed and gave no further trouble.

**Escape of Worms From the Umbilicus.**— Weiss\*\* gives a description of a case reported by Girone. †† A fourteen-year-old boy had suffered for some time with tabes mesenterica and was confined to bed. His abdomen was swollen and he had fever. For one year he complained of pain in the side. The

\* Borggreve: Abgang von Spulwürmern durch den Nabel. *Medicinische Zeitung*, 1841, x, 117.

† Bottini, G. D.: *Schmidt's Jahrbuch*, 1855, lxxxv, 308.

‡ Casali, T.: Un caso di elmintiasi con fuorinscita di ascaridi lombricoidi dall' ombellico. *Il Raccoglitore medico*, 1879, serie iv, xii, 281.

§ Denaire (Cited by E. Weiss): *Op. cit.*, obs. 4.

|| Diez: Spulwürmer im Nabel. *Med. Correspondenz-Bl. des Württemberg. aertzlichen Vereins*, Stuttgart, 1858, xxviii, 95.

\*\* Girone: Cited by E. Weiss, *op. cit.*, 1868.

†† Girone: *Gaz. méd. de Paris*, 1838, p. 231.



urine was cloudy and the stools liquid. The pains gradually increased, and finally an abscess appeared at the umbilicus, which opened spontaneously, and four round worms escaped. Fecal matter also came from the fistulous tract. The opening closed completely.

**A Case of Worms Escaping Through an Opening at the Navel.**—According to Simmons, Hamilton\* made the following report in a letter: A male child, a year and a half old, was thought by the mother for several weeks to have had worms. The umbilicus protruded about an inch and appeared inflamed. The mother said that the person who had cared for the child for a few days after its birth drew the bandage from the umbilicus too suddenly, and with the bandage the remains of the cord, before it had been completely separated. She added that, though the part healed, it had always remained tender. To prevent its protruding too much, a bandage had been applied pretty tightly over it. Soon after that the child seemed to have symptoms of worms, and on untying the bandage the mother observed a worm about seven inches long crawling over the abdomen. In the middle of the umbilicus were two small holes, out of one of which the worm had just issued. Before long two more came away through the same opening. One of the worms had protruded itself two inches when she pulled it away with the fingers. The next day two more worms came away. All of these were six to eight inches long and alive when they escaped. At the end of ten days six more came away in the course of twenty-four hours. In the succeeding five weeks no more had escaped and the opening had closed. The umbilicus was the size of a walnut, and evidently diseased, but the child continued well.

**Escape of Round Worms Through a Fecal Fistula at the Umbilicus.** †—Weiss mentions a case recorded by Heer.‡ A young girl vomited worms and also passed them by the bowel. An abscess developed at the umbilicus. This was opened, and a round worm escaped. Healing soon took place.

**Escape of Round Worms From the Umbilicus.** §—A four-year-old girl for eight days had been complaining of an inflammatory swelling at the umbilicus. After the application of poultices the swelling opened and there escaped a foul-smelling pus, together with three dead round worms. In a few days the umbilical opening closed and the child recovered. Two months later she was again ill with symptoms of worms. The umbilicus again became prominent and inflamed, opened, and discharged several more worms. The wound closed, and thereafter there were no further signs of worms.

**Escape of Worms From the Umbilicus.** ||—The patient was a seven-year-old boy who complained of pain in the lower abdomen. An umbilical abscess developed, and from it there escaped 41 round worms. The opening closed. Four months later it opened again and 11 worms escaped. The colic disappeared; nevertheless, no closure took place and a fecal fistula developed.

**Extraction of *Ascaris Lumbricoides* From the Umbilicus.** \*\*—A boy, four years of age, had been in good health until five months

\* Hamilton, Robert: London Med. Jour., 1786, vii, 372.

† Heer: Cited by E. Weiss, op. cit.

‡ Heer: Revue méd., 1837.

§ Hecking: Entleerung von Spulwürmern durch den Nabel. Generalber. des Königl. Rheinischen med. Coll. für 1839, Coblenz, 1842, 80.

|| Lini: Cited by E. Weiss, op. cit., p. 13.

\*\* Macphail, Donald: Glasgow Med. Jour., 1884, xxii, 382.

before admission. Shortly before coming under observation he had been treated for thread-worms. Five months before admission he had become restless, listless, cross, and had had diarrhea. The abdomen was swollen and tender and emaciation was noted. The condition gradually grew worse. The abdomen became prominent and tense, and the superficial veins were much enlarged. He was very weak, emaciated, and apathetic. The diarrhea was severe, and there was sweating every night. At this time a thin, watery pus commenced to escape from the umbilicus. This was very offensive, but had no fecal odor. During the next three weeks the condition was still worse; the discharge from the umbilicus became more abundant and excoriating. Later there was difficulty in micturition, with retraction of the testicles. Between the umbilicus and the pubes was a diffuse, slightly elevated swelling, which was very tender, but there was no redness. A few days later the child was almost moribund, and there was edema of the feet and legs. Protruding from the umbilicus were two inches of a wriggling round worm which was easily drawn out. It was nine inches long. There was rapid improvement in the child, but he was still very thin. When the case was reported before the medical society, the possibility of an open omphalomesenteric duct was considered.

**The Passage of Chyle and Worms From the Umbilicus.** \* — The patient was a girl seven years old. She had a well-marked ascites. There was a history of ascites on previous occasions. When two years of age she had ascites, which disappeared in three months. A few months before Marteau saw her ascites again developed. On admission there was a hard and inflamed tumor at the umbilicus. After the application of poultices the swelling became circumscribed and opened. Escaping with the pus were three lumbricoid worms. Following these, chylous material escaped. The opening persisted for six months and discharged pus, chyle, and pieces of undigested food, and from time to time round worms escaped. After six months the tract cicatrized, and thereafter there was nothing but a thin serous discharge. The child was well nourished. The exact cause of the trouble was impossible to determine.

**Ascaris Lumbricoides Extracted From an Umbilical Fistula.** † — A boy, seven years old, came to the hospital with an ascaris lumbricoides projecting two and one-half inches from the umbilicus. "I at once proceeded to deliver it in an artistic way, and I had to exercise some caution in the operation lest it should break, as there was considerable tension on the creature, and it was evident that its body was tightly compressed in a track or sinus, through which it was slowly making its way out." The father of the boy stated that since birth there had been a fistula at the umbilicus, and that it had constantly discharged. There were never, however, any signs of blood, bile, or feces. The discharge was clear yellow matter with no feculent odor. MacSwiney says his friend, Dr. Kelly, thought the fistula was due to an unclosed vitelline duct.

**Escape of Round Worms From the Umbilicus.** ‡ — A woman, twenty-five years of age, who had had two normal labors, complained of severe pain in the hypogastric region shortly after the second labor. The menses ceased, and the physician thought a new pregnancy was under way. Finally the

\* Marteau: Sur une ouverture à l'ombilic qui donnoit passage au chyle et à des vers contenus dans les intestins grêles. Jour. de méd., Paris, 1756, v, 100.

† MacSwiney, S. M.: Proc. Path. Soc. of Dublin, 1873-75, vi, 251.

‡ Nicolich: Abgang von Spulwürmern aus dem Nabel. Schmidt's Jahrbuch, 1846, I, 53 (translated from Gaz. di Milano, No. 11, 1845).

abdominal wall from the umbilicus to the symphysis became bright red. Applications were made, and the umbilicus opened. There was an escape of a moderate amount of foul-smelling pus, but no fecal masses. Several days later three round worms escaped, and a few days after this six more worms passed from the umbilicus. The pain became pronounced in the inguinal regions, and pressure here caused a moderate amount of pus to escape from the umbilicus.

**Fecal Fistula at the Umbilicus.\*** — The patient was a delicate boy who had previously passed lumbricoid worms. Toward the end of 1795 he complained of abdominal pain. There was distention and an area of inflammation at the umbilicus which seemed ready to rupture. The tumor, however, gradually receded. In March, 1796, the patient developed a severe cough. Before Easter the abdomen again became distended, and the umbilicus was very prominent, red, and painful. The skin was glistening and distended, and there was a marked degree of emaciation. On March 31st there was a rupture, with the escape of pale yellow, fetid fecal masses. The boy died on April 4, 1796. At autopsy the abdomen was found distended. The opening at the umbilicus was sealed up with dry pus. The peritoneum contained many small and large nodules, and from several openings beneath the stomach region four live round worms came away. The larger opening admitted the index-finger and was on the right, beneath the liver. Attached to the umbilicus was an intestinal loop, and from this pus had escaped. The mesenteric glands were enlarged and hardened.

**Escape of Several Round Worms From the Umbilicus.†** — The patient was a boy, three years of age, and of healthy parentage. The nurse made traction on the cord on the fifth day, as it had not come away. "Inflammation" followed, and a small opening developed. Sometimes this would close for three weeks or a month, but never for a longer period. On examination the mother was surprised to see a worm half an inch long crawling along the abdomen. The child, who had been sick, rapidly recovered. Several weeks later two worms similar in character were extracted from the umbilical fistula. In the intervals between the times of abdominal pain the child enjoyed good health, except for an occasional discomfort due to worms. At the umbilicus was a slight projection the size of a chestnut with an opening in the center. Escaping from this were contents resembling feces. On several occasions the physician was called to see the child when in great pain, and removed lumbricoid worms from the fistula. Some of these worms reached four and one-half inches in length.

[The history is strongly indicative of a patent omphalomesenteric duct.]

**Round Worms Escaping From the Abdomen.** — Richter‡ speaks of cases reported by Baumann, and one by Winterich, in which round worms were passed at the umbilicus, and says that such an occurrence is not rare.

**Escape of Round Worms From a Fecal Fistula at the Umbilicus.§** — This case came under the observation of Sanchez.|| The patient was a woman who developed a tumor at the umbilicus. After two years

\* Ossiander: *Neue Denkwürdigkeiten für Aerzte und Geburtshelfer*, i, 2. Abtheilung. Cited by Schrötter.

† Poussin: *Observation sur l'expulsion de l'abdomen par une ouverture à l'ombilic de plusieurs vers ascariides-lombricoïdes.* *Jour. de méd.*, 1817, xi, 81.

‡ Richter: *Bandwurmglieder aus einer Bauchfistel entleert.* *Schmidt's Jahrbuch*, 1855, lxxxv, 308.

§ Sanchez: Cited by E. Weiss, *op. cit.*, obs. 3.

|| Sanchez: *Gaz. Med. Italiana*, 1862, v, 284.

this formed an abscess and a fecal fistula developed, from which three worms escaped. When St. Sardi saw the patient, the tumor at the umbilicus was the size of a child's head. Pus flowed from it without any diminution in size of the tumor. With a probe an intestinal stone could be felt. This was removed at operation. The nucleus of the stone consisted of hardened feces and was covered over with earthy phosphates. The patient died fourteen days after operation.

**A Round Worm at the Umbilicus.** — Weiss\* says that in the *Journal de Progrès*, 1834, the case of a sixteen-year-old negro was recorded. The patient had a phlegmonous tumor at the umbilicus, and gave a history of having passed 92 worms at stool. The tumor was opened, and in it was found a half-digested worm.

\* Weiss, E.: *Op. cit.*

#### LITERATURE CONSULTED ON THE ESCAPE OF WORMS FROM THE UMBILICUS.

- Bédel: *Bull. de thérapeutique*, 1856, li, 550.
- Berner, H.: *Entleerung von Spulwürmern aus dem Nabel. Aertzliches Intelligenzbl.*, München, 1876, xxiii, 238.
- Borggreve: *Abgang von Spulwürmern durch den Nabel. Med. Zeitung*, 1841, x, 117.
- Bottini, G. D.: *Schmidt's Jahrbuch*, 1855, lxxxv, 308.
- Casali, T.: *Un caso di elmintiasi con fuorinseita di ascaridi lombricoidi dall' ombellico. Il Raccolgitore medico*, 1879, ser. iv, xii, 281.
- Davaine, C.: *Traité des entozoaires*, Paris, 1860, 115.
- Diez: *Spulwürmer im Nabel. Med. Correspondenzbl. des Würtemberg. aertzlichen Vereins*, Stuttgart, 1858, xxviii, 95.
- Hamilton: *Case of Worms Discharged through an Opening in the Navel. London Med. Jour.*, 1786, vii, 372.
- Hecking: *Entleerung von Spulwürmern durch den Nabel. Generalbericht des Königl. Rheinischen med. Coll. f. 1839*, Coblenz, 1842, 80.
- Kern, Theo.: *Ueber die Divertikel des Darmkanals. Inaug. Diss.*, Tübingen, 1874.
- Ledderhose, G.: *Chirurgische Erkrankungen des Nabels. Deutsche Chirurgie*, 1890, Lief. 45 b.
- Leuckart, R.: *Die menschlichen Parasiten und die von ihnen hervorgehenden Krankheiten. Leipzig*, 1876, ii, 241.
- Macphail, Donald: *Ascaris Lumbricoides Extracted from the Umbilicus. Glasgow Med. Jour.*, 1884, xxii, 382.
- MaeSwiney, S. M.: *Proc. Path. Soc. of Dublin*, 1873-75, vi, 251.
- Marteau: *Sur une ouverture à l'ombilic, qui donnoit passage au chyle et à des vers contenus dans les intestins grêles. Jour. de méd.*, Paris, 1756, v, 100.
- Nicaise: *Ombilic. Dictionnaire encyclopédique des sc. méd.*, Paris, 1881, 2 sér., xv, 140.
- Nicolich: *Abgang von Spulwürmern aus dem Nabel. Schmidt's Jahrbuch*, 1846, l, 53. (Translated from *Gaz. di Milano*, No. 11, 1845.)
- Ossiander, F. B.: *Original not located. Neue Denkwürdigkeiten für Aerzte und Geburtshelfer*, i, 2. Abtheilung. Reported by Schrötter.—Schrötter, E.: *Zur Kenntnis der Tuberculose der Nabelgegend. Arch. f. Kinderheilkunde*, 1902-1903, xxxv, S. 413.
- Poussin: *Observation sur l'expulsion de l'abdomen par une ouverture à l'ombilic de plusieurs vers ascarides-lombricoides. Jour. de méd.*, 1817, xl, 81.
- Richter, H. E.: *Bandwurmglieder aus einer Bauchfistel entleert. Schmidt's Jahrbuch*, 1855, lxxxv, 308.
- Siebold: *Abgang eines Bandwurms aus dem Nabel, nebst einigen Bemerkungen über das Wandern der Eingeweidewürmer. Med. Zeitung*, Berlin, 1843, xii, 75.
- Stiles: *Hygienic Laboratory*, U. S. Government, Washington. (Personal communication.)
- Tillmanns, H.: *Ueber angeborenen Prolaps von Magenschleimhaut durch den Nabelring (Ectopia Ventriculi) und über sonstige Geschwülste und Fisteln des Nabels. Deutsche Zeitschr. f. Chir.*, 1882-83, xviii, 161.
- Weiss, E.: *Ueber diverticuläre Nabelhernien und die aus ihnen hervorgehenden Nabelfisteln. Inaug. Diss.*, Giessen, 1868.

## CHAPTER XXII.

### THE ESCAPE OF VARIOUS FOREIGN SUBSTANCES FROM THE UMBILICUS.

- Gall-stones escaping at the umbilicus; report of cases.
- Hydatids at the umbilicus.
- The escape of liquor amnii or of fetal remains through the umbilicus.
- Escape of foreign bodies through the umbilicus.

#### GALL-STONES ESCAPING AT THE UMBILICUS.

THE escape of gall-stones from the umbilicus is very rare. One of the earlier reported cases was that of Buettner, published in 1744. I have been unable to obtain the original article, but it was referred to by Duplay in 1833. In Buettner's case 38 biliary calculi escaped from the umbilicus. Bérard, in the French Dictionary of Medicine, published in 1840, says that there were several examples of a biliary fistula opening at the umbilicus, and sometimes associated with the escape of calculi. The most exhaustive and best treatise on the subject is that of Legue-linel de Lignerolles, published in Paris in 1869. Other names closely identified with the development of the subject are Nicaise, Murchison, Courvoisier, and Ledderhose. According to Nicaise, Murchison collected 86 cases in which the gall-bladder opened in the right hypochondrium on a level with the fundus of this viscus; in other cases, in regions more or less distant in the abdominal wall. In a certain number of the cases they opened at the umbilicus. Courvoisier, in his Pathology and Surgery of the Bile-ducts, published in 1890, gives the following table of 169 cases in which the gall-bladder opened through the abdominal wall:

In the right hypochondrium . . . . .	49 times
At the edge of ribs on the right side . . . . .	36 “
In the right mesogastrium . . . . .	17 “
In the right iliac region . . . . .	10 “
In the epigastrium . . . . .	6 “
In the neighborhood of the umbilicus . . . . .	26 “
Through the umbilicus . . . . .	12 “
Below the umbilicus . . . . .	11 “
In the left inguinal region . . . . .	1 time
Multiple openings . . . . .	1 “

From this table it will be noted that in 26 of the 169 cases the opening occurred in the neighborhood of the umbilicus; in 12 instances at the umbilicus, in 11 cases below the umbilicus. Thus in 49 cases it occurred at or near the umbilicus.

I have not attempted to cover the literature on the subject, but have gathered together only sufficient material to give a fairly comprehensive composite picture of this class of cases. Of course, this complication will naturally occur during the decades when gall-stones are most frequently found. The youngest patient was twenty-three years of age. The great majority of the patients were over forty years of age.

Of 12 cases of biliary fistula at the umbilicus of which we have definite records. 1 was in a man and 11 were in women. This large percentage in women is rather striking, and may be due in some measure to the weakened condition of the umbilicus as a result of the stretching caused by pregnancy. I am not in a position to prove this point, however, as data on pregnancy in these cases are not available.

These patients, as a rule, give the usual history of gall-stones. Sometimes the initial pain is in the gall-bladder region, but occasionally it is first noted in the left hypochondrium, and after a time shifts to the right side. In addition to the hepatic colic noted there are sometimes nausea, vomiting, and diarrhea. After a varying length of time changes may be noted at the umbilicus. In Bramann's case fully two years elapsed before the umbilicus was involved.

**Umbilical Changes.** — The umbilical region usually becomes indurated, and may remain so for several weeks or months. In other cases it rapidly shows signs of reddening, becomes painful, and may soon open spontaneously.

In Clement's case the reddening around the umbilicus was treated as an eczema for some time; finally a biliary fistula developed.

In Richet's case, reported by Leguelinel de Lignerolles, a small tumor presented at the umbilicus, and in three months had grown to the size of an adult's fist and opened spontaneously.

When the abscess breaks, there is an immediate discharge of pus, sometimes, but not always, fetid. In Leclerc's case it contained sandy particles. With the escape of pus small biliary calculi may be discharged. As a rule, however, several days elapse before any are noted. If they are small, their exit may occasion little inconvenience, but when they are of any appreciable size, their expulsion is accompanied by marked abdominal contractions and much pain. In some of the cases it was only on probing the fistulous tract that calculi were detected at the bottom. When the stone is large, it may become firmly wedged in the fistula, and can then be removed only by dilating the channel and grasping the stone with forceps. With the escape of a large stone bile may for the first time appear at the umbilicus. In other instances the discharge has never showed even occult bile.

The subsequent history of the fistula depends on the contents of the gall-bladder. If the gall-bladder contains small stones, these escape from time to time, the fistula frequently being temporarily sealed over in the meantime. Where only one large stone has been present, after its expulsion the sinus usually closes permanently. In short, when once the umbilical fistula has formed, it rarely closes permanently until the gall-bladder has been completely emptied of its stones. Stones may escape at intervals for years.

The majority of the patients regain their normal health. In the case of Madame X, reported by Leguelinel de Lignerolles, the patient became emaciated and died. At autopsy a contracted gall-bladder was found which contained a calculus, and a calculus was present in the hepatic duct. In Robert's case, cited by Nicaise, dilatation of the fistulous tract was followed by peritonitis and death. In Leroy des Barres' case the patient, six years later, died of cancer of the stomach and liver.

Murchison's description of the mode in which biliary fistulæ penetrate the abdominal wall in various places is most instructive and is well worth a thorough study.

When the fistula develops at the umbilicus, it is either due to perforation of the gall-bladder with abscess formation and later perforation of the umbilicus by the

abscess; or the enlarged and prolapsed gall-bladder may become adherent to the umbilicus and open.

In some cases the gall-bladder is excessively long. In a case I saw with Dr. Franklin B. Smith in Frederick, Md., the greatly enlarged viscus hung over the brim of the pelvis and almost touched the uterus. The gall-bladder was distended with stones. Such a gall-bladder could very readily have become adherent to the umbilicus. A reference to Bramann's case will show that in that case the gall-bladder projected downward almost to the symphysis. It had become adherent and opened at the umbilicus.

#### CASES OF BILIARY FISTULÆ AT THE UMBILICUS WITH THE ESCAPE OF GALL-STONES.

In America very little attention has been paid to biliary fistulæ at the umbilicus, and the literature in the English language, apart from the excellent monograph of Murchison, is so meager that I append a number of cases sufficient to give an adequate view of the subject. Furthermore, although these cases have been rare in the past, they will be even rarer in the future because of the prompt operative measures now invariably adopted, when acute or chronic inflammations of the gall-bladder exist.

Case 1.—A Biliary Tumor Forming Two Small Abscesses at the Umbilicus, Followed by Fistula and Escape of Three Biliary Calculi. Healing.\*—This case was reported from the clinic given on January 11th at La Pitié, by Professor Richet. The patient had complained of abdominal pain for seven or eight months previously. For three months she had noted a small tumor at the umbilicus, but had never suffered from hepatic colic and gave no history of jaundice. The pain had been accompanied by alternating diarrhea and constipation. On her admission to Richet's service in December the patient presented a tumor situated in the umbilical region. It was the size of an adult's fist. It diminished a little as a result of fomentations and poultices, but was very red and painful on pressure. It gradually lost the character of a phlegmon. After eight or ten days it began to increase in size. The skin became thinner and broke, and there was an escape of pus and fragments of albumin and fibrin. A fistulous opening formed a few days later. A probe introduced into the two openings disappeared for a depth of 7 cm. and impinged upon a hard body. The patient at this time was pale, somewhat jaundiced, and had lost a little in weight. Richet considered in the differential diagnosis acute phlegmon, abscess of the glands, cold abscess, cancer, a syphilitic tumor, fecal fistula, and a fetal cyst.

On February 10th the tumor was opened and a large quantity of pus was evacuated. The two orifices were opened by a long incision. At the bottom was a hard body which was free, mobile, and had facets. Richet endeavored to remove it with forceps, but did not succeed. A few days later the body had approached more and more to the surface, and on February 17th a biliary calculus escaped. Richet probed again and detected a second calculus. This escaped. A few days later a third calculus, similar to the two others, was removed. The umbilical opening closed completely, and the patient was discharged well in the early part of March.

\* Leguelinel de Lignerolles: Quelques recherches sur la région de l'ombilic et les fistules hépatiques ombilicales. Thèse de Paris, 1869, No. 6, obs. 1.

**Fistulous Abscess of the Liver Communicating with the Gall-bladder; Dilatation and Cauterization of the Fistulous Tract; Escape of 14 Small Faceted Calculi and of Two Large Calculi Without Facets.\***—In April Dr. Vacher was called to see a woman, twenty-three years of age, who had a good previous history. She said that following a cut she had had an abscess of the liver. This abscess had opened spontaneously and for two months there had been a purulent discharge from the umbilicus, with pain and fever. A fistula had resulted. Vacher found a fistulous opening about three fingerbreadths from the umbilicus. On pressure seropurulent fluid escaped from it. A sound penetrated transversely and to the right for a depth of 4 cm. Abscess of the liver was diagnosed. Crepitation was transmitted to the sound, indicating old calcareous concretions like those sometimes found in the bottom of a cyst. The consultant advised against dilatation of the fistula and gave an unfavorable prognosis. Vacher, however, dilated the fistulous tract with sponges, and then could detect with a sound distinct signs of a calculus. The calculus escaped spontaneously a few days later. It was blackish, faceted, and the size of a pea. Greenish bile also escaped with the calculus. Two and later four other calculi of the same size came away. A calculus of large dimensions presented and was removed with a polyp forceps. It was the size of a pigeon's egg, similar to the others, and consisted of cholesterin. Three or four days later a similar calculus was extracted in the same manner. From this moment the patient improved. The tract was kept dilated for fifteen days. The patient recovered rapidly, and six years after was in excellent health.

**A Biliary Tumor Opening Spontaneously in the Umbilical Region, with Escape of a Calculus and Development of a Fistula.†**—In the first part of February, 1862, a man, aged forty-one, came saying that he had suffered with pain at the umbilicus for some time. At the umbilicus was a reddish tumor the size of a walnut, painful on pressure, and fluctuating. It was taken for an abscess. It opened spontaneously the next day, and a calculus with a small quantity of seropurulent liquid escaped. The cavity occupied by the calculus was lined with granulation tissue. On the sixth day it presented a small opening from which a little serous pus escaped. In the course of eight days the opening was completely closed. It, however, reëstablished itself, and pus escaped, but no other calculi. In May, 1868, this patient had ascites and cachexia and died in October from cancer of the liver and of the stomach.

**A Cystic Tumor Opening in the Region of the Umbilicus; Escape of Biliary Calculi From the Fistula.‡**—This case was originally reported by Dr. John Cockle.§ A woman, fifty-nine years old and well developed, had complained of very severe pain in the abdomen for nine days before her entrance to the hospital. She had had nausea and vomiting. The stools had been normal, and there had been no jaundice. At the level of the umbilical region there was a tumor which was red and inflamed, and there was also an opening. Eight days after entrance the patient discharged 14 small calculi.

\* Leguelinel de Lignerolles: Op. cit., obs. 2. [Abstract from *Traité d'affections calculeuses du foie*, Fauconneau-Dufresne, 482.]

† Leguelinel de Lignerolles: Op. cit., obs. 3. [Observation by Dr. Leroy des Barres, of Saint Denis. This case was related to the author by the son of Dr. Leroy.]

‡ Leguelinel de Lignerolles: Op. cit., obs. 4.

§ Cockle, John: *Med. Times and Gaz.*, May 10, 1862, p. 476.



Several days later three more calculi came away. The redness then disappeared, but the fistula remained. At a point 2 cm. to the right and below the umbilicus was a seromucous discharge. A probe detected the presence of a hard calculus, which appeared to be the size of a hen's egg. There was also an increase in size of the liver. After some time the swelling and redness reappeared and another calculus was removed. Three weeks later still another became fixed in the fistulous tract, about 2 cm. from the opening. As a result of the disastrous experience which Robert had had after the extraction of similar calculi under like circumstances, the surgeon did not attempt to remove this calculus, but from time to time small biliary concretions escaped.

Tumor of the Umbilical Region; Abscess with Fistulous Tract; Spontaneous Escape of Several Biliary Calculi; Grave Jaundice; Marked Emaciation. Death.\*—Madame X, aged sixty-five, had suffered from chronic gastritis. In 1857 she complained of vague pain in the right hypochondrium and a tumor could be made out in the region of the umbilicus. The tumor was hard, without any nodulation, and was painful on pressure. It opened at the umbilicus, and a considerable quantity of whitish pus escaped. In March, 1858, a biliary calculus appeared, and in the course of six months a large number escaped spontaneously. The opening closed after the exit of each calculus, but reopened to allow another to pass out. The patient gradually became emaciated, and died with a marked jaundice. At autopsy a sound introduced at the umbilicus passed into a cul-de-sac 3 cm. in depth. The liver was increased in size, and infiltrated with biliary material. The gall-bladder was transformed into a small, very hard tumor, round, the size of a walnut. It contained a calculus resembling those which had escaped. The hepatic duct was obstructed by a calculus.

Escape of a Biliary Calculus by an Abscess to the Left of the Umbilicus.†—This case was reported by Allé.‡ A woman, forty-six years of age, had had good health until 1828, when she had had what was called "nervous fever" (typhoid?). In 1830 she commenced to complain of pain in the left hypochondrium. A tumor was detected. The patient went to take the waters at Baden, but on her way there had very severe pain in the right hypochondrium, accompanied by headache and vomiting. In July, 1831, the skin in the region of the umbilicus became inflamed. After applications of poultices an abscess developed, which opened and a considerable quantity of pus escaped. On October 24th the patient experienced a very unusual sensation. She felt as if a foreign body had broken in the cavity of the abscess, and on the twenty-seventh noticed something hard presenting at the opening. A biliary calculus the size of a pigeon's egg escaped. The general condition of the patient was grave. She was becoming markedly emaciated, and had a continuous fever with exacerbations in the evenings and night-sweats. She was also constipated. The fistulous tract did not have the dimensions of a lentil. A probe introduced impinged upon a hard, immovable body. The opening was increased in size with a sponge. On November 25th a calculus presented. The surgeon attempted to remove it with forceps, but

\* Leguelinel de Lignerolles: *Op. cit.*, obs. 5. Abstract from *L'Union méd.*, 1859, 465.

† Leguelinel de Lignerolles: *Op. cit.*, obs. 6.

‡ Allé (in Brünn): *Vier grosse Gallensteine, welche durch einen Abscess zunächst unter dem Nabel abgingen.* *Med. Jahrb. K. K. Öster. Staates*, 1837, N. F. xii, 115.

it broke into four large fragments and several smaller ones. These were extracted, and the patient's health improved. The pain was severe, but the fistulous tract closed. In May, 1835, the fourth calculus was removed. Fifteen days later the opening closed completely, and it required only one month for the patient to regain her general health. When the fragments of the extracted stone were assembled, it was found that, together, they formed one calculus.

**Biliary Calculus Escaping From the Umbilical Region.** \* — A woman, sixty-seven years of age, had had pain in the epigastrium, in the right hypochondriac region, and in the umbilical region. At the umbilicus she developed a tumor which, by February, 1858, had reached enormous proportions. Her general condition, however, was satisfactory. At the beginning of April the tumor had a projection in its center. The skin at this point was thin and red. On the eighth day a large quantity of pus, sandy in character and fetid, escaped. Iodin and quinin were injected. Shortly afterward the patient went back to her work, but from time to time she had pain at the umbilicus and a seropurulent discharge; a fistula remained. Four years later the pain returned. In January, 1861, a blackish liquid with foul odor escaped from the fistula. At the same time at the orifice of the fistula was seen a black body, which escaped on January 23d, after violent abdominal contractions and much pain; it was hard, resistant, and the size of a pigeon's egg. A sound introduced into the opening disappeared for a distance of 5 cm. without impinging upon any solid body. The patient recovered. The body expelled without doubt was a biliary calculus which had made a channel toward the abdominal wall in the umbilical region. It was dark green in color, had the appearance and consistence of cholesterin, and burned in the flame of a candle.

**A Biliary Tumor Descending Toward the Umbilicus; Escape of a Calculus; Fistula. Recovery.** † — The wife of a pharmacist had been gradually weakened as a result of long suffering from hepatic colic. Reaching from the gall-bladder region toward the umbilicus was a tumor evidently containing a calculus which could be easily felt. This tumor ulcerated, bile escaped, and also a biliary calculus. The patient felt relieved and the opening closed. In the course of three months a new opening occurred in the region of the cicatrix and a second calculus escaped. It had evidently lain in the gall-bladder.

**Biliary Fistula at the Umbilicus.** ‡ — The patient in Bramann's Case 2 was an unmarried woman, sixty-three years of age. She had had typhoid fever at thirteen. At forty-five years of age she had complained of a sudden abdominal pain, had had a high fever, much discomfort in the gall-bladder region, and some nausea. The abdomen was somewhat swollen. A tumor the size of a fist had been made out in the umbilical region above and to the right. It had grown slowly and tended to pass more and more downward toward the symphysis.

Two years later a large quantity of foul-smelling pus had escaped from the umbilicus. This discharge had continued, the amount varying at different times. The patient was in good condition.

On admission her abdomen was slightly distended. The skin covering the umbili-

\* Leguelinel de Lignerolles: *Op. cit.*, obs. 7. Abstract from a case reported by Dr. Lelerc, *Gaz. des hôpitaux*, 1863, p. 48.

† Leguelinel de Lignerolles: *Op. cit.*, obs. 8. [This case was observed by Dr. Manec and reported by Fauconneau-Dufresne.]

‡ Bramann, F.: *Zwei Fälle von offenem Urachus bei Erwachsenen.* *Arch. f. klin. Chir.*, Berlin, 1887, xxxvi, 996.

cus was covered with crusts and exfoliated epithelium and small cysts. The umbilicus was retracted, and a small fistulous tract was discharging foul-smelling pus.

On palpation exactly in the middle line a long, egg-shaped tumor could be felt. At the umbilicus this was 5 cm. broad. It extended almost to the symphysis, and its lower end was from 7 to 8 cm. wide. The tumor lay distinctly behind the abdominal wall, and only in the neighborhood of the umbilicus was it intimately attached. In the lower part it was somewhat movable. On pressure it was found to be of dense consistence. A sound could be passed 12 cm. toward the symphysis, and the cavity widened out as it passed downward. Calculi were detected in the bottom of the cavity. The urine was always normal.

Operation.—An incision, 8 cm. long, was made from the umbilicus downward. Four faceted calculi the size of pigeon's eggs were removed from the sac. The cavity was cureted out. Healing occurred after three months, but it was necessary to curet several times. Microscopic examination of the calculi yielded cholesterin and bile-pigment, but no urinary salts.

Fatal Peritonitis Following a Biliary Fistula at the Umbilicus.\*—A woman, thirty-five years of age, had had for eight months a purulent fistula at the umbilicus. With a catheter introduced into the fistula Robert was able to detect a calculus situated at the bottom of the tract. He dilated the tract, but the patient developed peritonitis and died.

Escape of Biliary Calculi From the Umbilicus.—Clément† showed at the Medical Society two biliary calculi. The woman had had previous attacks of abdominal pain. When seen by Clément, she had a reddening around the umbilicus. This was unsuccessfully treated as an eczema. A fistula developed, and two days later a calculus escaped. On the day previous to the meeting Clément had extracted the two very small calculi from the umbilicus.

A Biliary Fistula at the Umbilicus.—Poncet‡ saw a patient with an umbilical fistula which from time to time discharged bile. The physician, under whose care the patient was, said that in the beginning an abscess had developed and a calculus had escaped. The resultant fistula resisted all treatment.

\* Robert: Cited by Nicaise: *Ombilic. Dictionnaire encyclopédique des sc. méd., Paris, 1881, 2. sér., xv, 140.*

† Clément: *Lyon méd., 1888, lvii, 53.*

‡ Poncet: *Lyon méd., 1888, lvii, 54.*

#### LITERATURE CONSULTED ON GALL-STONES ESCAPING FROM THE UMBILICUS.

Bérard, P. H.: *Dict. de méd., Paris, 1840, xxii, 66.*

Bramann, F.: *Zwei Fälle von offenem Urachus bei Erwachsenen. Arch. f. klin. Chir., Berlin, 1887, xxxvi, 996.*

Clément: *Lyon méd., 1888, lvii, 53.*

Courvoisier, L. G.: *Casuistisch-statistische Beiträge zur Pathologie und Chirurgie der Gallenwege, Leipzig, 1890, 117.*

Duplay: *Arch. gén. de méd., 1833, 2e série, i, 373.*

Ledderhose, G.: *Chirurgische Erkrankungen des Nabels. Deutsche Chirurgie, 1890, Lief. 45 bs*

Leguelinel de Lignerolles: *Quelques recherches sur la région de l'ombilic et les fistules hépatique. ombilicales. Thèse de Paris, 1869, No. 6.*

Murchison, C.: *Case of communication with the stomach through the abdominal parietes produced by ulceration from external pressure. Medico-chir. Trans., London, 1858, xli, p. 11.*

Nicaise: *Ombilic. Dictionnaire encyclopédique des sciences médicales, Paris, 1881, 2. sér., xv, 140.*

Poncet: *Lyon médical, 1888, lvii, 54.*

## HYDATIDS AT THE UMBILICUS.

The presence of hydatids at the umbilicus is exceptional. Examples have, however, been recorded by Guattani, Dupuytren, Thompson, Bérard, and Roux.

The parent echinococcus cyst usually develops in the liver, and the growth gradually extends to the umbilical region. The tumors may become adherent to the umbilicus and open, fluid and daughter-cysts escaping. Dupuytren's case is particularly interesting, in that autopsy showed that the primary focus was in the lung. The fistulous tract had perforated the diaphragm; it lay between the liver and abdominal wall, and opened at the umbilicus.

Leguelinel de Lignerolles reported Guattani's case.\* The patient was a man, forty-eight years of age, who had had, in the region of the liver, a tumor which was resistant, circumscribed, and tense. In the center an obscure fluctuation could be detected. Guattani was uncertain as to its character, and decided to temporize. Nine months later the tumor was prominent, the skin had become reddened, and through an opening at the umbilicus there escaped more than 300 hydatid cysts. A stilet introduced into the fistulous tract detected a large cavity which it was impossible to explore thoroughly. The fistulous tract remained open for a long time without any inconvenience to the patient. Healing took place six years afterward. [I was not able to study this case in the original. There seems to be some controversy, however, as Nicaise says the observation of Guattani cannot be considered as an example of hydatid fistula at the umbilicus. He claims that the tumor was in reality in the epigastric and not in the umbilical region, and that it ruptured, with the escape of more than 300 hydatids.]

Dupuytren reported his case in 1833. A woman entered the Hôtel-Dieu in 1811 with an inflammatory tumor of the umbilicus. As fluctuation was evident, and as it was manifest that the skin would give way, Dupuytren opened it and a large quantity of pus escaped, and with it several hydatid cysts. The woman died. At autopsy a communication was found between the umbilical opening and a cavity in the lung. The fistulous tract had perforated the diaphragm and lay between the liver and the abdominal wall. The cavity in the lung contained a large number of hydatid cysts. It was evident that the lung was the primary seat of the hydatids.

Leguelinel de Lignerolles cites Thompson's case. The original appeared in the *Medical Gazette*, 1844, and was recorded in the *Memoirs of the Medical Society*, London. The patient at intervals for a period of thirty years had discharged hydatid cysts from the umbilicus. She died at the age of fifty-three. The swelling was first noted after an abdominal injury. Following an abdominal incision she discharged numerous cysts, accompanied by a peculiar liquid which was sometimes purulent. The cysts continued to escape through an opening which developed at the umbilicus, and the patient experienced a great deal of abdominal pain. She had frequent attacks of diarrhea and occasionally fell into a state of great weakness. At autopsy, at the umbilicus were found two tumors communicating with the opening. The one contained friable material mixed with "quicklime," the other had very fetid contents. The fistula passed to the upper portion of the liver, with which it had evidently communicated. Eight or nine isolated hydatid cysts were found on the surface of the liver, and there was also an abscess which contained pus and remnants of hydatids. The gall-bladder was very much dis-

\* Guattani: *De ext. Aneurys.*, Roma, 1772, 109.

tended and contained similar cysts. In addition there were numerous hydatids between the folds of the mesentery.

Bérard, in 1840, reported the case of a woman who entered his service at St. Anthony's Hospital. For eighteen months she had had an umbilical fistula. On pressure over the right hypochondrium the purulent discharge from the umbilicus increased, and with the pus escaped several empty hydatid sacs.

Nicaise refers to Roux's case, which had been reported by Cruveilhier. A woman had at the umbilicus a tumor which had been taken for a hernia and a bandage had been applied. Roux noted that the skin covering the tumor had spontaneously opened; that there was a convex surface, whitish and prominent, at the opening of the skin. He thought of a hernial sac. He made several incisions to relieve the supposed strangulation, and was surprised to find that he was dealing with hydatid cysts.

Fischer, in his article on Suppurations in the Subumbilical Space, drew attention to an isolated echinococcus cyst of the abdominal wall. This was not situated at the umbilicus, but immediately in its vicinity, and was in no way connected with the abdominal cavity. It is of such interest that I report it in detail. He says (p. 537) that he operated on a man thirty-two years of age in whom a painless, smooth, fluctuating, immovable tumor, the size of a fist, had developed beneath and to the right of the umbilicus near the mid-line. Its increase in size had been very gradual, as it took six years for development. The patient during this time had often had vomiting, but was otherwise healthy. For three weeks the tumor had been painful and increasing in size. The skin had become reddened and edematous. The tumor had the size, form, and position of the subumbilical space. Fischer made an incision in the outer wall of the rectus along the subumbilical space, and found a densely adherent echinococcus sac, which could not be extirpated on account of its firm adherence to the peritoneum. He split it, scraped it out, and packed. The patient recovered and apparently remained well.

#### LITERATURE CONSULTED ON HYDATIDS AT THE UMBILICUS.

- Bérard, P. H.: Dict. de méd., Paris, 1840, xxii, 66.  
 Davaine, C.: Traité des entozoaires, Paris, 1860, 416.  
 Dupuytren: Tumeurs hydatiques. Clin. chir., 1833, iii, 378.  
 Fischer: Die Eiterungen im subumbilicalen Raume. Volkmann's Samml. klin. Vorträge, n. F., No. 89 (Chirurg. No. 24), Leipzig, 1890-94, 519.  
 Ledderhose, G.: Chirurg. Erkrankungen des Nabels. Deutsche Chirurgie, 1890, Lief. 45 b.  
 Leguinelin de Lignerolles: Quelques recherches sur la région de l'ombilic et les fistules hépatiques ombilicales. Thèse de Paris, 1869, No. 6.  
 Nicaise: Ombilie. Dictionnaire encyclopédique des sc. méd., Paris, 1881, 2. sér., xv, 140.

#### THE ESCAPE OF LIQUOR AMNII OR OF FETAL REMAINS THROUGH THE UMBILICUS.

A tubal pregnancy of small size may in time almost totally disappear. If it be of moderate dimensions and not operated upon, it may remain *in situ*, nothing but the distorted skeleton being left. I saw a most interesting example of this condition about fifteen years ago. Dr. J. Whitridge Williams received the specimen from New York, and on making a careful examination found that the tube near the uterus contained a recent small pregnancy, while in the outer end of the same tube was the skeleton of a previous tubal pregnancy. The bones of this fetus had been

compressed into a rounded mass several centimeters in diameter. On May 4, 1907, at the Johns Hopkins Hospital, I operated on a colored woman (Gyn. No. 13806) who had a definite mass in the ileocecal region. Her previous history was not clear and did not give us a clue as to the exact condition. On making an incision over the mass I found a packet of bones. (See Fig. 249, p. 584.) These were gradually dislodged. The end of one femur, which was fully 5 cm. long, had projected into the bladder, and the portion of the bone that had come in contact with the urine had a phosphatic covering several millimeters thick. The lumen of the large bowel in the vicinity of this collection of bones was perforated at two points, the ends projecting into the intestinal lumen. The opening in the bladder and the apertures in the bowel were closed and the sac drained. The patient made a prompt recovery.

In the case reported by Pfeffinger and Fritze, and referred to by Kussmaul, after the fetal bones had remained quiescent in a rudimentary uterine horn for over thirty years, suppuration had developed and the patient died. The accuracy of this case was fully attested, as the patient was a life prisoner and had escaped capital punishment years before only because at the time of the trial she claimed that she was pregnant. This case Dr. George L. Wilkins and I referred to several years ago.

The passage of fetal bones by the rectum has in the past been no great rarity. Where the pregnancy has been abdominal, the fetus in many instances goes on to term and becomes encapsulated, as was well seen in a full-term pregnancy that I removed several years ago and where the child had lain in the abdomen for four years. Sometimes the child may become calcified, as was clearly evident in the case reported by Dr. John G. Clark.

In the foregoing I have briefly outlined some of the end-results of an extra-uterine pregnancy. While going over the literature I found two cases in which there had been a tendency for the fetus to break through at or near the umbilicus, and to this I will add one coming under my own care.

Josenhans, in 1841, reported the case of a woman, sixty years of age, who was married at twenty and in short succession had two children. At thirty she complained of severe abdominal pain, with a rupture near the umbilicus. At first there was an escape of pus and then fecal matter, and on several occasions pieces of bone and hair. The fistula remained open and there was a prolapsus of the bowel through the opening. The patient died at sixty-four. There had evidently been an abdominal pregnancy, with escape of parts of the fetus through the abdominal wall. Had the bone and hair been due to a dermoid, a suppurating sinus would always have remained.

In 1874 Duboué reported the case of a woman, aged twenty-six, who entered the maternity hospital after being in labor for twenty-four hours. The pain diminished, and the patient complained of nausea and vomiting. On examination the enlargement suggested a seven and one-half months' pregnancy. The tumor was situated more to the right than to the left, and the nurse had previously made out the fetal heart. The patient improved and was sent home to await results. In February, at the time of the patient's admission, she was in fairly good health. A week after the labor pains had ceased, the patient lost her appetite, could not sleep, grew thinner, and had a peculiar brownish tint in her face. On February 7th she noted a considerable discharge of chocolate-colored material by the bowel.

On March 12th she again entered the hospital. The uterus was dilated on March 27th, and to the surprise of the surgeon was found to be empty. On April 9th the sac opened at the umbilicus and the fetus was then extracted piecemeal. The general peritoneal cavity was not opened, but the cavity containing the fetus was washed out. Two days later fecal matter came out of the sac. The patient gradually improved, and was discharged on June 6th. The fistula, which persisted until September of the same year, was scarcely perceptible, but there was an occasional escape of gas.

In 1901 I saw the following case at the Cambridge (Md.) Hospital:\*

On February 28, 1901, Dr. Goldsborough was called in by Dr. I. N. Tannar, of Vienna, Maryland, to see what the doctor supposed to be a case of obscure pregnancy. The patient had had one child nine years before. In April, 1900, she had missed her period and since then had presented the usual signs of pregnancy—nausea, enlarged breasts, increase in size of the abdominal girth. In August, while lifting some boxes, something had suddenly given way in her left side. This had occasioned severe pain and she had remained in bed until November 1st. About the middle of September there had been a bloody uterine discharge, and accompanying it considerable pain and nausea. Subsequently, she had had several similar discharges, which may have been menstrual periods. During the month of November she had been able to be out of bed, but had had to return in December. Throughout the entire illness she had had a good appetite and had been fairly well nourished. When seen, her temperature was 101.5° F.; her pulse, 140. Immediate removal to the Cambridge Hospital was advised, and on the following day she was driven 23 miles.

On examination under anesthesia the abdomen was seen to be very prominent. There was, however, no bulging in the flanks. The umbilicus had been converted into a tumor fully 5 cm. long by 3 cm. broad (Fig. 166). The skin over it appeared to be much thinned out, and at one point had given way. From this abraded area an exceedingly offensive, chocolate-colored fluid was escaping. Around the umbilicus the tissue was markedly indurated and pitted on pressure. On vaginal examination the cervix was found intact, but it was impossible to outline the uterus. Nothing could be detected laterally. An incision was made just below the sternum, and continued down almost to the pubes. The abdominal cavity proper was not exposed; that is to say, none of the abdominal contents came into view. Filling the cavity was a large quantity of chocolate-colored fluid, a fetus between six and seven months, and a large placenta. The placenta was attached low down in the pelvis, was exceedingly friable, but came away without producing any hemorrhage. The walls of the sac were about 4 mm. in thickness and excessively friable. They reminded me very much of granulation tissue. It was impossible to determine where the pregnancy had taken place, as the pelvic organs were entirely walled off. It is probable, however, that the uterus had ruptured and that the fetus with its membranes intact had escaped into the abdominal cavity. The fetal membranes had then become attached to the abdominal wall and to the surrounding structures. After removal of the fetus and the placenta, this large sac, which extended almost from the sternum to the pubes and laterally filled the entire anterior portion of the abdomen, was thoroughly washed out with salt solution and loosely packed

\* Goldsborough, Brice W., and Cullen, Thomas S.: A Rare Form of Extra-uterine Pregnancy. *Amer. Medicine*, April 6, 1901, p. 32.

with iodoform gauze. The upper half of the incision was closed, the lower half I left open to insure thorough drainage. At the time of operation the patient's pulse was 140. The operation occasioned no shock.

After the operation the temperature ranged from normal to 101.5° F. for the first four days, but after that time became normal. The pulse was weak and irregular for six days, but gradually regained its normal tone. The pack was removed on the seventh day, with the escape of a moderate amount of discharge. A light gauze drain was then inserted. On March 13th the abdomen was perfectly flat

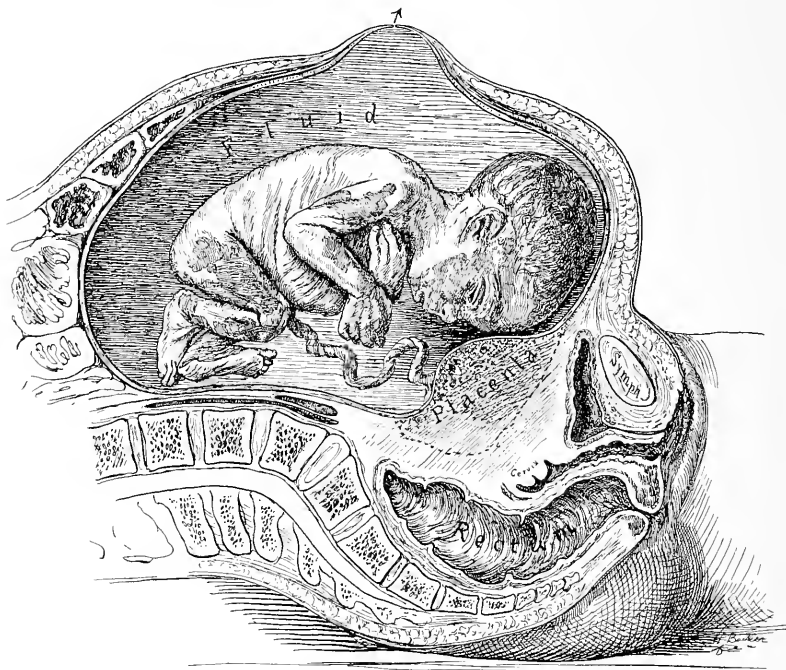

FIG. 166.—ABDOMINAL PREGNANCY WITH SPONTANEOUS ESCAPE OF LIQUOR AMNII FROM THE UMBILICUS.

The drawing, of course, is somewhat diagrammatic. It represents a longitudinal section of the body. The fetus and the fetal membranes are lying immediately beneath the abdominal wall, and are attached anteriorly to the peritoneum almost from the sternum to the pubes. At the umbilicus the fetal sac bulges into the hernial opening, and at the most prominent point this hernial sac has given way, allowing the fluid to escape externally. The fetus is well preserved, appears to be about six months old, and shows slight maceration on the face, arms, and legs. The site of the placenta is roughly outlined by the dotted lines. The cervix is normal, but on account of the marked distortion, the presence of the abdominal tumor, and the edema it was impossible to outline the uterus or appendages; hence their relation is left hazy. The bladder and rectum are in their normal positions. As will be seen from the drawing, a median incision in the abdominal wall would open directly into the sac and in no way involve the general peritoneal cavity.

and all evidence of edema had disappeared. On removal of the drain there was a slight discharge. On bimanual examination it was now possible to outline the uterus to some extent. The organ was about the size of a two months' pregnancy, and situated directly behind the pubes. It was slightly movable.

Pathological Report (Gyn. Path. No. 4744).—The specimen consists of a fetus with its accompanying placenta. The fetus, when folded upon itself, is 17 cm. in length. The distance from the occiput to the heel is 29 cm. The child is well formed, shows no external abnormality, and is a female. There is a moderate quantity of hair, but the skin has to a great extent macerated, and the pigmented



layer is readily peeled off. The umbilical cord appears to be about 8 cm. in length. It shows nothing of interest. The placenta is approximately 16 by 10 by 5 cm. It is very friable. In some places it presents the usual appearance; in others, especially in the depth, the tissue is somewhat homogeneous, hemorrhagic, and seems to be breaking down.

Histologic examination of sections from various parts of the placenta shows that it consists almost entirely of necrotic tissue and canalized fibrin. The contours of the villi are everywhere visible, but the nuclei of the epithelial cells, as well as those of the stroma of the villi, have entirely disappeared. The central portions of numerous villi are partially filled with calcareous plaques. At one point are a moderate number of disintegrated polymorphonuclear leukocytes. Otherwise the entire tissue is devoid of nuclei.

This complete necrosis of the placenta accounts for the ease with which it was peeled off and also for the absence of hemorrhage during its removal.

The discharge of bone and hair from the umbilicus, although it affords strong presumptive evidence of pregnancy, is not necessarily conclusive, as shown by Sanderson's case. Dr. S. E. Sanderson, in writing me from Detroit under date of March 31, 1913, says: "In September, 1897, I was called to see a German woman of the poorer class, aged about twenty-seven, married, with no children. She was suffering from a large abdominal tumor, and at the same time there was a bulging at the umbilicus covered with reddened skin and very compressible. This swelling evidently contained fluid.

"Several days after seeing this patient I was hurriedly called to her house. On arriving I found that rupture had taken place through the umbilicus. Several pints of a pea-soup-like fluid and two or three teeth had been discharged, while from the opening there extended a long strand of hair. The abdomen was greatly diminished in size, and the patient felt more comfortable. I advised her removal to the hospital for proper care, but she refused, and I lost track of her. About a year later I was told that she had gone to the hospital for operation and had had a large tumor removed."

As Sanderson says, this was without doubt a dermoid cyst. We all know that dermoid cysts show a peculiar tendency to become adherent, and that they are prone to suppurate. This cyst had suppurated, grown fast to the umbilicus, and part of its contents had escaped through the umbilical opening.

#### LITERATURE CONSULTED ON ESCAPE OF LIQUOR AMNII OR FETAL REMAINS THROUGH THE UMBILICUS.

- Clark, J. G.: A Rare Case of Lithopedion. *Johns Hopkins Hosp. Bull.*, November, 1897, viii, 221.
- Cullen and Wilkins: Pregnancy in a Rudimentary Horn, Rupture, Death, Probably Migration of Ovum and Spermatozoa. *Johns Hopkins Hosp. Reports*, 1897, vi, 126.
- Cullen, T. S.: A Series of Interesting Gynecologic and Obstetric Cases. *Jour. Amer. Med. Assoc.*, May 4, 1907, 1491.
- Duboué: Observation de grossesse extra-utérine, gastrotomie, guérison. Fistule intestinale au niveau de l'ombilic. *Arch. de tologie, des maladies des femmes et des enfants nouveaux-nés*, 1874, i, 577.
- Goldsborough and Cullen: A Rare Form of Extra-uterine Pregnancy. *Amer. Medicine*, April 6, 1901, 32.
- Josenhans: Merkwürdiger Fall von künstlichem After. *Med. Correspondenzbl., Württemberg*, 1841, xi, 60.

## ESCAPE OF FOREIGN BODIES THROUGH THE UMBILICUS.

Blum, in his article on Tumors of the Umbilicus in the Adult, published in 1876, cites three cases—those observed by Ambroise Paré, Diemberbroeck, and Greenhill.

Ambroise Paré's patient, a woman, had swallowed a brass needle. Two years later it passed out at the umbilicus through a small opening.

Diemberbroeck's patient, a child, had swallowed a shoemaker's awl. Later a small, painful, non-suppurating tumor presented at the umbilicus. This contained the foreign body.

Greenhill's case was reported in the Philosophical Transactions of the Royal Society of London in 1700, vol. iii, p. 93. A woman, who had swallowed a certain number of plum-stones, finally developed a tumor in the umbilical region. This suppurated, and the stones escaped from the umbilicus. The woman died twenty days later.

Weiss briefly referred to a case seen by Cladus. The patient was a man. Plum-stones and worms escaped from his umbilicus.

Pétrequin's case, in which a uterine sound introduced through the vagina was lost and finally presented at the umbilicus, is of such interest that I shall report it in detail.

Uterine Sound Introduced Into the Uterine Cavity and Removed Through the Umbilicus.\*—Madame X, mother of several children, claimed that when she was between six and eight weeks pregnant a midwife had introduced a sound to bring on a miscarriage. The sound was passed far up and could not be reached again. Miscarriage followed, but no sound came away. Six days later, after the most careful examination, no evidence of the sound could be found. Examinations on several days in succession were of no avail. Four months later the patient was in good health, but came to the hospital on account of a small enlargement at the umbilicus. It looked like a beginning umbilical hernia.

On bimanual examination with the patient standing, the upper end of the sound could be felt at the umbilicus. The uterus was dilated, and several attempts made to remove the sound from below, but without avail. An incision was finally made at the umbilicus, and by manipulation the sound was removed from above. The patient was perfectly well in seven days. In this case the sound had perforated obliquely the anterior portion of the cervix, and its lower end had slipped between the bladder and the cervix, while the upper end gradually had reached the umbilicus. Pétrequin and Foltz claim this as the only case of the kind on record.

These are the only cases of foreign bodies escaping from the umbilicus which we have found in the literature.

\* Pétrequin et Foltz: Extraction par l'ombilic d'une sonde de femme introduite par les voies génitales. Lyon méd., 1869, iii, 509.

## LITERATURE CONSULTED ON THE ESCAPE OF FOREIGN BODIES THROUGH THE UMBILICUS.

- Blum, A.: Tumeurs de l'ombilic chez l'adulte. Arch. gén. de méd., Paris, 1876, 6. sér., xxviii, 151.  
 Pétrequin et Foltz: Extraction par l'ombilic d'une sonde de femme introduite par les voies génitales. Lyon méd., 1869, iii, 509.  
 Weiss, E.: Ueber diverticuläre Nabelhernien und die aus ihnen hervorgehenden Nabel fisteln. Inaug. Diss., Giessen, 1868.

## CHAPTER XXIII.

### UMBILICAL TUMORS.

Hypertrophy of the umbilicus.

Angiomata of the umbilicus; report of cases.

Umbilical lymphocele.

Myxomata.

Fibromata; report of cases.

Papillomata; report of cases.

Lipomata.

Dermoids or atheromatous cysts; report of cases.

Umbilical tumors consisting chiefly of sweat-glands.

An abdominal tumor attached to the inner surface of the umbilicus by a pedicle two inches in diameter.

Papilloma of the umbilicus secondary to papilloma of the ovary.

### UMBILICAL TUMORS.

Benign:

Hypertrophy.

Angiomata.

Lymphocele.

Benign connective-tissue growths.

Myxomata.

Fibromata.

Papillomata.\*

Lipomata.

Dermoid cysts.

Sweat-gland tumors.

Abdominal myoma springing from the umbilicus.

Papilloma secondary to growth in ovary. †

Adenomyomata.

Malignant:

Carcinoma of the umbilicus.

A. Primary. { 1. Squamous-cell carcinoma.  
2. Adenocarcinoma.

B. Secondary. { 1. From the stomach.  
2. From the gall-bladder.  
3. From the intestine.  
4. From the ovary.  
5. From the uterus.  
6. From other abdominal organs.

Sarcoma.

1. Telangiectatic myxosarcoma.

2. Spindle-cell sarcoma.

3. Round-cell sarcoma.

4. Melanotic sarcoma.

\* In the ordinary umbilical papilloma the growth is caused by a proliferation of the stroma—the squamous epithelium covering the papillæ occupies merely a passive rôle. It is for this reason that we have grouped these small tumors with the benign connective-tissue growths.

† These may or may not be malignant.

## GENERAL REMARKS.

Many authors who have published cases showing abnormalities of the umbilicus have endeavored to classify satisfactorily umbilical diseases. Probably one of the best articles on the subject is the exhaustive treatise by Nicaise, published in Paris in 1881. In 1883 Codet de Boisse gave a satisfactory résumé of the subject, and the following year Reginald H. Fitz, of Boston, published a most instructive article in which he included lesions of the umbilicus owing their origin to persistence of the omphalomesenteric duct.

Villar, in 1886, wrote a thesis on umbilical tumors, going into the subject very carefully, and making a satisfactory classification of the various umbilical tumors. In 1890 Ledderhose discussed umbilical diseases very fully and satisfactorily, and in 1892 Pernice published his well-known monograph on Umbilical Tumors. Finally, in 1906, Guiselin, in his Bordeaux thesis entitled Cancer of the Umbilicus, outlined a very practical classification of umbilical tumors. After reviewing the literature on the subject, I have found the above classification the most satisfactory:

## LITERATURE CONSULTED ON UMBILICAL TUMORS IN GENERAL.

- Codet de Boisse: Tumeurs de l'ombilic chez l'adulte. Thèse de Paris, 1883, No. 311.  
 Fitz, Reginald: Persistent Omphalomesenteric Remains, Their Importance in the Causation of Intestinal Duplication, Cyst Formation, and Obstruction. Amer. Jour. Med. Sci., 1884, lxxxviii, 30.  
 Guiselin, E. J. M. J.: Du Cancer de l'ombilic. Thèse de Bordeaux, 1906, No. 47.  
 Ledderhose, G.: Deutsche Chirurgie, 1890, Lief. 45 b.  
 Nicaise: Omphilic. Dictionnaire encyclopédique des sc. méd., Paris, 1881, xv, 140, deuxième sér.  
 Pernice, Ludwig: Die Nabelgeschwülste, Halle, 1892.  
 Villar, Francis: Tumeurs de l'ombilic. Thèse de Paris, 1886, No. 19.

## HYPERTROPHY OF THE UMBILICUS.

Villar\* speaks of hypertrophy of the umbilicus in a patient sixty years of age. Inasmuch as from the description it is clear that there was a definite umbilical suppuration and the histologic examination showed an inflammatory condition, we should certainly hesitate to class the case as one of true hypertrophy of the umbilicus. I have encountered no other literature on the subject.

## ANGIOMATA OF THE UMBILICUS.

Definite literature on the subject is very rare.

Virchow, in 1862, mentions two varieties of umbilical fungi. The one is usually rich in blood-vessels, bleeds readily, and is found after the cord comes away. It consists of granulation tissue, and after the use of astringents soon disappears. He is evidently referring to the simple granulation tissue not infrequently noted after the cord comes away.

The second variety represents a congenital tumor, and in the majority of cases is a remnant of the omphalomesenteric duct. Virchow then refers to cases reported by Maunoir and Lawton.

\* Villar: Op. cit., p. 76.

Nicaise refers to the subject and mentions three cases from the literature.

Ledderhose briefly refers to angiomata of the umbilicus, and says that cases have been recorded by Maunoir, Chassaignac, Lawton, Boyer, and Colombe.

Kidd and Patteson, in 1889, in an article on Capillary Angioma of the Umbilicus, reported a case in a child six weeks old. From the description, however, it would seem probable that the tumor consisted of granulation tissue and was not an angioma in the accepted sense of the word, although it must be admitted that granulation tissue in itself at times has such a rich capillary blood-supply that it might with propriety be called an angioma.

Pernice, in his exhaustive monograph on Tumors of the Umbilicus, briefly considers the cases recorded in the literature. He also refers to a case recorded by Boyer. A nine-year-old girl from her birth had had an umbilical tumor largely made up of varicose veins. This tumor was pedunculated, like a polyp, grew slowly, was bluish in color, and felt soft. After being repeatedly tied off, it completely disappeared.

Robson, in 1872, reported a somewhat complicated tumor of the umbilicus occurring at birth. The soft and elastic portion of the tumor was of a dirty, livid color and probably represented an area of hemorrhage and not a genuine angioma. The essential points in the case are as follows:

The mother of the child was delivered before Robson arrived, but he noticed an abnormal condition at the umbilicus, three distinct tumors resting on the abdomen, and connected with the umbilicus close to the integument of the navel. The one containing the cord was about the length and circumference of a one-ounce quinin jar, with a continuation of a small, shriveled cord projecting from its extremity. The under part of this tumor consisted of firm, compact tissue; the upper was soft and elastic, without any pulsation, and of a dirty, livid color. Immediately beneath and growing from the first, at its junction with the abdomen, was a second tumor consisting of a transparent, globular mass the size of a large orange, and a third, the size of a pullet's egg, containing a thick, albuminous substance like jelly. The growths were extirpated.

The tumor consisted mainly of the cord in a spiral form, each coil adhering to the other and thoroughly agglutinated by the albuminous substance. There was extravasation of blood, with here and there organized matter.

In the cases reported by Chassaignac, Lawton, and Colombe, a definite angioma of the umbilicus existed. The first two were noted in infants, but Colombe's case occurred in an adult.

As seen from the detailed report, when Chassaignac's patient was twelve days old, a minute nodule was noted at the umbilicus. At six months the tumor was as large as a hen's egg and was non-pedunculated; the overlying skin had a bluish tinge, and beneath the surface a varicose network of veins could be seen. Where the veins were very near the surface, the bluish tinge of the skin was naturally more accentuated. A large vein appearing to the left of the xiphoid passed downward to the umbilicus and was continuous with the tumor.

Lawton's observation was made on a new-born child, and in addition to the tumor there was an umbilical hernia. The tumor was the size of a jargonelle pear, and darkish in color. It was of the consistence of placental tissue. On microscopic examination, it was found to be composed chiefly of the ramifications of large blood-vessels held together by areolar tissue.

Colombe's patient, when twenty-six years old, noticed a small tumor the size of a grain of wheat at the umbilicus. It gradually increased in size, was purple and soft. When seen ten years later, it was the size of the end phalanx of the little finger. Two years before coming under observation she had had a hemorrhage from the tumor lasting two days. The bleeding was controlled by styptics. Three days before admission the hemorrhage recurred and the bleeding was so excessive that the patient showed marked constitutional symptoms.

The cases of Chassaignac, Lawton, and Colombe are so interesting that I report them in detail:

**AN ERECTILE VENOUS TUMOR DEVELOPING IN THE REGION OF THE UMBILICUS IN A CHILD SIX MONTHS OLD.\***—The child was six months old. To the left of the umbilicus was attached a tumor the size of a small hen's-egg. This was regular, non-pedunculated, raising the left half of the umbilical margin and the skin, and giving the overlying skin a bluish tinge. The surface of the tumor was evidently made up of a network of varicose veins (subcutaneous), and had three or four small spots where the bluish tint was more marked. Another bluish spot, with the diameter of a 50-centime piece, had occupied the summit of the tumor. This was crescentic, with the hollow of the crescent directed upward and toward the median line. A large vein appearing to the left of the xiphoid passed downward to the umbilicus and evidently was continuous with the tumor.

Pressure on the tumor produced pallor, but, when the finger was raised again, the color returned with increasing intensity.

The mother noticed, twelve or thirteen days after birth, a small spot the size of a pin-head at the umbilicus. A bandage was applied, but the spot increased in size and became thickened. It was removed satisfactorily. The tumor consisted of two parts—adipose tissue and blood-vessels surrounded by cellular tissue. The vessels were very abundant, and in several places showed varicose dilatations. This tumor was an angioma.

**A CASE OF VASCULAR (ERECTILE) TUMOR IN THE SHEATH OF THE CORD IN A NEW-BORN.**—Mr. Lawton† was called to the delivery of a fine male child, and when he proceeded to tie the cord, he found a tumor the size and shape of a medium jargonelle pear with its neck communicating with the cavity of the abdomen through the umbilical opening and strongly adherent to the cord, the covering being common to both. Mr. Lawton divided the cord above the tumor in the usual way. On examination the growth felt tough, rather fleshy, and somewhat like a placenta might feel before degeneration commences—it did not feel at all like intestine, although when the child cried, both it and the investing membrane, together with the tegumentary portion of the umbilicus, enlarged very much—the tumor from being engorged with blood and the membrane from protrusion of intestine. Pressure reduced the one and somewhat decreased the size of the other.

After reduction of the hernia, pressure was applied by means of a pad and bandage, and it was resolved to wait and see what might be the termination of the case if left to nature, as it was thought that the tumor might dry up and slough with the cord. After a day or two affairs presented nearly the same appearance as

\* Chassaignac, M. E.: *Traité de l'écrasement linéaire*, Paris, 1856, 535.

† Lawton: *London Obstet. Trans.*, 1866, vii, 210.

at first, and Mr. Lawton determined to explore a little. He did so by carefully dissecting (over the fundus of the tumor) the outer covering, when a clear, yellow serum escaped. He then made a small opening into the second covering, and blood of a dark color flowed pretty freely. A pad and bandage were immediately applied, and the case was allowed to take its course for two days more. On entering the room on the third day the smell of the decomposing membranes was strong, and the integument around the umbilicus much inflamed. The umbilical opening was large enough to receive four fingers, and was more or less oval.

At the lower end protruded a knuckle of gut; at the upper end, a non-pulsating, pyriform tumor, and at the right-hand side, the cord, between the knuckle of gut and tumor. The membranes were gangrenous and the fundus of the tumor was bare. It presented a dark color; to the touch it felt firm, unless strongly compressed, when it somewhat diminished in size and was a little flaccid. The crying of the child gave now no impetus to the tumor.

Lawton resolved to return the protruded intestine, and, after applying a ligature around the neck of the tumor, to excise it. After chloroform had been given, a finger and thumb were applied to the neck of the growth and fully compressed it. The operator made a slight incision in the fundus of the tumor, and on careful relaxation of the pressure, the blood was inclined to flow very freely. A ligature was then applied around the neck of the growth, but the membranes, being gangrenous, it cut through them, and, the abdominal muscles becoming rigid at the same time, from eight to ten inches of gut protruded. The tumor was excised above the ligature, the cord tied as low down as possible, and after careful and patient manipulation the protruded intestine was returned. The opening was closed as far as possible by passing through four common needles in place of harelip pins; a pad and bandage were applied in the usual way. The child's bowels were not moved for three days after the operation, when they acted freely. The little patient had no bad symptoms, and at the time of the report was quite well.

Microscopic examination by Dr. J. Braxton Hicks showed that the whole mass was penetrated by large blood-vessels, of the ramifications of which it was principally composed, coupled with areolar tissue, in the network of which were nucleated cells of round or oval form, generally in groups of four or five. There was in some parts, however, an excess of the connective-tissue elements so as to form solid portions. The tumor was an angioma.

**A Vascular Tumor of the Umbilicus.\***—The patient was a woman, thirty-six years of age, in good health. She had had a child at nineteen. Ten years before she had noticed a small tumor the size of a grain of wheat at the umbilicus. It had gradually increased in size. It was purple, rather soft, painless, but made her uncomfortable. About the week before she was seen, it was the size of the end of the phalanx of the little finger. Two years before there had been a hemorrhage from the tumor, the bleeding coming in jets of the diameter of a pin. The hemorrhage lasted two days, was not continuous, and was controlled by perchlorid of iron. Three days before admission she had a second hemorrhage and perchlorid of iron was used, the flow ceasing just as the astringent was employed. The volume of bleeding could be compared to that from the femoral artery; the bleeding, however, was intermittent. The patient was in a sea of blood. She was

\* Colombe: Tumeur vasculaire de l'ombilic, hémorrhagie, guérison. *Gaz. méd. de Paris*, 1887, lviii, 245.

pale and apparently in a serious condition. Forceps were applied, and the area ligated *en masse*, but with difficulty, as the bleeding came from the bottom of the umbilicus. Seven days later the bleeding again recurred. A ligature was applied, and the bleeding stopped and never returned. The tumor disappeared.

#### LITERATURE CONSULTED ON ANGIOMATA OF THE UMBILICUS.

- Chassaing, M. E.: *Traité de l'écrasement linéaire*, Paris, 1856, 535.  
 Colombe: Tumeur vasculaire de l'ombilic, hémorrhagie, guérison. *Gaz. méd. de Paris*, 1887, lviii, 245.  
 Kidd and Patteson: Capillary Angioma of the Umbilicus. *Illustrated Med. News*, 1889, iv, 148.  
 Lawton: Case of Vascular (Erectile) Tumor in the Sheath of the Cord in a New-born. *London Obstet. Trans.*, 1866, vii, 210.  
 Ledderhose, G.: *Chirurgische Erkrankungen des Nabels*. *Deutsche Chirurgie*, 1890, Lief. 45 b.  
 Nicaise: Ombilic. *Dictionnaire encyclopédique des sc. médicales*, Paris, 1881, 2. sér., xv, 140.  
 Pernice, L.: *Die Nabelgeschwülste*, Halle, 1892.  
 Robson, R.: *Disease of the Funis Umbilicalis*. *Medical Examiner*, Chicago, 1872, xiii, 33.  
 Virchow: *Die krankhaften Geschwülste*, 1862-63, iii, erste Hälfte, 467.

#### UMBILICAL LYMPHOCELE.

Koeberle,\* in 1878, speaking of ovarian cysts, said that sometimes the lymphatic vessels beneath the umbilicus take on an excessive development and the umbilicus becomes the site of a tumor consisting exclusively of the sac-like dilations of the lymphatic vessels.

Codet de Boisse† quotes a letter from Koeberle to Blum in which Koeberle stated that in his Cases 49 and 50 he had removed growths of this character when operating for ovarian tumors. One of these umbilical tumors was 8 cm. in diameter. He further drew attention to the fact that similar tumors had never been described. They are evidently very rare, as I have not found mention of any in the literature. In a very large series of patients from whom ovarian tumors have been removed at the Johns Hopkins Hospital we have never seen umbilical growths of this character.

#### BENIGN CONNECTIVE-TISSUE GROWTHS OF THE UMBILICUS.

Under this head are included myxomata, fibromata, papillomata, and lipomata. As a rule, papillomata are classified with epithelial growths. In umbilical papillomata, however, the connective-tissue growth is the essential feature, the epithelium playing a passive rôle. I have accordingly included them under connective-tissue growths.

#### MYXOMATA OF THE UMBILICUS.

These tumors are exceptionally rare. According to Ledderhose,‡ Weber collected three cases—those of Fischer-Cöln, Busch, and his own. In Busch's case the tumor was the size of a goose's egg. Its surface was ulcerated.

\* Koeberle: *Nouveau dictionnaire de méd. et de chir. prat.*, 1878, xxv, 522.

† Quoted by Pernice: *Die Nabelgeschwülste*, Halle, 1892, 21.

‡ Ledderhose, G.: *Deutsche Chirurgie*, 1890, Lief. 45 b.



Mori\* described a sessile umbilical tumor the size of a cherry, which had ulcerated at its most prominent part. Histologically, it consisted of fibrous and myxomatous tissue. He gives a very good picture of the microscopic appearances.

In Pernice's† monograph will be found the best description of this class of umbilical tumors. He says that myxoma of the umbilicus was first described by Weber, and was supposed to originate from portions of Wharton's jelly. The condition is very rare, only nine cases being found in the literature. On section the tumors look like white pork, are pale, edematous, and gelatinous. Some are soft, others hard, according to the amount of connective tissue. They vary in size from that of a hazelnut to that of a goose's egg. In four cases the tumors were pedunculated and the pedicle came directly from the umbilical scar. In two cases the tumors lay on the top of an umbilical hernia. Pernice points out that only the cases since Weber's time have been examined microscopically. The blood-vessels are abundant. The vessel-walls are thick and lie in a connective-tissue framework consisting chiefly of spindle-cells and sometimes of round-cells. There is an intercellular substance. In other words, the ground-substance is like that encountered in embryonic tissue. Most of these tumors are covered over with normal skin, and only rarely is the surface ulcerated. The prognosis is good.

Pernice then goes on to record cases reported by Weber, Maunoir, Chassaignac, Lawton, Villar, Virchow, and Leydhecker. In only a few of the cases are the microscopic reports of any value.

#### FIBROMATA OF THE UMBILICUS.

Growths of this character are likewise rare. Although the majority occur in middle life and in males, they are sometimes found in infants. The size of the tumors reported varied greatly. One was as large as a bird's egg, another the size of a walnut, another as large as an apple. The largest was said to be the size of an infant's head at term. They are usually oval or round and more or less pedunculated, the pedicle springing from the umbilical depression. Sometimes, however, the umbilicus may be recognized as an irregular slit in the center of the tumor.

The growth is usually covered with normal or slightly atrophic skin. On account of the exposed site of the tumor, its more prominent surface may be excoriated, presenting blackened points; or the injured areas may be covered with crusts.

On section, the growth usually presents a grayish-white or whitish-yellow surface, with a definite fibrous arrangement. In a few instances one or more small cysts containing serous fluid were found, or a small quantity of fat was detected in the tumor.

Histologic examination shows that the skin covering the growth is normal or atrophic, or that there is some thickening of the squamous layers. In the last type the papillæ are much elongated. The stroma of the tumor consists, as a rule, of typical fibrous tissue containing a varying number of spindle-shaped nuclei. Some of the growths, particularly where there has been an irritation of the surface, show marked small-round-cell infiltration in the vicinity of the point or points of such irritation. Here, as in other parts of the body, the diagnosis between a very cellular fibroma and a spindle-cell sarcoma is fraught with much difficulty or is impossible.

\* Mori, A.: *Contributo allo studio dei tumori ombelicali*. Gazzetta degli ospedali, Milano, 1902, xxiii, 632.

† Pernice: *Die Nabelgeschwülste*, Halle, 1892.

On account of the rarity of this condition, I append those cases in which the diagnosis of fibroma of the umbilicus was certain, or at least highly probable.

#### CASES OF FIBROMA OF THE UMBILICUS.

**Fibroma of the Umbilicus.**—Legrand\* reported from Sappey's service the case of a man fifty-one years of age. When the patient was thirty-nine years old a tumor the size of a hazelnut had been observed at the umbilicus. This was soft and covered with skin of a natural color. For five months before the patient came under observation it had been increasing rapidly, becoming more than two-thirds larger. Later, small excoriations were noticed on the surface. These were covered with crusts.

On admission to the hospital an ovoid tumor, about seven or eight inches in its vertical diameter, was found in the umbilical region. It was somewhat pedunculated, and with the patient lying down reached to within 1 cm. of the xiphoid. The pedicle was inserted in the umbilical scar. The tumor itself was hard, smooth, round, and in its right third bossed and ulcerated. In other portions it was covered with brownish-yellow crusts alternating with a purple discoloration of the skin. At some points fluctuation was noted, but there was no hemorrhage from the surface. The patient's general condition was good. The tumor was removed and recovery followed. The tumor on section was whitish in color, homogeneous, and very hard. It contained a small, cyst-like cavity with serous fluid contents. Robin, who made the histologic examination, said that it was a fibroplastic tumor and not a cancer.

**A Fibronucleated Tumor at the Umbilicus.**†—The patient was thirty years of age, and the tumor had been noticed for three months. On admission to the hospital in April, 1857, the tumor was the size of an orange and situated beside the umbilicus. It had evidently developed in the umbilical wall, and was firm and fibrous in character. The general health was good. On histologic examination the tumor was found to be composed of fibrous tissue. Bryant draws attention to the fact that such tumors are evidently rare.

**Fibrolipoma of the Umbilicus.**‡—Hugh G., aged thirty, seven years before had noticed a small lump about the size of a walnut at the site of the navel. It increased gradually for two years, when a surgeon, probably a quack, "put it back," but it soon returned. Until six months before Barton saw him the tumor had increased only gradually, but since then had doubled in size. It was so large that it prevented the patient from walking. It was oval, and extended across the abdomen from the umbilicus to the left anterior superior spine. It was slightly constricted at its base, measured 23 inches in circumference, and was fixed to the skin only at the umbilicus. On removal it was found attached to the underlying tissue at only one point. The abdomen was not opened. No histologic examination is mentioned.

**Fibromata of the Umbilicus.**—Damalix§ treats the subject in general, and says that Sappey and Limange report cases in which the pedicle came from the umbilicus.

\* Legrand: Tumeur volumineuse de la région ombilicale de nature fibroplastique, prise pour une tumeur encéphaloïde. *Gaz. des hôp.*, 1850, 29.

† Bryant, T.: *Guy's Hospital Reports*, 1863, ix, 245.

‡ Barton: Reported by Bennett: *Dublin Jour. Med. Sci.*, 1882, lxxiv, 239.

§ Damalix: Étude sur les fibromes de la paroi abdominale antérieure. Thèse de Paris, 1886, No. 148.

**A Fibroma of the Umbilicus.** \*—A woman, twenty-two years of age, entered the Hôtel-Dieu on May 20, 1888. In February, 1887, one month after her child had been weaned, an umbilical tumor was first noticed. This was the size of a hazelnut, and could be rolled between the fingers. For a time it grew slowly, but after six months rapidly.

At the umbilical site was a tumor the size of the head of a child at term. Its summit was divided by the distended umbilical cicatrix. The tumor was hard, with several points of softening. It was irregular and bossed. The skin covering was normal, without any marked dilatation of the veins. It slid readily over the tumor.

The growth was easily dissected out, but was found intimately adherent to the peritoneum. Recovery followed.

The tumor was hemispheric, irregular, about 10 cm. in diameter; it had a whitish surface, and presented an irregular, bossed appearance in the depth, where there were several depressions dividing it into lobules. On section it was whitish and smooth; in the deeper portion, yellowish in color. Here it had a definite fibrous arrangement.

Histologically, the tumor was composed exclusively of fibrous tissue, wavy threads for the most part running parallel to one another, but with no characteristic arrangement. The cells were abundant and in general well developed. They were fusiform in shape. The tumor seemed to have originated from the aponeurosis. It was a fibroma.

**Fibrous Tumors in the Umbilicus.**—Pernice† says this form of tumor cannot be sharply differentiated histologically from those of inflammatory origin. It may originate from three different parts of the umbilicus: (1) From the dense connective tissue of the umbilical scar; (2) from that of the skin which, as we have seen, is really scar tissue covered with epithelium; (3) in young individuals from myxomatous connective-tissue remains of the cord.

**Fibroma of the Umbilicus** [?]. ‡—This case occurred in Volkmann's private practice. E. H., aged forty-two, had at the umbilicus a hard, slightly lobulated, broad-based tumor the size of an apple. This was thought to be a fibroma. On histologic examination, however, it proved to be a spindle-cell sarcoma. The spindle-cells were relatively small and had large nuclei. The abdomen was not opened. The woman was well at the end of ten years. [A sarcoma occurring in the abdominal wall is so intimately associated with the surrounding tissue that one would hardly expect a permanent recovery, such as occurred in this case. This fact would rather indicate a cellular fibroma.—T. S. C.]

**A Fibroma of the Umbilicus** [?]. §—A man, forty-nine years of age, entered Polaillon's service at the Hôtel-Dieu March 25, 1895. Eighteen months before he had noticed at the umbilicus small tubercles, which had caused pain and inconvenience.

Attached to the lower border of the umbilicus was a pedunculated tumor, cylindrical in form, 5 cm. long and 12 or 13 mm. in diameter. Its free end showed a small crust covering a healed area of ulceration. The skin covering it was deli-

\* Pic, Adrien: Lyon méd., 1888, lix, 546.

† Pernice, L.: Die Nabelgeschwülste, Halle, 1892.

‡ Pernice, L.: Op. cit., obs. 69.

§ Sourdille, Gilbert: Sarcome pédiculé de la peau de l'ombilic. Bull. de la Soc. anat. de Paris, 1895, lxx, 302.

cate and reddish in color. On taking the tumor between the fingers it gave the sensation of the finger of a glove filled with nuts. The skin surrounding the tumor contained seven or eight pinkish tubercles about the size of green peas. The skin alone was involved, as the tumor was movable on the underlying aponeurosis. No enlarged glands were detected, and the general health was good. The diseased area was removed. Histologic examination of the main tumor and of the small nodules showed sarcoma fusocellulare covered with skin. The superficial half of the skin seemed to have been the starting-point of the tumor, which tended to pass out and become pedunculated.

[The growth may equally well have been a fibroma associated with secondary small nodules. The microscopic examination is not conclusive.—T. S. C.]

Probably a Fibroma of the Umbilicus.\*—J. W., ten months old, was brought to the clinic February 27, 1896. He had remains of the omphalomesenteric duct at the umbilicus, as recognized by a reddish tumor covered with intestinal mucosa. In addition there was a smooth, cap-like area partly covering this reddish tumor, which was composed chiefly of fibrous tissue (Fig. 124, p. 209). [Evidently a true fibroma.—T. S. C.]

A Small Fibroma Associated with an Umbilical Concretion.—Coenen† reports cholesteatomata of the umbilicus, and in his Fig. 2 shows a definite but small fibroma occupying the umbilical cicatrix. It is covered over with many layers of squamous epithelium. The central portion consists of fibrous tissue, and scattered throughout it are many small round-cells, indicating recent inflammation. The inflammatory reaction was evidently started up by the umbilical concretion (Fig. 151, p. 252).

#### PAPILLOMATA OF THE UMBILICUS.

Probably the first case of this character recorded was that of Fabricius von Hilden, published in 1526. From that time on isolated cases of papilloma of the umbilicus have been recorded, but, as in the majority of these no microscopic examination was made and as the gross picture was not sufficiently convincing, we have omitted most of these, confining our attention chiefly to those cases in which a careful histologic description has been given. Most of the tumors have been noted between the twenty-fifth and fiftieth years. In Broussolle's case, however, in a child only two months old, a typical papilloma, 5 mm. in diameter, occupied the umbilical depression. Ordinarily one would consider this small nodule in such a young individual as a mass of granulation tissue left after the cord had come away, or as a remnant of the omphalomesenteric duct. Broussolle, however, distinctly says that its surface was covered with squamous epithelium analogous to that of the skin.

From the limited number of cases it is difficult to draw any definite conclusion, but papillomata seem to be equally frequent in both sexes.

As a rule, they are of slow growth and vary from 5 mm. in diameter to the size of a walnut. They are usually pedunculated, but in the case reported by Péraire the papillary growth had spread out for a considerable distance into the surrounding abdominal wall.

\* Sauer, F.: Ein Fall von Prolaps eines offenen Meckel'schen Divertikels am Nabel. Deutsche Zeitschr. f. Chir., 1896-97, xlv, 316.

† Coenen, H.: Das Nabelcholesteatom. Münch. med. Wochenschr., 1909, 56. Jahrg., 1583.

Where the growth is small, it frequently looks red and reminds one of a raspberry, and on examination with a magnifying-glass it is found to be composed of blunt papillary masses. As the growth increases in size the portion near the pedicle may have a violet tint, while the superficial portion is pinkish in color.

In Segond's case, reported by Villar, the growth consisted of rounded projections varying greatly in size. The largest nodule was bean-shaped and contained a small cyst; another was the size of a pea, and lying between them were smaller ones. As a rule, when the tumor reaches its full size it resembles a large wart. Its surface is covered with myriads of papillæ, and these are flattened laterally, owing to the close juxtaposition. On section the papillary or tree-like arrangement is clearly evident, and the stroma of the nodule and of its pedicle is seen to consist of fibrous tissue.

Histologic examination shows that the surface of the papillæ is covered with squamous epithelium, in which epithelial pearls can occasionally be demonstrated. Where there has been much irritation, the epithelium may be thickened and the skin papillæ greatly lengthened. The stroma of the papillary growth consists of fibrous tissue. Just beneath the epithelium this may show marked infiltration and greatly dilated blood capillaries. The general appearance, both macroscopically and microscopically, is similar to that of skin papillomata in any part of the body.

#### CASES OF PAPILOMA OF THE UMBILICUS.

Papillomata of the Umbilicus[?].—Küster\* cites a case seen by Fabricius von Hilden and recorded in 1526. A man, twenty-five years of age, well nourished, had a fungating excrescence at the umbilicus which had developed in about six months. The tumor was the size of a walnut, bright red in color, and emitted an odor like that of foul cheese. At first it was painless; later there were severe pain and two hemorrhages. Fabricius considered the growth a carcinoma. On exposing the tumor he found that it consisted of three portions, each with a delicate pedicle. He ligated the pedicles and the patient was well five months later.

[This does not seem to have been carcinoma, but suggests rather a papilloma with inflammation of the umbilicus due to accumulation of foul material. Of course, at that time no histologic examination was made.—T. S. C.]

In Küster's Case 8 a man, thirty-six years of age, had had a specific ulcer on the glans penis eight months before. Six weeks prior to observation he noticed that the umbilicus was moist. In the left umbilical fold was a small tumor which grew rapidly. Astringents proved of no value. On examination, in the left side of the umbilical cavity was a pedunculated tumor the size of a phalanx of the little finger; it was movable, and discharged a foul-smelling fluid. It was covered with small red bodies (papillæ) and looked like a raspberry. When the umbilicus was split open small papillary outgrowths were found springing from it. [On histologic examination the mass was found to be a simple papilloma covered over with several layers of epithelium. In some places there were epithelial pearls.]

Papilloma of the Umbilicus.—Tillmanns,† after saying that Küster had described a papilloma of the umbilicus, mentions a case seen by Wilms.

Papilloma of the Umbilicus. ‡—In a woman, fifty-four years of

\* Küster: Die Neubildungen am Nabel Erwachsener und ihre operative Behandlung. Langenbeck's Arch. f. klin. Chir., 1874, xvi, 234.

† Tillmanns: Deutsche Zeitschr. f. Chir., 1882-83, xviii, 161.

‡ Demarquay: Bull. de la Soc. de chir., 1870-71, 2. sér., xi, 209.

age, a tumor developed from a congenital umbilical nevus. This tumor became excoriated, and there was a discharge of bloody fluid. It reached the volume of an egg, and two enlarged glands were noted in the inguinal region. The tumor and the glands were removed. Demarquay says the inguinal glands were not malignant, but that the enlargement was due to irritation from the growth. On histologic examination the growth proved to be a papilloma.

*Papilloma of the Umbilicus.\**—The patient, a concierge, forty-three years of age, a year before he entered the hospital had noticed an irritation of the umbilicus. In the umbilical depression there were small elevations the size of pinheads. They had gradually increased in size, until six months later the tumor had emerged above the level of the umbilical depression and there were excoriations. At operation the growth was the size of a franc piece, round, with a narrow base. Microscopic examination showed that it was a fibropapilloma of the umbilical cicatrix.

*Papilloma of the Umbilicus.*—Broussolle† reported a case of a child, two months old, who suffered from suppuration at the umbilicus. There was a minute umbilical tumor, reddish in color, 5 mm. in diameter. Microscopic examination showed that it was a true papilloma composed of connective tissue only slightly organized. Its surface was covered with squamous epithelium analogous to that of the skin.

*Papilloma of the Umbilicus.‡*—This case was communicated to Villar by E. Launois. M. H., aged forty-six, was operated upon by Dr. Segond for a very large fibroma of the uterus. At the umbilicus also she had a lobulated tumor, which occupied all the cavity of the umbilical depression. This tumor had first been noticed six years previously. It had increased slowly in volume, its development occurring chiefly in the appearance of small lobules. The mass was very tender on pressure and on palpation. On examination it was found to consist of a series of small elevations juxtaposed to one another. Above and below were two rounded masses. The upper one was the size of a pea, the lower one presented the form and volume of a bean. Between the two were other lobules. The surface of the two voluminous portions was covered with skin which had retained its characteristic appearance, but was wrinkled. The small granulations had a blackish-violet appearance. At first sight the growth suggested a melanotic tumor. The umbilical nodules were included in the abdominal incision when the uterine tumor was removed.

At the base of the tumor were a number of vascular orifices distended with blood. The mass, which was the size of a pea, consisted of a small cyst containing yellowish liquid.

*Histologic Examination.*—The tumor was divided into three fragments. The first contained the cyst which has been described. The walls were composed of dense connective tissue. At several points in the cyst were remnants of epithelium. The second fragment comprised all the small elevations between the two larger ones. They were composed of a series of papillæ. Each papilla was formed of dense connective tissue containing a few nuclei. The skin covering the surface presented

\* Nieaise, M.: Fibro-papillome de la cicatrice ombilicale. *Revue de chir.*, Paris, 1883, iii, 29.

† Broussolle, E.: Des végétations de l'ombilic. *Revue mens. des mal. de l'enfance*, 1886, iv, 314.

‡ Villar: Tumeurs de l'ombilic. *Thèse de Paris*, 1886, obs. 38, p. 71.

the usual characteristics. The Malpighian layer was thicker than usual, and many cells contained yellowish-brown pigment. In each of the papillæ were numerous capillary vessels anastomosing with one another. The third fragment consisted of the inferior elevation, and was much larger than the first; it was formed of dense connective tissue, and the skin covering was somewhat thinner. The entire growth was evidently a papilloma.

**Papilloma of the Umbilicus.**—Ledderhose\* says that Rizzoli had a patient, fifty-one years old, with an ulcerating papilloma at the umbilicus which was removed with zinc paste.

**Fibropapilloma of the Umbilicus.** †—M. K., a fireman, aged thirty-five, three months before admission and shortly after a blow in the umbilical region, had noticed a small tumor at the umbilicus. This had steadily increased in size, and latterly caused much inconvenience and at times a dull, throbbing pain. The umbilical cavity was completely obliterated by a prominent, firm growth the margin of which was continuous with the skin of the abdominal wall. This growth was circular, with a diameter of  $1\frac{3}{4}$  inches. Its surface presented a warty appearance, and was covered with elongated papillary growths varying in size and flattened laterally by mutual compression. The surface of the tumor was pinkish in color, intact, and free from discharge of any kind.

This prominent and warty growth was seated on and continuous with a very hard, thick growth extending all around and into the umbilicus, and forming a sub-jacent swelling about three inches in diameter. The whole mass was freely movable in all directions. When the growth was removed, the abdomen was examined and found perfectly normal.

On section the tumor was of a dull white color, and its substance, which was of almost cartilaginous hardness, was directly continuous without well-defined margins. It had extended into the surrounding fat and other tissue. The peritoneum was adherent to the tumor and drawn up into it. The entire tumor presented to the naked eye an appearance very similar to that of a recent specimen of cancer of the mamma.

On histologic examination it was found to consist of fibrous tissue fully developed. The growth was a so-called fibropapilloma.

[Smith's description is a particularly good one.—T. S. C.]

**Papillary Fibromata of the Umbilicus.**—In the literature Pernice‡ found only seven definite cases of papilloma of the umbilicus, and he added one from the Halle clinic. [These cases did not impress us very definitely as being instances of simple papilloma.] Pernice says that the outer surface of the papilloma, as well as the stroma, is similar to that found in other parts of the body. Where an ulcerated papilloma of the umbilicus exists, a lymphatic swelling of the inguinal glands may follow, but this does not necessarily indicate that carcinoma exists. Where a papilloma is not pedunculated, the diagnosis may be difficult prior to operation. The clinical course of papilloma is benign throughout. He then goes on to report the cases of Küster, Weber, Billroth, Blum, Villar, and mentions some reported by Dugès. In very few of these is it absolutely clear that a careful histologic examination was made. In a second case of Küster's the microscopic

\* Ledderhose: *Deutsche Chirurgie*, 1890, Lief. 45 b.

† Smith, J.: *The Lancet*, 1890, i, 1013.

‡ Pernice, L.: *Die Nabelgeschwülste*, Halle, 1892.

examination showed that the growth was a simple papilloma. Pernice also reports some rather indefinite cases from the clinic at Halle.

Pernice says that when his article was already in the printer's hands he had an opportunity of seeing a rare case of papilloma of the umbilicus observed in a patient coming under the care of Dr. Harttung, of Frankfort. This patient was a woman, fifty-two years old, very corpulent, and previously healthy. Four years before, the umbilicus, which was markedly funnel-shaped, had commenced to be moist. The patient was not cleanly. After some time there was a reddening in the depth with much irritation and itching, which caused the patient to rub the umbilicus. Later on a wart-like appearance was noted. The secretion was much more abundant, and the patient complained of pain.

On examination the umbilicus was found to be much drawn in, very much reddened, and there were excoriated places on the skin about the size of a mark. In the center of this eczematous area was the umbilicus. It was covered with a large number of papillary-like growths, each being about the size of half a grain of wheat. These papillomata resembled in their color and arrangement pointed condylomata. When the abdominal walls were drawn apart, a large number of smaller papillomata were seen and there was a purulent secretion.

No induration could be made out at the base of the tumor, the axillary and inguinal glands were not swollen, and there were no symptoms referable to other organs.

The diagnosis of papilloma of the umbilicus was made, and the growth removed. The tumor was about 2 cm. in height and the skin of the part was raised. From the center of the tumor sprang about 20 or 30 wart-like growths of soft consistence. These were covered with smooth epidermis, and all their ends were somewhat pointed. These papillary masses filled the entire umbilical pocket, which was 2 to 3 cm. deep. Their epidermis was not ulcerated at any point.

The microscopic picture was very simple, and corresponded identically with the picture of the soft warts—in other words, the growth was a true papilloma. Along the edge was perfectly normal skin; toward the center the epidermis became thicker, and between the papillæ of the skin the epithelial projections were irregular, sometimes longer and narrower, and at other times thick and plump. The papillary masses consisted of a connective-tissue groundwork with an epithelial covering. The epithelium was here more irregular, and sometimes sent prolongations downward. The masses were, however, simple throughout. On the surface the hornification was somewhat advanced. The connective tissue of the tumor and also of the surrounding skin showed abundant small-round-cell infiltration.

*Papilloma of the Umbilicus.*\*—R. A., aged twenty-seven, had had a swelling at the umbilicus for four months, which discharged a serosanguineous fluid. On admission a tumor, the size of a walnut, was found situated in the center of the umbilicus. At its base it had a violet tint, and at its summit was grayish-white. It was sessile, soft, and round, resembling a wart. It was very painful on palpation. It was thought to be a papillofibroma of the umbilicus, and was removed under local anesthesia.

The microscopic examination was made by Professor Cornil. The skin was very irregular and in the form of papillæ. The papillæ on the surface of the tumor were

\* Péraire, Maurice: Fibro-papillome de l'ombilie. Bull. de la Soc. anat. de Paris, 1902, lxxvii, 346.



very long, very abundant, tree-like, and formed the depression penetrating the connective tissue. They were composed of dense connective tissue supporting the blood-vessels and were covered with epithelium. Between the epithelial cells were leukocytes. The tumor was a fibropapilloma showing inflammatory reaction. Péraire remarks that this variety of tumor is rare. Villar reported only four cases—those of Küster, Blum, Nicaise, and Segond.

**Papilloma of the Umbilicus.** \*—Mrs. B. C. C., aged forty-two, a patient of Dr. W. T. Watson, was admitted to the Church Home and Infirmary October 26, 1910. During the abdominal preparation prior to removing the appendix and shortening the round ligaments, we noticed a small papillary mass at the umbilicus. It was excised.

Gyn.-Path. No. 15692. The specimen is 5 mm. broad, 4 mm. long, slightly pedunculated. Its surface is divided into three lobules, which are perfectly smooth and remind one very much of a small fibroma (Fig. 167).

**Histologic Examination.**—The greater part of the specimen imbibes hematoxylin with avidity. The surface is covered with very atrophic squamous epithelium, the superficial portion of which is hornified. The deepest layer contains yellowish and brownish pigment in places, and reminds one of the skin of a colored person, although the patient is white. Beneath the epithelium is a narrow zone of connective tissue, poor in cell elements, and beneath this again fibrous tissue, literally packed with cells containing oval or round, uniformly staining nuclei. Dividing the fibrous tissue into alveoli are minute arterioles. The central portion of the specimen is made up of fibrous tissue poor in cell elements. The picture at first suggests sarcoma. The surface epithelium is, however, everywhere intact. The nuclei of the stroma cells, although exceedingly abundant, are uniform in size and there is no evidence of nuclear figures. In addition, the clinical history shows that the patient had had this small nodule for years. It is a simple papilloma of the umbilicus.

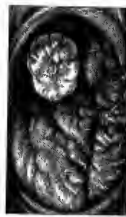


FIG. 167.—SMALL PAPILOMA IN THE UMBILICAL DEPRESSION.

The small growth was lobulated, the surface of each lobule being relatively smooth.

#### LIPOMATA OF THE UMBILICAL REGION.

In the umbilical depression there is little or no fat, consequently we should not expect to find any fatty tumors in this situation. Tillmanns,† however, points out that Wrany has drawn attention to the fact that, where there is a dilatation of the umbilical ring, some of the subperitoneal fat may escape through the hernial ring, producing an “adipose hernia” or a lipoma, which may be confused with an omental hernia.

A reference to Levadoux’s‡ masterly article on the Anatomy of the Umbilicus clearly shows just how such a hernial protrusion may occur at or near the umbilicus.

\* Cullen, Thomas S.: Personal observation.

† Tillmanns: Ueber angeborenen Prolaps von Magenschleimhaut durch den Nabelring (Ectopia ventriculi), und über sonstige Geschwülste und Fisteln des Nabels. *Deutsche Zeitschr. f. Chir.*, 1882–83, xviii, 161.

‡ Levadoux: Variétés de l’ombilic et de ses annexes. Thèse de la Fac. de méd. et de pharm. de Toulouse, 1907, No. 711.

## LITERATURE CONSULTED ON BENIGN CONNECTIVE-TISSUE GROWTHS OF THE UMBILICUS.

- Barton: Fibrolipoma of the Umbilicus. *Dublin Jour. Med. Sc.*, 1882, lxxiv, 239.
- Bennett: See Barton.
- Bryant, T.: A Fibronucleated Tumor. *Guy's Hospital Reports*, 1863, ix, 245.
- Broussolle, E.: Des végétations de l'ombilic. *Rev. mens. des mal. de l'enfance*, 1886, iv, 314.
- Coenen: Das Nabelcholesteatom. *Münch. med. Wochenschr.*, 56. Jahrg., 1909, 1583.
- Cullen; Thomas S.: Papilloma of the Umbilicus.
- Damalix: Étude sur les fibromes de la paroi abdominale antérieure. *Thèse de Paris*, 1886, No. 48.
- Demarquay: Cancer de l'ombilic. *Bull. de la Soc. de chir.*, 1870-71, 2. sér., xi, 209.
- Green, C. D.: *Trans. Path. Soc. of London*, 1899, 1, 243.
- Küster, E.: Die Neubildungen am Nabel Erwachsener und ihre operative Behandlung. *Langenbeck's Arch. f. klin. Chir.*, 1874, xvi, 234.
- Ledderhose, G.: *Deutsche Chirurgie*, 1890, Lief. 45 b.
- Legrand: Tumeur volumineuse de la région ombilicale de nature fibroplastique, prise pour une tumeur encéphaloïde (fibrome de l'ombilic). *Gaz. des hôp.*, 1850, 29.
- Mori, A.: Contributo allo studio dei tumori ombelicali. *Gazz. degli ospedali*, Milano, 1902, xxiii, 632.
- Nicaise: Fibro-papilloma de la cicatrice ombilicale. *Rev. de chir.*, Paris, 1883, iii, 29.
- Péaire, Maurice: Fibro-papillome de l'ombilic. *Bull. de la Soc. anat. de Paris*, 1902, lxxvii, 346.
- Pernice, L.: *Die Nabelgeschwülste*, Halle, 1892.
- Pic, Adrien: *Lyon méd.*, 1888, lix, 546.
- Sauer, F.: Ein Fall von Prolaps eines offenen Meckel'schen Divertikels am Nabel. *Deutsche Zeitschr. f. Chir.*, 1896-97, xlv, 316.
- Smith, J.: Fibroma of the Umbilicus. *The Lancet*, 1890, i, 1013.
- Sourdille, G.: Sarcome pédiculé de la peau de l'ombilic. *Bull. de la Soc. anat. de Paris*, 1895, lxx, 302.
- Tillmanns: *Deutsche Zeitschr. f. Chir.*, 1882-83, xviii, 161.
- Villar, F.: *Tumeurs de l'ombilic*. *Thèse de Paris*, 1886, No. 19.

## DERMOIDS OR ATHEROMATOUS CYSTS OF THE UMBILICUS.\*

Judging from the number of cases reported one would infer that dermoids at the umbilicus are by no means rare. Nevertheless, on carefully following the clinical histories and checking up the pathologic findings, one finds that in nearly all the cases the supposed dermoid cyst was nothing more than an umbilical concretion, in the majority of the cases associated with suppuration, and that the diagnosis of dermoid cyst has erroneously been made owing to the presence of the sebaceous material and hairs in the discharge from the infected umbilicus. Villar, in 1886, pointed out this erroneous conception, and several others have also mentioned it.

After carefully analyzing the cases of supposed dermoids or atheromata of the umbilicus that are available in the literature, I have found among them only six that were true umbilical dermoid cysts. These were reported by Küster, Lotzbeck, Morestin, Lannelongue and Frémont, Hue and Guelliot. These atheromatous tumors were all noted in young patients. In three they were found at birth, in one after the cord came away, and in the remaining two they had been present since childhood.

A dermoid cyst may spring from the umbilical cicatrix or from the side of the umbilicus. It may reach the size of a walnut and tend to become pedunculated.

\* In this connection we used the words dermoid and atheromatous as synonymous terms.

It may be tense or occur as a flaccid sac. It contains sebaceous material, which, on histologic examination, yields epithelium, fat-droplets, and frequently cholesterin crystals. The cyst-walls examined histologically have shown an inner lining of squamous epithelium devoid of hairs or glands of any sort, and in none of the cases have hairs been detected in the cyst contents.

The skin covering these cysts is, as a rule, unaltered. In Morestin's case, however, as a result of the rubbing of the clothing, it had become reddened at one point and slight suppuration had occurred, followed by discharge of the characteristic cyst contents.

#### DETAILED REPORT OF CASES OF DERMOID OR ATHEROMATOUS CYSTS OF THE UMBILICUS.

**Dermoid Cyst at the Umbilicus.\***—Case 7.—In July, 1872, Küster saw a woman, twenty-one years old, who had a tumor at the umbilicus. This had been noted since birth. It was round, soft, and attached to the umbilicus by a pedicle. It sprang from the left of the umbilical depression, and was easily shelled out. It had thin walls, and the sac was filled with atheromatous material, fat, epithelial cells, and cholesterin crystals. No microscopic examination was made of the nodule. It was probably, as Küster thought, a dermoid.

**A Pedunculated Sebaceous Cyst of the Umbilicus.†**—A man, twenty-seven years of age, entered the service of Péan. At birth he had had at the umbilicus a tumor the size of a hazelnut. Within five or six weeks before he entered, as the result of pressure produced by a belt, it had increased to four times its original size; it had become red at its prominent part, slightly ulcerated, and a whitish, thick, granular, or clotted material had escaped from it. On examination the tumor was found to be the size and shape of a small fig, and was attached to the umbilical cicatrix. It was lax, a little wrinkled, and gave the sensation of a half-empty pouch. It was not painful on pressure.

The skin covering it was thin. The patient refused operation. A congenital sebaceous cyst was diagnosed.

**Cyst of the Umbilicus, Possibly a Dermoid.**—Ledderhose,‡ after saying that the literature on the subject is scanty, refers to a case reported by Lotzbeck, in which Bruns removed a multilocular tumor the size of a fist from a child two and one-half years old. This had been noticed immediately after birth, and was then the size of a walnut. It contained fluid which was partly clear amber yellow, somewhat alkaline, and partly thick, honey-brown, and gelatinous. The tumor lay between the skin and the rectus. The connective-tissue wall of the cyst contained small, thread-like, cartilaginous deposits, and was lined with a simple squamous epithelium. The contents were fat, cholesterin, and numerous cells.

**A Congenital Dermoid Cyst.§**—A child, nine years old, presented in the middle of the umbilicus a hemispheric protuberance the size of half

\* Küster: Die Neubildungen am Nabel Erwachsener und ihre operative Behandlung. Langenbeck's Arch. f. klin. Chir., 1874, xvi, 234.

† Guelliot: Observation de kyste sébacé pédiculé de l'ombilic. Revue de chir., 1883, iii, 193.

‡ Ledderhose: Deutsche Chirurgie, 1890, Lief. 45 b.

§ Lannelongue et Frémont: De quelques variétés de tumeurs congénitales de l'ombilic et plus spécialement des tumeurs adénoïdes diverticulaires. Arch. gén. de méd., 1884, 7. sér., xiii, 36.

a walnut. The skin had not changed color. The central portion of the tumor was soft and fluctuating. It was circumscribed, but in the deeper portion adherent. It was not enlarged by crying, was irreducible, and was found to be a cyst. It had been noted immediately after the cord came away, and had enlarged rapidly during the first five or six months of life. At operation it was found to contain sebaceous material.

**A Dermoid Cyst at the Umbilicus.**—Hue\* noted a dermoid cyst of the umbilicus as large as a pigeon's egg. It had been taken for an umbilical hernia. The patient, a girl of nineteen, had carried it from childhood, and had only suffered from some slight inconvenience. The umbilical depression had been replaced by this round tumor. The skin covering it was normal, but the tumor was attached to the umbilical cicatrix by a flattened pedicle. It was soft, painless, and irreducible, but was easily removed. At the meeting of the Medical Society Hue showed photographs of the case. I wrote asking Dr. Hue if he could send me a photograph of the tumor. He replied saying that the photographs had been mislaid, but as soon as he found them he would gladly send me one, but thus far I have not received a second communication from him.

Dévé found it to be a cyst covered over with normal skin, and containing a whitish, creamy material without any development of hair. The cyst-wall was scarcely 1 mm. thick, composed of fibrous tissue, and lined with squamous epithelium without hair or glands of any sort. Hue thought it had originated from a nipping-off of a fragment of skin in the umbilical cicatrix following the dropping-off of the cord.

**A Dermoid Cyst of the Umbilicus.** †—The patient was a male, nineteen years old. Since childhood he had had a small round tumor attached to the umbilicus. A few days before Morestin saw him it had become tender, more prominent, and pink or reddish in color. It had occasioned some suffering. On the night after admission a whitish material was seen escaping from a small opening at the point where the redness had developed.

On examination the nodule was found to be the size of a walnut, whitish red, and occupying the center of the umbilical region. It was attached by a pedicle to the center of the umbilicus. The surrounding skin was normal. The growth was removed under local anesthesia, but the peritoneal cavity was not opened. The cyst contained some greasy whitish material. There were no hairs. Mallet made slides and found an epithelial lining, but no hairs and no glands. He felt sure that the tumor was a dermoid cyst.

**A Possible Dermoid of the Umbilicus.**—In this case of Villar's it is impossible to determine accurately whether or not the cyst was in reality atheromatous in character. It did not seem to be in any way associated with an inflammation of the umbilicus.

Villar‡ reports a case of dermoid cyst occurring in the service of Professor Verneuil. M. O., a Russian officer twenty-seven years old, was seen in consultation June, 1886, for a small tumor of the umbilicus situated exactly in the left of the umbilicus and passing off from the umbilical depression. The tumor

\* Hue, F.: Kyste dermoïde de l'ombilic. *La Normandie médicale*, 1909, xxiv, 28.

† Morestin, H.: Kyste dermoïde de l'ombilic. *Bull. de la Soc. anat. de Paris*, 1909, année 84, 742.

‡ Villar: Tumeurs de l'ombilic. *Thèse de Paris*, 1886, 66.

was the size of a walnut and semifluctuant. On pressure it did not change in volume. It had been present for a little more than two years and had not increased in size until a short while before. On pressure it was painful. The diagnosis lay between a small umbilical hernia, a cyst, and a lipoma. The tumor was opened with a bistoury and there escaped a clear liquid; a cystic sac remained. The histologic examination was made by Clado. The tumor was as big as a large walnut, was whitish blue, and fibrous in character. The inner surface presented a granular appearance and had a caseous-like covering; the contents were liquid and seropurulent. Microscopic examination showed white blood-corpuscles in large numbers and also some red blood-corpuscles, numerous very attenuated hairs, and small cholesterin crystals. Cultures from the liquid yielded a diplococcus. Examination of the cyst-wall was difficult. In the wall there were neither glandular elements nor hair-follicles. [The origin of this cyst does not seem to be perfectly clear.]

#### LITERATURE CONSULTED ON DERMOID CYSTS OF THE UMBILICUS.

(See also the literature on Umbilical Concretions, p. 260.)

- Bondi, J.: Zur Kasuistik der Nabeleysten. Monatschr. f. Geb. u. Gyn., 1905, xxi, 729. (From Schauta's clinic.)
- Guelliot: Observation de kyste sébacé pédiculé de l'ombilic. Revue de chir., 1883, iii, 193.
- Hue, F.: Kyste dermoïde de l'ombilic. La Normandie médicale, 1909, xxiv, 28.
- Küster, E.: Die Neubildungen am Nabel Erwachsener und ihre operative Behandlung. Langenbeck's Arch. f. klin. Chir., 1874, xvi, 234.
- Lannelongue et Frémont: De quelques variétés de tumeurs congénitales de l'ombilic et plus spécialement des tumeurs adénoïdes diverticulaires. Arch. gén. de méd., 1884, 7. sér., xiii, 36.
- Ledderhose, G.: Deutsche Chirurgie, 1890, Lief. 45 b.
- Morestin, H.: Kyste dermoïde de l'ombilic. Bull. de la Soc. anat. de Paris, 1909, année 84, 742.
- Pernice, L.: Die Nabelgeschwülste, Halle, 1892.
- Villar, F.: Tumeurs de l'ombilic. Thèse de Paris, 1886.

#### UMBILICAL TUMORS CONSISTING CHIEFLY OF SWEAT-GLANDS.

Three cases have been recorded in which the tumor was supposed to have originated in whole or in part from sweat-glands. These were reported by Wullstein, von Noorden, and Ehrlich.

In Wullstein's and also in von Noorden's case there is some doubt, and from the histories it seems to me that the growths probably originated from Müller's duct or from uterine mucosa. This point the reader can decide for himself, as they are reported in full on p. 384 and p. 387.

In Ehrlich's case part of the growth consisted of sweat-glands, the remaining portion of uterine glands. The sweat-glands were gathered into definite colonies. Each colony was embedded in a stroma, which was sharply differentiated from the surrounding stroma, although essentially similar in character to it. The epithelium lining the glands was of the characteristic low cuboid variety. Some of the glands were dilated (Fig. 176, p. 383).

On page 398 I have referred to a small aggregation of sweat-glands occurring in an adenomyoma of the umbilicus that came under my personal observation.

Fig. 183, p. 398, from this case reminds one somewhat of the gland grouping found in fibromata of the breast. Although, as a rule, there are no sweat-glands in the umbilicus, nevertheless, the normal skin is so close to it that a tumor consist-

ing of sweat-glands might so encroach upon the umbilicus that it could not be distinguished from one growing in the umbilical depression.

In the specimen recently sent me by Dr. Edward G. Jones of Atlanta I found sweat-glands and glands resembling those of the body of the uterus. Part of the small umbilical tumor, which was three-quarters of an inch in diameter, undoubtedly consisted of sweat-glands.

#### LITERATURE CONSULTED ON UMBILICAL TUMORS CONTAINING SWEAT-GLANDS.

Wullstein, L.: Arbeiten aus dem Path. Inst. in Göttingen, R. Virchow, zum 50. Doctor-Jubiläum, 1893, 245.

Von Noorden: Deutsche Zeitschr. f. Chir., 1901, lix, 215.

Ehrlich: Arch. f. klin. Chir., 1909, lxxxix, 742.

#### AN ABDOMINAL TUMOR ATTACHED TO THE INNER SURFACE OF THE UMBILICUS BY A PEDICLE TWO INCHES IN DIAMETER.

From the description of this case one gathers the impression that the tumor was a myoma. It may have been a myoma that had engrafted itself upon the umbilicus. A few details in the description point to the possibility that the growth was an adenomyoma ("ferous matter"). We know that a small adenomyoma with glands identical with those of the uterine mucosa may be found at the umbilicus. In the cases recorded the growths have been on the outer or skin surface of the umbilicus, but there seems to be no adequate reason why they might not just as well project from the inner or peritoneal side of the umbilicus, producing, as in this case, an abdominal tumor with its pedicle attached to the umbilicus. In the umbilical adenomyomata reported, however, the tumors have always been of small size.

A Hydrops Ascites From a Tumor Depending from the Navel Internally.\*—A multipara, about forty-three years of age, was thought to be pregnant. After going a year she had labor-like pains for eighteen hours. Her periods returned and continued to be regular for eight or nine months. There was then one flooding, after which no further periods were noted. She complained of fulness in the abdomen. Six years later she was tapped, large quantities of fluid being removed from time to time.

The patient finally died. A large carnosous excrescence was found depending from the umbilicus by a pedicle two inches in diameter. The tumor was adherent to several parts of the peritoneum, but these adhesions were easily separated with the hand. No vessels were seen except those in the pedicle of the tumor. The tumor appeared to be composed of cells communicating with each other. Some contained "ferous matter," others were full of a substance of the consistence of "marrow." From these cells tubes as large as goose-quills and full of the same material passed out into the umbilicus, being contained in a thick, muscular substance of which the neck of the tumor was principally composed. The entire tumor weighed eight pounds. Nothing widely deviating from the ordinary structures was noted in the abdominal viscera.

[At this time no careful histologic examinations were made. The muscular character of the tumor, coupled with the appearance of "ferous matter" and

\* Johnston, William: Medical Essays and Observations, Edinburgh, 1744, v, part ii, 640.

of spaces as broad as goose-quills filled with the same material, strongly suggests to us the possibility of an adenomyoma. Of course, this is merely surmise. The presence of ascites with a parasitic myoma is not of rare occurrence.—T. S. C.]

#### PAPILLOMA OF THE UMBILICUS SECONDARY TO PAPILLOMA OF THE OVARY.

This is the only case of this character of which we have any record. As will be noted from the history, papilloma of the ovary and secondary abdominal nodules were found at operation in 1898. The patient was seen from time to time, and about six and a half years later a small, partially ulcerated, umbilical nodule was removed. On histologic examination the superficial portions of the nodule showed some inflammatory reaction. The remaining portions were composed of papillary masses covered over with cylindric epithelium and conforming exactly in appearance to the histologic picture of papilloma of the ovary, but differing totally from a primary papilloma of the umbilicus. The relatively benign character of the growth is evident, as the patient was in fair condition over six years after partial removal of the papillary masses from the abdomen.

*Papilloma of the Umbilicus Secondary to Papilloma of the Right Ovary.*—Gyn. No. 6112. F. M., a woman, was admitted to the Johns Hopkins Hospital on May 18, 1898. An exploratory laparotomy was made, and a large sac was removed, together with papillary masses from the peritoneum.

Path. No. 2377. The growth proved to be papillary in origin and came from the right ovary.

Gyn. No. 6523. November 18, 1898: Two liters of ascitic fluid were removed.

November 13, 1899: The abdomen was opened for papillomata of the ovary involving the peritoneum, and also for post-operative ventral hernia.

Gyn. No. 8284. November 7, 1900: An exploratory operation was performed, and 14 liters of ascitic fluid were evacuated. There was a papilloma of the right ovary the size of a child's head and also papillary growths in the parietal peritoneum. In the pelvis was a subperitoneal cystic growth surrounding the rectum on both sides. It did not seem to be made up of papillary masses, but appeared to be due to an effusion of serous fluid beneath the peritoneum. The parietal peritoneum was roughened and reddened.

Gyn. No. 8575. March 13, 1901: Ascitic fluid was removed.

March 20, 1901: The fistulous opening in the abdominal wall was excised.

March 19, 1905: A small umbilical nodule was removed by Dr. Hunner.

Path. No. 8417. The superficial portion consists of granulation tissue. The surface is covered with hyaline material embedded in which are a large number of polymorphonuclear leukocytes; beneath this is canalized fibrin, also containing polymorphonuclear leukocytes, and in the depth are dilated capillaries surrounded by young connective-tissue cells. The central portions are well organized. The more protected parts consist of typical papillary masses, large and small. They are covered over with one layer of cylindric ciliated epithelium. The epithelium varies considerably; in some places it is exceedingly high, and in others cuboid. The nuclei may be oval and uniformly staining, or oval and vesicular. The tumor presents the typical picture of papilloma of the ovary, although found at the umbilicus. Some of the papillary masses are well organized. In places the stroma has

been replaced by hyaline tissue. In short, we have at the umbilicus a papilloma identical with an ovarian papilloma. On account of irritation from the clothing, the superficial portion has become inflamed and is partly replaced by granulation tissue. It is remarkable that the woman has lived so long, particularly with such wide-spread papillary masses. Some of these patients, however, live for a great many years. In 1894 I\* reported a case of double papilocystomata of both ovaries. Fifteen years later I heard from the same patient. She was well and had gained 49 pounds.

\* Cullen, Thomas S.: Johns Hopkins Hosp. Bull., November, 1894, No. 43, 103.



## CHAPTER XXIV.

### ADENOMYOMA OF THE UMBILICUS.

Historic sketch.  
Report of cases.  
Personal observations.

#### UMBILICAL TUMORS CONTAINING UTERINE MUCOSA OR REMNANTS OF MÜLLER'S DUCTS.\*

WHILE gathering together from the literature the numerous cases of primary tumor of the umbilicus I found several that did not seem to belong to any of the classes hitherto recognized, and yet all of these cases in one or more points bear a certain amount of resemblance to one another. Finally, the picture of this new group became so firmly fixed in my mind that when reading the description of a case recorded in 1899 by Dr. Green, of Romford, England, I felt so sure that his case came under this category that I wrote him, asking if perchance he still had a section of the tumor. An examination of the slide which he kindly furnished me showed that we were right in our surmise. In brief, the clinical histories in this class of cases, coupled with the gross appearances of the tumors, leave no doubt that we are dealing with a variety of umbilical tumor never before clearly understood.

The composite picture of such tumors—which were found only in women—is as follows: At some time between the thirtieth and fifty-fifth year a small tumor develops at the umbilicus, reaching its full size in the course of a few months. It is usually described as being the size of a small nut. Sometimes it is painful, especially at the menstrual period, and in at least one instance there was a brownish, bloody discharge from the umbilicus at such times.

The overlying skin is usually pigmented, and there may be one or two bluish or brownish cysts just beneath the skin. These may rupture and discharge a little brownish fluid—old blood. On section the nodule is found to be intimately attached to the skin, is very dense, and is traversed by glistening bands of fibrous tissue. Scattered throughout the nodule one sometimes finds small spaces presenting a sieve-like appearance. These spaces are filled with brownish fluid. Occasionally there may be a small cyst, several millimeters in diameter, filled with

\* Shortly after the appearance, in *Surgery, Gynecology and Obstetrics* (May, 1912, 479), of my article on Umbilical Tumors Containing Uterine Mucosa or Remnants of Müller's Duct, I received the following, in a letter from Dr. S. W. Goddard, of Brockton, Mass., dated September 10, 1912: "After reading your recent article in *Surgery, Gynecology and Obstetrics* on Umbilical Tumors and noting a similarity to two I have published, I am sending you a reprint of the same in hopes that they may be of interest to you, and, if of any value, would be glad to have you make use of them in connection with your work, as I infer that you are specially interested in the subject. I have not seen any similar cases since."

These two cases reported by Dr. Goddard belong to the same group as those I have collected. That he clearly recognized the source of origin of these glands is also evident from the title of his article: *Two Umbilical Tumors of Probable Uterine Origin*. I had overlooked Dr. Goddard's article completely. To him undoubtedly belongs the credit for having drawn attention to the probable origin of the glands in these cases. Dr. Goddard's cases, one recently recorded by Barker, and one examined by me for Dr. Jones, of Atlanta, are recorded at the end of the chapter.

brownish contents. Exceptionally, grayish, somewhat homogeneous areas are distinguishable in the tumor.

On histologic examination the superficial squamous epithelium is usually found intact. It may be normal or thickened. The stroma of the growth is composed of dense fibrous tissue. Sometimes a few bundles of non-stripped muscle are noted here and there in the fibrous stroma. In other specimens the non-stripped muscle is much more abundant than the fibrous tissue.

Scattered throughout the field are glands, round, oval, or irregular. They occur singly or in groups, and are lined with cylindric epithelium. When occurring singly, they frequently lie in direct contact with the fibrous tissue, but when found in groups, are usually surrounded by a characteristic stroma that stains more deeply and is much more cellular than the surrounding fibrous tissue. The cells of this stroma between the glands usually have oval or round vesicular nuclei. Frequently some of the glands are dilated and their epithelium is somewhat flattened. The cyst spaces, noted macroscopically and filled with brownish fluid, are likewise dilated glands, and the fluid is old blood. The stroma around the glands frequently shows fresh hemorrhage or remnants of old blood, to be recognized by the deposit of blood pigment.

From the above description it is clearly seen that the gland picture is that of the uterine mucosa with its typical glands and its characteristic stroma, and further that the typical menstrual reaction is often present, as evidenced by the pain in the nodule at the periods, the accumulation of old menstrual blood with the formation of small cysts, and in at least one instance by the occasional discharge of blood from the umbilicus. In this case (Fig. 168) one or two of the glands opened directly on the surface, thus allowing free escape of the menstrual blood.

In all, nine cases have been recorded. Green's case (Fig. 168), Mintz's first and third cases (Figs. 171 and 174), and Ehrlich's case (Fig. 177) owe their glandular origin without doubt to the uterus or to a portion of Müller's duct from which the uterine mucosa originally comes. Although the cases reported by Wullstein, Giannettasio, von Noorden, and Mintz (Case 2) also probably belong to the same group, the evidence is not quite so clear, and without the opportunity of carefully studying the original sections I should not feel justified in including them as certain instances.

The most common glandular elements at the umbilicus are remnants of the omphalomesenteric duct. These are usually identical in structure with the glands of the small intestine, and never give rise to the cystic dilatations noted in the group of cases under discussion; moreover, hemorrhage into the stroma is exceptional. They differ totally both in their gross and histologic appearances.

We have in this group of cases glandular elements that from their histologic appearance and arrangement correspond exactly with those found in adenomyoma of the uterus, and in one case at least (Green's) the surrounding stroma was composed chiefly of non-stripped muscle, making the growth essentially an adenomyoma. In the majority of the cases, however, the stroma consisted of fibrous tissue, but little muscle being present.

These growths are benign, and if removed *in toto*, provided no other embryonic foci exist, give rise to no further trouble. In Mintz's first case, four years after the first nodule had been removed, two others developed. These were also extirpated.

In Ehrlich's case, in addition to typical uterine mucosa, there was a definite tumor formation that had originated from sweat-glands.

In order that the reader may gain a clear insight into each of the cases, they are reported in detail, together with the comments on each case.

The descriptions of the illustrations naturally differ from those given by the various authors. I have redescribed each picture in the light of our new knowledge of the subject.

A Small Umbilical Tumor Containing Uterine Glands.\* — [The author very kindly placed a section of the growth at my disposal. There is no doubt that the gland elements in this case are identical with those of the uterine mucosa, as seen from Figs. 168, 169, and 170, which have recently been made.—T. S. C.]

The patient, a woman fifty years of age, had complained of irritation about the umbilicus for about two and a half years, and there had been an occasional discharge, brownish in color. When Dr. Green saw her, fourteen months before the growth was removed, there was some eczematous irritation of the skin in the neighborhood, but no projecting growth could be observed at that time. The bottom of the umbilical depression had an irregular, wart-like appearance. The surrounding eczema soon yielded to treatment, but there was from time to time an irritating discharge from the umbilicus, which the patient declared was always worse during her menstrual periods.

The umbilicus with the growth and a portion of the surrounding skin was removed. The omentum was not adherent to the umbilicus, and no intestine was seen at operation. The wound healed by first intention and there was no subsequent trouble, so far as could be learned.

On microscopic examination the skin was found to be normal. The stroma of the growth was made up of fibrous tissue and non-stripped muscle, scattered among which, without any definite arrangement, were numerous gland elements. Some of these were very near the free surface, others more deeply placed. They were for the most part tubular and lined with columnar epithelium showing large, deeply staining nuclei. They were thought to be reproductions of Lieberkühn's crypts, but differed from them in their exaggerated dimensions. Some of them were so large that they might almost have been described as cysts. [Dr. Green thought that the growth was a remnant of the vitello-intestinal tract.]

On reading this history I noted that there had been some discharge of blood from the umbilicus, as indicated by the brownish color, and, furthermore, that the patient had always been worse at the menstrual periods. This made me suspect the possible presence of uterine glands at the umbilicus. I wrote Dr. Green and early in July received the following reply:

THE FERNS, ROMFORD, ENGLAND, June 22, 1911.

*Dear Sir:* In reply to your query about my case of umbilical growth, I am pleased to be able to send you a section from the same, so that you may form your own judgment as to its histology. I did not think it was malignant. I last heard of the patient two and a half years after the operation. She was then alive and well. This, I think, shows that the growth was not secondary to an undiagnosed growth within the abdomen. Owing to removal, I have not subsequently heard of her, so I cannot say what ultimately happened to her. I inclose a copy of my paper which I happened to have kept.

Yours faithfully,

CHARLES D. GREEN.

\* Green, Charles D.: A Case of Umbilical Papilloma Which Showed Some Activity of Growth in a Patient Fifty Years of Age and Which was Due Apparently to Inclusion of a Portion of Meckel's Diverticulum. *Trans. Path. Soc. London*, 1899, 1, 243.

We were particularly fortunate in obtaining this specimen from Dr. Green, in the first place, because it was twelve years since the case had been reported, and,

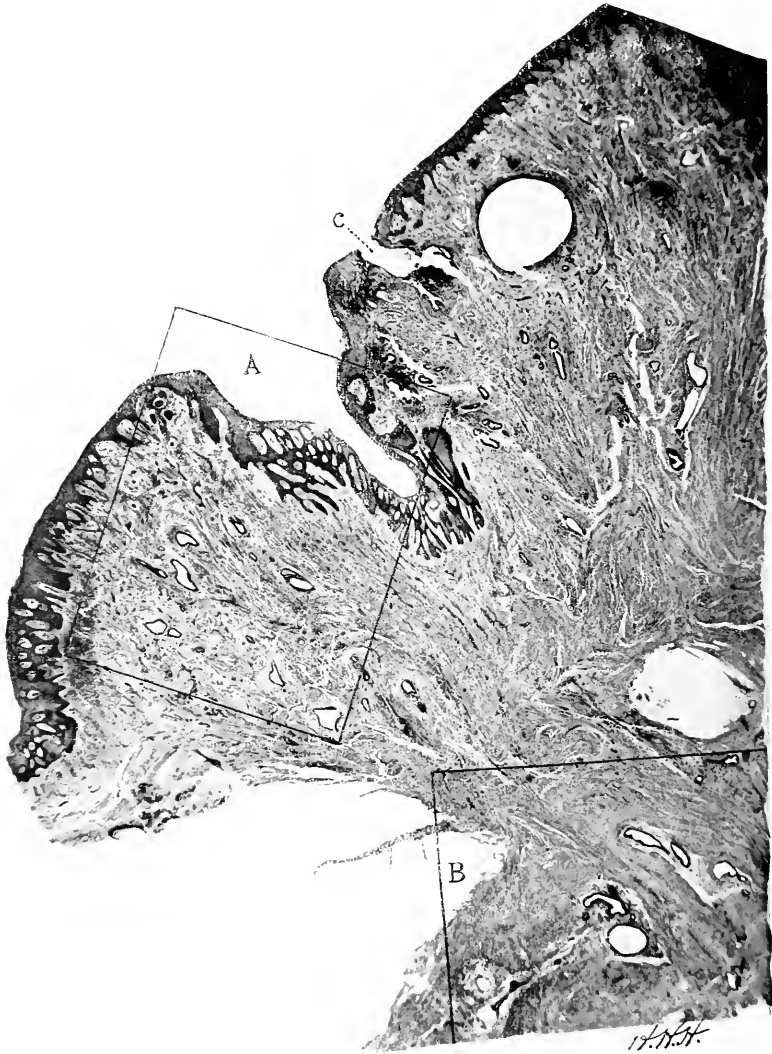


FIG. 168.—A SMALL UMBILICAL TUMOR CONTAINING GLANDS AND STROMA IDENTICAL WITH THOSE OF THE UTERINE MUCOSA.

The slide was kindly furnished me by Dr. Charles D. Green, of Romford, England, and is from the umbilical growth reported by him in the Transactions of the Pathological Society of London, 1899. The squamous epithelium is intact, and apart from some thickening appears normal. Scattered throughout the underlying stroma are oval, round, or irregular glands occurring singly or in groups; there are also a few cystic spaces. Some of the glands lie directly beneath the skin. At *c* two of the glands open directly upon the surface of the umbilicus. Area A has been enlarged and is shown in Fig. 169. The increased magnification of area B is seen in Fig. 170. The photomicrographs of this series were made by Mr. H. H. Hart.

in the second place, because it is one of the most valuable cases of this character thus far on record.

Dr. Green's specimen, No. 125.—The skin surface is intact and practically normal, although at a few points the epithelium is considerably thickened. In

one or two places directly beneath the skin there is small-round-cell infiltration, chiefly in foci. At one point the surface epithelium extends a short distance into a cavity (Fig. 168, *c*). In the lower portion of the cavity the lining consists of cylindric epithelium, one layer in thickness. Around this area the stroma shows a considerable amount of hemorrhage. It is from this point that there was undoubtedly bleeding at the menstrual periods. The underlying stroma consists to a large extent of non-striped muscle. Scattered here and there throughout the muscle

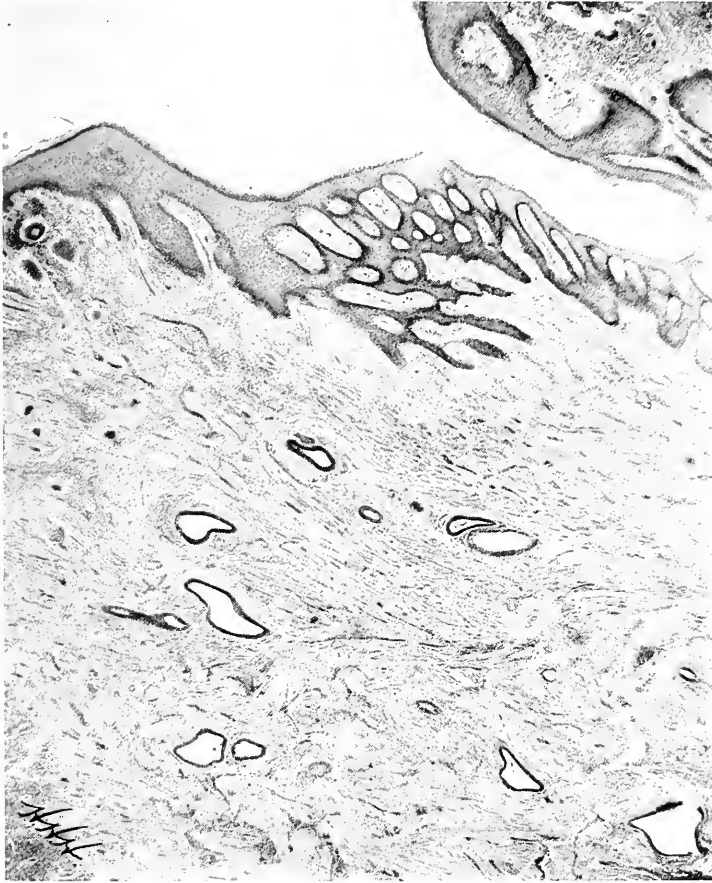

FIG. 169.—GLANDS FROM A SMALL UMBILICAL TUMOR.

The picture is an enlargement of the area *A* in Fig. 168. The normal character of the surface epithelium is clearly seen. The gland spaces vary considerably in size and shape and are lined with cylindric epithelium. Those in the picture lie in direct contact with the dense surrounding stroma.

are glands. They are small, round, oblong, irregular, or large (Fig. 169). A few of them occur singly and lie in direct contact with the surrounding stroma. The majority, however, occur in groups or in chains, and are separated from the surrounding stroma by a definite stroma of their own (Fig. 170), which is recognized by its deeper stain and its abundance of vesicular nuclei, which are oval or round. Some of the glands are very much dilated. Where such dilatations have taken place the surrounding stroma frequently shows a good deal of hemorrhage.

Were it not for the presence of the skin surface one would immediately diagnose the specimen as an adenomyoma of the uterus. The picture is typical, as seen from Figs. 168, 169, and 170. The growth is an adenomyoma of the umbilicus. Dr. Green at the time felt sure that the condition was a rare one, as indicated from a second communication dated August 4, 1911:

*Dear Dr. Cullen:* . . . . I am glad you found my specimen so interesting. I had some photographs prepared, but the Committee of the Pathological Society did not think them of sufficient interest to insert them in the Transactions. I was a little disappointed at the time, for I thought that the condition was uncommon.

Yours faithfully,

CHARLES D. GREEN.

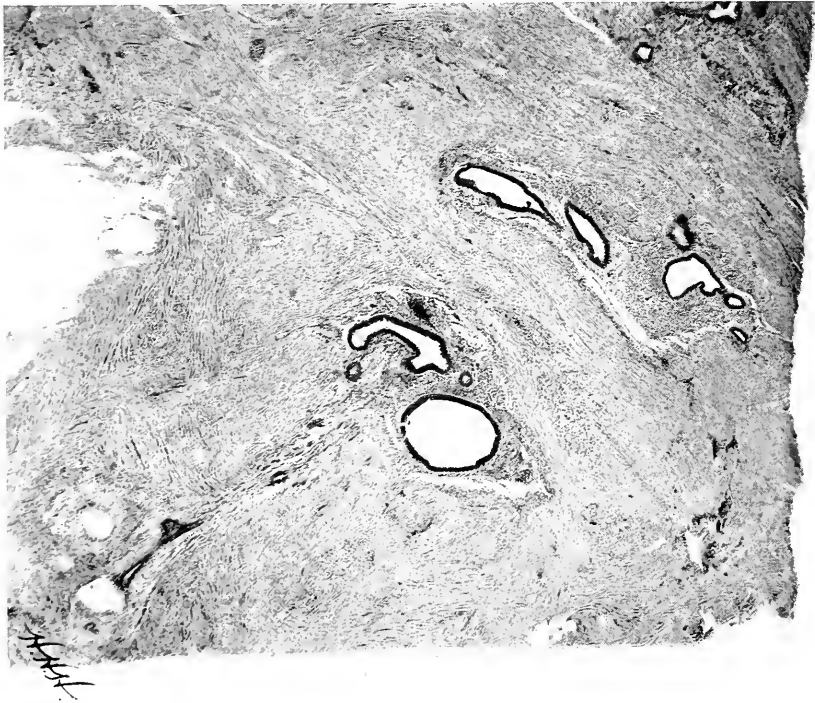


FIG. 170.—TYPICAL UTERINE MUCOSA IN A SMALL UMBILICAL TUMOR. AN ENLARGEMENT OF AREA B IN FIG. 168.

The three large glands in the right-hand part of the picture, in shape and arrangement, resemble those found in an adenomyoma of the uterus: separating them from the dense tumor growth is a definite and characteristic stroma. The group of glands in the middle of the picture is even more characteristic, one of the glands being dilated. All are lined with cylindric epithelium, and the contrast between the surrounding stroma and the dense growth is very clearly marked. As noted in the description, non-striped muscle was found scattered throughout the nodule.

[On looking up the Transactions, I found that two of the committee diagnosed the growth as a columnar-cell carcinoma, but whether primary or secondary they were unable to decide. The chairman of the committee said some of the members present who examined the specimen were not inclined to regard it as malignant. There is little wonder that at that time confusion existed, and had it not been for the specially favorable opportunity I had had of examining so many cases of adenomyoma, I should have undoubtedly overlooked the true origin.—T. S. C.]

Adenomyoma of the Umbilicus.\*—Case 1.—In 1883 a woman acquired an umbilical hernia after labor. Ten years later, within the space of about two months, a dark-blue tumor the size of a hazelnut developed on the umbilical elevation. This had two cystic areas on its surface. During menstruation the tumor swelled and the cysts ruptured. They contained blood-tinged fluid. The tumor was extirpated and the hernia repaired. This tumor on section presented a cavernous appearance, but no microscopic examination was made. In 1897, four years later, there was a return of the hernia, and at the umbilicus were two hard nodules about the size of hazelnuts. On microscopic examination they were found to contain glands lined with cylindric epithelium and surrounded by a definite stroma. Here and there bundles of non-stripped muscle were in evidence. The dilated glands contained blood-pigment. Mintz thought he was dealing with remains of the omphalomesenteric duct.

[When discussing this case some three years ago, just after making the abstract, I made the following note: "The clinical history, the macroscopic appearance, the picture of the glands, the stroma, and the contents of the dilated glands all point to adenomyoma, although adenomyoma of the umbilicus has never been reported."—T. S. C.]

We are fortunate in again hearing from Mintz on this subject. Ten years later he published an article entitled "Das Nabeladenom," *Arch. f. klin. Chir.*, 1909, lxxxix, 385. Here he describes, more in detail, the histologic findings of the same case. He says:

"The ground substance of the growth consists of connective tissue not very rich in cells. They cross one another or run parallel with one another in cords. Here and there in the scar tissue one sees gland tubules in either transverse or longitudinal section. They are surrounded by young, very cellular connective tissue, which passes very gradually into the old scar tissue. The glands are lined with one layer of cylindric epithelium. Their lumina are collapsed and contain blood pigment or reddish-colored contents (Fig. 171). In some places the tubules lie close, at other points they are separated. The newly formed connective tissue surrounding them has changed into old connective tissue poor in cell nuclei. Some of the glands are dilated and their epithelium is flattened. The lumina appear to be filled with detritus. Here and there the cylindric epithelium is unrecognizable and the cavity contains blood-pigment (Fig. 172). Where the dilatation has occurred, the epithelium has disappeared; in this way are to be explained the cysts with blood contents which were noted when the patient first entered the hospital. Between the glandular portion of the tumor there are at some points groups of non-stripped

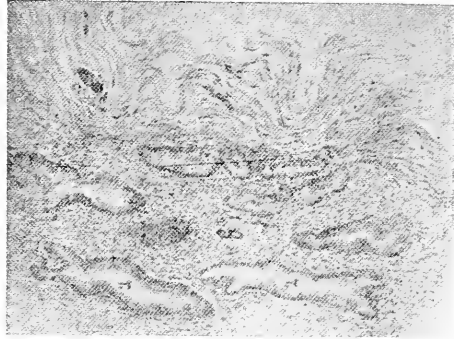


FIG. 171.—GLANDS IN A SMALL UMBILICAL TUMOR. (Mintz, Case 1.)

The outlying connective-tissue stroma is very irregular. Occupying the lower half of the field are glands showing some branching. They are lined with one layer of cylindric epithelium and lie in a characteristic stroma which separates them from the fibrous tissue of the tumor. The entire picture reminds one to a large extent of adenomyoma of the uterus.

\* Mintz, W.: Das wahre Adenom des Nabels. *Deutsche Zeitschr. f. Chir.*, 1899, li, 545.

muscle-fibers that have no definite topographic arrangement in relation with the glands. The microscopic examination shows an adenomatous growth in the scar tissue. This has stimulated the growth of the scar tissue, and thus originated the young connective tissue surrounding the new glands. In the mean time the periphery of the nodule in the scar has been converted into sarcoma."

[After giving this description he says in a foot-note that at the time of writing (that is, ten years later) the tumor had not returned. The explanation of the origin of this tumor he gives as persistent remains of the omphalomesenteric duct which had remained latent for forty-two years in the umbilical scar, and under the influence of chronic injury (a ten-year persistent umbilical hernia) had given rise to adenoma.

It can hardly be doubted that we are dealing with an adenomyoma, although such a case had heretofore never been described. We have the increase in size at the menstrual period, the cysts with blood contents, glands resembling uterine glands, the characteristic stroma of the mucosa surrounding the glands, that was

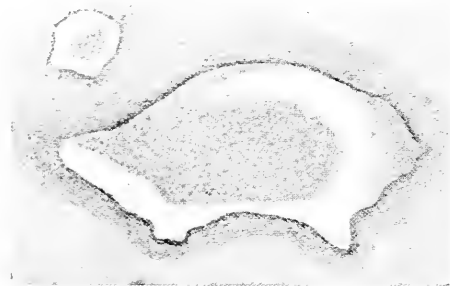


FIG. 172.—DILATED GLANDS IN A SMALL UMBILICAL TUMOR. (Mintz, Case 1.)

In the center of the field is a very much dilated gland. Its epithelium is flattened. The gland itself is separated from the surrounding stroma by a definite, dark-staining zone. As noted in the history, the dilated gland cavities in the tumor contained exfoliated epithelium, granular material, and in some instances blood.

thought by Mintz to be sarcomatous, and the fact that, after the second operation, the patient remained absolutely well for ten years. How these glands originated at the umbilicus we do not attempt to explain. We have, however, found them in the inguinal region, and I feel confident that, in the course of time, somebody will get a clear chain of evidence showing how remnants of the uterus can reach the umbilicus.—T. S. C.]

A Small Umbilical Tumor Containing Uterine Glands. — Case 2 (Mintz).—The woman was thirty-eight years of age. Eleven months before, a myomatous uterus had been removed through an abdominal incision.

Eight months later she noticed at the umbilicus a tumor which increased in size for three months and then stopped growing. During menstruation there was pain in the tumor. From the umbilicus to the symphysis there was an operation scar. At the umbilicus was a conic tumor with its base high in the umbilicus. The tumor extended for 2 cm. above the surface of the abdomen, and was covered with pigmented skin. During the excision it was noted that this tumor was adherent to the omentum. With the naked eye one could see in it a cavity containing several drops of brownish fluid. Microscopic examination showed that this cavity was scantily lined with epithelium. There were tubular growths and cavities, some more or less filled. By strong magnification one could see that the canals and spaces were lined with cylindric epithelium. At other points the cavities contained exfoliated epithelium. Around the glands the connective-tissue cells, here and there, were star-like and contained large quantities of collagen, suggesting the tissue of the umbilical cord. At other points the connective tissue surrounding the gland cavities showed inflammatory changes. The tubules were dilated, and here and there were seen emigrated leukocytes. In some of the connective-tissue cells hemosiderin was visible.



[In this case we are not so sure of the exact condition. It reminds us somewhat of adenomyoma, but no mention is made of muscle. It is just possible that the cells surrounding the glands were not inflammatory, but represented ordinary stroma. This, however, is doubtful. The chief points in favor of adenomyoma are that the tumor was painful during menstruation, and that the cavities contained blood or brownish fluid; furthermore, that the patient had been operated upon for a fibroid growth eleven months before, and that, on histologic examination, hemosiderin was noted in the stroma.—T. S. C.]

**A Small Umbilical Tumor Containing Uterine Glands.—Case 3 (Mintz).**—The patient was a woman, forty-five years of age. Nine months before, she had noticed a hardening at the umbilicus. During the first four months the tumor remained stationary in size, but later it grew and was painful. Then the growth ceased and the pain disappeared. The skin was adherent to the tumor; it was brownish in color and traversing it were slightly dilated veins. The tumor passed in a cone-shaped form into the umbilicus.

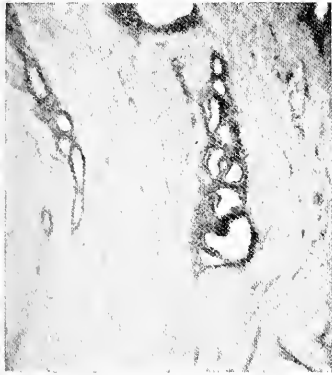


FIG. 174.—UTERINE GLANDS IN AN UMBILICAL TUMOR. (Mintz, Case 3.)

The gland grouping in the picture is similar to that seen in a typical adenomyoma of the uterus. In the colony of glands near the center of the picture the glands are regularly distributed and are surrounded by a definite stroma which separates them from the matrix of the tumor. The chain of glands in the left upper corner is in part surrounded by stroma, but some of its glands lie in direct contact with the dense surrounding tissue.

the epithelium assumes a flattened shape. On further dilatation the epithelium becomes still flatter and drops off into the cavities. These cavities are surrounded by connective tissue (Fig. 175); they contain detritus, swollen epithelium, and leukocytes.

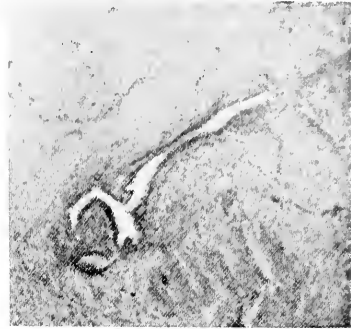


FIG. 173.—DICHOTOMOUS BRANCHING OF A GLAND IN A SMALL UMBILICAL TUMOR. (Mintz, Case 3.)

The histologic picture might very readily be taken for that of an adenomyoma. In the lower part the gland shows dichotomous branching.

The tumor on section was found to consist of firm scar tissue in which numerous small cysts filled with brownish contents were noted.

The tumor on section was found to consist of firm scar tissue in which numerous small cysts filled with brownish contents were noted.

**Microscopic Examination.**—The connective-tissue portion of the skin passes directly into the connective tissue of the tumor. This consists of parallel and irregular connective-tissue strands, here and there showing small-round-cell infiltration. With the low power one sees cavities of various sizes filled with a brownish, pigmented fluid. The small, round and tubular cavities are partly arranged in groups, partly separated from one another by old scar tissue. The tubules here and there show dichotomous branching (Fig. 173). At several points the growth is seen passing in various directions. At many points where one group of unchanged tubules exists, it is surrounded by young connective tissue, which toward the periphery passes off into the old fibrous tissue (Fig. 174). The cavities of more recent formation and the tubules are lined with one layer of cylindrical epithelium. In the more widely dilated cavities

[Mintz's various figures are very suggestive, and Fig. 174 could very readily be used by us to demonstrate an adenomyoma of the uterus instead of adenomyoma of the umbilicus. Here we have cross-sections of glands forming a definite colony. This area is surrounded by the characteristic stroma of the mucosa. Fig. 175 could be used to picture a mild grade of gland hypertrophy of the uterus. Here also the gland is surrounded by the characteristic stroma of the mucosa. Although no mention is made of muscle being found in this growth, the glands and the gland branchings are absolutely identical with those of the uterus. In my case of adenomyoma of the round ligament\* connective tissue predominated, and there is no reason why in some of these cases also connective tissue should not take the upper hand throughout.—T. S. C.]

On p. 396 Mintz gives a résumé of his three cases. They developed in women in middle life in the umbilical tissue, and the tumors reached the size of hazelnuts. The growth at first was slow, but suddenly increased after the lapse of several months. Examination of the tumors showed that they were painful. There was an exacerbation (congestion) at the menstrual periods.

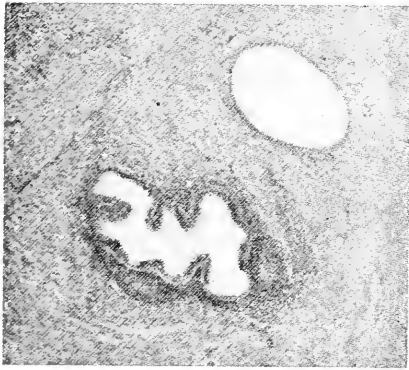


FIG. 175.—GLAND HYPERTROPHY IN A SMALL UMBILICAL TUMOR. (Mintz, Case 3.)

Near the center of the field is a gland showing hypertrophy. Separating it from the surrounding stroma is a characteristic stroma which stains more deeply and is rich in cell elements. This picture could be used very readily as an example of a uterine gland in the muscle.

In all three cases the microscopic picture showed the growth of tubular glands in the scar tissue of the umbilicus, this glandular growth being accompanied by granulation tissue reaction. This young connective tissue surrounded the tubular glands, separated them from one another, and transformed itself gradually into connective tissue.

[This is the characteristic stroma which one normally finds separating the uterine glands from one another.—T. S. C.]

The gland tubules showed one layer of cylindric epithelium, which, when the tubules dilated into cavities under the influence of the secretion, became flattened. Finally

this epithelium disintegrated and dropped into the cavities which contained the albuminous bodies and leukocytes. Mintz thought the tumors originated from remains of the omphalomesenteric duct. He then describes an instance of a somewhat similar growth reported by von Noorden in the *Deutsche Zeitschr. f. Chir.*, 1901.†

A Small Umbilical Tumor Containing Uterine Mucosa. ‡ — The patient was fifty-four years of age, and had had no children. She had had an abdominal operation ten years before on account of some uterine trouble.

\* Cullen, Thomas S.: Adenomyoma of the Round Ligament. *Johns Hopkins Hosp. Bull.*, May, 1896, 112. Further Remarks on Adenomyoma of the Round Ligament. *Johns Hopkins Hosp. Bull.*, 1898, 142.

† See also Herzenberg, R.: Ein Beitrag zum wahren Adenom des Nabels. *Deutsche med. Wochenschr.*, 1909, i, 889. Herzenberg evidently describes the same cases as those reported by Mintz.

‡ Ehrlich, H.: Primäres doppelseitiges Mammacarcinom und wahres Nabeladenom (Mintz). *Aus von Eiselsberg's Klinik, Arch. f. klin. Chir.*, 1909, lxxxix, 742.

Shortly after leaving the hospital she developed a tumor in each breast, which gradually reached the size of an apple. They caused little difficulty, and in the course of a year did not increase much in size. Simultaneously with the appearance of the tumors in the breasts the umbilicus was pressed upward markedly by a tumor the size of a hazelnut, developing at that point. This growth had remained stationary. The umbilicus had been transformed into a small tumor with pigmented skin. The tumor was hard, and was with difficulty pushed over the underlying structures. The umbilical growth and the carcinomata of both breasts were removed. (We are here interested chiefly in the umbilical tumor.)

The tumor of the umbilicus was 3 cm. in diameter. Macroscopically, it consisted of a hard, pure white, scar-like tissue firmly attached to the skin. Scattered throughout the tumor were a number of pin-head-sized spaces which contained a serosanguineous fluid. Histologically, the chief mass consisted of fibrous tissue, poor in nuclei and cell-elements. The skin covering the tumor, except that it showed a marked pigmentation of the basal layer, looked normal. The connective tissue of the skin passed directly into that of the underlying tumor. In the tumor were numerous islands of loose connective tissue which varied markedly in the number of their nuclei; and inside this were epithelial elements. There were two definite histologic pictures.

In the portion lying near the skin (Fig. 176) were groups of closely compressed and tortuous gland loops lined with large cuboid epithelial cells having small, centrally located nuclei. The gland lumina and the basement membrane of the tubal glands were easily recognizable. Similar glands were also found in the connective tissue. They were undoubtedly hypertrophic sweat-glands.

Predominating in the central portion of the extirpated tumor was a second kind of epithelial tissue likewise situated in the loose connective tissue, but exceedingly rich in nuclei. This consisted of tubular glands with high cylindric epithelium; cilia and goblet-cells were not visible. Through the fork-like arrangement of the tubular glands there had originated here and there many bay-like spaces which might be mistaken for papillary formations and which had given rise to cystic formations due to the presence of fluid. Here and there the epithelium of the cystic

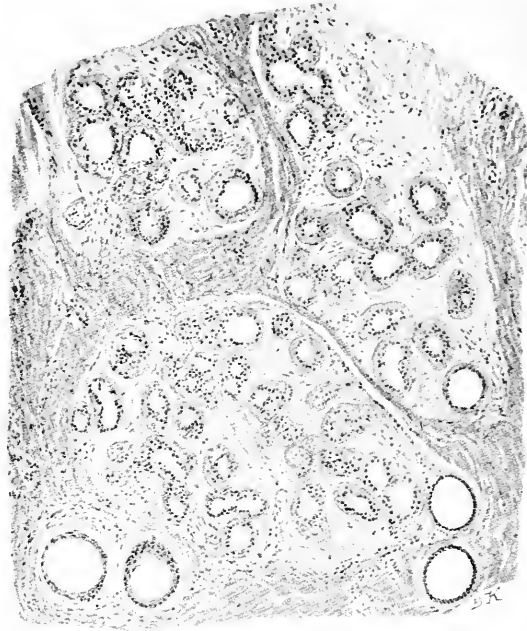


FIG. 176.—A TUMOR OF THE UMBILICUS COMPOSED PARTLY OF HYPERTROPHIC SWEAT-GLANDS. (After H. Ehrlich.)

The glands are gathered into definite groups, reminding one of the gland arrangement in small fibromata of the breast. The individual glands bear a marked resemblance to ordinary sweat-glands. Some of them are dilated. Another portion of the tumor consisted of typical uterine mucosa (see Fig. 177).

spaces had disappeared or become flattened. The contents of the cysts were hemorrhagic or showed a formless detritus, and in several places surrounding the cysts were masses of blood-pigment. Van Gieson's stain failed to bring out any smooth muscle surrounding the epithelial elements. This was found only in connection with the vessels of the connective tissue and there not abundantly.

While the glands first described are without doubt hypertrophic sweat-glands, the glands of the second group are, on account of their character and their epithelium, in all probability derivatives of the intestinal tract. Ehrlich speaks of the growth as an adenoma of the umbilicus.

[The reader will note that, judging from Fig. 176, there is no doubt that the first gland elements described by Ehrlich are sweat-glands and that the tumor consisted of sweat-glands. Fig. 177, however, shows everywhere, that the second variety of

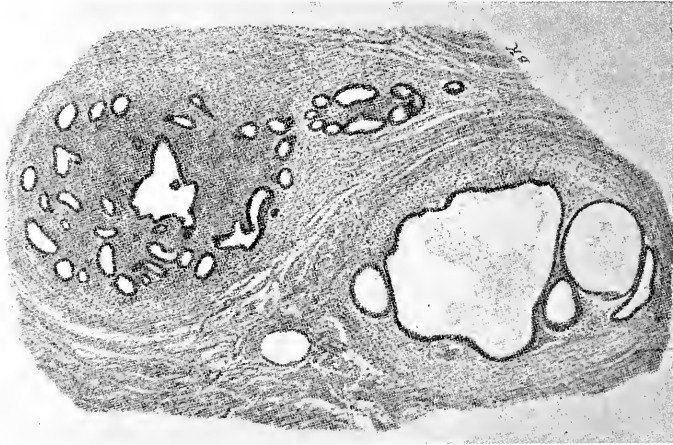


FIG. 177.—UTERINE MUCOSA IN AN UMBILICAL TUMOR. (After H. Ehrlich.)

To the left are characteristic uterine glands, a few of them dilated. They are surrounded by a definite stroma which separates them from the connective tissue. In the right portion of the picture are similar glands, the majority of which have become dilated. If we take the left half of the picture only, it might very readily pass without any description for a representation of an adenomyoma of the uterus.

glands can in no way be connected with remnants of the intestinal duct, but that we have here typical uterine mucosa enveloped in a definite stroma.

The cystic spaces, as noted in the text, were partly filled with blood. They are nothing more than glands that have been markedly dilated by old menstrual fluid. This is one of the cases in which the definite uterine character of the mucosa is clearly evident.—T. S. C.]

A Tumor of the Umbilicus Consisting of a Cystadenoma of the Sweat-glands and a Cavernous Angioma. (Eine Geschwulst des Nabels. Kombination von Cystadenom der Schweissdrüsen mit cavernösem Angiom.)—Wullstein\* says that in the literature he has found no tumor similar to the one he is describing. In 1891 a specimen was sent to the Göttingen laboratory. This consisted of an umbilical tumor which had developed in the course of three years and

\* Wullstein, L.: Arb. a. d. Path. Inst. in Göttingen, R. Virchow, zum 50. Doctor-Jubiläum, 1893, 245.

was attached by a thin pedicle, which had not been completely removed. The pedicle had extended into the abdominal cavity. The physician in charge had made a diagnosis of myxofibroma. The patient was a sterile woman thirty-four years of age. In addition to the umbilical tumor, another growth was present in the pelvis. This was the size of a fist, was connected with the uterus, and had spread out diffusely in the neighborhood of the right broad ligament. It could not be regarded as an exudate. The physician was interested to find out whether there was any connection between the two tumors; in other words, whether the umbilical growth was a metastasis. Wullstein examined a Müller's fluid specimen. It was everywhere covered with skin. It had a semicircular form and was about the size of a thaler. The umbilicus was raised 1 cm. above the surrounding abdominal skin, and its surface showed numerous shallow furrows. The umbilical furrow was recognized as an irregular, transverse cleft, which divided the umbilicus into two unequal portions, it becoming deeper and deeper in the middle until there was a depression 11 mm. in depth. About the middle of the under surface of the tumor was a cord about 1 cm. long, hardly as thick as a straw. This was solid and composed of connective tissue. The tumor itself was about 3 cm. long and averaged 1.5 cm. in thickness. On section it was seen that the umbilicus was everywhere covered with skin, which in all portions was thickened and markedly pigmented. From the bottom of the umbilical depression and running parallel were thick bundles of dense connective tissue. The tumor consisted of numerous dense, hard, glistening connective-tissue bundles, which enclosed more or less long or round areas of loose tissue, grayish in appearance, and in the interior in places were small lumina. Subcutaneous fat was absent. In the vicinity of the umbilical scar the tissue was sieve-like. The spaces of the meshwork were filled with dark-brown masses about the size of poppy-seeds. The meshwork consisted of firm connective tissue.

Microscopic examination of a section from the middle of the tumor showed that the epidermis was thickened. The deepest cells of the stratum mucosum were granular, and contained everywhere brown pigment. Only at the base of the umbilicus, where the papillæ were not markedly formed, was the pigment absent. Everywhere in the corium and in the subcutis were numerous mast cells. Hair and sebaceous glands were nowhere to be found. The deeper layers of the skin contained normally formed sweat-glands. The tumor consisted chiefly of a connective-tissue stroma and of cavities varying in size and form. The stroma, which in amount predominated over the alveolar tissue, was composed of broad, thick, dense connective tissue, which contained a few cell-elements with spindle-shaped nuclei. Only around the spaces there was present a connective tissue which was very delicate and whose fibers formed a network partly as fine bundles. The numerous nuclei were oval and frequently almost round. Immediately around the alveoli the connective-tissue threads formed a thick layer, really a membrana propria. The cavities were lined with cylindric cells placed at right angles to the basement-membrane. Their height was not always in proportion to the size of the cavity, but seemed to depend on the pressure of the gland contents. In a few places the tubules were filled with epithelium. The gland tubules were usually cut either obliquely or longitudinally. The gland lumina near the periphery of the tumor in width resembled normal sweat-glands. On the other hand, those in the middle of the tumor were markedly dilated and round; in the latter the tissue was frequently infiltrated with cells. The majority of the glands were filled with a secretion com-

posed of a most delicate, rather granular network of threads mixed with epithelial cells. The entire tumor was permeated by a thick network of capillaries which surrounded the individual gland tubules. In many places in the connective-tissue stroma in the neighborhood of the blood-vessels were remnants of old and fresh blood.

In the preparations taken from the lateral portion of the tumor accumulations of round cells and blood-vessels were seen. The cystic dilatation of the canals had evidently been produced by pressure from within. The cavities were lined with endothelium, and the walls of these new cavities had projections into them. These cavities were due to the confluence of the neighboring small cavities. The origin of these in some places could be followed. At several points between the blood-spaces were dilated tubules lined with cylindric epithelium, usually filled with secretion, and surrounded by the characteristic connective tissue which sometimes reached as far as the endothelium of the blood-spaces. A few of the gland-like cavities also contained blood. At no point, however, was this adherent.

After these findings we must ask: Are we dealing here with an individual tumor or is there a combination of two tumors? Further, under what category does this tumor formation belong? Wullstein held it to be a combination of cystadenoma of the sweat-glands with cavernous angioma.

On p. 250 he says that what makes him think there is a combination of two tumors is the fact that there is a different lining to the large spaces, the one being lined with endothelium and the other with cylindric epithelium. No less typical is the relation of the surrounding connective tissue to the spaces. The differences even with the low power are easily recognized, through the various microchemical reactions in color with methylene-blue. The above already described delicate bluish connective tissue is independent of the sweat-glands and their tributaries in the specimen, and is present only in the vicinity of the tubules lined with cylindric epithelium, whereas the spaces lined with endothelium are always surrounded by a thick, fibrillated tissue which stains intensely red. He thinks that the large cavernous spaces in the first place are due to circulatory disturbances.

On p. 251 he says we must look upon the sweat-glands as the point of origin for the epithelium of the new-growth, on account of the position of the tumor beneath the skin, the presence of cylindric epithelium, and the absence of squamous epithelial nests. Its origin from the epidermis or from the hair-follicles or the sebaceous glands is excluded. On the other hand, we must ask whether it may not be due to some embryologic deposit. Three things have to be thought of: the umbilical canal, the urachus, and the omphalomesenteric duct. Have we in this mixed tumor a purely accidental combination of an adenomatous cyst of the sweat-glands and a cavernous angioma? or do the two varieties bear a causal relation one to the other? In conclusion, he says, the old and fresh hemorrhages in various portions of the tumor have followed as a result of hyperemia—perhaps the menstrual hyperemia.

[Wullstein's tumor also occurred in a woman. He speaks of its characteristic connective tissue separating the glands lined with cylindric epithelium from the surrounding stroma. Further, in his last paragraph he speaks of the hemorrhage through the tumor being due to hyperemia, possibly menstrual in origin. We believe that here he has the clue and that, in all probability, the glands in this case were also uterine glands. Although the description of the histologic appearances in this case is in places somewhat involved, we have in our translation held closely

to the text in order that the points favoring the uterine origin of the glands might not be unduly accentuated. I wrote Professor Orth, of Berlin, and he in turn referred me to Dr. Wullstein, who at the time this case was published (1893) was an assistant of Professor Orth and occupied the room next to mine in the Göttingen Laboratory. Dr. Wullstein kindly sent me the reprint of his article, but I was unable to get the specimen, and consequently cannot speak with absolute certainty.—T. S. C.]

N. Giannettasio, in an article,\* gives a résumé of the literature on tumors of the umbilicus, and reports a case in a multipara aged forty-four. A year and a half before she came under his observation the patient noticed a small tumor the size of a walnut at the umbilicus. This was solid, immobile beneath the skin, and occasioned no discomfort. It occupied the lower and left side of the umbilical depression. It was removed, and the patient was perfectly well twenty-five months later. He gives a very good plate, but the text is not satisfactory. The nodule, however, he says, contained "cytogenous" connective tissue. The plate shows normal skin, dilated blood-vessels, and gland-spaces lined with apparently cuboid epithelium, and surrounded by a stroma, the picture somewhat suggesting uterine glands.

Probably Uterine Glands in a Small Umbilical Tumor. †  
—In the beginning of his article von Noorden states that he is going to demonstrate a tumor which, from its characteristics and anatomic picture, leaves no doubt that it originated from the sweat-glands, and that, so far as he knew, no similar case was on record. On October 1, 1898, a thirty-eight-year-old multipara told him that for two months she had had a slight unevenness in the middle of the umbilicus. Eight days previously a physician had observed a pea-sized enlargement in the floor of the umbilicus. Clinically it suggested a nevus, and on account of the dark pigmentation von Noorden thought of melanosarcoma. On October 14, 1898, the tumor was larger than a pea, semicircular, and not sharply defined from the surrounding umbilical tissue. In its center it had a small, wart-like elevation. There were no inflammatory changes in the vicinity. The skin over the tumor was somewhat uneven, grayish in color, and here and there more deeply pigmented than the floor of the umbilicus. No pulsation was noted, no variation on pressure. The umbilicus was removed. Two and a half years later the patient was perfectly well.

The umbilicus on section showed a drawing in of the skin, and in the depth there was a wart-like projection. The tissue of the umbilicus itself was very hard. On section a pea-sized, light brownish, pigmented area was observed, which was not sharply defined from the surrounding tissue.

Microscopic Examination.—The nodule was made up of a loose connective tissue with numerous large cells. It contained a large number of capillaries. Within this connective tissue were slit-shaped cavities lined with cylindric epithelium which had become loosened irregularly from the wall. Some of these cavities had become dilated into irregular cystic spaces, which here and there showed clearly a lining of cylindric epithelium, while in other places they had completely lost it. The contents of these cavities had dropped out in some places; in others it consisted of cylindric epithelium, and in numerous cases of an irregular, structureless network. Further sections were made, and the squamous epithelial layer over

\* Giannettasio, N.: Sur les tumeurs de l'ombilic. Arch. gén. de méd., 1900, n. sér., iii, 52.

† von Noorden, W.: Ein Schweissdrüsenadenom mit Sitz im Nabel und ein Beitrag zu den Nabelgeschwülsten. Deutsche Zeitschr. f. Chir., 1901, lix, 215.

the entire nodule was found to be intact. Over the most prominent part it was three times as thick as at the periphery. Where the cells were most abundant, the deepest layers showed pigmentation. At one point (Fig. 178) "the sweat-glands" could be traced almost to the surface, being covered only with a few layers of cells.

The stroma consisted of three definite kinds of tissue: normal, dense fibrous, and mucoid-like tissue. The chief interest lay in the sweat-glands: roots of hairs were nowhere to be found, and sebaceous glands were reduced to a minimum. The search for muscle-fibers in the reticulated tissue was fruitless. No elastic fibers were found.

In general it may be said the sweat-glands were normal in the subcutaneous layer and were arranged in groups. Then in one section one would find two large openings and three or four glands, and in another section groups of from two to four glands. Some were cut in such a manner that 9 to 15 round lumina were in a

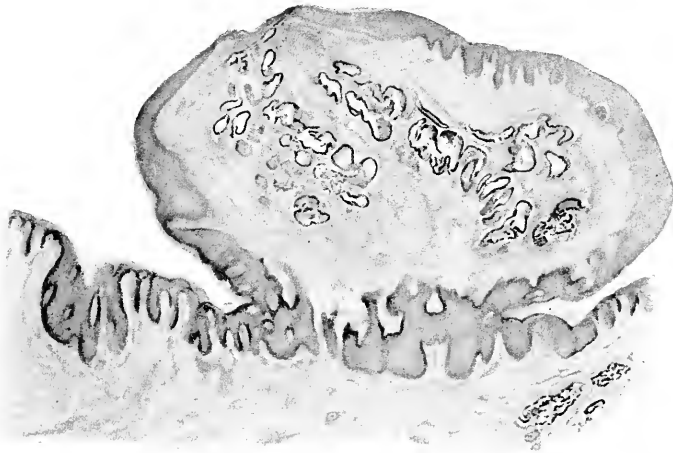


FIG. 178.—A SMALL UMBILICAL TUMOR CONTAINING NUMEROUS GLANDS. (After von Noorden.)

This is a low-power picture of the mass. The growth is covered with squamous epithelium. Scattered throughout the stroma are quantities of glands. In form they bear a closer resemblance to uterine glands than to sweat-glands. At one point the glands almost reach the surface. (For a higher magnification see Fig. 179.)

line or in the form of a hook. The groups lay, as a rule, very close to one another. The normal sweat-glands lay partly in the fibrous connective tissue, others—and this is to be noted—were separated by a rather broad layer of cells from the normal corium. The nuclei of this zone were pale and less abundant than in the remaining corium. This zone suggested the above-mentioned mucoid tissue, in which in part the altered glands lay. This tissue appeared always to penetrate between the normal gland grouping, and had separated the glands from one another. The gland epithelium was not changed. In addition to this slightly normal and slightly changed skein-like gland there were in the corium a number of cavities and tubules. These extended from near the surface of the papillary masses to the vicinity of the subcutaneous fat. The cavities and the tubules are to be seen in Figs. 178 and 179.

[We do not clearly understand what von Noorden means by corium. It seems, however, that he uses the term instead of stroma. His general description is somewhat hazy throughout.—T. S. C.]



On p. 222 he gives a résumé of his description: The tumor is made up of many roundish and often dilated, cyst-like portions which lie deeply seated in the corium. In intimate relation to these, or independent of them, are tubular channels with numerous corkscrew-like windings. These extend toward the epidermis. The cystic and also the tubular pictures are surrounded by dense and loose connective tissue which separates them from the surrounding connective tissue and are without any definite capsule. In the above-described coil we can with certainty recognize the sweat-glands.

On p. 229 he reports one of Mintz's cases and says that possibly the new-growth had developed from the glandular portion of the skin; for example, from the sweat-glands. He says: "I will also not assume this, but will say that portions of my tumor in respect to form, grouping, contents, and relation of the cells, both in the description and in the picture, produce a very similar appearance to the case reported by Mintz, and had it not been possible to establish a relation to the sweat-glands I should in all probability have followed the views of Mintz. Mintz found smooth muscle-fibers in the connective tissue at several points. The explanation as to the origin is difficult." In conclusion, von Noorden says: "From the above findings a true benign adenoma springing from the sweat-glands can be diagnosed."

[As will be noted from the history, the patient was a woman thirty-eight years of age. There was no evidence of inflammation. Histologic examination in some places showed groups of glands lying in a stroma differing from the ordinary surrounding stroma. These groups of glands were lined with one layer of cylindric epithelium, and the cavities of some of the dilated spaces contained cells that had taken up blood-pigment. Von Noorden draws attention to the fact that his case bore a marked resemblance in many ways to Mintz's case. There remains little doubt in my mind that the glands resemble those found in the body of the uterus, and the thickened, dense stroma around them bears a marked resemblance, even with the very low power, to the stroma of the uterine mucosa. The picture, at any rate, is much more suggestive of a glandular growth of uterine origin than of one coming from the sweat-glands. I endeavored, through Professor Döderlein, of Munich, to locate Dr. von Noorden, and, if possible, secure a section of this growth, but have not been successful.—T. S. C.]

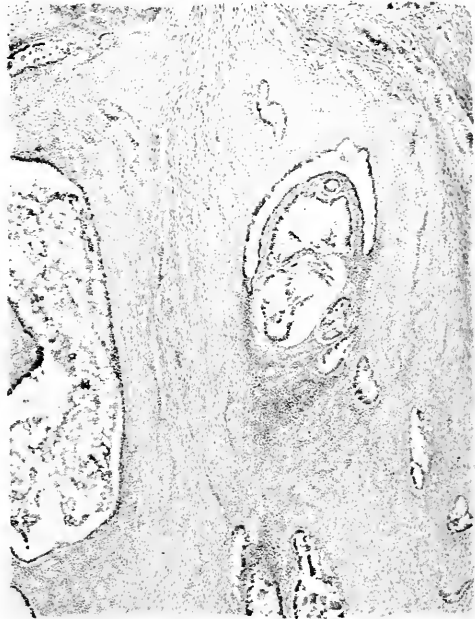

FIG. 179.—GLANDS IN A SMALL UMBILICAL TUMOR. (After von Noorden.)

The glands in the lower half of the picture bear quite a resemblance to uterine glands. Those in the center of the field remind one of the pictures seen in the depths of uterine glands, where there is some reduplication of the folds. The gland in the left part of the field is markedly dilated and contains much detritus.

It is rather difficult to classify this tumor reported by Villar, but as it presents a few clinical and histologic points suggestive of the group under consideration, I mention it here, although it is not considered in the digest.\*

L. L., aged forty-six, entered the service of Professor Guyon September 17, 1886. In the month of December, 1885, nothing abnormal was noticed in the umbilical region, but shortly afterward her corsets produced pain in this region and she discovered a small tumor the size of a pin-head, reddish in color, in the umbilical depression. This tumor increased very slowly, and in May, 1886, she went to the hospital for examination. She continued under treatment, and in the month of August entered the hospital. At that time at the umbilical depression was a tumor the size of a bird's egg. It was conic. Its base was continuous with the cicatrix, and was somewhat constricted by the depression. It had a very narrow, but relatively large pedicle. It was in reality sessile, firm in consistence, but elastic and reddish in color. At the top was a blackish point, 2 mm. in diameter. The tumor itself was not ulcerated and did not discharge any liquid. Two or three days after she entered the hospital the blackish point ruptured and there was an escape of tarry blood. The patient experienced no pain and there was no glandular enlargement.

Histologic Examination by Clado.—The tumor is situated in the center of the umbilicus and has developed in the depth of the cicatrix. It is covered with skin. In consistence it is a little less firm than a fibroma. On section one finds a capsule which surrounds the central mass. The tumor is whitish-gray, with numerous dark spots not any larger than the head of a pin scattered throughout it. Microscopic examination shows that the tumor is formed of sarcomatous tissue, the cells being fusiform in shape.

Some of the spaces are round, others oval, and have anastomosed with one another. Some of the canals are lined with pavement epithelium. Between the cystic spaces one finds stroma containing a small number of vessels. The skin which composes the outer covering of the tumor is exceedingly thin, but presents the characteristic appearance. There has been extravasation of blood at the center of the tumor.

[This woman, as above noted, was forty-six years of age. The history does not convince one absolutely that this was a sarcoma. It might very well have been a fibroma. It resembles in a few particulars those tumors of the umbilicus that contain uterine glands or glands somewhat resembling them.—T. S. C.]

#### FURTHER CASES OF ADENOMYOMA OF THE UMBILICUS.

These four cases have come to my knowledge since this chapter was prepared. They bear a striking resemblance to those already discussed in the preceding pages:

Two Umbilical Tumors of Probable Uterine Origin.†  
—In the surgical service of Drs. Munro and Bottomley, at the Carney Hospital, there recently occurred within a few weeks of each other two examples of umbilical tumor, the striking similarity and unusual histologic structure of which warrant their publication.

\* Villar: *Tumeurs de l'ombilic*. Thèse de Paris, 1886, obs. 68.

† Goddard, Samuel W.: *Surg., Gyn. and Obst.*, August, 1909, 249-252.

“Because of the comparative rarity of these cases the clinical histories are set forth in considerable detail:

“Case 1.—Miss S., a housekeeper, forty-four years of age, and born in New Brunswick, entered the Carney Hospital May 22, 1907. Her family and past history have no bearing on her condition at that time. A year previously, during a catamenial period, she noted some redness and tenderness about the umbilicus; two months later, at a similar time, a small tumor appeared in the abdominal wall close to the umbilicus. This tumor increased in size but slightly, and most of the increase came in the two weeks just preceding her admission to the hospital. The tenderness and pain, which at first were evident only during the menstrual periods, had been constant for some months, though most marked just before, during, and for a week after menstruation. Her menstrual history was not otherwise remarkable. An abdominal bandage, her only treatment, had given her some relief. There had been some little loss of weight and strength. For two months the tenderness had kept her from her usual work. No symptoms referable either to the gastro-intestinal or to the urinary tract had been noted.

“About and including the umbilicus was a rather deep-seated, spheric, slightly tender, fixed mass, of rather firm consistence, and about 2 cm. in diameter. In the navel itself was a thin, yellowish crust; a sinus could not be demonstrated; the skin over the tumor was not red. Examination of the abdomen was otherwise negative. Examination *per vaginam* showed only vaginismus and a moderately retroverted uterus.

“On May 23d Dr. Munro excised the growth (including the navel) with a portion of the adjacent peritoneum and sheath of the rectus muscle. The former was not involved in the growth; to the latter the growth was adherent. The convalescence was without note, and the patient was still free from recurrence one year after operation.

“Case 2.—Mrs. D., a housewife, entered the Carney Hospital June 23, 1907. She was born in Ireland forty-two years before that time, and came of healthy stock. Her menstrual history previous to her marriage was entirely normal in every way. Married seventeen years, she had borne four children. Following her first confinement she had had a ‘milk leg.’

“For six years previous to entering the hospital a slight bloody discharge from the navel without pain or tenderness had come with each menstruation. The discharge came only at that time. Independent of the umbilical disorder she had had in the past three years attacks of sharp pain beneath the right costal border, accompanied by vomiting, chills, and jaundice.

“The patient was rather obese, and showed distinct tenderness beneath the right costal border. At the umbilicus was a small, irregularly shaped papillomatous tumor, 2 cm. in diameter, with three distinct projections covered with normal appearing skin. At the top of the largest projection was a pin-hole opening capped with dried blood. The tumor was soft, freely movable, not tender, and apparently superficial.

“On June 24th the umbilicus with the tumor was excised by Dr. Bottomley. The tumor was confined to the skin and fat outside the aponeurosis. The peritoneal cavity was opened, and the gall-bladder and stomach regions were explored; these were found normal. Convalescence was uneventful except for the development of malaria on the ninth day, which promptly yielded to treatment. The

patient was discharged, relieved, on July 11th, and when heard from, one and a half years later, there had been no recurrence.

“For the microscopic study of these tumors, in the laboratory of Dr. Henry A. Christian at the Harvard Medical School, a large number of sections were taken from different planes and four different methods of staining were used for each section.

“So closely do the tumors resemble each other microscopically that no evident difference between them can be determined. The arrangement and construction, both in general and particular, are nearly identical. For descriptive purposes a median longitudinal section of Case 2 will be used. To the naked eye it presents an irregularly convex surface covered with true skin. Underlying this at each extremity are what appear to be sweat-glands, and in another part, chiefly in the center, are numerous vacuolated structures varying in size from a pin-point to a pin-head. The intervening structure cannot be definitely determined. Microscopically, the tumor is seen to be covered with normal epidermis, but varying in thickness. Below this, at either end, are numerous sweat-glands, thickly grouped, and around these is an abundance of fibrous connective tissue. The vacuolated or glandular structures found throughout the tumor vary in size, and for the most part are of rounded contour, while some are elongated. Some, especially the larger ones, are discrete, while others are aggregated into small groups. Some are immediately surrounded by fibrous tissue, while others are embedded in cellular tissue. There are none which appear to have any connection with the epidermis. All the gland-spaces are lined with epithelium. They are either devoid of contents, or contain a granular, structureless material in which are often found groups of red blood-cells. The epithelium varies in the different glands and even in the same gland, from the low, flattened variety to the tall, columnar cells with all the intermediate forms. The tall, columnar variety is for the most part closely compacted, with long, narrow nuclei and with no visible cell membrane. Most of them have a distinct top plate, and many show cilia of considerable length and uniformity, while others have only a suggestion of striæ. The cilia in some places are from one-fourth to one-third the length of their cells, and in others their extremities end in a globular, deeply staining tip. At irregular intervals among the nuclei of the columnar cells are larger rounded and more faintly stained nuclei. In some places the epithelium is distinctly cuboid, the nuclei clear and rounded, and the whole cell clearly defined. There is a larger group of glands which presents the flattened epithelium. The epithelium lining the glands, whether flattened, cuboid, or columnar, is for the most part in single layers. In some places the glandular epithelium is immediately supported by fibrous connective tissue, but in others the underlying structures are decidedly cellular. The cellular tissue is more compact the nearer the glandular tissue is approached, *i. e.*, the most cellular tissue is found in close connection with the gland-spaces. The nuclei are rounded or elongated and deeply stained, the protoplasm and cell membrane not being distinct. In the immediate neighborhood of some of the gland-spaces are large hemorrhagic areas in which large quantities of red blood-cells are scattered freely and intermingled with the cellular structures. These areas seem to have no direct relation to blood-vessels, which are not superabundant or enlarged. The fibrous connective tissue shows nothing of interest throughout the section. There is an abundance of smooth muscle which is closely interwoven with the connective tissue.”

The microphotographs accompanying Goddard's article bring out clearly the structure and arrangement of the tumors, and emphasize the points mentioned above.

Adenomyoma of the Umbilicus; also a Small Adenomyoma near the Anterior Iliac Spine.\*—Case 3.—“A woman, aged thirty-seven, came to me on September 2, 1908, for advice about a small tumor of the umbilicus which she had noticed during the last few months. The lump was about the size of a filbert, and lay in the lower part of the navel. It was irregular in outline, but smooth, and was of a bluish-purple color, suggesting a melanotic sarcoma. There were no abdominal symptoms or signs and no secondary deposits in the inguinal glands or elsewhere. A few days later I removed the whole navel and adjacent skin widely between two elliptic incisions, opening the abdomen on either side and taking away the intervening peritoneum. There were no traces of growth within the peritoneal cavity. The wound was stitched up in layers and healed absolutely by first intention. The specimen was given to Mr. Lawrence, the curator of our museum, for examination. Sections showed to the naked eye a hard, fibrous structure, the superficial parts of which, under the epithelial covering of the navel, were pigmented. In the deeper parts of this fibrous tissue were many islands of tubular glands lined with columnar epithelium and filled with epithelial débris. Some were cut obliquely and showed a looser areolar investing layer outside the membrana propria. The latter was not penetrated by the cells, so that one sign of the benign character of the tumor was present. Nor were there any other signs of the spread of the growth beyond the limits of the tubules. I, therefore, put it down as an adenoma derived from remnants of the vitelline duct, of which I had read but never seen.

“I saw no more of this lady until January, 1913, when she consulted me about a little nodule seated in the subcutaneous fat, about two inches internal to the left anterior iliac spine. It felt about the size of a pea, and was hard. On gently pinching the skin the latter puckered over the nodule. There were no enlarged inguinal glands or other signs of infiltration. This knot was removed shortly after by Mr. F. Hinds, of Worthing, and was sent to me. Mr. Lawrence kindly prepared several microscopic sections of it. They showed precisely the same structure as the first nodule, except that the fibrous tissue, which made up the bulk of the mass, was more dense and fewer connective-tissue corpuscles were scattered through it.

“The reappearance of this small knot, repeating the structure of the first nodule at the umbilicus, suggests, of course, strongly that the first was malignant and has recurred in the lymphatics of the subcutaneous tissue of the abdominal wall. Then the question arises, Was the original lump in the umbilicus a primary growth in some of the glandular remnants of the umbilicus enumerated above, or could it be a nodule secondary to some visceral carcinoma within the abdomen? This latter view is one adopted by Mr. Shattock, to whom I sent sections of both the first nodule removed and that obtained four and a half years later, and who was kind enough to write to me fully on the subject. It may be correct, but so far the lady has shown no evidence of visceral trouble—nearly five years after the appearance of the first nodule in the umbilicus. Time alone will show. In the meanwhile I am inclined to negative the visceral theory.”

\* Barker, A. E.: Three Cases of Solid Tumours of the Umbilicus in Adults. *The Lancet*, London, July 19, 1913, 128.

In answer to a request from me, Dr. Barker very kindly sent the only section of the umbilical tumor which the curator of the museum still possessed.

Description of the slide sent me by Dr. Barker (His No. 10,945).—The section of the umbilical nodule has a normal covering of squamous epithelium. The underlying tissue shows no evidence of glandular tissue. Dr. Barker, however, in his description of the case, says that this tumor contained glands, and, furthermore, that the glands near the anterior-superior spine were similar in character to those found at the umbilicus. Dr. Barker was good enough to also send me several slides from

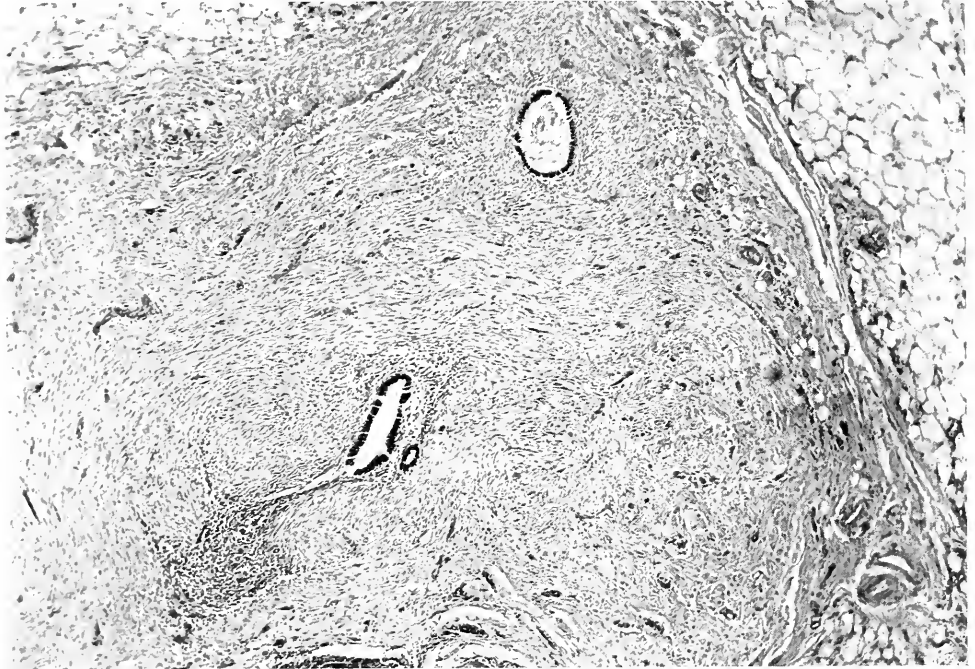


FIG. 180.—ADENOMYOMA IN THE ABDOMINAL WALL NEAR THE ANTERIOR ILIAC SPINE.

This is a photomicrograph of a portion of the small nodule furnished me by Mr. Arthur E. Barker, London, England. Near the center of the field are two glands. Their epithelium has been slightly strengthened to bring them out more distinctly. The glands are lined with one layer of cylindrical epithelium. Surrounding them is a zone of stroma cells. This zone is continuous with a large, irregular area of stroma just below and to the left of the glands. In the upper part of the field is another gland, which lies in direct contact with the tissue of the tumor. The greater part of the nodule consists of non-striated muscle and fibrous tissue. In the outlying portions of the field is adipose tissue. The growth is a typical adenomyoma, with glands similar to those of the uterine mucosa. Mr. Barker, in his description of the case, says that the umbilical nodule and the one here depicted were identical in character; consequently the umbilical growth was also an adenomyoma with glands and stroma identical with those of the endometrium of the uterus.

the growth near the anterior-superior spine. In one section I found not only myomatous tissue, but a triangular area of stroma with tubular glands at one end (Fig. 180). This area was sharply defined from the surrounding tissue. In another section was what appeared to be fibrous tissue, and possibly a little muscle. Here we had irregular, triangular areas of stroma, sometimes without any glands, sometimes with tubular glands identical with those of the uterine mucosa. At other points the glands lay in direct contact with the muscle. Surrounding the entire growth was adipose tissue. The picture in the main is analogous to that which we

have described as representing adenomyoma of the umbilicus. Mr. Barker's case is particularly interesting in that he had not only a tumor of this character at the umbilicus, but also a nodule near the anterior iliac spine.

A Small Umbilical Tumor Consisting in Part of Sweat-glands and in Part Apparently of Uterine Glands.—While in Atlanta, at the meeting of the Southern Surgical Association in December, 1913, Dr. Edward G. Jones, of Atlanta, told me that he had recently seen an umbilical tumor in which I might be interested. On December 22, 1913, he wrote: "I am sending under separate cover a section of the umbilical tumor. Unfortunately, I cannot give you any clinical data. The nodule was three-quarters of an inch in diameter, and gave the patient some discomfort at times." Later Dr. Jones discovered that, according to the patient's account, the tumor seemed to her to enlarge at the time of menstruation.

The specimen sent me by Dr. Jones is covered over with squamous epithelium which contains pigment in the deeper layers. The underlying tissue consists in a large measure of fibrous tissue. The capillaries scattered throughout it are in many places surrounded by round cells. Here and there throughout the fibrous tissue are groups of sweat-glands. These are separated from the fibrous tissue by a definite stroma.

At other points are large glands lined with cylindric epithelium. Some of these glands lie in direct contact with the fibrous tissue; others have a definite stroma, separating them from the connective tissue. This stroma stains more deeply than the connective tissue, and its nuclei are oval and stain deeply.

The tumor is evidently made up of two distinct varieties of glands: some corresponding to sweat-glands and others bearing a marked resemblance to those of the uterine mucosa. There is little doubt that part of this growth consists of uterine glands. The section was, unfortunately, too thick to supply a satisfactory photomicrograph.

#### PERSONAL OBSERVATION.

In 1900 Mrs. E. J. D., aged thirty-eight, was admitted to Dr. Howard A. Kelly's Sanitarium on account of a retroflexed uterus and a relaxed vaginal outlet. A small round nodule was at the same time detected at the umbilicus. The nodule was removed, the uterus brought up into position, and the perineum repaired. Her convalescence was prolonged on account of phlebitis in both legs.

This patient was the mother of four children. Her menses began at thirteen, were fairly regular, and lasted from three to five days. About two years before admission the patient first felt a little pain in the umbilical region. During the last year this had become very severe and the small umbilical growth had developed. There was no reddening at the umbilicus, and the general health had not been affected.

This small umbilical tumor was brought over to the gynecologic laboratory of the Johns Hopkins Hospital and carefully examined. For some unforeseen reason it was not indexed, and, consequently, when we were getting together all our umbilical material, was overlooked. It was accidentally discovered when class sections were being gone over a few days ago (March 3, 1915). Dr. Elizabeth Hurdon, who examined the specimen at the time, drew special attention to the fact that the

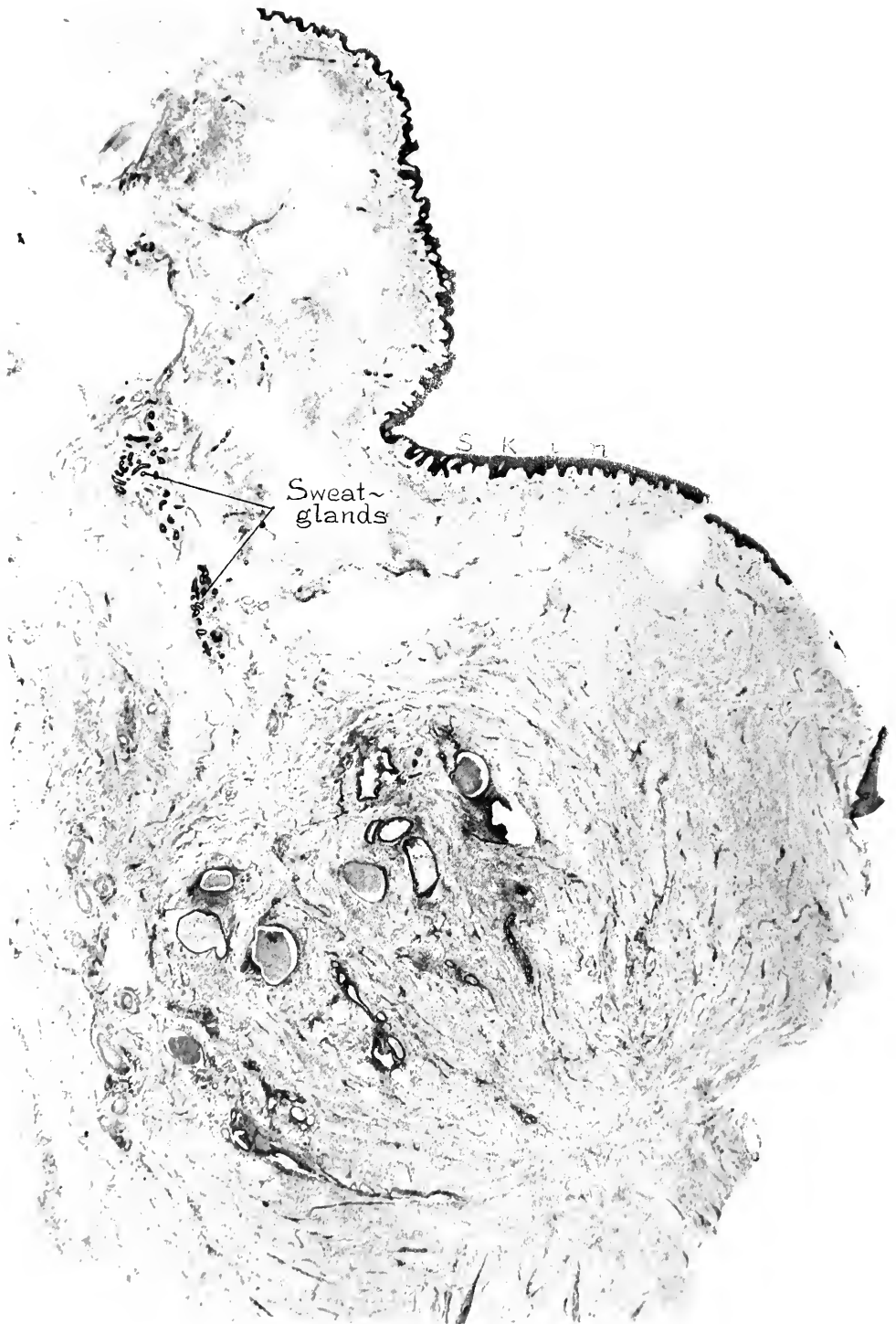

FIG. 181.—A SMALL UMBILICAL TUMOR CONTAINING GLANDS SIMILAR TO THOSE OF THE BODY OF THE UTERUS.

Gyn-Path. No. 3911. This is a low-power photomicrograph of a section of the entire umbilical nodule. The skin covering is normal. Occupying the lower half of the field is a somewhat circular growth, denser in structure than the surrounding stroma. It consisted of fibrous tissue and non-stripped muscle. Scattered throughout the tumor are glands. Some occur singly, others in groups. Some of the smaller glands are surrounded by a dark zone—a zone of characteristic stroma. Many of the glands are dilated and partially filled with blood. In the upper part of the field are aggregations of sweat-glands. (For the higher power picture see Figs. 182 and 183.)



glands in the growth were similar to those of the endometrium, and that some of them were surrounded by the characteristic stroma of the uterine mucosa.

Gyn.-Path. No. 3914. The tumor averages 1.5 cm. in diameter.

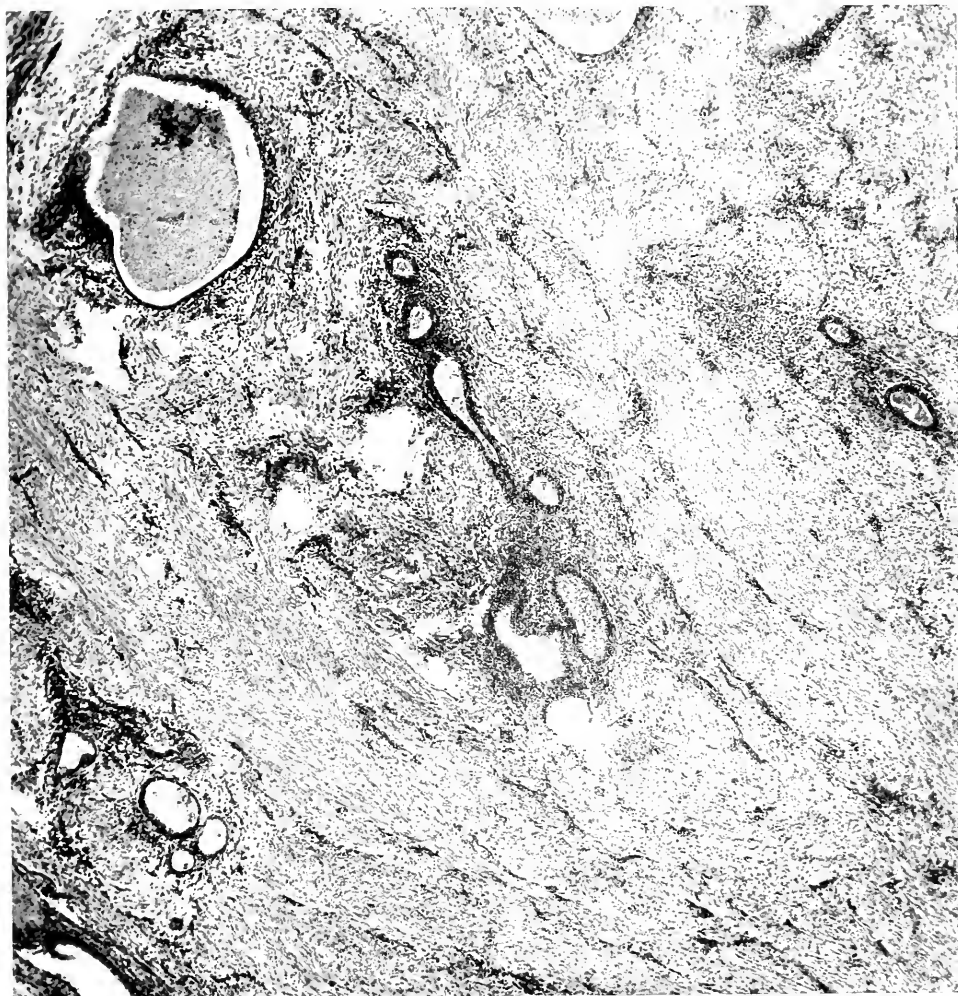

FIG. 182.—ADENOMYOMA OF THE UMBILICUS.

Gyn.-Path. No. 3914. This picture gives an enlargement of the adenomyoma seen in Fig. 181. The stroma of the growth consists of non-striated muscle and fibrous tissue. Occupying the center of the field are several glands. They were lined with one layer of cylindric epithelium, on which cilia were here and there demonstrable. The glands are separated from the muscle by a definite stroma. This, with a higher power, was found to be identical with that of the endometrium of the uterus. In the left upper corner of the picture is a markedly dilated gland. This and other dilated glands contained old blood and exfoliated epithelial cells, which had taken up blood-pigment and had become spheric. The entire picture of the umbilical tumor is analogous to that of an adenomyoma of the uterus.

Its outer surface is covered with normal-appearing skin. On section it presents a dense fibrous structure.

On histologic examination the skin surface is found intact and normal. The stroma of the growth consists of fibrous tissue with a moderate amount of non-striated muscle distributed throughout it.

Scattered here and there throughout the nodule are round or tortuous glands. Some of these occur in groups, others are single (Figs. 181 and 182). The glands are lined with one layer of low cylindric epithelium, which in a few places shows definite cilia. Some of the gland cavities are empty, others are dilated and filled with old blood, and in a few are exfoliated epithelial cells which have become spheric and have taken up the blood-pigment. Some of the glands lie in direct contact with the muscle or fibrous tissue; others are separated from the dense tissue by a

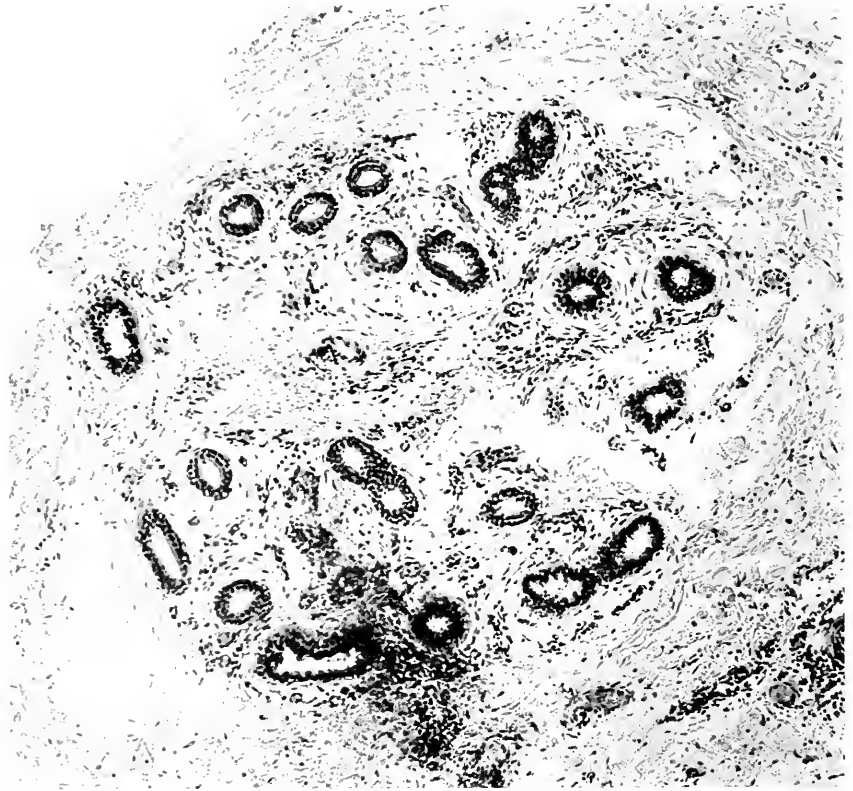


FIG. 183.—A GROUP OF SWEAT-GLANDS IN AN UMBILICAL TUMOR.  
Gyn.-Path. No. 3914. For their relation to the adenomyoma of the umbilicus see Fig. 181.

definite stroma, which is very cellular. The picture is that of a typical adenomyoma with glands identical with those of the uterine mucosa.

At one point is an aggregation of glands of a totally different type. These glands are small, round, and have a lining of two layers of low cuboid cells. They closely resemble sweat-glands (Fig. 183).

This is another definite example of an adenomyoma of the umbilicus. It will be remembered that in several of the recorded cases the sweat-glands were markedly increased in number.

## LITERATURE CONSULTED IN THE PREPARATION OF UMBILICAL TUMORS CONTAINING UTERINE MUCOSA OR REMNANTS OF MÜLLER'S DUCT.

- Barker, Arthur E.: Three Cases of Solid Tumours of the Umbilicus in Adults. *Lancet*, London, July 19, 1913, 128.
- Cullen, Thomas S.: Umbilical Tumors Containing Uterine Mucosa or Remnants of Müller's Ducts. *Surg., Gyn. and Obstet.*, May, 1912, 479.
- Ehrlich: Primäres doppelseitiges Mammacarcinom und wahres Nabeladenom (Mintz). Aus von Eiselsberg's Klinik. *Arch. f. klin. Chir.*, 1909, lxxxix, 742.
- Giannettasio: Sur les tumeurs de l'ombilic. *Arch. gén. de méd.*, 1900, n. série, iii, 52.
- Goddard, Samuel W.: Two Umbilical Tumors of Probable Uterine Origin. *Surg., Gyn. and Obstet.*, August, 1909, 249.
- Green: *Trans. Path. Soc. London*, 1899, 1, 243.
- Herzenberg: Ein Beitrag zum wahren Adenom des Nabels. *Deutsche med. Wochenschr.*, 1909, i, 889.
- Mintz, W.: Das wahre Adenom des Nabels. *Deutsche Zeitschr. f. Chir.*, 1899, li, 545.
- von Noorden, W.: Ein Schweissdrüsenadenom mit Sitz im Nabel und ein Beitrag zu den Nabelgeschwülsten. *Deutsche Zeitschr. f. Chir.*, 1901, lix, 215.
- Villar, Francis: Tumeurs de l'ombilic. *Thèse de Paris*, 1886.
- Wullstein, L.: Eine Geschwulst des Nabels. (Kombination von Cystadenom der Schweissdrüsen mit cavernösem Angiom.) *Arb. a. d. Path. Inst. in Göttingen*, R. Virchow, zum 50. Doctor-Jubiläum, 1893, 245.

## CHAPTER XXV.

### CARCINOMA OF THE UMBILICUS.

General consideration.

Classification.

Primary squamous-cell carcinoma of the umbilicus.

Primary adenocarcinoma of the umbilicus; report of cases.

Carcinoma of the umbilicus secondary to carcinoma of the stomach; symptoms; treatment; detailed report of cases.

Carcinoma of the umbilicus secondary to cancer of the gall-bladder; report of cases; personal observation.

Carcinoma of the umbilicus secondary to cancer of the intestine; report of cases.

Carcinoma of the umbilicus secondary to ovarian carcinoma; report of cases; personal observation.

Carcinoma of the umbilicus secondary to carcinoma of the uterus.

Cases of secondary carcinoma of the umbilicus in which the source of the primary growth was not determined.

A retroperitoneal carcinoma accompanied by cancer of the umbilicus.

IN an article on Surgical Diseases of the Umbilicus which I read before the Surgical Section of the American Medical Association in June, 1910, and which was published in the Journal of February 11, 1911, the subject of umbilical cancer was briefly referred to, and several cases that had come under my observation were reported. In the present article cancer of the umbilicus will be much more fully considered, and the cases hitherto recorded in the literature brought together. Associated intimately with the early development of the subject of carcinoma of the umbilicus are the names of Parker,\* Chuquet,† Villar,‡ Feulard,§ Burkhart,|| Ledderhose,\*\* Neveu,†† Morris,‡‡ Pernice,§§ Quénu and Longuet,|||| Le Coniac,\*\*\* and Besson.††† Many other authors have enriched the literature by publishing individual cases.

Before discussing the malignant epithelial growths occurring at the umbilicus, it may be well to refresh our minds as to the histologic appearance of the normal

\* Parker, W.: Excision of Umbilicus for Malignant Disease. Arch. Clin. Surg., New York, 1876-77, 1, 71.

† Chuquet: Du carcinome généralisé du péritoine. Thèse de Paris, 1879, No. 548.

‡ Villar, Francis: Tumeurs de l'ombilic. Thèse de Paris, 1886.

§ Feulard: Fistule ombilicale et cancer de l'estomac. Arch. gén. de méd., 1887, 7. sér., xx, 158.

|| Burkhart, O.: Ueber den Nabelkrebs. Inaug. Diss., Berlin, 1889.

\*\* Ledderhose, G.: Deutsche Chirurgie, 1890, Lief. 45 b.

†† Neveu: Contribution à l'étude des tumeurs malignes secondaires de l'ombilic. Paris, 1890.

‡‡ Morris: Malignant Disease of the Navel as a Secondary Complication. Verhandl. d. 10. Internat. Med. Cong., 1890, Berlin, 1891, iii, 7. Abth., 122.

§§ Pernice, L.: Die Nabelgeschwülste, Halle, 1892.

|||| Quénu and Longuet: Du cancer secondaire de l'ombilic. Rev. de chir., 1896, xvi, 97.

\*\*\* Le Coniac, H. C. J.: Cancer secondaire de l'ombilic, consécutif aux tumeurs malignes de l'appareil utéro-ovarien. Thèse de Bordeaux, 1898, No. 19.

—††† Besson, E.: Cancer de l'ombilic. Thèse de Paris, 1901, No. 263.

umbilicus and as to the umbilical lymphatics. The umbilical scar is covered over with a very thin squamous epithelium and is devoid of hair-follicles, sweat-glands, and sebaceous glands.

In a few cases remnants of the omphalomesenteric duct have been detected at the umbilicus. These may be recognized as small fistulous tracts or as cysts lying between the peritoneum and the rectus muscle, or just beneath and communicating with the skin. In a few instances remnants of the omphalomesenteric duct have been present as small tubular glands opening directly upon the surface of the umbilical depression. Such a case has been particularly well described by Fox and MacLeod\* (p. 268).

From the above description it is evident that, while, as a rule, we have only a very attenuated squamous epithelium at the umbilicus, in some cases cylindric epithelium is present. Consequently we can have two varieties of primary carcinoma in this region.

The careful study of many umbilical lesions in the past has demonstrated that, when the liver is involved in a malignant growth which has extended to or encroached upon the suspensory ligament, the growth tends to pass by way of the lymphatics out along the suspensory ligament to the umbilicus. Where a malignant pelvic growth extends to the umbilicus, it usually follows the lymphatics found in the course of the remnants of the obliterated umbilical arteries and urachus upward to the umbilical depression. If the umbilicus is the seat of a malignant growth, either the inguinal or axillary glands may be secondarily involved, according as the growth occupies the upper or lower part of the umbilicus. The lymphatics of the umbilical region are considered at length in Chapter II.

From a study of the literature it is found advisable to divide carcinomata of the umbilicus into two main groups—those that are primary, and those that are secondary to some intra-abdominal tumor. Each of these groups may be subdivided as follows:

- |                                   |   |   |
|-----------------------------------|---|---|
| A. Primary umbilical carcinoma.   | { | 1. Squamous-cell carcinoma.<br>2. Adenocarcinoma.   |
| B. Secondary umbilical carcinoma. | { | 1. From the stomach.<br>2. From the gall-bladder.<br>3. From the intestine.<br>4. From the ovaries.<br>5. From the uterus.<br>6. From other abdominal organs. |

Cancer of the umbilicus, whether primary or secondary, is exceptionally rare.† Thus, according to Parker (1876), Walshe‡ states that Tanchou found that the mortuary register of Paris and two adjacent arrondissements yielded 9118 deaths from cancer between the years 1830–40 inclusive, and that in only two instances was the umbilicus the seat of the carcinoma. With the early recognition of abdominal lesions and their timely surgical treatment, carcinoma of the umbilicus will in all probability diminish instead of increase.

\* Fox and MacLeod: A Case of Paget's Disease of the Umbilicus. *Brit. Jour. Dermatol.*, 1904, xvi, 41.

† I have carefully read Sir William Osler's splendid series of lectures on the Diagnosis of Abdominal Tumors, published in vols. lix and lx of the *New York Medical Journal*, 1894, but failed to find any case in which the umbilicus was the seat of a secondary carcinoma.

‡ Walshe: *Nature and Treatment of Cancer*, London, 1846, 92.

## PRIMARY SQUAMOUS-CELL CARCINOMA OF THE UMBILICUS.

Malignant squamous-cell growths occurring at the umbilicus are exceedingly rare. Hamay,\* in 1843, reported a case of scirrhus cancer of the umbilicus. A microscopic examination was, however, not given, and it is impossible to determine whether or not the growth was primary.

Pernice's † Case 77 from Volkmann's clinic is more suggestive. The patient for a long while had had an umbilical stone. A carcinoma developed, and there was a purulent secretion. When Volkmann saw him, there was an ulcerated area the size of a thaler. On account of the cauliflower-like walls the growth was diagnosed as a canceroid (squamous-cell) carcinoma. The diagnosis was probably correct, although we have no data as to any histologic examination. It would seem that in this case the constant irritation of the foreign body had stimulated the development of a malignant growth.

Pernice, in his Case 79, reports another carcinoma, also from Volkmann's clinic. The patient was a man, fifty-nine years of age, and of uncleanly habits. Not long before admission he had noticed a large number of brownish-looking spots all over the body. These varied in size from a finger-nail to a lentil. When the crusts were removed, there was free bleeding. For six or eight years he had noticed moisture around, and an odor from, the umbilicus. He consulted a physician, who removed several small particles of secretion. The walls of the umbilicus formed a cuff of canceroid or epithelial cancer. When Volkmann saw the patient, it was the size of a thaler and secreted a great deal. There was marked infiltration of the abdominal wall. The abdomen was opened during the operation. The patient died of sepsis in thirty-six hours. No further details of this case are given. The growth was evidently a primary carcinoma of the umbilicus, and in all probability had developed from the squamous epithelium, as indicated by the mode of origin and the slow growth. These are the only cases I could find suggesting a primary squamous-cell carcinoma of the umbilicus.

## PRIMARY ADENOCARCINOMA OF THE UMBILICUS.

In the cases reported in the literature it is very difficult to determine accurately whether the umbilical tumors were primary or secondary. Where the patient gave no history of any abdominal lesion, and where careful abdominal inspection before and at operation brought to light no evidence pointing to the existence of any other primary abdominal growth, one may, with a relative degree of certainty, conclude that the tumor was primary at the umbilicus. Still it must be remembered—as was clearly demonstrated in Valette's case—that, although a careful visual and manual examination may fail to reveal any primary cancer in the stomach, such a growth may nevertheless exist. In Valette's case, when the umbilical growth was removed, the stomach was brought up into the wound for examination, and was apparently free from disease. The patient died of peritonitis, and at autopsy a latent carcinoma of the stomach was found. The absence of any abdominal symptoms for a period of two or three years after a removal of an umbilical carcinoma is the most certain proof that the growth has originated in the umbilicus.

\* Hamay: *Edin. Med. and Surg. Jour.*, 1843, lx, 313.

† Pernice, L.: *Die Nabelgeschwülste*, Halle, 1892.

Pernice found in the literature 21 cases of what he considered primary carcinoma of the umbilicus. In this number he included both the squamous-cell and the glandular variety. I have discarded several of the cases included in his group, and have added several recorded since his valuable monograph was written in 1892; and still the actual number of cases remains uncertain. In the cases reported by Déjerine and Sollier, Bonvoisin, Forgue and Riche, Hue and Jacquin, Maylard, Parker, and Tillaux and Barraud, the growths seem, without a doubt, to have been primary. The growths reported by Ajello, Burkhart, Després, Dannenberg, Demarquay, Giordano, Guiselin, Heurtaux, Ippolito, Jores, Lewis, Stori, and Wagner were also probably primary adenocarcinomata of the umbilicus, although the evidence in these cases is not quite so convincing. In Besson's case the picture suggested to some extent the presence of an umbilical tumor containing uterine glands. Hertz's case need be only mentioned here. From the description the growth does not seem to have been a carcinoma, but resembled in some degree the type of umbilical tumors containing uterine glands.

Pernice's Case 78 bears a striking resemblance to that reported by Fox and MacLeod. The man was seventy-two years of age, and the commencement of the umbilical growth dated back five or six years. It was the size of a two-mark piece, and was here and there covered with hard crusts. It looked very much like a rodent ulcer. On microscopic examination it was found to be a slowly growing, relatively benign carcinoma of the epithelium. Here and there a definite tendency toward gland formation was noted. It is quite possible that these glands were remnants of the omphalomesenteric duct, and that the proliferation of the squamous epithelium was similar to that noted in the case reported by Fox and MacLeod, and designated as Paget's disease of the umbilicus.

In Döderlein's case and in Pernice's Case 76, although the umbilical growths were considered as primary, they would seem to have been secondary to an abdominal lesion.

Primary adenocarcinoma of the umbilicus usually develops as a very small nodule in the umbilical depression, which may grow slowly or rapidly. In some cases it has not been larger than a small nut; in others it has reached the size of a walnut or a hen's egg. Such a tumor has been known to grow to the size of a five-franc piece in the course of six months. It may be smooth or have a slightly papillary surface. With the increase in size there is a tendency for the surrounding tissue to become infiltrated. The central portions of the nodule tend to ulcerate, and these areas of ulceration may be covered over with crusts. The ulceration is naturally accompanied by serous secretion, and occasionally by some bleeding.

Histologically nearly all these growths have been put down as adenocarcinomata of the type usually developing from the small intestine. This is but natural, as they originate from remnants of the omphalomesenteric duct.

A g e . — In the cases which I have collected and in which the age was given, the youngest patient was thirty-seven, the oldest, seventy-six.

Under 40 years . . . . .	2 cases
Between 40 and 50 . . . . .	2 cases
"    50 and 60 . . . . .	7 cases
"    60 and 70 . . . . .	6 cases
"    70 and 80 . . . . .	5 cases
	22 cases

**S e x .** — Of 20 patients of whom I have records on this point, 9 were men and 11 women. This tends to show that the disease is equally prevalent in both sexes.

**T r e a t m e n t .** — This naturally consists in the wide removal of the umbilicus, care being taken not to spread the carcinoma cells into the surrounding healthy abdominal wall. The inner surface of the umbilicus should be carefully examined to see if adhesions exist, and then, after fresh abdominal dressings have been applied, a systematic inspection of the abdominal viscera should be made to exclude the possibility of carcinoma of the stomach, intestine, or pelvic organs. If no abdominal focus be found, and provided a wide removal of the growth has been possible, the prognosis is relatively good.

#### DETAILED REPORT OF CASES OF PRIMARY ADENOCARCINOMA OF THE UMBILICUS.

In the majority of the cases the umbilical tumors were undoubtedly primary, but in several it is not certain that they were not secondary to some intra-abdominal growth.

**A Primary Adenocarcinoma of the Umbilicus.** [?] — Ajello's\* patient was a woman, sixty-four years old, from whom an umbilical growth was removed. He gives a picture of the outer surface and also of the smooth peritoneal surface of the tumor.

Histologic examination showed a definite regular glandular growth. Ajello then discusses the literature.

**Primary Cancer of the Umbilicus.** — Besson† reports the case of a woman thirty-seven years of age. The patient's father had died of some pulmonary trouble, the mother of cancer. This woman, ten years before, on making an extra effort, had complained of intense pain at the umbilicus, and later noticed a small tumor developing in the umbilical cicatrix. It was the size of the last phalanx of the index-finger, and was hard in consistence. Elevation of the arms increased the sensitiveness at the umbilicus. The region was also somewhat painful at the menstrual period. The patient had been assured that the tumor was not reducible. It had increased in size quite slowly. According to the patient, during the last four months it had become painful and larger, and the skin had become violet in color. There had been some emaciation, associated with paleness. When the patient entered the hospital, the umbilical cicatrix formed a crescent with the concavity directed downward. Palpation showed that this elevation was produced by a solid tumor which was hard and about the size of a mandarin orange. The skin was not movable over the tumor, as it was adherent at the umbilical cicatrix. The tumor was removed, and the patient made a good recovery.

Histologic examination showed that it was composed of fibrous tissue and of a glandular growth similar to that developing from intestinal glands. When seen four years later, the patient was perfectly well. The growth was diagnosed as a cylindrical-cell carcinoma. It had developed at the umbilical cicatrix, and was covered with skin. It consisted of fibrous tissue and glands lined with cylindrical epithelium resembling that of the adult or embryonic Lieberkühn's glands. The epithelial cells had infiltrated into the stroma, and there was a tendency to invade the surrounding tissue.

\* Ajello: Contributo alla genesi embrionale di un adeno-epitelioma cistico primitivo dell'ombelico. (From Tansini's Clinic.) *La Riforma medica*, 1899, anno 15, iii, 663.

† Besson: Cancer de l'ombilic. *Thèse de Paris*, 1901, No. 263, 66.



**Primary Adenocarcinoma of the Umbilicus.**—Bonvoisin,\* after citing a case already described by Tillaux, reports a second also from Tillaux's service. The patient, a man sixty-four years of age, had the general appearance of a sick person. He had been ill for about two months. At the umbilicus was a brawny excrescence. There was no history of injury. When the nodule was first noticed it was the size of a small pea. In about fifteen days it commenced to ulcerate and the physician thought it was eczema. At the time of Tillaux's examination the umbilicus had disappeared and had been replaced by a shallow area of ulceration covered with a blackish crust surrounded by an area of inflammation several millimeters in diameter. The total zone of inflammation was the size of a five-franc piece and about 1 cm. broad. The mass was immobile vertically, but could be pushed from side to side. There was no enlargement of the axillary or inguinal glands.

The umbilicus was removed, but the patient died. Autopsy failed to reveal any peritonitis, and the peritoneal portion of the growth was free from adhesions. The stomach and intestines were normal. The growth was a primary adenocarcinoma of the umbilicus and had evidently originated from remains of a fetal structure. Ducellier made the microscopic examination in Prof. Cornil's laboratory.

**Primary Carcinoma of the Umbilicus.**—Dannenberg† reports the case of a day laborer, seventy-one years old, operated upon by Maas. For three months before admission he had complained of pain in the umbilicus, and now showed an umbilical tumor 3 cm. broad, 2.5 cm. long, and raised 5 mm. above the surface of the abdomen. There was a dark-red, funnel-shaped ulceration in the middle. The tumor was firm in consistence and the surrounding tissue was infiltrated. There was pain on contraction of the abdominal muscles, and swelling in the inguinal glands, more marked on the left than on the right side. The appetite was good. When the tumor was removed, the peritoneum was found perfectly free at the umbilicus. The patient made a good recovery.

Microscopically, solid nests were here and there visible, and at other points cavities lined with one layer of cylindric epithelium. The tumor was diagnosed as a scirrhus carcinoma, but from the description it would seem to have been an adenocarcinoma. [Although there are many points suggesting a primary growth in this case, in the absence of a most thorough abdominal examination it is impossible to say that it might not have been secondary.—T. S. C.]

§ **Primary Adenocarcinoma of the Umbilicus.**‡—At an autopsy on a man, fifty-four years of age, who had had tabes for eleven years, a tumor of the umbilicus was found, circular in form, about 7 or 8 cm. in diameter and 5 to 6 cm. thick. It lay in front of the aponeurosis, and had not encroached on the peritoneum. It was an adenocarcinoma. There was no evidence of metastases. This tumor was looked upon as a primary carcinoma of the umbilicus.

**Carcinoma of the Umbilicus.**—Demarquay's§ patient, fifty-four years of age, had a tumor the size of an egg at the umbilicus. She had had a congenital nevus at the umbilicus, and this had started to increase in size two years

\* Bonvoisin, G.: Étude pathogénique et histologique sur une variété de l'épithéliome de l'ombilic. Thèse de Paris, 1891, No. 305.

† Dannenberg, O.: Zur Casuistik der Nabeltumoren insbesondere des Carcinoma umbilicale. Inaug. Diss., Würzburg, 1886.

‡ Déjerine et Sollier: Bull. Soc. anat. de Par., 1888, 649.

§ Demarquay: Cancer de l'ombilic. Bull. Soc. de chir. de Par. (1870), 1871, 2. sér., xi, 209.

before her admission. The tumor had become excoriated, was painful, and there was a small amount of hemorrhage. Demarquay hesitated to operate on account of two small tumors in the inguinal region. These, however, were looked upon as papillomata of the inguinal glands, not malignant, but caused by irritation from the umbilical growth. The general health of the patient became poor, and a fatal issue seemed probable.

∧ Carcinoma of the Umbilicus (Primary or Secondary?).\*—The patient, a man of seventy-four years, complained of pain when the clothes came in contact with the umbilicus. Situated in the umbilicus was a reddish nodule the size of a pea, which was slightly blood-tinged. The tumor increased rapidly and reached the size of a two-franc piece. It was removed, and examination proved it to be an adenocarcinoma. There were no signs of any other growth.

§ Primary Adenocarcinoma of the Umbilicus.—Doederlein's† patient was a woman fifty-five years of age. Three months before admission she had first noticed a small, hard, painful tumor at the umbilicus. Four weeks before coming under observation the tumor had shown a small ulcer on its surface. The physician that saw her had diagnosed inflammation of the umbilicus, and ordered moist applications. The condition had become worse, and several other ulcers had developed around the umbilicus. When Doederlein saw her, the umbilicus was funnel-shaped and drawn in. The entire skin of the umbilicus was very thick, and the underlying parts were fixed. The surface was ulcerated, and there was a serous secretion. In the vicinity of the umbilicus were numerous dilated blood-vessels. Diffusely scattered, particularly toward the symphysis, were small hard nodules in the skin, the size of millet-seeds or linseeds. These on pressure were not painful. In both inguinal regions were hard packets of tumors the size of a goose's eggs. They were somewhat movable, and on pressure were not painful. Under anesthesia the umbilicus was widely removed. When the abdomen was opened, the peritoneum in the vicinity of the umbilicus was found to contain numerous small nodules. The umbilical tumor was removed, and the inguinal growths were dissected out. The patient died ten days later in collapse.

The portion of the abdominal wall removed was 20 by 12 by 4 cm., and the umbilical funnel was 2.5 cm. deep. The skin over the prominence of the umbilicus was somewhat stretched. On both sides of the umbilical depression were small superficial ulcers. These had irregular margins and somewhat reddened and dirty surfaces. In general the condition suggested that the depth of the umbilicus had consisted of small tumors which had pressed the skin forward and tended to break through. On palpation one could feel the nodules beneath the surface of the skin, and in the umbilical depression they merged with one another, forming a hard mass. A sharp outline between the skin and the tumor was macroscopically impossible.

On histologic examination the umbilical growth was found to be an adenocarcinoma; the enlargement in the inguinal glands was also due to carcinomatous involvement.

The liver contained about 20 irregular, small metastases on its surface. These varied from a millet-seed to a bean in size. There was also one on the anterior surface of the gall-bladder. The gall-bladder contained stones. In the visceral

\* Després: Bull. et Mém. Soc. de chir. de Par., 1883, ix, 245.

† Doederlein, F.: Ein primäres Adenokarzinom des Nabels. Inaug. Diss., Erlangen, 1907.

peritoneum were about 60 or 80 nodules. Doederlein came to the conclusion that the growth in the gall-bladder was a secondary one.

[From the evidence at hand it is impossible for us to determine whether the umbilical carcinoma was primary or secondary.—T. S. C.]

♁ **Primary Adenocarcinoma of the Umbilicus.**—Forgue and Riche\* report the case of a woman, aged fifty-six, who six months before coming under observation had noticed a reddish point at the umbilicus. At the time she was operated on it was the size of a five-franc piece and indurated, and for four months there had been a slight ulceration which emitted at times a bloody discharge. No abdominal tumor could be demonstrated at operation. The pelvis was empty; no enlarged glands could be detected. The tumor was removed, and on microscopic examination proved to be a typical adenocarcinoma. The glands in some places resembled those of Lieberkühn.

The patient was well twenty-two months after operation. This tumor would seem to have been a primary adenocarcinoma which had probably developed from remains of the omphalomesenteric duct.

♂ **Probable Primary Carcinoma of the Umbilicus.**†—The patient, a porter aged thirty-eight, had a papillary-like growth at the umbilicus from which there was bloody discharge. The growth varied from 10 to 15 mm. in diameter. The pictures given by Giordano are excellent. He thought he was dealing with a primary carcinoma of the umbilicus. He gives a short review of the literature.

**Primary Carcinoma of the Umbilicus.**—Guiselin‡ reports a case observed by Villar that had not yet been published. The woman was sixty-four years of age, a music teacher. Her father had died at seventy of cancer of the tongue. For five months she had noticed a small, painless enlargement at the umbilicus. The tumor had increased gradually in size and had become reddish in color during the two months before she was seen by Guiselin. On examination the umbilicus was found to be violet in color, and a tumor, the size of a hazelnut, occupied the umbilical depression. It presented bosses, was hard, adherent, and reducible. When the abdomen was opened, no tumor could be made out in the intestinal tract, stomach, liver, or genital organs.

Histologic examination showed the growth to be epithelial in character and of a cylindric type. It appeared to be a primary adenocarcinoma of the umbilicus.

**Adenocarcinoma of the Umbilicus.** [?] §—The woman, fifty-eight years of age, had a tumor the size of a small hazelnut at the umbilicus. This was very soft and reddish gray in color. Microscopic examination showed gland-spaces surrounded with loose connective tissue. The epithelium in some places was one and in others several layers in thickness. There were also “Schichtungsperlen,” but a real hornification did not exist. In other places there was a definite malignant growth of the glands. Hertz says that, although the growth was malignant, it must have developed from the epithelium of the intestine or of the omphalo-

\* Forgue et Riche: Montpellier méd., 1907, 2. s., xxiv, 145-169.

† Giordano, D.: Sopra un caso di cancro dell' ombelico. La Medicina Italiana, 1911, ix, 6.

‡ Guiselin: Du cancer de l'ombilic. Thèse de Bordeaux, 1906, No. 47.

§ Hertz: Ueber einen Fall von Adenocarcinom des Nabels bei einer 58-Jährigen Frau. Inaug. Diss., Würzburg, 1905.

mesenteric duct. [The growth strongly suggests an umbilical tumor containing uterine glands.—T. S. C.]

**Carcinoma of the Umbilicus.\***—The patient was fifty-one years old. A small tumor had developed at the umbilicus a few months after she had received a blow. Microscopic examination showed that it was a cylindric-cell carcinoma.

**Probable Primary Cancer of the Umbilicus.†**—The patient, a soldier forty-five years of age, had a nodule at the umbilicus. This was opened and was thought to contain pus, although there was only a slight discharge. It became fungating, and grew as large as a fist. There was bladder involvement. Whether the growth was primary or not was uncertain.

Microscopic examination showed that it was a carcinoma, apparently of the adenocarcinomatous type. Autopsy revealed no growth in the intestine or stomach.

The fungating process was probably hastened as a result of the cutting; consequently I omit any description of the umbilicus.

**Adenocarcinoma of the Umbilicus.—**Ippolito‡ gives a brief review of the literature and then reports the case of a woman fifty-one years of age. An umbilical growth was removed, which microscopically proved to be an adenocarcinoma of the intestinal type. Ippolito thought it was primary, but there is no note made of any careful abdominal examination. [Possibly it was a secondary growth.—T. S. C.]

**Probable Adenocarcinoma of the Umbilicus.§**—The tumor was removed by Professor Witzel; it was the size of a walnut. The peritoneum was intact. The tumor on section was hard, firm, and appeared to be encapsulated in fibrous tissue. On microscopic examination it proved to be an adenocarcinoma of the type resembling that usually found developing in the stomach. Examination of the patient did not give any evidence of cancer in the abdomen. This was probably a primary growth.

**A Malignant Tumor in an Umbilical Hernial Sac.||**—The patient was sixty-seven years of age and had had an umbilical hernia for fifteen years. No truss had been used, but the hernia had been reduced without difficulty until a year before. Pain in the umbilicus increased rapidly and radiated to the stomach and the pelvic region. The patient lost flesh and strength and had frequent vomiting, with constipation and diarrhea.

On examination a hard, nodulated, bluish-red tumor was found at the umbilicus. Its surface was slightly ulcerated. The sac contained omentum, which was not diseased, and also subperitoneal tissue infiltrated as far as a finger could reach. The growth was removed, but the patient died of shock six hours later. Microscopic examination showed a malignant growth, which the author thought was a sarcoma connected with Lieberkühn's glands, although he questioned whether or not it might represent remains of the omphalomesenteric duct. The case is not very clear, but the tumor was evidently malignant.

\* Heurtaux: Epithéliome de l'ombilic. *Gaz. méd. de Nantes*, 1886, iv, 46.

† Hue et Jacquin: Cancer colloïde de la l'ombilic et de paroi abdominale antérieure ayant envahi la vessie. *L'Union méd.*, 1868, 3. sér., vi, 418.

‡ Ippolito: Un caso d'epitelioma dell'ombelico. *Gazz. Internaz. di med.*, 1901, iv, 302.

§ Jores: Cylinder-Epithelkrebs des Nabels. *Vereins-Beilage der Deutsch. med. Wochenschr.*, 1899, xxv, 22.

|| Lewis: *Med. Record*, 1889, xxxvi, 394.

**Cylindric-cell Carcinoma of the Umbilicus.\***—The specimen was from a man sixty-five years of age. For two months before admission he had complained of pain in the lumbar region. He had not noticed the umbilical nodule until it was pointed out to him by the doctor. A small projection the size of a pea was readily seen and felt in the pit of the umbilicus. On deep palpation it appeared to be larger. It was removed through an elliptic incision. The peritoneal surface was puckered. On section, the tumor presented a solid appearance.

Microscopic examination showed a cylindric-cell carcinoma. Maylard suggested that it had developed from the omphalomesenteric duct. Macewen, in the discussion at the Glasgow Path. and Clin. Society, before which this case was reported, said he had seen two similar cases, but when brought to him both patients already had advanced peritoneal disease. Each of the umbilical growths was considered primary. In one case pain in the back was thought to be due to the involvement of the liver, as found at autopsy.

**Primary Carcinoma of the Umbilicus.†**—A woman, seventy-six years of age, had a malignant growth at the umbilicus. The disease gradually progressed and she died. At autopsy the feasibility of an operation for the removal of the mass forcibly impressed itself on Parker. The growth was evidently primary.

**Primary Carcinoma of the Umbilicus.‡**—Case 76.—Volkman removed from a man, seventy-four years of age, a squamous-cell carcinoma the size of a hen's egg from the umbilicus. The omentum was already degenerated with carcinomatous nodules, and death followed five months later with abdominal carcinoma and ascites. The growth was not glandular.

**Primary Carcinoma of the Umbilicus.§**—Case 78.—A forger, seventy-two years of age, came to Volkman suffering from an ulceration at the umbilicus the size of a two-mark piece, which had first begun some five or six years previously. Here and there it was covered with hard crusts. The condition strongly suggested a rodent ulcer. On microscopic examination it proved to be a slowly growing, relatively benign, carcinoma. The slightly thickened walls of the ulcer were excised, the abscess was curetted out and freely cauterized, and a plaster laid over it. The wound healed speedily, and the man had no return of the growth, but died of pneumonia four or five years later. Examination of the tumor showed no evidence of a horny layer or of nests of cells resembling those of the rete Malpighii. Here and there was a definite tendency toward gland formation.

[It is quite possible that in this case there were remains of the omphalomesenteric duct at the umbilicus, as seen in Fox and MacLeod's case, which they diagnosed as Paget's disease of the umbilicus (see p. 268).—T. S. C.]

**Adenocarcinoma of the Umbilicus.||**—The patient, sixty-eight years of age, for nearly a year had complained of discomfort just above the umbilicus, which was continuous and independent of digestion. At the umbilicus was an indurated area, the size of a pigeon's egg. When seen at operation, it was

\* Maylard: Trans. Glasgow Path. and Clin. Soc., 1886-91; 1892, iii, 294.

† Parker: Excision of Umbilicus for Malignant Diseases. Arch. Clin. Surg., New York, 1876-77, i, 71.

‡ Pernice, L.: Die Nabelgeschwülste, Halle, 1892.

§ Pernice, L.: Op. cit.

|| Stori: Contributo allo studio dei tumori dell'ombelico. Lo Sperimentale, Arch. di biologia normale e patologia, 1900, liv, 25.

ovoid in form, 6 cm. in its longest diameter, and 4 cm. broad. It seemed to be a primary tumor of the abdominal wall. It was removed, and the patient died of peritonitis. Microscopic examination showed that the growth was an adenocarcinoma.

[Whether this was primary or secondary is uncertain.—T. S. C.]

**Carcinoma of the Umbilicus Developing in the Depth of an Umbilical Diverticulum.\***—The patient, a woman forty years of age, entered the hospital for an umbilical tumor. In childhood she had had no serious diseases. Seven months previously, while bathing, she had noticed a small crust at the umbilicus. This she had removed, and had seen a small, dark-red tumor the size of a lentil. There was no ulceration and no discharge. It had increased steadily in size and had been cauterized, but had reappeared as a small but rapidly growing tumor. At the end of three weeks it had ulcerated, and there had been slight hemorrhages. On admission the entire umbilicus was found transformed into a tumor about the size of a ten-centime piece. It was circular and bulging. It was dark red, ulcerated, and cup-shaped over an area the size of a five-centime piece. The surrounding tissue was indurated. No axillary or inguinal gland enlargement was noted. The patient was in good condition and had no indigestion. An extensive removal was made. The omentum was not adherent, and no abdominal lesion was noted. Recovery followed.

Cornil made the following report: "The tumor consists of a cylindric-cell epithelioma. The epithelioma is analogous to that which develops primarily in the intestinal glands." [Of course, the length of time—about four months—was too short to warrant a final prognosis.—T. S. C.]

**Carcinoma of the Umbilicus.†**—A woman, aged forty, who had had 12 children, two years previously had noticed two pea-sized bodies in the skin on the left side of the umbilicus, which had grown gradually for eighteen months. Blisters had formed and broken, discharging a foul-smelling pus. On admission the tumor was  $4\frac{1}{2}$  inches in its longest diameter and 11 inches in circumference; it was lobulated and had a dirty, ulcerated surface, covered with a foul-smelling discharge. No other local manifestations were detected. The growth was removed in 1816 and the patient recovered. Naturally, at that time there was no microscopic examination.

[The duration is strongly indicative that this growth was primary, in view of the fact that, when the umbilical growth is secondary, the primary tumor usually causes death in the course of five or six months.—T. S. C.]

**A Supposed Submalignant Adenocarcinoma of the Umbilicus.**—From the history this growth seems to have been primary. Its situation and relation would suggest its origin from the urachus, but Koslowski says that the glands in it were of the intestinal type. It is probable that it had developed from extraperitoneal remnants of the omphalomesenteric duct. As it does not resemble any case heretofore described, I have allotted it a separate place.

Koslowski's‡ patient was operated upon in October, 1902. Five weeks before, he had noticed, in the mid-line, between the symphysis and umbilicus, a small

\* Tillaux and Barraud: Epithélioma de l'ombilic, développé aux dépens d'un diverticule intestinal; omphaléctomie, guérison. *Annales de Gyn.*, Paris, 1887, xxvii, 401.

† Wagner: Abtragung eines carcinomatösentarteten Nabels. *Med. Jahrb. d. k. k. öster. Staates*, Wien, 1839, n. F., xviii, 585-589.

‡ Koslowski: Ein Fall von wahren Nabeladenom. *Deutsche Zeitschr. f. Chir.*, 1903, lxi, 469.

painful tumor which grew to the size of a walnut. The abdominal pain radiated. On examination the man, although only fifty-five years old, was markedly emaciated and looked as if he were about seventy. He had had frequent diarrhea. He was bent over as if guarding the abdominal muscles. Between the umbilicus and the symphysis, near the mid-line, was a tumor reminding one of a patella. The overlying skin was free. The tumor was very painful and slightly movable. It felt dense and gradually merged into the surrounding tissue. Toward the umbilicus was a cord the size of a goose-quill. The growth was thought to be a malignant epithelial tumor of the urachus.

A median incision showed that the tumor had grown through the linea alba and the sheath of the rectus. A portion of the rectus muscle, of the transversalis fascia, and of the peritoneum were removed. After the abdomen had been opened and the tumor had been drawn up, fibrous cords were seen passing from the umbilicus. The upper one was the size of a goose-quill, firm and infiltrated; the lower contained a venous cord, was less firm, and passed into the vesico-umbilical ligament. The peritoneum covering the posterior surface of the tumor showed evidence of scarring and of ulceration. The patient made a good recovery.

The tumor in form, as mentioned above, resembled a patella. The peritoneum was firmly attached to it, and the surrounding muscle had been penetrated by it. On microscopic examination the growth was found to be made up of glands varying in size between that of a urinary tubule and that of a gland large enough to be seen with the naked eye. The diagnosis was fibro-adenocarcinoma submalignum. The glands resembled those of the intestinal type.

#### LITERATURE CONSULTED ON PRIMARY CARCINOMA OF THE UMBILICUS.

- Ajello: Contributo alla genesi embrionale di un adeno-epitelioma cistico primitivo dell'ombelico (from Tansini's clinic). *La Riforma medica*, 1899, Anno 15, iii, 663.
- Besson, E.: Cancer de l'ombilic. Thèse de Paris, 1901, No. 263.
- Bonvoisin, G.: Étude pathogénique et histologique sur une variété de l'épithéliome de l'ombilic. Thèse de Paris, 1891, No. 305.
- Burkhardt, O.: Ueber den Nabelkrebs. Inaug. Diss., Berlin, 1889.
- Chuquet: Du carcinome généralisé du péritoine. Thèse de Paris, 1879, No. 548.
- Dannenberg, O.: Zur Casuistik der Nabeltumoren insbesondere des Carcinoma umbilicale. Inaug. Diss., Würzburg, 1886.
- Déjerine et Sollier: *Bull. Soc. anat. de Paris*, 1888, 649.
- Demarquay: Cancer de l'ombilic. *Bull. Soc. de Chir. de Par.* (1870), 1871, 2. s. xi, 209.
- Després: *Bull. et Mém. Soc. de chir. de Paris*, 1883, ix, 245.
- Doederlein, F.: Ein primäres Adenokarzinom des Nabels. Inaug. Diss., Erlangen, 1907.
- Fox and MacLeod: A Case of Paget's Disease of the Umbilicus. *Brit. Jour. Dermatol.*, 1904, xvi, 41.
- Forgue et Riche: *Montpellier méd.*, 1907, 2. s., xxiv, 145-169.
- Feulard: Fistule ombilicale et cancer de l'estomac. *Arch. gén. de méd.*, 1887, 7. sér., xx, 158.
- Giordano, D.: Sopra un caso di canero dell'ombilico. *La Medicina Italiana*, 1911, ix, 6.
- Guiselin, É. J. M. J.: Du cancer de l'ombilic. Thèse de Bordeaux, 1906, No. 47.
- Hertz, W. H.: Über einen Fall von Adenocarcinom des Nabels bei einer 58-Jährigen Frau. Inaug. Diss., Würzburg, 1905.
- Heurtaux: Epithéliome de l'ombilic. *Gaz. méd. de Nantes*, 1886, iv, 46.
- Hue et Jacquin: Cancer colloïde de l'ombilic et de la paroi abdominale antérieure ayant envahi la vessie. *L'Union médicale*, 1868, 3. sér., vi, 418.

- Ippolito, G.: Un caso epitelioma dell'ombelico. *Gaz. internaz. di med.*, 1901, iv, 302.
- Jores: Cylinder-Epithelkrebs des Nabels. *Vereins-Beilage der Deutsch. med. Wochenschr.*, 1899, xxv, iv, 22.
- Koslowski: Ein Fall von wahrem Nabeladenom. *Deutsche Zeitschr. f. Chir.*, 1903, lxi, 469.
- Ledderhose, G.: *Deutsche Chirurgie*, 1890, Lief. 45 b.
- Lewis, D.: A Malignant Tumor in an Umbilical Hernial Sac. *Medical Record*, 1889, xxxvi, 394.
- Le Coniac, H. C. J.: Cancer secondaire de l'ombilic, consécutif aux tumeurs malignes de l'appareil utéro-ovarien. *Thèse de Bordeaux*, 1898, No. 19.
- Maylard: Cylinder-celled Epithelioma of the Umbilicus. *Trans. Glasg. Path. and Clin. Soc.*, 1886-91; 1892, iii, 294.
- Morris, R.: Malignant Disease of the Navel as a Secondary Complication. *Verhandl. d. 10. Internat. Med. Cong.*, 1890, Berlin, 1891, iii. Abth., vii, 122-126.
- Neveu, v.: Contribution a l'étude des tumeurs malignes secondaires de l'ombilic. *Paris*, 1890.
- Osler, Sir William: Lectures on the Diagnosis of Abdominal Tumors. *New York Med. Jour.*, 1894, lix; lx.
- Parker, W.: Excision of Umbilicus for Malignant Disease. *Arch. Clin. Surg.*, New York, 1876-77, i, 71.
- Pernice, L.: *Die Nabelgeschwülste*, Halle, 1892.
- Quénu et Longuet: Du Cancer secondaire de l'ombilic. *Revue de Chir.*, 1896, xvi, 97.
- Sollier, Paul Henri: See Déjerine.
- Stori, T.: Contributo allo studio dei tumori dell'ombelico. *Lo Sperimentale, Archivio di biologia normale e patologia*, 1900, liv, 25.
- Tillaux and Barraud: Epithélioma de l'ombilic, développé aux dépens d'un diverticule intestinal; omphalectomie; guérison. *Ann. de Gyn.*, Paris, 1887, xxvii, 401.
- Villar, F.: Tumeurs de l'ombilic. *Thèse de Paris*, 1886.
- Wagner: Abtragung eines carcinomatös entarteten Nabels. *Med. Jahrb. d. k. k. öster. Staates*, Wien, 1839, N. F., xviii, 585-589.

#### CARCINOMA OF THE UMBILICUS SECONDARY TO CARCINOMA OF THE STOMACH.

In 27 cases we have found fairly conclusive evidence that the umbilical growth was secondary to carcinoma of the stomach.

*A g e*. — In 23 of these we have definite data as to the age of the patient. The youngest patient was twenty-six, the oldest seventy-two, years of age.

26 years old . . . . .	1 case
Between 30 and 40 . . . . .	1 "
" 40 and 50 . . . . .	4 cases
" 50 and 60 . . . . .	10 "
" 60 and 70 . . . . .	5 "
" 70 and 80 . . . . .	2 "

From the above it will be seen that the age distribution corresponds to that in which carcinoma of the stomach is usually found.

*S e x*. — Of the 27 cases, data as to the sex are given in 23. Ten of the patients were men and 13 were women, indicating that men are nearly equally liable to this affection.

*T r a u m a*. — Occasionally, as in the cases reported by Attimont, Burkhart, and Wulckow, and in my own Case G., the patient attributed the umbilical lesion to an injury. Attimont's patient dated her symptoms from the time she had hurt her abdomen on the edge of a tub. Burkhart's patient noticed an umbilical nodule four months after her abdomen had been accidentally and forcibly compressed; Wulckow's patient, as he was going home on a dark night, struck his abdomen against a stony projection and complained from that time on. My patient, shortly



before the umbilical growth was noticed, had been struck in his umbilical region by a boot, which was probably not unusual for him, as he kept a shoe-store.

**G a s t r i c S y m p t o m s .**— In about two-thirds of the cases symptoms suggestive of deranged digestion were noted. In some there was loss of appetite, in others indigestion accompanied by more or less epigastric pain; some vomited food, and in one case at least the vomitus contained blood.

A deep-seated tumor in the pyloric region was detected in several cases, and the condition was so clear that the physician diagnosed cancer of the stomach. In a few cases a definite enlargement of the liver was found, and in several instances the abdomen contained ascitic fluid. Quite a number of the patients, however, gave no gastric symptoms whatsoever, but felt weak and looked cachectic. In at least one case (Valette's) there was not the slightest evidence at operation of any other abdominal lesion. It will be noted that the umbilical growth was the size of a 50-centime piece, and that its central portion was ulcerated, and, moreover, that it was firmly fixed. During removal of the tumor the abdomen was inspected and small peritoneal metastases were found. The stomach, however, appeared to be normal. The patient died on the eighth day, and at autopsy a primary carcinoma was found in the stomach.

The umbilical nodule, when first noted, may not be larger than a grain of wheat. In the course of a few months it has increased in some cases to the size of a small nut, in others to that of a chestnut. Sometimes it is first noted in the umbilical depression; in other instances in the umbilical wall or in the tissues immediately adjacent to the umbilicus. At first these tumors may be sharply circumscribed, the overlying skin being free. But with the growth of the nodule the skin soon becomes adherent and the tumor may show a bluish-violet or brownish-red discoloration. The more prominent portions of the tumor tend to become ulcerated, and may discharge a serous or purulent fluid or be covered with crusts. In a few instances there have been several small hemorrhages from them. With the continued growth of the nodule the central portion may be deeply ulcerated, and surrounding the ulcer papillary or cauliflower-like masses may form and the nearby skin show considerable infiltration, frequently of an inflammatory character.

In Cannuet's case there was a small umbilical hernia. This contained incarcerated omentum, in which was found a carcinomatous nodule. In a case which I have recently seen (Plate V) the patient had had an umbilical hernia for thirty-two years. A few months before coming under my care the hernial mass had become hard, and on palpation definite firm nodules could be felt scattered throughout it. At operation I found an ovarian tumor, general peritoneal carcinosis, and a markedly thickened omentum. The portion of the omentum incarcerated in the umbilical hernia also contained carcinomatous nodules. The primary growth in this case was apparently in the ovary.

There is another group of cases presenting a totally different picture. The umbilicus may or may not be the seat of a nodule, but a slight tumefaction of the region is noted. The swelling increases in amount and abscess is suspected. In some cases the picture is that of an acute phlegmon. On the supposition that the condition was inflammatory, several of the tumors were opened. The incision in some yielded nothing but blood and serous fluid; in others small foci of pus were found. In a short time the supposed inflammatory area would undergo gradual dissolution or necrosis *en masse*, and a fungating base be left at the site of the

umbilicus. A little later gas-bubbles would be noted, and ere long stomach-contents would commence to pass through the fistulous opening. The margins of the fistulous opening in some cases were surrounded by large papillary or fungoid growths. In these cases the carcinoma had not extended to the umbilicus by way of the suspensory ligament, but by direct continuity. The carcinoma of the stomach had become adherent to the abdominal wall at or near the umbilicus, and by direct extension had caused a gradual disintegration until the surface of the abdomen had been reached.

If the carcinoma is situated at or near the pylorus and becomes adherent to the abdominal wall, it is only natural that the attachment should be in the umbilical region. If the disease, however, be in another part of the stomach, the abdominal wall may be attacked at another point, as was well shown in the following case:

Mrs. B., seen in consultation with Dr. Edwin B. Fenby July 8, 1910. This patient had been seized that evening with sudden abdominal pain about an inch and a half above and to the left of the umbilicus. She had a temperature of 100° F.; pulse, 116. When I saw her, she was rather pale. Appendicitis was ruled out, but some malignant growth was suspected. She had a leukocytosis of 15,000. She was at once removed to the hospital for observation. Ten days later we made an incision through the left rectus, and on cutting down to the fascia found some edema. On going into the peritoneal cavity we found that the stomach had become adherent to the anterior abdominal wall. After adhesions had been liberated, the parts were walled off as thoroughly as possible, and a tract 3 mm. in diameter was found passing from the stomach directly to the abdominal wall. In other words, there was a perforation of the stomach at this point. We gradually loosened the organs from the surrounding indurated tissue, which in some places was fully 2 cm. thick and as hard as gristle. The stomach was brought out and was found to be indurated in every direction. The growth was a carcinoma. The area of induration in the anterior wall was 7 by 5 cm., and just beneath the point of perforation there was a punched-out area in the carcinoma 2 cm. long. It was at the thinnest point of this that the perforation had taken place. We removed about half of the stomach. The patient made a very satisfactory recovery, and for a year there were no definite signs of a return of the growth. These, however, developed later and she died on November 12, 1911.

In those cases in which the disease reaches the umbilicus by way of the suspensory ligament the peritoneal surface of the umbilicus is usually smooth, because the lymphatics are extraperitoneal. On section an intact carcinomatous nodule of the umbilicus does not resemble cancer, but we find what looks like a diffuse fibrous thickening, and one can hardly realize that it is fairly riddled with glands. This fibrous appearance is well seen in Fig. 184, B (p. 424), and Fig. 190 (p. 443). Where ulceration exists, however, the true character of the growth is more manifest. On histologic examination the tumor is found to consist of fibrous tissue with myriads of carcinomatous glands scattered throughout it. The gland type is identical with that found in the original gastric tumor, and where ulceration has occurred, the usual picture of gland disintegration, together with polymorphonuclear leukocytes and small-round-cell infiltration, is noted on the surface.

**Treatment.**— If a patient has given definite signs of carcinoma of the stomach, by the time an umbilical nodule has developed the malignant process has become so wide-spread that operative interference is of no avail. In those cases in

which the cancer has extended to the abdominal wall by continuity and has broken down, causing a gastro-umbilical fistula, operation is out of the question.

There are a certain number of cases, however, in which, even when a secondary abdominal nodule exists, gastric symptoms are lacking. Here the surgeon will naturally remove the umbilical growth in the hope that it may be a primary lesion. In all such cases, when the abdomen is opened, a careful survey of the stomach and abdominal contents should be made to determine if any visceral carcinoma exists.

**Prognosis.** — Where an umbilical carcinoma is secondary to carcinoma of the stomach, practically all the patients speedily succumb.

#### CASES OF CARCINOMA OF THE UMBILICUS SECONDARY TO CANCER OF THE STOMACH.

In the majority of the cases here detailed the diagnosis is certain, as proved at operation or at autopsy. In a few of the cases such absolute proof was wanting, but the clinical picture strongly suggested the stomach as the source of the primary tumor.

**Carcinoma of the Umbilicus Secondary to Carcinoma of the Stomach.** — Attimont's\* patient was a woman fifty-three years of age. She had enjoyed good health until three months before he saw her, and dated her gastric symptoms from the time she hit her abdomen on the edge of a tub. On palpation no internal tumor could be found, but at the umbilicus were two small nodules the size of grains of wheat. At the end of two months the patient returned emaciated. The nodules at the umbilicus had increased in size, one being as large as a small walnut. It was hard, and the overlying skin was adherent. The umbilical mass was removed and proved to be an adenocarcinoma.

Autopsy at a later date showed carcinoma of the lesser curvature of the stomach, with secondary nodules on the surface of the liver and uterus and cancerous masses between the folds of the suspensory ligament.

**Cancer of the Stomach; Gastro-abdominal Fistula.** † — A woman, forty-nine years of age, complained of epigastric pain, difficult digestion, and frequent vomiting. Blood had never been noted in the vomited material or in the stools. On palpation an ill-defined tumor was found in the epigastric region which was painful on pressure. Cancer of the stomach was diagnosed. Some time after the patient entered the hospital she had fever at night. The tumor rapidly increased in size. The abdominal wall became a little red, was painful on pressure, and fluctuation was detected. On making an opening with the bistoury odorless pus escaped. A sound could be passed inward for 5 or 6 cm. The fever disappeared and the patient ate without vomiting or pain. A month later the skin around the incision was thinner, reddened, and an area of ulceration the size of a five-franc piece existed. In the depression were fungoid masses which gave off a fecal odor. Two weeks later all trace of the umbilicus had disappeared and there was an area of ulceration as large as the palm of the hand, and three fungoid masses, forming a tumor the size of a fist, presented. The discharge was so fetid that the patient was isolated. Gas and particles of stomach-contents escaped. The mushroom growths increased rapidly and broke down easily. Hemorrhages

\* Attimont, A.: *Remarques sur le cancer de l'ombilic.* *Gaz. méd. de Nantes*, 1887-88, vi, 137; 149.

† Auger, M. G.: *Cancer de l'estomac fistule gastro-abdominale.* *Bull. Soc. anat. de Paris*, 1875, i, 708.

resulted, which were controlled with difficulty. The patient became very cachectic, and died two weeks later.

At autopsy the abdomen contained clear yellow fluid. The intestines were small in caliber, but not adherent. The anterior part of the stomach was adherent to the ulcerated abdominal wall. The opening was near the pylorus; the area round it was hard and infiltrated. The subcutaneous abdominal tissue was necrotic. The right lobe of the liver contained cancerous masses. In this case the carcinoma of the stomach had become adherent to the umbilicus and the opening between the stomach and the umbilicus had resulted.

*Carcinoma of the Stomach with Perforation of the Abdominal Wall.* \*—The patient was a weakly woman, fifty-two years of age, and the mother of 17 children. In the spring she had complained of pain in the abdomen, and in July had had to give up work. She was very anemic and wasted. In August she had had severe colicky pains in the region of the spleen; in September these had migrated to the umbilical region. At this time there could be felt a tumor the size of a fist deep in that region. The tumor descended until it lay behind the umbilicus, forming a mass about 5 inches in diameter, with the umbilicus in the center. It became softer, and a few days later a small area sloughed, and the stomach-contents escaped. The opening rapidly increased in size and the patient soon died. The growth was a carcinoma of the stomach which had opened near the umbilicus.

*Carcinoma of the Umbilicus Probably Secondary to Carcinoma of the Stomach.* †—A delicate, poorly nourished woman, fifty-nine years of age, entered Bergmann's clinic. Some time before, her abdomen had been accidentally compressed, and four months later she had noticed a painless but hard nodule at the umbilicus. The skin covering it was smooth. Three months later the tumor was the size of a hazel-nut. On examination the umbilicus was elevated. The tumor was the size of a two-mark piece and could be sharply outlined. The surface was very red and nodular, and suggested dense granulation tissue. It secreted pus. Operation was not advised, but was insisted upon by the patient. She left the hospital before any local return had occurred. The growth was a glandular carcinoma and probably secondary to carcinoma of the stomach.

*Carcinoma of the Umbilicus Secondary to Carcinoma of the Stomach.* ‡—A farmer, aged seventy-two, for six months had been complaining of gastric disturbances. Ten weeks before coming under observation he had noticed a moistness at the umbilicus and a discharge of a tarry-looking, brownish secretion. Later there had been ulceration, which had gradually increased. The patient was well nourished and strong. At the umbilicus was an irregular ulceration the size of a two-mark piece. It was hard and seemed unattached. At operation it was necessary to remove the ligamentum teres to the liver. The patient died one month after. A carcinoma the size of a three-mark piece was found near the pylorus; it was adherent to the liver, and in the liver diffuse carcinomatous infiltration was present.

\* Balluff: Magenkrebs, Erweichung und Aufbruch desselben durch die allgemeinen Bauchdecken, Magenfistel. Correspondenzbl. des Württemberg. ärztl. Vereins, Stuttgart, 1854, xxiv, 37.

† Burkhart: Ueber den Nabelkrebs. Inaug. Diss., Berlin, 1889.

‡ Burkhart: Op. cit.

Carcinoma of the Liver with Carcinoma of the Omentum; Incarcerated Umbilical Hernia.—Cannuet\* reported the case of a patient with carcinoma of the liver probably secondary to carcinoma of the stomach. There was an umbilical hernia containing incarcerated omentum, and in this incarcerated omentum was a cancerous nodule.

Carcinoma of the Umbilicus Secondary to Carcinoma of the Stomach. †—A man, sixty-three years of age, had had pain in the abdomen, complained of indigestion, and later had noticed a tumefaction at the umbilicus. He had diarrhea and vomiting and a supposed abscess of the abdominal wall. This was opened and bloody fluid escaped. Later there was the characteristic fetid cancerous discharge from the umbilicus. At autopsy a carcinoma of the pylorus was found adherent to the umbilical tumor.

Carcinoma of the Umbilicus Secondary to Cancer of the Stomach. ‡—In a woman, twenty-six years of age, a fistula developed at the umbilicus. There was no vomiting, but emaciation. Just above the umbilical cicatrix was a reddening. The skin was distended, hot, and painful and serous or purulent fluid escaped from the opening. At autopsy cancer of the pyloric region was found. On the outer surface of the pylorus were cancerous vegetations. These had become adherent to the abdominal wall; suppuration had followed, and an opening had developed at the umbilicus.

Carcinoma of the Umbilicus Secondary to Cancer of the Stomach.—Fischer§ operated on a woman fifty-two years of age who had a carcinomatous tumor of the umbilicus which had extended as far as the interior of the abdomen. On opening the abdomen he discovered that the anterior part of the stomach was perforated and transformed into a large carcinomatous ulcer, which penetrated directly into the transverse colon. The patient had never manifested any gastric symptoms. Fischer removed the entire anterior portion of the stomach and the diseased colon. The patient made a good recovery, but developed other stomach symptoms and died five months later.

Carcinoma of the Umbilicus, Secondary. ||—A woman, fifty years of age, had had a warty, nodular growth at the umbilicus for two or three months and was not in good health. No abdominal lesions being noted, Hutchinson made an elliptic incision and removed the growth. It extended to but had not invaded the peritoneum. Two months later there was a nodular thickening of the liver, great irritability of the stomach, and the patient died four months after operation. Hutchinson thought that the umbilical growth was secondary to that in the liver. In two other of his cases, he says, a carcinoma of the umbilicus had developed secondarily to a growth in the liver.

[Of course, the majority of the cases of cancer of the liver are secondary to those of the stomach.—T. S. C.]

Carcinoma of the Umbilicus Secondary to Cancer of the Stomach. \*\*—A man, forty-four years of age, gave a history of vom-

\* Cannuet: Bull. Soc. anat. de Paris, 1852, xxvii, 274.

† Codet de Boisse: Tumeurs de l'ombilic chez l'adulte. Thèse de Paris, 1883, No. 311.

‡ Feulard: Fistule ombilicale et cancer de l'estomac. Arch. gén. de méd., 1887, 7. s., xx, 158.

§ Fischer (Breslau): Résection de l'estomac. La Semaine méd., Paris, 1888, viii, 134.

|| Hutchinson, Jonathan: Arch. of Surgery, 1893, iv, 153 (1 pl.).

\*\* Largeau, R.: Cancer de l'ombilic. Bull. Soc. anat. de Par., 1884, lix, 210-212.

iting and loss in weight. At the umbilicus was a tumor 5 cm. in diameter. Its central portion was ulcerated and surrounded by a zone of induration. At death the growth was found extending to the peritoneal surface, but there was no adhesions. The patient had cancer of the stomach, which had extended to the liver. There were numerous other secondary nodules.

**Carcinoma of the Umbilicus Probably Secondary to Cancer of the Stomach or Liver.**—Ledderhose,\* after giving a survey of the literature, reports a case communicated to him by A. Cahn. L., fifty-eight years of age, complained of gradually increasing lack of appetite and of the development, a few months later, of edema of the lower extremities and varicose veins in the leg. Still later the scrotum and the abdominal wall became edematous and there was also ascites with complete loss of appetite and intestinal obstruction. At the umbilicus was a hard, semicircular nodule. By deep ballottement, enlargement of the hardened liver could be made out. A provisional diagnosis of carcinoma of the liver with peritonitis was made. No microscopic examination is given. In all probability the umbilical growth was secondary to a carcinoma of the stomach with implication of the liver. Ledderhose follows this by two other observations; in none of the cases, however, was any autopsy made.

**Carcinoma of the Umbilicus Secondary to Carcinoma of the Stomach.** †—A man, forty-five years of age, gave a history of vomiting for a year. He was well nourished and of good color, but had lost 24 pounds. At the upper and left side of the umbilicus was a small tumor the size of a bean; the overlying skin was free. In two weeks the tumor had become adherent to the skin and had increased in size. Two months later the abdomen was distended with ascitic fluid, and the patient died soon after the fluid had been removed.

Autopsy showed carcinoma of the lesser curvature of the stomach and compression of the portal vein; no involvement of the liver was found. No microscopic examination of the abdominal tumor is recorded.

**Umbilical Fistula Due to Latent Cancer of the Stomach.**—Monod's‡ patient was a woman sixty-six years of age. She was cachetic, but had had no vomiting. At the umbilicus was a fistulous opening of recent date. A diagnosis of latent cancer of the stomach was made. At autopsy in the region of the umbilicus Monod found a compact mass consisting of the stomach, liver, transverse colon, and duodenum. The lesser curvature of the stomach was adherent to the liver. The anterior surface of the stomach was involved in the cancer, which extended to the posterior surface; the fistulous opening reached the umbilicus. The transverse colon communicated by an oblique opening, measuring 5 x 6 cm., with a pocket formed by the stomach and the left lobe of the liver.

**Cancer of the Umbilicus Secondary to Cancer of the Pylorus.** §—A woman, seventy years of age, came with a diagnosis of cancer of the pylorus. Six months from the beginning of her symptoms she had begun to have pain at the umbilicus and noticed a small lump there. This became very

\* Ledderhose: *Chirurgische Erkrankungen des Nabels*. Deutsche Chirurgie, 1890, Lief. 45 b.

† Mirallié: Reported by Attimont.

‡ Monod: *Fistule Ombilicale; cancer latent de l'estomac*. Bull. Soc. anat. de Paris, 1877, lii, 38.

§ Morris, Robert: *Lectures on Appendicitis and Notes on Other Subjects*, 1895, 95.

hard, was about as large as a chestnut, bluish red in color, and had a smooth surface, which was somewhat ulcerated and discharged a little straw-colored serum. Morris removed the diseased umbilicus and found that it was not in contact with anything but normal structures. The patient died two months later with the ordinary symptoms of cancer of the pylorus. No autopsy, however, was permitted. The umbilical growth was an adenocarcinoma.

**Cancer of the Pylorus; Secondary Growth at the Umbilicus.**—Morris\* cites an extract from a letter from Dr. Grinnell, of Burlington, Vermont. The patient was a man sixty-eight years of age who had symptoms of cancer of the pylorus. Eight months before death the umbilicus became hard and painful and there was a malodorous discharge from it. Five months before death enlargement of the liver was noted; the death was caused by cancer of the liver, as determined at autopsy.

**Carcinoma of the Umbilicus Probably Secondary to Cancer of the Stomach.** †—Case 109 was a personal communication received by Pernice from R. Volkmann. The man was tapped on account of the presence of ascitic fluid, which proved to be hemorrhagic in character. After the removal of the fluid a tumor could be palpated. The umbilicus, stomach, and liver region were involved, and at the umbilicus were adhesions to the skin. The patient died without operation and no autopsy was allowed.

**Secondary Carcinoma of the Umbilicus.** ‡—A woman, aged fifty-nine, entered the Frauenklinik in Breslau. About six or nine months before, she had noticed below the umbilicus a small, hard nodule, that gave rise to little trouble and did not interfere with her work. She suffered from lack of appetite, vomiting, and constipation. The nodule grew rapidly and commenced to give trouble. The umbilicus became reddened and inflamed. On admission she looked frail and cachectic. The swelling at the umbilicus had extended to the surrounding parts, and the tissue was very hot and painful. On examination there could be felt in the depth a tumor the size of an ostrich's egg. On both sides the tumor extended 5 cm. from the umbilicus and could be sharply outlined. About 3 cm. above the umbilicus were several other fluctuating nodules. An exploratory operation was made, and three small abscesses, containing purulent, smeary masses were removed. The abdomen was opened, and the tumor was found to involve the stomach. Resection of the stomach was done, and the patient died of shock. In this case there was a primary carcinoma of the stomach and a secondary growth at the umbilicus. It will be noted that the primary tumor in the beginning had given hardly any symptoms.

**Secondary Carcinoma of the Umbilicus.** §—This case was reported from the Universitätsklinik in Halle. A man, fifty-eight years of age, had been strong and healthy until he began to complain of pain in the abdomen and of a brownish vomitus. Later he had pain in the region of the umbilicus and then a nodule was detected. The patient on admission was very feeble, and the skin had a jaundiced tint. The umbilicus was somewhat distended by a nodule the size of a 10-pfennig piece. It was very hard and painful, brownish red, and on the surface slightly ulcerated. In this case there was probably a carcinoma of the stomach with secondary carcinoma at the umbilicus. Operation was refused.

\* Morris: Op. cit., 114.

† Pernice: Die Nabelgeschwülste, Halle, 1892.

‡ Pernice: Op. cit., obs. 110.

§ Pernice: Op. cit., obs. 123.

Carcinoma of the Umbilicus Secondary to Cancer of the Stomach.\*—For about a year a woman, sixty-two years of age, had had symptoms of cancer of the stomach. For four months she had noticed a hardening at the umbilicus. This was prominent; the skin was reddened, the surface of the tumor uneven and very dense. It was sharply defined and showed no ulceration.

Carcinoma of the Umbilicus Secondary to Abdominal Carcinoma.†—A woman, forty years of age, suffered from a malignant disease in the abdomen and had been frequently tapped. At autopsy carcinoma of the liver, omentum, and peritoneal surfaces of the intestine was found, and the uterus and ovaries formed one mass. At the umbilicus was a circumscribed tumor the size of the last phalanx of the thumb, looking like an umbilical hernia. This was also a carcinoma, evidently secondary to the abdominal tumor, which had probably originated in the stomach.

Carcinoma of the Umbilicus Secondary to Cancer of the Stomach.—Tillmanns‡ said he saw a case of carcinoma of the stomach with a secondary growth at the umbilicus.

Secondary Carcinoma of the Umbilicus.§—A farmer, aged fifty-two, for two months had noticed an enlargement at the umbilicus which had increased rapidly in size and become ulcerated. The patient was slightly emaciated. The inguinal glands were enlarged. Peritoneal carcinosis, which had probably originated from the stomach, was found at operation. No microscopic examination was made.

Cancer of the Umbilicus Secondary to Cancer of the Cardiac End of the Stomach.||—The patient, fifty years of age, was admitted to the service of Damaschino. Cancer of the stomach could be definitely made out. Later on, just beneath the umbilicus, one could feel with the ends of the fingers a hard tumor occupying the lower portion of the epigastric region. This tumor had a regular surface and presented the characteristics of a secondary neoplasm. Still later, at the umbilical cicatrix, there appeared a small, violet-colored tumor. This was covered over with a delicate crust. Microscopic examination showed that the tumor of the stomach and omentum, the abdominal glands, and the growth in the umbilical cicatrix were of precisely the same type of cancer.

Carcinoma of the Umbilicus Secondary to Carcinoma of the Stomach.—The report of the case was communicated to Villar\*\* by Broussolle. X. entered the service of Professor Le Fort in 1885. There had been no digestive disturbances. The patient had come to Paris to consult a

\* Schlesinger: Die Bedeutung der Nabelmetastasen für die Diagnose abdomineller Neoplasmen. Wien. med. Wochenschr., 1911, No. 8, 519.

† Storer: Circumscribed Tumor of the Umbilicus Closely Simulating Umbilical Hernia, etc. Boston Med. and Surg. Jour., 1864, lxx, 73.

‡ Tillmanns, H.: Ueber angeborenen Prolaps von Magenschleimhaut durch den Nabelring (Ectopia ventriculi), und über sonstige Geschwülste und Fisteln des Nabels. Deutsche Zeitschr. f. Chir., 1882-83, xviii, 161.

§ Tisserand: A propos de deux cas de cancer secondaire de l'ombilic. La Loire méd., St. Étienne, 1906, xxv, 131.

|| Villar: Tumeurs de l'ombilic. Thèse de Paris, 1886, obs. 79.

\*\* Villar: Op. cit., obs. 85.



surgeon on account of a vegetative, ulcerating tumor situated in the umbilical region.

On admission to the hospital he was very feeble, and this feebleness was attributed to the fatigue of the journey. In the epigastric region and encroaching on the umbilicus was a vegetating tumor which was ulcerating and bled. At first sight it appeared to be a phlegmon, but on careful examination was found to present special characteristics. Some time afterward cancerous nodules appeared in the liver. At autopsy cancer of the pylorus was found and cancerous masses of the liver and plaques of carcinoma, which occupied the umbilicus and a certain portion of the anterior abdominal wall.

*Carcinoma of the Umbilicus Secondary to Latent Carcinoma of the Stomach.*—Valette\* gives a list of the cases of primary and secondary carcinoma of the umbilicus, and then cites the history of a woman, sixty-one years old, who entered the hospital on August 16, 1896. In March of the same year she had noticed a small lump at the umbilicus. Later this had become painful, in some weeks had reached the size of a large nut, and ulcerated.

On admission the umbilical depression was found replaced by an elevation of the skin with an ulceration in the center and fungus-like margins. The growth was the size of a 50-centime piece (about 2 cm. in diameter). The ulceration had extended to the aponeurosis and the tumor was fixed. The inguinal glands were not enlarged. The question arose as to whether the growth was primary or secondary. The patient gave no history of stomach trouble and had had no vomiting, but the appetite was slightly diminished and she had lost weight in the last six months. At operation the peritoneal surface of the umbilicus was found smooth. There were small metastases in the peritoneum. The stomach was apparently normal. The patient died on the eighth day. At autopsy an adenocarcinoma of the stomach was found. The growths in the abdomen and at the umbilicus were similar to that in the stomach and were evidently secondary. This case demonstrates very clearly the fact that a malignant growth in the stomach may be unrecognizable during life, and be detected only at autopsy.

*Carcinoma of the Umbilicus Secondary to Carcinoma of the Stomach.* †—The patient was a man, thirty-three years of age, of strong build. When going home one dark night he struck his abdomen in the region of the stomach against a stony projection and was never well afterward. Early next year he consulted his physician for indigestion. In the fall of the same year he noticed that the umbilicus was inflamed, but there was no pain. When seen by Wulckow the umbilicus was slightly raised above the surrounding skin and was reddened. Along the margins were rough excrescences, and where the skin was gone the surface was moist. The entire mass was the size of a large plum. The skin around the umbilicus was reddened over an area the size of a two-thaler piece (about 6 cm. in diameter). The growth could be lifted up from the underlying abdominal contents. The patient died of hemorrhage of the stomach. At autopsy carcinoma was found in the stomach and at the umbilicus. The umbilical growth was in all probability secondary to that in the stomach.

\* Valette: Contribution à l'étude du cancer secondaire de l'ombilic. Thèse de Paris, 1898, No. 550.

† Wulckow: Beitrag zur Casuistik der Nabelneubildungen. Berlin. klin. Wochenschr., 1875, xii, 533.

LITERATURE CONSULTED ON CARCINOMA OF THE UMBILICUS SECONDARY TO  
CARCINOMA OF THE STOMACH.

- Attimont, A.: Remarques sur le cancer de l'ombilic. *Gaz. m'éd. de Nantes*, 1887-88, vi, 137; 149.
- Auger, M. G.: Cancer de l'estomac, fistule gastro-abdominale. *Bull. Soc. anat. de Paris*, 1875, 1, 70S.
- Balluff: Magenkrebs. Erweichung und Aufbruch desselben durch die allgemeinen Bauchdecken, Magenfistel. *Med. Correspondenzbl. des W'urtemberg. ärztl. Vereins*, Stuttgart, 1854, xxiv, 37.
- Burkhart, O.: Ueber den Nabelkrebs. *Inaug. Diss.*, Berlin, 1889.
- Cannet: *Bull. Soc. anat. de Paris*, 1852, xxvii, 274.
- Codet de Boisse: Tumeurs de l'ombilic chez l'adulte. *Thèse de Paris*, 1883, No. 311.
- Feulard, H.: Fistule ombilicale et cancer de l'estomac. *Arch. g'n. de m'éd.*, 1887, 7. sér., xx, 158.
- Fischer: Résection de l'estomac. *La Semaine m'éd.*, Paris, 1888, viii, 134.
- Hutchinson, J.: Carcinoma of the Umbilicus, Secondary. *Arch. of Surgery*, 1893, iv, 153 (1 pl.).
- Largeau, R.: Cancer de l'ombilic. *Bull. Soc. anat. de Paris*, 1884, lix, 210-212.
- Ledderhose, G.: Chirurgische Erkrankungen des Nabels. *Deutsche Chirurgie*, 1890, Lief. 45 b.
- Mirallié: Reported by Attimont.
- Monod, E.: Fistule ombilicale; cancer latent de l'estomac. *Bull. Soc. anat. de Paris*, 1877, lii, 3S.
- Morris, Robert T.: *Lectures on Appendicitis and Notes on Other Subjects*, 1895, 95.
- Pernice, L.: *Die Nabelgeschwülste*, Halle, 1892.
- Schlesinger: Die Bedeutung der Nabelmetastasen für die Diagnose abdomineller Neoplasmen. *Wien. med. Wochenschr.*, 1911, No. 8, 519.
- Storer, H. R.: Circumscribed Tumor of the Umbilicus Closely Simulating Umbilical Hernia, etc. *Boston Med. and Surg. Jour.*, 1864, lxx, 73.
- Tillmanns, H.: Ueber angeborenen Prolaps von Magenschleimhaut durch den Nabelring (Ectopia ventriculi), und über sonstige Geschwülste und Fisteln des Nabels. *Deutsche Zeitschr. f. Chir.*, 1882-83, xviii, 161.
- Tisserand, G.: A propos de deux cas de cancer secondaire de l'ombilic. *La Loire m'éd.*, St. Étienne, 1906, xxv, 131-136.
- Valette, A.: Contribution à l'étude du cancer secondaire de l'ombilic. *Thèse de Paris*, 1898, No. 550.
- Villar, F.: Tumeurs de l'ombilic. *Thèse de Paris*, 1886.
- Wulckow: Beitrag zur Casuistik der Nabelneubildungen. *Berlin. klin. Wochenschr.*, 1875, xii, 533.

CARCINOMA OF THE UMBILICUS SECONDARY TO CANCER OF THE GALL-BLADDER.

Inasmuch as primary carcinoma of the gall-bladder is relatively rare, we should not expect to find many growths of the umbilicus secondary to it. Ledderhose, in 1890, reported a case that he had observed in Kussmaul's clinic. A woman, fifty-six years old, was brought to the hospital on account of jaundice. It was impossible to detect any growth in the liver either by palpation or percussion. At the umbilicus, however, was a bean-sized, hard tumor which suggested the diagnosis of carcinoma of the liver or of the gall-bladder. Subsequently it became possible to detect large and irregular masses with nodular margins in the liver. At autopsy a primary carcinoma of the gall-bladder was found which had given rise to the umbilical growth.

In 1901 Besson gave a splendid résumé of the literature on secondary carcinoma of the umbilicus, and cited a case of carcinoma of the gall-bladder with a secondary growth at the umbilicus. The umbilical growth was the size of a small hazelnut.

The histologic pictures from this case are given in Figs. 225, 226, and 227 of Cornil and Ranvier's *Manuel d'histologie pathologique*, published in the same year.

Tisserand, in 1906, reported a case of this character. A woman, fifty-four years old, the mother of four children, had had pain for five months in the umbilical region, but her general health had been good. On abdominal examination the cicatrix of the umbilicus seemed to be simply inflamed. It was very red, slightly painful, and indurated. An exploratory operation was performed. The patient died suddenly on the tenth day. There was a carcinoma of the gall-bladder with biliary stones. The glands along the suspensory ligament of the umbilicus showed a bead-like involvement. No trace of cancer could be found in any other organ. In this case there was a definite carcinomatous extension along the lymphatics.

Schlesinger, in 1911, reported a case of primary carcinoma of the gall-bladder with a secondary nodule at the umbilicus.

In this connection the following case of biliary fistula reported by Gross may be of interest:

**Biliary Fistula at the Umbilicus.\***—A man, aged forty-four, two months before had noticed a small lump at the umbilicus; it was not painful, but caused a continuous pricking sensation. The lesion had progressively enlarged, and on admission the umbilical growth was the size of a large red button and the man had a continuous dull pain. For a month it had been severe enough to prevent him from sleeping. The patient had become emaciated, but had had no intestinal disturbances.

On admission he was thin, and grayish in color. On January 29th a tumor covered by intact red skin was removed. It was adherent to the peritoneum. Microscopic examination showed it to be a cancer. The patient developed pneumonia, but recovered from it. On February 18th, an irritating biliary discharge was noted, but no inflammatory reaction. He left the hospital on March 11th well of his pneumonia, but with a biliary fistula.

Gross thinks that the gall-bladder had become adherent to the umbilicus, and after operation a small abscess had developed and perforation of the gall-bladder had taken place.

[It is just possible that a primary carcinoma of the gall-bladder existed in this case.—T. S. C.]

While reviewing the literature on diseases of the umbilicus I was asked to see the following case, and profiting by the knowledge gleaned from the literature, at once ventured a provisional diagnosis of either carcinoma of the stomach or of the gall-bladder with gall-stones and a secondary malignant growth at the umbilicus.

**Adenocarcinoma of the Umbilicus Secondary to Carcinoma of the Gall-bladder.†**—Mrs. B., aged fifty-eight, was seen in consultation with Dr. George L. Wilkins and admitted to the Church Home and Infirmary April 24, 1910.

The patient showed a slight bulging at the umbilicus on standing. This was painful when the clothes rubbed against it. It had been noticed first in December, 1909, that is, about four months before examination. For some months the patient had suffered at intervals with pain in the region of the gall-bladder and had been jaundiced. The pain had radiated to the back and to the right shoulder. At the time of examination there was some tenderness in the gall-bladder region. She

\* Gross, G.: Néoplasme de l'ombilie. *Revue méd. de l'est.*, Nancy, 1898, xxx, 559.

† I reported this case in *Jour. Amer. Med. Assoc.*, 1911, lvi, 391.

had suffered from the presence of gas and from constipation. No clay-colored stools had been noted. The heart, lungs, and kidneys were normal.

From the history and general condition a provisional diagnosis was made of either cancer of the stomach or of the gall-bladder, associated with a secondary nodule at the umbilicus. On examination of the umbilicus there was just a slight rolling out, but nothing to suggest a nodule until one picked the umbilicus up between the fingers, when marked sensitiveness became apparent (Fig. 184).

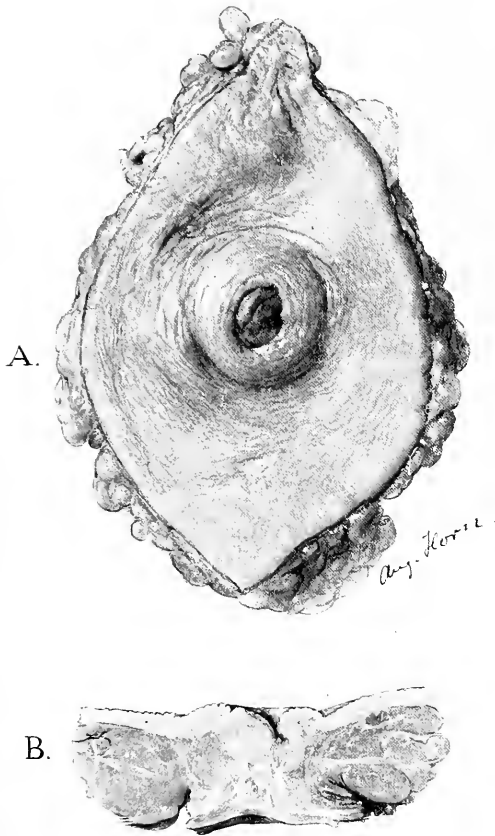


FIG. 184.—APPEARANCE OF THE CARCINOMATOUS UMBILICUS AFTER REMOVAL. (Natural size.)

Path. No. 14968. A., The parts are slightly distorted from the action of the hardening fluid and the umbilicus comes out more prominently than it really did in the patient. There is, however, a slight unfolding of the umbilicus, and one part seems somewhat raised. The umbilicus itself, however, was perfectly intact. B., A transverse section through the umbilicus. The half to the left is more prominent and represents the elevation noted in the umbilical depression. The surface, however, is intact. There is an increase in the amount of connective tissue, but no evidence of any definite nodule. Histologic examination showed that this area was everywhere infiltrated with carcinomatous glands.

large secondary nodules in the abdominal cavity, and died on September 16, 1910.

Pathologic Examination (Path. No. 14968).—The specimen consists of the umbilicus and surrounding skin. It is 7 cm. in length, 5 cm. in breadth. The umbilicus is slightly prominent. It is commencing to unfold a little, as seen in Fig.

Operation. — April 25, 1910. On making a right rectus incision I at once encountered little nodules in the lesser omentum. The gall-bladder contained numerous stones and also a new-growth. The latter was firm and had extended to the lymph-glands around the portal vein. One of these was over 3 cm. in diameter. We were dealing with a carcinoma of the gall-bladder, together with metastases in the lesser omentum and the umbilicus. On account of the marked involvement of the lymph-glands complete removal of the primary growth was impossible. As the patient had had a great deal of pain in the umbilicus, this was removed. The inner or peritoneal surface of the umbilicus was free from adhesions. The patient made a good temporary recovery and was discharged May 9, 1910.

She subsequently developed

184. It was not quite so prominent, however, in the fresh state. The nodule could be readily felt on lifting the umbilicus up with the fingers. It appeared to be about 1 cm. or more in diameter. In the hardened specimen the tissue was contracted, bringing the tumor out more prominently. The skin was everywhere intact. The peritoneal surface was slightly puckered, but was free from adhesions. On section of the umbilicus the tissue looked fibrous and in its middle portion was what appeared to be a little area of hemorrhage about 2 mm. in diameter. At first sight one would not for a moment suspect the presence of carcinoma.

**Histologic Examination.**—The squamous epithelium is intact, and immediately beneath it in a few places are some sweat-glands. Approaching the peritoneum colonies of glands are found closely packed together with very little connective tissue between them. The gland epithelium is for the most part one layer in thickness. In some places it is cuboid, at other points cylindric, and there are very minute glands. The nuclei of the epithelial cells stain uniformly, but vary considerably in size. In some places the epithelial cells seem to have a tendency to be arranged in single rows. The growth is without doubt a carcinoma. The small metastatic nodules found in the lesser omentum in the neighborhood of the gall-bladder present a precisely similar appearance. We are undoubtedly dealing with a primary carcinoma of the gall-bladder, involving the lymphatics around the portal vein. There have been metastases in the lesser omentum and also involvement of the umbilicus.

**Treatment.**—When the diagnosis is perfectly clear, operation is not indicated, as it is impossible completely to eradicate the disease. In my case the operation was undertaken solely on account of the severe pain caused by the umbilical nodule.

#### LITERATURE CONSULTED ON CARCINOMA OF THE UMBILICUS SECONDARY TO CANCER OF THE GALL-BLADDER.

- Besson, E.: Cancer de l'ombilic. Thèse de Paris, 1901, No. 263.  
 Cornil et Ranvier: Manuel d'histologie pathologique, 3. éd., Paris, 1910, i, 493.  
 Gross, G.: Néoplasme de l'ombilic. Revue méd. de l'est., Nancy, 1898, xxx, 559.  
 Ledderhose, G.: Deutsche Chirurgie, 1890, Lief. 45 b.  
 Schlesinger: Die Bedeutung der Nabelmetastasen für die Diagnose abdomineller Neoplasmen. Wien. med. Wochenschr., 1911, Nr. 8, 519.  
 Tisserand, G.: A propos de deux cas de cancer secondaire de l'ombilic. La Loire méd., St. Étienne, 1906, xxv, 131-136.

#### CARCINOMA OF THE UMBILICUS SECONDARY TO CANCER OF THE INTESTINE.

I have found five cases of this character in the literature, those of Lage, Chuquet, Villar, Permice, and Barker. It is quite probably that Plagge's case also belongs to this group, although the tumor was described as a myxosarcoma. In Chuquet's case the carcinoma was situated in the rectum.

On reading the histories of these cases it will be seen that in the majority of the cases, in addition to the primary growth, there were wide-spread abdominal metastases facilitating extension of the carcinomatous process to the umbilicus.

Histologically, the umbilical growths conform exactly to the type of the original intestinal tumor.

## CASES OF CARCINOMA OF THE UMBILICUS SECONDARY TO CANCER OF THE INTESTINE.

*Carcinoma of the Large Bowel With Metastases at the Umbilicus.*\*—The patient died of carcinoma involving nearly all of the large bowel. There were metastases in the mesenteric glands. At the umbilicus was a brownish red, mottled growth. The umbilicus felt like a broad, hard, flat surface. The growth was probably a carcinoma secondary to that of the large bowel.

*Carcinoma of the Rectum With Secondary Carcinoma at the Umbilicus.*†—This case had been reported by Lebert (Bull. Soc. anat. de Paris). A woman, fifty-four years of age, six weeks before coming under observation had commenced to have violent colic and pain at the umbilicus with digestive disturbances. On admission she looked cachectic and the abdomen was much distended. Beneath the umbilicus was felt a hard, cartilaginous plaque which at its prominent part raised the skin nearly 3 cm.

At autopsy small carcinomatous masses were found scattered over the peritoneum and there was a scirrhus carcinoma of the rectum. The umbilical growth had developed in the linea alba.

[Although the growth was probably secondary to that in the rectum, one cannot feel absolutely sure.—T. S. C.]

*Carcinoma of the Umbilicus Secondary to Carcinoma of the Transverse Colon.*—Villar‡ describes a case occurring in the service of Damaschino. The patient, fifty-three years of age, had a cancer of the transverse colon involving the omentum, cancerous nodules in the peritoneum, ulceration and cancer of the umbilicus, and secondary nodules in the liver.

During the progress of the disease a hard mass developed in the umbilical region, and in two months the umbilical depression was effaced by a violet mass which reached the dimensions of a two-franc piece. This was covered with a thick crust. When this was removed, the new-growth was found to be nodular, irregular, and reddish. On palpation one could feel in the umbilical region, over an area 10 cm. in diameter, a hard, slightly movable, mass. At autopsy it was found that the tumors of the omentum and of the peritoneum, as well as the umbilical mass, were of exactly the same structure as the intestinal growth.

*Cancer of the Transverse Colon with Secondary Carcinoma of the Umbilicus.*§—Case 1.—“A man, aged thirty-seven, admitted to the University College Hospital February 3, 1910. In March, 1909, he noticed occasional pains around the navel irrespective of food. These lasted three or four months. In the July following he entered a country hospital, having noticed for about a fortnight a swelling in the abdominal wall at the umbilicus. This was opened with the knife on July 24th and was said to have given exit to pus and to have healed again in a week. In the September following the swelling increased again and burst, and has been discharging ever since. On admission on February 3d he was well nourished. Below and to the left of the navel was a discolored and irregular prominence about  $2\frac{1}{2}$  inches in diameter, with a wound

\* Lage: Krebshafte Entartung eines grossen Theils des Dickdarms. Schmidt's Jahrbuch, 1847, iv, 295.

† Chuquet: Du carcinome généralisé du péritoine. Thèse de Paris, 1879, No. 548, obs. 18.

‡ Villar, F.: Tumeurs de l'ombilic. Thèse de Paris, 1886, obs. 78, 112.

§ Barker, A. E.: The Lancet, London, July 19, 1913.

discharging through the old scar. On palpation the induration was much larger than it looked. It extended downward for several inches in the left rectus muscle and was everywhere very hard. Except to the skin over the most prominent part, it showed no attachment anteriorly, but was incorporated with the rectus. The discharging sinus led downward and outward about  $1\frac{1}{2}$  inches. To be quite sure of its nature, which was believed to be cancerous, I made an incision into the swelling, and, finding it unmistakably so, prepared for removal. This was done on February 20th, between two long elliptic incisions from above downward, opening the abdomen and including most of the left rectus muscle. The tumor was then seen to be obviously a growth of the transverse colon fungating through the umbilicus. I then clamped the colon on each side and removed it with about  $2\frac{1}{2}$  inches on both sides of the growth—about seven or eight inches in all. The ends of the divided bowel were brought together in the usual way, and the wound was only partially closed, as there was little or no muscle to fill it. Some suppuration followed, as I expected, from the foul state of the breaking-down growth, and a fecal fistula formed for a little while, but soon closed and the wound granulated up. On May 6th I removed a nodule of growth, cutting the skin and inserting a delicate wire netting. Since then all has gone well, and I have recently seen the man—more than three years after the operation—quite free from any sign of recurrence. He plays golf and performs on a wind instrument; he has no hernia.

“The growth was a typical columnar carcinoma, and corresponded to an ulcer on the mucous surface of the free side of the transverse colon, as large as a crown piece, with everted edges. There were no tangible glands in the mesentery or any other signs of generalization.”

Secondary Carcinoma of the Umbilicus.\*—Case 129, reported from the Frauenklinik of Breslau. A woman, fifty-two years of age, complained of a sticking, burning pain, which was more marked on pressure. The abdomen was much distended. In the vicinity of the stomach and also in the region of the umbilicus nodules could be made out. The patient looked weak and cachectic. In the umbilical region there was marked resistance. This extended three fingerbreadths to the right and over a handbreadth and a half to the left. On account of the ascites, nothing more could be made out. There was a small umbilical tumor. At an exploratory operation carcinomatous nodules were found on the intestine, and the omentum was everywhere covered with small carcinomatous nodules.

A Case of Myxosarcoma of the Umbilicus.[?]†—In childhood the man had difficulty in digestion, and later vomiting and diarrhea. In the summer of 1887 he had pain in the stomach for the first time and noticed a small tumor at the umbilicus. By November of the same year the tumor had reached the size of a hazel-nut, and four weeks later a nodule the size of a pea below and to the left, close to the linea alba, could be felt. The patient became emaciated and died on March 14, 1888. At autopsy the umbilicus showed a thickening, the size of a five-franc piece, raised 2 cm. above the abdominal level. Above and below, the thickening could be followed 5 cm. in each direction. The skin was movable over the area of thickening. When the abdomen was opened, a nodule 2 mm. in diameter was found in the umbilical region. In the ligament passing from the umbilicus

\* Pernice, L.: Die Nabelgeschwülste, Halle, 1892.

† Plagge, H.: Ein Fall von Myxosarcom des Nabel. Inaug. Diss., Freiburg i. B., 1889.

were small nodules. The omentum, diaphragm, and intestine were implicated. The stomach was normal. Microscopically, a diagnosis of myxosarcoma was made.

[The clinical picture in no way indicated a primary growth. The condition resembles in some degree a case of a colloid carcinoma of the intestine with secondary growths at the umbilicus.—T. S. C.]

#### LITERATURE CONSULTED ON CARCINOMA OF THE UMBILICUS SECONDARY TO CANCER OF THE INTESTINE.

Barker, A. E.: Three Cases of Solid Tumors of the Umbilicus in Adults. *The Lancet*, London, July 19, 1913.

Chuquet, A.: Du carcinome généralisé du péritoine. Thèse de Paris, 1879, No. 548.

Lage: Krebshafte Entartung eines grossen Theils des Dickdarms. *Schmidt's Jahrbuch*, 1847, lv, 295.

Pernice, L.: Die Nabelgeschwülste, Halle, 1892.

Plagge, H.: Ein Fall von Myxosarcom des Nabel. *Inaug. Diss.*, Freiburg i. B., 1889.

Villar, F.: Tumeurs de l'ombilic. Thèse de Paris, 1886, obs. 78.

#### CARCINOMA OF THE UMBILICUS SECONDARY TO OVARIAN CARCINOMA.

I have found several cases of this character in the literature, and two have been observed in the Gynecological Department of the Johns Hopkins Hospital. A very careful review of the subject was given by Le Coniac in his thesis published in 1898.

The youngest of the patients here recorded was thirty-two years of age; the oldest, sixty-eight. Five of the nine patients were between fifty and sixty years of age.

Most of the umbilical growths were small, and some of them were very hard. In Gueneau de Mussy's case the growth was pedunculated. A small umbilical hernia had existed, and a month before the patient came under observation it had become irreducible. It then became very hard, and was evidently infiltrated with cancer. In Burkhart's case, in addition to the umbilical nodule, there was also one attached to a rib. The umbilical nodule in one of Demons and Verdet's cases was ulcerated. In one of our cases (Gyn. No. 6150) there was a round, ulcerated area with sharply cut edges and a granular base. As seen from Fig. 185 (p. 432) the floor of this ulcer consisted of carcinomatous tissue. In Aslanian's case the carcinoma had extended to the inguinal glands.

It is hardly necessary to analyze the histories of these cases, as the findings are common to those ordinarily noted where carcinoma of the ovaries, together with wide-spread peritoneal carcinosis, is present. It will be noted that in all but one of the cases there was a wide-spread peritoneal carcinosis, and consequently secondary involvement of the umbilicus was relatively easy.

The histologic picture of these umbilical nodules naturally corresponds to that present in primary ovarian tumors. In Fig. 185, which Mr. Hart kindly photographed for me, we see the edge of the carcinomatous nodule in case Gyn. No. 6150. The growth can be traced through the abdominal wall as far as the epithelial covering of the umbilicus. Over the area of ulceration the skin covering had disappeared entirely and the carcinomatous tissue formed the floor of the ulcer. Any operative treatment in these cases is of little or no value.



## CASES OF CARCINOMA OF THE UMBILICUS SECONDARY TO OVARIAN CARCINOMA.

*Carcinoma of the Umbilicus Secondary to Carcinoma of the Ovaries.*—Aslanian\* covers the literature on peritoneal carcinosis very thoroughly. He cites the following case: A woman, aged thirty-five, had cancer of the ovaries with metastases to the abdominal peritoneum. Eleven months before she had given birth to a child. Fifteen days later she had commenced to suffer with abdominal pain and developed an induration at the umbilicus. The umbilical growth had finally ulcerated, and it was for this that the patient entered the hospital. During surgical intervention metastatic nodules were noted in the parietal peritoneum. The patient recovered from the operation, but did not improve. The appetite diminished more and more, and she became thin. She returned to the hospital on account of the abdominal pain and another growth in the umbilical region. At the site of the umbilicus the scar contained a soft tumor the size of a walnut. In both inguinal regions the glands were enlarged and formed two elongate tumors parallel with the inguinal folds. One could detect beneath the integument of the abdominal wall some small nodules the size of lentils or peas, and over these the skin was adherent. To the left of the tumor was a hard cord, 3 to 4 cm. long, which terminated in the enlarged glands. Deeper down, nodules could be made out in the hypogastrium. At the level of the umbilicus on the right was a deep-seated induration. Palpation was not painful, and there was an accumulation of ascitic fluid.

All the time the patient was in the hospital she continued to complain of pain. The emaciation increased, and toward the end of her illness there was edema of the feet.

At autopsy the peritoneal cavity was found to contain 300 c.c. of reddish fluid. In the pelvis the normal relations were markedly altered. Both ovaries had been converted into hard tumors the size of apples. They were nodular and had uniform surfaces. The left ovary presented a small cyst. On section, the tumors were found to have a uniform, hard, grayish surface, with yellowish areas scattered here and there through them. The Fallopian tubes showed hypertrophy. Their extremities were free, but the mucosa of the fimbriæ contained cancerous nodules which were yellowish in color, very hard, and simulated eruptions of tubercles. The entire peritoneum was involved in the cancer. The neck of the cervix was hard and infiltrated in its entire thickness with numerous cancerous nodules, some as large as a pea. In addition to the wide-spread peritoneal involvement, the omentum was contracted into numerous folds and contained cancerous nodules. It was adherent to the abdominal wall at the umbilicus. At this point the cancerous nodules were very abundant. The small intestines did not show any secondary nodules, but there were some in the mesentery. The liver was voluminous and nodular, and occupied all the epigastrium. Glisson's capsule did not contain any nodules, but in the hepatic tissue there were 15 secondary growths varying from the volume of a pomegranate to that of a peach in size. On the inferior surface of the diaphragm on the right side were cancerous plaques. On the anterior abdominal wall were whitish cords. These were cancerous lymphatics, following the direction of the umbilical arteries, and terminating at the umbilical tumor

\* Aslanian, G.: Contribution à l'étude de la péritonite cancéreuse. Thèse de Paris, 1895, No. 150, obs. 70.

where the omentum was adherent to the abdominal wall. The nodules at this point varied from the size of a pin-head to that of a pea. Cancerous nodules were present in the thorax.

On histologic examination, the ovary, uterus, intestine, muscle, and peritoneum of the umbilical tumor all showed an alveolar carcinoma. Aslanian says that pregnancy played a large rôle in the provocation of the generalization of the cancer, not only on the serous surfaces, but also in the generative organs and in the anterior abdominal wall. His article is a very thorough one.

**Carcinoma of the Umbilicus Secondary to Ovarian Carcinoma.**—Burkhart\* reports Küster's† case of a woman, fifty-seven years of age, who had had several labors. Two years before she had complained of a dull feeling in the lower abdomen, and six months before a small nodule had been detected at the umbilicus; two months before coming under observation nodules had been noted on the ribs near the sternum. At the time of the patient's death the tumor at the umbilicus was the size of a nut. The overlying skin was movable. The malignant growth had involved the uterus and ovaries. It had originally been an ovarian cyst and had become carcinomatous.

**Carcinoma of the Umbilicus Secondary to Carcinoma of the Ovary.**‡—Case 1.—A woman, forty-five years of age, for a month had had an abdominal enlargement. She was thin, and the abdomen contained an accumulation of fluid. At the umbilicus was a small tumor. Deep palpation revealed a large tumor attached to the uterus. At operation the abdomen was found to contain pelvic tumors. There were papillomata involving the intestine and the omentum, and converting the ovaries and uterus into one mass. The fluid was removed, and the umbilical tumor taken away. The histologic picture noted in the umbilical tumor was identical with that frequently found in the ovary.

**Cancer of the Ovaries with a Secondary Growth at the Umbilicus.**§—Case 2.—A woman, fifty-three years of age, for nine months had had abdominal pain. Shortly after falling on her abdomen she had noticed a small, non-painful enlargement. The abdomen increased in size and the patient became emaciated. On examination abundant free fluid was found. At the umbilicus was a small tumor which was not ulcerated and lay beneath the skin. Hard, fixed masses could be felt in the lower abdomen. Vaginal examination revealed a nodular, irregular tumor. The condition was diagnosed as carcinoma of the ovaries with secondary carcinoma of the umbilicus. At operation 12 liters of ascitic fluid were removed. Tumors were found filling Douglas' cul-de-sac. Attached to the parietal peritoneum were several secondary nodules, and the omentum formed a tumor mass. The umbilical growth was removed and the abdomen closed.

**Probable Carcinoma of the Ovary with a Secondary Growth at the Umbilicus.**||—A woman, sixty-eight years of age, a year before admission had had abundant uterine hemorrhages and since then had been ill. The abdomen was slightly distended. Her appetite had gone, she was

\* Burkhart, O.: Ueber den Nabelkrebs. Inaug. Diss., Berlin, 1889.

† Küster: Beiträge z. Geb. u. Gyn., 1875, iv, 6.

‡ Demons et Verdelet: Cancer secondaire de l'ombilic. Congrès périodique de gyn., d'obstét. et de paed., 1898, ii, 344.

§ Demons et Verdelet: Op. cit.

|| Demons et Verdelet: Op. cit.

constipated, and had been gradually wasting away. She had pain in the abdomen. Two months previously she had first noticed at the umbilicus a hard, irregular tumor, which soon ulcerated. Eight days before admission jaundice had become pronounced. On examination the abdomen was found distended, tympanitic, and at the umbilicus was a small, indurated tumor with diffuse margins. It was ulcerated. A diagnosis of cancer was made. In Douglas' pouch was a tumor. The outlines were not clear. The patient was too weak for operation. The condition was diagnosed as cancer of the ovaries with secondary growths at the umbilicus. [Of course, there is a chance for error in this case, as no operation was performed.—T. S. C.]

*Probable Carcinoma of the Umbilicus Secondary to Carcinoma of the Ovaries.\**—A woman, fifty-nine years of age, for three months had been supposed to have influenza. Two months before coming under observation she had become yellow and had had pain in the abdomen. On admission she was jaundiced, had lost weight, vomited bile, and gave a history of vomiting blood on one occasion. At the umbilicus was a knob-like hardness drawn inward, as if pulled by something from within. At autopsy carcinoma of both ovaries was found. There were small nodules in the peritoneum and pleuræ. The gall-bladder was small and filled with stones. The common duct was compressed by cancerous nodules. The growth at the umbilicus was apparently secondary to that in the ovaries.

*Carcinoma of the Umbilicus Secondary to Cancer in the Pelvis.*—Gueneau de Mussy's† patient, a woman fifty-nine years old, was suffering from an obscure abdominal lesion. At the umbilicus was a small, hard disc, the size of a large almond, attached by a pedicle in the umbilical ring. The patient said she had had a small hernia, easily reducible, but for the past month it had been hard and remained outside.

At autopsy, several months later, an abdominal carcinoma was found. The pelvis contained a mass the size of a new-born child's head, and other foci existed.

*Probable Adenocarcinoma of the Umbilicus Secondary to Carcinoma of the Ovary.*—Gyn. No. 2004; Path. No. 8. Mrs. C. W., aged thirty-two. Admitted to the Johns Hopkins Hospital May 25, 1893. Operation by Dr. Kelly. The abdomen contained about 8 ounces of ascitic fluid; the peritoneum was dark in color. The right ovary was the size of an orange, and was surrounded by a capsule  $\frac{1}{4}$  inch in thickness. This was easily torn. Several small nodules were felt in different portions of the peritoneum; in the median line and around the umbilicus was a loosely encapsulated white lump the size of a shellbark nut. This was not removed, on account of the presence of secondary nodules. The liver was covered with whitish nodules, similar in character; these extended from the liver down to the umbilicus.

Path. No. 8. The specimen consists of the ovary, tube, and a portion of the broad ligament. The ovary is very much enlarged and contains three or four cysts. The surface is irregular in outline. There is a dense, hard capsule with several small cysts showing through the outer surface. At the inner end of the ovary is a cyst, 2 cm. in diameter, filled with clear, watery fluid. The cysts are confined to the superficial portion of the ovary. On section, the greater portion of the mass appears

\* Living: The Lancet, 1875, ii, 8.

† Gueneau de Mussy: Cancer du péritoine. Clin. méd., Paris, 1875, ii, 28.

to be made up of translucent, grayish tissue having an edematous appearance, and running through this in every direction is dense fibrous tissue. There are ecchymotic patches here and there throughout the specimen. The broad ligament is thickened and contains numerous hard masses varying from a pin-head to a lima bean in size. On histologic examination the matrix of the tumor is found to consist of very edematous fibrous tissue. Scattered sparsely or abundantly throughout the stroma are colonies of carcinomatous glands. The gland type in some areas is very well preserved. At other points the carcinoma seems to form solid masses.

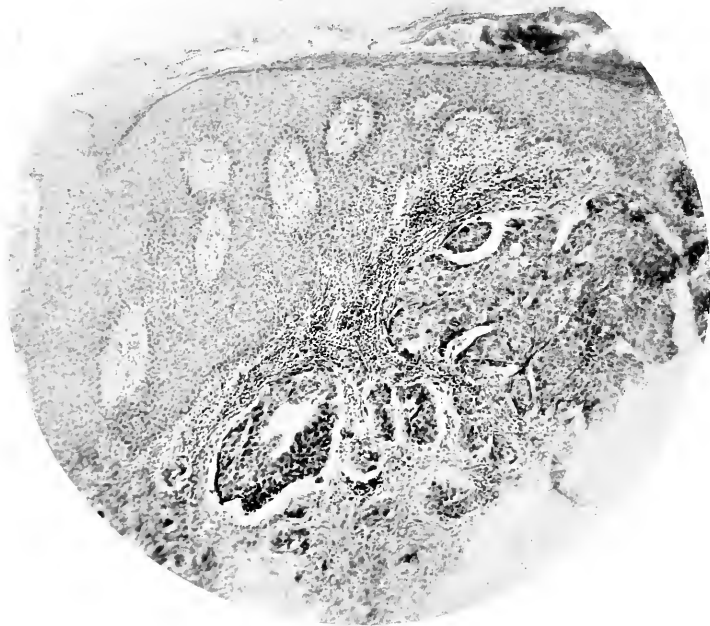

FIG. 185.—CARCINOMA OF THE UMBILICUS SECONDARY TO CARCINOMA OF THE OVARIES.

Gyn. No. 6150; Path. No. 2407. The umbilicus has been converted into a round, ulcerated area, with sharp edges and a granular base. The picture is taken from the indurated tissue near the edge of the ulcer. To the left is squamous epithelium, which in places is much thickened, but in the upper part of the picture is normal in thickness. On the surface is some exfoliated and partly hornified epithelium. Immediately beneath the skin the stroma shows considerable small-round-cell infiltration. The right half of the field consists of nests of cancer-cells. The floor of the ulcer to a large extent is made up of cancerous tissue. In many portions of the growth the typical glandular character of the tumor was evident. It was an adenocarcinoma.

There is no trace of ovarian stroma remaining. The growth is a virulent adenocarcinoma of the ovary. It is exceptional with such an early tumor to find such wide-spread metastases. The nodule at the umbilicus, although not examined histologically, was undoubtedly similar in origin. Whether the umbilical growth was due to extension upward from below or from above is problematic, but with metastases in the liver and extending down along the suspensory ligament to the umbilicus it looks very much as if the growth were secondary to the liver nodules.

Adenocarcinoma of the Ovary; Metastases to the Peritoneum and to the Umbilicus.—Gyn. No. 6150. A. H.,

admitted to the Johns Hopkins Hospital June 6, 1898. The patient, fifty-five years of age, was married twenty-six years ago. She has had no children and no miscarriages. The present illness began over a year ago. She has gradually grown weaker, and has not been able to work for a long time. She complains of abdominal enlargement, of marked constipation, and of a growth at the umbilicus.

At operation the parietal peritoneum was studded with small, whitish elevations, and the abdominal cavity contained several cystic masses reaching to the umbilicus. They could not be removed. The umbilicus itself had been converted into a round, ulcerated area with sharp edges and a granular base. This was excised when the abdomen was opened. The patient was much relieved by the operation and the tenderness over the abdomen disappeared.

Path. No. 2407. The specimen consists of fluid from the peritoneal cavity, of a small section of a cyst wall, and of the umbilicus.

Section from the Umbilicus.—The skin surrounding the umbilicus is perfectly normal. As one approaches the area of ulceration it is raised somewhat and becomes thickened, and the papillæ extend a certain distance downward. The tissue beneath the squamous epithelium is normal, but as one approaches the area of ulceration it shows small-round-cell infiltration around the capillaries. Near the edge of the ulcerated area one finds nests of epithelial cells which have retracted somewhat from the surrounding stroma (Fig. 185). In certain areas one can make out a definite gland arrangement. The growth is an adenocarcinoma with a tendency to form solid nests. As one passes to the ulcer, the squamous epithelium disappears. The surface is covered with fibrin, polymorphonuclear leukocytes, and small round-cells. The nuclei of the cancer-cells vary considerably in size. Some cancer-cells are large, stain deeply, and contain irregular masses of chromatin. The entire floor of the ulcer is made up of granulation tissue and nests of cancer-cells. The line of junction between the surface epithelium and the cancer is very sharply defined. In the depth of the ulcer the tissue consists almost entirely of nests of cancer-cells. The process has undoubtedly extended up from the abdomen as a wedge and raised the squamous epithelium. Over the area of carcinoma the skin has given way and an ulcer has resulted. The umbilical growth is identical in character with the ovarian tumor from which it originated.

After the book was in type and shortly before going to press the following interesting case came under my care:

Adenocarcinoma in the Omentum Incarcerated in an Old Umbilical Hernia (Plate V).—The primary growth was apparently in the ovary, possibly in the uterus. Mrs. Annie E., aged seventy-two, referred to me by Dr. Albert Singewald, was admitted to the Church Home and Infirmary September 28, 1915. The patient had had two children and one miscarriage. The menopause had occurred at forty.

Present Illness.—About four years before she had noticed vaginal bleeding, which had persisted up to the time of admission. For the last two or three months she had had profuse bleeding, lasting from three to four days. Between these attacks there had been a continuous thin, pinkish discharge. For the last two months she had suffered a great deal with pain over the sacrum and in the lower abdomen, and during the same time there had been pain on voiding. She had lost 25 pounds within the last two months.

The patient was a very large woman, weighing 235 pounds. She looked relatively well. On physical examination the abdomen was found much distended, but there was some laxness in both flanks. An umbilical hernia (Plate V) was noted, which presented a somewhat unusual appearance. It seemed somewhat lobulated, and the umbilicus itself was crescentic. The entire raised area measured about 5 cm. from above downward and about 4 cm. from side to side. It did not present the uniformity of outline so frequently noted in umbilical herniæ. On palpation it felt hard, and one could detect definite nodular thickenings in the hernial mass. These were apparently four or five in number, and immediately suggested metastatic nodules.

On carefully questioning the patient we learned that she had had an umbilical hernia since she was forty; in other words, for thirty-two years. During the last three months she had noticed that the hernia, which hitherto had been quite soft, had become gradually hard and nodular.

On abdominal palpation a definite tumor mass could be felt to the left of the umbilicus. Its exact dimensions could not be determined on account of the abdominal distention. In either flank fluctuation could be elicited.

I kept the patient in the ward several days, while debating whether any operative procedure should be undertaken. She was so anxious for relief that I finally consented to make an exploratory incision.

Operation October 1, 1915.—An elliptic incision was made around the enlarged and nodular umbilicus, and in the abdominal muscles just above the umbilicus was found a definite nodule, about 1 x 1.5 cm. After the umbilical growth had been freed from the abdominal wall, a tongue of omentum was discovered that passed into the hernial sac. This portion of omentum was intimately blended with the umbilicus and was removed with the sac. The parietal peritoneum everywhere was studded with carcinomatous nodules varying from 1 to 6 mm. in diameter. To the left of the umbilicus was an ovarian tumor which appeared to be about 16 cm. in diameter. The omentum was markedly thickened, and the greater part of it lay rolled up above the umbilicus. Loops of small bowel were adherent to the anterior abdominal wall near the symphysis, and also at other points, and here and there,

---

PLATE V.

CANCER OF THE UMBILICUS APPARENTLY SECONDARY TO A TUMOR OF THE OVARY.

Gyn.-Path. No. 21554. Mrs. A. E.

Fig. 1 gives the general relations as found at operation. At the umbilicus was the hard umbilical hernial mass containing cancerous nodules, and at operation a cancerous nodule was found in the mid-line just above the umbilicus.

To the left of the umbilicus was an ovarian tumor apparently cystic. The greater part of the omentum was rolled up and formed a tumor mass about midway between the xiphoid and the umbilicus. As there was a general peritoneal carcinosis and many adhesions, a more extended examination was not made.

Fig. 2 is an exact drawing of the umbilicus as it appeared before operation. The umbilical area is sharply raised from the surrounding abdominal walls, and the umbilical depression is represented by a crescentic slit. In this tumor four or five very hard nodules could be distinctly made out, at once suggesting malignancy.

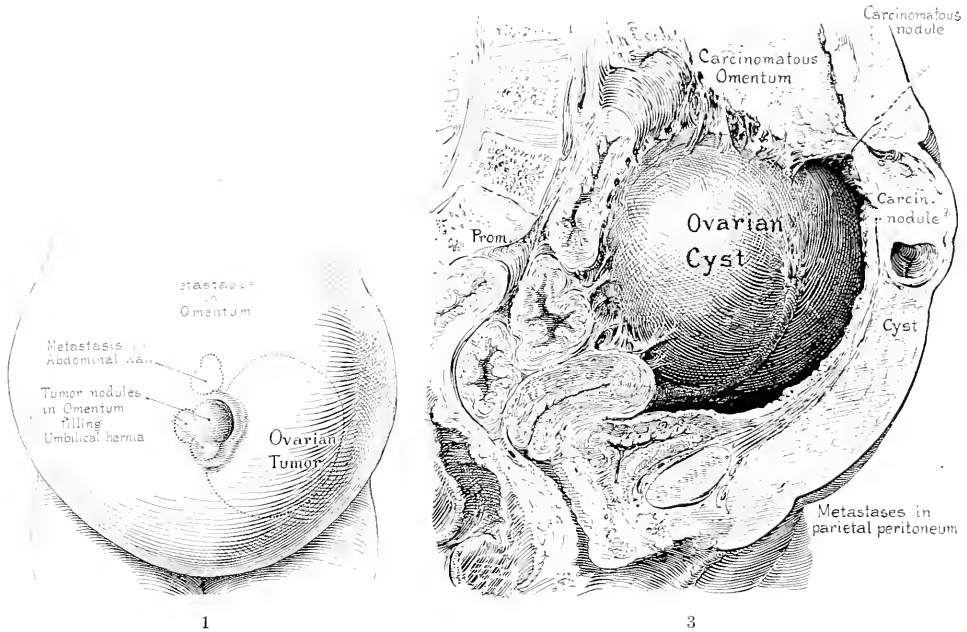
Fig. 3 graphically depicts the condition noted when the abdomen was opened. Occupying the left side of the lower abdomen is an ovarian cyst. This below and posteriorly is adherent. The omentum above the umbilicus is greatly thickened as a result of involvement in the carcinomatous process.

The lower end of the omentum fills the umbilical hernial sac. This portion of the omentum is also much thickened and has become intimately blended with the hernial walls. The incarcerated omentum is riddled with cancer. In the lower part of the omentum, that lies in the hernia, is a small cyst.

Fig. 4 shows a longitudinal section of the umbilical tumor. Between *a* and *a'* we see small carcinomatous nodules in the parietal peritoneum of the anterior abdominal wall. The omentum (*b*) projects into, completely fills, and is intimately blended with the hernial sac. In the upper part of the picture, where a catgut ligature is seen, the omental fat can still be fairly well recognized, but most of the omentum in the hernia looks very much like fibrous tissue. It was everywhere invaded by adenocarcinoma. The cyst (*c*) was lined with one or more layers of cancer cells. *d* indicates the lower limit of the hernial sac; *e* is the bottom of the crescentic umbilical slit seen in Fig. 2.

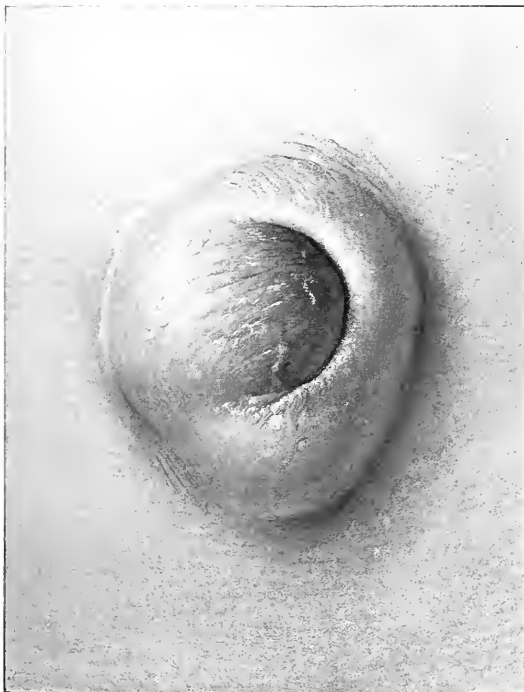PLATE V.

Cancer of the Umbilicus Apparently Secondary to a Tumor of the Ovary.

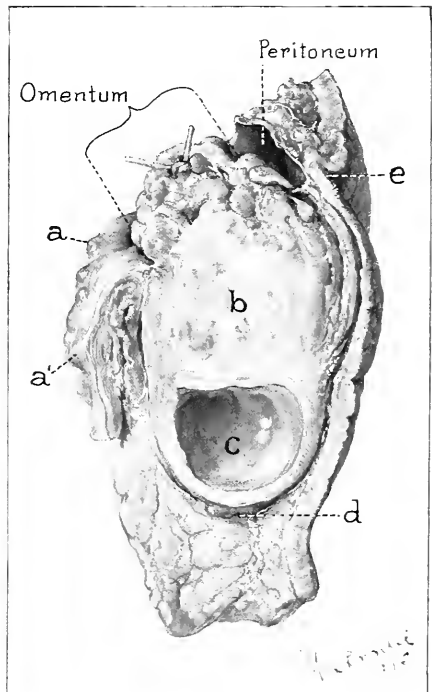


1

3



2



4

where such adhesions existed, the bowel was covered over with flakes of fibrin. Further examination being impossible, the abdomen was closed as soon as the umbilical growth had been removed.

The patient rallied remarkably well and left the hospital on October 23, feeling very much relieved.

Gyn.-Path. No. 21554. Sections involving the entire hernial mass show that the omentum which had extended into the hernia has become blended with the walls of the hernial sac, and that very little adipose tissue remains, the stroma consisting almost entirely of fibrous tissue, rich in spindle cells (Plate V, Fig. 4). Scattered through this are many glands occurring singly or in groups. In some places they are lined with one layer of epithelium, the cells being somewhat cuboidal or roundish and manifesting a tendency to drop off. In other places there are colonies of glands, some of the gland-spaces being partially or completely filled with epithelial cells. The nuclei of the epithelial cells vary markedly in size. Some of them contain large masses of deeply staining chromatin. The picture is that of an adenocarcinoma of a type usually noted in the ovary. The cyst-like space noted at one end of the umbilicus is lined with epithelium. In some places this is almost flat; in other places it is drawn up in papillary-like folds. In this case we have a definite adenocarcinoma of the umbilicus.

From the foregoing it is perfectly clear that the primary cancer was either in the ovary or in the uterus. The type of gland found in the carcinoma might well have been from either the body of the uterus or from the ovary. Uterine hemorrhage extending over a period of four years is somewhat unusual in so old a patient unless some serious uterine trouble exists. On the other hand, we all know that uterine hemorrhage is not infrequently associated with an ovarian tumor.

The presence of the ovarian tumor, with apparently thick walls, would strongly suggest the ovary as the primary seat of the trouble. Further, metastases from an ovarian carcinoma are not uncommon. Peritoneal metastases of such a character following a carcinoma of the body of the uterus I have never seen.

In all probability, then, this patient had a primary carcinoma of the left ovary; general peritoneal metastases had developed, and finally the omentum in the umbilical hernia had been invaded by carcinomatous nodules. Here they could be palpated with the utmost ease.

#### LITERATURE CONSULTED ON CARCINOMA OF THE UMBILICUS SECONDARY TO OVARIAN CARCINOMA.

- Aslanian, G.: Contribution à l'étude de la péritonite cancéreuse. Thèse de Paris, 1895, No. 150.  
 Burkhart, O.: Ueber den Nabelkrebs. Inaug. Diss., Berlin, 1889.  
 Cullen, Thomas S.: Gyn. No. 2004, from the records of the Johns Hopkins Hospital; Gyn. No. 6150, from the records of the Johns Hopkins Hospital.  
 Cullen, Thomas S.: Cancer of the Uterus, 1900.  
 Demons et Verdelet: Cancer secondaire de l'ombilic. Congr. périodique de gyn., d'obstét. et de paed., 1898, ii, 344.  
 Gueneau de Mussy: Cancer du péritoine. Clin. méd., 1875, ii, 28.  
 Liveing: Cancer of Ovaries and Peritoneum and Umbilicus. The Lancet, 1875, ii, 8.

#### CARCINOMA OF THE UMBILICUS SECONDARY TO CARCINOMA OF THE UTERUS.

Extension of carcinoma of the uterus to the umbilicus is exceptionally rare. In the examination of an unusually large number of cases of uterine cancer I have



never detected an umbilical involvement. Le Coniac,\* in his thesis on cancer of the umbilicus secondary to primary uterine or ovarian growths, says that in one case there existed between the cancer of the uterus and the umbilical tumor a chain of nodules along the anterior abdominal wall.

Catteau,† in his thesis in 1876, described the case of a young woman who had carcinoma of the body of the uterus. There were two nodules in the abdomen and a tumor the size of a filbert at the umbilicus. The inguinal glands were enlarged. In this case the umbilical growth was in all probability secondary to that in the uterus. These are the only two cases that I can find in any way suggesting cancer of the umbilicus secondary to a primary growth in the uterus.

Quénu and Longuet,‡ however, in their paper mention two cases of cancer of the uterus with secondary nodules at the umbilicus.

#### CASES OF SECONDARY CARCINOMA OF THE UMBILICUS IN WHICH THE SOURCE OF THE PRIMARY GROWTH WAS NOT DETERMINED.

These cases closely resemble those of secondary carcinoma of the umbilicus already considered. A few, however, present particularly well some of the salient points and other features not illustrated by the preceding cases.

In Bantigny's case a small, ovoid, sessile nodule was present at the umbilicus. The inguinal, axillary, and subclavicular glands on both sides were implicated.

In Chuquet's Case 3, at the umbilicus was a cancerous plaque, 10 by 5 cm., which was continuous with the induration in the suspensory ligament.

My case (G) was unusual, in that the umbilical changes had become apparent exceptionally early, there being merely a delicate papillary growth in the umbilical depression. This growth on section clearly shows the fibrous appearance of these tumors (Fig. 188, p. 441). The specimens from three others of these cases came under my personal attention. In Dr. W. T. Willey's case the growth was bluish red and very prominent, as seen in Fig. 186, p. 439. It showed areas of ulceration. Operation was contraindicated, and we were unable to get an autopsy. In Irving Miller's case the umbilical growth reached the surface of the umbilicus. Haggard's case is particularly striking on account of the large dimensions of the umbilicus (Fig. 190, p. 443), its general contour being still preserved. This tumor on section also clearly showed the apparent fibrous character of these growths. The carcinomatous structure would not for a moment be suspected from such a picture.

**Secondary Carcinoma of the Umbilicus.**—Bantigny's patient, § a man fifty-three years of age, six months before coming under observation, had noticed a tumor the size of a pea in the center of the umbilical depression. His digestion had been poor for some time, and he had had radiating pains in the umbilical region. There had been loss of appetite and progressive emaciation for two months. At the time of operation the umbilical nodule was the size of a small walnut, ovoid in form, and with a broad pedicle. It was purple in color, ulcerated, but apparently movable. The inguinal glands on both sides were enlarged. The subclavicular and axillary glands were also involved.

\* Le Coniac, H. C. J.: Cancer secondaire de l'ombilic, consécutif aux tumeurs malignes de l'appareil utéro-ovarien. Thèse de Bordeaux, 1898, No. 19.

† Catteau, J. F.: De l'ombilic et de ses modifications dans les cas de distension de l'abdomen. Thèse de Paris, 1876.

‡ Quénu et Longuet: Du cancer secondaire de l'ombilic. Rev. de chir., 1896, xvi, 97.

§ Bantigny, A.: Un cas de cancer de l'ombilic. Jour. des sci. méd. de Lille, 1898, 2. s., xxi, 91.

At operation the omentum was found adherent, and at its extremity was a small tumor the size of a pea, hard, and manifestly cancerous. Bantigny held that the umbilical cancer was secondary to some visceral growth.

**Carcinoma of the Umbilicus Secondary to Peritoneal Carcinosis.**—Chuquet\* bases his paper on general carcinosis of the peritoneum on 46 cases.

Case 3.—A woman, sixty years of age, two and one-half months before, had begun to complain of severe pain in the legs and in the inguinal region. At that time a painful, hard, and ulcerated enlargement at the umbilicus had been noticed. The ulceration was superficial and covered with a crust which dropped off at intervals. At the same time she had had a diarrhea lasting three weeks.

The abdomen was enlarged, and on examination an area of induration, 5 by 6 cm., could be felt at the umbilicus, and in the abdomen hard masses could be detected. Several glands were palpable in the inguinal region.

At autopsy several liters of ascitic fluid were found. The intestines were studded with small cancerous nodules. A large tumor was present in the omentum, which was adherent to the anterior surface of the stomach. At the umbilicus was an indurated plaque, 10 cm. long by 5 cm. broad, continuous with an induration in the suspensory ligament of the liver. The ulceration of the umbilicus was only superficial. Nodules were present in the pelvis and the liver. The mucosa of the stomach had not been invaded.

[Of course, in this case the primary site is still in doubt.—T. S. C.]

**A Malignant Growth of the Umbilicus, Apparently a Carcinoma Secondary to Some Abdominal Growth.**—Mrs. J. J., aged eighty, seen in consultation with Dr. W. T. Willey, October 5, 1910. This patient has had indigestion for years, more marked during the last few months. She rises early for her breakfast and then goes to bed for several hours on account of the uncomfortable sensation in the abdomen. For about ten years she has had uterine hemorrhages at irregular intervals. Her chief complaint is of pain and enlargement at the umbilicus.

Examination.—The umbilicus is rolled out and its right side is occupied by a bluish-red nodule, 3.5 cm. in diameter (Fig. 186). This presents a glazed appearance. In some places it is covered over with skin, but at a few points are little areas of ulceration, which, however, do not bleed much. If one attempts to roll the tumor out of the umbilicus, some pus escapes from the crevices. Surrounding the umbilicus is a zone of induration about 1 cm. in diameter. The umbilical tumor seems to be fairly well fixed.

On pelvic examination the uterus is found to be about four times the natural size. The cervix is normal.

It looks very much as if the growth at the umbilicus is a carcinoma, and that it is secondary to some abdominal growth. It is just possible that it may come from a carcinoma of the body of the uterus, but it is more probable that it is secondary to some growth in the stomach.

After considering the matter fully I decided against operation on account of the patient's age, and because there existed some inoperable growth in the abdomen.

The patient died a few months after my visit. No autopsy was permitted.

\* Chuquet, A.: Du carcinome généralisé du péritoine. Thèse de Paris, 1879, No. 548.

Carcinoma of the Umbilicus Secondary to an Abdominal Growth. (Personal communication from Dr. Irving Miller.)—E. M. was operated on at the Church Home and Infirmary on August 31, 1909. She was a woman fifty-eight years of age, married, and had had one child. At the lower end of the umbilical depression was a painless growth the size of a lentil, grayish red in color. There was a considerable amount of moisture. No nodule could be detected in the abdomen, and the patient had no indigestion. During the removal of the growth nodules were found in the omentum and mesentery. These varied

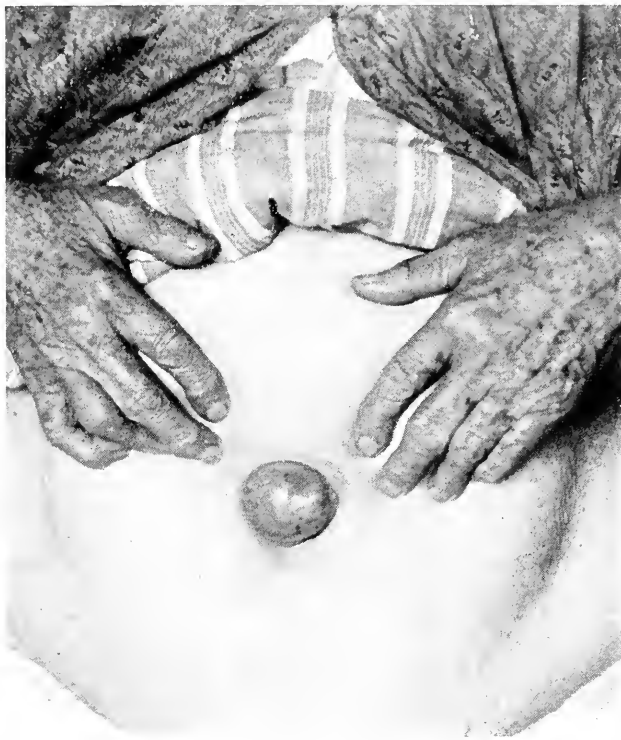

FIG. 186.—A MALIGNANT GROWTH OF THE UMBILICUS, APPARENTLY A CARCINOMA SECONDARY TO SOME ABDOMINAL GROWTH.

This photograph of Dr. Willey's patient was made by Dr. Cecil Vest. A growth occupies the site of the umbilicus; this is several centimeters broad, as indicated by comparing it with the fingers. The skin is still intact, but very thin, and over the dark areas is almost wanting.

from the size of a pea to that of a hazelnut. The peritoneum was free and there was no hernia.

Dr. Miller thought that the umbilical growth was secondary, but could not locate the original tumor. It did not emanate from the pelvis.

Path. No. 14122. The specimen measures 3 by 1 cm., and consists of tissue covered over with skin. Occupying the umbilical region is a firm nodule which, on section, has a whitish, fibrous appearance. The entire specimen resembles a large umbilicus.

On histologic examination the squamous epithelium in the vicinity of the umbilicus is perfectly normal and the underlying stroma unaltered. It ends abruptly,

and coming up from below and reaching the surface is a cancerous growth (Fig. 187). This is glandular in character, and consists of long, finger-like folds or of papillary masses or groups of glands. The cells are very regular, but mitotic figures are very abundant. Only at one point over a very limited area is the skin lacking. Here the cancerous tissue reaches the surface. It is covered with a moderate amount of fibrin in which are a few leukocytes. Certain portions of the tumor show small areas of calcification. It is without doubt a secondary carcinoma of the umbilicus. The picture present resembles very closely that found in cancer of

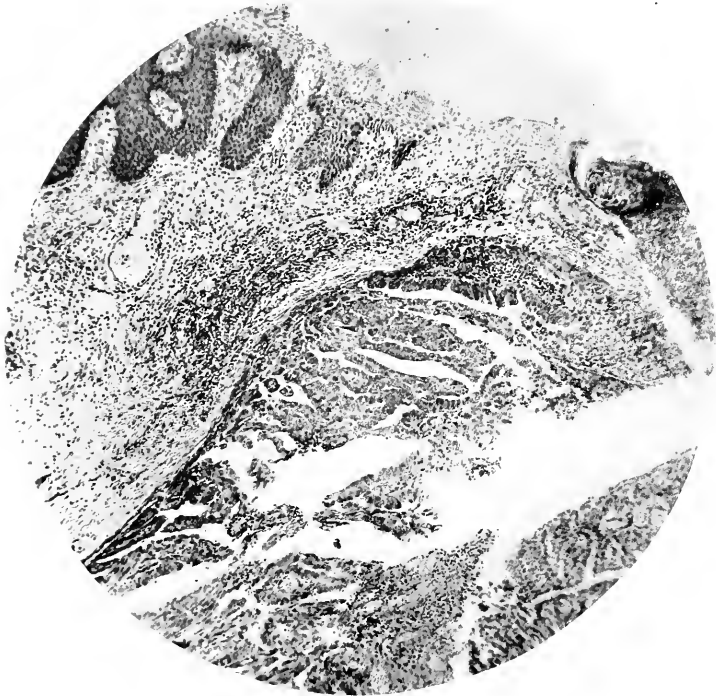


FIG. 187.—ADENOCARCINOMA OF THE UMBILICUS SECONDARY TO AN INTRA-ABDOMINAL GROWTH.

Gyn.-Path. No. 14122. (Specimen sent by Dr. Irving Miller, Baltimore.) The surface on the left is covered over with squamous epithelium, which shows little deviation from the normal. As we pass to the right the squamous epithelium gradually disappears, and on the extreme right the surface is composed of cancerous tissue. The right half of the picture shows a definite papillary or finger-like character of the growth. It is an adenocarcinoma. Along the advancing margins of the cancer the stroma shows much small-round-cell infiltration.

the body of the uterus. It is impossible for us, however, to determine absolutely the original source of the growth.

*Secondary Carcinoma of the Umbilicus; Metastases in the Right Inguinal Glands.*—Mr. G.,\* forty-two years of age, was seen in consultation August 30, 1904. The patient was well nourished, and complained of a discharge from the umbilicus. Six weeks before he had been struck in the abdomen with a shoe and the umbilicus had commenced to discharge three weeks later. The umbilicus itself presented a granular appearance (Fig. 188) and the tissue surrounding it was indurated. The patient had had dyspepsia for years;

\* This case was reported by me in the Jour. Amer. Med. Assoc., 1911, lvi, 391.

also pain in the lower abdomen over the appendix. He was admitted to the Church Home. Under anesthesia the inguinal glands were carefully palpated. A definite enlargement was found in the right side. An incision 10 cm. in length was made and the inguinal glands were removed, together with the surrounding fat. I then made a long elliptic incision around the umbilicus and removed the umbilical tumor, giving the hardened area a wide berth. The growth at the umbilicus closely resembled a retracted nipple. The patient took the anesthetic badly, and consequently I could not make as thorough an abdominal exploration as I desired. With the finger carried in all directions I was unable to detect any thickening.

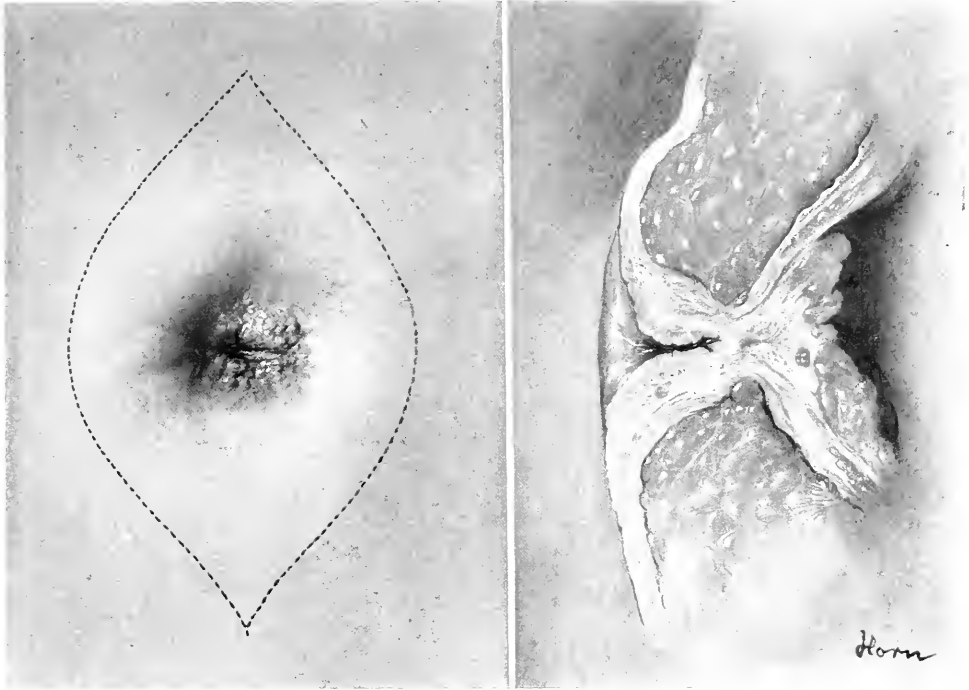


FIG. 188.—ADENOCARCINOMA OF THE UMBILICUS.

The umbilicus looks very much like an inverted carcinomatous nipple. The margins present a fine nodular appearance. The dotted line indicates the limits of the incision. On the right is shown a longitudinal section through the umbilicus. There is much thickening due to carcinomatous infiltration. The peritoneum beneath the umbilicus was free from adhesions. (Gyn.-Path. No. 7729.)

**Histologic Examination.**—Path. No. 7729.—The umbilical growth proved to be a typical adenocarcinoma. The squamous epithelium in many places was normal, but along the edge of the growth it was impossible to distinguish between the cells of the adenocarcinoma and those of the squamous epithelium. There was as yet little breaking down. The growth in the inguinal glands macroscopically looked like cancer (Fig. 189). On histologic examination it presented exactly the same pattern as that noted at the umbilicus.

On January 25, 1905, the patient was in fairly good health; but was still constipated and had great difficulty in defecation. On February 24th a firm globular mass fully 10 cm. in diameter was found occupying the middle of the abdomen and

the left inguinal glands were considerably enlarged. The umbilical growth was undoubtedly secondary to the intra-abdominal cancer. In May, 1905, I again saw the patient. His bowels had not moved for ten days, and he was so emaciated that one could hardly recognize him. Nodules were palpable everywhere in the abdomen. He died a few days later.

**Cancer of the Umbilicus.**—Haggard\* reports the case of a man fifty-nine years of age. Three months before admission the patient had noticed a hard nodule the size of a hickory-nut just above the umbilicus. The hardness

gradually increased, and the umbilicus commenced to bulge. The tumor was slightly tender, and there was a sense of uneasiness; it was the size of a goose's egg, was stony hard, and the skin could not be moved over it. The mass was fixed. The patient commenced to lose flesh.

Haggard removed the umbilicus February 17, 1904, making an elliptic incision. The resultant opening gaped nearly as large as a saucer. The stomach, gall-bladder, and liver were examined for cancer, but none was found. The gall-bladder was very hard and thickened and contracted down on a stone; this was removed and the gall-bladder drained. The peritoneum could not be approximated. The omentum was turned up and sewed to the serous margins of the incision. With considerable difficulty the fascia and muscle were partly brought together with interrupted sutures of catgut. The edges of the wound were still about  $1\frac{1}{2}$  inches apart. The silver wire filigree of Willard-Bartlett was

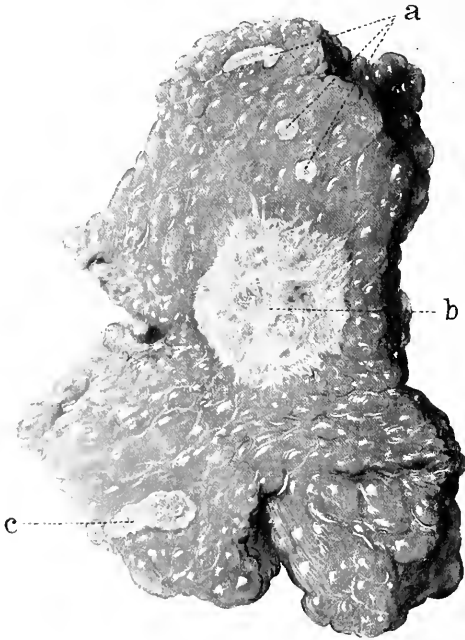


FIG. 189.—THE SECTION SHOWS CARCINOMA OF THE RIGHT INGUINAL GLANDS.

Scattered throughout the adipose tissue are several solid areas. Those indicated by *a* are small lymph-glands. The lymph-gland at *b* is greatly enlarged, and everywhere infiltrated by carcinoma which is invading the surrounding tissue; *c* is also an area of carcinoma. Fig. 188 shows the umbilical cancer in the same case.

used. This was laid on corduroy sutures of catgut, the edges resting between the fat and the fascia, and the skin was closed. The wound healed without incident.

**Secondary Adenocarcinoma of the Umbilicus.** †—Path. No. 15029.—The specimen sent me by Dr. Haggard, of Nashville, Tenn., in April, 1910, consists of the umbilicus with a good deal of surrounding tissue. The entire specimen measures 10 cm. in length, 7 cm. in breadth. The umbilicus is 2.5 cm. across and is covered with skin. It presents a rather uneven, nodular

\* Haggard, W. D.: Cancer of the Umbilicus. Amer. Jour. Surg. and Gyn., St. Louis, 1903-04, xvii, 196.

† This case was reported by me in Jour. Amer. Med. Assoc., 1911, lvi, 391.

surface, and is much more prominent than usual, having welled up in the center (Fig. 190). There is no evidence of ulceration at any point. On section the distance between the umbilicus and the peritoneal surface is 2 cm. The tissues look fibrous, and in the vicinity of the umbilicus show infiltration, apparently with fibrous tissue. At one point is an area of what looks like localized fibrous thickening, 2.5 cm. in diameter. The adipose tissue has been almost entirely replaced at this point.

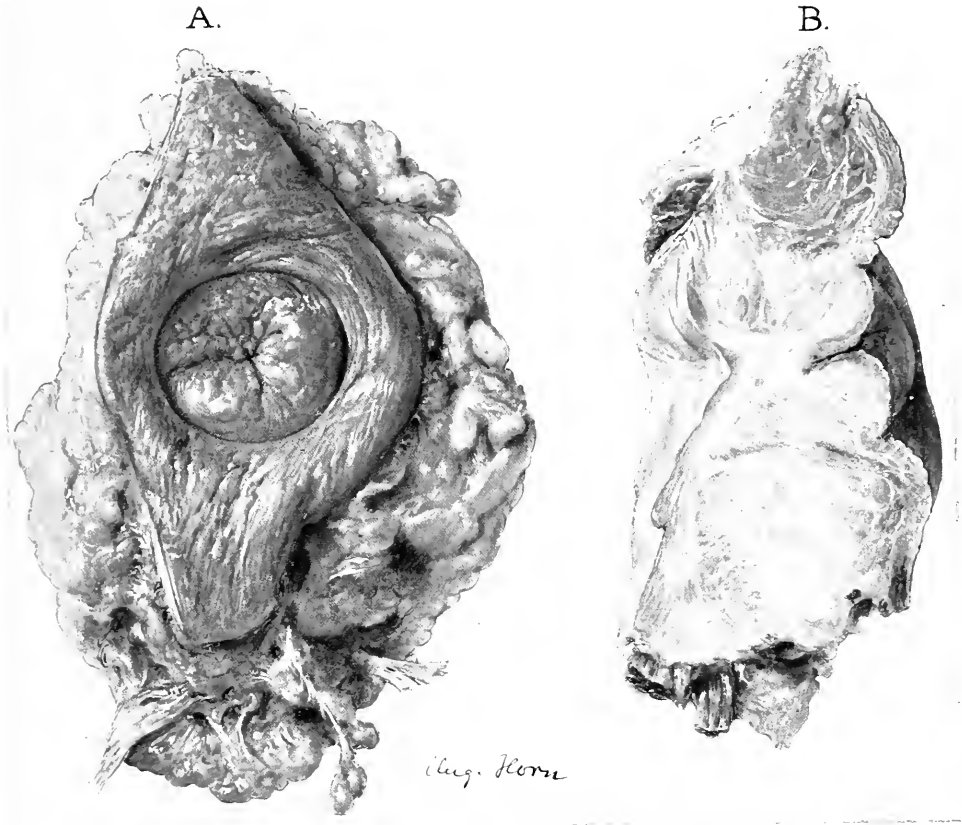


FIG. 190.—SECONDARY CARCINOMA OF THE UMBILICUS. (Natural size.)

Path. No. 15029. (Specimen sent by Dr. W. D. Haggard of Nashville, Tenn., April, 1910.) The umbilical fold is much widened, and the umbilicus is shallower than usual. It presents a somewhat uneven and nodular appearance, but is everywhere intact. On the right is shown a longitudinal section through the umbilicus. There is a deep cleft along the skin surface, and the umbilical fold is deeper than usual. The fat in the depth has been replaced to a large extent by fibrous tissue, which is everywhere infiltrated with carcinoma. The peritoneal surface, which is to the left, is perfectly smooth; there is no evidence of any adhesions.

**Histologic Examination.**—The squamous epithelium is intact, and there is pigmentation in the deeper layers, suggesting that the specimen has come from a colored patient. The tissue immediately beneath the skin in some places is normal; at other points it shows some small-round-cell infiltration. Scattered everywhere throughout the thickened fibrous tissue are glands. Some of them are small and round, others elongated or tubular; others are dilated. The glands are lined with cylindric or cuboid epithelium, which in most places is one layer in thickness. The

nuclei of the epithelial cells are for the most part oval and stain uniformly. A few of the epithelial cells have very large and deeply staining nuclei. Where the glands are dilated, the epithelium tends to become cuboid. At other points the glands are very abundant, are undergoing disintegration, and are filled with mucus. In some places the epithelium is several layers in thickness. Here and there gland epithelium has proliferated to such an extent that new glands are being formed. The growth is undoubtedly a carcinoma of a glandular type and similar to one originating either in the stomach or intestine.

**Encephaloid Cancer of the Umbilicus.\***—The umbilicus of an old man was occupied by a tumor the size of a fist, and presenting a bluish aspect. It was apparently adherent to the peritoneum and to the skin at the umbilicus. It was soft, but could not be moved at all without displacing the abdominal wall. The patient had lancinating abdominal pains. Demarquay diagnosed cancer of the umbilicus, but did not operate. The patient died.

**Cancer of the Umbilicus.**—Demarquay† with Dr. Roger saw a patient, sixty years of age, who had a soft and somewhat fluctuating tumor at the umbilicus. It was the size of two hands. It had originated at the umbilicus. It was opened at several points and fungating masses grew from it. A diagnosis of encephaloid cancer was made. The patient died. No histologic examination is reported.

**Cancer of the Omentum and Umbilicus Simulating Hernia. ‡**—Mary T., aged sixty-six, the mother of four children, had been in good health until four years previously, when she had noticed a projection at the umbilicus. This was the size of a finger-tip, and was pressed on by her stays. The bowels had been regular until one month before, when diarrhea had commenced. This had ceased without any treatment, but had returned two weeks later, accompanied by pain in the abdomen, especially at the umbilicus. Vomiting had then started, and the patient had rapidly grown worse.

After admission she vomited frequently. The vomitus had an offensive but non-fecal odor. The patient had an anxious expression. She was stout and well nourished; the abdomen was distended, tympanitic, and tender. There was a nodular projection in the left half of the umbilicus, half an inch in diameter. The overlying skin was normal, but immediately beneath the umbilicus and in the abdominal cavity was an ill-defined, very hard, slightly movable tumor, apparently continuous with that of the umbilicus. The patient on the twelfth day developed a temperature of 104° F. and died.

Autopsy showed invasion of the peritoneum by cancer. The mass involving the omentum had extended into the umbilicus. [This case at first simulated a small, strangulated umbilical hernia. There is no note as to the original site of the cancer.—T. S. C.]

**— Carcinoma of the Umbilicus. §**—A stout woman, forty-nine years of age, had had an umbilical hernia for a long time. Six months before she had received a slight injury of the umbilicus, and from that time the hernia had

\* Demarquay: Bull. Soc. de chir., 1870, 2. sér., xi, 209. Séance du 8 Juin.

† Demarquay: Op. cit.

‡ Forster, J. Cooper: Guy's Hospital Reports, 1874, 3. s., xix, 4.

§ Gallet, M. A.: Epithélioma de l'ombilic. Jour. de chir. et ann. Soc. belge de chir., Bruxelles, 1901, i, 565.



increased in size. On admission it was as large as an egg, hard, painful on pressure, and irreducible.

The umbilical growth was removed. The omentum was found adherent, and in it were enormous cancerous masses. Two large ovarian cysts were removed at the same time. At autopsy gall-stones were found. The intestinal tract was normal. Gallet thought the cancer was primary in the umbilicus. No microscopic examination, however, was given, as the case was reported at the society on the day of the operation.

[The umbilical growth was probably secondary.—T. S. C.]

**C a r c i n o m a o f t h e U m b i l i c u s .** — Küster\* reports a case personally communicated to him by Wilms. An old Israelite had a carcinoma of the umbilicus and died in consequence of digestive disturbances. The general history suggests that the umbilical growth was secondary.

**C a n c e r o f t h e U m b i l i c u s .** † — A young married woman, twenty-seven years of age, had a tuberculous peritonitis with effusion. In the region of the umbilicus was an ulcerated and hemorrhagic area. McMurtry opened the abdomen, evacuated the contents and took the umbilicus out through an elliptic incision. He diagnosed the case as one of fibroid carcinoma.

[In the absence of mention of a microscopic examination a possible tuberculous character of the umbilical lesion cannot be absolutely excluded.—T. S. C.]

**C a r c i n o m a o f t h e U m b i l i c u s .** ‡ — A man, fifty-four years of age, had carcinoma of the glands of the left groin for two years and intra-abdominal symptoms of malignant disease. For four weeks a small, very painful, fungating mass had been developing at the umbilicus. The umbilicus as a whole was not enlarged or hardened. From its center sprang a tuft of purplish-red granulation about as large as a small pea. Morris removed the umbilicus, and at the same time made an exploratory opening for examination of the abdomen. The omentum was the seat of a colloid carcinoma, but there were no adhesions of the omentum to furnish a route for infection to the umbilicus. The umbilical growth was an adenocarcinoma.

**C a n c e r o f t h e U m b i l i c u s .** — Nélaton§ speaks of a scirrhus of the umbilicus in a patient sixty years of age. It was spheric, regular, about 2.5 cm. in diameter. No microscopic examination was made.

**C a r c i n o m a o f t h e U m b i l i c u s S e c o n d a r y t o A b d o m i n a l C a r c i n o m a .** || — A woman, fifty-one years of age, had had an abdominal enlargement for fifteen months. In the right iliac fossa was a round enlargement increasing in size. Her digestion was poor, and she suffered from nausea and vomiting and lost weight. Blood and pus were present in the stools. One of the left inguinal glands was enlarged to the size of a hazelnut. The point of origin of the tumor was not certain. At the umbilicus was also a carcinomatous nodule the size of a walnut, hard and purple in color. In the vicinity there was another nodule.

\* Küster, E.: Die Neubildungen am Nabel Erwachsener und ihre operative Behandlung. Langenbeck's Arch. f. klin. Chir., 1874, xvi, 234.

† McMurtry, L. S.: Louisville Monthly Jour. of Med. and Surg., 1902-03, ix, 492.

‡ Morris, R.: Lectures on Appendicitis and Notes on Other Subjects, 1895, 96.

§ Nélaton: Squirrhe ombilical. Gaz. des hôp., Paris, 1860, xxxiii, 294.

|| Neveu, V.: Contribution à l'étude des tumeurs malignes secondaires de l'ombilic, Paris, 1890, No. 50.

The growth was an adenocarcinoma. Neveu then goes on to give a general résumé of the subject.

**Secondary Carcinoma of the Umbilicus.**—Pernice\* cites a case reported by Bergeat (Inaug. Dissert., Munich, 1883). A woman, sixty-one years old, for three years had had a tumor at the umbilicus which had ulcerated. The inguinal glands were swollen. At autopsy a tumor the size of a child's head was found, which projected into the abdomen. The gall-bladder was adherent and had opened into the tumor.

**Excision of Umbilicus for Malignant Diseases.** †—The patient, thirty-seven years of age, was thin and cachectic. At the umbilicus was a nodule the size of a hen's egg. It had been growing rapidly, was painful and ulcerated. Operation was advised, but the patient disappeared.

**Secondary Carcinoma of the Umbilicus.** ‡—A woman, fifty years of age, had been in perfect health until six months before, when she commenced to lose her appetite and have vomiting spells. In less than two months she had lost 15 kilos. A month before admission she had noticed a moderate-sized induration at the umbilicus. A few days later it had become dark red. She never had had any pain. The umbilicus was removed. No tumor was detected in the abdominal cavity. The specimen consisted of a violet-colored mass which had ulcerated, and there was induration of the surrounding tissue. On cutting through there was a gritty-like feel suggestive of carcinoma. The peritoneum covering the under surface was indurated, but smooth. There was no evidence of neoplasm in the abdomen. On histologic examination the growth proved to be a cylindrical-cell carcinoma. From the findings thus far the tumor might have been considered as primary. Three months later, however, the patient was suffering from hemorrhage from the bowels. The inguinal glands on both sides were enlarged, forming a definite mass. The patient became cachectic and soon died. The umbilical growth had evidently been secondary.

Quénu and Longuet gave the following data concerning cases with secondary carcinoma of the umbilicus

In 32 cases in which the sex is recorded, 23 of the patients were females—a proportion of 70 per cent. (To explain this Damaschino expressed the opinion that carcinoma of the umbilicus occurs secondarily to carcinoma of the uterus or the ovaries.) In 19 out of 36 cases in which accurate data were given, the primary growth was in the gastro-intestinal tract. Of these 19 cases, in 14 the growth was primary in the stomach, in 4 in the intestine, and in 1 in the stomach and intestine. In two cases the primary cancer was in the uterus, and in three cases the original tumor was found in the ovaries.

**Secondary Carcinoma of the Umbilicus.**—Verchère§ gives a short review of the literature and reports the case of a woman, fifty-five years of age, who for several days had had signs of intestinal obstruction. Her general health up to that time had been good. The abdomen was distended, and at the umbilicus was a tumor slightly smaller than half an apple. It was hard, red,

\* Pernice, L.: Die Nabelgeschwülste, Halle, 1892.

† Parker, Willard: Arch. Clin. Surg., New York, 1876-77, i, 71.

‡ Quénu et Longuet: Du cancer secondaire de l'ombilic. Rev. de chir., 1896, xvi, 97.

§ Verchère: De la valeur sémiologique du cancer de l'ombilic. Rev. des mal. cancéreuses, 1895-96, i, 81.

and ulcerated, but on the surface was smooth and regular. It was surrounded by a deep funnel, the walls of which were composed of healthy skin. Verchère thought it was a secondary growth, and made a rectovaginal examination, inquired for gastric and intestinal symptoms, and examined the anterior surface of the liver. All these examinations gave negative results. At operation he found, on the peritoneum of the anterior abdominal wall, many small, whitish-yellow, cancerous nodules. The primary source of the abdominal growth which had given rise to these metastases and to the secondary carcinoma at the umbilicus could not be located.

**A Adenocarcinoma of the Umbilicus.** \* — The patient was sixty-eight years old, and for nearly a year had had discomfort just above the umbilicus. This was almost continuous and was independent of digestion. At the umbilicus was an indurated area the size of a pigeon's egg. When the patient came under observation the induration was ovoid in form, 6 cm. in its longest diameter, and 4 cm. broad. It seemed to be a primary tumor of the abdominal wall. It was removed but the patient died of peritonitis.

On microscopic examination, according to Stori, the growth proved to be an adenocarcinoma.

**A Retroperitoneal Carcinoma Associated with Cancer of the Umbilicus.** — From the accompanying history it appears that the primary growth was retroperitoneal. From what epithelial structure it originated, it is, however, impossible to say.

MacMunn's<sup>†</sup> patient was a woman sixty-three years of age. She was cachectic and had a "mouse smell." The lymphatics in the left groin were of stony hardness and considerably enlarged. At the umbilicus was a hemispheric tumor, purplish in color, the size of a plum. It was firm, and had on its surface two small ulcers. When lifted up, the tumor could readily be isolated from the deeper structures.

At autopsy the umbilical growth was found to be bluish or grayish white and hard; it projected through the abdominal wall, raised the peritoneum slightly, but was not adherent to the structures. A few small, whitish nodules were found between the umbilicus and the pubes. The omentum contained nodules, the largest  $2\frac{1}{2}$  by  $\frac{1}{2}$  inch. Secondary growths were also present in the mesentery. The umbilical growth was undoubtedly secondary to the retroperitoneal tumor.

\* Stori, Teodoro: Contributo allo studio dei tumori dell' ombelico. *Lo Sperimentale, Arch. di biologia normale e patologia*, 1900, liv, 25.

† MacMunn: Case of Retroperitoneal Cancer Accompanied by Cancer of the Navel. *Dublin Jour. of Med. Sci.*, lxxii, 1876, 1.

#### LITERATURE CONSULTED ON CASES OF SECONDARY CARCINOMA OF THE UMBILICUS IN WHICH THE SOURCE OF THE PRIMARY GROWTH WAS NOT DETERMINED.

- Bantigny, A.: Un cas de cancer de l'ombilic. *Jour. des sci. méd. de Lille*, 1898, 2. s., xxi, 91.  
 Chuquet: Du carcinome généralisé du péritoine. *Thèse de Paris*, 1879, No. 548.  
 Cullen, Thomas S.: Dr. W. T. Willey's case: Secondary Carcinoma of the Umbilicus.  
 Cullen, Thomas S.: Dr. Irving Miller's case: Secondary Carcinoma of the Umbilicus.  
 Cullen, Thomas S.: Personal case.  
 Cullen, Thomas S.: Surgical Diseases of the Umbilicus. *Jour. Amer. Med. Assoc.*, February 11, 1911, lvi, 391.  
 Haggard, W. D.: Cancer of the Umbilicus. *Amer. Jour. Surg. and Gyn.*, St. Louis, 1903-04, xvii, 196.

- Demarquay: Cancer de l'ombilic. Bull. Soc. de chir., 1870, 2. sér., xi, 209. (Séance du 8 Juin.)
- Forster, J. C.: Cancer of the Omentum and Umbilicus Simulating Hernia. Guy's Hospital Reports, 1874, 3. s., xix, 4.
- Gallet, M. A.: Epithéliome de l'ombilic. Jour. de chir. et ann. Soc. belge de chir., Bruxelles, 1901, i, 565.
- Küster, E.: Die Neubildungen am Nabel Erwachsener und ihre operative Behandlung. Langenbeck's Arch. f. klin. Chir., 1874, xvi, 234.
- McMurtry, L. S.: Cancer of the Umbilicus. Louisville Monthly Jour. Med. and Surg., 1902-03, ix, 492.
- Morris, R.: Carcinoma of the Umbilicus. Lectures on Appendicitis and Notes on Other Subjects, 1895, 96.
- Nélaton: Squirrhe ombilical. Gaz. des hôp., Paris, 1860, xxxiii, 294.
- Neveu, V.: Contribution à l'étude des tumeurs malignes secondaires de l'ombilic. Paris, 1890.
- Pernice, L.: Die Nabelgeschwülste, Halle, 1892.
- Parker, W.: Excision of Umbilicus for Malignant Diseases. Arch. Clin. Surg., New York, 1876-77, i, 71.
- Quénu et Longuet: Du cancer secondaire de l'ombilic. Rev. de chir., 1896, xvi, 97.
- Stori, T.: Contributo allo studio dei Tumori dell' ombelico. Lo Sperimentale, Arch. di biologia normale e patologia, 1900, liv, 25.
- Verchère, F.: De la valeur séméiologique du cancer de l'ombilic. Rev. des maladies cancéreuses, 1895-96, li, 81.

## CHAPTER XXVI.

### SARCOMA OF THE UMBILICUS.

Telangiectatic myxosarcoma.  
Spindle-cell sarcoma of the umbilicus: report of cases.  
Round-cell sarcoma of the umbilicus.  
Melanotic sarcoma of the umbilicus.

THE literature on this subject is in a very chaotic condition. From the recorded cases it is possible to make the following classification:

1. So-called telangiectatic myxosarcoma occurring at or near the time of birth. This in reality is not malignant.
2. Spindle-cell sarcoma.
3. Round-cell sarcoma.
4. Melanotic sarcoma.

At best my description of sarcoma of the umbilicus will be fragmentary and incomplete. I shall give abstracts of the more characteristic cases recorded, so that the reader may draw his own conclusions. After careful histologic studies of such cases in the future it is to be hoped that before many years the subject of sarcoma of the umbilicus will be placed on a clear and satisfactory basis.

#### TELANGIECTATIC MYXOSARCOMA.

Cases of this nature have been reported by Virchow, Kaufmann, and von Winckel. In 1864 Gerdès saw a child, a few hours old, with a horn-like projection from the umbilicus. It was four inches in length and about the thickness of the index-finger, and gradually tapered to the end. At first it was bright red in color, later dark. It was very smooth, had an abundant blood-supply, was rather firm, had no pulsation, and on compression did not diminish in size. The growth was composed of spindle-cells separated from each other by a mucous intercellular substance. Virchow termed it a telangiectatic myxosarcoma.

In Kaufmann's case, reported in 1890 (Figs. 191 and 192), the tumor was likewise present at birth, and in the course of a few days was observed to grow gradually. It projected 6 cm. from the abdominal wall and was 16 cm. in circumference. It was partly covered with skin, partly with amnion. Its outer portion was dense; its central part cavernous. On histologic examination the former was found to consist of spindle-cells, the latter of myxosarcomatous tissue. The angiomatous appearance in the central portion was due to the great dilatation of the arteries.

Von Winckel in 1893 observed a red tumor at the umbilicus in a new-born child. This tumor (Fig. 194) was 4 cm. long, and at the umbilicus 2.8 cm. in diameter. It was bright red in color. Its surface was covered with what appeared to be a hyaline membrane. The growth was composed chiefly of spindle-shaped cells. There was an abundance of large blood-vessels, and, in addition, large lymph-spaces. At certain points the endothelium of the lymph-spaces had proliferated.

These endothelial cells were markedly enlarged and projected into the lumina of the lymphatics. The stroma-cells in the vicinity were very large (Fig. 195), but the majority of them contained no nuclei and looked more like cells undergoing degeneration. This case, apart from dilatation of the lymphatics, bore a striking resemblance to those reported by Virchow and Kaufmann. Abstracts of Kaufmann's and von Winckel's cases are appended.

**A Congenital Umbilical Tumor.\***—On the second day after birth Lissner saw the child. The mother was forty-eight years of age, strong, and well nourished. The patient was the twelfth child. The labor had been easy, and the umbilical tumor had caused no hindrance. At first it was small, but by the end of twenty-four hours had grown markedly. When seen, it was the size of an apple, reddish in color. The skin of the abdomen extended up for some distance on the sides of the tumor. The remaining portion of the tumor was covered over with amnion, which was continued upon the umbilical cord. The tumor was firm in consistence, and on pressure could not be rendered smaller. After six days it had grown a good deal and there had been bleeding from it, which had been



FIG. 191.—TELANGIECTATIC MYXOSARCOMA OF THE UMBILICUS. (After Kaufmann.)

This is from the specimen after it had been hardened in alcohol. Below and to the left one sees where the tumor has been amputated from the umbilicus. To the right is the attachment of the cord. Here the tumor was partly covered with amnion.

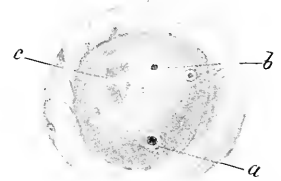


FIG. 192.—APPEARANCE OF THE UMBILICUS AFTER REMOVAL OF THE TUMOR SHOWN IN FIG. 191. (After Kaufmann.)

*a*, The umbilical vein; *b*, cross-section of the umbilical artery; *c*, cross-sections of other arteries.

checked by the use of styptics. Under chloroform narcosis three needles were passed through the base of the tumor and a bichlorid silk thread was tied around it. The tumor was then cut away, and the wound dressed antiseptically. Six days later the remnant of the tumor was recognized as a thick, brown, hard, dry, mummified crust, which came away readily. Healing took place rapidly.

The tumor (Fig. 191) was firm in consistence, almost round, 16 cm. in circumference, and reached a height of 6 cm. At its base, where it passed to the umbilical ring, were seen cross-sections of the umbilical arteries and of the umbilical vein. The latter contained a red thrombus. In addition there were cross-sections of other blood-vessels (Fig. 192).

Near the surface the tumor is everywhere dense and fibrous. In the middle portion it is of a myxomatous character, and in this myxomatous tissue are numerous blood-vessels, some of which present a cavernous appearance (Fig. 193).

\* Kaufmann: Ueber eine Geschwulstbildung des Nabelstrangs. Virchows Arch., 1890, cxxi, 513.

Beneath the surface epithelium the cells are partly round, but to a great extent spindle-shaped. These spindle-cells are narrow and often long, resembling muscle-fibers, but the nuclei are more delicate. From the picture Kaufmann concludes that it is a spindle-cell sarcoma. As one nears the center of the tumor the spindle-cells become more sparse and we have a picture of myxomatous tissue. It is in the




FIG. 193.—MYXOSARCOMA OF THE UMBILICUS. (After Kaufmann.)

This is a low-power picture of Fig. 191. At *a*, where we should have the epithelial covering, it has been rubbed off. Beneath this the tumor is dense and consists of spindle-cells. The central portion, *d*, is composed of mucoid-like tissue containing large arterial sinuses.

myxomatous portion of the tumor that the blood-vessels have increased in size and that a cavernous appearance is noted. Some of the blood-vessels show many branchings—some narrow, others wide. A few of the vessels are still filled with blood. The cavernous appearance is due to dilated arteries. Kaufmann designates the tumor as a myxosarcoma telangiectodes, and speaks of its resemblance to the case reported by Virchow.

A Congenital Solid Tumor of the Umbilical Portion of the Cord. — On December 16, 1893, von Winkel\* saw a female child, 49 cm. long and weighing 2500 grams. At the margin of the umbilical cord, immedi-

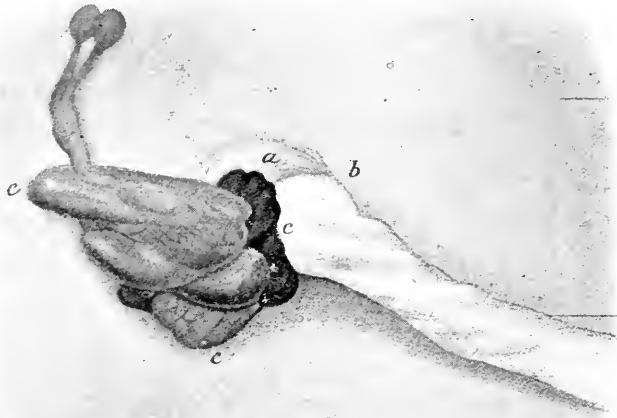

FIG. 194.—TELANGIECTATIC MYXOSARCOMA PROJECTING FROM THE RIGHT SIDE OF THE UMBILICUS. (After v. Winkel.)  
a, The cord; b, the margin of the amnion over it; c, the telangiectatic myxosarcoma.

ately after labor, a tumor had been noted (Fig. 194). This was firm in consistence, bright red in color, and had here and there a bluish, translucent surface. Near the

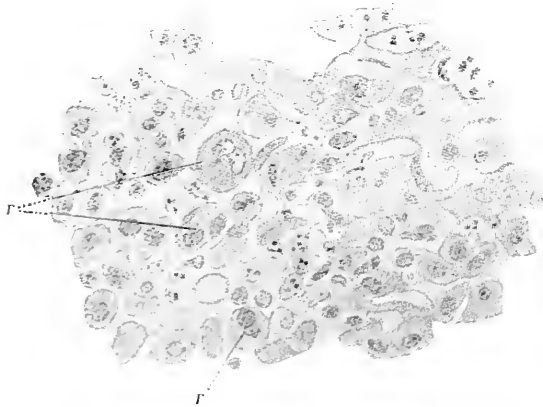


FIG. 195.—A TELANGIECTATIC MYXOSARCOMA. (After v. Winkel.)  
The section is from the tumor seen in Fig. 194. It consists of very large, well-defined cells. r, r, Giant-cells. Here and there between the cells are a few leukocytes.

free end were two fine threads with small bodies the size of linseeds on their surfaces. The entire tumor was 4 cm. long, at its base, 2.8 cm. thick, and near the end, 1.6 cm. in diameter. The tumor was removed with the cautery, and the peritoneum opened for a breadth of from 2 to 5 mm., a small quantity of serous fluid escaping. The operation did not last over fifteen seconds. A compression band was applied, and the child made a satisfactory recovery. Fourteen days later, however, she died suddenly of pneumonia.

The outer surface of the tumor was covered with what appeared to be hyaline membrane, which contained connective-tissue nuclei in large or small numbers. Beneath the surface there was a net-like arrangement of threads consisting of

\* von Winkel: Ueber angeborene solide Geschwülste des (perennirenden) Theiles der Nabelschnur. Sammlung klin. Vorträge, n. F. No. 140. (Gyn. Nr. 53.)



connective-tissue nuclei and leukocytes. In the superficial layers of the tumor there was an abundance of large blood-vessels. In addition there were lymph-vessels showing a definite endothelial lining. These contained fibrin threads and leukocytes. The endothelium of the lymphatics appeared to be proliferating. The endothelial cells were markedly enlarged and projected into the lumen; here and there they contained mitotic figures. In the vicinity of these lymph-spaces, in the connective tissue, spindle-shaped cells were seen, between which there appeared to be some fluid. There were also large epithelioid cells in the stroma (Fig. 195). These stained with hematoxylin-eosin a diffuse violet. The majority contained no nuclei and resembled degenerated tissue-cells.

In the pedicle of the tumor a similar structure was noted. The large, deeply tinged cells, however, were lacking. The blood-vessels were abundant. Von Winckel said that, from the description of his case, there was no doubt that he was dealing with a telangiectatic myxosarcoma similar to those reported by Virchow and Kaufmann.

From a careful study of these cases it would appear that they bear a marked resemblance to those considered under angiomas of the umbilicus, and that, in all probability, they should be included in that class. They do not seem to be malignant.

#### SPINDLE-CELL SARCOMA OF THE UMBILICUS.

Only a few instances have been recorded, and, as pointed out by Nicaise, Pernice, and others, even in such cases careful histologic reports are usually lacking. Spindle-cell sarcoma of the umbilicus would appear to be the most common variety, and the growth has been designated as a spindle-cell sarcoma, a fibrosarcoma, a myxosarcoma, or a sarcoma fibrocellulare.

Firm connective-tissue growths of the umbilicus are relatively rare. They may occur in the young, middle-aged, or old. They usually are oval or round, and may slowly or rapidly reach the size of a fist or an orange. As a rule, they have an intact skin covering. This may be normal, have large veins coursing over its surface, or the skin may show a purple discoloration. Occasionally, as a result of irritation, the surface of the tumor may be slightly ulcerated. The tumor may be sessile or somewhat pedunculated.

Clinically, it is almost impossible to determine whether such a growth is a fibroma or a spindle-cell sarcoma unless metastases occur; and, even if a nodule develops in the abdominal wall, several months or a year or more after the tumor has been removed, there is still the possibility that this second nodule may be a fibroma.

On section, most of these tumors have a fibrous appearance, few of them presenting the homogeneous, pork-like surface so characteristic of sarcoma. If, on histologic examination, the cells contain large, irregular nuclei with deeply staining chromatin, or if nuclear figures are abundantly distributed throughout the tumor, the diagnosis of sarcoma is clear. If, on the other hand, only quiescent spindle-cells are in evidence, it is absolutely impossible to make the diagnosis from the histologic findings, and the surgeon remains in the dark as to the exact character of the tumor, unless its malignancy is clearly shown by the later development of metastases.

Where the sarcoma of the umbilicus is secondary, the growth may tend to spread out into the abdominal wall and will not be so prominent and well defined.

CASES REPORTED AS INSTANCES OF SPINDLE-CELL SARCOMA OF THE UMBILICUS.

Some of these tumors were clearly sarcomatous; others in all probability were fibromata. The reader can draw his own conclusions as to the proper diagnosis in each case. Those cases that were clearly instances of fibroma, although previously classified as sarcoma, are included under fibromata, while quite a number in which not even a probable diagnosis could be made have been entirely omitted.

*Spindle-cell Sarcoma of the Umbilicus.*\*—This tumor was removed by Wehsarg from the umbilical region of a poorly nourished girl aged fourteen. The tumor had grown slowly until three or four years before, when it had suddenly become painful and rapidly grown to the size of a fist. At operation it was round and the size of an orange, smooth, smaller at its base, and slightly pendulous, the umbilicus being pushed down. The skin over the tumor was very thin, bluish red in color, and there were numerous dilated veins. The lower part of the tumor showed several excoriated ulcerated plaques covered with clots and pus. The tumor was removed. It lay on the superficial fascia of the abdominal wall. On section it was yellow, homogeneous, and resembled pork, with here and there darker places surrounded by vessels. Microscopically it proved to be a spindle-cell growth.

*Possible Sarcoma of the Umbilicus.*—Villar† describes the case of a woman aged forty-six who entered the service of Professor Guyon, September 17, 1886. About December, 1885, she had noticed that her corsets produced pain in the umbilical region, and on examination had found a small, reddish tumor the size of the head of a pin in the umbilical depression. This tumor grew slowly. In May, 1886, the patient presented herself at the hospital for examination. In August, after she had been using iodine without any results, she again came to the hospital. Examination at this time showed that, at the umbilical depression, was a tumor the size of a small bird's egg, but different in form. It was conic, with its base continuous with the umbilical cicatrix. It was slightly pedunculated, firm in consistence, but elastic and reddish in color. At its top was a blackish point 2 mm. in diameter. There was no discharge from the tumor. Two or three days later the blackish point ruptured and there was an escape of dark blood. No glandular enlargement was detected. The tumor was removed. The tumor in question was a little less firm than a fibroma. On section a capsule was found surrounding the central mass. The tumor was whitish gray and had numerous dark spots no larger than the head of a pin scattered throughout it.

Histologic examination showed that the capsule was formed of connective tissue. The central portion of the tumor was composed of sarcomatous tissue, the cells being fusiform. In the center of the tumor there were cavities lined with pavement-cells. These cavities presented various forms. Some were round, others were oval and had anastomosed with one another. In the stroma between the spaces were a small number of blood-vessels. The skin covering the outer surface of the tumor was exceedingly thin, but presented the usual appearance. In the center there had been some extravasation of blood recognizable by deposits of pigment.

[This woman was forty-six years of age. Although the description is not per-

\* Leydhecker, F.: *Zur Diagnose der sarcomatösen Geschwülste*, Giessen, 1856.

† Villar, Francis: *Tumeurs de l'ombilic*. Thèse de Paris, 1886, obs. 68.

fectly clear, it bears somewhat the ear-marks of the case reported by Mintz—a case that proved to be an adenomyoma of the umbilicus (see Fig. 174, p. 381). It does not tally with our usual idea of sarcoma.—T. S. C.]

A Case of Myxosarcoma of the Umbilicus.—Plagge\* reports the case of a man, twenty-two years of age, who in childhood had had difficulty in digestion and later vomiting and diarrhea. In the summer of 1887 he had pain in the stomach for the first time and noticed a small tumor in the umbilicus. By November, 1887, the tumor was the size of a hazel-nut. Four weeks later there was a nodule the size of a pea below and to the left, close to the linea alba. The patient was much emaciated. He died on March 14, 1888. At autopsy, at the umbilicus a thickening the size of a five-mark piece was noted rising 2 cm. above the abdominal level. Above and below, this thickening could be followed 5 cm. in each direction; the skin was movable over it. On examination of the abdominal cavity in the region of the umbilicus was a nodule, 2 mm. in diameter. In the ligament passing from the umbilicus was a small nodule. The omentum, diaphragm, and intestines were involved. The stomach was normal.

Microscopic examination showed that the growth was a myxosarcoma.

[If this had been a primary malignant growth, why had it not broken down? The clinical picture in no way indicates a primary growth. The histologic appearance suggests very much a colloid carcinoma of the intestine with a secondary growth at the umbilicus.—T. S. C.]

Sarcoma at the Umbilicus. †—An East Indian male, aged twenty-four years, was admitted on June 2, 1889. Several weeks before, April 5th, he had exposed himself to the night air after returning from a party. The next morning he felt pain in and around the umbilicus. Two weeks later a small, hard swelling was detected in the navel, and in a few days an unpleasant sensation in this region caused vomiting. The swelling was considered inflammatory in origin, and local applications were made. On examination a subcutaneous growth the size of a hen's egg was found situated exactly at the umbilicus. The skin covering it was deep purple and firmly adherent. The growth was apparently deeply attached by a pedicle fixed to the right side of the umbilicus. A few hard bosses were noted over the surface of the tumor, and a nodule the size of a hazel-nut, detected on the right abdominal wall, was apparently connected with the tumor. This nodule was situated about three and a half inches from the umbilicus. The secondary growth had only recently been noted. Both tumors were tender to the touch.

The main growth and the secondary nodule were removed, but the abdomen was not opened. The patient did not improve, but became profoundly cachectic. About a month after operation a small, freely movable nodule was felt in the subcutaneous connective tissue, about an inch from the abdominal incision below the umbilicus. Soon after, another was noted in the left rectus, close to the cartilage of the ribs. This increased rapidly; there was great nausea and occasional vomiting, suggesting dissemination in the diaphragm. [Microscopic examination showed that the umbilical growth was a fibrosarcoma. The abdomen was not opened. The secondary growth proved the malignancy of the condition, and the vomiting and loss of weight strongly suggested a primary abdominal growth with secondary manifestations at the umbilicus.]

\* Plagge, Heinrich: Ein Fall von Myxosarcom des Nabels. Inaug. Diss., Freiburg, 1889.

† O'Brien, Surgeon-Major: Indian Med. Gaz., 1889, xxiv, 215.

A Supposed Sarcoma of the Umbilicus. — Neveu\* reported an unpublished case of Monnier's. The patient was a woman fifty years old. She had a uterine growth which extended to the umbilicus. The curet showed sarcoma fusocellulare. Implicating the umbilicus was a mass the size of a hazelnut. No microscopic examination of the umbilical growth was made.

[It is often very difficult, when examining a submucous myoma, to determine whether it is really a spindle-cell sarcoma or a simple myoma. Without an examination of the umbilical nodule we should hesitate to accept this as representing a nodule secondary to the growth in the uterus.—T. S. C.]

Sarcoma of the Umbilicus. — Pernice† reports the cases of Blum, Bryant, and Villar. None of the descriptions seem to me to be convincing enough to warrant the growths being included as sarcomata.

Pernice then reports from the Halle Clinic the case of R. Schroeder, aged nineteen. As a child she had a small tumor at the umbilicus. It was not painful and did not grow until the thirteenth year; it was then extirpated. Two years later a new tumor appeared, and, when she was admitted to the hospital, it was the size of a baby's head and was covered with intact umbilical skin. The tumor shone through the skin and was hard. The inguinal glands were not enlarged. The abdomen was widely opened during removal of the tumor, and the patient recovered. About three years later she was in good condition, but shortly afterward a return of the growth was noted. This tumor was the size of a small apple when the patient came back to the hospital. It was situated in the upper angle of the previous incision.

No histologic examination was given. This tumor had not yet been removed when Pernice reported the case.

[Pernice then goes on to report several other cases, none of which would appear to be an undoubted instance of sarcoma.

Although it is quite possible that the growth reported by Pernice was a sarcoma, we must remember that it may equally well have been a fibroma. Where one fibroma develops, others are prone to occur.—T. S. C.]

Possibly a Sarcoma of the Umbilicus. — Sourdille‡ reports the case of a man, forty-nine years of age, who entered Polaillon's service at the Hôtel-Dieu March 25, 1895. Eighteen months before he had noticed at the umbilicus small tubercles. These caused him some pain and inconvenience. On admission, attached to the lower border of the umbilicus was found a pedunculated cylindrical tumor, 5 cm. long and 12 to 13 mm. in diameter. Its free end was covered with a small crust over a healed ulceration. The skin covering it was delicate, thin, reddish in color. When grasped between the fingers, the tumor gave the sensation of a finger of a glove filled with hazelnuts. The skin surrounding the tumor contained seven or eight pink tubercles, about the size of green-peas. The skin was movable on the underlying aponeurosis. No enlargement of the glands could be made out. The patient's general health was good. The diseased area was removed.

On histologic examination the main tumor and the small nodules gave a picture of sarcoma fusocellulare covered with skin. The superficial half of the skin seemed

\* Neveu: Contribution à l'étude des tumeurs malignes secondaires de l'ombilic, Paris, 1890.

† Pernice, L.: Die Nabelgeschwülste, Halle, 1892.

‡ Sourdille, Gilbert: Sarcome pédiculé de la peau de l'ombilic. Bull. de la Soc. anat. de Paris, 1895, lxx, 302.

to be the starting-point of the tumors, which tended to pass out and become pedunculated.

[This growth may equally well have been a fibroma with very small nodules. The microscopic examination was not very extensive.]

**Primary Sarcoma of the Umbilicus.**—Garnier\* reports for Blanc the case of an otherwise healthy man fifty years old. Six months previously he had noticed a small, hard, painless tumor in the right border of the umbilical depression. It was independent of the skin, and was the size of a hazelnut. The patient had some colic, but no constitutional trouble. He thought that the pain in the pyloric region was due to pressure of the growth on the pylorus. He had lost in weight in the last month.

On admission the tumor was the size of a mandarin orange, round, and was carrying the unfolded umbilicus on its surface. It was hard, painless, and firmly fixed by the contraction of the abdominal muscles. The overlying skin was purple.

At operation it was found that the tumor had developed in the deeper layers. The underlying peritoneum was perfectly smooth, and the tumor was easily removed. Blanc regarded it as a great rarity, this being the first instance observed. He based his assumption that the growth was primary on the absence of functional trouble and on the relative integrity of the patient's general condition.

[He does not mention the examination of the abdominal cavity at the time of operation, and furthermore does not account for the sense of discomfort experienced in the region of the stomach; nor do we know the final outcome.—T. S. C.]

On microscopic examination the growth was found to be composed of myriads of small cells separated from one another by a delicate stroma. The cells in general were round or fusiform and had but little protoplasm. Histologically, the growth appeared to be malignant and was a sarcoma. It had developed from the fibrous tissue of the abdominal wall.

#### ROUND-CELL SARCOMA OF THE UMBILICUS.

The following case represents the only definite instance of round-cell sarcoma of the umbilicus with which I am familiar. The umbilical growth was a secondary one.

Pernice† reports a secondary sarcoma of the umbilicus (Case 71, from the Breslau Gyn. Clinic). The patient was a woman thirty-two years of age. The umbilicus was lifted 3 cm. above the surface of the abdomen. It had the form of an egg-cup, was very hard, but covered with normal skin. There was marked ascites, which made palpation useless. At operation eight liters of hemorrhagic fluid were removed and the omentum protruded. Scattered over it were tumors the size of plums. The umbilical tumor was completely isolated and was removed. It was in no way connected with the omentum. The primary tumor could not be discovered. Microscopic examination showed that the tumors were large round-cell sarcomata.

#### MELANOTIC SARCOMA OF THE UMBILICUS.

Pernice draws attention to two cases—one observed by Volkmann, the other by Olshausen. Volkmann's case occurred in a young girl who had an umbilical tumor

\* Garnier: Cancer [Sarcoma] primitif de l'ombilic. La Loire médicale, 1910, xxix, 503.

† Pernice, L.: Op. cit., obs. 71.

not larger than a cherry. Notwithstanding the wide removal of the growth, countless secondary tumors were soon noted and the girl died.

Olshausen's patient was a woman twenty-one years of age. She had at the umbilicus a melanotic sarcoma the size of an apple. It had been noted first a year and a half before she came for operation. The growth was removed, but twenty-one months later the patient died, with brain symptoms strongly indicative of cerebral metastases.

Catoir\* also reports a case of melanotic sarcoma of the umbilicus. The patient was a man sixty-five years old. He noticed a slight, faintly blood-tinged discharge from the umbilicus. At that time there could be seen a simple brownish spot, without any underlying induration. Four months later there was a thickening surrounding the umbilicus. Applications were employed, and an attempt was made to remove the growth with the thermocautery. Two months later the tumor was 3 cm. in diameter. It was raised and formed a semicircle with the umbilicus in the center. The tumor was removed. No note is given as to the prognosis.

Microscopic examination corresponded with the clinical diagnosis of melanotic sarcoma. No other primary source of the growth could be found.

[Despite the probability of the correctness of the diagnosis, in the absence of an abdominal exploration it is impossible to feel sure that the growth was primary. —T. S. C.]

\* Catoir, S.: Sarcome mélanique de la région ombilicale chez un homme de 65 ans. *Jour. d. sci. méd. de Lille*, 1899, xxii, 36.

#### LITERATURE CONSULTED ON SARCOMA OF THE UMBILICUS.

- Aveling: *Brit. Gyn. Jour.*, 1886-87, ii, 56; 187.
- Bérard, P. H.: *Fistules urinaires*. *Dict. de méd.*, Paris, 1840, xxii, 64.
- Blum, A.: *Tumeurs de l'ombilic chez l'adulte*. *Arch. gén. de méd.*, Paris, 1876, 6. sér., xxviii, 151.
- Catoir, S.: *Sarcome mélanique de la région ombilicale chez un homme de 65 ans*. *Jour. des sci. méd. de Lille*, 1899, xxii, 36.
- Dannenberg, O.: *Zur Casuistik der Nabeltumoren insbesondere des Carcinoma umbilicale*. *Inaug. Diss.*, Würzburg, 1886.
- Demarquay: *Cancer de l'ombilic*. *Bull. de la Soc. de chir.*, 1870-71, 2. sér., xi, 209.
- Forgue et Riche: *Montpellier méd.*, 1907, xxiv, 145.
- Garnier: *Cancer [Sarcoma] primitif de l'ombilic*. *La Loire méd.*, 1910, xxix, 503.
- Kaufmann, E.: *Ueber eine Geschwulstbildung des Nabelstrangs*. *Virchows Arch.*, 1890, cxxi, 513.
- Leydhecker, F.: *Zur Diagnose der sarcomatösen Geschwülste*, Giessen, 1856.
- Neveu, N.: *Contribution à l'étude des tumeurs malignes secondaires de l'ombilic*, Paris, 1890, No. 50.
- Nicaise: *Fibro-papilloma de la cicatrice ombilicale*. *Rev. de chir.*, Paris, 1883, iii, 29.
- O'Brien, Surgeon-Major: *Sarcoma at the Umbilicus*. *Indian Med. Gaz.*, 1889, xxiv, 215.
- Pernice, L.: *Die Nabelgeschwülste*, Halle, 1892.
- Plagge, H.: *Ein Fall von Myxosarcom des Nabels*. *Inaug. Diss.*, Freiburg, 1889.
- Quénu et Longuet: *Du cancer secondaire de l'ombilic*. *Rev. de chir.*, 1896, xvi, 97.
- Sourdille, G.: *Sarcome pédiculé de la peau de l'ombilic*. *Bull. de la Soc. anat. de Paris*, 1895, lxx, 302.
- Tillmanns, H.: *Deutsche Zeitschr. f. Chir.*, 1882-83, xviii, 161.
- Villar, Francis: *Tumeurs de l'ombilic*. *Thèse de Paris*, 1886.
- Virchow, R.: *Virchows Arch.*, 1864, xxxi, 128.
- von Winckel, F.: *Ueber angeborene solide Geschwülste des (perennirenden) Theiles der Nabelschnur*. *Sammlung klin. Vorträge*, n. F. No. 140. (Gyn. Nr. 53.)

## CHAPTER XXVII.

### UMBILICAL HERNIA.

Hernia into the umbilical cord.

Amniotic hernia.

Congenital nipping off of an umbilical hernial protrusion.

Small umbilical hernia at birth.

Serous umbilical hernia; report of cases.

Serous umbilical hernia in children.

Escape of serous fluid from the umbilicus in a case of tuberculous peritonitis.

Serous umbilical hernia associated with an ovarian cyst.

A serous umbilical hernia associated with a large cystic myoma and marked abdominal ascites.

Umbilical hernia in the adult; radical cure in a patient weighing 464 pounds.

Cysts of the umbilicus.

UMBILICAL hernia has been so thoroughly considered in the text-books on surgery that I shall here confine myself to a very brief description of the various forms of hernia in this region.

1. Hernia into the umbilical cord.
2. Amniotic hernia.
3. Congenital nipping-off of a hernial protrusion.
4. A small umbilical hernia at birth.
5. Serous umbilical hernia.
6. Umbilical hernia in the adult.
7. Cysts of the umbilicus.

#### HERNIA INTO THE UMBILICAL CORD.

A reference to the chapter on Embryology (Fig. 8, p. 8; Fig. 10, p. 10; Fig. 11, p. 11, and Fig. 12, p. 12), will show that in the early months of fetal life the greater portion of the small intestine lies in the umbilical cord. This extra-abdominal cavity is called the exocoelomic cavity. The intestine gradually withdraws into the abdomen, and the cavity in the cord becomes obliterated.

In rare instances, however, this opening does not close. In such cases at birth there is a cystic swelling at the fetal end of the cord. The cyst-walls are very thin, consisting, for the most part, of the amnion and of peritoneum; consequently, the intestinal loops within the sac are readily visible.

I shall refer to only three cases of this character—one mentioned by Sheen, one by D'Arcy Power, and the third reported in detail by Reed.

Sheen\* mentions the case of a patient seen by Hope at Queen Charlotte's Hospital. At birth there was a hernial protrusion into the cord. It formed a mass the size of a hen's egg. The neck of the sac was covered with skin, and the fundus with the covering of the cord. The umbilical vessels were spread out over the right

\*Sheen, William: Some Surgical Aspects of Meckel's Diverticulum. *Bristol Medico-Chirurg. Jour.*, 1901, xix, 310.

side of the sac. The sac contained large and small intestine. The small bowel was adherent to the sac, but was separated without difficulty. What appeared to be the vermiform appendix was so intimately fused with the tissues of the umbilical cord that it had to be ligated and cut off. The child recovered.

D'Arcy Power's\* patient was a full-term boy. At the fetal end of the umbilical cord was a transparent sac containing several coils of small intestine (Fig. 196). Taxis was employed, but it was found impossible to push the bowel back into the abdomen. The sac was opened, and it was also necessary to cut the umbilical ring. About one foot of small intestine lay in the sac. After the bowel had been returned

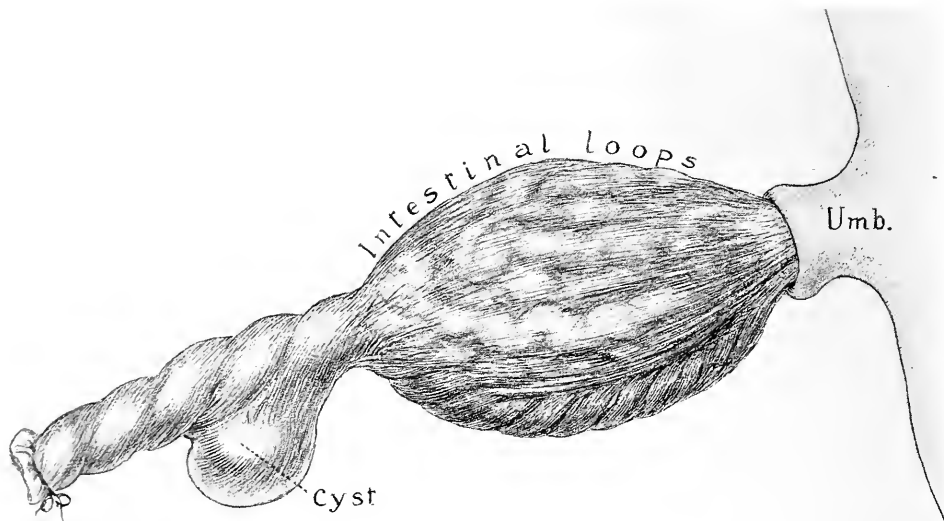


FIG. 196.—A CASE OF CONGENITAL UMBILICAL HERNIA. (D'Arcy Power.)

The labor was quite normal. Situated in the cord near the abdomen was a transparent sac containing several coils of small intestine. The cord was ligated and divided and an ineffectual attempt was made to replace the bowel through the umbilical opening. After the application of gentle taxis for ten minutes the umbilical ring was enlarged and a foot of small intestine was then with some difficulty returned into the peritoneal sac. The edges of the ring were subsequently brought together with silver wire. The child died of peritonitis three days later. The tumor appeared to be formed of a dilatation of the covering of the cord, which was fusiform in shape and had the main constituents of the abdominal cord running as a band along its lower border. The wall of the sac consisted of a thin, soft membrane which was so transparent that the coils of intestine could be seen through it. At the apex of the tumor the cord reappeared and had on its under surface a cyst containing viscid fluid.

into the abdomen the hernial ring was closed. The child died of peritonitis on the third day.

Powers said that Scarpa and Sir William Lawrence, in their classic treatises on rupture, have given a complete account of this variety of hernia.

One of the most remarkable cases of this character on record is that furnished by Edward N. Reed,† of Clifton, Ariz. The prompt and efficient manner in which Reed treated his case shows how much can occasionally be accomplished even when the outlook is most unfavorable.

\* Power, D'Arcy: A Case of Congenital Umbilical Hernia. *Trans. Path. Soc. London*, 1888, xxxix, 108.

† Reed, Edward N.: Infant Disemboweled at Birth—Appendectomy Successful. *Jour. Amer. Med. Assoc.*, July 19, 1913, 199.



Reed says:

"I was called to attend Senora Y. A., a Mexican woman, in confinement, March 14th. I found that the head of the infant was already free, and with the next pain, a moment later, the trunk was expelled. I was astonished at finding that the whole intestine, both small and large, was outside the abdominal cavity. Examination showed that the bowels had passed along inside the cord for about two inches, at which point the walls of the cord had ruptured, allowing the bowels to escape laterally.

"No preparations for the confinement had been made; the bed was filthily dirty, and the mass of intestines was thickly sprinkled with bits of straw, feathers, crumbs of food, and fecal matter from the mother.

"I had left the bedside of a woman just about to be delivered in order to respond to this call. I hurriedly ligated the cord, delivered the placenta, and wrapping the baby in the cleanest thing I could find, returned to the patient I had left.

"Finishing this case I called my colleague, Dr. T. B. Smith, and we went together to see the disemboweled infant and took it at once to the Arizona Copper Company's Hospital. It was placed on the operating table two hours after birth. By this time the bowels were matted together with fibrinous adhesions, which included many of the particles of débris mentioned above. They were cleansed gently with sponges and warm salt solution, but this cleansing was not very thorough, of course. The appendix, three-fourths of an inch long, seemed to be contused and swollen, and a catgut ligature was thrown around its base and it was then removed. The umbilical opening admitted the tips of two fingers. It was enlarged for half an inch upward and downward, and the cord-bearing edges were trimmed off. The intestines were then replaced, and a hurried closure was made with one layer of buried catgut and one of silkworm-gut.

"The child made an uneventful recovery, save for one small stitch-abscess, and is at this date well and growing normally."

In cases of this character the wisest plan is to do a radical operation at once. If no operation be performed, the cord must be ligated at a point distal to the hernial sac, but even if the intestine can be easily replaced, the thin-walled sac still persists, and, as its walls consist merely of amnion and peritoneum, they are liable to tear and there will then be great danger of peritonitis.

#### AMNIOTIC HERNIA.

In 1881 Nicaise\* referred to the amniotic umbilicus. He said that, according to Widerhofer, it is characterized by an absence of skin around the umbilicus, the defect being replaced by amnion which is reflected upon the abdomen from the cord. In such cases the surrounding abdominal wall is generally intact. The amniotic umbilicus does not usually interfere with the health of the child. In the case mentioned by Nicaise the amniotic disc was gradually replaced by scar tissue and the umbilicus completely closed.

Runge, † in 1893, when discussing this subject, said that in rare instances there is a preponderance of amnion and a lack of skin at the umbilicus, and that this condition is spoken of as an amniotic umbilicus.

Where an amniotic umbilicus exists, the intra-abdominal pressure naturally tends to produce a hernial protrusion at the navel, particularly if the abdominal skin and underlying muscular walls are lacking over a wide area.

\* Nicaise: *Ombilic*, *Dict. encyclopédique des sciences médicales*. Paris, 1881, 2. sér., xv, 140.

† Runge, M.: *Die Wundinfektionskrankheiten der Neugeborenen*. Die Krankheiten der ersten Lebensstage, Stuttgart, 1893, 2. Aufl., 56.

Stewart,\* in 1905, reported the case of a well-developed male child with a hernia of the cord the size of a very large apple. The cord dropped off at the usual time, leaving the sac exposed. The child thrived well. Stewart advised non-interference, but the parents were particularly anxious that something should be done. Consequently a plastic operation was attempted. The sac contained a portion of the intestine and the whole of the liver so firmly adherent to the apex of the sac that its separation was impossible.

In 1903 Dr. S. E. Sanderson,† of Detroit, saw a new-born babe in whom the anterior abdominal walls had failed to develop. The entire abdominal contents were visible through a thin, transparent covering. The covering, being distended, allowed the abdominal organs to press forward, forming a sort of "total hernia,"

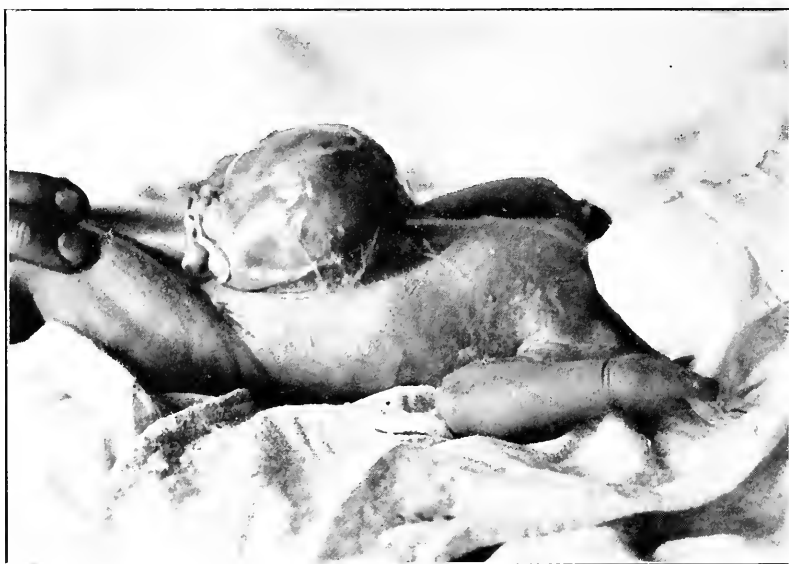

FIG. 197.—AN AMNIOTIC HERNIA. (Photograph of Dr. H. Wellington Yates' case.)

The photograph is of a new-born eight-month child with a large hernial protrusion occupying the greater part of the anterior abdominal wall. The walls of the hernia were composed of a very thin membrane, which was almost transparent and which appeared to consist of amnion and peritoneum. The skin of the abdominal wall extended up the sides of the sac for a very short distance. The sac contained the greater part of the bowel.

while the partly developed abdominal wall, composed of skin, muscle, and peritoneum, was retracted.

When Sanderson first saw the child it was one day old, was strong, in good condition, and seemed to be unaffected by the physical defect. It nursed and cried, as do other new-born babes. The thin abdominal covering had, however, begun to dry, and the intra-abdominal pressure had already produced a marked protrusion. Dr. Sanderson felt that the opportune time for repairing the defect was past, but as a last resort he advised operation. This was performed at the Grace Hospital. Sanderson, after resecting half of the liver, was able to bring the muscles and skin together. The child stood the operation well, but died twenty-four hours later.

As pointed out by Sanderson, the time to operate is immediately after birth,

\* Stewart, G. C.: *Hernia of the Umbilical Cord*. *Brit. Med. Jour.*, 1905, i, 247.

† Personal communication.

before there is any drying out of the thin membranous covering of the abdominal wall, and before the hernial protrusion has been increased in size by the accumulation of fluid in the stomach. As mentioned above, Sanderson was not called to see this case until twenty-four hours after birth.

In January, 1913, I gave an address in Detroit, on Diseases of the Umbilicus before the Wayne County Medical Society, and shortly afterward received the following letter from Dr. H. Wellington Yates, of that city:

"DETROIT, February 1, 1913.

"*My dear Doctor.* A short time ago I reported a case of congenital hernia of the cord in the new-born at the Wayne County Medical Society. I referred in my paper to three other cases which I had previously observed, together with references to those which had been reported in the literature up to that time. After the meeting your brother Ernest asked me if I would not send you a brief review of the cases reported, together with my reprint of 1907. I therefore take pleasure in inclosing these data, together with a copy of the picture of the case in question. I feel fortunate in having had four cases of this type come under my observation, and shall be glad if you can use the picture or case to any advantage.

"Very respectfully,

"H. WELLINGTON YATES."

The picture referred to by Dr. Yates is reproduced in Fig. 197. The child was born on January 11, 1913. It was an eight-month child, weighed six pounds, and was 18½ inches long. Occupying the greater part of the abdominal wall was a hernial protrusion. This was 14 cm. broad and 17 cm. long. The child was otherwise well formed. Yates says that he was, unfortunately, unable to get an autopsy. The walls of the hernial protrusion were almost transparent, and apparently consisted of merely amnion and peritoneum. At the base the skin was continued for a short distance upon the sac. From what Yates could gather, the larger part of the intestine was in the sac.

It is obvious that in all such cases the only chance of saving the child is by operating immediately after birth.

#### CONGENITAL NIPPING-OFF OF AN UMBILICAL HERNIAL PROTRUSION.

In our study of the embryology of the umbilical region we have seen that in the early months a large part of the small bowel lies out in the umbilical cord. Later the intestine recedes into the abdomen. The cavity in the cord becomes obliterated and the umbilical ring closes. If for any reason the bowel becomes adherent to the cavity in the cord, it may be impossible for the adherent portion to pass back into the abdomen. If such a condition exists and the umbilical ring closes, we shall have one or more loops of small bowel nipped off and lying on the abdominal wall. Fortunately, such a condition is very rare. That it may occur, however, is clearly shown by instances reported by Kern and Ahlfeld.

Kern\* reports an observation made by Meckel. Meckel, in examining a four months' embryo seven inches long, found malformations of the lower extremities and of the heart, and, in addition, noted that the intestine was divided into two halves, which did not communicate with each other. The upper or stomach half consisted of the normal stomach and of 11 inches of intestine. The intestine was

\* Kern, Theo.: Ueber die Divertikel des Darmkanals. Inaug. Diss., Tübingen, 1874.

for the most part of normal caliber, but for a space of one inch was dilated to four times the normal diameter. It then gradually became smaller and passed out through the umbilicus. It extended outward on the abdomen one inch, and then contracted down to a very fine thread. This passed over into an equally fine thread, which was continuous with the upper end of the lower portion of the intestinal canal. This is a good example of the nipping-off of the intestine outside the abdomen in early fetal life. In this case the umbilical ring was still open.

Ahlfeld,\* in 1872, was asked by a midwife to examine a child with a rather unusual tumor. The child was six hours old, had passed no meconium, and cried constantly. It was well nourished and apparently healthy. At the navel was an

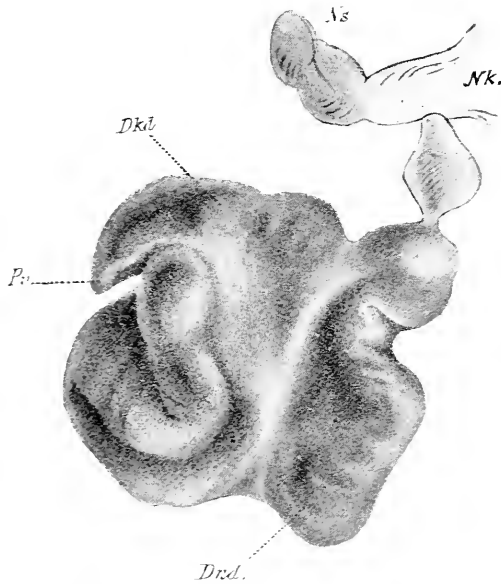


FIG. 198.—SEVERAL LOOPS OF BOWEL WHICH LAY OUTSIDE THE UMBILICUS AND WERE NIPPED OFF DURING FETAL LIFE. THE CHILD LIVED A SHORT TIME AFTER BIRTH. (After Ahlfeld.)

*Ns*, Umbilical elevation: *Ns*, umbilical cord: *Dkd*, small bowel: *Drd*, large bowel: *Pr*, vermiform appendix. It will be noted that the pedicle of this tumor is very narrow at the umbilicus. It then expands somewhat and again becomes exceedingly narrow. The intestine forming this mass was totally cut off from the portion in the abdominal cavity.

of the intestine between the enterostomy opening and the umbilicus was wide and flat. At a point 1 cm. above the umbilicus the intestine ended blindly, and from there to the umbilical ring there was nothing but a delicate strand of mesentery.

The ascending colon passed toward the pedicle of the tumor and ended blindly at the umbilical ring. The remainder of the bowel to the anus was small and filled with mucus.

The condition was due to the fact that a portion of the intestine lying on the abdomen had been cut off by closure of the umbilical ring.

\* Ahlfeld: Zur Aetiologie der Darmdefecte und der Atresia ani. Arch. f. Gyn., 1873, v, 230.

irregular tumor the size of an apple (Fig. 198). This tumor was attached to the umbilicus by a very thin pedicle.

It was clearly evident that the tumor consisted of a nipped-off intestinal convolution. The individual parts of this were firmly adherent to one another as a result of adhesions. The tumor was hard in consistency, and was attached to the umbilicus by a definite pedicle.

The anus was well formed, and a flexible catheter could be passed into the rectum for a considerable distance. The rectum, however, contained no meconium.

The tumor was removed by Professor Credé, and the pedicle was found to be solid. Under the existing circumstances it was deemed advisable to make an artificial anus above the umbilicus, but the child died.

At autopsy it was found that the stomach was in the normal position. The duodenum and jejunum were markedly dilated, while the portion

Fortunately this complication is a great rarity. Should such a condition be noted at birth, immediate operation is indicated. After the umbilical growth has been cut off, the abdomen should be opened and the upper and lower portions of the bowel united by a lateral or end-to-end anastomosis.

#### SMALL UMBILICAL HERNIA AT BIRTH.

Herniæ of this character are relatively common. On referring to Fig. 30 (p. 27) we see the umbilical weak spot. This is usually to the right of the umbilical vein, and above the umbilical arteries. In this connection it will be well for the reader to study the normal appearance of the umbilical ring as viewed from the peritoneal side (p. 39). A careful study of Plate VI will give a clear idea of the various appearances of umbilical herniæ.

In the young infant the hernia is usually not over 1 to 2 cm. in diameter, and when an appropriate pad is applied, as a rule, gives rise to little trouble. The hernia tends to diminish gradually in size and may soon disappear. In those cases in which it persists, operation may be deemed advisable. In such cases a small longitudinal incision may be made, the edges of the ring dissected away, and the surfaces carefully approximated. It is often difficult to bring the peritoneum together as a separate layer, on account of its extreme delicacy in the infant.

One of the most ingenious and apparently the safest method of curing umbilical hernia in children is that practised by Nota, of Turin. His method has been clearly described by Brun.

Brun\* expatiated on the ease, harmlessness, and effectual outcome of the method which Nota, of Turin, has applied since 1890 to 244 children from two months to nine years old. The earlier the operation, the smaller the hernia and the better the outcome. An elastic cord 30 to 40 cm. long is passed around the base of the hernia with a long curved needle worked through horizontally under the skin. The hernia is then reduced and held in place with the finger, while the elastic cord is drawn tight until the opening is entirely obliterated. The ends of the cord are then held with a clamp and tied with silk close to the skin and cut off, the short ends only being left protruding. The cord is drawn taut by an assistant, while the reduced hernia is controlled by the operator. In the course of a few days the rubber cord gradually cuts through the soft tissue in its grasp, the tissues growing together in its wake and thus solidly closing the opening. After twelve or fifteen days the entire rubber cord comes out through the hole in the skin from which the ends protrude, and a thick, solid cicatrix is left around and on the top of the old hernial opening. The dressings are not disturbed for ten days; then a new dry dressing is applied, and it is wise to have the child wear a simple cloth binder around the abdomen for two or three months afterward. The elastic cord is sterilized by soaking for an hour in 70 per cent. alcohol containing 1.5 per cent. glacial acetic acid. No complications of any kind were ever observed and the abdominal wall gradually becomes smooth and supple. Recurrence was observed in only one case—that of a young infant with a hernia 5 cm. in diameter. The hernia recurred during an attack of coughing, but was radically cured six months later by a repetition of the procedure. General anesthesia is not required for infants; for older children Nota uses a few whiffs of

\* Brun: Treatment of Umbilical Hernia. Jour. Amer. Med. Assoc., 1912, October 26, 1578. Abstract from Arch. de médecine des enfants, Paris, Sept., xv, No. 9, 641.

ethyl chlorid. The child comes to at once after the little operation, which never takes over six minutes, and can be taken home if kept quiet.

#### SEROUS UMBILICAL HERNIA.

In some instances in which the abdomen contains a large quantity of ascitic fluid, the umbilicus unfolds, as it were, and becomes distended, so as to suggest an umbilical hernia. Indeed, the condition has been termed a serous umbilical hernia. While this unfolding of the umbilicus is not very common, still it is by no means rare. The reason that so little has been written on the subject is evidently due to the fact that the accumulation of ascitic fluid in the umbilical sac has been looked upon as a perfectly natural accompaniment of the abdominal distention associated with a large amount of ascitic fluid.

The chief articles on the subject are those of Catteau (1876), Gauderon (1876), Nicaise (1881), Ledderhose (1890), Gallant (1906), and Perrin (1910). Nicaise referred to cases reported by Brehm, Van Horne, Nuck, and Morgagni, and Ledderhose, to one recorded by Pineo-Hyannis.

Catteau examined the umbilicus in 19 cases of ascites, with the following results:

Slight projection of the umbilicus in . . . . .	11 cases
Unfolding of the umbilicus in . . . . .	3 cases
True umbilical hernia in . . . . .	5 cases

Perrin, discussing this subject in 1910, said that in 32 cases of abdominal ascites that he collected, the umbilicus was more or less distended in 9 cases. He also said that Bertrand, in 28 cases of abdominal ascites, had noted umbilical distention in 6 cases. It is thus clearly evident that a serous umbilical hernia is no great rarity.

**Clinical Course.**—The majority of the patients concerning whom we have records were women between thirty and sixty-five years of age, but the umbilical dilatation may also occur in men. The ascites was usually attributable to chronic nephritis, cirrhosis of the liver, cardiac dilatation, or to a combination of these. When the ascites was first noticed, no change in the umbilicus was detected, but with the gradual abdominal distention alterations in the navel developed.

**The Umbilical Tumor.**—With increased abdominal tension the umbilicus gradually unfolds and a small hemispheric prominence is noted. This


#### PLATE VI. UMBILICAL HERNIA.

All but the last (No. 11) of the cases of umbilical hernia here depicted were accidental discoveries made during the study of normal umbilici on patients in the hospital wards. The results of this study are pictured on Plates I-IV.

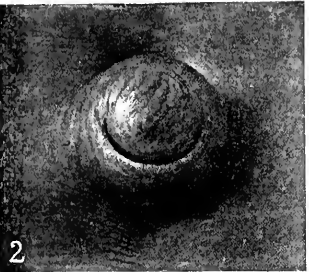
In the fetus and new-born a small hernial protrusion at the upper margin of the umbilicus, or occasionally on the upper right or left, may be regarded as entirely normal. In the erect posture and on straining or coughing this small congenital hernia always becomes more pronounced, and an invisible hernia may thus become demonstrable. There is marked diastasis of the recti muscles in Nos. 1, 2, 3, 6.

The most prominent part of the hernia may contain the umbilical cicatrix (Nos. 1, 3, 6); the usual location is below the hernia. In the course of a few years this scar gradually becomes effaced (No. 3), and may entirely disappear (No. 5). Pregnancy also has a tendency to smooth out the folds of the scar (No. 4). Immediately after birth the skin over the navel puckers up (No. 9) and remains permanently so in a woman who has had many children (No. 7). The hernia in both Nos. 7 and 9 were capable of much distention, but were drawn while devoid of contents. No. 11 represents a large multilocular hernia filled with adherent masses of omentum. This also was drawn when the patient's abdominal walls were relaxed. For the further appearances in this case see Fig. 203, p. 475, and Fig. 204, p. 476. Nos. 8 and 10 are small hernia in the male adult. Note the faint parumbilical vein coursing over the hernial sac in No. 8. In No. 10 the hernia was covered by perfectly white skin. The patient was a very dark-skinned negro, who had leukoplakia over the thighs, genitalia, etc. Thus in this case, there was a white umbilicus in a coal-black negro.

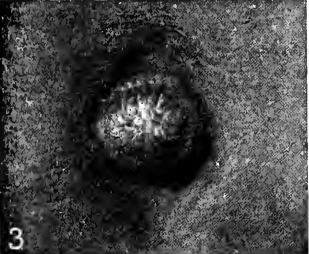
PLATE VI.




1  
Male, 5 weeks, 12 lbs.



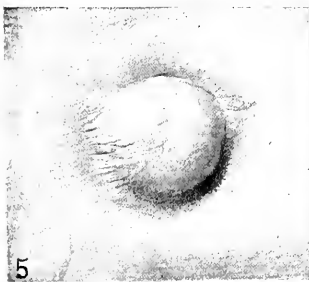
2  
Male, 6 months, 17 lbs



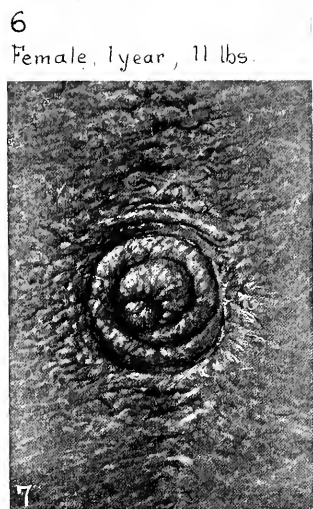
3  
Male, age 11 years, 58 lbs.



4  
Female, age 19, 126 lbs, pregnant

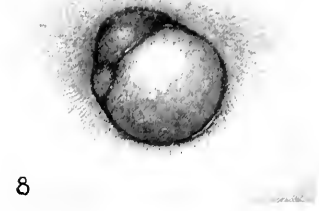


5  
Female, age 58, 142 lbs, 7 para

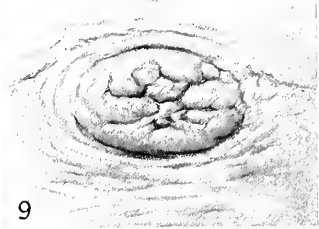

6  
Female, 1 year, 11 lbs.

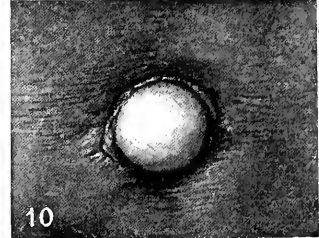
7  
Female, age 32, 125 lbs. 7 para



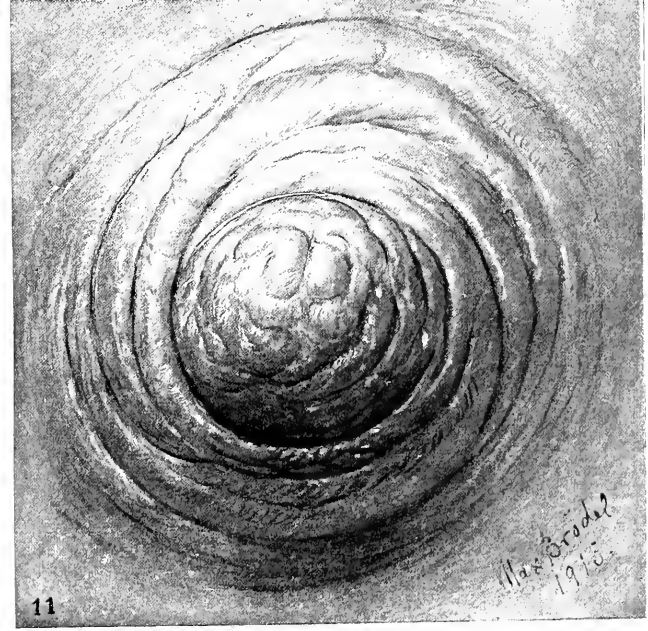8  
Male, age 60, 180 lbs



9  
Female, age 22, 140 lbs, 1 para



10  
Male, age 30, 150 lbs. Leukoplakia



11  
Female, age 35, 464 lbs. 5 para.

Max Bröder  
1915

may be very small, or reach 2 or 3 cm. in diameter. The overlying skin looks normal, and often the sac is seen to contain clear fluid. Sometimes, however, this can be detected only by transmitted light.

As the intra-abdominal pressure continues, the umbilical tumor may become as large as a goose's egg or an orange and may be either hemispheric or lobulated. When the hernia reaches such a size, the overlying skin is usually greatly stretched, and the fluid contents of the sac are easily distinguishable. The fluid from the sac can usually be forced back into the abdomen with or without gurgling, after which the finger can usually make out the sharp, hard margins of the umbilical ring. When the pressure is released, the fluid at once flows back into the sac, producing, as pointed out by Raciborski (Nicaise), a peculiar thrill.

Occasionally, when the sac is small, it may also contain a loop of small intestine, but where the abdominal distention is marked, it contains nothing but the fluid. This is evidently due to the fact that when the abdominal distention is marked, the mesentery of the small bowel is not long enough to allow the intestine to reach the abdominal wall.

As a rule, the serous umbilical hernia is only an incident in the course of the nephritis, cirrhosis, or cardiac disease. Occasionally, however, the local condition may attract some attention. Catteau mentioned a case of Morgagni's in which an umbilical tumor the size of a goose's egg broke, each day discharging limpid fluid. It finally healed. According to Nicaise, rupture of the umbilicus distended by ascitic fluid is very rare, as he knew of only two observations, those of Brehm and Van Horne. Ledderhose mentions a case recorded by Pineo-Hyannis, in which the ascitic fluid escaped from the umbilicus and recovery took place.

Perrin reported a case of a man, aged fifty-one, suffering from hepatic cirrhosis. The umbilical sac was as big as an orange. It ruptured on the right side, but cicatrized and the patient was afterward tapped 15 times, an average of 24 pints of ascitic fluid being drawn off.

As a rule, the subsequent history of the patient will depend entirely upon the pathologic lesion responsible for the ascites. In a case reported by Perrin, a woman aged fifty-two had a serous umbilical hernia. This ruptured, the sac remaining open and shrunken. Erysipelas developed around the umbilicus and proved fatal.

Perrin has studied the umbilicus in normal and ascitic subjects and finds that at least three causative factors must be taken into account. In the first place, the umbilical ring varies greatly in diameter. In the second place, the ring is much more readily distended in some cases than in others, as its fibrous and connective tissue may be abundant and firmly welded together or loose in texture; and, finally, the obturator membrane varies greatly in strength.

#### CASES OF SEROUS UMBILICAL HERNIA.

From the following cases the reader may gather a clear idea of the clinical picture. The small number of cases here recorded is, however, no index of the frequency of serous umbilical hernia.

Prominences at the Umbilicus Associated with Interstitial Nephritis, Cirrhosis of the Liver, and Ascites.\* — An alcoholic woman, aged thirty-two, who had interstitial nephritis

\* Catteau: De l'ombilic et de ses modifications dans les cas de distension de l'abdomen. Thèse de Paris, 1876, obs. 11, 12, 13.



and cirrhosis of the liver, had also had ascites for four weeks. The umbilicus was hemispheric, transparent, and 3 to 4 cm. in diameter. The finger could be easily introduced into the umbilical ring.

A patient, thirty-one years of age, who was suffering from Bright's disease, had an irregular umbilical tumor, 6 by 4 by 4.5 cm. It was lobulated, and the overlying skin was transparent.

A woman, aged forty-nine, had had marked abdominal enlargement for two months, and for six weeks had had at the umbilicus a tumor 3 cm. in diameter.

**An Umbilical Protrusion Due to Abdominal Ascites.**—Gauderon\* reports a case coming under Guyot's observation. The patient was a vigorous man, aged thirty-five, who entered Guyot's clinic with definite symptoms of Bright's disease, characterized by albuminuria, edema of the legs and of the abdominal walls, with moderate ascites. The ascites increased. The umbilicus was distended, and on March 12, 1876, an umbilical intestinal hernia developed. The hernia was irreducible, and gurgling could be made out. This man had never had an umbilical hernia before and had never used a bandage.

By April 3d of the same year the intestine had disappeared from the hernial sac and the site was occupied by serous peritoneal fluid. During this period the ascites had increased. The patient left the hospital at his own request on April 20th.

#### SEROUS UMBILICAL HERNIA IN CHILDREN.

Very few cases have been recorded, simply because ascites is much rarer in children than in adults. Were ascites just as frequent in children, we would have a much larger percentage of serous umbilical herniæ in the child, as in early life the umbilicus gives way very readily. I shall here give a typical example of an umbilical hernia in an infant:

Baby H. Seen in consultation with Dr. Vogler at the Church Home and Infirmary, Baltimore, November 14, 1910. The child is eight months of age and has marked abdominal distention. Two weeks ago an umbilical hernia developed. The hernial sac is about 2 cm. in diameter and projects at least 1.5 cm. from the abdominal wall (Fig. 199). The skin over the umbilicus shows marked tension and is shiny; and one can detect clear fluid in the hernial sac. On percussion there is a distinct wave of fluctuation throughout the entire abdomen, and there is also much enlargement of the liver. Two or three days ago inguinal herniæ developed on both sides. After much consideration it was felt wiser not to let the fluid out for fear that the child might develop a general peritonitis. He was taken home, but notwithstanding the most careful nursing he grew worse. He developed pneumonia about two months after leaving the hospital and died.

\* Gauderon: De la péritonite idiopathique aiguë des enfants; de sa terminaison par supuration et par évacuation du pus à travers l'ombilic. Thèse de Paris, 1876, No. 148, 51.

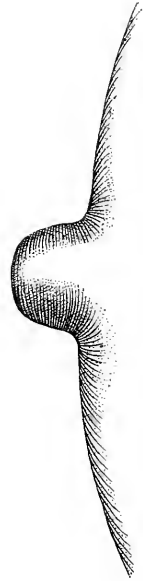

FIG. 199.—A SEROUS UMBILICAL HERNIA.

This represents the abdominal contour in the umbilical region of a child eight months old. The child's liver was markedly enlarged and the abdomen full of ascitic fluid. The umbilicus was unfolded and formed the projection here depicted. The overlying skin was very thin, and the fluid in the umbilical sac could be clearly seen.

## ESCAPE OF SEROUS FLUID FROM THE UMBILICUS IN A CASE OF TUBERCULOUS PERITONITIS.

Ledderhose\* reports an observation by Henoeh on an eight-year-old boy. On two occasions, on account of marked ascites, several liters of fluid had been removed by puncture and from time to time clear serum escaped from the distended umbilicus. This flow was followed by a diminution in the abdominal distention. Three months later, as a result of tuberculous meningitis, the child died. At autopsy tuberculosis of the peritoneum was found. In the abdominal cavity at the time of autopsy there were only about 100 c.c. of clear, light yellow fluid.

## SEROUS UMBILICAL HERNIA ASSOCIATED WITH AN OVARIAN CYST.

We have records of two such cases, those reported by Catteau and Gauderon. If there be ascites associated with an ovarian tumor, the development of serous umbilical hernia is easily explained. It is also easily understandable that if, through injury, rupture of the ovarian cyst occurs, the free ovarian fluid may pass into an umbilical hernia.

*An Ovarian Cyst Associated with Umbilical Swelling.* — Catteau, in Case 16, refers to a woman forty-five years of age, who had had an ovarian cyst for ten years. After falling on her back she vomited, and a tumor was noted at the umbilicus. Two months later there was an escape of fluid through an umbilical opening.

*A Serous Umbilical Hernia Associated with an Ovarian Cyst.* † — This case was communicated to Gauderon by his friend Dus-saussey: Catherine S., aged sixty-five, entered the service of Dr. Millard, April 21, 1876. On admission she was found to have an enormous abdominal tumor, which had first been noticed six years previously and diagnosed as an ovarian cyst. It was complicated by the presence of ascitic fluid. When the patient entered the hospital there was a hemispheric tumor at the umbilicus. It was fluctuant and reducible without gurgling. After reduction the finger met with a hard umbilical ring. The tumor was supposed to be a serous hernia complicating ascites. The patient said that this small tumor had existed for more than a year. Several days later she developed peritonitis and died on May 2, 1876.

Autopsy revealed a multilocular ovarian cyst on the left side. There were traces of peritonitis. At the umbilicus there was a true serous hernia. The umbilicus was distended in the form of a hernia the size of a large walnut, and the hernial sac was lined with peritoneum. The umbilical ring itself was 1 cm. in diameter. The peritoneum of the sac was whitish and opalescent.

## A SEROUS UMBILICAL HERNIA ASSOCIATED WITH A LARGE CYSTIC MYOMA AND MARKED ABDOMINAL ASCITES.

While preparing this chapter the following case came under my care at the Johns Hopkins Hospital:

Gyn. No. 18101, Gen. No. 81548. E. G., colored, aged thirty-four, was admitted to Ward O January 16, 1912, complaining of abdominal distention and shortness of breath. She has always enjoyed good health previous to the present illness. During the last winter she has had several colds, which were accompanied by persistent cough and some expectoration. Since September, 1911, the patient has had periods of suppression of urine, which have lasted for twenty-four hours, and for

\* Ledderhose: *Deutsche Chirurgie*, 1890, Lief. 45 b.

† Gauderon: *Op. cit.*, obs. 15.

the last four months there has been marked constipation. Eleven months ago the patient noticed that her abdomen was increasing in size. It has steadily grown larger, and she suffers a good deal from dyspnea. The limbs have become so swollen lately that whenever the patient has had to get into bed she has been obliged to have some one lift her legs for her. She has had very little abdominal pain, her main complaint being shortness of breath and abdominal swelling.

Present Condition.—The patient is a sparely nourished, rather emaciated negress. She has some trouble with dyspnea and reclines in bed on several pillows. The abdomen is markedly distended and there is an umbilical hernia. The abdomen is full and somewhat rounded. The distention extends from the xiphoid to the symphysis. There is a definite bowing of the xiphoid cartilage. It is pressed almost at right angles to the sternum. No masses are to be made out in the abdomen on deep palpation. There is considerable edema throughout the lower half of the abdomen and marked pitting on pressure. A definite fluctuation wave is made out. With the patient in the dorsal position, the dulness extends to either flank.

Operation.—Abdominal hysteromyomectomy, January 17, 1912.

The umbilicus was dilated, forming a hernia about 2 cm. in diameter. The walls here were very thin, and the sac, which was evidently filled with fluid, projected as a little dome about 2 cm. from the surface of the abdomen. I picked up the hernial sac on either side with forceps and opened it. A rubber hose was firmly pressed over the opening, and we removed over 17 liters of ascitic fluid from the general abdominal cavity. The incision was then increased in size, and I saw what appeared to be an ovarian cyst, with a small opening in it. I hooked my finger into this and raised it up still more. On getting it out I was surprised to find that, instead of an ovarian cyst, we had a cystic myoma, which projected from the posterior surface of a myomatous uterus. A supravaginal hysterectomy was done, and the abdomen closed without drainage. Convalescence was uneventful.

Path No. 16947. The multimodular myomatous uterus is approximately 12 cm. long, 10 cm. broad, 10 cm. in its anteroposterior diameter. The uterus contains numerous subperitoneal and interstitial nodules. Projecting from the fundus is a cystic nodule, approximately 14 cm. in diameter. At its upper end is a small hole from which serous fluid oozes. The tumor on section is found to be partly cystic, partly solid. There are numerous loculi which open into one another, and there are bands of tissue running from side to side in the main cyst. The right tube is the seat of a hydrosalpinx, and the entire mass is enveloped in adhesions. On the left side the tube is 9 cm. long and has been converted into a hydrosalpinx.

#### UMBILICAL HERNIA IN THE ADULT.

For a general consideration of this subject the reader is referred to the textbooks on surgery. I shall mention only the salient facts and refer to certain points that have particularly impressed me.

Umbilical hernia in the adult seems to be much more prevalent in the female than in the male, and not infrequently is noted after the abdominal distention consequent to pregnancy. It is more common in stout women than in thin persons. This is probable partly due to the fact that, when individuals take on adipose tissue externally, there is a coincident increase in the amount of fat in the omentum and mesentery, and therefore an increased tension on the abdominal wall.

With the increase of adipose tissue there is an increased tendency toward a pendulous condition of the abdomen. If the umbilical hernia is small and can be readily reduced, the patient often experiences little or no discomfort. In those cases in which the hernia reaches a diameter of 3 to 4 cm., when the omentum is adherent

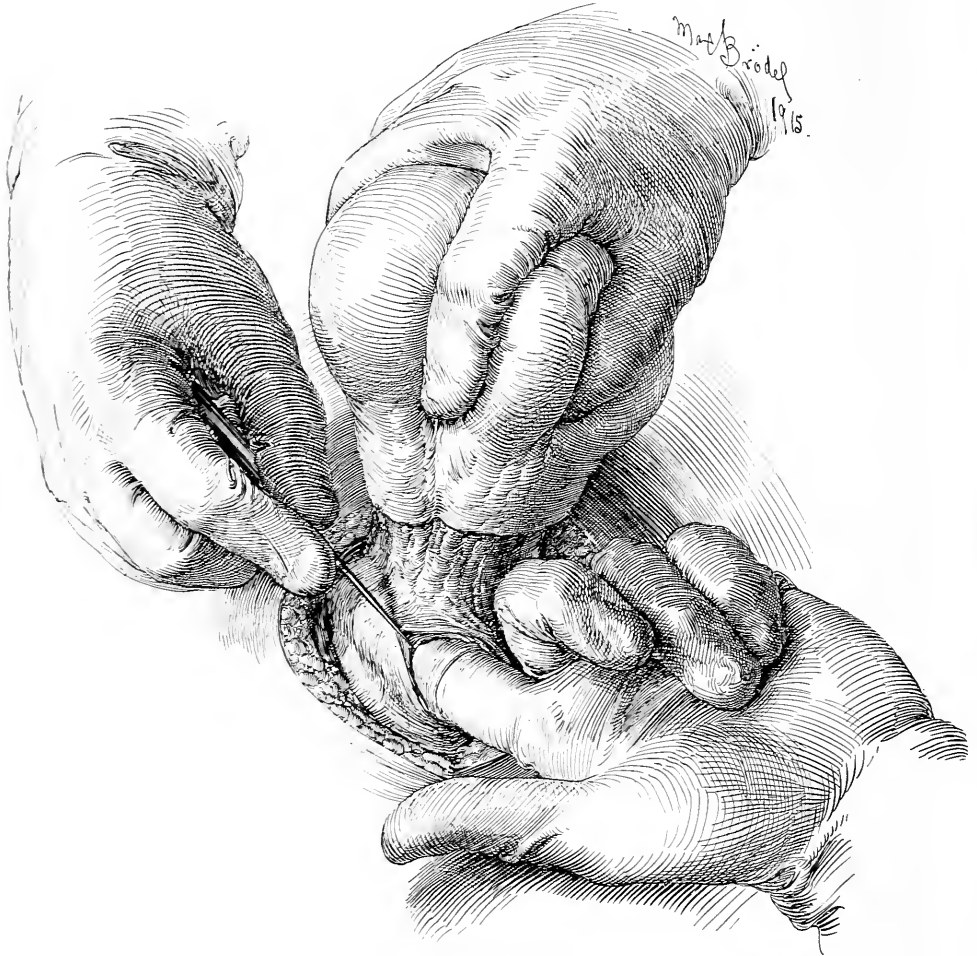

FIG. 200.—FREEING THE UMBILICAL HERNIAL SAC FROM THE ABDOMEN. (HEAD OF PATIENT BELOW, SYMPHYSIS ABOVE.)

In this case an elliptic abdominal incision has been made around the hernia from above downward, and the adipose tissue has been reflected back on either side until the neck of the sac and the surrounding abdominal fascia are clearly exposed. In those cases in which there is much redundancy and it is deemed advisable to remove a large area of adipose tissue, the skin incisions should be from side to side. When the neck of the sac is well exposed, the fascia is cut through just above the sac,—above, because there are few if any adhesions at this point,—and a finger is introduced as indicated. With the finger as a guide the sac is cut free all the way around. The hernial mass is now isolated, and can be lifted well away from the abdominal wall and then walled off with gauze. The sac is now slit open from neck to base. If it contains intestinal loops, these are liberated and returned into the abdomen. Where the omentum is very loosely attached, it is also liberated and returned to the abdominal cavity, but when it is densely adherent, the extra-abdominal portion is tied off and removed with the sac. For the closure of the hernial opening see Figs. 201 and 202.

and the abdomen is pendulous, the patient experiences a dragging sensation if on her feet much. This is evidently due to tension on the transverse colon.

When a small umbilical hernia exists, the fat lobules occasionally present in the ring may increase in volume, thereby stretching the ring.

When the omentum has been incarcerated for a considerable time, there may be edema of the surrounding abdominal wall and a tendency for the more prominent parts of the hernia to become excoriated.

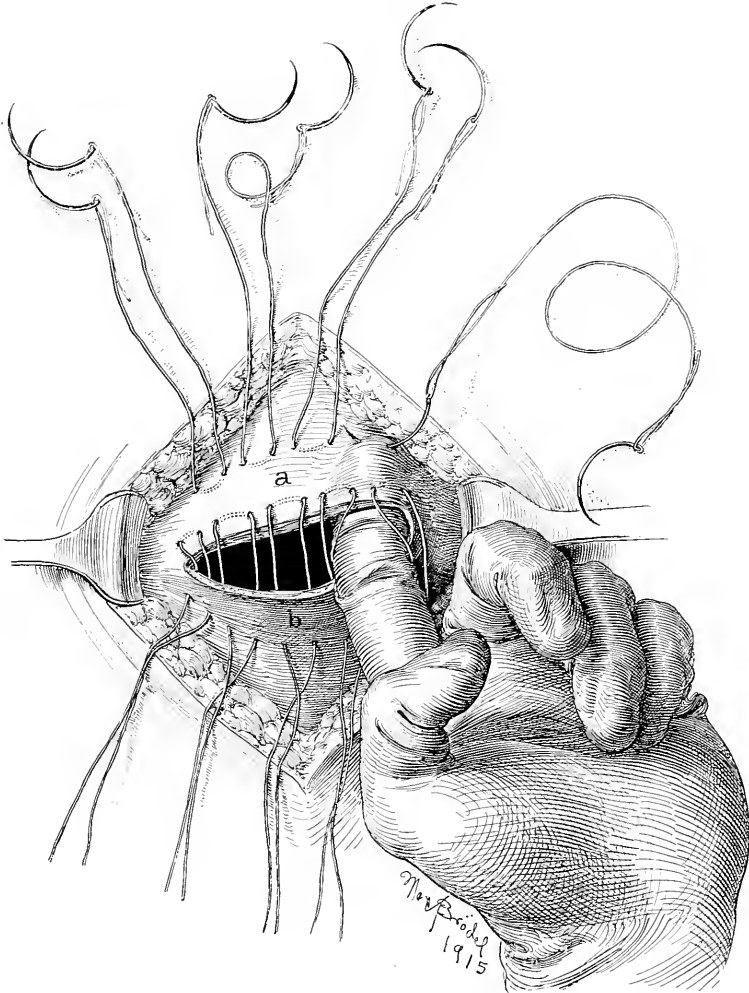


FIG. 201.—CLOSURE OF THE HERNIAL OPENING AT THE UMBILICUS.

A row of mattress sutures consisting of kangaroo tendon, chromicized catgut, or silk, as the operator may prefer, are so placed that the lower flap *a* is drawn well up under the upper flap *b*. Before tying these the second row of mattress sutures is passed through the lower flap *a*. They are inserted now because, with the abdomen opened, one can take a much deeper bite, the finger serving as a guide to the depth of their insertion. When they are placed after the first row has been tied, the operator rarely grasps enough tissue, as he is afraid of piercing the underlying intestine. After the first row of mattress sutures has been tied, the ends of the second row of sutures are passed through the edge of the upper flap and tied. Needles have been placed on the ends of each of these sutures to facilitate the understanding of the procedure. In actual practice each pair of suture ends is temporarily clamped with forceps and rethreaded after the first row has been tied. (For the appearance of the ring when closed see Fig. 202.)

It is in the small herniæ that a knuckle of gut is liable to become incarcerated, and the patient then speedily develops the characteristic symptoms of a partial or complete intestinal obstruction.

**Treatment.**—Given a thin patient, the operation is usually easy. Unfortunately, however, the majority of these patients are stout, many of them quite

obese, and show a marked tendency toward emphysema. Such patients are prone to develop postoperative lung complications, and this danger should be thoroughly considered before any operative interference is undertaken. I invariably follow the postoperative course of such a case for several days with some concern. The preparatory treatment of these cases has recently been admirably outlined by Alexius McGlannan (*Proc. Southern Surg. and Gyn. Assoc.*, 1914, xxvii, 311).

The radical operation for umbilical hernia may be a most difficult procedure or a relatively simple operation, depending in large measure on the manner in which it is performed. So far as my personal experience goes, it is wise to make an elliptic incision from above downward or from side to side. A wide area is usually outlined and freed down to the fascia. The hernia and the flap of fat are dissected free until the neck of the sac stands out clearly on all sides. A small incision is then made

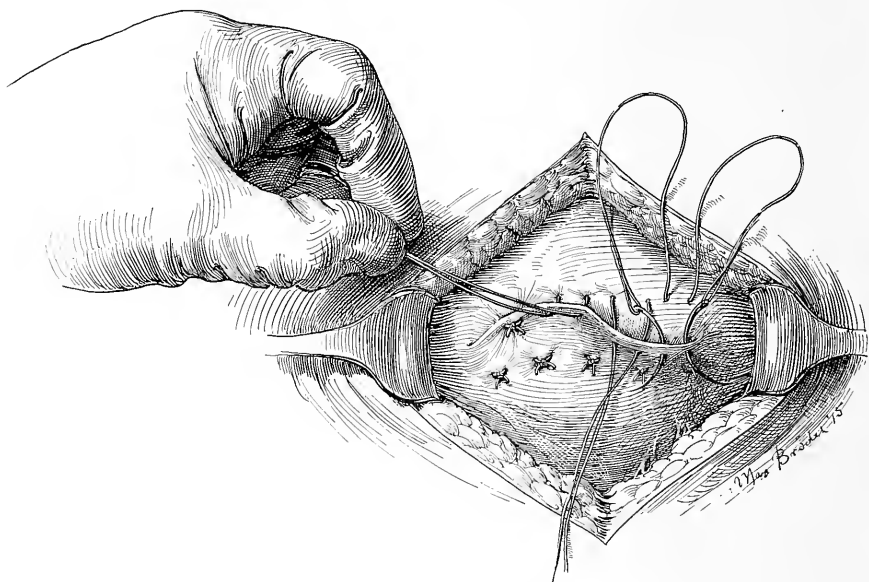


FIG. 202.—CLOSURE OF THE HERNIAL OPENING AT THE UMBILICUS.

For the first steps in the closure see Fig. 201. The first row of sutures has been tied, and the second row is nearly completed.

through the fascia of the abdominal wall, at a point just above the sac—above, because the omentum is here usually free from adhesions. The opening in the abdomen should be just large enough to admit the finger. After the finger has been introduced, it acts as a guide, and the operator cuts down on it, severing the sac all the way round just at its point of attachment to the abdominal wall (Fig. 200).

When the neck of the sac has been cut loose, the hernia can be lifted out and laid on a large piece of gauze. After seeing that no intestinal loops are incarcerated in the hernia, the operator now slits up the wall of the sac to see if the omentum can be saved. Sometimes this is possible; in other cases, however, the omentum is so densely adherent to the sac that it must be removed with the sac.

Unless one has carefully dissected a series of large umbilical herniæ, he has little idea of the many alcoves and channels running off from the main cavity (Fig. 204). After the omentum has been replaced or tied off, as the case may be, the peri-

toneum is closed and the fascia overlapped from above downward, as advocated by Dr. Wm. J. Mayo, Dr. Charles P. Noble, and others. The fascia from the lower part of the abdominal ring is drawn up in under the fascia of the upper wall (Fig. 201). Two rows of mattress sutures in the fascia usually suffice to give a permanent cure (Fig. 202). The fat and skin are then approximated. It would be im-

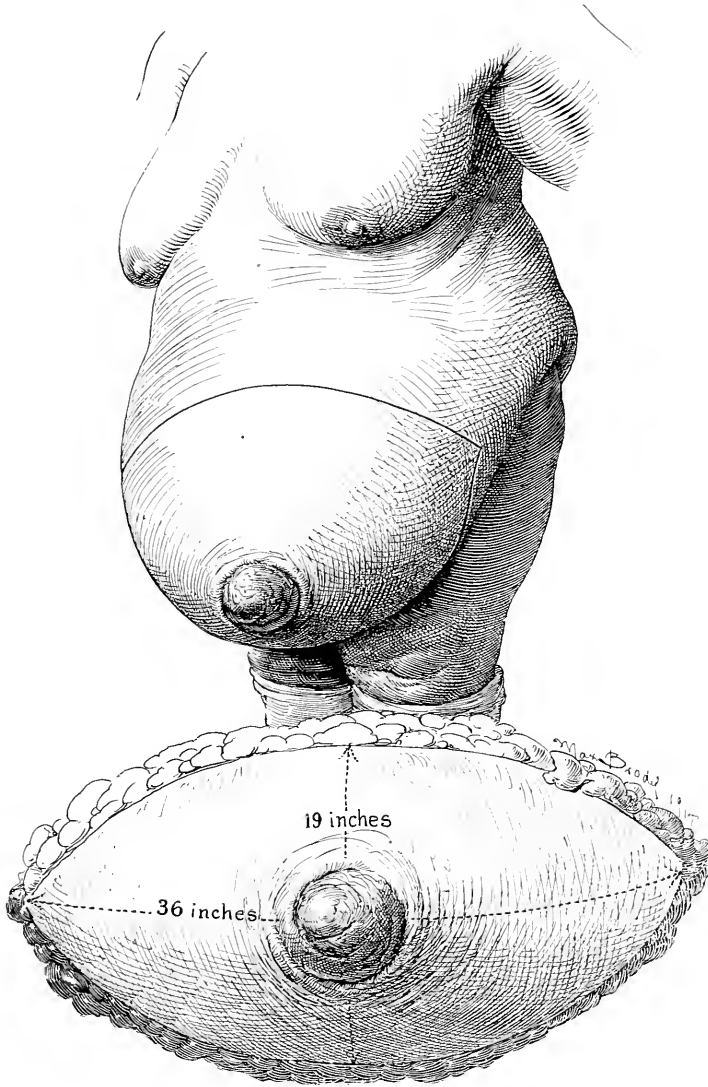


FIG. 203.—AN UMBILICAL HERNIA ASSOCIATED WITH MARKED PROLAPSUS OF THE ABDOMINAL WALL. The umbilical hernia was about 10 cm. in diameter. The elliptic transverse incision is indicated by the black line. The lower figure indicates the shape and size of the piece of adipose tissue removed.

possible to lay too much stress on the importance of freeing the neck of the sac from the abdominal wall before attempting to unravel the sac-contents, and upon the ease with which this can be accomplished by using the finger in the abdomen as a guide in its liberation. I have used this method for years, and found it particularly useful in the following case:

Mrs. C. J., aged thirty-five, admitted to the Church Home and Infirmary on February 11, 1914. This patient has had five children, the youngest being

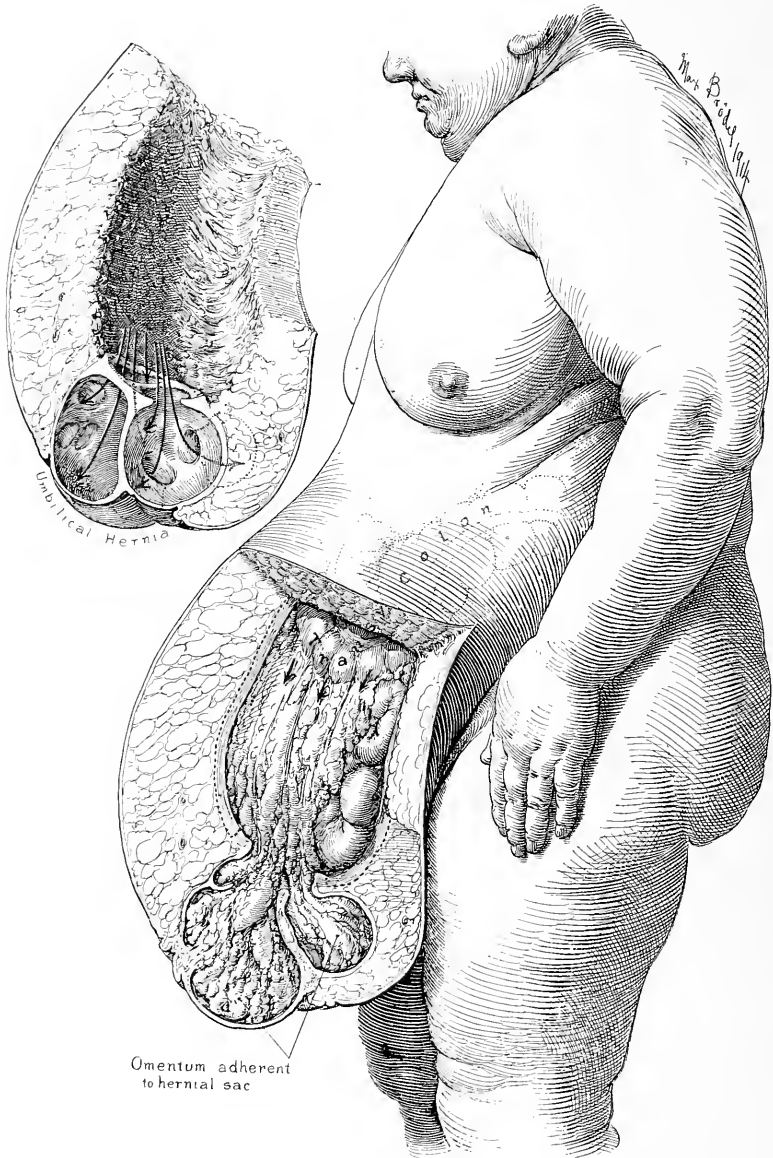


FIG. 204.—AN UMBILICAL HERNIA AND A MARKEDLY PENDULOUS ABDOMEN IN A PATIENT WEIGHING 464 POUNDS.

This is a sketchy outline of the condition found. With the patient standing, the dependent portion of the abdomen reached the knees. As the omentum was adherent to the hernial sac, the transverse colon was markedly drawn downward. The dotted line indicates the line of dissection, the fat of the abdominal wall being removed down to the fascia. The hernial sac was divided into numerous secondary cavities. This is particularly well seen in the upper sketch, which was drawn from the hernial sac after removal.

eight months old. At the time of her marriage she weighed 225 pounds. Her weight today is 464 pounds. She complains of an umbilical hernia which is about 10 cm. in diameter. When on her feet, the abdomen hangs down to her knees.



The dragging sensation caused thereby is so great that she is forced to keep off her feet as much as possible. I was unwilling to operate, and explained the danger to her husband. The patient, who is still a relatively young woman, said that she was becoming a semi-invalid and insisted that she be relieved.

Operation.—February 12, 1914. On account of the marked redundancy of the abdominal wall, we decided to relieve her of a large quantity of fat, together with the hernia, as advocated by Dr. Howard A. Kelly. Accordingly, a large transverse elliptic area was outlined (Fig. 203). This area, when measured on removal, was 36 inches from side to side and 19 inches from above downward. The adipose tissue of the huge flap was dissected from the fascia of the abdominal wall all around as far



FIG. 205.—THE ABDOMINAL SCAR AFTER THE REMOVAL OF A VERY LARGE AREA OF FAT.

The abdominal wound gave a transverse measure of 36 inches. After the wound had healed, the scar had contracted down to 27 inches. Note the size of the patient relative to that of the bed. This was of the three-quarter size, the ordinary hospital bed being too small for the patient.

as the neck of the hernia. Then, with a finger in the abdomen as a guide, the neck of the sac was cut all around at its margin with the abdominal wall. The dotted line in Fig. 204 indicates the line of the dissection. The omentum in the sac was so intimately blended with the walls of the sac that this portion of the omentum was cut off and removed with the sac and redundant tissue. Max Brödel, in the upper sketch in Fig. 204, has clearly shown the neck of the sac and the numerous chambers passing off from it. The hernial opening was closed by the Mayo method—by sliding the fascia of the lower margin of the opening up under that of the upper margin. We used kangaroo tendon for the mattress sutures, and after the first row had been placed and tied, the edges of the upper flap were fastened down with

a second row of mattress sutures. The abdominal wound was now approximated with interrupted silver-wire and silkworm-gut sutures. Each suture included the skin, fat, and a little of the fascia. Accurate skin approximation was obtained by using continuous black silk. At each end of the incision a protective drain was introduced.

The patient made a speedy recovery, and the abdominal wound healed perfectly. When the stitches were removed, the abdominal incision had contracted down until it measured only 27 inches from side to side (Fig. 205). Eight months later the patient was in excellent health.

#### HERNIAE THROUGH WEAK SPOTS IN THE ABDOMINAL WALL.

Where the hernia develops from a weak spot near the umbilicus it closely resembles an umbilical hernia, and clinically may be considered as such. This subject is discussed in detail on p. 55.

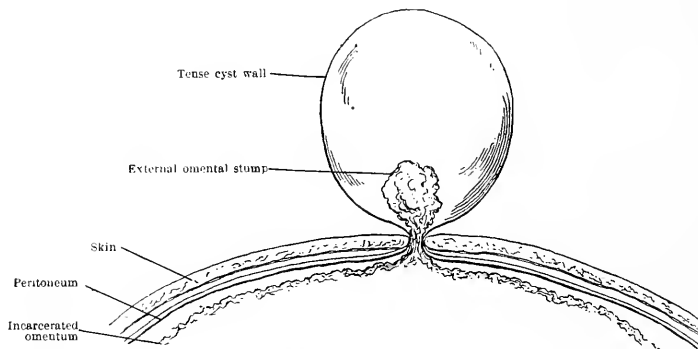


FIG. 206.—AN UMBILICAL CYST. (After Gallant.)

A Scotch terrier developed a small umbilical hernia when about four months old. It enlarged so that the dog had to drag itself about on the floor. The cyst became larger and somewhat inflamed. The skin grew so thin that the fluid could be seen in the center. The ring had evidently contracted down on the omentum, and the peritoneal fluid had accumulated.

#### CYSTS OF THE UMBILICUS.

When an umbilical hernia exists, as a matter of course the peritoneum is carried ahead of the hernial mass and hence lines the hernial sac. If by any chance the hernial sac becomes completely separated from the abdominal cavity, peritoneal fluid may accumulate in this sac, producing a cystic tumor. Gallant and Walz report cases clearly demonstrating such a phenomenon. Gallant's\* subject was a Scotch terrier that developed a small umbilical tumor when four months old. The hernia enlarged, and the puppy had to drag himself about the floor on his abdomen. The cystic mass increased in size and became somewhat inflamed. The skin covering it grew so thin that the fluid in the sac could be readily seen. At operation the condition depicted in Fig. 206 was found. Firmly plugging the hernial ring was a small piece of omentum, and the peritoneal lining had doubtless secreted the fluid found in the sac.

Walz, † on January 6, 1902, saw a gunmaker, aged fifty-one, lying in bed com-

\* Gallant: Disorders of the Umbilicus with Special Reference to the New-born and the Infant; III Umbilical Infections. *Internat. Clinics*, 1907, 17, series, i, 151.

† Walz, Karl: Ein Beitrag zur Kenntnis der Nabelcysten. *Münch. med. Wochenschr.*, 1902, xlix, 959.

plaining of pain in the umbilical region and of diarrhea. For several years the patient had noticed a tumor the size of a walnut at the umbilicus. This could be readily pressed back, but coughing caused it to reappear. For twenty-four hours the patient had had increasing pain at the umbilicus, and the tumor had rapidly increased in size and could not be reduced. Since that time there had been diarrhea, but no vomiting. His temperature was 37.6° C.; pulse 90 and regular. In the umbilical region was a half-ball-shaped tumor, the size of a hen's egg, directly to the left of the umbilicus. It overlapped and covered the umbilicus. The overlying skin was movable and somewhat reddened.

Walz thought that the nodule was due to incarcerated omentum. At operation it was found to contain clear serous fluid supposed to be peritoneal fluid. After the fluid had escaped, the cavity was found to be empty. The walls were 0.5 to 1 mm. thick, and the sac ended in a pedicle the thickness of a lead-pencil, which passed into the umbilical ring. There was no opening into the abdomen. The sac was tied off and removed, and the patient made a good recovery.

Microscopic examination of the sac shows that it was composed of fibrous tissue with an inner wall of granulation tissue; there were a few polymorphonuclear leucocytes, and no evidence of epithelium. Walz thought it possible that a hernial sac had been nipped off from the abdomen as a result of an inflammatory process, and that the fluid had accumulated. This seems to be the correct interpretation.

These two cases clearly demonstrate how small umbilical cysts may be the end-result of old herniæ.

Caruso\* reports an instance of an umbilical cyst the size of a chestnut, in a woman forty-two years of age. On histologic examination it was found to be lined partly with cuboid, partly with low cylindric epithelium. He called it a cystic adenoma. Without seeing the specimen I should hesitate to classify it, but we know that the cells covering the peritoneal surface, when protected, frequently become cuboid.

Ledderhose,† in his masterly article on surgical diseases of the umbilicus, refers to the scanty mention of umbilical cysts. He then describes Lotzbeck's case, in which a multilocular tumor the size of a fist was removed by Brun from the umbilicus in a child two and one-half years old. It was noticed immediately after the birth, and at that time was the size of a walnut. It contained partly clear, amber-yellow, somewhat alkaline fluid, partly a thick, honey-brown, gelatinous substance. The tumor lay between the skin and the rectus. The connective-tissue wall of the cyst contained small, thread-like, cartilaginous deposits, and the cyst was lined with simple squamous epithelium. The cyst fluid contained fat, cholesterin, and numerous cells. The possibility that this was a dermoid cyst must not be overlooked.

For umbilical cysts of urachal origin see pages 526 and 539.

Coÿne,‡ in 1909, reported a case that hardly belongs to the solid umbilical tumors, and yet, on the other hand, cannot be considered as a simple umbilical cyst.

\* Caruso, F.: Contributo allo studio anatomo-patologico dei tumori cistici dell' ombelico. *Atti della Soc. Italiana di Ost. e Gin.*, 1901, viii, 293.

† Ledderhose: *Chirurgische Erkrankungen des Nabels*. *Deutsche Chirurgie*, 1890, Lief. 45 b.

‡ Coÿne: Tumeur congénitale de l'ombilic développée dans un vestige de la vésicule allantoïdienne. *Comptes rend. hebdom. des séances et Mém. de la Soc. de biol.*, Paris, 1909, lxxvii, 383.

Coÿne's tumor was from a woman who had noticed it for sixteen months. She had always had some abnormality at the umbilicus. The mass was the size of an adult's head and was pedunculated. It was 20 cm. in diameter. On section it was found to contain arteries and veins in a reticulated tissue. There was one large cavity with three or four secondary cavities opening into it. These contained vegetations.

The cavities were lined with cylindric epithelium, and the vegetation was covered with cylindric epithelium. In the pedicle was found the fibrous tissue characteristic of the urachus. In the center were vestiges of the allantois. These portions of the allantois had undergone colloid cystic transformation and had been the point of departure for this cystic tumor.

Whether Coÿne was right in his assumption I am not in a position to judge.

#### LITERATURE CONSULTED ON UMBILICAL HERNIA.

- Ahlfeld: Zur Aetiologie der Darmdefecte und der Atresia ani. Arch. f. Gyn., 1873, v, 230.
- Brun: Treatment of Umbilical Hernia. Jour. Amer. Med. Assoc., October 26, 1912, 1578. Abstract from Arch. de médecine des enfants, Paris, Sept., xv, No. 9, 641.
- Caruso, F.: Contributo allo studio anatomo-patologico dei tumori cistici dell' ombelico. Atti della Soc. Italiana di Ost. e Gin., 1901, viii, 293.
- Catteau, J. F.: De l'ombilic et de ses modifications dans les cas de distension de l'abdomen. Thèse de Paris, 1876, obs. 11, 12, 13.
- Coÿne: Tumeur congénitale de l'ombilic développée dans un vestige de la vésicule allantoïdienne. Comptes rend. hebdom. des séances et Mém. de la Soc. de biol., Paris, 1909, lxxvii, 383.
- Gallant, A. E.: Disorders of the Umbilicus with Special Reference to the New-born and the Infant; II; Umbilical Fistulas, Sinuses, and Cysts. International Clinics, 1906, 16. series, iii, 218. See also International Clinics, 1907, 17. series, i, 151.
- Gauderon: De la péritonite idiopathique aiguë des enfants; de sa terminaison par suppuration et par évacuation du pus à travers l'ombilic. Thèse de Paris, 1876, No. 148.
- Kern, Theo.: Ueber die Divertikel des Darmkanals. Inaug. Diss., Tübingen, 1874.
- Ledderhose: Deutsche Chirurgie, 1890, Lief. 45 b.
- Nicaise: Omblie. Dict. encyclopédique des sci. méd., Paris, 1881, 2. sér., xv, 140.
- Perrin, Maurice: Brit. Med. Jour., April 9, 1910. Epitome of Current Med. Lit., 58.
- Power, D'Arcy: A Case of Congenital Umbilical Hernia. Trans. Path. Soc., London, 1888, xxxix, 108.
- Reed, Edward N.: Infant Disemboweled at Birth—Appendectomy Successful. Jour. Amer. Med. Assoc., July 19, 1913, 199.
- Runge, M.: Die Wundinfektionskrankheiten der Neugeborenen. Die Krankheiten der ersten Lebensstage, Stuttgart, 1893, 2. Aufl., 56.
- Sanderson, S. E.: Personal communication.
- Sheen, William: Some Surgical Aspects of Meckel's Diverticulum. Bristol Medico-Chirurg. Jour., 1901, xix, 310.
- Stewart, G. C.: Hernia of the Umbilical Cord. Brit. Med. Jour., 1905, i, 247.
- Walz, Karl: Ein Beitrag zur Kenntnis der Nabeleysten. Münch. med. Wochenschr., 1902, xlix, 959.
- Yates, H. Wellington: Personal communication.

## CHAPTER XXVIII.

### THE URACHUS.

General consideration.  
Exstrophy of the bladder.

In early fetal life this structure passes as a patent duct through the umbilicus, and at birth in a few cases the canal still persists. A consideration of the umbilical portion of the urachus was accordingly essential. The subject became so fascinating that I undertook a comprehensive study of the urachus and its diseases, the results of which are given in the following pages.

In the chapter on Embryology, the development of the urachus is given in full.

Exstrophy of the bladder has been considered here because clinically it has some points of resemblance to the dilated umbilical end of the urachus occasionally noted:

A reference to the chapter on The Patent Urachus will show that now and then the urachus remains open all the way from the bladder to the umbilicus, and that in such cases, just as soon as the cord drops off, urine escapes both from the urethra and from the umbilicus.

Under remnants of the urachus I have considered small segments of the duct that have persisted in children or in adults. Such remnants are usually spindle-shaped, and contain a small amount of secretion, which may be yellow and limpid or sticky and brownish in color.

Urachal cysts form a very interesting group of cases. They may be small or large. The small ones are usually not larger than a pea, and are accidentally discovered during an operation or at autopsy. The large cysts occasionally occupy not only the entire anterior abdominal wall, but also the pelvis. They naturally lie between the abdominal muscles and the peritoneum of the anterior abdominal wall.

Urachal remains occasionally communicate with the umbilicus or bladder or with both. Those opening into the bladder are particularly instructive. These patients usually give a history of vesical irritability, and from time to time pus is passed with the urine. Sometimes the urachus is in reality an alcove from the bladder, the opening being very wide and assuring complete emptying of the cavity each time the bladder is evacuated. On the other hand, if the communicating opening is very small, whenever the bladder contracts, a good deal of urine may be forced into the urachal pouch. In these cases the urine stagnates, decomposes, and the patient develops a train of constitutional symptoms.

From time to time a very hard tumor develops between the umbilicus and pubes. This usually gives the patient considerable pain, and its presence is sometimes accompanied by fever. When the growth is exposed, it is found to lie between the recti muscles in front and the peritoneum of the anterior abdominal wall behind. Its walls are dense, and its center is filled with grumous material mixed with pus. These tumors result from a low-grade infection of remnants of the urachus.

I have considered acquired urinary fistulæ at the umbilicus somewhat fully. They evidently occur only rarely unless remnants of the urachus exist. In these cases if the urethral canal is closed as the result of stricture, an enlarged prostate, a vesical stone, or a tumor of the bladder that blocks the inner urethral orifice, the old path from the bladder to the umbilicus may become open again and the urine escape in part or in its entirety from the umbilicus, until the urethral obstruction is removed.

I have devoted some space to a consideration of urachal concretions and urinary calculi associated with urachal remains. Urachal calculi may be multiple. They are very small, and seem in the main to be composed of inspissated contents of the small cyst cavities. Urinary calculi are now and then associated with urachal remains, and in one instance at least a vesical stone has been removed through the umbilicus. In this case the urachus extended as a wide canal from the umbilicus to the bladder.

In a few cases malignant changes have developed in a patent urachus. The growth may be a cancer or a sarcoma.

With the careful study and publication of urachal lesions in the future, I feel sure other interesting urachal remnants or pathologic conditions caused by them will be brought to light.

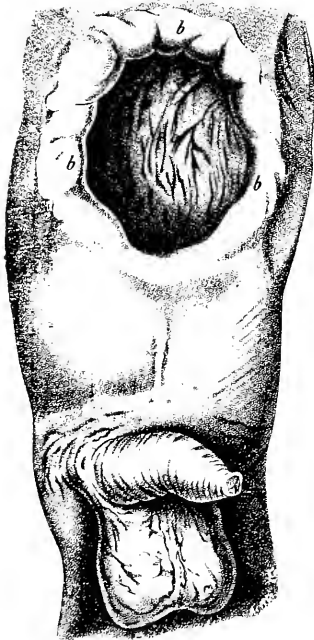


FIG. 207.—EXSTROPHY OF THE BLADDER. (After F. A. von Ammon.)

(Plate 16. Fig. 16. Copied from Forriep.) This shows the bladder opening at or near the umbilicus. The genital structures appear to be normal, and the abdominal wall immediately above the symphysis is unaltered. *a*, The bladder opening very high up; *b*, the surrounding undulating abdominal wall.

#### EXSTROPHY OF THE BLADDER.

An extended description of exstrophy of the bladder hardly comes within the scope of this book, but, on account of its occasional proximity to the umbilicus, I shall briefly consider it.

A glance at the chapter on Embryology (p. 17) will show that the bladder in the young embryo frequently extends upward almost to the umbilicus; consequently, if for any reason there be a defect in the lower abdominal wall, exstrophy of the bladder may result.

Prestat,\* in 1838, described the appearance of a still-born child at the seventh month, with exstrophy of the bladder. The greater portion was open anteriorly. The bladder was represented as a slight depression covered over with mucous membrane, which was continuous with the skin of the abdomen. It extended from half an inch below the umbilicus to the pubes. In its lower part were two tubercles—the ureteral openings. The pubic bones were represented by fibrous tissue. The other pelvic structures were normal.

Von Ammon,† in his book on Congenital Surgical Diseases, published in 1842,

\* Prestat: Bull. de la Soc. anat. de Paris, 1838-39, xiii, 69.

† von Ammon, F. A.: Die angeborenen chirurgischen Krankheiten des Menschen, Berlin, 1842.

says that the umbilicus in cases of exstrophy of the bladder is inserted very deeply.

He refers to an interesting case of bladder exstrophy reported by Froriep. The illustrations in this case are most instructive.

Fig. 207 shows a large, almost circular opening in the umbilical region.

Through this aperture the posterior wall of the bladder is visible. The lower part of the anterior abdominal wall is intact and the genitals of the child, which was a male, are normal.

In Fig. 208 we have a lateral view of the entire urinary tract. The only abnormality is in the upper part of the bladder. The

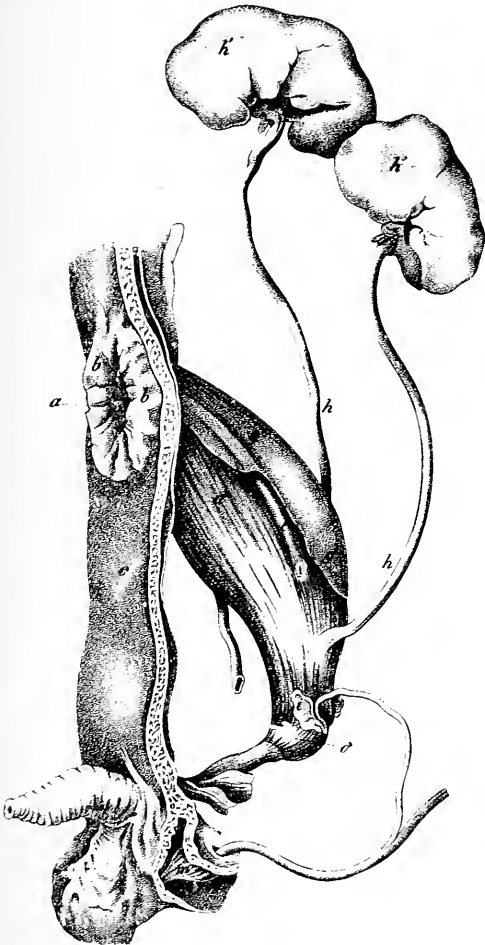


FIG. 208.—EXSTROPHY OF THE BLADDER. (After F. A. von Ammon.)

This is a side view of the case depicted in Fig. 207, and gives the relative distance from the symphysis to the opening in the abdominal wall. *a*, the opening; *b, b*, the margins; *d*, the bladder; *g*, the covering and peritoneum of the posterior surface; *h*, the ureter; *h'*, the kidney.

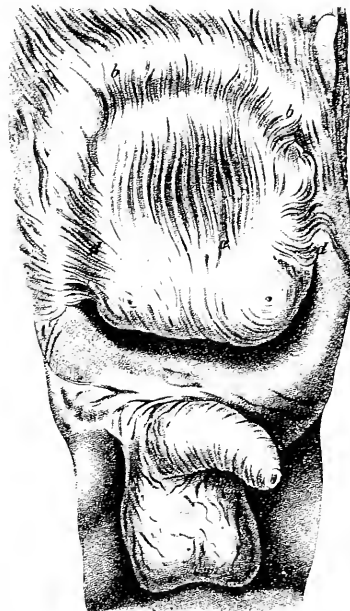


FIG. 209.—EXSTROPHY OF THE BLADDER. (After von Ammon.)

This represents Fig. 207 turned inside out. The bladder has literally been inverted upon the abdomen. *a*, the bladder mucosa; *d, d*, are a short distance from the corresponding ureteral orifice; *b, b*, indicate the margins of the opening.

top of the bladder is firmly fixed to, and opens directly upon, the abdominal wall, just below where the umbilicus should be.

Fig. 209 shows that it was possible for almost the entire bladder to prolapse through the exstrophy opening. In other words, the bladder could be turned inside out, and the ureteral orifices were then recognized as small openings just above the symphysis. Such a picture as this is, of course, exceptional.

*Exstrophy of the Bladder.*—Recently a very interesting case of this character came under our observation:

Gyn. No. 21594. Miss A. C. H., aged twenty-nine, was admitted to the Gynecological Department of the Johns Hopkins Hospital under Dr. Howard A. Kelly's care on October 11, 1915, for a "growth in the abdominal wall."

Her father, mother, one sister, and two brothers are living and well, and she has always enjoyed relatively good health. No history of congenital malformation in any member of the family could be elicited.

The patient began to menstruate at seventeen, was irregular for five years, but has been regular since then. The flow lasts six days and is accompanied by pain on the first day. There is no intermenstrual bleeding.

*Present Illness.*—The patient has always had a mass in the lower abdominal wall. She does not think it has grown except in proportion to the growth of the body. The pubic bones have always been widely separated, as they are now, causing nodular elevations laterally. There is no difficulty in walking. The patient has never been very strong, but has always been well.

Her main discomfort has been a tenderness in the lower border of this mass, accompanied by an inability to hold her urine. She has always worn pads to catch it. The urine has never showed blood. The mass has not ulcerated, but slight traumatism has always been sufficient to start bleeding.

When the patient was fifteen, she had pain in the left side, the maximal intensity being in the upper left fossa. There was also great tenderness in the left superior lumbar triangle. The pain was intermittent; it was unaccompanied by nausea or vomiting, and was not sufficient to cause the patient to go to bed. These pains lasted for two years. Since then they have occurred once or twice a year, but have been relieved by hot applications. Ever since the trouble on the left side the urine from the left ureter has been cloudy and scant in amount. The flow from the right, on the other hand, has always been abundant.

*Physical Examination.*—The right kidney extends to the crest of the ilium, the left cannot be felt. The umbilicus is small, shallow, and situated rather low in the abdominal wall.

In the mid-line, in the suprapubic region, is a red, raw-looking mass, which is soft and contains urine (Plate VII). It looks something like a large red raspberry, with lobulations at irregular intervals on its surface. On its inferior surface are two lobulated knobs. At the apex of each knob is a small orifice. From the

PLATE VII.

EXSTROPHY OF THE BLADDER.

The patient was twenty-nine years old. The inverted bladder is seen situated where the symphysis pubis should be. Its velvety mucous surface is rolled out and hangs over the labia minora. The prominence on each side represents the pubic ramus. Between them is a gap 7 cm. wide, which is bridged over by a strong fibrous band. Between the umbilicus and the exstrophied bladder is a flattened, triangular area, bordered on its sides by the separated recti muscles, which are inserted into their respective separated pubic bones. The triangle is divided perpendicularly by a thick, cord-like structure connecting the umbilicus and bladder—evidently the urachus. Where exstrophy of the bladder exists, the umbilicus is usually much nearer the symphysis. In this case, however, it is not far below its normal position.

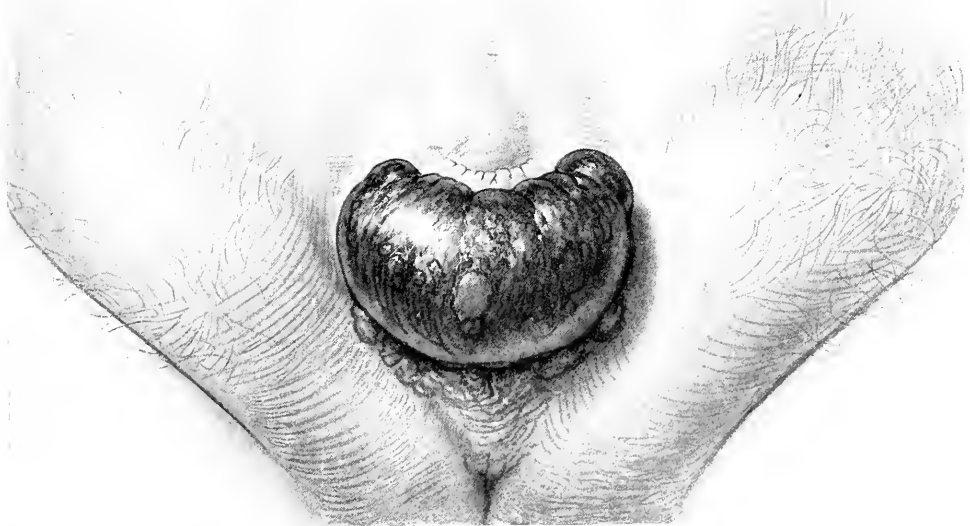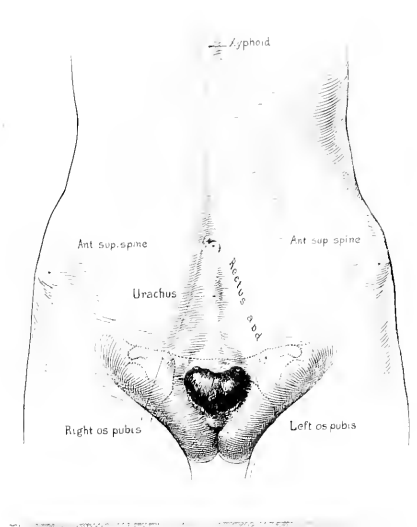
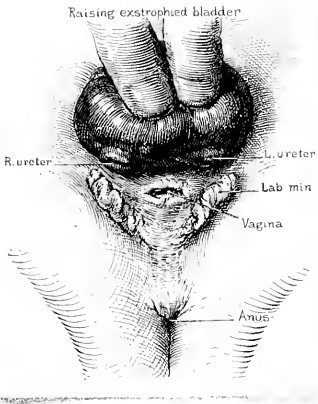
In the upper left diagram the bladder has been gently raised, exposing the ureteral orifices. Urine escaped freely from the right ureter; the left was apparently functionless.

The labia minora are widely separated above. The clitoris apparently consists of two separated portions.

The right upper picture schematically represents the abdominal topography. Note the wide separation of the pubic bones and of the anterior-superior spines, likewise the unusually wide space between the thighs.



PLATE VII.  
Exstrophy of the Bladder.



right. urine flows in a small stream on voluntary expulsion by the patient. The lower and under surface of the mass is very tender. The mass measures 4.5 x 3 x 4 cm. It cannot be reduced into the abdomen.

The pubic hairs are scanty. The labia minora are very atrophic, and diverge above, extending outward to the lateral margins of the exstrophy. Some observers are of the opinion that the clitoris is absent; others that it appears as two rudimentary portions. The urethra and the anterior bladder-wall are totally wanting. The vaginal orifice is very small; the hymen is intact.

Rectal Examination.—The sphincter tone is normal. The cervix is elongated, and its external os lies just within the hymen. The uterus is somewhat enlarged and in good position. The adnexa cannot be felt. From each uterine cornu a round cord, the size of a lead-pencil, can be felt passing downward and outward to the inguinal canal—these are apparently the round ligaments.

At the apex of the vagina, and extending laterally from the junction of the cervix and body of the uterus, firm, ligamentous structures can be palpated—these are probably the bases of the broad ligaments.

A cord can be felt extending from the upper margin of the exstrophied bladder to the umbilicus. This, undoubtedly, is the urachus.

The pelvis has a peculiar form. It is abnormally wide; it shows a flaring of the false pelvis and a wide diastasis of the anterior pelvic arch. The spines of the pubes are 19 cm. apart. For a woman of her size they should be 10 cm. apart. The mesial borders of the pubic bones are separated by a space of 7 cm., there being a tight, dense, but pliable ligament connecting them.

The following are the measurements of the pelvis:

Distance between the pubic bones in front . . . . .	7 cm.
Distance between the external superior spines . . . . .	19 cm.
Distance between the anterior superior spines of the ilium . . . . .	32.5 cm.
Distance between the iliac crests . . . . .	35 cm.
Distance between the great trochanters . . . . .	39 cm.

The perineum is wide. When the legs are brought together, the space between them is not closed. With the knees together and the legs flexed, there is a space 9 cm. broad, representing the width of the perineum.

A glance at Plate VII will give the reader a clear idea of the appearance of the exstrophy.

The implantation of the ureters into the rectum was considered, but the patient refused to have anything done and returned to her home.

Kelly and Burnam,\* when referring to the subject of exstrophy of the bladder, quote Spooner as saying that in 116,500 patients it was noted only four times, a clear indication that this is a very rare malformation. In Fig. 491, Vol. II, of Kelly and Burnam's work, is depicted an exstrophy of the bladder observed by Guy L. Hunner. In this case the exstrophy bears a marked resemblance to the one we are describing, but the umbilicus was situated just above the exstrophy, instead of in the relatively normal position.

\* Kelly, Howard, and Burnam, Curtis F.: Diseases of the Kidneys, Ureters, and Bladder, D. Appleton & Co., 1914, ii, 385.

## CHAPTER XXIX.

### CONGENITAL PATENT URACHUS.

#### Symptoms.

Appearance of the umbilicus.

An umbilicus without tumor formation.

An umbilicus with tumor formation.

#### Treatment.

Patent urachus and patent omphalomesenteric duct in the same child.

Detailed report of cases of children born with a patent urachus.

OCCASIONALLY an infant is brought to the physician with the history that a few days after birth a watery discharge was noted at the umbilicus and that this discharge has continued. Where the discharge is abundant, it is invariably due to a patent urachus.

**E s c a p e o f U r i n e .**—The manner in which the urine escapes from the umbilicus varies. It may come away in very small quantities or be discharged in abundance. In Jacoby's case the umbilical depression was often filled with urine. In Goupil's case it came drop by drop, as from a still. In Alric's Case 1 it came drop by drop when the child cried. In Charles' case urine would "fall" from the umbilicus. In Jahn's case urine escaped when pressure was made upon the abdomen. Stierlin's patient passed only a small quantity from the umbilicus during the day, but at night the bed was saturated. In Paget's case the urine gushed from the umbilicus, while in Marx's case it came away in jets. French's patient discharged a small umbilical stream when crying. Annandale's patient, who was thirty-nine years of age, passed two-thirds of his urine from the umbilicus in a stream, when in the upright position; when he was lying down, the urine escaped involuntarily from the umbilicus. Erdmann's patient, who was four years old, at times passed an umbilical stream 4 to 12 inches high. In Hue's case the urine escaped from the umbilicus at night.

In Pauchet's case the escape of urine from the umbilicus was intermittent, occurring at intervals of from four to five days and persisting from one to two days each time.

In Cabrol's case, in which the urethra was completely blocked, all the urine, of course, escaped from the umbilicus.

The character and size of the umbilical stream will, of course, depend on the caliber of the patent urachus, the size of the umbilical opening, and occasionally on the ease or difficulty with which urine can escape from the urethra. The urine naturally follows the path of least resistance.

On questioning the parent it will be found that the urine commenced to escape from the umbilicus just after the cord came away; and some of the more careful observers among the physicians, midwives, and mothers will have noted that the umbilical cord was unusually thick near the abdomen. In these cases, of course, the urachus was patent from the bladder to a point in the cord distal from

the point of ligation, and naturally no urine could escape until the ligature had sloughed off.

In Delagènière's case the urachus was evidently almost patent at birth, but did not open until the child was six months old.

#### APPEARANCE OF THE UMBILICUS.

In glancing over the detailed histories of the cases of patent urachus it will be noted that in some cases the umbilicus was but little altered (Fig. 210), while in others a definite, tumor-like mass was found.

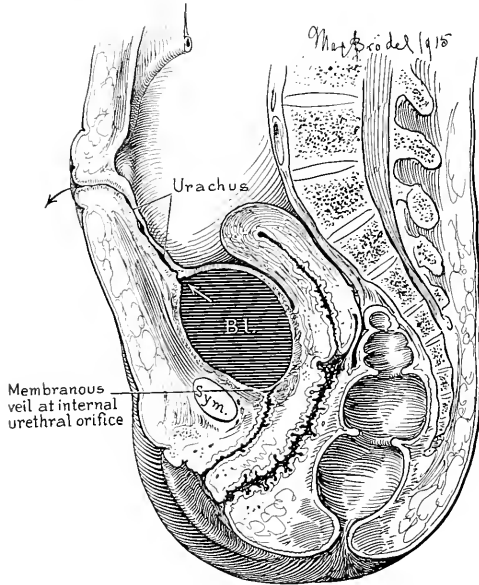


FIG. 210.—ESCAPE OF URINE FROM THE UMBILICUS WHEN THE INNER URETHRAL ORIFICE IS BLOCKED BY A MEMBRANE. (Schematic.)

At least one case of this character has been recorded. As soon as the membrane was severed, nearly all the urine escaped by the urethra, and in a short time the discharge from the umbilicus ceased.

In Florentin's case, in which it was the size of a pea. The nodule is usually spoken of as being the size of a nut, a cherry, or small strawberry. Sometimes it is dark red, flabby, and suggests granulation tissue. In other cases it may be firm, and red or violet in color. In a few cases it resembled a mushroom or flattened button, and was attached to the umbilicus by a pedicle (Fig. 211).

In Starr's case the umbilicus was larger and more widely open than usual, and in the center of the cartilaginous, nipple-like projection was an orifice which admitted an ordinary probe. In Cabrol's case (quoted by Florentin) there was a projection at least four fingerbreadths long which resembled the crest of a turkey. In Alric's Case 1, a boy ten months old, had a bright-red umbilical projection, 3 or 4 cm. long. This also bore a marked resemblance to the comb of a turkey-gobbler.

Occasionally the umbilical tumor resembled a glans penis (Fig. 212). Meyer's patient was a child one year old. The umbilicus was thickened and, although no hernia existed, it was prominent and in contour resembled a glans penis.

**An Umbilicus Without Tumor Formation.**—The umbilicus may show little deviation from the normal, and the urachal opening be scarcely visible. In other cases the umbilicus is a little broader than usual and has five or six radial folds. At the place where these meet the urachal opening is usually found, and sometimes there is a definite funnel-like depression. Occasionally, as noted in Huggins' case, the urachal opening may be found in the lower margin of the umbilical ring. In Stevens' case there was a small hernial protrusion at the umbilicus. Fig. 255 (p. 625) represents a small hernial protrusion associated with a patent urachus.

**An Umbilicus with Tumor Formation.**—As a rule, the umbilical growth is small. Sometimes it is very minute, as in

French's patient was a female infant six weeks old. At the umbilicus there was a hernia-like protrusion of the skin about three-quarters of an inch in length, surmounted by a red, fleshy outgrowth like a swollen and fungoid glans penis; whenever the child cried or struggled, this growth became very prominent and vascular. In practically all of the cases in which the umbilical tumor existed, the urachal opening was situated in the center of its most prominent point.

**Size of the Umbilical Opening.**— Sometimes it is not larger than a pin-point and is hardly demonstrable. In other cases it is one or more millimeters in diameter, and may admit a fine probe or a medium-sized catheter. Sometimes the probe or catheter can be carried from the umbilicus directly into the bladder, and, if the bladder extends almost to the umbilicus, the distal end of the probe can be swung as a pendulum from side to side. In some cases, particularly in those in which the urachus is tortuous, the probe can be passed only a short distance.

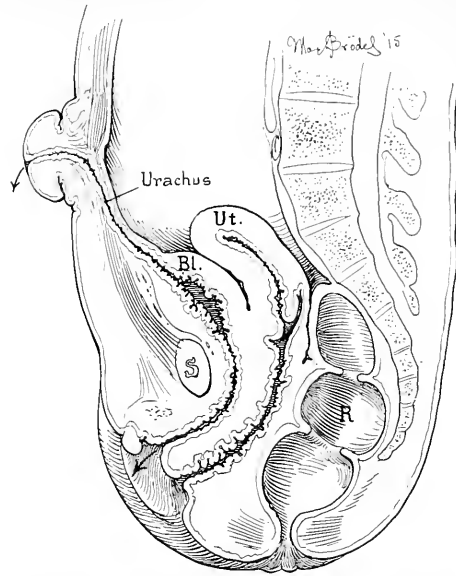


FIG. 211.—A PATENT URACHUS WITH A MUSHROOM-LIKE PROJECTION AT THE UMBILICUS. (Schematic.)

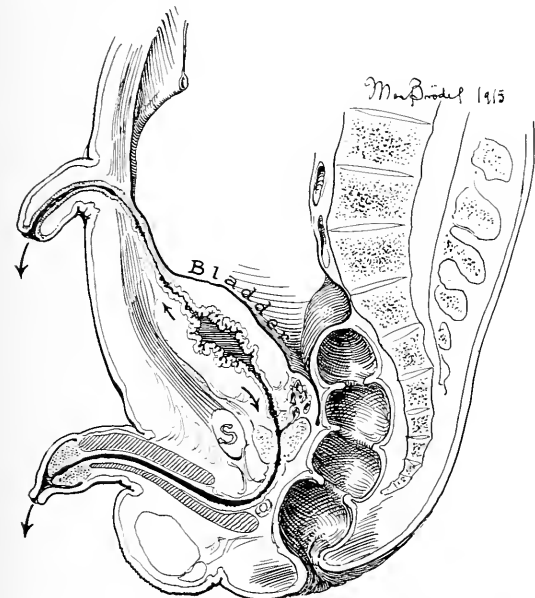


FIG. 212.—A PATENT URACHUS WITH A PENILE PROJECTION AT THE UMBILICUS. (Schematic.)

Where the urachus remains patent the umbilical end may appear as a small depression in the floor of the umbilicus. In some instances a mushroom-like elevation occupies the site of the umbilicus. In exceptional cases a definite penile projection springs from the umbilicus, and at the end of this is the opening of the urachus, as indicated in the picture.

**Irritation.**— Occasionally there is a mild or severe inflammation of the skin around the umbilicus, the degree evidently depending on the irritating qualities of the escaping urine. At times the inflammation of the skin may be so severe that small ulcerations develop.

In Hind's case, in a very young infant extravasation of urine occurred around the umbilicus and finally extended all over the abdomen. The child soon died.

**Sex.**— In 53 of the cases here recorded, 35 of the patients were males and 18 females. These figures seem to coincide with those of other observers in showing that a patent urachus at birth is more common in males than in females.

Monod, in his splendid monograph, says that it is three times more common in males than in females.

R a c e . — It will be noted that both Cabell's and Stites' patients were colored. Future observations will probably demonstrate that a patent urachus is relatively as common in the colored as in the white races. The majority of our observations to date have come from countries and localities where few negroes are found.

G e n e r a l C o n d i t i o n o f t h e C h i l d . — From the histories it will be seen that nearly all the children were in good health. A few were anemic or slightly emaciated, but no greater percentage than one would expect to find under ordinary conditions. The presence of a patent urachus seems to have little effect on the general health of the child.

#### TREATMENT.

Before undertaking the closure of the umbilical fistula the patency of the urethra must first be ascertained. In the majority of the cases the urethra has been perfectly normal. In some cases, however, a phimosis exists, and under these a circumcision should first be performed.

Goupil, in 1756, reported the case of a twelve-year-old boy all of whose urine escaped from the umbilicus. In this case there was a congenital malformation and the penis was not perforated. Draudt reports a case of urinary umbilical fistula in a child a day old. Death occurred on the fifteenth day, and at autopsy it was found that the urethra was almost totally obliterated. It is obvious that in Goupil's and in Draudt's case any attempt to close the umbilical fistula would not only have been useless, but essentially harmful.

Quite a number of the patients were never operated upon, and the urinary umbilical fistula persisted even in adult life. Spontaneous closure of the fistula is exceptional. Lugeol, however, reports the case of a female child who had at the umbilicus a small, soft, reddish-violet tumor, in the center of which was a small fistulous opening. Little by little the urinary discharge from this diminished and finally disappeared. Five months later the child was well.

Tuholske also reports a case of spontaneous healing. His patient was a man fifty-two years of age. In infancy he had passed urine from the umbilicus. This condition ceased in his fourth year without treatment, and he had no further trouble until his forty-eighth year, when, apparently without cause, the urine again commenced to flow through the navel.

Monod reports the case of a patient that came under the care of Jaboulay. A man sixty-two years of age, who was suffering with painful micturition and symptoms of an enlarged prostate, noticed urine escaping from the umbilicus. When questioned, he said that his mother had often told him that shortly after birth he was treated for the escape of urine from the umbilicus, and that this discharge had disappeared in the course of fifteen days after the application of an appropriate bandage. Jaboulay's case is another example of spontaneous closure of the fistula.

In the early days the fistulous opening was usually treated with caustics or with the actual cautery, and in quite a number of instances the fistula soon closed. Occasionally a simple plastic operation gave very fair results.

In those cases in which a definite umbilical tumor was present, it was in some instances transfixed with needles and ligated. The tumor would slough off in a few days, and the umbilical end of the fistulous tract usually remained closed.

Where the urachus still persists, there is always a chance of subsequent trouble, and there are at least three cases on record in which the patient later developed cancer of the urachus. Graf reported the case of a man, twenty-eight years old, who died of cancer of the urachus. This patient at birth had an umbilical fistula. It was healed with escharotics. Twenty-five years later carcinoma of the urachus developed. Hoffmann also reports a case in which the patent urachus was closed with escharotics when the child was in his third year. This man, when twenty-seven years old, developed a fatal carcinoma of the urachus.

Fischer records the case of a man of thirty-two who had an inoperable carcinoma of the urachus. During childhood this man, when voiding, had been aware of a "moisture at the umbilicus." Later this symptom had disappeared and he had noticed no further trouble until he was thirty-one years old.

In the light of our present knowledge of abdominal surgery the wise plan is always to remove the fistulous tract. The umbilicus is encircled and freed, and, together with the fistulous tract, is dissected free to the bladder. The bladder attachment of the urachus is treated in precisely the same manner that an appendix stump is dealt with, namely, by the employment of a purse-string suture. After the stump has been inverted into the bladder, the closure is reinforced with one or two more sutures and the wound closed. The purse-string suture should consist of fine black silk or of catgut that will last for several weeks. This method of treatment has been in use for several years, and has yielded excellent immediate results. It has also insured absolutely against any subsequent urachal trouble.

In those cases in which the urachus gradually broadens out into the bladder, the bladder opening is naturally large and sometimes cannot be satisfactorily closed with a purse-string suture. In such cases it may be necessary to close it with a continuous suture, as in the procedure for closing the bladder after a suprapubic operation.

#### PATENT URACHUS AND PATENT OMPHALOMESENTERIC DUCT IN THE SAME CHILD.

We have found numerous examples of a patent omphalomesenteric duct and of a patent urachus, but there are only two cases, as far as we could learn, in which both were patent in the same child.

Lexer, in his article on the Treatment of Urachal Fistulæ, refers to the case of a boy a year old. Urine escaped in large quantities from the umbilicus. From the accompanying history it is certain that at operation a patent omphalomesenteric duct was found, in that it is stated that the fistula was lined with typical intestinal mucosa. There seems to be little doubt that both the vitelline duct and the urachus were patent.

In the second case—related to me by Dr. Heflin—at operation a fistulous tract passing directly from the umbilicus to the small bowel was found. This tract was three inches long. After it had been cut away and the bowel closed, a second tube was found extending from the umbilicus to the bladder. This was also patent.

I have had microscopic sections made from this case. One duct, the vitelline, is lined with typical intestinal mucosa, the other, the urachus, with remnants of transitional epithelium. The patency of both ducts in this case cannot be questioned (Fig. 214).

Both of these cases are of such interest that I will cite them in detail.

A Patent Urachus and Probably a Patent Omphalomesenteric Duct.—Lexer\* in his article reports the case of a boy, a year and a half old. The cord came away on the fifth day and clear fluid was noticed coming from the umbilicus. It is said that at this time there was a reddish tumor, the size of the end of the little finger, at the umbilicus. This gradually became smaller and finally disappeared. When the child was six months old the fistula was closed by a physician by means of salves and plasters. It remained closed, however, for only two weeks. The child was restless, and there were general systemic disturbances. When the fistula reopened, a large quantity of watery fluid escaped, and pus was said to have come away at one time. When Lexer saw the child he was somewhat weak and pale. About 5 mm. below the umbilicus was a fistulous opening surrounded by an area of inflammation. Each time the child urinated a large quantity of urine escaped from the fistula, whereas from the urethra it passed drop by drop. There was a marked congenital phimosis. The case was diagnosed as one of urachal fistula. By placing a glass at the umbilicus the observer estimated that about one-quarter to one-third of the urine escaped from the navel. With a sound it was possible to make out only a small, bay-like cavity beneath the skin.

The prepuce was cut; four weeks later the urine was flowing normally and there had been a diminution in the size of the fistula. After excision of the skin around the umbilicus there was disclosed a depression lined with granulations, and scarcely larger than a hazelnut, communicating with the fistula. From this fistulous opening a sound could be passed exactly in the mid-line of the abdomen toward the bladder region. Further examination could not be made, as the child did not take the anesthetic well. As the mucosa of the fistulous tract was exposed, it was grasped with forceps and gradually drawn out. The sac was dissected out and the wound closed.

The tube was 7 cm. long, and microscopic examination showed that it was not a patent urachus, but a persistent omphalomesenteric duct. This on cross-section showed a well-developed intestinal mucosa; the lumen increased in size as it passed inward. It was lined with cylindric epithelium, had the typical Lieberkühn's glands, and also the circular and longitudinal muscle-fibers. Lexer said that from the above picture it was clear that he was dealing with a Meckel's diverticulum. The child remained well.

The history clearly demonstrates the existence of a urinary fistula, and the microscopic examination of the specimen shows a tube lined with intestinal mucosa. The only way in which the picture can be adequately explained is by a persistence of both the urachus and the omphalomesenteric duct.

A Patent Urachus and a Patent Omphalomesenteric Duct in the Same Child.—While conversing with Dr. H. T. Heflin, of Birmingham, Ala., on May 6, 1912, he related to Dr. Cunningham Wilson and myself his experience with a child fourteen months old. He saw the patient (J. S.) on August 29, 1911. Two or three days after birth bleeding occurred from the umbilicus. This bleeding at times was moderate in amount, but at other times severe, and as a result the child became very anemic. Apart from this he was perfectly well except for a tight prepuce, which had to be released. He was often constipated and cried a great deal. The more he cried the more he bled. Dr.

\* Lexer, E.: Ueber die Behandlung der Urachusfistel. Arch. f. klin. Chir., 1898, lvii, 73.



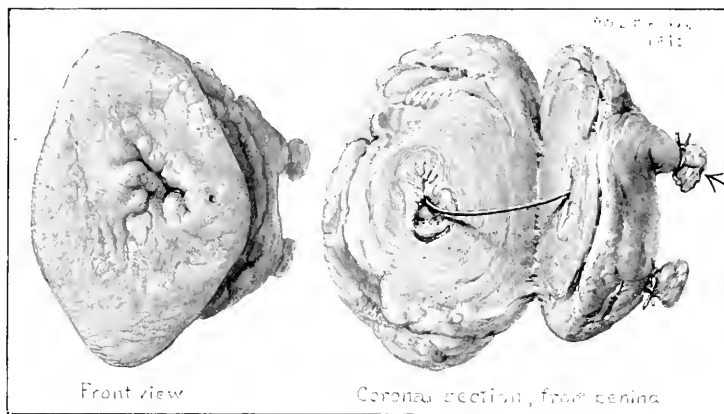


FIG. 213.—THE APPEARANCE OF THE UMBILICUS IN A CASE IN WHICH BOTH A PATENT OMPHALOMESENTERIC DUCT AND A PATENT URACHUS EXISTED. (Heflin's case.)

The umbilical depression is irregularly funnel-shaped and lobulated, and along one side is a small opening no larger than a pin-head. The picture to the right shows the cross-section of the omphalomesenteric duct in the abdominal wall. It is nearly 1 cm. in its longest diameter. It was lined with typical mucosa. To the extreme right are seen the ligated ends of the omphalomesenteric duct and the urachus. For the microscopic picture see Fig. 214.

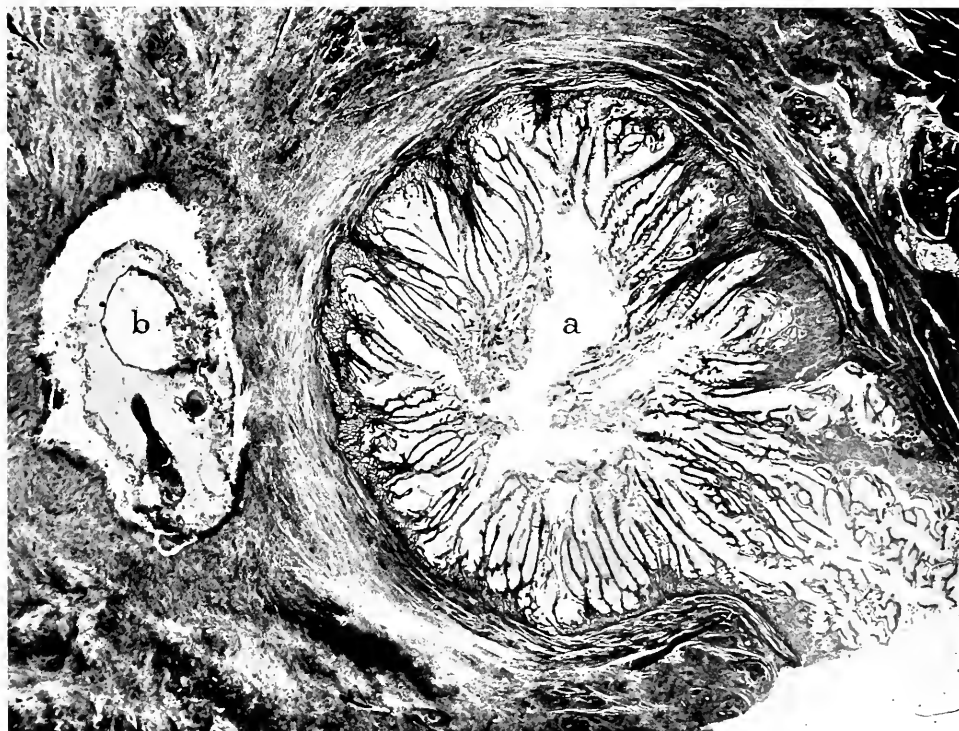


FIG. 214.—CROSS-SECTION OF THE PATENT OMPHALOMESENTERIC DUCT AND OF THE PATENT URACHUS IN THE SAME CHILD. (Heflin's case.)

The large cavity (a), to the right, is the lumen of the omphalomesenteric duct, which has been cut slightly on the slant. The mucosa is drawn up into long, papillary-like folds. Surrounding the lumen is a circular layer of non-striated muscle. The small cavity (b) to the left is what remains of the urachus. This cavity was partly filled with debris containing small round-cells and some polymorphonuclear leukocytes. The tissue immediately surrounding the lumen was very delicate in texture and has retracted from the surrounding dense tissue. The elongate dark area just below the lumen is a lymph-nodule. The tissue for a considerable distance around the urachus was infiltrated with small round-cells and polymorphonuclear leukocytes. (Photomicrograph by Mr. Herman Schapiro.)

Heffin had him under observation for some time. The mother would bring him every day or two for examination. He became paler and more exsanguinated. The bleeding was stopped temporarily sometimes by pressure, sometimes by the use of the cautery, adrenalin, or hydrogen dioxid, but, instead of diminishing, the amount of hemorrhage increased. At a later date stick silver nitrate was used.

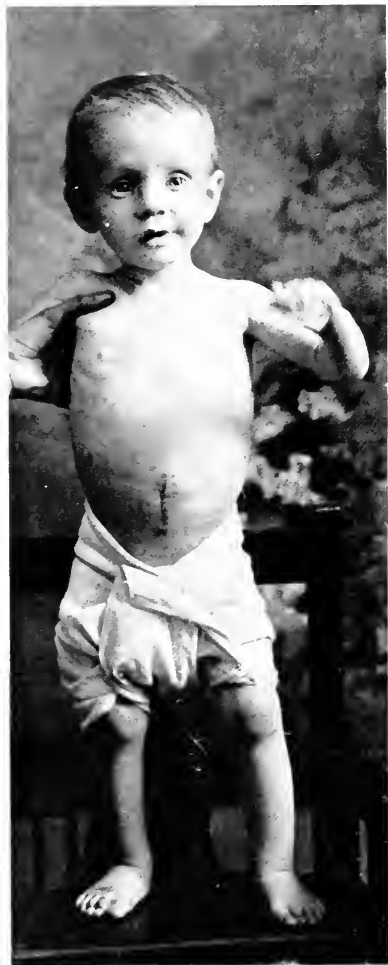

FIG. 215.—A PICTURE OF THE CHILD THREE WEEKS AFTER REMOVAL OF A PATENT OMPHALOMESENTERIC DUCT AND A PATULOUS URACHUS. HE IS NOW IN GOOD HEALTH. (Heffin's case.)

Finally, a small piece of the umbilicus was cut out for examination. The glands found in it suggested malignancy. From the time of his birth there had been some discharge from the umbilicus which had an odor of urine and at other times strongly suggested feces. Finally Dr. Heffin decided that the only proper procedure was removal of the umbilicus. He made an elliptic incision, and on lifting the umbilicus out found that there was a continuous fistula about three inches long, from the umbilicus to the small bowel. He removed it, and treated the opening in the bowel precisely as if it had been the stump of an appendix. The mesentery of the small bowel opposite the point of this opening contained quite a number of large lymph-glands, some of them nearly 1 cm. in diameter.

He also found a second tube attached to the umbilicus, which passed downward toward the bladder. It was patent. He tied it off with catgut and brought it up into the abdominal incision. The abdominal wound was brought together without difficulty and the child made a good recovery (Fig. 215).

Sections through the mass removed by Dr. Heffin from the umbilicus show two distinct tubes. One is almost circular and nearly 1 cm. across; the other about 2 or 2.5 mm. in diameter. The larger one, on histologic examination, is found to be lined with long, shaggy intestinal mucosa of the type found in the small bowel (Fig. 214). The epithelium is everywhere intact. Surrounding the mucosa is a circular muscular layer and outside of this again a cylindrical layer.

The smaller tube is somewhat disorganized. Its walls are surrounded by muscle, and its inner surface consists in large measure of granulation tissue which has become organized. The nuclei have mostly disappeared. Clumps of polygonal cells are seen here and there clinging to the wall. Surrounding the lumen are large numbers of lymphoid cells, reminding one a good deal of young lymph-glands. In the walls are polymorphonuclear leukocytes and small round-cells. Un-

doubtedly the tube represents the degenerated urachus. In this case there was a patent omphalomesenteric duct and also an open urachus.

#### REPORT OF CASES OF CHILDREN BORN WITH A PATENT URACHUS.

The following cases represent nearly all the cases we could find in the literature. Some in which the history was inconclusive have been omitted.

**A Patent Urachus with a Long Projection at the Umbilicus.**—In Alric's Case 1\* the patient was a boy ten months old, seen in 1862. He was well developed, but had at the umbilicus a tumor 3 to 4 cm. long. This was regular, round, with a diameter a little larger than that of a goose-quill. It was firm and resembled mucosa. It was bright red, and, as in Cabrol's case, bore a marked resemblance to the comb of a turkey-cock. In the center was an opening having the diameter of a fine probe, and when the infant cried, urine passed from the umbilicus drop by drop. Its nature was recognized by the color and odor.

The genital organs were normal, and the child urinated naturally through the urethra. This state of affairs had existed since birth.

As the child did not return to the hospital, no operation was done.

**A Patent Urachus.**—Alric's Case 2† was seen in 1873. The child was five years of age, and in every other respect seemed to be healthy except that it had a urinary odor. The umbilical depression was replaced by a soft, flabby, fungus-like, dark-red, somewhat rounded tumor, the size of a walnut. On manipulation it was found to have a short pedicle about the size of a pen-holder. Continually escaping from the center was a liquid, recognized by its odor as urine. When the bladder contracted, the urine escaped more freely from the umbilicus; at one time the force was sufficient to cause it to pass out in a jet. The urethra was normal.

The tumor was raised and transfixed with a needle threaded with double-waxed thread. The loop was cut, making two threads. These tied both halves of the tumor firmly. The tumor in a few minutes became dark and separated in a few days. By the fifteenth day cicatrization was complete. There was no further escape of urine and the boy remained well.

**A Case of Unclosed Urachus with Umbilical Fistula. ‡**  
—The patient was a big, strong, healthy, well-formed man thirty-nine years of age. He had passed a portion of his urine through the umbilicus ever since his birth. When he urinated in the upright position, about two-thirds would come out of the fistula in a full stream, the other third passing by way of the urethra, in a strong but small stream. When the patient was lying down, the urine would flow out spontaneously through the fistula—more markedly so when he was lying on his left side. He had to pass water regularly about every two hours, and in doing this he found it necessary to loosen all his clothes in front and bend forward. His health was good, but on one or two occasions he had passed fine calculous material with the urine.

The genital organs were well formed. The abdominal walls were perfect. The umbilicus was a little flatter than usual. In the center was an opening with depressed margins. The opening would admit the tip of the little finger. A No. 12

\* Alric: Sur deux cas de persistance de l'ouraue. Bull. de thérapeutique, 1879, xcvii, 34.

† Alric: Loc. cit., Case 2.

‡ Annandale, T.: Edinb. Med. Jour., 1870, xv, 680.

catheter passed easily from above into the bladder. There was no excoriation. A No. 6 catheter passed readily through the urethra into the bladder.

Operation was suggested, but refused.

**U r a c h a l F i s t u l a .** — H. R. Wharton reports a case that came under Ashhurst's\* care. The patient was a boy nine months old. At the umbilicus was an opening through which urine had escaped since birth. Occupying the position of the umbilicus was a flattened tumor the size of a filbert. It was covered over with mucosa, and in its center was a depressed opening, through which the urine escaped. There was no obstruction in the urethra.

The actual cautery was applied to the fistulous tract and the projection at the navel was ligated. Recovery followed.

**P a t e n t U r a c h u s .** — Binnie† says that J. D. Griffith, in a girl fifteen years of age, split, cauterized, and packed the fistula with splendid results. In this case the mother said that there had been more or less umbilical discharge from the time the cord had separated.

**A P a t e n t U r a c h u s .** — In 1847 Cabell‡ examined a mulatto girl fourteen or fifteen years old. She was in good health, but had an umbilical fistula, through which she had passed urine since her earliest childhood. Most of it, however, was passed through the natural channel. She claimed to have the power of passing it either way at will.

The umbilicus presented a flattened, disc-like appearance about the size of a quarter of a dollar. The skin around it was loose and in folds, but not so much as to attract particular attention to it. In the center was a small aperture of the usual appearance, and through this urine escaped. A catheter could be passed six to seven inches downward toward the bladder, and urine escaped from it. The urethra was rather smaller than usual.

**A P a t e n t U r a c h u s . §** — The patient was a well-developed boy one year old. The urine was first noticed escaping from the umbilicus when the cord dropped off. From the urethra it was passed with difficulty, coming only in drops. No tumor was noted at the umbilicus, but the urine filled the umbilical cup and ran over.

The prepuce was long, contracted, and adherent to the glans. The child was circumcised, and the urine later was projected through the urethra some distance, very little coming away from the umbilicus.

Charles says that sometimes it is necessary to operate on the fistula. He did not do so in this case, and the cure was not complete.

**A P a t e n t U r a c h u s . ||** — The patient, C. F., was five and a half years of age. The baby had at the umbilicus a small, violet-colored tumor, the size of a currant. At the age of six months this small tumor began to grow; it became prominent and enlarged considerably, until it reached the size of a strawberry. Some time later an orifice formed at its summit, from which a stream of serosanguineous fluid escaped. This was never examined. Since that time, according to the mother,

\* Ashhurst: *Med. News*, Philadelphia, 1882, xli, 122.

† Binnie, J. F.: *Jour. Amer. Med. Assoc.*, 1906, xlvii, 109.

‡ Cabell, R. G.: *Amer. Jour. Med. Sci.*, Philadelphia, 1848, n. s., xv, 313.

§ Charles, J. J.: *The Treatment of Patent Urachus*. *Brit. Med. Jour.*, 1875, ii, 486.

|| Delagénière, H.: *Traitement de l'ouraqué dilaté et fistuleux par la résection et la suture*. Une observation. *Arch. provinc. de chir.*, 1892, i, 222.

there had been sometimes a cessation of the discharge, but then immediately there had developed a severe pain at the umbilical region. It was on account of this pain that the mother sought surgical aid.

On examination the child was well nourished, but rather backward in development, and looked more like a four-year-old child than one of five and a half. The umbilicus was the seat of marked irritation. It was deformed and showed a transverse furrow, dividing it into two halves, an upper and a lower, both of which were indurated and red. This furrow measured about 2 cm., and was surrounded by an inflammatory zone several centimeters broad, which presented multiple erosions of the skin and several indurated points—veritable hard nodules. The principal one was situated 3 cm. below the fold of the umbilicus. Through the furrow it was possible to introduce a probe and pass it easily downward toward the nodule mentioned. The fluid escaping from the umbilicus was usually clear and transparent, sometimes tinged with blood, chiefly when the child walked. The urine escaped from the urethra in a jet, and a short time afterward some could be seen coming from the umbilicus. When the urine ceased to pass by the urethra, the discharge from the umbilicus increased.

On May 2, 1892, a median incision was made. The tissue on section had a lardaceous appearance. The operator entered into an excavation lined with fungosities and numerous diverticula. This cavity was cureted. In the lower part was a pocket into which a sound could be introduced. Delagénière decided to remove the sac (Fig. 216). He opened it and entered the peritoneal cavity. He then easily recognized the urachus, which showed as a duct lined with smooth mucous membrane. The duct was isolated for a distance of 3 cm. and ligated. The sac was then removed, a drain introduced, and the abdomen closed. The patient made a satisfactory recovery.

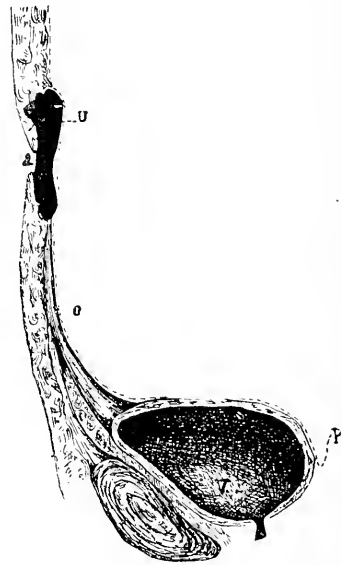


FIG. 216.—A PATENT URACHUS. (After Delagénière.)

Anteroposterior section through the lower part of the abdomen. P, peritoneum; V, the bladder; O, the urachus; U, the urinary pouch; a, the orifice of the fistula at the umbilicus.

**A Patent Urachus.**—Draudt\* describes the case of Fritz R., six months old. For several weeks a clear fluid had been escaping from the umbilicus. Whether it had begun almost immediately after birth was not known. The child was healthy and otherwise normally formed. The umbilical ring was completely closed. There was, however, an escape, drop by drop, of a clear, acid-reacting fluid from the umbilicus. After a 4 per cent. solution of indigo-carmin was introduced into the gluteus muscle, the urine from the urethra and the fluid from the umbilicus both took on a deep blue color. There was a phimosis, but the stream from the urethra was fairly well developed.

**Operation.**—Professor Lexer, with the patient in the Trendelenburg position, made an incision around the umbilicus and continued it to within a fingerbreadth

\* Draudt, M.: Beitrag zur Kenntnis der Urachus-anomalien. Deutsche Zeitschr. f. Chir., 1907, lxxxvii, 487.

of the symphysis (Fig. 217). The incision was deepened and the parts dissected free. On the posterior surface of the cord, passing from the umbilicus to the bladder, the peritoneum was very thin. The opening in the bladder-wall was closed with a continuous mattress suture, which was reinforced, and the abdomen was closed.

The specimen was 7 cm. long, with a canal about 2 mm. in diameter extending throughout its entire length. About 1.5 cm. from the outer skin, at the umbilicus, the lumen became wider. It was funnel-shaped and passed gradually into the skin. The portion toward the bladder was similarly arranged. The funnel-like dilatation imperceptibly passed over into the bladder mucosa. There was no evidence of a fold or of a valve.

Microscopic examination gave findings similar to those obtained by Luschka, Suchanek, and Wutz. The inner surface of the tube was everywhere lined with several layers of epithelium, usually three layers in thickness.

**A Patent Urachus Associated with a Partially Obliterated Urethra.\***—In the case of K. B., a male infant one day old, no evidence of a urethra was found externally and the bladder did not seem to be very full. Under these circumstances a urethral orifice was sought for in the perineum. The entire bulbus was laid free and carefully examined, but no urethra was discovered. The opening made in the perineum was not closed. The dressings a few hours later were found to be moist. Injections of indigo-carmin into the gluteus muscles did not, however, give a very clear blue color. The

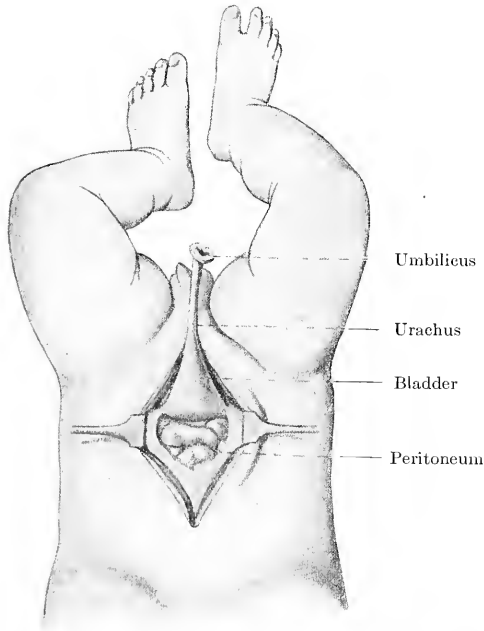


FIG. 217.—A URACHUS OPEN FROM BLADDER TO UMBILICUS. (After Draudt.)

The child is in the Trendelenburg posture. The umbilicus has been encircled by the incision, and the cord dissected free to the bladder. It was cut off at the top of the bladder, and the bladder closed. The patient made a good recovery.

moisture on the clothes continued, but no opening corresponding to the urethra could be seen. After gradually becoming weaker, the child died when fourteen days old. At autopsy it was found possible to remove the urachus, bladder, and urethra intact. (Fig. 218 gives a typical picture of the condition.) The bladder itself was spindle-shaped, approximately 4 cm. in length. At its broadest point it measured 2 cm. in diameter. The walls were very thick, especially near the fundus. The mucosa was folded. The ureters opened at the normal points. Projecting from the fundus was a canal 1.8 cm. long and about 5.5 mm. in diameter. This passed gradually into the funnel-like opening at the top of the bladder, and there was no evidence of a fold-like formation at the junction of the bladder with the canal. The tube was lined with epithelium, extended to the umbilicus and was open

\* Draudt, M.: *Loc. cit.*

there. The opening, being not over 0.1 mm. in diameter, macroscopically was hardly visible, but in serial sections the condition became apparent. The inner surface was lined with a very definite epithelium, four or five layers in thickness. The superficial epithelium was also cylindric in character.

On examination of the urethra it was found that the bulbous portion followed an eccentric course and lay to the left. In the course of the urethrotomy it had been cut a little,—sufficiently to allow urine to escape,—but not enough to be recognized macroscopically. The urethra was eccentric and ended as a connective-tissue thread about 2 cm. beneath the point of the glans. This case belongs to the rather rare group of defects of the urethra in its glandular portion. Kaufmann, in 1886, could find only 11 cases of this anomaly.

**Vesico-umbilical Fistula.\***—This case was also recorded by Dupuytren and Roux and also forms Guéniot's Observation 5.

Madam L. brought a male child twenty-three and one-half months old to the hospital on May 14, 1810. The child looked well. From birth he had presented a remarkable and extraordinary phenomenon. Part of the urine had passed from the urethra and part from the umbilicus. The umbilicus was radiating in form, and in the center could be seen the umbilical extremity of the urachus. At the umbilicus at birth was an oblong tumor. The cord was situated in the middle of the extremity of this tumor, which was red and bloody. After the cord had dropped off the boy had commenced to emit jets of urine from the umbilicus. The extremity of the tumor was always red, and covering it was a small quantity of pus. In the course of fifteen days the tumor assumed a more favorable aspect. It commenced to cicatrize, and after six weeks healing was complete, but the fistula persisted.

**A Patent Urachus in a Child Four Years Old. †**—In this child, four years of age, there was a leakage of urine from the umbilicus. At times the stream was from four to twelve inches high.

The boy was well nourished, had normal genital organs, and voided some of his urine from the urethra.

At the umbilicus was a large, mushroom-like eversion fully half an inch high, with a crater-like center. The entire structure was covered with epithelium, and showed no erosions. In the center there was a small cicatricial area surrounding the opening, which admitted an ordinary probe. The boy was kept under observation and was found to have a fairly good stream from the urethra.

**Operation.**—A probe could be passed from side to side like a pendulum, showing

\* Marx: *Enfant de vingt-trois mois et demi, qui rendait l'urine en partie par la verge et en partie par l'ouverture ombilicale de l'ouraque.* Répertoire général d'anatomie et de physiologie pathologique, 1827, iv, 120.

† Erdmann, John F.: *Pediatrics*, 1908, xx, 356.

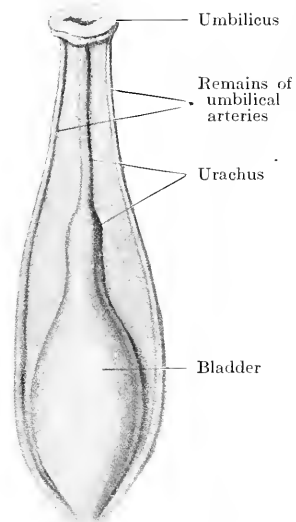


FIG. 218.—AN OPEN URACHUS. (After Draudt.)

The bladder is spindle-shaped. The upper portion is narrow and gradually passes over into the open urachus, which can be followed up to the umbilicus.

a rather wide urachus with a diameter of fully half an inch. A free incision was made from an inch above the pubes to the umbilicus. In dissecting the urachus free the operator made several small openings in the peritoneum. The bladder was fusiform in shape, and the urachus, which was three-quarters of an inch wide and about three inches long, was apparently continuous with the bladder itself. The umbilicus was excised, and about an inch of the urachus with the umbilicus cut off. Direct apposition sutures were then applied, followed by a circular row below, with inversion of the sutured portion, as in the case of an appendix stump. A third row of catgut sutures was placed over the inverted end, and the abdominal wound closed. A catheter was placed in the bladder and kept in three days. The boy made a good recovery, and was discharged on the seventeenth day.

**A Patent Urachus.**—Florentin\* quotes Cabrol's case. In the year 1550, in the village of Beaucaire, there was an exhibition by the village guard before the house of Mlle. de Varie. Several of the young ladies were accidentally injured. When treating these patients, Cabrol noticed a most offensive odor of urine, and tried to find out the cause. The next day he examined a girl and found at the umbilicus an elongation the length of four fingerbreadths, resembling the crest of a turkey-cock, whose urine is passed through the cloaca. The surgeon was at once impressed with the danger of closing this opening without allowing the urine to pass by the ordinary channel. The girl was eighteen years of age. He found the vesical orifice closed by a membrane. He opened this and passed a lead cannula into the bladder. The next day he closed the opening at the umbilicus. It had entirely healed by the twelfth day.

**A Patent Urachus.**—Florentin† reports a case of urinary fungus in a girl of four years, from the clinic of Professor Froelich. She was admitted to the surgical department for fistula at the umbilicus. At birth nothing abnormal was noted. The cord came away on the ninth day. At that time the mother noticed at the base of the umbilical cicatrix a tumor the size of a small pea. This discharged continuously a whitish liquid with the odor of urine. Since that time the tubercle had gradually increased in volume, the discharge had persisted and produced a marked erythema at the orifice of the umbilicus. This condition had persisted for four years, without any interference with the health of the child. On examination, at the base of the umbilical fold was seen a violet-colored tumor the size of a pea. A probe could be introduced downward and backward. The tumor was irreducible. There was no hernia at the umbilicus. At intervals a drop of clear liquid with a urinous odor escaped.

**Operation.**—The tumor was encircled and dissected down to the peritoneum. All that could be drawn out was cut off and the wound closed. Microscopic examination showed an outer coat of connective tissue, then the cell-fibers of non-stripped muscle, and in the center a duct lined with pavement epithelium. The child made a good recovery.

**A Patent Urachus.**‡—A male child, two or three months old, was brought to Professor Helmuth's College Clinic in 1885. The nurse who accompanied the child said that it passed urine through the umbilicus. On examination an outgrowth, about an inch and a quarter in length, was discovered in this locality. It

\* Cabrol: Quoted by Florentin, P.: *Fongus de l'ombilic chez le nouveau-né et chez l'enfant*. Thèse de Nancy, 1908-09, No. 22.

† Florentin, P.: *Op. cit.*, obs. 9.

‡ Freer: *Annals of Surg.*, 1887, v, 107.



was hollow and was connected by a completely pervious urachus with the bladder. This point was proved by the continuous discharge of urine through it. The urine excoriated the parts and rendered the child exceedingly uncomfortable. The method of treatment suggested for the deformity was ligation of the excrescence, but, owing to the absence of the child's parents, this was deferred.

**A Patent Urachus.**—Freer\* says that in cases of vesico-umbilical fistula several methods of treatment have been devised. He cites the case of a child of five months. The urachus was completely pervious and admitted a medium-sized catheter. At its umbilical extremity was an outgrowth that resembled a strawberry. This was encircled with a subcutaneous ligature and removed; the edges were pared and sutured, and complete closure followed.

**A Case of Fleishy Tumor of the Umbilicus with Patent Urachus.**—French's† patient was a female six weeks old. There was at the umbilicus a hernia-like protrusion of the skin about three-quarters of an inch in length, surmounted by a red fleshy outgrowth, like a swollen and fungoid glans penis. Whenever the child cried or struggled, this growth became very prominent and vascular, and through a small opening urine was expelled.

**Operation.**—After it had been determined that no knuckle of intestine was in the way, a harelip pin was driven through the fleshy mass at its junction with the cuticle and transversely to the body axis. Beneath this and at right angles to it a needle armed with a stout double ligature was passed, and the threads were drawn through. These were tied tightly on each side under the pin. The fleshy mass came away with the pad on the third day. On the tenth day the wound had completely healed and was covered with skin. An umbilical truss was ordered as a simple precaution.

**Escape of Urine from the Umbilicus.**‡—The patient was a boy of twelve who, for three years, had had an oval tumor directly above the symphysis. It was about the size of a hen's egg. The overlying skin was tender and apparently inflamed, but showing no great amount of reaction. To the left of the tumor was an oblique cleft about 9 mm. long. It was through this opening that the child urinated, but drop by drop, as from a still. Below the tumor was a transverse opening, from which air escaped with some noise, and there was sometimes a foul odor. Immediately beneath this was another tumor, which may have been a penile gland. The penis was not perforated. Goupil asks how the urine could come from the umbilicus, but quotes Graf, Diemerbroeck, du Laurent, Fernel, and others as having seen it escaping. He wonders whether the foul odor could have been from the bowel, but says that no feces were passed through the umbilicus.

**A Patent Urachus.** §—This case was recorded in the *Deutsche Klinik*, 1864, xvi, 116. A man twenty-eight years of age had a urachal fistula at birth. This was healed after the employment of escharotics. Twenty-five years later a tumor developed between the umbilicus and the symphysis. This broke and discharged pus, then urine. Autopsy revealed a carcinoma of the mucosa of the urachus, which had perforated into the umbilicus and the bladder.

**Possibly a Patent Urachus.** ||—This case was reported in Vaughan's article. No reference is given as to the original source.

\* Freer: *Loc. cit.*

† French, John G.: *The Lancet*, London, 1882, i, 60.

‡ Goupil: *Sur un vice de conformation singulière.* *Jour. de méd. de Paris*, 1756, v, 108.

§ Graf, Fritz: *Urachusfisteln und ihre Behandlung.* *Inaug. Diss.*, Berlin, 1896.

|| Griffith, F.: See Vaughan, G. T.: *Trans. Amer. Surg. Assoc.*, 1905, xxiii, 273.

The patient was a male infant five months old, from whose navel there had been a discharge of clear fluid ever since the detachment of the cord. This fluid was colorless, limpid, and did not have a urinous odor. The parts were kept clean, dressed frequently, and adhesive plaster was used to approximate the edges. After three months recovery took place.

**A Patent Urachus.\***—The child was presented before the Society of Surgery first at the meeting on June 5, 1872; and during the second meeting on July 10th, several days after complete healing had taken place. Guéniot says that it is incontestable that the continuity of the vesical cavity with the persistent canal of the urachus has been confirmed in a certain number of cases in the bodies of adults.

He says that Albinus, Beudt, and Haller have reported examples of this character.

On June 1, 1872, Alfred R., ten and a half months old, was admitted to Guéniot's service. He was in good general health, but had a tumor at the umbilicus. This was dull red, had a mucous surface, was moist, and resembled a cherry in form, color, and volume. It was 2.2 cm. in diameter, and was attached at the umbilicus by a pedicle 6 to 8 mm. long and 16 mm. broad. It was rather soft and covered with delicate skin. On pressure it was irreducible. The umbilical ring was enlarged, slightly indurated, and hypertrophied, and formed a circular elevation which increased in size with any movement of the child. There was weakness at the umbilical ring. The tumor looked like a mushroom with a short pedicle. Finally—and this is the most important point—there was an expulsion of a transparent liquid from the orifice in the tumor, and the patient also urinated in the natural way. There was, in other words, a urinary fistula, with hernia and hypertrophy of the mucosa at the umbilicus. The genital organs were well developed. The testicles appeared to have been arrested at the rings.

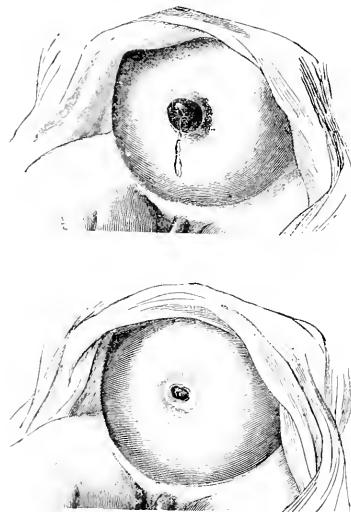


FIG. 219.—ESCAPE OF URINE FROM THE UMBILICUS DUE TO A PATENT URACHUS. (After Guéniot.)

The upper picture represents the urine escaping from the umbilicus prior to operation. Surrounding the opening is a dark area where there had been a rolling out of the mucosa. The lower picture shows the umbilicus after operation. Cicatrization is perfect. There is no escape of urine.

On June 10th, after several ineffectual attempts at compression and the employment of iron perchlorid and zinc chlorid, Guéniot ligated the umbilical tumor. This caused pain, and at the same time he noticed redness of the tumor. The passage of urine was not stopped. On the twelfth a second ligature was applied at the same point. On the fifteenth he noticed that the tumor had ulcerated circularly, and where the ligature had been applied there was a deep furrow. The surface of the ulcer was cauterized with silver nitrate and a new ligature applied. On the nineteenth the discharge of urine from the umbilicus still persisted; the ulceration at the base of the tumor had increased, and the furrow had become deeper. The fourth ligature was applied and tied more tightly than the one preceding. This time the

\* Guéniot, R.: Des fistules urinaires de l'ombilic dues à la persistance de l'ouraue, et du traitement qui leur est applicable. Bull. de thérapeutique, 1872, lxxiii, 299; 348.

tumor was markedly congested, and on the twentieth for the first time the urine ceased to pass from the umbilicus. The tumor was black and gangrenous. On the twenty-second there was a marked diminution in the secretion from the umbilicus and no escape of urine. The tumor was dead. On the twenty-fourth the ligature came away, and by the twenty-eighth the umbilicus had assumed a more normal conformation. The pedicle of the tumor had diminished markedly in its dimensions, and nothing but a small tubercle about the size of a pea remained. There was no farther escape of urine, and the child was discharged well.

**A Partially Patent Urachus.** \* — This case is quoted by Simon (Obs. 4). (I have been unable to locate the original article.) He says that during the year 1648 Haran received at the Hotel-Dieu a new-born child who had at the umbilicus a tumor the size of a pigeon's egg. This contained clear fluid and was adherent to the extremity of the cord below the ligature. It was opened in the presence of several people, and there escaped a serous fluid which proved to be urine. Urine then escaped in abundance. All present thought that it came from the bladder.

**A Patent Urachus.** † — Case 1.—The patient was a male child who, when five weeks old, began to discharge urine from the umbilicus. There was inflammation resulting from extravasation of urine around the umbilicus. The extravasation spread all over the abdomen and the child died in a few days.

**A Partially Patent Urachus.** ‡ — Case 3.—The patient was a girl four years of age who had a chronic discharge from the umbilicus and pain between the umbilicus and symphysis. A probe was passed nearly to the vertex of the bladder. The urachus was ligated and cut and then treated in exactly the same manner as the vermiform appendix. No opening was detected at the bladder. The peritoneum was accidentally opened during the operation. The child recovered.

**A Patent Urachus.** § — The patient was a vigorous boy, fifteen years of age. Since infancy he had sometimes lost urine at night through the umbilicus. During the day the bladder had held it better.

In a discussion following the presentation of Hue's case, one physician asked if the tract could not have been injected with some substance impermeable to the x-ray and then a radiograph made. Another suggested the introduction of milk or some coloring-matter to see if it would pass into the bladder.

**A Patent Urachus.** — On April 20, 1911, I received from Dr. R. H. Huggins, of Pittsburgh, the following abstract from one of his histories:

"The patient was the third child of a healthy mother. It weighed seven and a half pounds. It was well developed and apparently normal in every way. About ten days after delivery the nurse called attention to the escape of fluid from the umbilicus. Examination revealed an opening in the lower border of the umbilical ring. This was surrounded by a small inflamed area by which urine escaped at times, not, however, in large quantities, but sufficient to saturate the bandage and neighboring clothing. A small probe was passed to a point about 4 cm. from the bladder. Repeated cauterizations for about four weeks effected a closure of the fistula and there was no further trouble."

\* Haran: *La pratique des accouchements*, i, 38.

† Hind, W.: *Diseases of the Urachus and Umbilicus*. *Brit. Med. Jour.*, London, 1902, ii, 242.

‡ Hind, W.: *Loc. cit.*

§ Hue, François: *Persistence du canal de l'ouraquet; fistule ombilicale*. *La Normandie médicale*, 1905, xx, 311.

A P a t e n t U r a c h u s . \* — This case was reported in Vaughan's article. I have not been able to obtain the original.

A girl, aged six years, had passed urine from the umbilicus from the twelfth day, that is, from the time that the cord dropped off.

The urachus was excised, and the lower end ligated with catgut. The wound was closed, leaving the end of the catgut ligature projecting. The patient had scarlet fever, and the wound opened superficially, but it was reunited and healed without further trouble.

A P a t e n t U r a c h u s . — Jacoby's† patient was a strong, normally developed boy, but he had an unusually thick cord. Jacoby tied the cord himself. The umbilical ring was the size of a silver gulden. After the cord came away the wound was the same size. It rapidly became smaller, so that in three weeks it formed nothing but a funnel-shaped opening, but a few weeks after this the nurse casually mentioned that the umbilicus was often wet or filled with water. On investigation it was found that there was a fine fistulous opening through which fluid escaped when the bladder was full. The water came drop by drop and filled the umbilicus. The opening was so small that a sound could not be made to enter it.

Jacoby tried compression, which answered very well until the pressure was removed. Later he tried the actual cautery, and as soon as the slough had come away he drew the surfaces together. This procedure proved successful after the second treatment. The umbilicus became ditch-like instead of funnel-shaped, and no trace of the fistula remained.

A P a t e n t U r a c h u s . — Jahn‡ reports a case coming under Mikulicz's care. A boy five years of age was seen in February, 1895. There was no hereditary taint. Soon after his birth the parents noticed that he passed little urine in the natural way, but that an abundance escaped by the umbilicus.

On examination the boy was found to be well developed. The umbilicus was the size of a mark piece, flat and prominent, and gathered into radial folds. In the middle was a funnel-shaped depression from which, when abdominal pressure was made, urine escaped. A sound 6 mm. in diameter passed without difficulty 14 to 16 cm. downward toward the symphysis, and could be moved freely in all directions, there being no indication of a septum. When the umbilical opening was closed, the boy could urinate well by the urethra, but in a small stream. A catheter could be readily carried into the bladder, and a sound introduced from above came into direct contact with it.

A cystoscope introduced from above passed into the bladder, and a careful examination of the viscus was thus rendered possible. A diagnosis of congenital umbilical fistula, due to an open urachus, was made.

Mikulicz, on February 5, 1895, cut around the umbilicus and dissected the canal free for 3 cm. Here it passed over into the apex of the bladder. During the dissection the peritoneum was opened at one point. This opening was closed. The urachus with its opening into the bladder was cut away, and the wound in the bladder closed. The abdominal walls were brought together, a small gauze drain being passed down to the bladder sutures.

\* Imbert, L.: See Vaughan, G. T.: *Trans. Amer. Surg. Assoc.*, 1905, xxiii, 273.

† Jacoby, M.: *Zur Casuistik der Nabel fisteln.* Berlin. klin. Wochenschr., 1877, xiv, 202.

‡ Jahn, A.: *Ueber Urachus fisteln.* Beiträge z. klin. Chir., Tübingen, 1900, xxvi, 323.

The boy was able to urinate on the next day. The result was excellent, and three and a half years later the boy was still well.

Jahn gives a very good review of the literature.

**A Patent Urachus.\***—The patient was a child seven months old (sex not given). It had been passing urine from the umbilicus since birth. At the umbilicus was a sort of flattened, button-shaped tumor, the size of a cherry. It was red, and evidently due to everted mucosa at the umbilicus. A probe passed into the urachus three inches. The greater part of the urine was passed by the urethra.

**A Patent Urachus.**—Lannelongue's† patient was a child three months old. The mother said that it had two penises, and that it urinated from both at the same time (Fig. 220). One penis was normal; the other organ was situated at the umbilicus, and looked exactly like a normal penis. The child died later. There was an umbilical hernia and a patent urachus which had been tied off with the cord; hence there had resulted a fistula when the cord came away.

**A Patent Urachus.‡**—In the case of Meyer-Kempen the urine escaped in a stream from the umbilicus when the child cried. Ledderhose says that excoriations of the skin in the neighborhood of the fistula may or may not be present. As long as the urine is acid, the irritation of the skin is only small in amount. In some cases ecchymosis has been noted. The prognosis is good.

**A Fistula of the Urachus.§**—The patient was a female child. On the seventh day the cord, which was still partially attached, was cut with scissors. In a few days the clothes at the umbilicus were wet. The discharge of fluid continued. Litmus paper showed that the umbilical fluid had an acid reaction. When the child was examined, a small, soft tumor, reddish violet in color, and with a small hole in its center, was noted at the umbilicus. A probe was easily passed 3 cm. downward toward the bladder. The child was taken to the country five weeks after birth. Little by little the fluid diminished and then disappeared. Five months later the child was perfectly well.

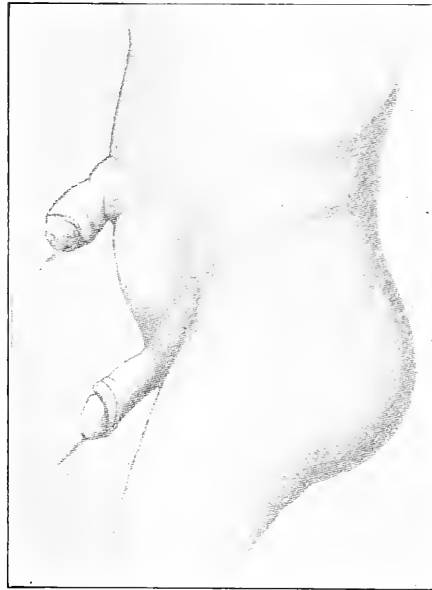

FIG. 220.—A PATENT URACHUS WITH A PENILE PROJECTION AT THE UMBILICUS. (After Lannelongue.)

The penile projection at the umbilicus conformed in shape and size to the penis of a child. The urine escaped from the urethra and also from the umbilicus.

\* Kennedy, A.: Brit. Med. Jour., London, 1899, i, 1396.

† Lannelongue: Un cas de faux pénis ombilical. Leçons de clinique chirurgicale, Paris, 1905, 388.

‡ Ledderhose, G.: Chirurgische Erkrankungen des Nabels. Deutsche Chirurgie, 1890, Lief. 45 b, 109.

§ Lugeol: Fistule urinaire ombilicale par persistance de l'ouraue. Jour. de méd. de Bordeaux, 1879-80, ix, 3.

**Congenital Vesico-umbilical Fistula.** \* — The child, a year old, had an opening at the umbilicus through which, when it cried, the urine escaped in a stream. The opening had the form of a urethral orifice. The umbilicus was thickened and, although no hernia existed, it was prominent and in its contour resembled a glans penis. When the child was quiet, the urine passed by the urethra, but, when abdominal pressure was made or the child cried, it came in a stream from the umbilical opening. The urachus had evidently remained patent. Operation was refused by the parents.

**A Patent Urachus.** † — Monod, on pp. 122 and 123 of his splendid treatise, gives somewhat full tabulations of the cases heretofore recorded.

On p. 124 he reports a case of congenital urinary fistula at the umbilicus due to persistence of the urachus: G. G., aged ten, admitted to the hospital in June, 1899. When the cord came away there was a plaque the size of a franc at the umbilicus. The urine escaped from it and also from the urethra. The flow was intermittent. He had never had any tumor at the umbilicus. The orifice was small, but admitted without pain a No. 13 bougie. Around the opening the skin was like scar tissue and showed transverse, raised folds radiating from the periphery to the center. The surrounding skin was smooth. The sound could be introduced through the fistula into the bladder. At times the urine passed from the umbilicus, at other times from the urethra. Sometimes all of it was passed from the umbilicus and a few drops only from the meatus. At other times the reverse occurred, and occasionally all the urine passed by the urethra and none by the fistula. The child had a phimosis, but there was no obstruction in the urethra.

The entire urachal tract was removed. Histologic examination showed that the cavity was lined with a stratified squamous epithelium similar to that of the skin.

**A Patent Urachus that Closed and Reopened Later in Life as a Result of Hypertrophy of the Prostate.** — Monod‡ describes a case seen by Jaboulay and reported in 1897. The patient was a man, sixty-two years of age, who had been in good health up to that time. He had painful micturition and symptoms of hypertrophy of the prostate, the diagnosis being confirmed on examination. One day after painful micturition he noticed that drops of urine with a fetid odor were escaping from the umbilicus. The quantity of urine that escaped the first time was probably 150 to 200 c.c. He entered the hospital for the fistula, and said that he had never had any accident, but that his mother had often told him that shortly after birth he was treated for escape of urine at the umbilicus, and that the discharge had disappeared in the course of fifteen days after the application of an appropriate bandage.

The urachus was dissected out for 3 or 4 cm. and tied off. Later, however, it reopened.

**Operation for Pervious Urachus.** § — The patient was a female child four months old. The urine escaped from the umbilicus, keeping the bed-clothes soaked. When the umbilical folds were drawn apart, an opening which

\* Meyer: *Offenbleiben des Urachus nach der Geburt.* Casper's Wochenschr. f. d. gesammte Heilkunde, 1844, 424.

† Monod, Jean: *Des fistules urinaires ombilicales dues à la persistance de l'ouraue.* Thèse de Paris, 1899, 62.

‡ Monod, Jean: *Op. cit.*, 184.

§ Paget and Bowman: *On an Operation for Pervious Urachus.* Medico-Chir. Trans., London, 1861, xlv, 13.

would admit a lead-pencil was found and the skin was inverted. When the skin was drawn apart, urine gushed out. The circumference of the opening was denuded, and the edges coapted with a suture pin and lint, as in a case of harelip. On the third day a small amount of urine escaped by the umbilicus. The result was perfect.

A Case in Which the Urachus Remained Open and the Ring-shaped Calculus that had Formed upon a Hair in the Bladder was Extracted Through the Umbilicus.\* — The patient, John Conquest, an ironfounder, aged forty, had for a year or more suffered from frequent and painful micturition. He also said that, when attempting to pass water or when doing strenuous work, urine would escape from the navel. On being questioned it was found that from the time of his birth some of the urine had come away from the umbilicus—a clear indication of a patent urachus.

He was admitted to the Leicester Infirmary on August 15, 1844. Paget, on sounding him, readily made out a vesical calculus, and further found that the sound could be carried up through the bladder to the umbilical opening. Hoping that it might be possible to remove the vesical stone through the umbilicus, he temporarily plugged the umbilical opening, distended the bladder with warm water, and placed the patient upon a Heurteloup table with his head lower than the pelvis; in other words, he put the patient in what we now call the Trendelenburg posture. The plug was now removed, and a finger introduced into the umbilical opening. The tip of the finger caught in the center of the ring-shaped calculus (Fig. 221), and with care Paget was able to extract the stone through the umbilical opening. This calculus was ring-shaped because it had developed around a curled-up hair.

Paget says that at the umbilicus there was a circular deficiency in the linea alba one inch in diameter. The margins of this ring were thickened and of cartilaginous hardness, and through the opening protruded a hernial mass the size of a goose's egg. This hernia was covered over with mucous membrane which became dry when exposed to the air for any length of time. The patient could not pass water when this hernia was out, and when he tried to void, the projection gradually withdrew into the abdomen, and urine then forcibly escaped from the umbilicus, and in a moderate stream from the urethra.

It was clearly evident that the muscular walls of the bladder made traction on the umbilical hernial projection. Paget says that the bladder and urachus formed a urinary receptacle that in shape might be compared with a curved-necked cupping-glass.

The description of the case strongly suggests a partial exstrophy of the bladder. After the extraction of the calculus the man was relieved of his bladder symptoms. No attempt, however, was made to repair the congenital defect.

Paget again saw the man in April, 1860.† When the patient was fifty-five years old (Paget said) the opening in the linea alba was elliptic in shape, and admitted



FIG. 221. — A RING-SHAPED VESICAL CALCULUS WITH A FINE HAIR IN ITS AXIS. (After Paget and Bowman.)

This calculus had formed on a hair in the bladder and was extracted through the umbilicus. The calculus was as thick as a medium-sized writing quill. The urachus was patent throughout.

\* Paget and Bowman: *Medico-Chir. Trans.*, pub. by the Royal Med. and Chir. Soc., London, 1850, 2. ser., xv, 293.

† *Loc. cit.*, 1861, xlv, 13.

three fingers. In the mean time the man had developed a second vesical calculus. This was disc-shaped and had come away. Paget, after passing a finger through the umbilical opening into the bladder, to exclude the possibility of another calculus, successfully closed the umbilical opening.

**A Vesico-umbilical Fistula.**— Pauchet's\* patient was a boy five years of age. Shortly after the cord came away a large mass of "proud flesh" was noted at the umbilicus, and from it a clear fluid with a urinary odor escaped. The discharge of fluid would occur at intervals of four or five days, persist for one or two days, coming unexpectedly and never in a jet, and accompanied by abdominal pain. The granular area was destroyed with silver nitrate.

When seen, the boy was emaciated. A No. 6 bougie passed the urethra easily. The fistula admitted a bristle, which penetrated 3 or 4 cm. without giving any indication of the direction of the canal. The umbilicus occupied its normal site and was surrounded by an area of induration about 1 cm. in diameter. On palpation of the abdomen some urine escaped from the umbilicus. There existed in reality a retro-peritoneal pocket, at one end communicating with the bladder, at the other with the umbilical fistula. The amount of urine discharged from the navel during the twenty-four hours was about 80 c.c. There was no cystitis. Urination was painless, not too frequent, and the urine was clear.

The existence of a retro-umbilical pocket was not known prior to operation. A median incision was made 3 cm. above the fistula, encircling the umbilicus and extending to within 2 cm. of the pubes. After obtaining good exposure by separating the muscles Pauchet freed the tissues around the umbilicus and the subjacent tissue and made traction. He was easily able to detach a fibrous mass the size of a walnut from the peritoneum without opening the peritoneal cavity. The urachus was then visible as a delicate, transparent cord, resembling an empty vein. It passed to the summit of the bladder. It was tied off with catgut and severed. The stump was turned in with a catgut suture and the abdominal wound closed with interrupted sutures. No drainage was employed. The wound healed in ten days.

The ovoid mass was the size of a walnut. Its surface was adherent to the surrounding skin, and at its center was the fistula. The lower extremity of the mass was continuous with the urachus for a length of 3 cm. On section, the cavity resembled a small and contracted bladder. The walls were fibrous, and the mucosa presented a large number of folds.

**A Patent Urachus.**— In 1887 Penny† reported the case of a healthy child, aged eleven months, who, after separation of the cord on the ninth day, had been passing urine through the navel. A probe passed into the fistula could be felt to touch a catheter passed up the urethra into the bladder.

After the cord came away the umbilicus was represented by a raised rounded mass the size of a hazelnut. Its surface was intensely red and covered with mucosa. A constriction existed at the junction with the abdomen. Surrounding the umbilicus was a dusky red areola, about one inch in width, due to irritation from the fluid. In the center was a sinus through which the urine escaped.

Operation was declined.

\* Pauchet, V.: *Fistule ombilico-vésicale. Résection sous-péritonéale de l'ouraqué et d'une poche urinaire rétro-ombilicale, guérison.* Bull. et Mém. de la Soc. de chir. de Paris, 1902, xxviii, 785.

† Penny, W. J.: *Bristol Medico-Chir. Jour.*, 1888, vi, 36.



**A Congenitally Patent Urachus.** — Petit's\* patient in Case 4 was a young boy who, since his birth, had had an escape of urine from the umbilicus. At the navel was a kind of cushion, in the middle of which was a round opening through which the urine escaped. There was no obstruction in the urethra because the urine passed also by the natural way, and, when the patient did not wear a bandage, it escaped also from the umbilicus.

**Urinary Fistula at the Umbilicus.** — Pierre's† patient was a boy with a congenital urinary fistula at the umbilicus, without any obstruction in the urethra. At the umbilicus was a ring, 2 cm. in diameter, in the center of which was an irregular opening 5 mm. in diameter. Behind this was a discoid cavity from which a small amount of urine escaped. No operation is mentioned.

**A Patent Urachus.** — In 1876 Preston‡ saw an infant so malformed that its sex could not be determined. It had an opening through the umbilicus from which urine came. The child weighed nine pounds. Two years later it was still passing urine from the umbilicus, but was in good health. The mother informed Preston that there was never any urinary odor on the diapers used to receive the feces, indicating that little or no urine escaped from the urethra.

**A Case of Congenital Vesico-umbilical Fistula — Patent Urachus.** § — The patient was a boy eleven years of age. At birth there was a rounded swelling in the umbilical region the size of a duck's egg. It was easily reduced and kept in place by a bandage. Urine escaped from this swelling. Up to his seventh year compresses were used, but these were of little value. On examination the boy was found to be strong. In the center of the umbilicus was an opening which admitted a uterine sound. Urine passed by the urethra and also by the umbilicus. Jacobi saw the child and passed a catheter from the umbilicus into the bladder.

**Operation.**—A raw surface was made above the fistula; a flap was dissected up from below and attached to the raw area. At the end of a week a small amount of urine escaped from the umbilicus, but the opening soon closed after the use of silver nitrate. A year later Jacobi introduced 12 ounces of water into the bladder through the urethra and none escaped from the umbilicus.

**A Series of Cases with Patent Urachus.** — Smit|| reported three cases:

**Case 1:** A woman, aged fifty-eight, complained of retention of urine which dribbled from the navel. A vesicovaginal fistula was established and the urachus closed spontaneously. Later the vesicovaginal fistula closed.

**Case 2:** A girl aged seventeen had constant dribbling of urine from the navel; also of blood at the menstrual period. The edges of the fistula were split and a purse-string suture applied, with a perfect result.

**Case 3:** A boy, one and a half years old, had an offensive discharge of urine from the navel. There was also an eczematous condition at the umbilicus. The boy had marked phimosis. Circumcision failed to cure the fistula. The navel was excised and the urachus successfully closed with a purse-string suture.

\* Petit, J. L.: *Traité des maladies chirurgicales*, Chap. xi, 3. *Oeuvres complètes*. 8°. Limoges, 1837, 799. (Quoted from Simon.)

† Pierre: *Bull. Soc. de méd. de Rouen*, 1888, 2. série, ii, 32.

‡ Preston, W.: *Med. Record*, New York, 1898, liv, 315.

§ Rose, A.: *Med. Record*, 1877, xii, 516.

|| Smit, J. A. R.: *Abstract from Zentralbl. f. Gyn.*, 1904, Nr. 41.

It is not stated in these cases whether the urine had passed from the umbilicus from birth. We are including them all as instances of patent urachus.

**An Open Urachus.**—Smith\* reported the case of a boy, aged two years, who had a papilla-like projection at the umbilicus. In the center of this was an opening from which, at all times, there transuded a fluid looking and smelling like urine. A ligature was firmly applied to this projection, and after a few days it dried up and fell off. The fistula seemed to be permanently closed.

**Fistula of the Urachus.**—Stadfeldt† reports a case of fistula of the urachus and gives a table of cases from the literature. [No translation of the article could be obtained.]

**Escape of Urine from the Umbilicus.**—Starr's‡ patient was a female child thirteen weeks old. Since birth the urine had escaped from the umbilicus. The urethra was normal. The flow from the umbilicus was not continuous, but occurred at intervals, regulated by the detrusive action of the bladder. The general appearance of the umbilicus was larger and more open than usual, and in the center of the cartilaginous, nipple-like projection was an orifice which admitted an ordinary probe. This passed in the direction of the linea alba toward the bladder. Starr diagnosed the condition as one of open urachus, although he pointed out that a leading authority claimed that the urachus was open only in those cases in which the urethra was closed.

**The Radical Cure of a Patent Urachus.** §—The patient was a tall youth, seventeen years of age, who had had urine escaping from the umbilicus since birth. The umbilicus bulged forward; there was a small hernia of subperitoneal fat and an eczematous condition around the umbilicus. The patient had always had some pain when voiding.

**Operation.**—The bladder was emptied and four ounces of boric solution were allowed to run in. A transverse incision was made one inch above the symphysis. The recti muscles were separated, and a good view of the bladder and its peritoneal reflection was obtained. In caliber the urachus was as large as the stem of a clay pipe. The part close to the bladder was clamped, a second clamp was applied high up and a cut made between. A purse-string of celluloid thread was placed around the vesical stump of the urachus, and the latter was invaginated as in dealing with an appendix. The umbilical end of the urachus was brought up out of the abdomen between the recti muscles and anchored to the muscle, and the sheath covered over with fat and skin. Further dissection was not made on account of the eczematous condition of the skin. The patient made a good recovery.

**A Patent Urachus.**—Stierlin|| reports the case of a twelve-year-old girl brought to the hospital on June 28, 1896. At the umbilicus was an opening from which urine flowed. During the daytime only a small amount escaped, but at night so much came away that practically every morning the bed was wet through. The urine escaped only drop by drop from the umbilicus. There was never any pain. This watery discharge from the umbilicus was noted as soon as the umbilical cord

\* Smith, Thomas: *Med. Times*, London, 1863, new series, i, 320.

† Stadfeldt, A.: *Bidrag til Læren om den medfødte Vesiko-umbilikal fistel (Urachus-fisteln) og dens Behandling.* Nordiskt Medicinskt Arkiv, Stockholm, 1871, iii, No. 23, 1.

‡ Starr, T. H.: *Med. Gaz.*, London, 1844, xxxiii, 484.

§ Stevens, B. Crossfield: *The Lancet*, London, 1904, ii, 584.

|| Stierlin, R.: *Zur Casuistik angeborener Nabelfisteln.* Deutsche med. Wochenschr., 1897, xxiii, 188.

came away. The child was well nourished. The umbilicus was flat, broad, and about 3 cm. in diameter. In its lower portion was a depression toward which the skin on all sides passed in radiating folds. The umbilical ring was wide, so that the point of the finger could be passed into it. If the patient coughed, the upper part of the umbilicus became distended. In addition, in the linea alba there was a small prominence the size of a pea. Stierlin diagnosed the case as one of hernia of the linea alba. The depression in the lower part of the umbilicus formed the entrance to a large, roomy, fistulous canal. When pressure was made upon the hypogastrium, several drops of clear fluid with a urinary odor escaped. A No. 9 bougie could be passed into the fistula with ease and entered a cavity. When a metallic sound was introduced through the urethra at the same time, both instruments were found to have entered the bladder.

Operation.—On both sides of the fistula the skin was divided in transverse directions for 1.5 cm. The walls were freshened up, and the urachus closed with continuous catgut. The abdominal walls were then brought together and a catheter was placed in the bladder. There was no hematuria, and the patient made a good recovery.

*Patulous Urachus in a Child of Nine Months.\**—The patient was a negro girl nine months of age. Ever since the separation of the cord she had discharged urine from the umbilicus. At the navel was a protruding mass of granulation tissue, but bulging only about one-sixteenth of an inch from the skin. In its center was an opening. In five or six weeks a cure was effected after cauterization of the orifice several times at various intervals.

*A Patent Urachus That Closed in the Fourth Year and Opened Again at Forty-eight.*—Tuholske's† patient was a man fifty-two years of age, who in infancy had passed urine through the umbilicus. This condition ceased in his fourth year without treatment, and he had no further trouble until he was forty-eight years of age, when, apparently without cause, the urine again commenced to flow through the navel. The margins of the opening were pared and sewed together, but without effecting a cure. Six months later the canal was exposed by incision, and half an inch beyond the margin was found to spread out into the bladder, no division existing between the bladder and urachus. The urachus was split down to what should have been the summit of the bladder and sewed across for a distance of two inches. The operation was extraperitoneal. Recovery followed.

*Congenital Sinus of the Urachus.*—Vander Veer,‡ in 1886, saw in consultation with Dr. DuBois, a female twenty years of age who, since the tenth day after her birth, had discharged urine from the umbilicus at irregular intervals. For the last two years she had had pain, the discharge had become offensive, and the parts about the umbilicus had become excoriated. A probe passed downward toward the symphysis for three inches. The sinus lay just extraperitoneally.

The operation consisted in slitting up the urachus, curetting, suturing the lower part, and packing the upper part with iodoform gauze. Recovery followed.

*A Patent Urachus.*—Velpeau§ reports a case of a boy two years of age,

\* Stites, T. H.: Amer. Medicine, Philadelphia, 1903, vi, 136.

† Tuholske, H.: St. Louis Medical Review, February 11, 1905. (From Vaughan's article.)

‡ Vander Veer, A.: Med. and Surg. Reporter, 1889, lxi, 661.

§ Velpeau: Arch. de méd., 1826, xi, 554. (Quoted from Guéniot, obs. 6.)

who was seen in consultation by Professor Roux for congenital tumor of the umbilicus. The child was in a condition of continuous suffering. The greater part of the urine escaped from the urethra. The umbilical tumor was the size of a walnut and resembled a fungus. It was bright red, and in its center was an orifice from which the urine continued to pass. It escaped when the child cried or moved. A small sound was left in the urethra, and in the course of three weeks, when this had done no good, an elastic bandage was put on to compress the tumor. It, however, produced an ulcer without diminishing the discharge.

**P a t e n t U r a c h u s i n a C h i l d F i v e M o n t h s O l d . O p e r a t i o n . R e c o v e r y .** — Waller,\* in 1884, had a male patient, five months old, who had passed urine through the umbilicus ever since the cord had separated. The aunt said that the child had a tumor growing from the navel and that this had gradually become larger since birth. Caustics had been applied several times without result. At the umbilicus was a tumor about 1 inch in diameter. This apparently consisted of a flabby granulation tissue. It was red, inflamed, and very sensitive. From a slight depression at its summit drops of urine were constantly oozing. The drops came fast when the child micturated. The skin around the tumor was excoriated. The child was otherwise well.

Under anesthesia, a catheter could be passed from the umbilicus to the bladder. The urachus formed a cord the thickness of the little finger, and during the dissection the peritoneum was opened. The upper part for one inch was removed; the lower part was ligated with silk. The parts united and recovery followed.

**O p e r a t i o n f o r O p e n U r a c h u s .** — De Forest Willard,† in 1888, reported the case of a female child, two years of age, who had passed urine through the urachus ever since birth, about half a dram escaping during the course of the day. There was a spot two inches in diameter about the umbilicus where the epithelium was excoriated, and from which there was an offensive discharge. The urethra was free. The labia minora were adherent in front of the orifice.

Several vain attempts were made to close the opening by cauterization with silver nitrate. An operation was undertaken, and the edges of the navel were freshened up. Union resulted, but in a month the wound broke down and the discharge returned. The parts were then opened, curetted, cauterized, and a drainage-tube was put in. A cure resulted.

**A P a t e n t U r a c h u s — U r a c h u s C y s t s . ‡** — A woman, twenty-eight years of age, from her birth up to three years of age had discharged urine from the umbilicus. The opening was closed by the use of escharotics, but in her twenty-seventh year cancer developed at the open umbilicus. This perforated into the abdominal cavity, and the patient died of acute peritonitis.

**A P e r v i o u s U r a c h u s . §** — The patient was a male, three weeks old. When the cord came away a protuberance half an inch long, with blood oozing from the surface, was noted at the umbilicus. From this urine had passed ever since the cord had come away. In the center was a slight depression that freely admitted a small probe, which could be passed into the bladder.

\* Waller, C. B.: *Med. Bull.*, Philadelphia, 1885, vii, 371.

† Willard, De Forest: *Med. News*, Philadelphia, 1888, liii, 710.

‡ Wolff, Carl Christian: *Beitrag zur Lehre von den Urachuseysten*. Inaug. Diss., Marburg, 1873, Case 3.

§ Yates, W. S.: *Phila. Med. Journal*, 1902, x, 173.

The umbilical opening was closed with a purse-string suture passed around the protruding portion subcutaneously; the protruding part was then cut off. The wound healed and there was no further trouble.

#### LITERATURE CONSULTED ON CONGENITAL PATENT URACHUS.

- Alric: Sur deux cas de persistance de l'ouraqué. *Bull. de thérapeutique*, 1879, xxvii, 34.
- Annandale, T.: Case of Unclosed Urachus with Umbilical Fistula. *Edinb. Med. Jour.*, 1870, xv, 680.
- Ashurst: Urachal Fistula. *Med. News*, Philadelphia, 1882, xli, 122.
- Bérard, P. H.: Fistules urinaires. *Dict. de méd.*, Paris, 1846, xxii, 64.
- Binnie, J. F.: Development of the Urachus. *Jour. Amer. Med. Assoc.*, 1906, xlvi, 169.
- Cabell, R. G.: *Amer. Jour. Med. Sci.*, Philadelphia, 1849, n. s., xv, 313.
- Charles, J. J.: Treatment of Patent Urachus. *Brit. Med. Jour.*, 1875, ii, 486.
- Delagénère, H.: Traitement de l'ouraqué dilaté et fistuleux par la résection et la suture. Une observation. *Arch. provinciales de chir.*, 1892, i, 222.
- Draudt, M.: Beitrag zur Kenntnis der Urachusomalien. *Deutsche Zeitschr. f. Chir.*, 1907, lxxvii, 487.
- Dupuytren and Roux: Un ouraqué ouvert. (Cited by Guéniot.)
- Erdmann, J. F.: A Patent Urachus in a Child Four Years Old. *Pediatrics*, 1908, xx, 356.
- Florentin, P.: Fongus de l'ombilic chez le nouveau-né et chez l'enfant. Thèse de Nancy, 1908-09, No. 22.
- Freer, J. A.: *Annals of Surgery*, 1887, v, 107.
- French, J. G.: A Case of Fleshy Tumor of the Umbilicus with Patent Urachus. *The Lancet*, 1882, i, 60.
- Goupil: Sur un vice de conformation singulière. *Jour. de méd. de Paris*, 1756, v, 108.
- Graf, Fritz: Urachusfisteln und ihre Behandlung. *Inaug. Diss.*, Berlin, 1896.
- Griffith, F.: Possibly a Patent Urachus. (Vaughan's article.)
- Guéniot, R.: Des fistules urinaires de l'ombilic dues à la persistance de l'ouraqué, et du traitement qui leur est applicable. *Bull. de thérapeutique*, 1872, lxxiii, 299; 348.
- Haran: La pratique des accouchements, i, 38. (Quoted by Simon.)
- Heflin, H. T.: Personal communication.
- Hind, W.: Diseases of the Urachus and Umbilicus. *Brit. Med. Jour.*, London, 1902, ii, 242.
- Hue, F.: Persistance du canal de l'ouraqué; fistule ombilicale. *La Normandie médicale*, 1905, xx, 311.
- Huggins, R. B.: Personal communication.
- Imbert, L.: See Vaughan's article.
- Jacoby, M.: Zur Casuistik der Nabelfisteln. *Berlin. klin. Wochenschr.*, 1877, xiv, 202.
- Jahn, A.: Beiträge z. klin. Chir., Tübingen, 1900, xxvi, 323.
- Kennedy, A.: A Patent Urachus. *Brit. Med. Jour.*, London, 1899, i, 1396.
- Launelongue: Un cas de faux pénis ombilical. *Leçons de clinique chirurgicale*, Paris, 1905, 388.
- Ledderhose, G.: Chirurgische Erkrankungen des Nabels. *Deutsche Chirurgie*, 1890, Lief. 45 b.
- Lexer, E.: Ueber die Behandlung der Urachusfistel. *Arch. f. klin. Chir.*, 1898, lvii, 73.
- Lugeol: Fistule urinaire ombilicale par persistance de l'ouraqué. *Jour. de méd. de Bordeaux*, 1879-80, ix, 3.
- Marx: Enfant de vingt-trois mois et demi, qui rendait l'urine en partie par la verge et en partie par l'ouverture ombilicale de l'ouraqué. *Répertoire général d'anatomie et de physiologie pathologique*, 1827, iv, 120.
- Meyer: Offenbleiben des Urachus nach der Geburt. *Casper's Wochenschr. f. d. gesammte Heilkunde*, 1844, 424.
- Monod: Des fistules urinaires ombilicales dues à la persistance de l'ouraqué. Thèse de Paris, 1899, No. 62.
- Paget and Bowman: *Medico-Chir. Trans.*, pub. by the Royal Med. and Chir. Soc., London, 1850, 2. ser., xv, 293.

- Paget and Bowman: On an Operation for Pervious Urachus. *Medico-Chirurgical Trans.*, London, 1861, xliv, 13.
- Pauchet, V.: Fistule ombilico-vésicale. Résection sous-péritonéale de l'ouraque et d'une poche urineuse rétro-ombilicale, guérison. *Bull. et Mém. de la Soc. de chir. de Paris*, 1902, xxviii, 785.
- Penny, W. J.: *Bristol Medico-Chirurgical Jour.*, 1888, vi, 36.
- Petit, J. L.: *Traité des maladies chirurg.*, chap. xi. *Oeuvres complètes*, Limoges, 1837, 799.
- Pierre: *Bull. Soc. de méd. de Rouen*, 1888, 2<sup>e</sup> série, ii, 32.
- Preston, W.: *Med. Record*, New York, 1898, liv, 315.
- Rose, A.: A Case of Congenital Vesico-umbilical Fistula, Patent Urachus. *Med. Rec.*, 1877, xii, 516.
- Simon, C.: Quels sont les phénomènes et le traitement des fistules urinaires ombilicales? Thèse de Paris, 1843, No. 80.
- Smit, J. A. R.: Abstract from *Zentralbl. f. Gyn.*, 1904, Nr. 41.
- Smith, T.: An Open Urachus. *Med. Times*, London, 1863, new series, i, 320.
- Stadfeldt, A.: Bidrag til Læren om den medfødte Vesiko-umbilikal fistel (Urachus-fisteln) og dens Behandling. *Nordiskt Mediciniskt Arkiv*, Stockholm, 1871, iii, No. 23.
- Starr, T. H.: Escape of Urine at the Umbilicus. *Med. Gaz.*, 1844, xxxiii, 484.
- Stevens, B. C.: The Radical Cure of a Patent Urachus. *The Lancet*, London, 1904, ii, 584.
- Stierlin, R.: Zur Casuistik angeborener Nabelfisteln. *Deutsche med. Wochenschr.*, 1897, xxiii, 188.
- Stites, T. H.: Patulous Urachus in a Child of Nine Months. *Amer. Medicine*, Philadelphia, 1903, vi, 136.
- Tuholske, H.: A Patent Urachus That Closed in the Fourth Year and Began Again at Forty-eight. *St. Louis Med. Review*, February 11, 1905. (From Vaughan's article.)
- Vander Veer, A.: Congenital Sinus of the Urachus. *Med. and Surg. Reporter*, 1889, lxi, 661.
- Vaughan, G. T.: *Trans. Amer. Surg. Assoc.*, 1905, xxiii, 273.
- Velpeau: Cited by Guéniot.
- Waller, C. B.: Patent Urachus in a Child Five Months Old. Operation. Recovery. *Med. Bull.*, Philadelphia, 1885, vii, 371.
- Willard, De Forest: *Med. News*, Philadelphia, 1888, liii, 710.
- Wolff, C. C.: Beitrag zur Lehre von den Urachuscysten. *Inaug. Diss.*, Marburg, 1873.
- Yates, W. S.: *Phila. Med. Jour.*, 1902, x, 173.

## CHAPTER XXX.

### REMNANTS OF THE URACHUS.

Historic sketch.

Observations of Luschka.

Observations of Wutz.

Remnants of the urachus noted in various animals.

In the chapter on Embryology (p. 16) we have seen that the urachus develops primarily from the yolk-sac and that it passes from the bladder to the umbilicus. We have also learned that, although in the majority of embryos it finally forms a fibrous cord, it nevertheless shows an inherent tendency to remain patent at certain points and that the patent areas are recognized as spindle-like dilatations occurring here and there in the otherwise imperious cord.

Méry, in 1700, described two twin female fetuses. There was only one placenta, but each fetus had its cord. In each the umbilicus formed a kind of cushion elevated from one-quarter to one-third of an inch from the surface of the abdomen. In the center of each umbilicus was a hole. The colon ended at the edge of the umbilicus and formed an anus for the fetus. The fundus of the bladder was also open, forming a trough which terminated at the umbilicus.

On page 45 of his book on "Einige Krankheiten der Nieren und Harnblase," published in Berlin in 1800, Walter briefly describes the case shown in Fig. 222. He said very little is known about remnants of the urachus.

He further said that Noreen, a

Swede, in a Göttingen dissertation (1749), mentioned the subject under the title "*De mutatione luminum in vasis hominis nascentis, in specie de uracho.*" Noreen was probably the first person to write somewhat fully concerning dilatation of the

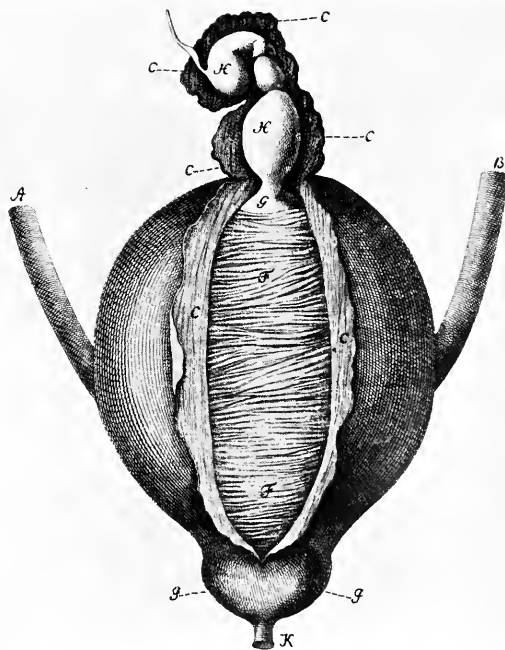


FIG. 222.—A PARTIALLY PATENT URACHUS. (After F. A. Walter.)

A, the right ureter; B, the left ureter; C, represents the position of the longitudinal muscle-fibers, which have been dissected back; F, F, indicate the transverse muscle-fibers; G, the tough submucosa; H, H, bay-like dilatations of the urachus; I, indicates the prostate; K, the nearest portion of the urethra. The specimen was from a boy twelve years of age.

urachus. He believed that the urachus remained open only during childhood; that after birth the canal closed and was transformed into a solid cord.

Civiale, in 1823, saw a cadaver from which the intestine had been lifted out, but the pelvic organs were intact. The bladder made a prominent termination above, by a cylindric prolongation which had been cut across several lines above the bladder proper. The opening permitted the introduction of a finger into the bladder and corresponded exactly with the insertion of the urachus. It was smooth, roundish, and surrounded by a sort of muscle.

For many years a controversy went on as to the permeability of the urachus after birth. C. Simon, in his thesis published in 1843, says that Harvey, Noreen, Haller, and others had noted, in children born before the normal time, a cavity in the urachus extending more or less in the direction of the umbilicus. Into this it was possible to introduce a bristle or to inject mercury. These dilatations were, however, confined to children born prematurely.

Simon refers to a case observed by Albinus. The patient was a young man. The urachus was hollow and opened into the bladder. Albinus held that it was by no means rare to find the urachus in a permeable condition in adults.

According to Simon, Verdries, Beudt, and Haller had reported examples of the same character, and Haller in the cadaver of an adult found the urachus permeable and was able to introduce a bristle into it.

Simon mentions cases reported by Littré and Civiale, and refers to a case recorded by Boehmer in his thesis, "De uracho humano." Boehmer's patient was a man aged forty, who died of an "inflammation in the chest." At autopsy, when water was injected into the bladder, the urachus swelled up and became prominent.

Probably the most important article that we possess is that of Luschka, published in 1862.

Luschka deals with the so-called obliterated urachus or median suspensory ligament of the bladder in adults under normal conditions. He says there is no doubt that in embryonic life the urachus remains patent as far as the umbilicus, and that it communicates with the bladder. He says that the views vary widely concerning its relationship, when the body is fully developed, and that the differences mainly have to do with the question whether in the adult this cord is hollow or solid. He says that the majority of writers agree that it is solid.

Luschka refers to the observations of Walter. This author thought that, as a rule, there was a persistence of the patent urachus and that the canal was frequently filled with a reddish fluid. On the other hand Noreen (*De mutatione luminum in vasis, etc., in specie de uracho*, 1749) held the opposite view, although in one instance in an adult he was able to pass a bristle for two inches into the urachus. The views of Portal (*Mémoires de Paris*, 1769) and Meckel (*Handbuch der menschlichen Anatomie*, Bd. iv, S. 474) coincided with those of Noreen.

Luschka says that from the top of the bladder there pass a number of bundles of the deep detrusor muscle of the bladder. These extend upward for a certain distance (Fig. 223). The muscle gradually loses itself in a thick, pale yellow tissue which consists chiefly of elastic fibers and which really is the tendon of the smooth muscle bundle. Luschka says that, as a rule, this bundle can readily be followed in its course upward, and that it gradually diminishes in thickness and ends in the umbilical scar. Sometimes remnants of this tissue of the cord pass upward to the round ligament of the liver. More frequently, however, the median vesical ligament



does not reach the umbilicus, but, beginning at a point some 5 or 6 cm. above the summit of the bladder, terminates in a number of tendon-like threads, which, usually unsymmetrically, unite with the left and right vesical ligaments, or may merge into one another, forming a kind of network. If one carefully splits the longitudinal axis of the urachus from the summit of the bladder, he will in some cases be able to see an extension of the bladder mucosa upward as a tubular projection reaching a distance of 2 mm., and a pin-point opening may be found existing between the urachus and the bladder. Usually, however, only a small depression is noted at the summit of the bladder, and very frequently even this may be lacking, so that in the examination of the free surface of the bladder mucosa no trace of the original communication between the urachus and the bladder is visible. In these cases the beginning portion of the urachus has been obliterated. Such a complete closure of the canal, however, says Luschka, is usually noted only for a short distance. The urachus soon shows the cavity again for a length of from 5 to 7 cm., or sometimes more. The urachus, however, becomes thinner and thinner, and, as a rule, varies from 0.5 to 1 mm. in breadth. Luschka says that in the adult the cavity of the urachus in the median vesical ligament has a manifold tortuous course with numerous large and small round bays running off from it, giving it a nodular appearance, and occasionally a configuration suggestive of the acinous type of glands (Fig. 224). These dilatations sometimes involve the entire circumference of the tube, but more often are lateral. In such cases they may have a broad base or be more or less pedunculated. Luschka says that he has time and again noted that some of these dilatations have grown as pipe-like branches in the length of the duct. Some of the dilatations in the course of time are nipped off, and as a result of further growth develop into cysts (Fig. 225).

The early stage of cyst formation occurring from metamorphosis of the urachus is produced very frequently as a result of the urachus remaining open only at isolated points. The cysts may vary in size. As a rule, they are so small that they are recognized only when studied between cover-glasses. They may, however, be as large as millet-seeds or reach the size of a pea. They may be isolated, but are sometimes present in large numbers, and more or less closely packed together, so that they present tumors resembling bunches of grapes.

Luschka says that he has not had any individual experience with cysts of the urachus, and knows of no observations by others, but he has not the slightest doubt that large cystic tumors of the anterior abdominal wall needing surgical interference develop and that these tumors have originated from the urachus.

He suggests that, if one wishes to study the cavity formation of the interior of

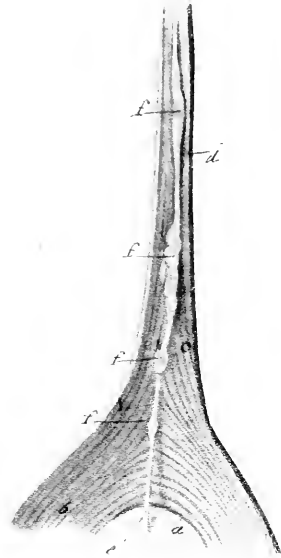


FIG. 223.—A PATENT URACHUS. (After H. Luschka.) (Natural size; from a man fifty years old.)

The outer side of the upper end of the bladder mucosa (*a*) has been freed from the muscle (*b*), and this has been turned outward. The muscular portion (*c*) and the tendinous portion (*d*) of the median vesical ligament have been dissected free and turned back. In this way the urachus has been exposed and here and there shows marked nodular dilatations (*f, f, f*).

the median vesical ligament, it is necessary to cut it out in sections, treat it with acetic acid, and make firm pressure between glass plates. The structures can then be gradually dissected out. He then goes on to describe the ground membrane, the layer of fibers, and finally the epithelium of the urachus. In speaking of the epithelium he says that where the canal in the adult is well preserved, one can scrape away the thick layer, which is similar to the so-called transitional epithelium noted in the bladder, ureters, renal pyramids, and the pelves of the kidneys. All possible forms of these cells can be noted. Some are round, others polygonal, some are branched, and some resemble cylindrical epithelium.

The contents of the urachus vary. The fluid is usually pale yellow, thin, and translucent. It may, however, be cloudy, brown, or reddish in color. It contains a large number of cells of the type above described. There are also numerous fat-globules and not infrequently corpora amylacea. In the dilatations and in the isolated cysts the contents are frequently sticky and dirty brown. Scattered throughout the fluid are bodies which have a marked resemblance to prostatic concretions.

FIG. 224.—A PORTION OF A URACHUS SEVEN TIMES ENLARGED, WITH NUMEROUS LARGE AND SMALL DILATATIONS. From a man twenty-seven years old. (After H. Luschka.)

Veiel, a pupil of Luschka, published a thesis on the urachus in 1862. He gave a very extensive review of the literature, and referred to the patent urachus in the calf and pig. He also reported (Case 3) an observation on a man twenty-four years of age. The urachus was 4.1 cm. long, tortuous, and formed pearl-like dilatations. These dilatations were partly central, partly eccentric, varied from 1 to 2 mm. in breadth, and contained a yellowish, cloudy fluid. The largest was situated just above the bladder. When the urachus was placed between glass plates, the fluid could be forced from one dilatation into the next.

Hoffmann, in 1870, when considering the pathologic changes in the urinary tract, referred to the early work of Walter. He says that Walter sought to prove that the urachus under normal conditions in both sexes remained as an open canal into which one could introduce a fine sound and pass it to the bladder. This view was not accepted, and most of the later anatomists concluded that the urachus in the grown person was completely obliterated. Hoffmann refers to the work of Luschka, in which it was demonstrated that in most

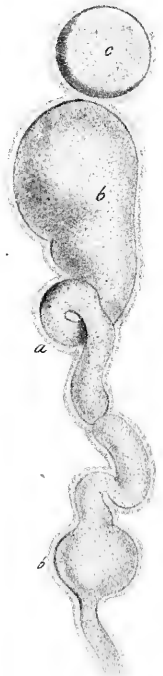

FIG. 225.—PORTION OF A URACHUS TEN TIMES ENLARGED. (After H. Luschka.)

This here and there shows a tortuous course as indicated by *a*. At certain points (*b, b*) are dilatations. One of these dilatations (*c*) has already become completely nipped off, forming a cyst.

of the cases the urachus is patent for a certain distance, even if it does not always communicate with the bladder. He also drew attention to the fact that Luschka agreed with Walter in holding that the urachus is lined with mucosa. With Luschka's statement that the caliber of the urachus is not uniform but tortuous, and that it has numerous large and small bays running out from it and giving rise to a nodular appearance, reminding one somewhat of an acinous gland, Hoffmann in general agreed.

Gruget, in 1872, published a very interesting thesis on urinary umbilical fistulæ due to persistence of the urachus. He examined in all 82 bodies, and only twice did he find the urachus permeable.

C a s e 1. — A human embryo, two and a half months old, was received by Dr. Guéniot. It weighed 20 grams. The distance from the pubes to the umbilicus was 7 mm. A portion of the abdominal wall was gelatinous. The walls of the bladder were transparent, and the bladder contained a few drops of a colorless liquid. When the bladder was opened a fine probe could be carried into the urachus, which was patent. In this case the urachus was open from the bladder to the umbilicus, and was continued as a pervious canal out into the cord for at least 3 cm.

[This is occasionally noted in a human embryo at this age—7.5 cm.]

C a s e 2 was that of a female fetus born living at the end of the fifth month and dying twenty minutes after birth. This case also came under Dr. Guéniot's observation. The urachus was obliterated in its inferior or vesical portion, but open in its upper portion and also out into the cord, where it again became obliterated, forming a filament. Gruget, from his studies, came to the conclusion that persistence of the urachus is very rare. His article is very carefully written.

Nicaise assures us that a hollow urachus is not rare. He says that Haller demonstrated this condition in the cadaver of an adult, and that he had seen the urachus large enough to have a silk thread passed through it. He adds that Harvey, Moreau, Verdries, and Beudt had described examples of the persistence of the urachus.

Tillmanns says that Meckel, in 1809, described a cystic dilatation of the urachus. Next to the fundamental work of Luschka is that of Wutz, published in 1883. Wutz said that Peu, in his book on Obstetrics, in 1694, speaks of a tumor the size of a pigeon's egg situated at the umbilicus in a child two hours old. When this tumor was opened, urine escaped.

Wutz refers to the early literature on the urachus, mentioning the names of Blasius (1674), Littré (1701), Peyer (1741), Albinus (1754), Boehmer (1764), Portal (1769), Walter (1775), Meckel (1820), and finally reviews the findings of Luschka.

Wutz (p. 390) gives a description of his own work, and says that his observations are based on the examination of 74 bodies of various ages, including males and females.

He found that the distance from the top of the bladder to the lower margin of the umbilicus was as follows:

In the young and new-born . . . . .	3.1 cm.
In persons from seventeen to twenty-five years . . . . .	16.5 cm.
“ “ “ twenty-five to seventy years . . . . .	18.7 cm.

He says that at the top of the bladder the median vesical ligament has a thickness of from 2 to 2.5 mm. He then takes up the consideration of the urachus, and draws

attention to the fact that Suchanek, in his investigations, left the urachus in hydrochloric acid for two days. As a result, the musculature and the connective tissue were then so soft that they could easily be removed.

Wutz, after using a 1 per cent solution of sodium chlorid, hardened the specimen in alcohol and then stained it with Grenacher's carmin, picrocarmin, or hematoxylin. The specimen was then passed through oil of cloves and mounted in Canada balsam. In this way it was possible to obtain a beautiful low-power picture and at the same time study the specimens under the higher power. Wutz says that after careful division of the rather tough capsule the transparent urachus is reached (Fig. 226). His examination showed that the commencing portion of the epithelial tube is frequently embedded in the musculature of the vertex of the bladder for a distance of 0.5 to 1 cm. He says that within the thickness of the bladder-wall the urachus often runs at an angle (Fig. 227). On examination of the inner surface of the bladder at the point where the urachus begins, in the majority of cases there is a funnel-like depression, and at the point of the funnel a fine opening. Fifty-one (69 per cent) of Wutz's cases presented an opening of such a character, into which a bristle could be passed for 0.3 to 0.5 mm. In 32 of these cases this could be carried upward for a distance of from 2 to 6 mm., while in 19 it penetrated from 1.1 to 4.8 cm.

In 2 cases out of 74 (2.7 per cent) the surface of the mucosa was smooth and indicated no trace of a previous communication between the urachus and bladder. In the remaining 21 cases there was a very perceptible groove at the entrance of the urachal canal. In these cases it was, however, impossible to pass a sound upward, although it could be passed from above downward for a certain distance. In several of the cases in the first group, in which the sound could be passed from the bladder, a certain degree of obstruction was noted at the entrance of the canal. In other cases Wutz gathered the impression that the urachal opening was guarded by a valve-like structure apparently supplied by a transverse fold. He says that, under normal conditions, the passage of urine through the urachus does not occur, notwithstanding the existing communication. In cases of marked dilatation of the bladder due to prostatic



FIG. 226.—CYSTS OF THE URACHUS ARRANGED LIKE A STRING OF PEARLS, FROM CASE 17. (After J. B. Wutz's Plate xii, Fig. C.)

The cysts are near to the bladder. There are three of uniform size, with two smaller ones between them. In the upper portion of the urachus are several small, spindle-shaped dilatations. *V* is the bladder. *B* is a bristle passing up into the urachus.



FIG. 227.—SPINDLE-SHAPED DILATATIONS OF THE URACHUS. (After J. B. Wutz, Plate xi, Fig. E.) Case 22.

*V* is the bladder; *Eur*, the urachus. Near the bladder there is a small dilatation, then a spindle-shaped dilatation, and a little farther up the largest spindle-shaped cyst.

hypertrophy the dilatation of the canal was never noticed by him, and in the new-born the passage of a bristle was only occasionally possible.

Wutz measured microscopically the epithelial tube and found that the average length in the new-born was about 1.6 cm., in adults, 6.7 cm., and in one case it was 7.7 cm. He says that the greatest diameter (1.5 to 2 mm.) of the urachal tube is at or near the bladder. In the region of the umbilicus it had become smaller, being 0.5 mm. The cells forming the lining of the urachus were large, oval, and showed large nuclei. Some were long and had tails, and there were many branching, flat epithelial cells. As a rule, there were three layers of epithelium. In the upper portion there were sometimes two layers, but finally only one layer. The transverse section of the urachus was usually not round, but flattened or elliptic, and not infrequently wavy. The outer longitudinal layer of muscle Wutz found to be constant, and in all cases it extended beyond the epithelial tube above.

Wutz's summary is as follows:

1. The epithelial tube of the median vesical ligament in most cases in its lower portion can be sounded from the bladder. In other words, a probe can be passed into it from the bladder.

2. At the entrance of the urachus there is a transverse fold which makes the entrance of the sound more difficult and hinders the passage of fluid into the urachus. [This obstruction has of late years been known as Wutz's valve.—T. S. C.]

3. Toward the upper end of the epithelial tube the diameter of the urachus diminishes in both its muscular and epithelial portions.

4. The musculature under all conditions extends farther upward than the epithelial tube.

5. The beginning of the tendinous character of the median vesical ligament corresponds somewhat constantly in children to one-half, and in adults to one-third, of the distance between the umbilicus and the summit of the bladder.

Monod, in 1899, published an interesting thesis of over 200 pages on Urinary Umbilical Fistulæ Due to Persistence of the Urachus. In the historic portion of his publication he refers to the observations of Meckel, Cuvier, Pokels, Velpeau, and Robin. Monod says that he does not consider the persistence of the urachus a malformation as rare as was believed by Guéniot and his pupil Gruget, but agrees with Forgue and Morer and Trogneux that this malformation is not very frequent without being exceptional.

Mériel, in 1901, gave a very good résumé of the literature, and Vaughan, in 1905, presented an interesting paper on the subject before the American Surgical Association.

Binnie, in 1906, published a paper on the development of the urachus and gave the results of Mr. Clendening's investigations. Sixteen cadavers and 7 fetuses were examined, with the following results:

1. In seven adults and six fetuses the bladder showed a distinct diverticulum from 1 to 2 cm. deep, at the point where the urachus is usually attached.

2. In one adult there was a slight projection instead of a diverticulum.

3. In eight adults and one fetus the dome of the bladder was smooth.

4. In none of the cases did Clendening find lacunæ lined with epithelium in the urachus.

5. The average adult urachus was 12 cm. long and 1.5 [mm.] wide.

6. The urachus was usually adherent to the abdominal wall, but in one patient

(a diabetic with frequent retention of urine) it was not close to the parietes, but lay between loops of the small intestine.

7. In all cases the urachus was well supplied with vessels.

From this review of the literature it is evident that the urachus in a certain number of cases remains patent throughout. Hence under such circumstances, as soon as the cord comes away a few days after birth, a urinary fistula exists at the umbilicus.

In other cases portions of the urachus may remain open. The vesical end of the urachus may be connected with the bladder, but more frequently small, cyst-like dilatations are found in the course of the obliterated urachal cord. These may later dilate, giving rise to urachal cysts. In some instances they become infected, and an abscess develops in the anterior abdominal wall, between the recti muscles and the peritoneum of the anterior wall of the abdomen. In those patients in whom remnants of the urachus exist, any interference with the easy passage of urine from the urethra is liable to be followed by a reopening of the urachus, with an escape of urine from the umbilicus. Such a condition may be due to a vesical calculus plugging the inner urethral orifice, to a urethral stricture or to blocking by an enlarged prostate. In quite a number of cases cystitis with its consequent vesical tenesmus has been followed by infection of the urachus and the development of a urinary umbilical fistula.

In the succeeding chapters I shall consider in detail the literature on abnormalities due to remnants of the urachus.

#### LITERATURE CONSULTED ON REMNANTS OF THE URACHUS.

(See also the literature of the following chapters.)

- Binnie, J. F.: Development of the Urachus. *Jour. Amer. Med. Assoc.*, 1906, ii, 109.
- Civiale, J.: *Traité de l'affection calculeuse*, Paris, 1838, 258.
- Gruget, L.: Des fistules urinaires ombilicales qui se produisent par l'ouraqué resté ou redevenu perméable. Thèse de Paris, 1872, No. 422.
- Hoffmann, C. E. E.: Zur pathologisch-anatomischen Veränderung des Harnstrangs. *Arch. der Heilkunde*, 1870, xi, 373.
- Luschka, H.: Ueber den Bau des menschlichen Harnstranges. *Arch. f. path. Anat. u. Physiol. u. f. klin. Medizin*, 1862, xxiii, 1.
- Mériel: Les dérivés pathologiques de l'ouraqué. *Gaz. des hôpitaux*, Paris, 1901, lxxiv, 181.
- Méry: *Hist. Acad. roy de sc. (de Paris)*, Amsterdam, 1700, 53.
- Monod, J.: Des fistules urinaires ombilicales dues à la persistance de l'ouraqué. Thèse de Paris, 1899, No. 62.
- Nicaise: Ombilic. *Dict. encyclopédique des sci. médicales*, Paris, 1881, 2. sér., xv, 140.
- Simon, C.: Quels sont les phénomènes et le traitement des fistules urinaires ombilicales. Thèse de Paris, 1843, No. 80.
- Tillmanns, H.: Ueber angeborenen Prolapsus von Magenschleimhaut durch den Nabelring (Ectopia ventriculi) und über sonstige Geschwülste und Fisteln des Nabels. *Deutsche Zeitschr. f. Chir.*, 1882-83, xviii, 161.
- Vaughan, G. T.: Patent Urachus. Review of the Cases Reported. Operation on a Case Complicated with Stones in the Kidneys. A Note on Tumors and Cysts of the Urachus. *Trans. Amer. Surg. Assoc.*, 1905, xxiii, 273.
- Veiel, E.: Die Metamorphose des Urachus. *Diss.*, Tübingen, 1862.
- Walter, F. A.: *Einige Krankheiten der Nieren und Harnblase*, Berlin, 1800.
- Walters, F. R.: Umbilical Pocket. *Brit. Med. Jour.*, 1893, i, 173.
- Wutz, J. B.: Ueber Urachus und Urachuseysten. *Virchows Arch.*, 1883, xcii, 387.

## REMNANTS OF THE URACHUS NOTED IN VARIOUS ANIMALS.

I have made no attempt to cover the literature on this subject, but while studying the urachal remains noted in the human being, I have from time to time met with references to partial or complete urachal remains noted in animals.

There seems to be little doubt that urachal remains are more commonly found in the horse than in any other domestic animal. Gurlt, in 1832, in speaking of the horse, said: "It sometimes happens that after birth the bladder with the urachus separates from the umbilicus and closes up, but a vesical portion of the urachus does not disappear, but gradually develops into an open chamber as large as the bladder itself. In these cases we have, as it were, two bladders, one sitting on the top of the other, and the two communicating through a large channel." Gurlt observed this condition in a grown horse.

O'Brien, writing in 1879, quotes Cheaureau: "In a fetal horse the bladder occupies the abdominal cavity as far as the umbilical opening, the anterior extremity forming a veritable neck. At birth this anterior neck separates from the urachus and is transformed into a cul-de-sac which is gradually withdrawn into the pelvis." O'Brien, while dissecting a young colt dead of osteitis, found that the bladder extended by a funnel-shaped canal to the umbilicus.

Finch, in 1903, reported a case of pervious urachus in a colt. The colt was ten days old and had colicky pains, as was evidenced by his uneasiness. The umbilicus was much enlarged and wet, this condition being evidently due to the presence of a pervious urachus. The colt apparently had pain over the loins. The urine was clear.

Purgatives and soothing applications were employed, but the colt died in a few days. The autopsy showed that a portion of the large bowel was inflamed. The umbilical cord was thickened and contained a small amount of thick, creamy pus. The walls of the bladder were thickened and inflamed. Nothing is stated in the protocol about the urachus.

Salvisberg, in 1902, related his experience with urachal fistulæ in the horse, and outlined his method of handling them. He says that when the cord is torn off too close to the body in colts, the urachus remains open, and part of the urine escapes from the umbilicus. The urachus in colts has grown fast to the umbilical ring; consequently the closure of the ring is not so easy. If the cord of every colt were properly tied, a urinary fistula at the umbilicus would be very rare.

Salvisberg says that every spring he operates on several colts with urachal fistulæ. It is no art to tie the cord 3 or 4 cm. from the abdomen.

From three to fourteen days after the birth of the colt the farmer reports the fistula. The urine drops from the umbilical opening, or during urination a certain amount escapes from the umbilicus.

Where a stump is present, the surrounding skin shows little change, the urine being carried off, as it were, through a pipe. Usually the opening is on the skin level or in a small groove. It is then surrounded by a zone of granulation tissue. The hair is wet and stuck together. An area around the umbilicus is swollen, and has scattered over it many ulcers; or it is occupied by one large ulcer from which a purulent foul discharge comes.

Salvisberg used silver nitrate, copper sulphate, etc., but some of the colts died of pyemia or polyarthritis. The use of a purse-string suture proved of no value.

Dissecting out the urachus from the umbilicus and tying was fatal, as the peritoneum has to be opened.

Salvisberg finally decides upon the following procedure: The umbilical region is shaved and disinfected and injections of salt solution are made into the parts in the immediate vicinity. These should produce small elevations, the size of hazelnuts, all around the opening; two or three rows are made. The surface is then covered with an iodoform-collodion dressing. Frequently, in a few hours, the elevations disappear and a uniform swelling closes the urachus. Sodium chlorid solution, 15 per cent, is used. To this a few drops of pure carbolic acid are added. The results appear to be good.

Swain, in the *Veterinary Archives* for 1903, when referring to persistency of the urachus, says: "The equine family seems much more subject to this abnormality than the bovine or other domestic animals, and the breeds of draft-horses are more subject than the finer breeds; the male foal is more subject to this persistence than the female."

Bland-Sutton, in "Tumors, Innocent and Malignant," 1907, says that he had observed urachal cysts in the horse.

Recently, while conversing with my old friend and classmate, Dr. W. N. Barnhardt, about urachal remains, he told me that for years he had been interested in this subject, and that he had observed numerous abnormalities in the horse. I asked him to give me briefly the results of his observations. Under date of April, 1914, he writes:

"Living for years on a horse-breeder's ranch, I developed a curiosity as to the cause of death of foals. Among other morbid conditions I observed, by post-mortem examination, a patent urachus in five foals that had died within four days of their birth. One of these showed a red thrombus about the size and shape of a small banana, and two others showed infection and inflammation within the urachus. In four of them urine had flowed quite freely from the umbilicus. In others that lived and attained a healthy maturity I have observed an occasional discharge of urine at the umbilicus in the first few days after birth."

From the foregoing it is clearly evident that urachal remains, particularly umbilical fistulæ, are relatively common in the horse.

*Urachal Remains in the Cow or Steer.* — Gurlt, in 1831, when referring to a cyst-like pouch of the urachus seated on the top of the bladder and resembling a second bladder in a horse, said that he had once observed a similar condition in a cow. This case was seen in consultation with a veterinary surgeon named Naundorf.

Veiel, in 1862, reported several cases. In the examination of an eleven-day-old steer he found passing from the top of the bladder a urachus which could be traced for 5.6 cm. as a tube. It was 6 mm. broad and had a relatively uniform diameter. Veiel, in Case 3, refers to a sixteen-day-old calf. The top of the bladder gradually diminished in size and passed over into the urachus, which was open as far as the umbilicus.

Bland-Sutton has observed urachal cysts in the ox, in the pig, and in the mole.

*Urachal Remains in the Pig.* — In a sow one year old, Veiel observed at the top of the bladder a cord 7.3 cm. long and about 2 mm. broad. On carefully splitting the muscle and turning it back, he detected a small lumen. This was uniform in diameter, but at each end was a round dilatation.



Hoffmann, in 1870, made an interesting observation on cysts of the urachus in a swine embryo. He first referred to an observation by Meckel, who found in a swine at term a cyst of the urachus, one inch in diameter, situated four inches below the umbilicus. At either end it was attached to the urachus.

Hoffmann said that in 1866 he received from a butcher a so-called double urinary bladder. This came from a full-grown pig and had the form of two sacs of the same size, which were separated from one another by a narrowing in the middle. When distended, both halves were elongated and rounded, and it looked as if, on the summit of the portion connected with the urethra, a second bladder was situated. In the distended condition the lower compartment was 31 cm. long and 22 cm. in diameter. The upper one was 25 cm. long and had a breadth of 24 cm. These two cavities occupied the space between the urethra and the umbilicus. Over its entire surface was a peritoneal covering. At the umbilicus the upper portion was closed. The lumen occupying the usually obliterated portion of the urachus had dilated, forming the second bladder.

Sutton observed urachal cysts in the pig.

#### LITERATURE CONSULTED ON REMNANTS OF THE URACHUS IN ANIMALS.

- Bland-Sutton, J.: Tumors, Innocent and Malignant, Chicago, 1907.  
 Finch, R.: Case of Pervious Urachus (in a Colt). *Veterinary Record*, London, 1902-03, xv, 798.  
 Gurjt, E. F.: *Path. Anat. der Haus-Säugethiere*, 1831, i, 213.  
 Hoffmann, C. E. E.: Zur pathologisch-anatomischen Veränderung des Harnstrangs. *Arch. der Heilkunde*, 1870, xi, 373.  
 O'Brien, J. E.: Pervious Urachus, *Comparative Anatomy*. The *Obstetric Gazette*, Cincinnati, 1879-80, ii, 100.  
 Salvisberg: Die Behandlung der Urachusfistel beim Fohlen. *Schweizer Arch. f. Thierheilkunde*, 1902, xlv, 228.  
 Swain, S. H.: Persistency of the Urachus. *Jour. Compar. Med. and Veterinary Archives*, 1903, xxiv, 95.  
 Veiel, E.: Die Metamorphose des Urachus. *Diss.*, Tübingen, 1862.

## CHAPTER XXXI.

### URACHAL REMNANTS PRODUCING TUMORS BETWEEN THE UMBILICUS AND SYMPHYSIS.

Small urachal cysts; Historic sketch; Report of cases.  
Personal observations on small cysts of the urachus.

REMNANTS of the urachus may become distended, producing small or large cysts, which may or may not become infected. Some of them are directly connected with the bladder or with the umbilicus or with both. For convenience I have made the following tentative classification. Some overlapping, of course, is inevitable.

- (1) Small urachal cysts.
- (2) Large urachal cysts. 

{	Non-infected.
	Infected.
- (3) Urachal cavities lying between the symphysis and umbilicus and communicating with the bladder or umbilicus or both.

#### SMALL URACHAL CYSTS.

Small urachal cysts naturally give rise to no clinical symptoms, hence they are recognized only when the abdomen is opened for some intra-abdominal lesion or at autopsy. It is not to be wondered at, therefore, that the literature on the subject is very meager.

As has been said before, Luschka concludes that large cystic tumors of the anterior abdominal wall needing surgical interference develop, and that these tumors originate from the urachus.

Veiel, in 1862, in his dissertation on the Metamorphosis of the Urachus, cites the findings in the body of a man forty-five years of age. Passing downward from the umbilicus was a delicate cord 1 mm. broad. About 3 cm. above the bladder it grew larger, so that at the top of the viscus it was 1.2 cm. thick. At this point it was covered with a thick layer of bladder muscle. The urachus could be divided into four sections—the lowest (part 1), which was open, was 14 mm. long. In the middle it was somewhat smaller, but at each end it was 2 mm. thick. Part 2 was 7 mm. long and was closed and thread-like. Part 3 was 8 mm. long, was open, and about 1 mm. thick. Part 4 was closed and thread-like. On microscopic examination the upper open portion showed moisture and had a lining of so-called transitional epithelium. After the specimen had been treated with acetic acid, three dilations of the canal were found. These contained yellowish concretions.

Wutz, in 1883, after reporting his Case 22, in which the urachal cyst contained a firm, stony, hard, yellowish brown, glistening body, described the following case in detail:

Case 24. — The specimen was from a man twenty years old, dead of peri-

tonitis following a perforated appendix. The distance from the umbilicus to the top of the bladder was 16 cm. The bladder mucosa in the vicinity of the trigonum was diffusely reddened, and on its surface were a few blood and pus corpuscles. The bladder was small and drawn out to a point. It was 7.5 cm. in length. In the mucosa of the vertex the opening of the urachal canal had a diameter of 2 mm.; 2.5 cm. above the bladder was a cyst 1.5 cm. long, 0.8 cm. broad, and attached to the side of the urachus; into it a sound could be passed from the urachus. About 3 mm. above this cyst were several smaller ones, some reaching the size of a pin-head. Wutz said that a probe could be passed into the urachal canal for a distance of 4.3 cm. The large cyst was filled with clear yellow fluid, which contained albumin and mucin. Microscopic examination showed polymorphous epithelium, pus-cells, and red blood-corpuscles. In the smaller cyst the epithelium was normal and there was no evidence of pus-cells.

Wutz (p. 404) sums up the results of his observations of the urachus and urachal cysts as follows:

1. All the observed cysts have been located in the lower fourth or lower third of the distance from the urachus to the top of the bladder, and originated from the normally persistent portion of the urachus.

2. In the majority of the cases they were lined with several layers of flat epithelium.

3. The cysts had a more or less strongly developed covering of smooth muscle-fibers.

4. The size of the cysts varied from that of microscopic objects to that of a large bean.

5. Laminated bodies contained in the cyst fluid did not stain blue with iodine, but yellow, and they did not consist of amyloid substance.

6. Concretions in the canal of the urachus or in the urachal cysts were of rare occurrence, and then reached only a small size.

7. Urachal cysts were sometimes the seat of inflammatory changes.

Morestin, in 1900, reported a case in which two small urachal cysts were discovered between the muscle and peritoneum during an abdominal operation for a left pus-tube. They were too small to be recognized before operation. They were arranged one above the other, but were independent. The cord of the urachus passed from the summit of the bladder and disappeared in the lower cyst. It was again recognized above the upper cyst, and could be followed to the umbilicus. The peritoneum was loosely attached to the cysts. The cysts were globular, smooth, transparent, of a bluish tinge, and contained a limpid, colorless fluid. Their inner surfaces were smooth and presented a serous aspect. There was an outer covering of connective tissue and an inner lining of flattened epithelium. These cysts manifestly had originated from the urachus.

Wyss, in 1870, under the title of "A Cyst Near the Umbilicus," reported his findings at autopsy. Between the peritoneum and muscle, a little to the side of the linea alba, and about one inch above the umbilicus, was a cyst the size of a bean. It contained turbid, tenacious mucus, grayish yellow in color. It was lined with cylindrical epithelium. Wyss thought that the cyst had resulted from embryonic remains.

The location of the cyst, the changes in the epithelium, and the cyst contents strongly suggest that it had originated from remnants of the omphalomesenteric duct.

Opitz, in his article on Urachal Cysts published in 1905, referred to a cyst of the abdominal wall and said that it looked like an appendix; that it was lined with one layer of low epithelium, and was surrounded by a circular layer of muscle, outside of which was a longitudinal muscular layer. From the description it is impossible to get a clear idea of the case.

Caruso, when operating on a woman forty-two years old for removal of a myoma, noted a small cyst at the level of the umbilicus. This was lined with cuboid epithelium. He also noted tubular glands and non-striped muscle. The location of this cyst would throw some doubt upon its urachal origin, and the presence of tubular glands suggests that it may have originated from remains of the omphalomesenteric duct or from uterine glands at the umbilicus.

Weiser, in his article, says that he received personal letters from Wm. J. Mayo, Nicholas Semm, Edwin Martin, W. A. Smith, Roswell Park, J. F. Erdmann, Howard A. Kelly, DeForest Willard, and from E. Wyllys Andrews, saying that they had personally encountered instances of cysts of the urachus.

From the foregoing it is seen that small urachal cysts are found between the bladder and umbilicus, and that they lie between the muscles and peritoneum of the anterior abdominal wall. There may be only one cyst or several in a row. They may be minute or reach a centimeter or more in diameter. They have thin walls, and may be transparent or translucent. Their inner surfaces are smooth. They are lined with transitional or cylindric epithelium. The cyst fluid contains albumin, mucin, and exfoliated epithelium, and sometimes polymorphonuclear leukocytes and red blood-cells. They are merely dilatations.

Wutz's observations on small urachal cysts are the most complete that we possess. It will be of interest to glance through the 22 cases that he has recorded.

**C a s e 1.** — A nineteen-year-old boy had had a right-sided otitis media. The urachus was the seat of several small cystic dilatations, some of which communicated with one another.

**C a s e 2.** — A girl, twenty years of age, died of tuberculous peritonitis. The distance of the umbilicus from the vertex of the bladder was 20 cm. The length of the epithelial tube was 3.6 cm. The latter terminated in five transparent cysts the size of pin-heads.

**C a s e 3.** — A twenty-three-year-old man died of pulmonary tuberculosis. The distance from the umbilicus to the vertex of the bladder was 17 cm., and the length of the epithelial tube, 4 cm.

The latter ran straight, could be sounded, and terminated in three cysts the size of millet-seeds.

**C a s e 4.** — A woman, twenty-four years of age, died of pulmonary tuberculosis. The distance from the umbilicus to the top of the bladder was 26.5 cm. At a point 3.7 cm. from the bladder, lying on the left side and communicating with the canal, was a cyst the size of a pea.

**C a s e 5.** — The woman, twenty-seven years of age, was suffering with "sarcomatous struma." The distance from the umbilicus to the vertex of the bladder was 26.8 cm. About 0.5 cm. above the vertex, on the side, was a transparent cyst the size of a millet-seed.

**C a s e 6.** — The patient was a woman, thirty-one years of age, with pulmonary tuberculosis. The distance from the vesical vertex to the umbilicus was 17 cm. The epithelial tube could be sounded, the probe passing directly upward. In the

middle of its course the tube was obstructed, but the canal again appeared and terminated in a small cyst, conic in form, and almost 1 mm. long.

C a s e 7. — The patient was a man, thirty-six years of age, who had pulmonary tuberculosis. The distance from the umbilicus to the vertex of the bladder was 15.5 cm. The length of the epithelial tube was 4.4 cm. At a point 0.75 mm. from the top of the bladder was a spindle-like dilatation, 0.71 mm. long and 0.1 mm. broad.

C a s e 8. — A man, thirty-eight years of age, died of tuberculosis. The distance from the umbilicus to the vertex was 25 cm. The length of the epithelial tube was 0.7 cm. At a point 3 mm. from the vertex of the bladder was a spindle-like dilatation varying from 1.5 to 0.42 mm. in diameter. About 1 mm. from this was a second, 2 mm. long, 0.67 mm. broad.

C a s e 9. — The subject was a woman, thirty-nine years of age, dead of cerebral hemorrhage. The distance from the umbilicus to the vertex was 20.5 cm. The length of the epithelial tube was 4.3 cm. At a point 2.5 cm. above the vertex of the bladder was a dilatation 3.5 x 1.5 mm., filled with a yellowish, crumbly material.

C a s e 10. — The subject was a woman forty years of age, dead of tuberculous cerebrospinal meningitis. The distance from the umbilicus to the vertex of the bladder was 18.8 cm., and the length of the epithelial tube was 1.9 cm. About 1 cm. above the vertex of the bladder were two cysts attached to the left side of the tube. The first was roundish and measured 0.54 x 0.3 mm. The second was 0.63 x 0.49 mm. Scattered throughout the entire length of the tube were numerous small dilatations. These were somewhat pedunculated, and were situated on all sides of the tube.

C a s e 11. — The man, forty-three years of age, had died of delirium tremens. The distance from the umbilicus to the vertex of the bladder was 20 cm. The length of the epithelial tube was 5.6 cm. In the bladder mucosa there was a distinct groove. At a point 3.5 cm. above the bladder were three nipped-off cysts the size of millet-seeds. A short distance from the bladder the tube contained an oval body, 0.17 x 0.1 mm. This was brownish in color and homogeneous in consistence. In the further course of the tube were several diverticula and nipped-off cysts of various forms, filled with firm brown contents.

C a s e 12. — The man, forty-three years of age, had died of pachymeningitis. The distance from the umbilicus to the vertex of the bladder was 12 cm. Projecting from the top of the bladder were two small cystic dilatations.

C a s e 13. — A woman, forty-three years old, had died from degeneration of the heart. The distance from the umbilicus to the base of the bladder was 15 cm. The epithelial tube was 5.4 cm. long. The tube showed four spindle-shaped cysts; the largest was 1.5 cm. above the vertex of the bladder and measured 6 x 2 mm.

C a s e 14. — The man, forty-five years of age, had died of pulmonary tuberculosis. The distance from the umbilicus to the vertex of the bladder was 16 cm. The length of the epithelial tube was 5 cm. At a point 3 mm. above the top of the bladder was a cyst the size of a millet-seed, with a second the size of a pin-head on the top of it. The tube passed for a distance of 3 cm. and terminated with three cysts resembling a string of pearls. Besides these were numerous round, oval cysts, recognized microscopically.

C a s e 15. — The man, sixty-five years of age, had died of typhoid fever.

The distance from the umbilicus to the vertex of the bladder was 26 cm. The length of the epithelial tube was 5.5 cm. From the top of the bladder the tube passed directly upward and formed at the junction of the lower middle third a beautifully spindle-shaped cyst, not nipped off. This was 1.6 mm. long and 0.4 mm. broad. Above this point the tube showed numerous diverticula extending as far up as 3 cm. Here there was a broad-based cyst projecting from the right side. It was oval and measured 2.16 x 1.62 mm. These cysts were filled with lumps of brownish yellow material.

*C a s e 16.* — The man, sixty-one years of age, had died of pachymeningitis with hemorrhage. The distance from the umbilicus to the vertex was 19 cm. The length of the epithelial tube was 3.1 cm. It showed diverticula and cysts. They were arranged in groups around the canal, and at first sight suggested acinous glands.

*C a s e 17.* — The woman, sixty-six years old, had died of an incarcerated hernia. The distance from the umbilicus to the vertex of the bladder was 22.5 cm. The length of the epithelial tube was 7.7 cm. Commencing 1 mm. above the top of the bladder were five pearl-like cysts, almost round and transparent. The first, third, and fifth were the size of small peas, while the two between them were as large as millet-seeds. The dilatations opened into one another, and the tube for several centimeters further admitted a fine bristle (Fig. 226, p. 520). The contents were yellowish-white and friable. Commencing 4.8 cm. above the bladder were six cysts of the size of pin-heads containing transparent fluid.

*C a s e 18.* — The man, sixty-seven years of age, had died of bronchopneumonia. The distance from the umbilicus to the vertex of the bladder was 16 cm. The epithelial tube was 4.8 cm. long. Situated 4.6 cm. above the bladder was a spindle-shaped cyst, 2 x 1 mm., with brownish-yellow contents.

*C a s e 19.* — The man, sixty-nine years of age, had died of cardiac degeneration. The distance from the umbilicus to the vertex of the bladder was 22.5 cm. The epithelial tube at the bladder had a diameter of 0.3 mm. Beyond this point were three cysts, the largest 10 mm. in diameter. The cysts communicated with one another.

*C a s e 20.* — The subject was a man, sixty-five years old, who had had softening of the brain due to an embolus. The distance from the umbilicus to the vertex of the bladder was 21.5 cm. The epithelial tube was 6 cm. long. The mucosa of the bladder at the vertex showed a definite, tent-like depression. Then there was a canal 1.6 cm. long and irregularly dilated. Situated 3 mm. above this was a spindle-shaped dilatation, 2 cm. x 4.5 mm.

*C a s e 21.* — The man, seventy-three years old, had died of carcinoma of the esophagus. The distance from the umbilicus to the vertex of the bladder was 19.5 cm. The epithelial tube was 0.6 cm. long. Situated 2 mm. from the vertex were two pin-head-sized, transparent cysts.

*C a s e 22.* — The man, seventy-three years old, had died of bronchopneumonia. The distance from the umbilicus to the vertex of the bladder was 16 cm. The epithelial tube was 6.7 cm. long. About 1 cm. from the top of the bladder was a spindle-shaped cyst, 0.7 cm. long and 0.3 cm. broad. Situated 0.3 cm. above this was a second cyst, nearly 2 cm. in length and 4.5 mm. broad (Fig. 227, p. 520).

Wutz in discussing these cysts says that the epithelium taken from the inner surface of the fresh cysts consisted of cells of various forms and sizes. A transverse

section through the cysts showed that they had an epithelial lining, then a structureless membrane, then a delicate connective tissue, and numerous smooth muscle-fibers were arranged chiefly longitudinally. In the walls were a small number of blood-vessels. The acinous glands described by Luschka were not observed by Wutz. He saw, however, quite frequently the lateral dilatations that gave a picture of a grape-like formation. The cysts contained partly transparent, partly yellowish or yellowish-brown or brownish-red masses. In the first case the contents were fluid, in several of the later ones they were firm. There were numerous fat-crystals, fat-droplets, and free fat, large fat-cells, brownish-yellow amorphous masses, isolated cholesterin crystals, and small, round, strongly glistening bodies.

#### LITERATURE CONSULTED ON SMALL URACHAL CYSTS.

- Caruso, F.: Contributo allo studio anatomo-patologico dei tumori cistici dell' ombelico. *Atti della Soc. Italiana di Ost. e Gin.*, 1901, viii, 293.
- Luschka, H.: Ueber den Bau des menschlichen Harnstranges. *Arch. f. pathologische Anat. und Physiol. u. f. klin. Medicin*, 1862, xxiii, 1.
- Morestin, H.: Kystes de l'ouraque. *Bull. de la Soc. anat. de Paris*, 1900, lxxv, 1040.
- Opitz: *Verhandl. Deutsche Gesellsch. f. Gyn.*, Kiel, 1905, xi, 545.
- Veiel, E.: Die Metamorphose des Urachus. *Diss.*, Tübingen, 1862.
- Weiser, W. R.: Cysts of the Urachus. *Annals of Surg.*, 1906, xlv, 529.
- Wutz, J. B.: Ueber Urachus und Urachuseysten. *Virchows Arch.*, 1883, xcii, 387.
- Wyss, H.: Zur Kenntnis der heterologen Flimmercysten. *Virchows Arch.*, 1870, li, 143.

#### PERSONAL OBSERVATIONS ON SMALL CYSTS OF THE URACHUS.

As far back as 1895 Dr. Kelly was much interested in small urachal remains that from time to time were noted during abdominal operations; and for a year or two he removed portions of the urachus where any thickening was noted. All these I examined histologically. Sometimes the cord itself would show a uniform thickening, as in Case 6902 (Path. No. 3144). Here it varied from 3 to 8 mm. in diameter, and yet on histologic examination there was no evidence of a lumen. The center was composed of longitudinal bundles of non-striated muscle. Surrounding this was fibrous tissue, and external to the latter was a circular muscular layer. This case shows that a large urachal cord does not necessarily mean that the urachus is patent.

A survey of the accompanying cases will show that the cysts varied from some very minute ones to others measuring 1 x 0.9 cm. From our experience it seems that where the urachus appears as a single dilated tube, the duct is usually lined with several layers of transitional epithelium, as in Fig. 229 (Gyn. No. 6792) and Fig. 232 (Path. No. 17025). It may, however, have only a single layer of cylindrical epithelium, as seen in Fig. 228 (Gyn. No. 3802).

Occasionally the remnants of the urachus appear as a small multilocular cyst, as noted in Fig. 230 (Gyn. No. 8250). The loculi are lined with cuboid epithelium. It is probable that such small multilocular cysts represent remnants of the acini described by various authors as projecting from the sides of the urachus.

The urachal remains were in every case surrounded by non-striped muscle.

Our experience leads us to believe that remnants of the urachus in the adult are by no means rare.

The small cysts may be filled with colorless fluid. Frequently they contain

granular débris which has a yellowish-brown tinge, and swollen and granular exfoliated cells containing brown pigment.

**Small Cyst of the Urachus.**—Gyn. No. 3802. A. P., aged twenty-five. Admitted November 19, 1895. At operation the uterus was suspended, the perineum repaired, an adherent ovary freed, and a cyst of the urachus removed (Fig. 228).

Path. No. 887. The specimen consists of fat containing a small cord 3 mm. in diameter, 1 cm. long. This ends at the upper end in an oval cyst, 1 x 0.9 cm., which has thin walls and contains clear fluid. This cyst is lined with one layer of cuboid cells, showing oval, uniformly staining nuclei parallel with the cyst-wall. In many places the epithelium appears to be two or three layers in thickness where

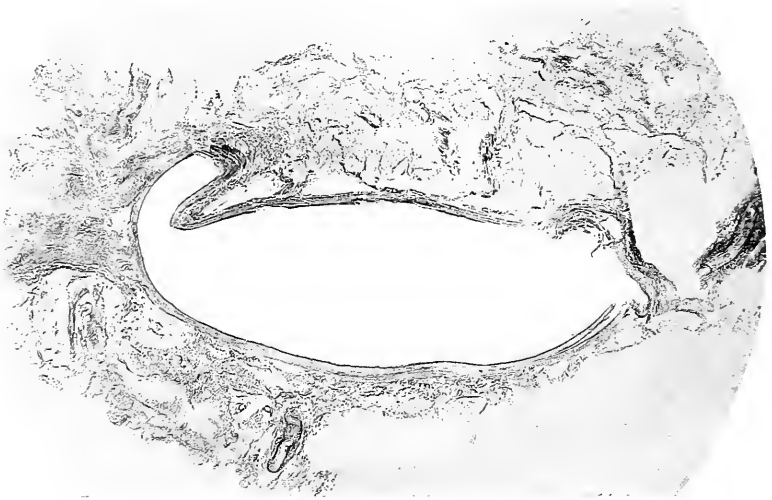


FIG. 228.—A SMALL CYST OF THE URACHUS.

Gyn. No. 3802. Path. No. 887. This cyst measured 1 x 0.9 cm., had thin walls, and contained clear fluid. In the handling, the cyst has been somewhat flattened. It is embedded in adipose tissue, and at either end is seen a fibrous cord—the obliterated urachus. The definite cyst-wall is composed of fibrous tissue and non-stripped muscle. The cyst was lined with one layer of cuboid cells.

cut on the bias. It is surrounded by fibrous tissue, and a moderate amount of muscle separates it from the surrounding adipose tissue.

Diagnosis: Small cyst of the urachus.

**Cyst of Urachus.**—Gyn. No. 6722. E. G., aged forty-six. Admitted to the Johns Hopkins Hospital February 27, 1899, with a diagnosis of uterine myoma. Operation: Hysteromyomectomy, excision of a small urachal cyst found lying between the obliterated hypogastric arteries.

Path. No. 2947. The cyst is 8 mm. in diameter. Its walls average 1 mm. in thickness. On histologic examination the little growth is found to consist of clusters of alveoli embedded in connective-tissue stroma, the entire area being surrounded by fat and fibrous tissue. The alveoli vary from a pin-point to 1 mm. in diameter. Some of them undoubtedly communicated with one another. They are lined with cuboid epithelium which is one layer in thickness.

Diagnosis: Cyst of the urachus.



**A Partially Patent Urachus.** — Gyn. No. 6739. C., aged forty-nine. Admitted to Ward B, Johns Hopkins Hospital, March 6, 1899. Operation: Dilatation of the cervix and suspension of the uterus. A portion of the urachus was excised.

Path. No. 2961. The piece removed was 1.8 cm. long and varied from 2 to 3 mm. in thickness. On histologic examination the lumen of the urachus was found to be 1 mm. in diameter. It was lined with transitional epithelium two or three layers in thickness. The nuclei of the epithelial cells were round or oval, and stained uniformly. External to the epithelial lining was a varying amount of muscular and connective tissue, and surrounding the whole was adipose tissue.

**A Partially Patulous Urachus.** — Gyn. 6778. Mrs. S., admitted to Ward B, Johns Hopkins Hospital, March 2, 1899. During the course of the abdominal operation a portion of the urachus was removed. This piece was 1 cm. long and varied from 2 to 4 mm. in thickness.

Path. No. 3023. The small cord at first suggests a tube. It is tortuous, shows little projections into it; it is lined with one or sometimes two or three layers of epithelium and completely surrounded by non-striped muscle. Situated near the lumen is a small, gland-like space lined with cylindric cells. Scattered throughout the muscle are quantities of blood-vessels. In many respects it resembles the Fallopian tube more than it does a urachus, but at other points the similarity is not so marked.

**A Partially Patent Urachus.** — Gyn. No. 6792. G., Ward B. Operation: Hysteromyomectomy, drainage of gall-bladder, excision of a portion of the urachus.

Path. No. 3049. The portion of the urachus removed is in two pieces. The first (*a*) is 2.5 cm. long, 0.5 cm. in diameter, and removed from a point about 7 cm. above the summit of the bladder. *b*, the intervening part, is 7 cm. long and 1 mm. in diameter. In the first specimen there is a definite lumen 0.5 mm. in diameter, lined with two or three layers of cells of the transitional type (Fig. 229). The nuclei are oval or round and stain uniformly. Surrounding the lumen is fibrous tissue, a small number of non-striped muscle-fibers, and external to this adipose tissue. There is no doubt that we have here remains of the lumen of the urachus. In the portion near the bladder the lumen has been completely obliterated.

**Urachal Remains.** — Gyn. No. 6902. M., nineteen years old. Admitted to Ward B, Johns Hopkins Hospital, May 8, 1899. The operation consisted of hysterotomy, curettage, and resection of an ovary, together with excision of a portion of the urachus. The part of the urachus removed was 3.5 cm. long and from 3 to 8 mm. in diameter. These measurements included some of the surrounding adipose tissue.

Path. No. 3144. Microscopically, no trace of the lumen could be made out. In the center was a stroma consisting of bundles of non-striped muscle arranged longitudinally and surrounded by fibrous tissue; external to this again was a circular layer of muscle. In other words, this cord was made up entirely of muscular and fibrous tissue without any sign of a lumen.

**A Very Small Multilocular Urachal Cyst.** — Gyn. No. 8250. J. W., married, aged twenty-seven. Admitted October 24, 1900. The uterus was suspended for a retroflexion, and a cyst, supposedly of the urachus, was

removed. The cyst of the urachus was 3 x 5 mm. It was translucent and showed irregular, tiny, projections into the cavity, Fig. 230.

Path. No. 4441. The specimen was found to be a multilocular cyst, the loculi being large and small and apparently opening into one another. The epithelium in some places was cuboid. The nuclei of the epithelial cells were oval; they stained uniformly and were arranged parallel with the cyst-wall. Where the tissue was cut on the bevel, the epithelium appeared to be several layers in thickness and suggested squamous epithelium. The stroma between the cysts consisted essentially of non-stripped muscle-fibers separating the cyst proper from the sur-

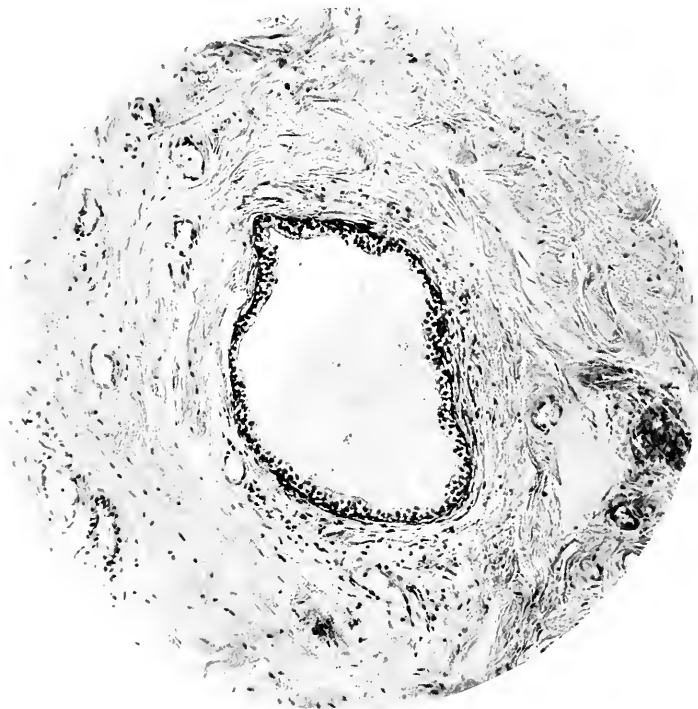


FIG. 229.—A PATENT URACHUS.

Gyn. No. 6792. Path. No. 3049. This portion of the urachus was in the mid-line, about 7 cm. above the bladder. The lumen is slightly irregular and contains some granular detritus. Lining the cavity is transitional epithelium, in some places only as a single layer, but at most points two or three layers thick. Surrounding the lumen is fibrous tissue in which some non-stripped muscle was recognized.

rounding fibrous and adipose tissue. This cyst was a remnant of the urachus. Whether the loculi all communicated with one channel or not it is difficult to say.

A Partially Patent Urachus.—Path. No. 3012. This patient was admitted to Dr. Kelly's sanitarium March 7, 1899. The operation consisted of an abdominal myomectomy and excision of the urachus.

Histologic Examination.—The lumen is found narrow and lined with two or three layers of columnar epithelium. External to the epithelium are bundles of longitudinal and circular muscle-fibers. The urachus is pervious.

Probable Cyst of the Urachus.—Gyn. No. 6815. Path. No. 3062. B., twenty-five years old. Admitted to Ward B, Johns Hopkins Hospital, April 8, 1899.

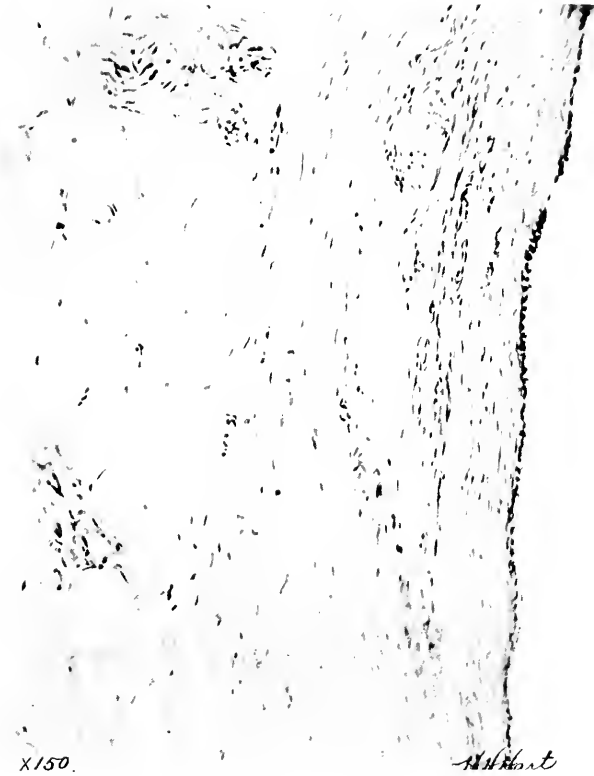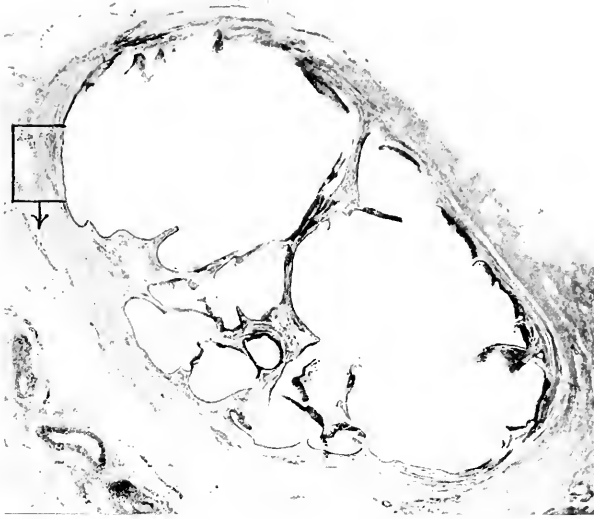


FIG. 230.—A MULTILOCULAR CYST OF THE URACHUS.

Gyn. No. 8250. Path. No. 4441. This cyst was 3 x 5 mm. and was translucent. As seen from the upper, low-power picture, it was composed of numerous loculi. Many of these seemed to communicate with one another. Surrounding the cyst, and separating it from the adipose tissue, is a definite wall. This consisted of fibrous tissue and non-stripped muscle. The small area of the cyst-wall, blocked off and indicated by the arrow, has been enlarged and is seen in the lower picture. The cyst is lined with one layer of cuboid cells.

Operation.—Exploratory laparotomy; excision of a small cyst from the anterior abdominal wall just above the symphysis. This cyst contained two small lumina, which appeared to be convolutions of the same tube. Each was lined with two or more layers of transitional epithelium. The nuclei of the epithelial cells were oval and stained uniformly, and the lumen was surrounded by non-striped muscle-fibers arranged circularly. External to these were parallel bundles of non-striped muscle-fibers embedded in fibrous tissue. It seems practically certain that they were remains of the urachus.

A Partially Patent Urachus. — Gyn. Path. No. 17025. While

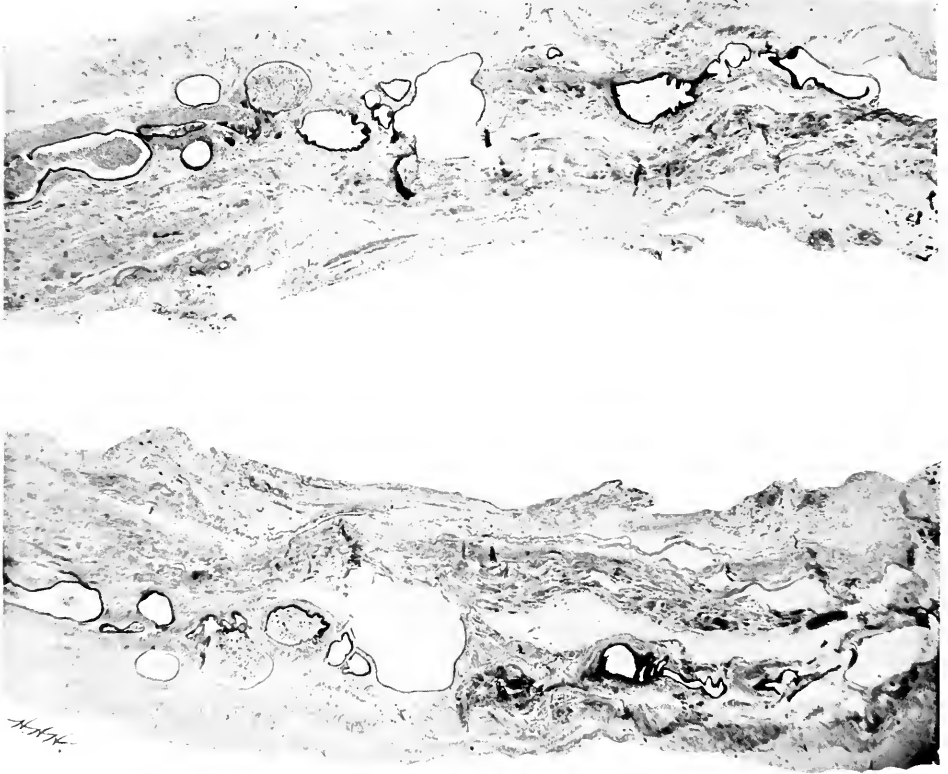


FIG. 231.—SECTION OF A PATENT URACHUS.

Gyn. Path. No. 17025. A longitudinal section of a portion of the urachal cord. The tube has evidently been tortuous, thus accounting for the longitudinal and transverse sections of the lumen. (For the high-power picture see Fig. 232.)

collecting the literature on the urachus I found, when operating on Mrs. M. E. at the Church Home and Infirmary, February 28, 1912, a urachal cord that seemed unusually large. Longitudinal sections of this showed elongate, irregular, and round cavities embedded in non-striped muscle and fat. The low-power picture is well shown in Fig. 231. One gathers the impression that the urachus consists of one tortuous and probably slightly branching tube. It will be noted that these spaces have a distinct lining and that some of them are filled with a definite substance. From Fig. 232 we learn that the spaces are lined with transitional epithelium. The contents of the cavities were in the main brownish yellow. The

small oval or spheric masses are swollen, exfoliated cells, which have taken up pigment granules. This was without a doubt a patent and slightly cystic urachus.

A Small Urachal Cyst. — Gyn. No. 21255. N. D., aged twenty-three, white, was admitted to the Johns Hopkins Hospital on June 4, 1915, complaining of severe abdominal pain and of backache. She was married and had had one child.




FIG. 232.—TRANSVERSE SECTION OF A PATENT URACHUS.

Gyn. Path. No. 17025. The cavity is lined with several layers of transitional epithelium. It contains a certain amount of débris. Surrounding the urachus is non-striated muscle.

After a careful examination it was found that she had a relaxed vaginal outlet and a retroposed uterus, chronic appendicitis, and gall-stones.

At operation Dr. J. Craig Neel, the resident gynecologist, repaired the perineum, brought up the uterus, removed the appendix, and emptied the gall-bladder of its stones. While making the median abdominal incision to bring up the uterus, he found a small cyst of the urachus in the mid-line (Fig. 233). This cyst was about

1 x 1.5 cm. in diameter, and seemed to be filled with clear fluid. The cyst and about 1 cm. of the urachus on each end of it were removed.

Gyn.-Path. No. 21256. Sections from the cyst wall show that it is composed in a large measure of connective tissue with here and there a little non-striped

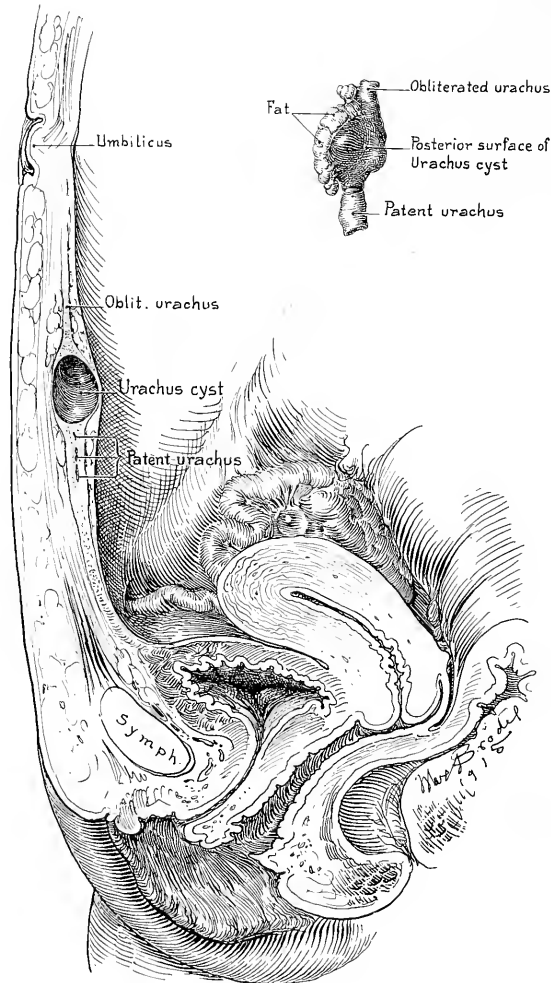


FIG. 233.—A SMALL CYST OF THE URACHUS.

Gyn. Path. No. 21256. This cyst was accidentally discovered when a median abdominal incision was being made. The cyst was located at a point midway between the umbilicus and symphysis. It was thin-walled, and above and below was directly continuous with the urachal cord. In the urachus just below the cyst were three slit-like openings—points at which the urachus was apparently still patent. The small drawing in the right upper corner of the picture shows the cyst after removal. The urachus above was obliterated; below, it was patent for a short distance.

muscle. The cyst is lined with one layer of almost flat epithelium. The wall in most places is smooth but here and there is slightly wavy.

The solid cord above the cyst consists almost entirely of connective tissue. The urachal cord is composed in part of connective tissue, but contains many bundles of non-striped muscle. The slit-like spaces noted macroscopically are devoid of any epithelium. There is no doubt that this cyst is of urachal origin.

## CHAPTER XXXII.

### LARGE URACHAL CYSTS.

Historic sketch.

Symptoms.

Differential diagnosis; personal observations on a large diffuse neuroma of the bladder.

Treatment.

Detailed report of large, non-infected urachal cysts.

THE small urachal cysts that we have considered rarely reached 1 cm. in diameter, and were naturally readily overlooked clinically. Probably one of the first urachal cysts ever opened was the one observed by Peü in 1648, and recorded in his *Pratique des Accouchements*, 1694, p. 38, and recently referred to by Wutz. The patient was a child two hours old. Situated at the umbilicus was a tumor the size of a pigeon's egg. It was opened, and a serum-like fluid escaped. This proved to be urine, and on the following morning urine escaped in a jet from the umbilicus.

Atlee, in 1873, in his treatise on Ovarian Tumors, reported the case of a girl eighteen years old. When opening the abdomen for the removal of an ovarian tumor he accidentally incised a urachal cyst containing an ounce of fluid resembling ordinary ascitic fluid.

Von Recklinghausen in 1902 demonstrated a polycystic tumor the size of a walnut which had been excised from a man thirty years old.

E. R. LeCount found a urachal cyst the size of an orange while making an autopsy on a man fifty-two years of age.

Interesting articles on urachal cysts have been written by Rippmann (1872), Wolff (1873), Scholz (1878), Schaad (1886), Tait (1886), Dössekker (1893), Douglas (1897), and others, and in 1906 the splendid monograph of Weiser appeared.

These cysts are naturally first noted in the mid-line between the umbilicus and pubes. They lie in the anterior abdominal wall just external to the peritoneum.

**Size.** — In the beginning they are relatively small, as in von Recklinghausen's, Atlee's, and LeCount's cases. As a rule, the increase in size is only gradual, but in a few instances the growth has been very rapid. They rarely extend above the umbilicus, but in some instances have reached as far as the xiphoid. Among the largest cysts are those recorded by Pratt and Bond, Macdonald, Rippmann, and Tait. In Pratt and Bond's case the cyst reached upward beneath the liver. Macdonald's patient had a markedly distended abdomen; it was firm and rather flat as far as the ensiform cartilage. In Tait's Case 1, 30 pints of fluid were evacuated at operation. Rippmann's was probably the largest on record. At autopsy the cyst was found to contain 52 liters of fluid weighing 100 pounds.

The cyst may or may not burrow beneath the bladder, and encroach on the vaginal vault. It is sometimes attached to the bladder by the urachal cord, and where the tumor has reached large proportions, it is usually adherent to the umbilicus.

The cyst-walls vary considerably in thickness. Some are very thin, others may be from 1 to 4 mm. thick.

The inner surface of the cyst is usually smooth. Sometimes coagulated cyst fluid clings to its walls. In Macdonald's case papillary masses were found springing from the inner surface of the cyst (Fig. 240, p. 559).

As these cysts are due to dilatations of the urachus, we should naturally expect to find them lined with transitional epithelium. When the cysts are small, the lining with transitional epithelium is often found, but in the large cysts, there not being enough to cover the whole surface, remnants of this transitional epithelium are often found only over certain areas on the cyst-wall. The walls are composed of fibrous tissue and contain a varying quantity of non-striped muscle. In Tait's Case XI calcareous particles were found scattered throughout the wall of the cyst.

**Cyst Fluid.**—The character of the fluid contained in urachal cysts varies considerably. Sometimes it is pale yellow and limpid, closely resembling ascitic fluid. In other cysts it is yellow and transparent or tenacious and ropy. The fluid may be of a pale-green color. In some cysts it is brown or of a chocolate color; or it may be thin and with a hemorrhagic tint. Whether the fluid be thin and clear, or dark and turbid, it often contains large clumps of coagulated lymph or fibrin. Such masses have been referred to by some writers as "necrotic lymph" or cheesy masses. They are strongly suggestive of the coagulated material often noted in ovarian cysts. The cyst fluid contains albumin and mucus. On histologic examination exfoliated squamous epithelium, fat-droplets, and cholesterol crystals are often noted.

#### SYMPTOMS.

**Sex.**—Of the cases of simple uncomplicated and non-infected urachal cysts here recorded, and in which we were able to obtain definite data as to the sex, 16 were in women and 5 in men.

**Age.**—The youngest patient was six years and the oldest fifty-four. The accompanying table furnishes the following data:

Six years of age . . . . .	1 case
Between ten and twenty years . . . . .	1 "
" twenty and thirty years . . . . .	1 "
" thirty and forty years . . . . .	7 cases
" forty and fifty years . . . . .	3 "
" fifty and sixty years . . . . .	2 "

The first symptom is usually enlargement of the lower part of the abdomen. This, as a rule, is in the mid-line, but the swelling, sometimes accompanied by pain, may first be noticed in the right iliac fossa, and the picture may strongly suggest an appendicitis.

With the increase in abdominal girth there may be a moderate degree of indigestion, and where the cyst has reached large proportions, there has been dyspnea. Some of the patients have become progressively emaciated and have lost in strength.

Micturition has been normal in some, frequent in others. It is but natural that the bladder should be markedly encroached upon in some cases, particularly as the excursus of the tumor is limited, on the one side by the peritoneum, and on the other by the anterior abdominal wall.

Pain has been a marked feature in some cases, absent in others. The pain is probably in a measure due to pressure on the terminal sensory nerve-trunks, owing



to the tension under which the cyst develops, confined, as it is, between the layers of the abdominal wall. But it must also be remembered that the cyst is separated from the abdominal contents only by a thin peritoneum, and consequently the slightest inflammation of the cyst-wall must readily extend to the peritoneum and not only produce pain, but also cause the omentum or some other abdominal structure to become adherent to the abdominal wall over the cyst. Such a condition was noted in Carroll's case, and also in one recorded by Doran.

On physical examination an abdominal swelling is noted. This may extend over the entire abdomen, or be limited to the lower portion. Although the tumor may be exceedingly large, there exists a certain amount of repression of the abdominal wall, due to the tonic contraction of the recti muscles. When the patient is anesthetized and the recti muscles are relaxed, instead of being board-like, the abdomen may become quite soft, and the cystic tumor can then be readily detected. If the abdominal walls are naturally tense, the difficulties in making an accurate diagnosis are augmented. In some cases definite fluctuation can be elicited.

#### DIFFERENTIAL DIAGNOSIS.

Urachal cysts have been diagnosed as a distended bladder, as ascites, as an appendicitis with abscess formation, as a cyst with or without twisting of the pedicle, as a localized peritonitis with a serous exudate under the anterior abdominal wall, and as a tuberculous peritonitis.

The distended bladder is readily emptied, and the ascites relieved by paracentesis. With the patient asleep, it is relatively easy to outline the cyst and to differentiate it by the absence of the induration, usually associated with an appendix abscess. Furthermore, with the abscess there is likely to be a history of an elevation of temperature and of a definite leukocytosis.

An ovarian cyst, whether mobile or twisted, lies much farther back in the abdomen and can be separated from the anterior abdominal wall, particularly when the patient is under narcosis. The differentiation from a localized peritonitis or from a tuberculous peritonitis is not so easy, particularly when the patient has become emaciated. Even in these cases, however, when the patient is asleep, the sharp outlines of the urachal cyst are readily distinguishable from the rather diffuse cystic accumulation occurring with a peritonitis. Again, in the case of a urachal cyst, moving it from side to side is likely to produce traction on the umbilicus. With an aspirating needle one can readily remove some of the cyst fluid and thus usually settle the diagnosis.

The following case that recently came under my notice is of such interest in connection with the differential diagnosis of urachal cysts that I shall report its salient features.

**A Tremendously Thickened Bladder-wall Producing a Tumor Reaching Almost to the Umbilicus and Simulating a Urachal Cyst.**—The great thickening of the vesical wall was due to a diffuse neuroma. I shall refer to this case very briefly, as Dr. Welch and I will report it in detail elsewhere.

Surg. No. 34093. P. B., a colored boy three years and seven months old, was admitted to the surgical service of the Johns Hopkins Hospital on March 9, 1914, for an ununited fracture of the left tibia and fibula. Dr. Heuer wired the ununited

fracture, and the boy made an uneventful recovery. When he entered the hospital it was noted that he had a firm mass extending upward from the symphysis to within 2 cm. of the umbilicus. This mass was broad below and rather narrow near

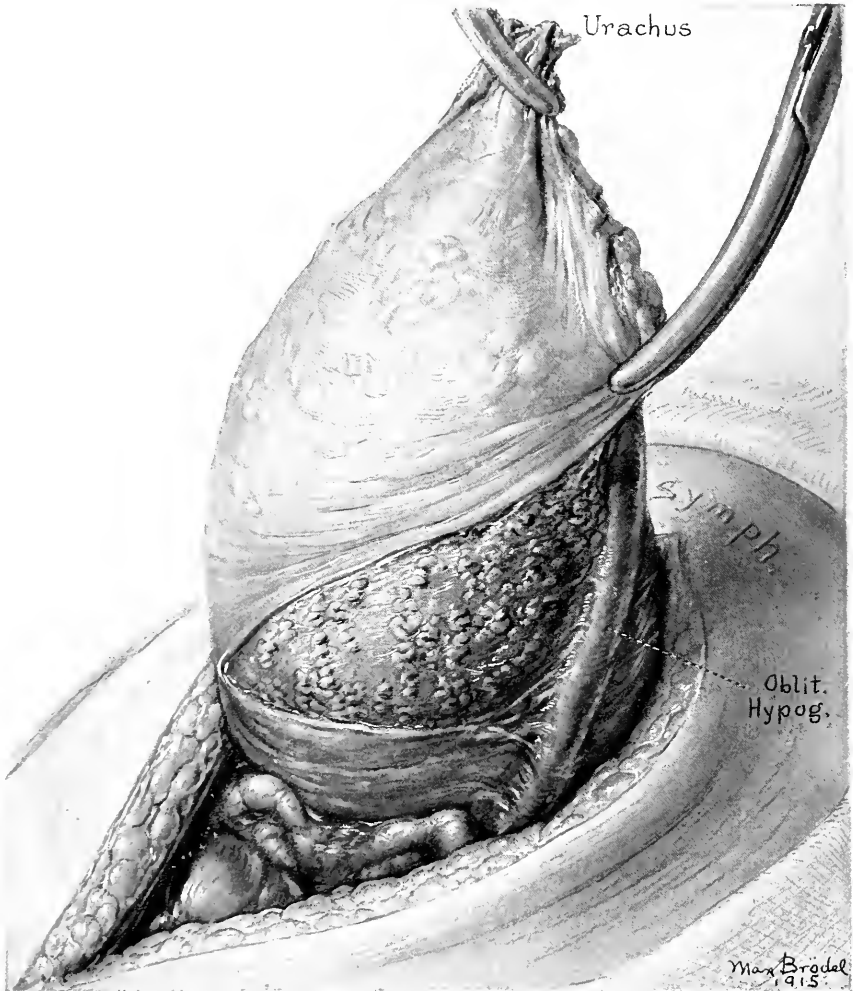


FIG. 234.—A DIFFUSE NEUROMA OF THE BLADDER. (After William H. Welch and Thomas S. Cullen.)

The picture shows the appearance of the bladder when the abdomen was opened. The contracted viscus extended almost to the umbilicus, was large and exceedingly hard, and even after it had been brought out of the abdomen, it was almost impossible to realize that it was the bladder. When the bladder was lifted up, it was found that the right ureter was 8 mm. in diameter. The left ureter was slightly enlarged. The surface of the bladder was covered with great congeries of what appeared to be small and tortuous vessels. These were noted at once, but were particularly well seen when the peritoneum was stripped back. Subsequent histologic examination showed that most of these tortuous cords were nerves. The remnant of the urachus was larger than usual. Not knowing at the time the unusual character of the growth, I cut into it and found that the tumor was caused by a tremendous thickening of the bladder-wall. For the appearance of the cut bladder-wall see Fig. 235; for the histologic picture see Fig. 236.

the umbilicus. Through the lax abdominal walls it could be readily grasped with the hand. Micturition was normal, and when the bladder was empty, this tumor diminished little, if any, in size.

It seemed to be a urachal tumor of some kind, and Professor Halsted, knowing

that I was much interested in urachal remains, kindly transferred the case to the Gynecologic Department.

Operation (March 28, 1914).—Feeling confident that we were dealing with a

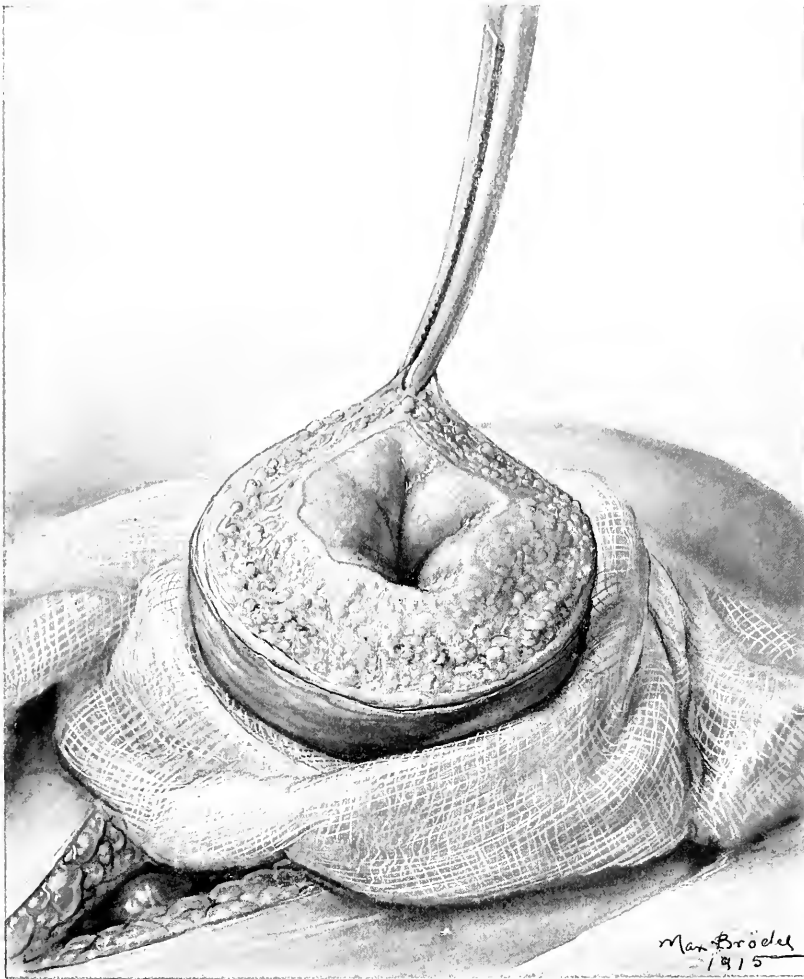

FIG. 235.—CUT SURFACE OF THE BLADDER SHOWING A DIFFUSE NEUROMA OF ITS WALLS.  
(After William H. Welch and Thomas S. Cullen.)

The figure shows the lower part of the bladder seen in Fig. 234, after the top had been removed. The bladder-walls protruded into the cavity, rendering it very small. The inner surface at this point was covered over with only a single layer of epithelium, which stained very faintly. All trace of the transitional epithelium was wanting in the sections examined. The bladder-walls in the portion removed varied from 1 to 3 cm. in thickness, and everywhere this coarse and tortuous texture was the striking characteristic. A low-power section through the bladder-wall showed an abundance of nerves on the outer surface. There was a muscular zone with nerve-bundles scattered throughout it, and an inner zone, varying from 1 to 2 cm. broad, consisting almost entirely of nerve elements. (See Fig. 236.)

urachal tumor, I made a median incision from the umbilicus to the symphysis, and at once encountered the tumor seen in Fig. 234. It was very firm, and over a large area was covered with peritoneum. Attached to its upper end was what appeared to be the urachal cord. Immediately beneath the peritoneum of the tumor were

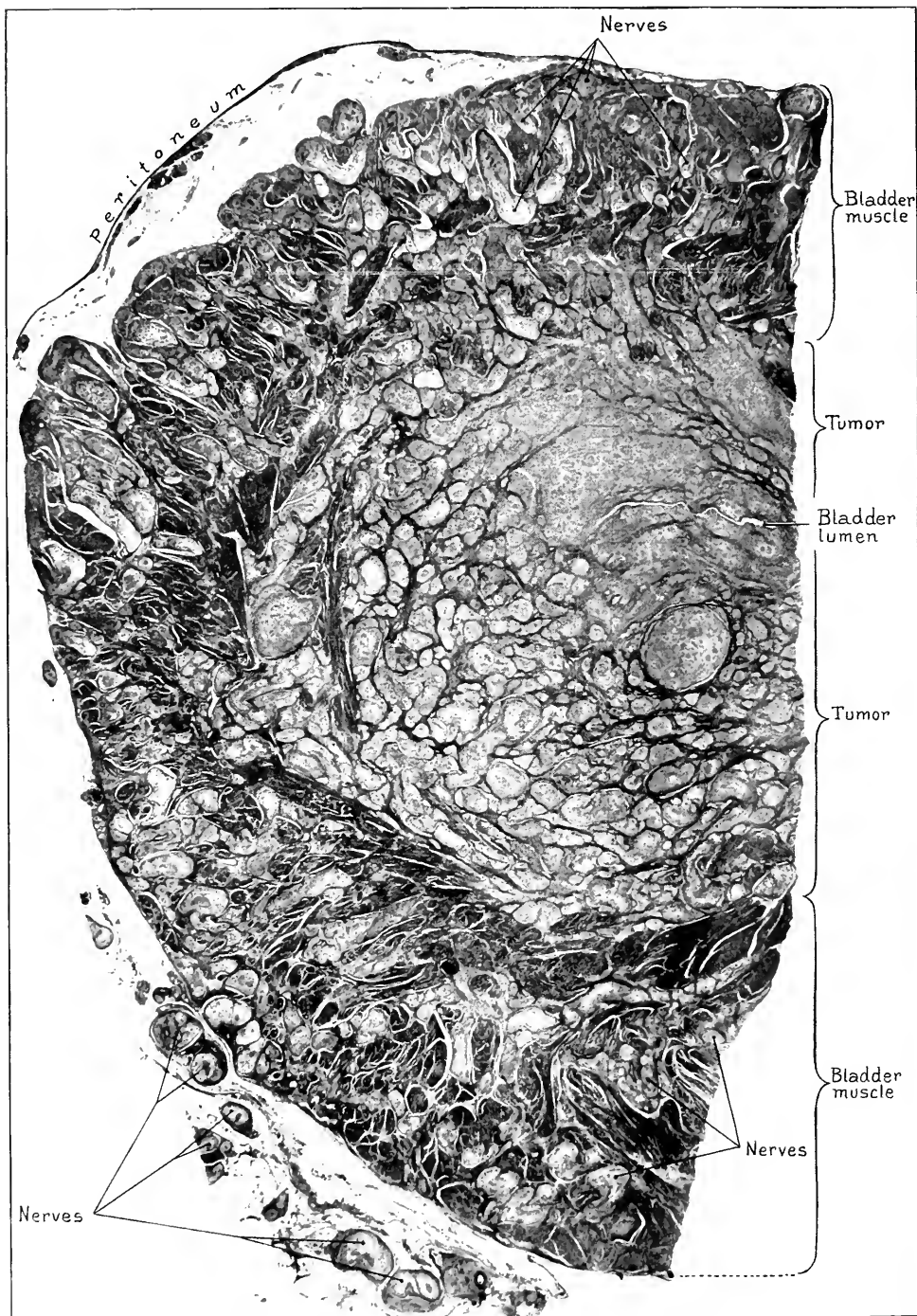


FIG. 236.—A DIFFUSE NEUROMA FORMING A MANTLE AROUND THE CAVITY OF THE BLADDER.  
(After William H. Welch and Thomas S. Cullen.)

Surg. No. 31093. Service of Professor William S. Halsted, Johns Hopkins Hospital. The section has been taken through the top of the bladder seen in Fig. 234. It embraces both walls of the bladder, and near the center the slit-like vesical lumen is visible. This photomicrograph shows numerous nerve-trunks on the outer surface of the bladder. The white areas scattered throughout the bladder muscle are also nerves. Surrounding the bladder cavity is a mantle composed almost entirely of nerves. This nerve zone varied from 1 to 2 cm. in thickness. The mucosa of the bladder in this vicinity was in most places reduced to one layer of epithelial cells that were cuboid or flat. (Iron-haematoxylin. Photomicrograph by Mr. Herman Schapiro.)

numerous small, tortuous cords. The obliterated hypogastric remains were unusually large.

The ureter on the left side was normal in size; that on the right, fully 8 mm. in diameter. It was evident that this tumor either lay as a cap on the top of the bladder or that it formed an integral part of the bladder-wall. After carefully walling it off, I cut into it and found that we were dealing with a greatly thickened bladder-wall. Fig. 235 shows the proximal portion of the wall on section. The inner surface of the bladder was thrown into folds, and its mucosa was exceedingly thin. The bladder-wall was markedly changed, being coarse in texture, due to the cross-section of many cords which emerged from the surface. Only near the peritoneal surface was there any semblance of normal bladder muscle. The walls of the bladder were approximated with considerable difficulty, and sutured, and a drain was laid down to the peritoneum. After the operation the boy did well for several hours; he then developed nausea, vomiting, abdominal distention, and tenderness; his temperature ranged from 100.4° to 103.8° F. and his pulse was very rapid.

On April 1st it was deemed advisable to do an enterostomy. He was given a few whiffs of gas, but died before any operative procedure could be carried out. Much to our regret no autopsy could be obtained, but the abdomen was sufficiently opened to see that peritonitis existed.

Examination of the portion of the bladder removed showed that its walls varied from 1 to 3 cm. in thickness, the extreme degree of thickening being more marked in the posterior vesical wall and at the top of the bladder. Wherever the thickening was marked, this very unusual and coarse appearance was noted.

Fig. 236 is a photomicrograph of a section taken through the top of the bladder. It embraces both walls and the lumen of the bladder. On the outer surface of the bladder are a large number of nerves. These represent the tortuous cords noted at operation. The muscular walls of the bladder are still well preserved, but penetrating here and there are large nerves. Separating the muscle from the bladder mucosa is a zone consisting entirely of nerve elements. In other words, surrounding the bladder cavity in this region is a mantle of nerve tissue varying from 1 to 2 cm. in thickness. We are indebted to Mr. Charles Miller, the technician in Professor Mall's department, for preparing many exquisite sections showing the appearances with the various nerve-stains. These findings will be reported in detail at a later date.

The bladder mucosa in the portion removed was in some places composed of several layers of transitional cells, but in most places the epithelium was but one layer thick and almost flat, and the nerves came up to and encroached upon the epithelium.

Had I, prior to operation, for a moment dreamed that this was not a urachal tumor, the bladder would have been at once filled with thorium and x-rayed. Knowing what we do now, we are not in the least surprised that such a bladder would be very slow to heal after being incised. The broad inner zone consisted almost entirely of nerves, and in addition had a very meager blood-supply.

This is the only bladder tumor of this character with which we are familiar; a mistake in diagnosis of this kind will rarely occur.

## TREATMENT OF URACHAL CYSTS.

A median incision, commencing just below the umbilicus and extending to the pubes, will be sufficient to expose a urachal cyst of moderate size. As soon as the recti muscles are separated, the cyst will come into view. Sometimes it is infected and shows signs of inflammation. It is usually loosely adherent to the peritoneum, and can be readily shelled out. Sometimes it is rather firmly adherent to the posterior surface of the bladder. In those cases in which the urachus is rather thick and passes directly into the cyst, it is well to treat it as a pervious cord and to ligate it with Pagenstecher thread and cover this in turn with catgut, to prevent the possible development of a urinary fistula in the lower angle of the abdominal wound.

If the urachal cyst extends upward beyond the umbilicus, it is wise, when making the abdominal incision, to encircle the umbilicus, as this is often adherent to the cyst and should be removed with it.

In some cases it has been found possible to remove the cyst without opening the abdominal cavity. In others the cyst had become adherent to the omentum, and it was necessary to liberate the omental adhesions before the tumor could be removed.

When the cyst is exceptionally large, the peritoneum has of necessity been widely separated from the anterior abdominal wall. After operation the normal intimate relation is usually restored, but that this does not always happen is evident from Douglas's case. After drawing off 25 pints of clear fluid, Douglas readily separated the cyst-wall. The area of peritoneum separated from the parietes extended from about three inches above the umbilicus to the symphysis. It was observed that the peritoneum sank away from the parietes, but, thinking that when the abdominal wound was closed the intra-abdominal pressure would bring it into apposition with the abdominal wall, Douglas made no effort to stitch it there. The abdominal wound was closed in the usual manner and a firm compress was applied. The patient left the operating room in a remarkably good condition. Twenty-four hours later her temperature was 99.4° F., her pulse 136, respirations, 30. She was nauseated, vomited slightly, and there was some epigastric distention. She became dull and roused only when vomiting. Her condition rapidly grew worse, and she died forty-six hours after operation.

At autopsy the entire detached peritoneum on the right side was found to be gangrenous. There had been no hemorrhage, but there was a little effusion between the peritoneum and abdominal wall. The peritoneal cavity contained a little brown serous effusion, but no pus or lymph.

Tait also reported a death in one of his large cyst cases. The cause could not be ascertained, as no autopsy was obtainable.

As a rule, non-infected urachal cysts can be removed with little danger. If very large, it may in rare instances be advisable merely to drain them and allow the sac to contract down gradually. It can then be removed with less danger of injury to the peritoneum. On the other hand, the adhesions at the second operation are liable to be much denser.

Where the peritoneum has been widely denuded, it may be tacked to the abdominal wall with several delicate catgut sutures; or one or two delicate protective drains may be carried down to the peritoneum, not only providing for the escape of any slight amount of fluid that may accumulate, but also allowing the air to escape and tending to make the abdominal walls flatten down on the peritoneum.

## DETAILED REPORT OF LARGE, NON-INFECTED URACHAL CYSTS.

This list includes those cases in which little or no infection existed. Tait, in his article published in 1886, recorded a relatively large number of cases. The majority of these and some others were rather indefinite and have purposely been omitted.

The cyst in Schaad's case was probably urachal in origin, but it was lined with high cylindric epithelium; and as glands opened into it, its origin from remnants of the omphalomesenteric duct cannot be absolutely excluded.

**A U r a c h a l C y s t .** — Atlee,\* on opening the abdomen for the removal of an ovarian tumor in a girl eighteen years of age, found a urinary pouch in the linea alba. This he accidentally divided with the knife. The abdominal walls were very thick, vascular, and remarkably muscular. Between the muscle and the peritoneum he opened a small cyst from which about one ounce of yellowish liquid, resembling ordinary ascitic fluid, escaped. The posterior wall of the sac was cut through and the peritoneum opened. There were no adhesions. The bladder occupied the normal position. On the sixth day the dressings were moist, and by the end of a month Dr. Fay, who looked after the case, felt sure that the fluid was urine. The patient was advised to empty the bladder frequently, and the discharge soon ceased.

“The only conclusion possible was that we were dealing with a dilated urachus, which, although closed at the umbilicus, had from birth maintained a communication with the bladder.”

**A U r a c h a l C y s t .** † — “I. F., aged six years; Newcomerstown, Ohio. Physician, Dr. Hosick. The patient had been taken suddenly sick about three weeks before. The pain seemed to be in the neighborhood of the appendix, but somewhat below McBurney's point. Slight elevation of temperature. Thighs flexed. Amount of pain quite variable. Bowels regular. No appetite. A little before she came to the hospital the abdomen became much distended and painful. Pulse more rapid. Temperature, 100° F. The presumptive diagnosis had been appendicitis with enormous abscess formation. When the patient reached the hospital (May 7, 1911), the abdomen was considerably distended and tender throughout, and with distinct fluctuation. There was perhaps a little more tenderness in the appendix region than elsewhere, but this was not marked. Diagnosis, very doubtful, but the case clearly one for exploration.

“When the patient was under the anesthetic I could determine nothing more about the case. No lump in the region of the appendix. Made the usual median incision. As soon as the incision was made there was an escape of a large amount of rather thin, yellow, odorless fluid. The opening was enlarged, and the cavity thoroughly flushed out, the water bringing out a large amount of what seemed to be necrotic lymph. The cavity was found to be bounded below by the pelvis, above by probably the transverse colon and the stomach. It extended on each side clear to the flanks. The intestines were crowded back by the posterior wall of the cyst. The uterus in this case could be readily felt, though infantile in size, below the membrane. Introduced drainage, with partial closure of the incision. The patient made a smooth convalescence and returned home in the usual time, with distinct warning as to the probability of a hernia.

\* Atlee, Washington L.: *Ovarian Tumors*, Philadelphia, Lippincott, 1873, 50.

† Baldwin: *Large Cysts of the Urachus*. *Surg., Gyn. and Obst.*, 1912, xiv, 636.

“September 3, 1911, patient returned with her mother because they had noticed a beginning hernia. The hernia was operated upon the next day. I made an incision directly through the old scar, dissecting down very cautiously, as I expected to find extensive adhesions. On finally opening the peritoneum I found that the abdominal contents were in every respect absolutely normal, except for two cobweb adhesions of the omentum to the anterior abdominal wall. The appendix was brought up and found to be entirely normal; was removed on general principles. Pelvic organs normal. In fact, had one not familiar with the previous history of the case made the operation, he would have found nothing whatever to suggest any previous trouble in the abdomen. In other words, the sac had absolutely disappeared. The bladder, however, seemed to be a little higher up than usual, though even that was not positive.”

**Large Urachal Cysts.**—Dr. Bantock\* said he was sure he was expressing the sentiments of every one present when he desired to offer the thanks of the Society to their President [Lawson Tait] for the very remarkable and interesting paper which he had just read. The cases were of remarkable interest, but he feared there was no one who could discuss the subject from experience. The paper was one for future perusal and careful study. He at least was not prepared to discuss it, but he thought he might refer to two cases of which he was reminded by some of the cases related by the President.

The first case was that of a married woman, aged thirty, the mother of two children. On dividing the parietes, Bantock opened into a cyst containing 25 pints of a thick, grumous fluid, with a very decided biliary tinge. When the whole of the fluid was removed, the cyst was found to be unilocular, and looking down into the pelvis was like looking into one's hat, so completely did the walls of the cyst line the pelvic cavity. After separating what appeared to be cyst-wall from the parietes on each side, and cutting away what was thus separated, recognizing the hopelessness of proceeding further, he washed out the cyst with a solution of iodine and closed the wound, leaving a drainage-tube passing down to the bottom of the pouch. Although the separation of what was taken as cyst-wall was carried beyond the umbilicus, the peritoneal cavity was not opened. A thick, pultaceous fluid of the color of mustard came from the cavity for many weeks, but the patient was discharged quite well at the end of about two months. Bantock had lately seen this patient in perfect health. He adds that the source of the brilliant yellow color of the discharge was still a puzzle to him.

The second case was that of a married woman, thirty-seven years of age, the mother of three children. The history told that she was taken ill on January 10th with violent sickness and pain all over the stomach. She was laid up and became feverish; the pain being severe for five days and the sickness for two days. The abdomen gradually got larger, and about the end of February she was tapped of rather more than half a gallon of a thickish, pale-yellowish fluid. In about a month more she was tapped again to the extent of three pints of a thicker fluid, and recommended to apply poultices. Shortly after this the puncture-hole opened and discharge came away. She then presented herself at the out-patient department of the Samaritan Hospital, under the care of Dr. Amand Routh, with whom Bantock saw her. There was then a fistulous opening about two inches below the umbilicus, in the middle line, and an ordinary surgical probe passed in for its whole length. She

\* Bantock: From Tait's article, *Brit. Gyn. Jour.*, 1886-87, ii, 348.



was admitted into the hospital on July 20th, and Bantock thought he had to deal with a multilocular tumor of which a central cyst had suppurated, as on withdrawing the probe no discharge followed. On July 27th he divided the parietes by a double elliptic incision, with the view of cutting out the fistulous tract, and was not a little surprised to find, on completing the division on one side, that he had opened directly into a unilocular cyst containing from three to four pints of a purulent-looking fluid. On further examination he found the same condition of things as in the first case, and, recognizing the inadvisability of proceeding further, he thoroughly washed out the cavity with plain warm water and closed the wound, leaving in a glass drainage-tube. The patient presented herself at the hospital two or three weeks before the meeting of the society and was in perfect health. In this case the uterus was low down, pressed forward, and fixed. Bantock said that he was as much at a loss to explain the relations and origin of this cyst as in the first instance, but he thought they were worthy of being related in connection with the very remarkable cases read by the President.

**P r o b a b l y a U r a c h a l C y s t .** — Bryant,\* in discussing Doran's paper, reported two cases. In Case 1, on operating on what had been diagnosed as an ovarian cyst, he suddenly opened into a cyst from which serosanguineous fluid escaped. This was in front of the peritoneum, and was with difficulty separated from the bladder. When this had been done, the cyst came away in his hand, and it was clear that it had no pedicle nor any connection with the broad ligament.

**A C y s t i c U r a c h u s .** — Carroll's† patient was a woman thirty-four years old. She had been well until twenty-three. After that she had had attacks of abdominal pain, loss of weight, and on one occasion inflammation of the bladder.

On examination an induration was found extending from the umbilicus two to three inches to the right, and downward for three or four inches. The tumor was apparently too near the umbilicus to be of appendiceal origin.

Roswell Park made a median incision below the umbilicus. The tissues were very dense and difficult to cut. A sac was opened and fluid escaped. The incision was enlarged, and a finger introduced. The tumor was found to be a cystic urachus. A connection with the bladder could be traced, but a probe could not be passed. The connection was tied off and the cyst dissected out. There were a number of adhesions between the tumor and the omentum. The patient made a good recovery. "The probable explanation of the attacks seemed to be an oozing of urine into the upper or cystic part of the urachus, and as there was no egress for the fluid once gathered, it was absorbed into the system, causing a toxemia."

**A L a r g e C y s t o f t h e U r a c h u s . ‡** — The patient was a girl, twenty years of age. The tumor had first been noticed a year before admission. It had increased greatly in size in the last four months. It had commenced as a painful point in the right iliac fossa. On account of the patient's emaciation and the increase in abdominal girth the physician had diagnosed tuberculous peritonitis. On admission there was great abdominal distention, evidently due to fluid.

**Operation.**—An incision was first made as far as the umbilicus, and was extended upward to the xiphoid. The tumor was adherent at the umbilicus. The pedicle was attached to the summit of the bladder. It had no lumen and did not open into

\* Bryant, T.: *Brit. Med. Jour.*, 1898, i, 1390.

† Carroll, Jane W.: *Buffalo Med. Jour.*, 1895-96, xxxv, 869.

‡ Cotte et Delore: *Gros kyste de l'ouraque*. *Lyon méd.*, 1905, cv, 373.

the bladder. The uterus, tubes, and ovaries were normal. The cyst was unilocular and contained between eight and nine liters of brown, hemorrhagic fluid. This was not examined microscopically. The inner lining of the cyst was made up of inflammatory tissue. On the cut surface the urachus was recognized as a cord. The authors say that the cyst had developed from the urachus. The patient made a good recovery.

**A Urachal Cyst Simulating an Appendicular Abscess.** \*—“The patient, aged seventeen and a half years, unmarried, applied to Dr. R. Drummond Maxwell at the out-patient department of the Samaritan Free Hospital on July 16, 1908. She complained of tenderness and swelling in the right iliac fossa, associated with a history of a sudden attack of pain in that region a month previously, and she was admitted into my ward at once. After admission I found that the relations of the swelling to adjacent organs could not well be defined until I examined the patient with the aid of anesthesia, under circumstances presently to be explained. The patient's mother informed me that the catamenia were established at the age of fourteen years, without pain or constitutional disturbance. The periods were always scanty and attended with very little pain, and the interval was about five weeks. The patient had never suffered from any neurosis before, at, or after puberty. On June 16th, one calendar month before admission, the menstrual flow appeared as usual, but was accompanied by violent pain never experienced before. The pain continued for two days and then it abated. The patient at once resumed her work, but the pain returned two days later and obliged her to take to her bed again. During the whole of the week before admission she was quite incapable of attending to her duties. Roughly speaking, as regards what could be made out before anesthesia was employed, there was a fairly defined, almost spheric swelling in the right iliac fossa, slightly movable and tender to the touch. There was resonance on percussion over its outer aspect. The lower part of the swelling could be defined on rectal examination. I refrained from making a vaginal exploration until a consultation was held. Then it was found that the vagina was barely two inches deep. A kind of dimple could be defined at the blind extremity toward the right. The tumor did not bulge into the vagina. At the lower limits of the swelling was a tuberosity which lay behind the vagina and in front of the rectum. The temperature and pulse were low. The patient had never been laid up with any severe illness. Before the arrested development of the vagina had been detected, appendicular abscess was suspected, but after the examination, hematometra or hematosalpinx seemed equally probable. On July 21st the period began, as usual, about five weeks after that which had preceded it. I found that there was no palpable increase of pain or tenderness in the tumor nor any appreciable increase or decrease in size. The flow was unusually free. I decided to examine the patient under anesthesia during the period in order to discover the channel which transmitted the menstrual blood into the vagina, and for other manifest reasons.

“Examination under Anesthesia.—The perineum was markedly deep, so that the anterior commissure lay far forward. The labia, clitoris, and meatus urinarius were normally developed. There appeared, on the other hand, to be no hymen nor was there the least trace of carunculae.”

“The vagina formed a blind pouch about two inches deep. The rugæ were prominent.

\* Doran, Alban H. G.: *The Lancet*, 1909, i, 1304.

“The vaginal pouch was distinctly deeper on the right side, whence dark menstrual blood was seen to issue. On stretching the adjacent mucosa with the fingers, a crescentic fold with the concavity toward the left was detected. It covered the aperture whence proceeded the blood. A uterine sound could be passed into this aperture and pushed onward for three inches upward, backward, and a little to the right, closely following the outer limits of the lower pole of the swelling, as could easily be defined on digital exploration from the rectum (Fig. 237). On bimanual palpation the swelling was found to be a well-circumscribed tumor, firm, pushed a little downward, yet even then its lower pole did not bulge into the vagina, but passed behind it. The tuberosity in the rectovaginal septum, discovered at the previous examination, lay to the left of the menstruating tract. It felt like a small cervix. The nature of the case remained obscure. I kept the patient at rest for a week. The period ceased, and the tumor remained stationary. There was one sharp attack of local pain on July 28th, without any rise of pulse or temperature.”

“Operation.—On July 29th I operated with the assistance of Dr. R. V. G. Monckton, Dr. S. H. Belfrage administering ether and chloroform. I made an incision in the middle line. The parietes were unusually vascular. After separating the recti I came across a thick membrane of doubtful character, and lower down I exposed the wall of the bladder, which extended for quite two inches above the pubes. The membrane was cut through, and about half a pint of a perfectly clear fluid was removed; unfortunately, none was preserved. The fluid lay in a cyst behind the recti and anterior to the parietal peritoneum, the membrane through which I had made the incision being the anterior portion of the cyst-wall. The cyst was connected with the bladder by a thick cord half an inch in length. The upper limits of the cyst lay close below the umbilicus. In exploring the upper end of the tumor I laid open the peritoneal cavity. The omentum adhered to the peritoneum, investing the back of the cyst in this region. The intestines seemed healthy; there was no evidence of tuberculous disease, no free fluid, and no intraperitoneal tumor. Lower down some coils of ileum adhered to the parietal peritoneum behind the tumor. “I endeavored to define the relations of the cyst to the genito-urinary tract. A catheter was passed into the bladder, and a few ounces of urine were drawn off. There was no communication between the cavity of the bladder and the cavity of the cyst; the thick cord between the two was clearly a portion of the urachus, and I observed that it ran into and not over the cyst-wall.

“As might have been suspected from what could be defined before the operation, the cyst lay to the right of the middle line. On pressing against its wall on the right inferiorly, from the inner side I detected a fusiform body like a uterine cornu or a small but entire virgin uterus, lying in the position of the menstruating tract along

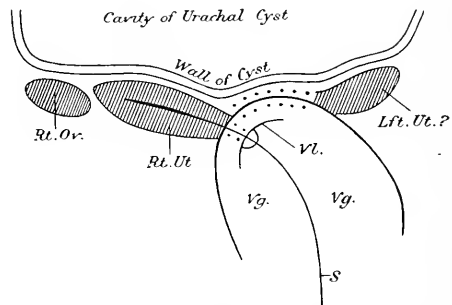


FIG. 237.—DIAGRAM SHOWING THE ARRESTED DEVELOPMENT OF THE GENITAL TRACT AND THE RELATION OF THE MALFORMED PARTS TO THE CYST OF THE URACHUS. (After A. Doran.)

*Vg.*, vagina, its blind end rising higher on the right side than on the left; *Vl.*, valvular fold, through which a sound (*S*) passes into *Ru. Ut.*, the right cornu; *Ov.*, right ovary; *Lft. Ut.*, solid body, probably left cornu; the dotted lines indicate a band, not clearly definable, connecting it with the right cornu.

which a sound had been passed a week before. Above this body thickened tissue could be felt—apparently a small ovary. The tuberous, cervix-like body already mentioned could be plainly defined through the walls of the lowest part of the cyst. When thus explored, it was found to be a distinct, fairly movable structure—the left ovary or uterine cornu. On further palpation through the cyst-wall the pelvic cavity felt quite free from any tumor or deposit. There certainly was no such thing as a collection of retained menstrual blood.

“At this stage of the operation it became evident that the swelling, which disappeared entirely when I opened the cavity full of fluid, was a urachal cyst. The swelling—in other words, the cyst—had been the cause of all the patient’s recent trouble. As there was no trace of a hematometra or hematosalpinx, I did not feel justified in dissecting in the dark behind the cyst, amid deformed structures, in

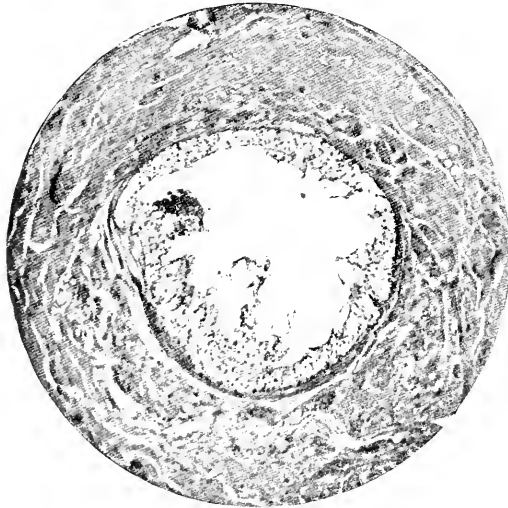


FIG. 238.—SECTION OF THE SEGMENT OF URACHUS WHICH PASSED BETWEEN THE BLADDER AND THE CYST-WALL, AS SEEN UNDER A LOW POWER. (After A. Doran.)

The canal is quite unobstructed and lined with transitional epithelium; the muscular coat is very thick. (In our reproduction part of the detail has been lost—T. S. C.)

very uncertain relations to ureters, blood-vessels, etc., merely to make out the extent of arrested development of the uterus and appendages. It was with the cyst, therefore, alone that I had to deal. I knew of several objections to the draining of a urachal cyst, nor could I dissect away its outer wall, since, as I have just observed, its positive relations to malformed structures were very uncertain. For these reasons I simply trimmed away as much of the lining membrane as could be safely removed. Then I cautiously passed several fine cat-gut sutures along the substance of the outer wall and tied them, so that the cyst cavity was closed in. This outer wall was the muscular sheath of the urachus abnormally thickened, so that the manœuvre just described was easy and nothing was caught up behind the cyst. I transfixed the segment of the urachus, which ran between the lower limits of the cyst and the bladder, with a fine linen suture and tied it on both sides. It was then divided between the cyst and the ligature. As will be explained presently, it is fortunate that I transfixed the urachus instead of tying a single ligature around it as though it were an artery. I kept the portion attached to the cyst for microscopic examination. Lastly, the sheaths of the recti were united with interrupted fine linen sutures and the integuments closed with interrupted silkworm-gut.

“During the summer vacation Dr. Maxwell took charge of the patient in my absence. He reported that up to the day of her discharge at the end of August there was no sign of leakage of urine through the wound nor any show of blood.”

Microscopic Examination of the Cord Between the Cyst and the Bladder.—A section of the cord-like structure which ran on the surface of the parietal peritoneum

between the fundus of the bladder and the cyst was made at the Royal College of Surgeons of England. There could be no doubt that it was a portion of the urachus. Mr. S. G. Shattock reported that the canal was quite patulous and lined with perfect transitional epithelium of the bladder type. The lumen was free from catarrhal or other morbid products. The muscular coat was abnormally thick, but showed no evidence of inflammation or edema. Its inner portion was mostly made up of circular, and its outer portion of longitudinal, fibers, but there was some irregularity in the direction of the fibers in both portions. Some subperitoneal fat was intimately connected with the periphery of the urachus. The appended reproduction of a photomicrograph (Fig. 238) shows the above-described appearance of the urachus as seen under the microscope.

On p. 635 I have recorded another interesting case of Doran's—a cystic sarcoma of the urachus.

**A Large Cyst of the Urachus.**—Dössekker\* reports the case of a woman, born in 1850. When forty years of age a tumor the size of a small fist was found to the right of the uterus. She had various abdominal symptoms, and finally was sent to a sanitarium. When forty-two years of age she was admitted under the care of Krönlein. She looked very pale. The abdomen was markedly distended, as with a pregnancy at the ninth month. There was, in addition, a distention at the umbilical region, with definite fluctuation. The diagnosis made was ovarian cyst, possibly from the right side, with hemorrhage into the cyst, and probably torsion of the pedicle.

**Operation.**—An incision was made from the umbilicus to the symphysis. As soon as the abdominal walls were cut through the knife entered a cyst cavity. The wall of the cyst was intimately attached to the abdominal wall, and a large quantity of thin, hemorrhagic fluid escaped. This was not sticky and had no odor. It amounted to between three and four liters. The tumor was gradually shelled out, with little or no hemorrhage, and the abdominal cavity proper was not opened. The cyst did not extend into the pelvis, but reached as far as the top of the bladder. At no point was the peritoneum opened. In other words, the large cyst with its contents lay between the abdominal wall and the parietal peritoneum. The patient made a splendid recovery. Examination later showed that the uterus and left ovary were normal. The right ovary could not be outlined.

Dössekker, after discussing the various points of interest, says that on histologic examination the wall was found to consist chiefly of dense connective tissue. The inner surface in most places was without any epithelial lining, but at some points this was intact. It consisted of a high, many-layered, so-called transitional epithelium. The basal nuclei were elongate or oval; the peripheral were more roundish or flat in form. The epithelium corresponded in character to that of the bladder, and agreed with the description given by Luschka of the epithelium lining the canal of the urachus.

**A Cyst of the Urachus.**—On page 182 Douglas† describes the case of "Mrs. C., aged thirty-six, married eleven years, but sterile. The family and personal history is good; she has always enjoyed good health, but has never been robust. Menstruation has been scanty and painful, but regular; she has suffered with con-

\* Dössekker: *Klin. Beitrag zur Lehre von den Urachuscysten. Beiträge z. klin. Chir.*, 1893, x, 102.

† Douglas, Richard: *Trans. Amer. Assoc. of Obstet. and Gynecologists*, 1897, x, 177.

stipation, but the kidneys have acted freely and normally until recently. About eighteen months ago she observed a swelling in the lower portion of the abdomen, rather more prominent on the right side. The enlargement was soft and painless. It grew slowly and did not materially show until the last four months, within which time its growth has been rapid, chiefly to the right side. She has suffered from backache, some loss of flesh, slight cough, and decided digestive disorders. There has been but little pain or tenderness from the tumor, and no history indicating local peritoneal inflammation. The bladder has been somewhat disturbed, its action frequent, but the urine normal. She now complains more particularly of vomiting after eating and a sense of weight and heaviness in the epigastric region. Of late she has grown nervous and suffers from insomnia."

"Physical Examination.—The abdomen presented a very peculiar appearance. It was symmetrically distended to about the size of a seven months' pregnancy, the greatest enlargement being on the right side; the veins were not enlarged, the skin was white and anemic-looking. By palpation the irregular swelling could be outlined. The tumor seemed to lie in the lower zone and the right half of the abdomen. It was soft, elastic, fluctuant and compressible. It was not movable; there were no irregularities or bosses upon it; its surface was smooth; palpation was painless; the abdominal walls did not appear to glide freely over the surface of the tumor. There was dulness upon percussion over the entire tumor, yet that dulness, as was repeatedly remarked during examination, was not the characteristic flatness noted in ovarian cystoma. The dulness was absolute low down, but in the region of the umbilicus and beyond, the note became more resonant. Auscultation negative. Vaginal examination showed the uterus small, retroflexed, and rather low in the pelvis; vaginal vault encroached upon by an elastic, fluctuant swelling. The weight of the evidence was in favor of the diagnosis of ovarian cystoma. The following peculiarities, however, were remarked upon, and were of such importance in our judgment as to render questionable the nature of the case. The appearance of the abdomen was not such as is usually noted in ovarian cystoma. While, of course, we appreciate that the shape of the abdomen varies greatly, yet in a cyst so distinctly unilocular as this appeared to be, and lying so superficially, one would expect to find the abdomen rising abruptly from the symphysis; that is, the tumor forming a distinct angle with the abdominal plane. In this case the abdomen looked more like one distended by ascitic fluid, rather flat upon the upper surface, and widely bulging upon the right flank. The next peculiar physical sign was the character of the percussion dulness.

"Operation.—An incision was made in the middle line, and in going through the linea alba and transversalis fascia I came upon the red, congested cyst-wall, which I at first thought was the peritoneum inflamed. I now aspirated the cyst and drew off 25 pints of clear fluid. An examination of the collapsed sac soon convinced me that I was not in the peritoneal cavity, and that I was dealing with a cyst of the urachus. Its attachment was not very intimate, and its enucleation was readily accomplished. Only slight hemorrhage attended its separation. As I removed the sac I recognized that I was working entirely outside of the peritoneum. The viscera could be felt through the peritoneum. The sac dipped down into the true pelvis in front of the uterus, depressing and retroflexing it. There was no apparent attachment of the sac of a ligamentous character to the bladder. Indeed, the cyst lay between the peritoneum and the transversalis fascia, with no special attachment

beyond a universal adhesion to all surrounding parts. The area of the peritoneum separated from the parietes extended from about three inches above the umbilicus to the symphysis, and from two inches to the left of the linea alba and through the lumbar and iliac regions of the right side. As there was no bleeding of consequence, we now prepared to close the abdominal wound. It was observed that the peritoneum sank away from the parietes, but thinking that, when the abdominal wound was closed, the force of intra-abdominal pressure would bring it in apposition with the wall, no effort was made to stitch it there. The abdominal wound was closed in the ordinary way. A good compress was applied over the abdomen, and a snugly-fitting bandage adjusted.

“The patient sustained but little shock from the operation and was placed in bed in remarkably good condition. The fluid removed measured 25 pints, was of a pale green color, and a few flocculi were observed in it. I regret to say that it was carelessly thrown away without being submitted to chemical and microscopic tests. The sac was composed of a thin, fibrous material, showing no evidence of muscular structure, and almost transparent; it was removed without tearing.

“The patient was operated upon on June 20th at 11 o'clock. Twenty-four hours after the operation the pulse was 136, respiration 30, temperature 99.4° F. She was nauseated and had vomited slightly; there was some epigastric distention; she had slept but little; the bowels had not moved, although active efforts were employed; the kidneys had acted sufficiently, 36 ounces of urine having been voided since the operation. The patient now became very dull, inclined to sleep, was roused only when vomiting; the vomiting was of regurgitant character, without apparent effort; the matter ejected had that ugly green color that we so much dislike to see. Her condition grew rapidly worse, the pulse became more frequent, the temperature reached 102° F. She died at 10 A. M., forty-six hours after operation.

“Autopsy.—The entire detached peritoneum on the right side was gangrenous. There was no hemorrhage, and but very little effusion between the peritoneum and wall. There was a little brown, serous effusion in the peritoneal cavity, no pus nor lymph. Death was due undoubtedly to sapremia. The detached peritoneum was not forced against the abdominal wall, as I had supposed it would be, but hung loosely, leaving quite a space between. This peritoneum was deprived of its nutrition, and had simply died from starvation.”

Cysts of the Urachus. \* — Ferguson says: “I do not feel, however, as has been stated by Tait, that extraperitoneal tumors in that region are all derived from the urachus. Tait's dictum was based on two cases submitted to operation, both of which resulted in death, in neither of which was there a postmortem examination, and in both of which the reported character of the cystic contents would justify the hypothesis entertained by some that cysts originating in the pelvic region may develop upward and forward in such a manner and way as to separate the peritoneum from the anterior abdominal wall, and thus become extraperitoneal. It is my conviction that I have seen at least one case of that character—one which grew to great dimensions and was cured over twenty-five years ago by excision of some of the anterior portion of the sac, and ‘suture puckering’ of the opening thus made, with drainage of the remainder, enucleation of the entire sac seeming too large an undertaking.

“In June, 1898, the patient, a man aged about forty-seven years, was brought to

\* Ferguson, E. D.: *Phil. Med. Jour.*, 1899, iii, 830.

my office by Dr. M. B. Hutton, of Valley Falls, New York. He had lost notably in flesh and strength, though he was not anemic. He was inconvenienced by frequent urination, and complained of considerable pain in the lower portion of the abdomen. Dr. Hutton had satisfied himself that notable abdominal enlargement had been developing lately, which he ascribed to a tumor in the hypogastric region. The first recognition of the tumor was about a month earlier, but the first sense or discomfort was felt in July, 1897, nearly a year before the discovery of the tumor.

“On examination a flat tumor was found extending from the pubes to about two inches above the umbilicus, and from near each anterior superior spine of the ilium to its opposite fellow. The upper border was slightly irregular near the umbilical region, but elsewhere the contour was quite regular. The sense of resistance was that of a very firm, solid tumor, and at no point could fluctuation or diminished hardness be found. There was, however, a sense of nearness of the mass to the surface, which led me to state that it seemed to me to be in the abdominal wall, but its flattened shape and hardness, together with some irregularity of the upper border, led me to conclude that it was probably a malignant disease of the omentum. Though such a growth as a primary trouble must be exceedingly rare, the shape and hardness led me to that working hypothesis, while the freedom from evidence of bowel involvement, and the yet moderate constitutional effects, led me to advise an exploratory operation, the final decision as to what could and should be done with the mass being left to a consideration of the conditions found on section.

“I heard nothing further of the patient until in July, when his increasing size and discomfort led him to accept my somewhat gloomy, or at least to him unsatisfactory, view of his case, and he decided to submit to an operation. Of course, the absence of renal or other contraindication had been established. The operation was undertaken July 26, 1898, and the first surprise occurred when, on moving the anti-septic dressing after he was under the anesthesia, I found the mass to be then of a globular form. To this was added a great diminution in the sense of resistance and a manifest fluctuation, showing the cystic character of the tumor. This change in the tumor was undoubtedly due to the relaxation produced by the anesthetic in recti muscles of unusual development. My first impression now was that I was dealing with a distended bladder, for the sac evidently extended into the pelvis and seemed more remote than formerly. Having satisfied myself that it was not a distended bladder, I proceeded with the operation until I came to the wall of the cyst just under the deep fascia of the abdominal wall. At this juncture the nature of the case flashed upon me, and I was able to state to those present that we were dealing with a cyst of the urachus. This conclusion was strengthened by the water-like appearance of the fluid which was removed by an exploring syringe. It being apparent that the lower portion of the cyst extended deeply into the pelvis and was probably intimately associated with the bladder-wall, a condition that would explain the frequent urination, I exposed the wall of the cyst before opening it, from as near the umbilicus as the mergeance of structures would allow, to near the pubes. This I did in order to further a plan which I had quickly formed for the management of the case. In the first place, I had determined not to try to enucleate the entire cyst, but to remove the posterior portion with the underlying peritoneum so far as I could, and allow the reclosure of the peritoneum, dealing with the remainder according to circumstances. Such a procedure would require free access to the deep portions of the cyst, hence my long incision. The cyst was



then opened the entire extent of the overlying incision, and an unknown quantity of water-like fluid escaped. The quantity, from absence of convenience for collection (the operation occurring in a private house), could only be estimated, but it was evidently more than two quarts, and probably less than four quarts.

“It was now practicable to investigate the relation of the wall of the cyst to contiguous parts; it was found to be intimately related to the bladder over a considerable extent of the surface of that organ, for it extended deeply into the pelvis. The posterior wall of the cyst was free from evidence of adhesion or other connection with the abdominal organs, and I was about to excise that portion of the sac when it occurred to me to ascertain whether the inner and secreting layer could be removed, thereby securing a surface which would unite. Beginning at the inner edge of my incision in the wall of the sac, and near the lower end of the opening of the belly, I was surprised and gratified to find that a layer of tissue, so thin as to be diaphanous in moderate light, and so strong as to allow of considerable traction without tearing, could be removed without much trouble and with practically no hemorrhage. In that manner the entire lining of the cyst was removed except at the umbilical region, where quite a surface existed, in which digitations penetrated the abdominal wall, and a blending of the tissues prevented the removal of the lining. This surface seemed rather large for complete excision with subsequent easy closure of the belly at that point, hence it was allowed to remain while attention was given to the denuded portion of the cyst. A single deep skin suture was placed to divide the unclosed umbilical area from the subcutaneous suturing below that point. Some iodoform gauze was then placed in the pocket left at the umbilicus, where the lining layer could not be removed, and the whole was sealed with a collodion seal, except over the gauze packing, with the request that it be left for several days unless indications arose showing inflammatory processes.

“It had closed in September, and the area showed in December a perfectly normal state of affairs aside from the scar at the umbilicus.”

*Cyst of the Urachus.* \*—The patient from whom this specimen was obtained was admitted to the Cook County Hospital February 27, 1895. He was a man fifty-two years of age, white, and single. He was admitted for an illness which had begun four weeks previously, with frequent micturition and pain in the region of the kidneys. Examination revealed an enlarged prostate. He had symptoms of cystitis with retention of urine. Hydronephrosis was present, and uremia ensued. He died on April 9th.

Autopsy Abstract.—“The bladder is large, with markedly thickened walls. Each lateral lobe of the prostate is the size of an English walnut. At the summit of the bladder, and separated from the bladder cavity by a thin membrane, is a cyst, the size of an average orange. It contains a thick, turbid, viscid, brownish fluid. The lining of the cyst presents an irregular surface, but there are no distinct rugæ. The irregularities of the cyst lining are present on the upper surface of the intervening septum, between it and the bladder cavity. The rugæ of the bladder are continued upon its inferior surface. The ureters are dilated, as are also the pelves of both kidneys. Careful dissection fails to reveal further urachus remains in the abdominal wall or about the navel. Microscopic examination of the septum between cyst and bladder cavities disclosed the fact that the muscular coats of the bladder-wall were

\* Le Count, E. R.: Transactions of the Chicago Pathological Society, Dec., 1895, to April, 1897, ii, 215.

not continued into the septum. This fact, taken in conjunction with the position of the cyst and the fact that the peritoneum of the abdominal wall was reflected upon the back of the cyst, and thence upon the back of the bladder, leaves no doubt that the cyst represents the obliterated and dilated lower end of the urachus."

**AN ENORMOUS CYST OF THE URACHUS.\***—The following case is cited on account of some unusual features, and because it should be added to the list reviewed by W. R. Weiser in a most interesting and instructive article published in the *Annals of Surgery* for October, 1906.

Miss —, aged forty. History of slowly growing abdominal tumor, beginning in the region of the bladder and growing upward, with gradual onset of pressure symptoms, especially difficult respiration, pain, and impaired digestion. The abdomen was enormously distended, but not tender, nor did it bulge much in the flanks. It was rather firm, and was flat on percussion from the pubes to the ensiform cartilage. Its appearance is well shown in Fig. 239.



FIG. 239.—THE ABDOMINAL CONTOUR IN A CASE OF VERY LARGE URACHAL CYST. (After T. L. Macdonald.)

"Operation (October 6, 1907).—Through the usual incision the cyst-wall was perforated and the fluid drawn off. Two-thirds came away clear; the remainder was turbid, and, lastly, thick, cheesy masses were wiped out. Investigation of the inside of the sac disclosed several thick, nodular masses which were strikingly carcinomatous in character. So far, the peritoneal cavity had not been opened, the sac being situated in front of it. The task of separating the cyst-wall from the peritoneum and viscera was begun by first stripping and cutting it from the epigastric region and from beneath the ribs, and here the peritoneal cavity was opened. It was hoped that from this point downward the dissection would be less difficult, but it was more so. The anterior surface of the peritoneum seemed to be fused with the sac, and the posterior with the viscera generally; and the character of the adhesions was the most dense ever encountered by the writer. These were followed deeply into the pelvis, in all directions, and freed; and finally the firm, fibrous

\* Macdonald, T. L.: *Ann. Surg.*, July-December, 1907, xlvii, 230.

attachment to the bladder was severed and the sac removed. The appendix, six inches in length, bright red, and surrounded by adhesions, was also removed. The abdomen now presented a most unusual sight. With the exception of the anterior surface of the stomach, not a vestige of normal peritoneum was visible. All the abdominal contents, including tubes, ovaries, uterus, and bladder, could be seen outlined through the thin, raw film of peritoneum to which they were firmly attached. The abdominal cavity was filled with normal salt solution and closed with three layers of buried absorbable sutures without drainage.

"Fig. 240 shows some of the nodular masses. There are others on the opposite side. These were on the inner surface of the sac, which was photographed in this way. The cyst was turned inside out, and through the incision, which had served for the evacuation of the contents, a large, thin, collapsed rubber punching bag was thrust, then inflated, thus distending the sac for photographic purposes.

"The report of our hospital pathologist, Dr. Birdsall, shows the cyst-wall to be fibrous, and the nodular masses, which, during operation we feared were carcinomatous, were papillomata. Of course, in a cyst of this size, which had been growing presumably for forty years, and subjected to the ever-increasing pressure of the accumulating fluid, we could not expect to find the normal histologic features of the urachus. Naturally, all except the fibrous structures would disappear by pressure absorption; even bone has been known to do the same.

"Postoperative Course.—The patient's condition was critical for the two following days, active stimulation and intravenous saline infusion being demanded. The wound healed by primary union. The bowels were loose. The temperature ranged from 101° to 102° F. Daily palpation of the abdomen revealed fluctuation, and the percussion-note was flat, showing that the salt solution was not being absorbed. On the seventh day a chill occurred, followed by a rise in temperature to 104° F. Assuming that the unabsorbed solution had become infected through the raw surface of the intestines, the lower end of the now healed wound was cocaineized and cut through, allowing the escape of quarts of the salt solution, which had become purulent, and which presented the colon bacillus characteristics. This was followed by prompt improvement. Drainage and irrigation were continued for a week, after which the wound closed and convalescence and return to health were satisfactory.

"Comments.—The density of the adhesions cannot be appreciated unless encountered. It is true, incision, evacuation, and drainage would probably have been successful after a long period of waiting for the cavity to undergo obliteration. The assumption, however, that portions of the sac had become carcinomatous made extirpation seem imperative.

"Extirpation is evidently not commonly resorted to. Among the 86 cases re-




FIG. 240.—A URACHAL CYST TURNED INSIDE OUT AND SHOWING PAPILLARY MASSES, PARTICULARLY IN THE LOWER PART OF THE PICTURE. (After T. L. Macdonald.)

viewed by Dr. Weiser, only eight were extirpated. None of these was said to be large, and with one or more the history and result were lacking."

*Dilated Urachus Treated by Incision and Drainage.\**  
 —The patient, W. J. P., was a man aged fifty-four who consulted Dr. Pratt on June 8, 1889, complaining of pain and distention in the abdomen and increasing general weakness. He had been quite well until the previous November, when he complained of pain in the lower part of the abdomen. He remained in bed for three weeks and in the house for four months. He could not account for the onset of the trouble in any way. There had been no blow, no lifting of heavy weights, nor straining of any kind. His occupation was that of a store-keeper and clerk near New York, where he had lived for many years. He had had a gonorrhoeal infection when twenty-one, but had never had symptoms of syphilis. He had led a very intemperate life until seven or eight years previously. Since then he had been a moderate drinker. On examination the abdomen was found to be much distended in the lower half and in front: the distended area was dull on percussion and reached as high as three fingerbreadths above the umbilicus. The pain extended as far as the pubes, laterally, on either side, as far as vertical lines drawn through the anterior superior iliac spines. He had no trouble with micturition or defecation. The urine appeared to be normal. The prostate was not enlarged, but there was a fullness of the left side of the pelvis.

On June 15, 1889, the tumor was aspirated and about one dram of a gummy, semitransparent fluid, which blocked the tube was withdrawn. It contained only a trace of albumin, but a large quantity of mucin, as shown by the precipitate it gave with acetic acid. Microscopically it showed many leukocytes.

On July 9th Mr. Bond made a four-inch median incision midway between the umbilicus and the pubes. After division of the linea alba a very thick membrane was reached, resembling a peritoneum much thickened by tubercular peritonitis. It proved, however, to be the outer wall of the cyst. It was divided, and a very large quantity of aropy, gummy, semisolid material came away, of which over a gallon was measured. This had the appearance and consistence of semi-decolorized fibrin, was partly squeezed and partly drawn out in stringy layers. A considerable quantity was left in the cavity, as any attempt to sponge it off the inner surface of the cyst-wall left a red, raw surface which bled freely. On exploration of the cavity with the hand and arm it was found to extend upward to and beneath the liver and downward into the pelvis. The intestines could be made out behind and at the sides of the cyst, though shut off and separated from it. The peritoneal cavity was not opened. A Keith drainage-tube was placed in the wound, and reached to the floor of the pelvis. The rest of the incision was closed.

Chemical examination showed that there was only a trace of albumin, that the fluid was practically mucus and fibrin, with a large predominance of the former. Microscopic examination showed mucus-corpuseles and blood.

The cyst-walls shrank, and the patient gradually improved. In December 1889, on his departure for America, he seemed to be in good health, could walk nine miles at a stretch, and his appetite was excellent. There still remained, however, an irregular shaped cavity with thickened walls capable of holding half a pint of fluid. Mucoid material was secreted daily. The discharge, however, was not fetid and did not seem to in any way depress his health. In a letter dated February

\* Pratt, R., and Bond, C. J.: *The Lancet*, 1890, i, 898.

27, 1890, the patient said that the wound was still kept open by a glass tube, and that there was a discharge of clear, watery fluid, with very little of the jelly-like material. The man was in excellent health and was working thirteen hours a day.

**A True Urachal Cyst.** — Von Recklinghausen\* demonstrated a cyst, about the size of a walnut, which had been removed from a man thirty years of age. The cyst varied from 1 to 3 cm. in diameter, and contained tenacious, colorless mucus. It was situated directly at the top of the bladder, with which it was intimately connected. It lay in the median line in the subperitoneal adipose tissue, and was completely cut off from the bladder. It was polycystic. There was a main cavity with many bays running off from it, and in addition to this there was a small cystic mass which was attached to the bladder, and which contained a labyrinth of microscopic spaces looking like gland loops, or, at any rate, like dilated crypts. The dense connective-tissue walls were nearly everywhere covered over with bundles of smooth muscle-fibers. The epithelium was several (or usually two) layers in thickness, and was definitely squamous in type. Here and there in the crypts were abundant numbers of goblet-cells. On account of the presence of goblet-cells it was necessary to consider the possibility of an enterocystoma; in other words, a derivative from the omphalomesenteric duct. But von Recklinghausen said that this could be excluded, because the tumor was entirely extraperitoneal and because it was in no way connected with the peritoneum.

**Cyst of the Urachus.** — Reed† cites a case (his Fig. 321) in which the sac had extended from near the ensiform cartilage to the pubes and forced the viscera from their normal positions. The cyst was enucleated without any opening into the peritoneal cavity. He gives a schematic picture of the condition. Microscopic details are lacking.

**Probably a Urachal Cyst.** ‡ — This case was also reported by Freer. A divinity student had from infancy been remarkable for his large abdomen, which had made him an object of ridicule to his companions. Thinking adipose tissue to be the cause, he had tried to reduce it by fasting, but without avail. It caused him no trouble until his twenty-fourth year, when a marked increase in size took place. This seriously impeded his respiration and led to an examination, which revealed fluctuation in and around the umbilical region. The dyspnea having increased to such a degree that relief became imperative, a puncture was made and a considerable quantity of reddish-yellow fluid escaped. The procedure was followed by vomiting and intense abdominal pain. The puncture afforded him some relief, and with the exception of occasional fainting spells, his health remained good for a period of two years, after which his abdomen again commenced to increase in size, the dyspnea returned, and his general appearance became cachectic. He again entered the hospital and six liters of bloody fluid were withdrawn. The operation was repeated three times during the ensuing nine months—the remainder of his life. The amounts of fluid were  $18\frac{1}{4}$ , 17, and 6 liters respectively. At his death he weighed about 192 pounds. At autopsy the contents of the cyst were found to amount to 50 liters, which weighed about 100 pounds. The cyst fluid contained

\* Von Recklinghausen: Eine richtige Urachuscyste. Deutsche med. Wochenschr., 1902, xxviii, Vereinsbeilage, 266.

† Reed, Charles A. L.: A Text-Book of Gynecology, 1901, 805.

‡ Rippmann, G.: Eine seröse Cyste in der Bauchhöhle, mit einem Inhalt von 50 Liter Flüssigkeit. Deutsche Klinik, 1870, xxii, 267.

cholesterin crystals, flat epithelium, and fat-droplets. A minute examination of the cyst-wall showed it to consist of three layers, the external being a serous coat. This rested on a layer composed of elastic and fibrous tissue, and the interior was lined with pavement epithelium. The bladder contained a little yellowish urine. It was contracted, and its lining mucous membrane was pale. The urachus was found closed at the bladder end. In its course toward the umbilicus below the commencement of the large cyst, a small cyst was situated near the umbilicus. The fibrous tissue passed into the subperitoneal coat of the larger cyst, which occupied almost the whole abdominal cavity, but the cyst was absolutely independent of the abdominal cavity and the abdominal organs were normal.

**Probably a Urachal Cyst.**—Schaad's\* patient was a married woman thirty-two years of age. Nothing was known about the condition of the umbilicus at birth. She had had two normal labors. At the last labor a tumor had been noted below the umbilicus. The patient was supposed to have had a severe inflammation of the bowels seven years before. Several fingerbreadths below the umbilicus could be felt an elastic tumor the size of a child's head. It could be sharply outlined and pushed in all directions.

A cyst the size of a five-franc piece was found situated about two fingerbreadths below the umbilicus, and attached to the abdominal wall in the mid-line. It was separated from the peritoneum and drawn out of the abdomen. The omentum was tied off; the cyst was found adherent to the appendix. The left ovary was hard and atrophic; the right ovary was normal. The patient recovered.

The cyst was oval in form, and measured 7.5 x 6 x 4.5 cm. The walls varied from 2 to 4 mm. in thickness. The outer surface was fairly smooth, except where it was adherent. The inner surface resembled mucosa and was light yellow in color, with dark spots. On the right side of the cyst was a secondary cyst opening into the larger one. The opening was the size of a pin-head. The inner surface of this second cyst was smooth and yellow; its walls were 1 mm. thick. The large cyst contained about 200 c.c. of a chocolate-colored, cloudy, tenacious fluid, showing much cholesterin, detritus, fat-droplets, etc. The contents of the small cyst were similar in character, but thicker. The wall of the large cyst consisted of connective tissue and large quantities of smooth muscle arranged in bundles. These ran in all directions. The inner surface was lined with high cylindric epithelium; there were also glands opening upon the surface. In places the epithelium and glands were absent. The small cyst was lined with granulation tissue, in which were encountered giant-cells, some containing as many as 20 or 30 nuclei, arranged at the margin or irregularly scattered or in the center. [These are suggestive of foreign-body giant-cells.] Schaad felt sure that he was dealing with an omphalomesenteric duct, a portion of which had remained open, with a resulting retention cyst. [From the cases followed in the literature the case strongly suggests a urachal cyst. The question, however, is an open one.—T. S. C.]

**A Cystic Urachus.**—Scholz† reports the case of a sixteen-year-old girl who complained of difficulty in micturition and a painful tumor in the abdomen. The abdomen was prominent, the largest measurement being between the umbilicus and symphysis. The tumor was very painful. On both sides there was tympany.

\* Schaad, T.: Ueber die Exstirpation einer Cyste des Dotterganges. *Correspondenzbl. f. Schweizer Aerzte*, 1886, xvi, 345.

† Scholz: *Wien. med. Wochenschr.*, 1878, xxviii, 1327.

After a time an opening, about the size of a hair, developed at the umbilicus, and fluid escaped from it. The opening was dilated and about 300 c.c. of colorless, transparent, thick, tenacious fluid escaped, and finally a thick yellow pus. The wound closed in the course of two months.

A Large Urachal Cyst.\* — Case 1.—“This case was sent to me by Dr. Lamb, of Albrighton. She had complained of abdominal pain and tenderness, and in October, 1880, she began to suffer from somewhat serious symptoms, more particularly frequent vomiting and disinclination to take solid food. Some swelling in the lower part of the abdomen was noticed about the same time, this being then regarded as ascitic. The symptoms slowly increased in severity until February 11, 1881, when a consultation was held between Drs. Lamb, Heslop, and Saundby. As a result of this consultation she was tapped, and 10 pints of fluid were removed, although this was by no means the amount of fluid in the cavity, because large masses of flocculi obstructed the tube of the trocar and prevented the complete emptying of the cyst. Some of this fluid was submitted to me for an opinion, and from the fact that it was brown and thick and gave an abundant flaky yellow deposit, which consisted chiefly of pus, I unhesitatingly gave the opinion that it was not ascitic, but a fluid that must have been contained in some cyst cavity, probably a cyst of the parovarium. I saw her on February 13th, when we found that the abdomen was quite as much distended as before the tapping. I therefore proposed an exploratory incision for the removal of the tumor, if it were possible to remove it, although the extremely exhausted condition of the patient gave no very great prospect of success. It was perfectly clear, however, that if let alone nothing but death could be the result, and therefore an operation was accepted by her attendants and relatives.

“I opened the abdomen at the usual site, and after cutting through all the layers except the peritoneum I came upon the cyst-wall. I opened the cyst and removed about 30 pints of fluid, exactly the same as that which had been removed at the tapping; and mixed up with it I found large masses of the fibrinous deposit, which accounted for the failure of the tapping to remove the whole of the fluid. I then proceeded to remove the enormous cyst, which was uniformly attached to the parietal wall on its outer aspect, and to the outer surface of the thickened peritoneum on its posterior aspect. The cyst did not dip into the pelvis at all, and the anterior parietal peritoneum did not reach the wall lower than the ensiform cartilage. The intestines and the pelvic organs could be felt through the anterior peritoneal fold, non-adherent, and, as far as could be determined, perfectly healthy. The cyst lay, therefore, entirely between the transversalis fascia on the outer side and the parietal peritoneum on the inner, the peritoneal cavity having been nowhere opened during the severe and protracted operation. The cyst was removed in its entirety, and its inner surface consisted of broken-down mucoid epithelium, infiltrated everywhere with pus, lying upon the basement membrane, which consisted almost entirely of muscular fibers.

“The conclusion concerning the nature of this cyst, at which I have arrived, is that it was developed from the urachus, a part of which had been occluded at both ends, but during the developmental changes of embryonic and infantile existence had not become obliterated. I entirely fail to see any other possible origin for it, and, if my explanation be correct, it is very marvelous that this structure should have re-

\* Tait, Lawson: Twelve Cases of Extraperitoneal Cysts. Brit. Gyn. Jour., 1886-87, ii, 325.

mained quiescent for fifty-six years and then should suddenly undergo an inflammatory change which developed it into this enormous cyst. The patient went on very well for three days, and then rapidly sank from exhaustion. No postmortem examination was allowed, and therefore I can shed no further light upon it; and, as far as I know, the observation is unique, although it is perfectly well known, as I myself have repeatedly had occasion to observe, that small cysts of the urachus are opened in abdominal section. I do not know that any such cyst has previously been met with sufficiently large to be of pathologic importance. It was noted and published at the time that the basement membrane of this cyst consisted almost entirely of muscular fiber, an observation which is absolutely concurrent with the examination of the cyst in Case X, made by Mr. Bland-Sutton.”

Probably a Large Urachal Cyst.\*—Case XI.—“This case was sent to me by Dr. T. S. Bourne, of Kenilworth, as a case of acute inflammatory disease of the abdomen, of which he said: “I find it impossible to make an exact diagnosis.” When I saw her I found her with a high pulse and temperature, and abdomen distended with a large quantity of free fluid. My opinion, expressed at the time, was that it was a case of tubercular peritonitis. I made the usual section, and found it another of these cases of congenital cysts belonging to the category of the cases already described in numbers IV, V, VI, VII, VIII, IX, and X. I removed a small piece of the cyst-wall for examination, and the reports of the microscopic examination by Dr. Arthur Johnstone and Mr. J. Bland-Sutton of Cases X and XI are annexed. I used the circular drainage method, and the patient has completely recovered. The following is Mr. Bland-Sutton’s report:

“Sections of the cyst-wall exhibited under the microscope a mixture of fibrous and non-striated muscle tissue arranged in fasciculi, closely corresponding to the disposition of the bundles of tissue which make up the walls of the urinary bladder. Scattered throughout the whole thickness of the sections were small calcareous nodules. It was difficult to make out any definite epithelial investment to the sections, but on scraping the smooth surface of the specimen with a cover-glass, the field of the microscope became crowded with flattened, rounded, and pyriform cells, similar to those found lining the interior of the urinary bladder, only very much smaller.

“As the urachus is lined with epithelium agreeing in shape, and continuous with that found in the interior of the bladder, the evidence that these cysts are allantoic seems to me to be complete (J. Bland-Sutton).”

[Tait cites a considerable amount of literature and discusses other cases at length. It is very difficult to tell in the majority of these cases whether he was right in his assumption or not. His entire paper, however, is a very interesting one.—T. S. C.]

A Urachal Cyst.—Wolff † reports two cases which came under his observation in the clinic in Marburg in 1872, and which, according to his view, were urachal cysts. I shall here report only Wolff’s Case I.

Mrs. K., aged thirty-one, was always healthy in childhood. Two years before her admission she noticed a tumor in the left side of the lower abdomen. This gradually increased. In March, 1872, there was a pregnancy which terminated nor-

\* Tait, Lawson: *Loc. cit.*, Case xi.

† Wolff, C. C.: *Beitrag zur Lehre von den Urachuseysten*. Inaug. Diss., Marburg, 1873.



mally, but was followed by an acute fever, with severe pain in the left part of the abdomen. The abdomen suddenly reached enormous proportions in a few days. The patient was treated by her physician for peritonitis. Convalescence was slow, but the patient again became quite strong. On palpation of the abdomen, a tense, elastic, fluctuant, rounded tumor could be felt. This filled the entire left side of the lower abdomen, and extended over to the right a handbreadth beyond the linea alba. Upward it reached beyond the umbilicus. The tumor could not be pushed from side to side. It had a smooth surface, and apparently consisted of one mass. A median incision was made, but the peritoneum did not become visible. After careful dissection the cyst was opened and yellowish, serum-like fluid escaped. The patient was laid on her side and the contents of the cyst gradually flowed out. After 5 liters of fluid had been removed in this way, the tumor was gradually loosened. The peritoneum was thickened, evidently as a result of inflammation. In the inner part of the cyst were large, lumpy coagula of fibrin. The connection of the cyst with the peritoneum was in part firm and in part very loose. The tumor was shelled out without difficulty. It was possible to do the operation almost entirely extraperitoneally; only at one point was the peritoneum opened for a distance of 1 cm. This was closed with silk. The patient made a good recovery.

The cyst was egg-shaped. Its largest circumference was 63 cm. When flattened out it was 31 cm. in breadth. The cyst-walls varied from 1 to 3 or 4 mm. in thickness. The outer surface was rough, with numerous string-like processes which indicated where the adhesions to the peritoneum had been cut. It had a poor blood-supply. The cyst-wall had a tough consistence. The interior of the cyst was smooth, like a serous wall. It had over its surface fibrinous deposits. According to Lieberkühn, who made the histologic examination, the cyst-wall consisted of fine connective tissue with fibers running in various directions; here and there were non-striated muscle-fibers. A definite epithelium was not detected on the inner surface. The fluid consisted of large granular masses of detritus and pus-cells.

#### LITERATURE CONSULTED ON LARGE NON-INFECTED URACHAL CYSTS.

- Atlee, W. L.: Ovarian Tumors, Lippincott, Philadelphia, 1873, 50.  
 Baldwin: Large Cyst of the Urachus. *Surg., Gyn., and Obst.*, 1912, xiv, 636.  
 Bantock: See Tait's article.  
 Bryant, T.: Discussion on Doran's paper, *Brit. Med. Jour.*, 1898, i, 1390.  
 Carroll, J. W.: Cystic Urachus. *Buffalo Med. Jour.*, 1895-96, xxxv, 869.  
 Cotte et Delore: Gros kyste de l'ouraque. *Lyon méd.*, 1905, cv, 373.  
 Doran, A. H. G.: Urachal Cyst Simulating Appendicular Abscess; Arrested Development of Genital Tract; with Notes on Recently Reported Cases of Urachal Cysts. *The Lancet*, 1909, i, 1304.  
 Dössekker: *Klin. Beitr. z. Lehre von den Urachuscysten. Beiträge z. klin. Chir.*, 1893, x, 102.  
 Douglas, R.: Cysts of the Urachus. *Trans. Amer. Assoc. of Obstet. and Gynecologists*, 1897, x, 177.  
 Ferguson, E. D.: Cysts of the Urachus. *Phila. Med. Jour.*, 1899, iii, 830.  
 Ill, E. J.: Tumors of the Urachus. *Trans. Amer. Assoc. of Obstet. and Gynecologists*, 1892, v, 238.—*Amer. Jour. Obst.*, 1897, xxxvi, 568.  
 Le Count, E. R.: Cyst of Urachus. *Trans. Chicago Path. Soc.*, Dec., 1895, to April, 1897, ii, 215.  
 Macdonald, T. L.: An Enormous Cyst of the Urachus. *Annals of Surg.*, July-December, 1907, xlvi, 230.  
 Pratt and Bond: Dilated Urachus Treated by Incision and Drainage. *The Lancet*, 1890, i, 898.

- Von Recklinghausen: Eine richtige Urachuscyste. Deutsche med. Wochenschr., 1902, xxviii, Vereinsbeilage, 266.
- Reed, C. A. L.: Cyst of the Urachus. A Text-Book of Gynecology, 1901, 805.
- Rippmann, G.: Eine seröse Cyste in der Bauchhöhle, mit einem Inhalt von 50 Liter Flüssigkeit. Deutsche Klinik, 1870, xxii, 267.
- Schaad, T.: Ueber die Exstirpation einer Cyste des Dotterganges. Correspondenzbl. f. Schweizer Aerzte, 1886, xvi, 345.
- Scholz: Cystis urachi. Bericht des k. k. Allg. Krankenhauses, Wien, 1877 (quoted by Wutz).
- Tait, L.: Twelve Cases of Extraperitoneal Cysts. Brit. Gyn. Jour., 1886-87, ii, 328.
- Weiser, W. R.: Cysts of the Urachus. Annals of Surg., 1906, xlv, 529.
- Wolff, C. C.: Beitrag zur Lehre von den Urachusysten. Inaug. Diss., Marburg, 1873.
- Wutz, J. B.: Ueber Urachus und Urachusysten. Virchows Arch., 1883, xcii, 387.

## CHAPTER XXXIII.

### ABSCESSSES IN THE ANTERIOR ABDOMINAL WALL BETWEEN THE UMBILICUS AND SYMPHYSIS DUE TO INFECTION OF URACHAL REMAINS OR OF URACHAL CYSTS.

Report of a personal observation.

Clinical course.

Treatment.

Cases of abscess of the abdominal wall due to infection of remains of the urachus, and not communicating with the bladder.

My attention was particularly drawn to this group of cases in 1910 when Dr. L. Gibbons Smart, of Lutherville, Md., asked me to see a boy, aged fifteen, who was complaining of a hard mass extending from the symphysis to the umbilicus in the mid-line. There was no history of abdominal injury.

Seven weeks before, the patient had begun to suffer with severe pain in the lower abdomen. On making an examination he had noted that it was very hard to the touch, but not tender. His pain had been constant during one day, and then had disappeared, only to recur every few days and last a day or two at a time. Sometimes the pain in the mid-line had disappeared; on other occasions it had been referred to the right or left side. He did not remember having had chills or fever until two weeks before entering the hospital, when he had had a chill, followed by an elevation of temperature. After this there had been several chills.

He had had no increased pain when voiding and had never passed any urine from the umbilicus, nor had he any umbilical discharge. He said he remembered having had a few night-sweats.

His appetite for the last eight weeks had been very poor, following a period of several months when he seemed unable to satisfy his craving for food.

The patient was a well-developed and healthy looking youth. He said that at the time he first noticed the condition his abdomen was just as hard as it was on the day that he entered the hospital, seven weeks later. His bowels were usually constipated; his urine was normal.

Operation.—Church Home and Infirmary, June 11, 1910. Under anesthesia it was noted that the umbilicus was more prominent than usual, and that it welled out on both sides (Fig. 241). The hardness in the abdominal wall also became much more evident when the patient was asleep. I made an incision commencing just below the umbilicus and extending to the symphysis. After separating the recti we found that the tumor lay extraperitoneally. It was exceedingly hard, and almost as dense as cartilage. An incision having been carefully made through this hard tissue, we encountered a sac, somewhat irregular in form, and filled with brownish, grumous contents amounting to about 50 c.c. The cavity was carefully scraped out. A portion of the thickened wall was removed for examination, and the cavity packed with iodoform gauze. The patient made a complete recovery.

Histologic examination of the tissue showed newly formed connective tissue, but without any evidence of an epithelial lining.

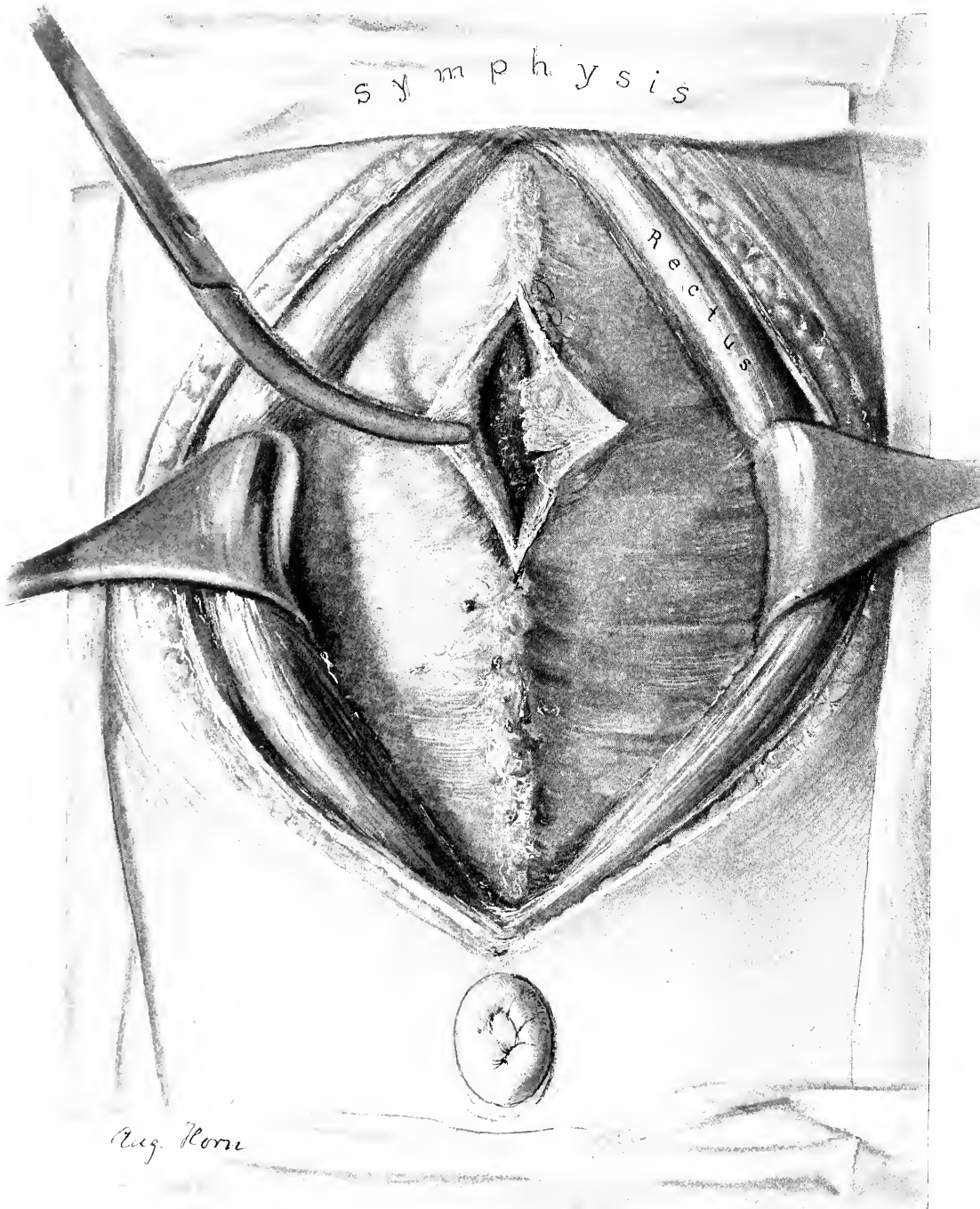


FIG. 241.—INFECTED URACHAL REMAINS.

The umbilicus is prominent and wells out. The recti muscles have been retracted, exposing a hard, indurated mass. Its walls were exceedingly dense, in places fully 2 cm. thick, and as hard as gristle. The cavity was irregular in outline and contained about 50 c.c. of brownish, grumous contents. On histologic examination the walls of the mass were found to be composed of dense fibrous tissue and the cavity was lined with granulation tissue. No attempt was made to remove the mass. The cavity was wiped out and packed, and in a few weeks the mass had literally melted away, leaving a perfectly soft abdominal wall. The patient at the present time (March 1, 1916) is perfectly well.

The patient has since remained absolutely well. In this case the situation of the tumor left little or no doubt that we were dealing with remains of the urachus which had undergone a low grade of infection. The rapidity with which the inflammatory tissue literally melted away after drainage was established was remarkable.

#### CLINICAL COURSE.

One of the first symptoms is a feeling of pain or discomfort in the lower abdomen. As the process advances, the pain may be intermittent in character, as noted in my case, or sudden and violent, as experienced in Page's case. Arrou's patient, a soldier, had such abdominal discomfort that, when on the march, he walked with his body bent forward. Vaussy's patient experienced great abdominal pain, which was intensified on inspiration.

A moderate degree of fever was noted in Arrou's, Page's, Vaussy's cases, and in Weiser's Case I. My patient also had some fever and also night-sweats.

As often happens when pus is forming, some patients had a loss of appetite. Page's patient was nauseated, and Baldwin's suffered a good deal from vomiting. Page's patient had diarrhea, and in Hörnig's case there was loss of weight. Vaussy's patient was markedly depressed. In those cases in which the posterior surface of the abscess causes an inflammation of the peritoneum the constitutional symptoms will be more marked.

From Weiser's Case II we get a graphic picture of the alarming symptoms that may develop: "On admission her temperature was 101.2° F., pulse 172, respirations, 30. The child was pale and emaciated, and had a dry tongue and an anxious expression. She complained bitterly of abdominal pain, and the entire abdomen was tender, especially so about the umbilicus, and the entire abdomen was greatly distended and board-like. A positive diagnosis was not made prior to operation, but tubercular peritonitis and suppurative urachal cyst were both considered."

There are, as a rule, no bladder symptoms. In Van Hook's six-months-old patient, however, the urine was quite turbid. In Weiser's seventy-five-year-old woman there had been frequent micturition for a month prior to operation. This absence of vesical symptoms stands out in sharp contrast to what occurs in those cases in which the urachal enlargements have a direct connection with the bladder. In the latter, vesical symptoms are the rule.

On examination of the abdomen it is often possible to detect a board-like induration between the umbilicus and symphysis. If the abdominal walls are particularly lax, one may be able to grasp the tumor in the hand and move it from side to side. As a rule, however, this is possible only when the patient is asleep and the recti muscles are relaxed.

As a rule, the abdominal skin looks perfectly normal. In Van Hook's case, however, the umbilicus had a red, inflamed appearance, and thin pus trickled from a small opening in the lower umbilical fold when pressure was made on the tumor. The right inguinal glands were enlarged.

In Weiser's Case II the umbilicus was surrounded by a zone of redness, where the abscess was ulcerating toward the surface. In Weiser's seventy-five-year-old woman there was a copious discharge of pus from the umbilicus, which had existed for fifteen years.

Although the abscess usually opens at the weakest point, viz., the umbilicus, nevertheless, in rare instances, a fistulous opening may develop in the mid-line between the umbilicus and bladder, as indicated in Fig. 242.

**The Abscess Sac.**—The abscess walls are usually densely adherent to the recti in front and to the peritoneum behind. They vary much in thickness, some reaching in places almost 2 cm. The inner surface of the sac is usually smooth and velvety, resembling an ordinary abscess sac. The contents of the sac vary considerably. Sometimes they consist of ordinary pus; this, in Vaussy's case and also in Weiser's seventy-five-year-old woman, was very fetid. The fluid

may, however, be yellowish red, yellowish brown, or brownish in color, and be gumous or ropy in character and contain necrotic material, which Baldwin and Doran said reminded them of "disintegrating omentum."

From a careful consideration of these cases it seems to me that yellowish or brownish contents are found in those in which a very low and slumbering grade of infection has existed, the typical pus being found in the more acute inflammations.

In Arrou's case a calculus the size of an olive was found in the sac. It looked like a piece of incompletely dried mortar.

Weiser's seventy-five-year-old woman had in the abscess sac a calculus that weighed 70 grains. As noted from his personal communication to me, it was hard, had a dark-brown surface, and on section resembled a bladderstone in color and appearance.

On histologic examination the walls of the sac are found composed in a large measure of dense inflammatory tissue. In places some non-striped muscle may still be detected; all trace of transitional epithelium

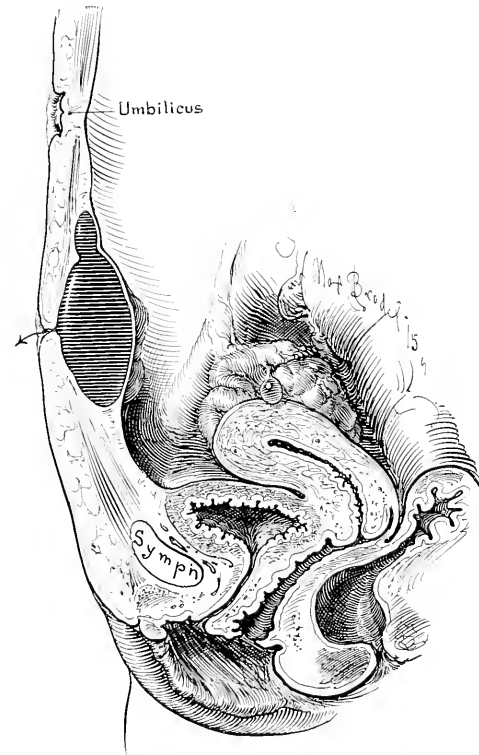


FIG. 242.—AN INFECTED URACHUS OPENING BETWEEN THE UMBILICUS AND BLADDER. (Schematic.)

When a urachal infection opens, it is usually either at the umbilicus or bladder; occasionally, however, it perforates the abdominal wall below the umbilicus, as indicated here.

is usually lost, but it may occasionally be recognized in the contents of the abscess.

For abscesses developing in the subumbilical space the reader is referred to the investigations of Fischer, given in detail on p. 263.

#### TREATMENT.

After the median abdominal incision has been made and the recti have been separated, the abscess wall is at once encountered. If the walls are thin, the cavity is readily reached, but at times it is necessary to cut deliberately through from 1 to

2 cm. of very dense tissue before the fluid is reached. The cavity should be wiped out, and, if it has thick walls, it should be curetted. It is then packed with gauze and allowed to close by granulation. Great care should be taken to avoid opening the peritoneal cavity. It is astonishing to see the rapidity with which the scar tissue disappears as the result of adequate drainage. In those cases in which the urachus is enlarged and adherent to the sac, and where this tube can be readily reached, it is advisable to ligate and cut it, as there is a possibility of urine escaping later from the abscess sac.

#### CASES OF ABSCESS OF THE ABDOMINAL WALL DUE TO INFECTION OF REMAINS OF THE URACHUS, AND NOT COMMUNICATING WITH THE BLADDER.

I have not cited all the recorded cases, but have included only those that are especially convincing.

**Suppurating Cyst of the Urachus.**—Arrou\* reported the case of a patient operated upon by Tricot. A soldier, who gave absolutely no history of bladder trouble, complained of vague pain in the umbilical region. The pain became acute, and during his march he had to bend forward. He had no nausea or intestinal disturbances; urination was normal, the temperature unaltered.

Examination revealed a plaque as large as a hand a little below the umbilicus. This was painful, but there was neither edema nor reddening. Gradually a little swelling was noted. The patient had some pain and fever.

**Operation.**—An exploratory operation under local anesthesia was determined upon, the condition being thought to be due to an abscess of the abdominal wall. But almost as soon as the patient reached the operating room an escape of a small amount of pus was noted coming from the lower margin of the umbilicus. A probe introduced into the small orifice descended downward and backward into the cavity, which was 6 cm. long in its vertical direction. The patient was at once anesthetized, and a cavity was opened; this proved to be as large as a mandarin orange, and contained a calculus the size of an olive, like a piece of mortar incompletely dried. The cyst lining resembled an inflamed mucosa. Unfortunately, both sac and calculus were lost. The upper end of the sac ended at the bottom of the umbilicus; the lower extremity terminated in the closed cul-de-sac. Attached to the lower end of the sac was a cord the size of the little finger; this cord gradually became smaller and terminated in the fundus of the bladder. There is no doubt that it was the urachus.

The peritoneum was opened above and laterally, the intestine projected. The urachus was cut across with a cautery at a point several millimeters above the bladder. The sac was completely removed and the wound closed. The patient made a good recovery.

**Abscess Between Umbilicus and Pubes.** †—“Mrs. C. L. R., aged thirty-three, Shenandoah, Ohio. Physician, Dr. J. M. Fry. Married twelve years; one child, aged eleven years; labor normal; no miscarriages; appetite fair, but much vomiting; kidneys normal; menstruation normal. Patient had suffered from her present trouble for about a year, but no diagnosis had been

\* Arrou: Kyste suppuré de l'ouraoue. *Bull. et Mém. de la Soc. de chir., Paris*, 1910, xxxvi, 832.

† Baldwin, J. F.: Large Cysts of the Urachus. *Surg., Gyn., and Obst.*, June, 1912, xiv, 636.

made until about three weeks before I saw her, which was March 29, 1901. In the previous July she had had a feeling of fulness and was as large as though pregnant six months. In September much of this fulness disappeared, but it again increased. When I saw her, the uterus was pushed forward and to the right by a tumor, which did not seem to involve the uterus but which extended from the pubes to the umbilicus. This tumor was cystic, and apparently about the size of an adult head. It could not be said to be movable, but did not seem to be very firmly fixed. Dr. Hunter Robb, of Cleveland, and myself saw the patient together in consultation, and assumed that the tumor was ovarian.

"She came to Columbus and was operated on April 24, 1901, Dr. Fry being present. When under the anesthetic the uterus was found, as before, pushed forward against the bladder, and the cyst could be very distinctly mapped out. On opening the abdomen we found the transversalis fascia to be much thickened. It was dissected through with great care. On getting through there was a gush of pus. With the fingers on the inside the incision was enlarged sufficiently for thorough examination. A large quantity of pus was evacuated, together with a considerable amount of more or less necrotic material, resembling somewhat disintegrated omentum (as in one of the cases mentioned by Doran). The cavity having been entirely cleaned out, the sac was found to be a smooth and rather thick membrane. The peritoneal cavity itself had not been entered. In the pelvis the uterus was found standing up, as it were, distinctly in the cavity, though covered by the membrane, as were also its appendages. The connection of the membrane with the surrounding parts seemed to be so firm as to render any attempt at its enucleation undesirable. The cavity was therefore drained, the incision being only in part closed.

"Patient stood the operation well, made an excellent operative recovery, and returned home in due time. Dr. Fry reported, under date of March 15, 1904, that the fistula which followed the drainage had closed only about four months before. Patient had been warned as to the probability of a hernia. Under date of September 17, 1911, the patient, in response to a letter of inquiry, reported that her health was as good as ever. From her letter it is evident that there is a small hernia at the point of drainage which perhaps should be operated upon, but seems to be making no special trouble. Menstruation perfectly regular." Baldwin said that the patient has had no further pregnancies.

*Infection of the Urachus.* — In Bryant's\* Case 2 the patient was a man about thirty years of age who had a slight epispadias. He had had for many years a tumor the size of a small cocoon lying between the umbilicus and the symphysis. He came under observation on account of great swelling and tenderness between the pubes and the umbilicus. The condition was thought to be due to an abscess. The urine was normal. After incision, very fetid material came out, but there was no urinary smell. The cavity was packed with terebene, and some days later urine was discharged from the wound.

*Abscess Formation in the Patent Urachus.* † — A female child, apparently normal at birth, had abdominal pain and diarrhea and vomiting when three weeks old. When five months old she was sick again, and the mother noticed a protrusion of the abdominal wall below the umbilicus. The swelling

\* Bryant, T.: *Brit. Med. Jour.*, 1898, i, 1390.

† Van Hook: *Amer. Jour. Obst.*, New York, 1894, xxix, 624.



reached the size of an orange. Hot applications resulted in an opening at the umbilicus, with the discharge of a large quantity of pus. Later on cystitis developed and pus continued to be discharged through the umbilicus.

Van Hook examined the child when it was six months old. She urinated repeatedly during the examination. The urine was quite turbid. The umbilicus projected slightly upward and forward and was apparently pushed in this direction by a tumefaction the size of a small apple, which also pushed forward the abdominal wall between the umbilicus and the pubes. The umbilicus had a red, inflamed appearance. A thin pus trickled from the small opening in the lower umbilical fold when pressure was made on the tumor. There was swelling of the right inguinal glands.

Under chloroform a probe was passed down almost to the pubes, but did not enter the bladder. The opening was dilated and a drainage-tube put in. Recovery followed in a week.

**An Infected Urachal Cyst.**—Hörnig\* reviews the literature and reports a case from Trendelenburg's clinic.

The patient was a girl, three years and nine months old. For several weeks she had complained of painful urination. For eight days the mother had noticed swelling of the abdomen. The child had lost weight. The father said that she had often felt sick, and in the spring had remained in bed for two days.

**Operation (December 4, 1902).**—The umbilicus bulged out, forming a nodule the size of a cherry. It was bluish red and covered with thin skin. From the umbilicus to the symphysis the abdomen was half-ball-shaped from tension. Palpation met with a tense resistance. The umbilical swelling collapsed while the child was being bathed, and yellowish-red, thick, fluid masses escaped. On catheterization the urine was perfectly clear and transparent; it contained no albumin nor sediment. The umbilical fluid contained staphylococci, and microscopically many flat cells. After the bladder had been emptied the half-ball-shaped swelling between the umbilicus and the symphysis became less prominent, and by rectal examination, with one hand on the abdomen, the surgeon could make out very clearly a cystic tumor.

The fistulous opening was closed to prevent infection. The incision encircled the umbilicus and extended to 2 cm. above the symphysis. The anterior wall of the cyst was exposed. On account of the danger of peritonitis total extirpation of the cyst was not attempted, but the anterior cyst-wall and the umbilicus were removed. A finger in the cyst showed that it extended downward behind the symphysis, and that it ended blindly in the pelvis. A catheter introduced into the bladder could be felt behind and to the left. The cyst-wall was curetted with a sharp curette to remove any epithelial lining. A drain was laid and the opening closed. By January 13, 1903, only a small, granulating strip, 5 mm. wide, remained.

On microscopic examination no epithelial lining of the cyst could be found. The walls were composed of connective tissue, showing marked round-cell infiltration. They also contained smooth muscle-fibers. Although the epithelium was missing, Hörnig felt that the smooth muscle was all that was necessary for diagnosis.

**A Case of Hardening of the Linea Alba and Umbilicus.**—In some healthy persons Legg† says there may be felt in the linea alba,

\* Hörnig, Paul: Zur Kasuistik der Urachuscysten. Inaug. Diss., Leipzig, 1905.

† Legg, J. W.: Saint Bartholomew's Hospital Reports, 1880, xvi, 251.

between the pubes and the umbilicus, a certain thickness or firmness which is not, however, very marked. He cites an interesting case in which the linea alba between the pubes and the umbilicus was one inch thick, a new growth having its seat apparently in the subperitoneal tissue. This growth was white, dense, tough, and much thicker on the left than on the right of the mid-line. The omentum was thickened. The stomach was small, constricted, and adherent to the omentum. No microscopic examination was made. [The possibility of a malignant abdominal growth in this case cannot be excluded.—T. S. C.]

**A Partially Patent and Infected Urachus.**—Lexer\* reports a case coming under the observation of Delagénière. The patient was a boy, five and a half years old, who had a fistula dating from early childhood. At the sixth month a small tumor at the umbilicus opened. Delagénière cut around and then entered, behind the umbilicus, a pocket filled with granulation tissue. Its lower portion communicated with the urachus. In dissecting this out he opened the peritoneum and could feel a string of the urachus passing downward to the bladder. It was isolated for 3 cm. and cut across. The lumen was turned in and closed with sutures. The fistula healed as the result of this procedure, which Delagénière spoke of as partial resection of the urachus. The child remained healthy.

**An Infected Cyst of the Urachus.**—Page's† patient was a man thirty-six years of age, married, and previously in good health. In March, 1899, he had dull pain about the fundus of the bladder. The pain was intermittent, ceased, and reappeared the second year. In July, 1901, he had sudden violent cramps in the abdomen, followed by diarrhea. The diarrhea ceased in two weeks, but the pain continued. Page suspected appendicitis.

On admission the patient walked bent over. He had great pain in the hypogastric region. His temperature was 102.5° F., pulse 100. He was nauseated. Examination disclosed a circumscribed mass, the size of an average orange, which lay between the umbilicus and pubes, and seemed to be in the abdominal wall. The patient had had a chill the night before. Dr. F. L. Taylor suggested a suppurating cyst of the urachus.

**Operation.**—Incision three inches long over the mass. In cutting through the fascia the tissues were found to be dense and hard. The operator entered a cavity containing four ounces of thick, flaky fluid, yellowish-brown in color. The abscess cavity was large; the walls were smooth and very thick. In lengthening the incision the peritoneum was accidentally opened. It was at once closed.

The recovery was slow. The cavity gradually became obliterated. The sinus had to be curetted several times, but it healed permanently. The man had formerly weighed 115 pounds; he then weighed 145.

**Subperitoneal Phlegmon of the Anterior Abdominal Wall Without Appreciable Cause, Opening Below the Umbilicus; Rapid Healing.**‡—On p. 5 Vaussy gives the history of phlegmonous subperitoneal inflammation of the anterior abdominal wall, and on p. 6 says that Velpeau, Boyer, Nélaton and Vidal, had cited in their publications

\* Lexer, E.: Ueber die Behandlung der Urachusfistel. Arch. f. klin. Chir., 1898, lvii, 73.

† Page, Charles C.: The Post-Graduate, New York, 1902, xvii, 1094.

‡ Vaussy: Des phlegmons sous-péritonéaux de la paroi abdominale antérieure. Thèse de Paris, 1875, No. 445, Obs. 2.

several examples of vast purulent accumulations developing between the peritoneum and the anterior abdominal wall. On p. 25 he gives Observation 2. A boy, aged eleven, had at first complained of malaise, fever, and lack of appetite, and later of extreme pain in the hypogastric region. This was increased on inspiration. For a time the pain became general throughout the entire abdomen. The parents soon noticed a swelling in the abdomen below the umbilicus. When admitted (October 26, 1875) to the hospital, the boy showed a great deal of depression, had fever, no appetite, but gave no history of chills or vomiting.

On inspection a tumor was found extending from the umbilicus to the pubes. It was in the median line, and extended over to the left 5 cm. and to the right as far as the crest of the ilium. The tumor was hard, possibly fluctuating, but this could not be determined on account of the patient's pain. It suggested in contour a markedly distended bladder. The skin was of normal color; there was no redness nor edema. Rectal examination was negative. It was decided that the condition was due to a subperitoneal phlegmon of the anterior abdominal wall. It was impossible to determine the cause of the phlegmon, as the child had never been injured, nor had he had typhoid fever. The hypogastric region remained painful, the tumor became fluctuating, and a small red point the size of a 50-centime piece appeared immediately below the umbilicus in the median line. Poultices were applied. The pain and redness persisted, and there developed a small tumor the size of a cherry. Fluctuation being evident, a small incision was made with a bistoury and an enormous quantity of pus escaped. This had a very fetid odor, but did not in any way suggest stercoraceous material. By the eleventh of November the fistula had closed and the child left the hospital. The cause of the inflammation in this case was not clear.

[The history, which is characteristic of such cases, suggests remains of the urachus which had become inflamed.—T. S. C.]

**Suppuration of a Urachal Cyst.**—In Weiser's Case 2 the patient was a girl, eleven years old, who was admitted to the Mercy Hospital on April 11, 1905. The child had complained for several days of headache and vomiting and had gradually developed slight tenderness and some pain in the abdomen. At first there had been no localized tenderness and very little distention. One week prior to admission general flatness had been noted with fluctuation. The abdomen had become more and more distended. On admission her temperature was 101.2° F.; pulse, 172; respirations, 30. The child was pale and emaciated and had a dry tongue and an anxious expression. She complained bitterly of abdominal pain, and the entire abdomen was tender, especially about the umbilicus, greatly distended and board-like. The flatness extended from the umbilicus to the symphysis, and from a point two inches to the right of the median line almost completely into the loin on the left. Surrounding the umbilicus was a zone of redness  $1\frac{3}{8}$  inches in diameter, which represented an area through which the abscess was ulcerating toward the surface. A positive diagnosis was not made prior to operation, but tubercular peritonitis and a suppurative urachal cyst were both considered.

Under anesthesia the abdomen was opened in the mid-line between the umbilicus and symphysis. Absence of the peritoneum made a diagnosis quickly possible. The abdominal cavity was divided into two compartments by the sac-wall, which

\* Weiser, W. R.: *Annals of Surgery*, 1906, xliv, 529.

had displaced the intestines almost entirely to the right side of the cavity and walled them off. Almost the entire left side below the umbilicus was filled with the cyst, which had ruptured, as shown in Fig. 243. Except at the point of rupture, the cyst contents were entirely extraperitoneal, although occupying so large a part of the abdominal cavity. Free pus to the amount of several pints was confined to the left side, and was not in contact with the intestines. The position occupied by the mass is fairly well shown in Fig. 243. The urachus was patulous down to within three-eighths of an inch of the bladder, and was ligated at this point. So much of the sac as could be dissected out without tearing up the limiting wall was taken

away, and the abscess cavity washed out and drained with a coffer-dam drain of iodoform gauze. An area 2 x 4½ inches was bare of peritoneum at the site of the wound, but there was no trouble from this source.

**A Small Urachal Cyst Showing Inflammation.\***—Case 23. Autopsy No. 260, 1881.—The body was that of a man, sixty-three years old, dead of arteriosclerosis, hypertrophy and dilatation of the heart, emboli of the lungs, general edema, hypertrophy of the prostate, catarrhal cystitis. The bladder was pear-shaped, and its vertex appeared to reach to within 4 cm. of the umbilicus. When it was opened at the upper end, tenacious and slimy pus escaped. An abscess lay above and behind the top of the bladder. The bladder itself was 11.5 cm. long, and the distance from the vertex to the umbilicus was 8.4 cm. The bladder appeared to be independent of the first abscess (*a*). Above the surface of the larger abscess (*a*) was a smaller one (*b*), the size of a bean. The cavities of both of these were reddish. Above this point the urachus appeared as a cord, accompanied by the umbilical arteries. The mucosa of the bladder was pale, not ulcerated. On the mucosa of the vertex of the bladder was an extravasation the size of a pin-head, and in the middle of this was a punctiform depression through which a

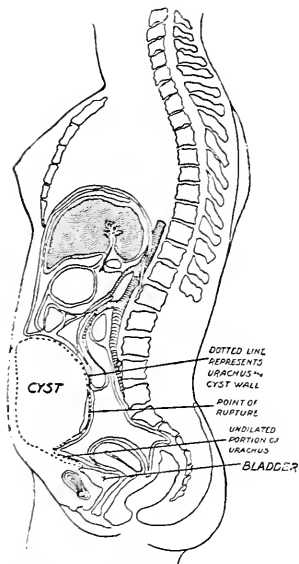


FIG. 243.—URACHAL CYST. (After W. R. Weiser, Case 2, Fig. 2.)

The urachus was patulous down to within three-eighths of an inch of the bladder. Above that it had dilated into a large cyst. The urachus was ligated and severed and as much as possible of the suppurating cyst-wall was cut away. The abscess cavity was washed out and drained.

bristle could be passed into abscess (*a*). The cavity of abscess (*a*) was 1 cm. long, 0.6 cm. broad. From this abscess cavity a bristle could be passed into abscess (*b*) so that the connection between the two was easily followed. From abscess (*b*) the urachus could be traced 0.5 cm. toward the umbilicus. Microscopic examination of the walls of the abscesses (*a*) and (*b*) showed that they were inflammatory urachal cysts. In some places the characteristic several layers of epithelium were in evidence; at other points the inner surface of the cyst was ulcerated and the connective tissue showed small-round-cell infiltration. The entire length of the urachus in this case was 4 cm.

\* Wutz, J. B.: Ueber Urachus und Urachuscysten. Virchows Arch., 1883, xcii, 387.

LITERATURE CONSULTED ON ABSCESS IN THE ANTERIOR ABDOMINAL WALL,  
BETWEEN THE UMBILICUS AND THE SYMPHYSIS, DUE TO INFECTION OF  
URACHAL REMAINS AND OF URACHAL CYSTS.

- Arrou: Kyste suppuré de l'ouraqué. Bull. et Mém. de la Soc. de chir., Paris, 1910, xxxvi, 832.
- Baldwin, J. F.: Large Cysts of the Urachus. Surg., Gyn., and Obst., June, 1912, xiv, 636.
- Bryant, T.: Brit. Med. Jour., 1898, i, 1390.
- Fischer, H.: Die Eiterungen im subumbilicalen Raume. Volkmann's Sammlung klin. Vorträge, n. F., No. 89 (Chir. No. 24), Leipzig, 1894, 519.
- Heinrich: Ueber beschränkte, sogenannte äussere oder tuberculose Peritonitis bei Kindern, oder über Entzündung der subkutanen Schicht der Bauchwand und über die Bildung von Abszessen und Verhärtungen daselbst. Jour. f. Kinderkrankheiten, 1849, xii, 6.
- Van Hook, W.: Abscess Formation in the Patent Urachus. Amer. Jour. Obst., New York, 1894, xxix, 624.
- Hörnig, P.: Zur Kasuistik der Urachuseysten. Inaug. Diss., Leipzig, 1905.
- Legg, J. W.: Cases of Hardening of the Linea Alba and Umbilicus. Saint Bartholomew's Hospital Reports, 1880, xvi, 251.
- Lexer, E.: Ueber die Behandlung der Urachusfistel. Arch. f. klin. Chir., 1898, lvii, 73.
- Nicaise: Ombilic. Dictionnaire encyclopéd. des sciences médicales, Paris, 1881, 2. sér., xv, 140.
- Page, C. C.: Cyst of the Urachus. The Post-Graduate, New York, 1902, xvii, 1094.
- Vaussy, F.: Des phlegmons sous-péritonéaux de la paroi abdominale antérieure. Thèse de Paris, 1875, No. 445.
- Weiser, W. R.: Cysts of the Urachus. Annals of Surg., 1906, xlv, 529.
- Wutz, J. B.: Ueber Urachus and Urachuseysten. Virchows Arch., 1883, xcii, 387.

## CHAPTER XXXIV.

### URACHAL CAVITIES BETWEEN THE SYMPHYSIS AND UMBILICUS COMMUNICATING WITH THE BLADDER OR UMBILICUS OR WITH BOTH.

General consideration.

Symptoms.

Differential diagnosis.

Treatment.

Instance of a urachal cavity between the symphysis and umbilicus and communicating with the bladder or umbilicus or both.

FIGS. 244 and 245 graphically illustrate urachal cavities communicating with the bladder. Fig. 246 shows in a schematic manner the way in which a distended urachus may open at the umbilicus. Dilatation of the urachus with the escape of urine from both the bladder and umbilicus is indicated in Fig. 247, while in Fig. 248 we see the tremendous quantities of stagnant urine that may be forced little by little into the pervious urachus when the bladder contracts during micturition. Finally, the valve-like opening is overcome and there is a sudden gush of ammoniacal urine from the urethra; or an opening may develop at the umbilicus; or the urine may escape from both the urethra and the umbilicus.

*Sex.* — Of the cases here recorded, and in which data as to the sex are available, 14 were in males and 12 in females.

*Age.* — The youngest patient (Savory's) was thirteen months old. Weiser's patient, a woman of seventy-five, was the oldest. The age table is as follows:

Under ten years of age . . . . .	4 cases
Between ten and twenty years of age . . . . .	2 "
Between twenty and thirty years of age . . . . .	7 "
Between thirty and forty years of age . . . . .	1 case
Between forty and fifty years of age . . . . .	4 cases
Between fifty and sixty years of age . . . . .	1 case
Between sixty and seventy years of age . . . . .	1 "
Over seventy years of age . . . . .	2 cases

These figures are of only relative value. Bramann's patient, who came under observation at twelve, had definite symptoms when nine years old. Freer's patient came under treatment at fifty-four, but from the history it was evident that symptoms were first noted when the patient was seven years old. Newman's patient was thirty-nine years old, but he had had an enlargement in the lower abdomen as long as he could remember. Vaughan's patient, a man of forty, had experienced pain in the suprapubic region when seventeen.

#### SYMPTOMS.

The chief symptoms are those referable to the bladder and to the development of a tumor between the symphysis and umbilicus. When infection occurs, constitutional disturbances are superadded.

A reference to the accompanying histories will show that the vesical symptoms varied greatly. Some patients complained of frequent micturition, others of incontinence, while others had difficult micturition, retention, or an almost total inability to void.

In some the vesical symptoms had been of short duration; others had had defi-

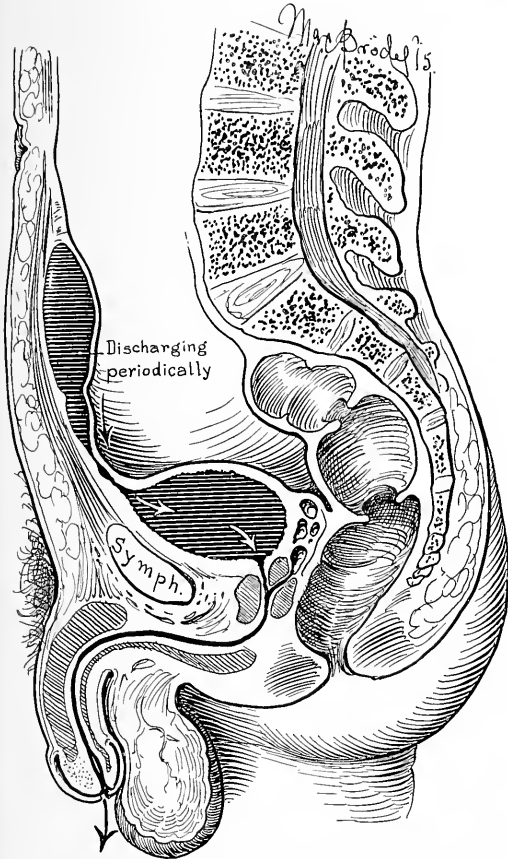


FIG. 244.—A DILATED URACHUS COMMUNICATING WITH THE BLADDER. (Schematic.)

Where such a condition exists, when the bladder contracts during micturition part of the urine escapes from the urethra and part may be forced into the urachal sac. Finally the urachal sac will empty itself into the bladder.

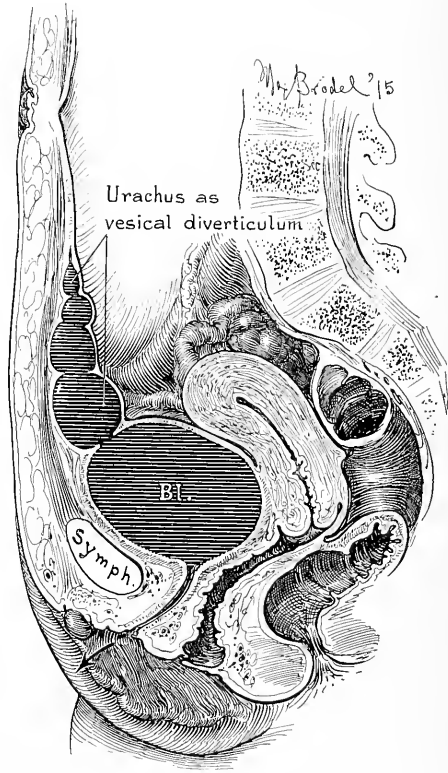


FIG. 245.—LARGE ACCUMULATION OF URINE IN A PARTIALLY PATENT URACHUS. (Schematic.)

Some patients give a history of cystitis, and a few months later a hard, globular tumor is noted between the umbilicus and symphysis. After the bladder has been emptied with a catheter the tumor still persists. Finally, after a very large amount of fluid has accumulated, it may all be discharged at once through the bladder, or the urachus may open at the umbilicus, allowing the accumulated urine and pus to escape by this avenue. In these cases there is usually a periodic filling and emptying of the urachal sac.

nite bladder disturbances for years. In Patel's case, for example, a child three years old had had incontinence of urine day and night since birth, the urine being passed involuntarily and at frequent intervals. In Freer's patient, a woman fifty-four years old, vesical symptoms were first noted when she was seven years old. Schnellenbach's patient, who was sixty-six years old, had had frequent micturition for one year and pressure was necessary to start the flow. When the patient was

catheterized, 1500 c.c. of urine came away. Worster's patient gave a history of having developed a cystitis with incontinence after diphtheria, and eleven years before coming under observation had passed a large amount of pus from the urethra.

In some cases the urine was turbid and contained pus and occasionally blood. In other cases the urine was clear; occasionally, as in Graf's, Lexer's, and Matthias'

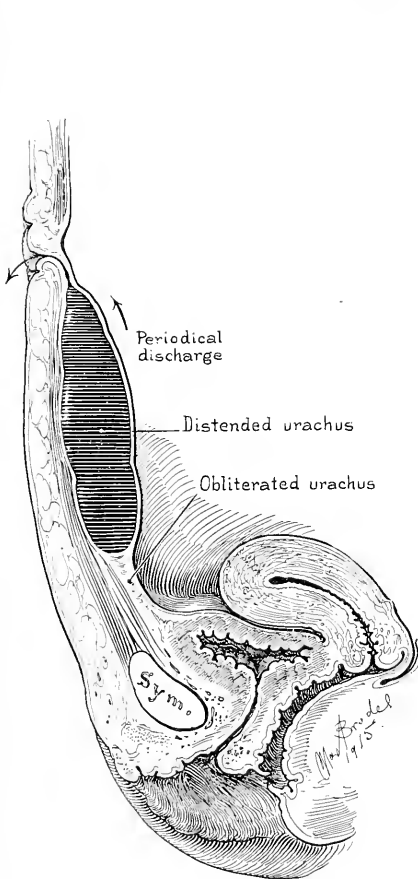


FIG. 246.—AN INFECTED URACHUS OPENING AT THE UMBILICUS. (Schematic.)

Occasionally urachal remains become infected, and after a time open at the umbilicus. In those cases in which the vesical end of the urachus is closed there is no escape of urine from the umbilicus, the discharge being purulent or slimy in character.

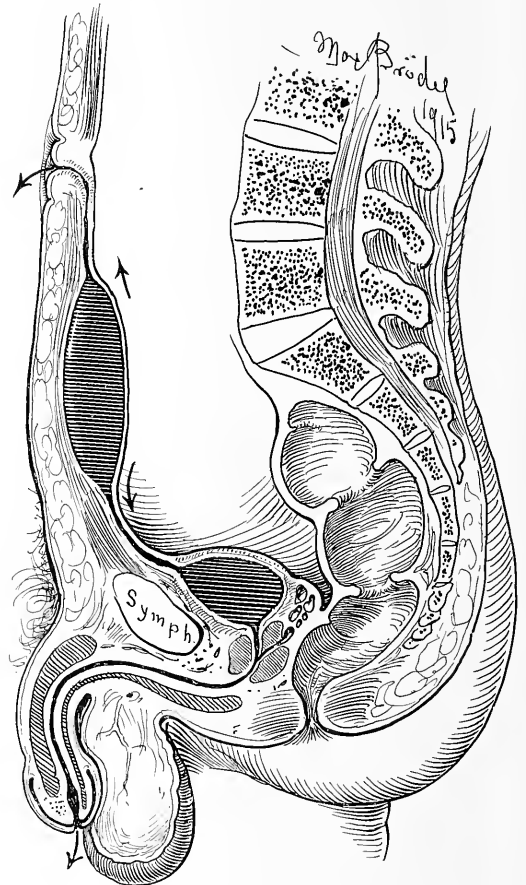


FIG. 247.—A PATENT URACHUS DILATED IN ITS MIDDLE PORTION. (Schematic.)

In such cases the middle portion of the urachus may become markedly distended, sometimes containing a liter or more of decomposing urine. (See Fig. 248.)

cases, the patients had previously had a gonorrheal infection. This naturally confused the clinical picture to some extent.

**Pain.**—More or less pain in the lower abdomen was a frequent symptom. In Bourgeois' case there was an almost insupportable feeling of tension in the lower abdomen, and the suprapubic region was particularly sensitive after fatigue. In Matthias' case there was a feeling of pressure in the lower abdomen, accompanied by malaise. Worster's patient had to bend forward at an angle of 45 degrees to



get relief, and was incapable of stooping down to pick up anything. Newman's patient suffered much pain, walked with difficulty, and had an anxious expression. Hind's patient had a steady pain in the lower abdomen. Suddenly something gave way, there was a feeling of relief, and a large amount of pus escaped from the bladder.

**The Umbilicus.**—With the progress of the disease the umbilicus in about half of the cases became inflamed and ruptured, with the escape of pus, and later of urine. In Bourgeois' case a small, soft, red tumor the size of an almond developed at the navel. During micturition it would become prominent and painful. It was opened and urine escaped.

Bramann's patient, two years after vesical symptoms had been noted, had a sudden discharge of urine from the umbilicus. In Hastings' case the urine for a time ceased entirely to pass from the urethra. On one occasion, when the patient had not voided at all for a long period, there was a sudden gush of two quarts from the umbilicus.

Lexer's patient, one and a half years after the onset of symptoms, complained of pain in the umbilical region. The tissues swelled up, became red, and a quantity of purulent material escaped. On pressure pus and urine were discharged from the umbilicus. Savory's patient developed a tense umbilical swelling two to three inches in diameter. This was tender during micturition. It was opened later, pus escaped, and finally nearly all the urine was passed by this avenue.

In Schnellenbach's case there was pain in the umbilical region, followed by the escape of pus. Vaughan's patient had poultices applied to the umbilical region. Two weeks later pus and urine passed from the umbilicus. Occasionally the opening would close for a couple of days. This closure was accompanied by much pain,

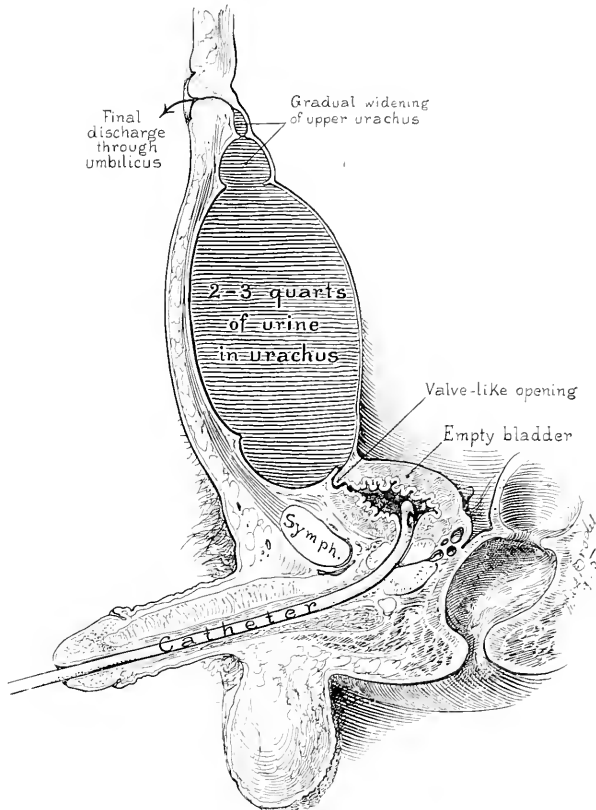


FIG. 248.—ACCUMULATION OF A LARGE QUANTITY OF URINE IN A URACHAL POCCH. (Schematic.)

Occasionally the urachal pouch is very large, and when the bladder contracts, part of the urine escapes from the urethra, part is forced up into the sac. An opening may or may not exist at the umbilicus. If there be no exit at the umbilicus, the valve-like opening between the urachus and bladder is after a time temporarily overcome, and suddenly there escapes from the bladder a large quantity of ammoniacal urine mixed with pus, the urachal tumor at once disappearing. Such a sac will fill up and empty periodically.

which was not relieved until the fistula reopened. The discharge was so offensive that the patient could not mingle with his friends. Worster's patient also developed a tumefaction in the umbilical region, followed by the escape of pus and urine.

The opening in Weiser's Case 3, did not develop at the umbilicus, but 2 inches below it. Urine only escaped; at no time was there any pus.

When the infection of the urachus extends up to the umbilicus, it is but natural that the latter should be secondarily involved, particularly when much tension exists in the sac.

Constitutional symptoms have not been at all prominent in these cases, evidently because there was a certain amount of drainage by the bladder, umbilicus, or both. In Hastings', Lexer's, and Morgan's cases fever was present, and in Morgan's case there was vomiting accompanied by diarrhea.

The carefully recorded case reported by Hastings in 1829 (p. 589) is well worth a thorough study. This case clearly shows that, notwithstanding most alarming symptoms, such as convulsions, the patient may recover. Savory's patient, a sickly child thirteen months old, died; in this case the inflammatory process had extended to the abdomen, as indicated by the adherent omentum. Ball's eight-year-old child died of peritonitis.

In Nicaise's (p. 597) and Roser's (p. 598) cases the patients successfully passed through a pregnancy while suffering from an infected urachal cyst. Roser's patient miscarried during a subsequent pregnancy four years later.

The urachal cyst varies considerably in size. It is attached to the bladder below and to the umbilicus above, and any great increase in size, as a rule, will be in its central portion. In Bramann's case the tumor resembled a long sausage. In Worster's patient it was recognized as a large cord, two inches in diameter. In Freer's case, when the patient was fourteen years old, it was the size of an apple, but when she came under observation, at fifty-four, it was much larger. In Patel's case the tumor was the size of two fists. Vaughan's patient had a pyriform tumor three inches long, and having a capacity of about three ounces. Schnellenbach's tumor was the size of a head, while in Timmerman's case the sac contained about 1500 c.c. of fluid.

Urachal cysts communicating with the bladder can hardly reach as large proportions as some of those that have no external opening. In Roser's case, however, notwithstanding the opening into the bladder, the sac contained between three and four liters of fluid.

The walls of the sac may be thin or thick, depending in a large measure upon the amount of inflammatory reaction. In Newman's case the walls were thin; in Bramann's case they were several millimeters thick, and in Matthias' case they varied from 2 to 20 mm. in thickness.

The interior usually consists of but one cavity. The inner surface may be perfectly smooth, or lined with granulation tissue. On histologic examination the inner surface may have a lining of transitional epithelium, as noted in Bramann's case, or of one layer of squamous epithelium, as found by Schnellenbach. In the latter's case the underlying stroma showed small-round-cell infiltration.

The cyst fluid in Patel's case was pale yellow. In the greater number of the cases it consisted of urine and pus. The urine in Newman's and in Roser's case was very ammoniacal. In Vaughan's case the cavity contained laminated clots.

## DIFFERENTIAL DIAGNOSIS.

The history of cystitis, coupled with the development of a tumor just above the symphysis, is strong presumptive evidence of a dilated urachus, particularly if the tumor increases in size when the patient has not voided for several hours, or if it decreases markedly in size after catheterization, accompanied simultaneously by pressure on the tumor. There are some cases, however, in which the effort to void forces a large part of the urine out of the bladder into the sac, only a portion escaping from the urethra. In such cases the tumor is larger after the bladder has been emptied.

With the aid of the cystoscope the diagnosis becomes more easy. In Matthias' case, for example, on exploration of the bladder a transverse oval opening was found near the top of the anterior bladder-wall. This passed into a funnel-shaped diverticulum, which extended upward toward the umbilicus.

Occasionally a suppurating dermoid or an inflamed appendix ulcerates through into the bladder. When the dermoid opens into the bladder, the tumor is situated in one side of the pelvis. The urachal tumor, on the other hand, is in the mid-line, and lies in the anterior abdominal wall. Furthermore, in the case of a dermoid cyst, on cystoscopic examination it may be possible to see a tuft of hair projecting from it into the bladder. When an appendix opens into the bladder, there has usually been a definite history of appendicitis and the discharge passing from the bladder has a distinctly fecal odor. The following case although not exactly germane to the subject has several points in common, and is of such interest that I shall briefly report it.

In May, 1907, I saw a very interesting case of extra-uterine pregnancy, in which, long after the death of the fetus, the sac opened into the bladder. The patient, L. S., colored, aged thirty-three (Gyn. No. 13806), was admitted to the Johns Hopkins Hospital on May 3, 1907. For the previous five years she had complained of much pain in the lower right abdomen. This was usually dull, and occasionally accompanied by nausea. Three years before admission she was supposed to be pregnant and to have proceeded to about the eighth month. Severe, labor-like pains lasting five minutes suddenly developed, and the patient passed blood from the uterus. Shortly afterward she noticed that the abdominal girth was diminishing, and that a hard, tender lump was present in the right lower abdomen. This gradually became smaller. She gave no history of chills or of fever, but had had some vomiting, had suffered from pain from time to time, and had lost in strength and in weight.

On admission the right lower abdomen was distended by an irregular nodular mass, which on palpation gave a peculiar feeling of crepitus. On pelvic examination the uterus was found slightly enlarged and lying posteriorly. On the right side was a pelvic mass attached to the side of the uterus.

On catheterization under ether a large amount of thick, tenacious urine came away, and the catheter came in contact with a substance feeling very much like a stone.

Operation.—A median incision, after liberation of the adherent omentum, disclosed a large, irregular mass in the right lower abdomen. The large and small bowel were found densely adherent to the sac. The small bowel was dissected free, but its coats were slightly injured.

The sac contained a large number of fetal bones (Fig. 249). The bladder was

densely adherent to the mass, and after it had been freed, an opening was found to exist between the sac and the bladder. One of the long bones, a femur, was seen projecting from the sac into the bladder, and the portion lying in the bladder was heavily coated with urinary salts (Fig. 250). The vesical opening was closed.

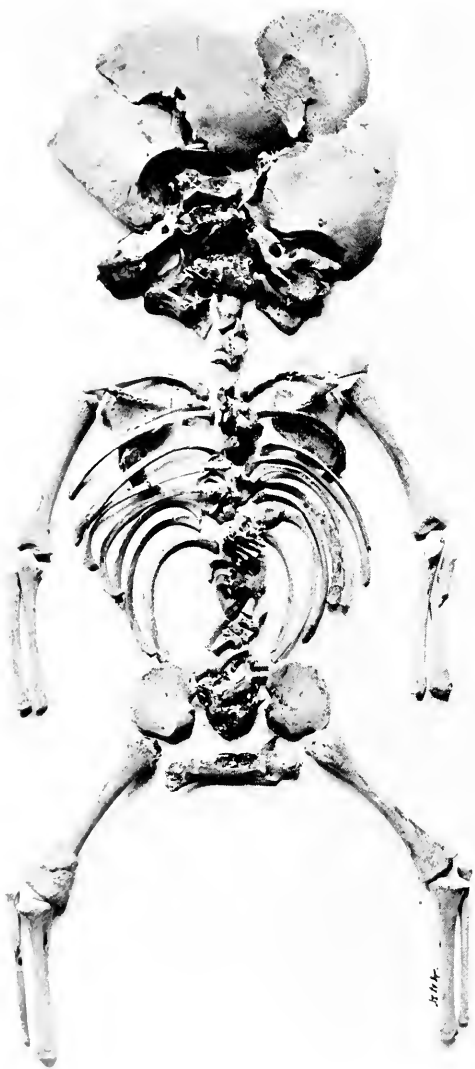


FIG. 249.—FETAL BONES REMOVED FROM AN OLD EXTRA-UTERINE PREGNANCY SAC.

Gyn. No. 13806. The bones have been roughly assembled. They are very well preserved. The ends of two long bones projected into the lumen of the cecum and one into the cavity of the bladder. The end of this bone is heavily coated with phosphates. This is particularly well shown in Fig. 250.

able merely to open up and drain the sac. If possible, at the same time the bladder should be separated from the sac and the vesical opening closed. The sac is then packed and allowed to contract down.

In the cecum, near the ileocecal valve, long bones projected from the fetal sac into the lumen of the bowel. There was a second opening into the large bowel six inches above the ileocecal valve. After closing the intestinal openings and removing the appendix, which was thickened and indurated, I also removed a parovarian cyst from the right side. The abdomen was then drained. The patient made a good recovery.

In such a case as this the previous history pointed to a pregnancy. Bimanual examination revealed an intra-abdominal tumor situated on one side, and not in the mid-line. Cystoscopic examination would have determined the presence of a foreign substance projecting into the bladder.

From the foregoing it is seen that urachal tumors connected with the bladder are relatively easy to diagnose.

#### TREATMENT.

Where a marked infection is present, it is advisable to open up and drain the sac. If possible, at the same time the bladder should be separated from the sac and the vesical opening closed. The sac is then packed and allowed to contract down.

If there is little danger of infection, the umbilicus is encircled and removed, together with the sac, and the bladder opening closed.

The vesical symptoms usually disappear as soon as the source of irritation—the dilated urachus—is eliminated.

**EXISTENCE OF A URACHAL CAVITY BETWEEN THE SYMPHYSIS AND UMBILICUS, AND COMMUNICATING WITH THE BLADDER OR UMBILICUS OR BOTH.**

Quite a number of the cases in the literature were not sufficiently definite to warrant citation; only those that clearly illustrate the condition have been selected.

**Cystitis with Tumor Formation in the Bladder.**—In 1882 Ball\* saw a boy eight years old who had suffered from incontinence of urine at night from birth, and during the previous six weeks also by day. In March, 1882, the urine was bloody and contained pus, but the boy improved, although he was still complaining of pain in the lower abdomen. When he next came to Ball, in January, 1883, he had an umbilical fistula, which he stated had appeared three weeks previously after rupture of an abscess. Since that time all the urine had passed through the navel. The urethra was very small, but later a moderate amount escaped by this passage also.

The treatment consisted in cauterizing the opening. This was done three times. The parts remained healed only for a short time. A fourth operation was of a plastic nature; the fistula remained closed for two months. One month later the boy died of peritonitis.

At autopsy the urinary organs were removed entire. On the next day the cavities were first injected with colored lard through an opening in one of the ureters. A minute hole about  $1\frac{1}{2}$  inches below the umbilicus and  $2\frac{1}{2}$  inches above the fundus of the bladder was found. From this urine had escaped into the abdominal cavity. In the upper abdomen there was abundant evidence of a recent peritonitis. The omentum was adherent to the anterior abdominal wall, apparently as the result of a long antecedent inflammation. The amount of fluid in the abdominal cavity was small, but there was an abundance of lymph matting the abdominal viscera together.

\* Ball, C. B.: Case of Pervious Urachus with Remarkable Disease of Bladder. *Trans. Acad. Med. Ireland*, 1883-84, Dublin, 1884, ii, 376. This case is probably identical with that referred to by Freer in 1887. Although the age does not correspond, the findings were precisely the same.



FIG. 250.—A PHOSPHATIC DEPOSIT ON THE END OF A LONG BONE.

Gyn. No. 13806. One end of this bone projected into the bladder and has a heavy covering of urinary phosphates. This is clearly evident in the lower part of the picture.

The ureters and pelves of the kidneys were much dilated. The bladder was very small and firm; the walls were much thickened. From the fundus of the bladder to the umbilicus extended a tongue-like cavity,  $2\frac{1}{2}$  by  $1\frac{1}{2}$  inches. This was situated between the peritoneal covering and the muscular layers of the anterior abdominal wall. It was in the anterior wall of this cavity that the fatal rupture had taken place.

During the separation of the bladder from the other pelvic contents it was found that the viscus was surrounded by cicatricial adhesions. The bladder-walls were enormously hypertrophied, and projecting into the cavity were a number of new-growths which resembled the columnæ carneæ of the heart. Some were attached by one end only to the vesical wall, the other end being free in the cavity; others were attached at both ends, but were free along the sides, so that a probe could be passed between them and the bladder-wall. Microscopic examination showed that they were composed of fibrous tissue with a covering of mucosa.

The bladder was divided into two compartments by a septum. This was attached posteriorly about the middle of the trigonum. Immediately above the septum was a minute opening leading off into the cicatricial tissue in front of the bladder. There had evidently been an extravasation of urine which had become localized as the result of an inflammation.

The fundus of the bladder communicated with the cavity lying between it and the umbilicus by a wide opening. The cavity contrasted remarkably with the bladder proper. Its walls were extremely thin and the inner surface smooth. The openings by which the extravasation had taken place into the peritoneal cavity were two in number—one a small aperture, the other a rent apparently of recent origin.

Whether this case was one in which the urachus had remained patent up to the umbilicus and in which, upon supervention of bladder obstruction, suppuration had occurred at the umbilical cicatrix, leaving a fistulous opening, or whether, in consequence of an extravasation of urine in the neighborhood of the fundus, an abscess cavity had been formed which followed the track of the obliterated urachus, are among the interesting pathologic features of the case.

**An Abscess Between the Umbilicus and Symphysis Opening at the Umbilicus.**—On August 7, 1821, Bourgeois\* presented to the Paris Society a young soldier, aged twenty, who had at the lower portion of the umbilical cicatrix a granular excrescence the size of a small lentil. At its summit was a minute cavity, from which there escaped, drop by drop, and sometimes in a jet, a fluid which resembled urine. The patient had pain in the anterior abdominal wall which extended from the pubes to the umbilicus. Several times after fatigue the discomfort became severe and it was necessary to apply liniments. Later he had an attack of retention of urine and complained of a feeling of insupportable tension. After several days a round tumor developed. It was the size of an almond, and was red, soft, and fluctuating. When the patient attempted to urinate, this mass became tense. He was brought to the hospital and came under the care of Larrey, who incised the tumor. The skin was very thin, and there escaped a large quantity of serosanguineous and purulent fluid of a strongly urinary odor, which suggested a communication between this cavity and the urinary tract.

\* Bourgeois: Jour. gén. de méd., année 1821, lxxvi, 219.

**Tumor Formation Between the Umbilicus and Symphysis Due to Remains of the Urachus.**—Bramann,\* in 1887, reported a case from von Bergmann's clinic. The patient was a girl of twelve who had been normal until her ninth year. She then complained of pain and frequent micturition, and there was a discharge of pus and a little blood from the bladder. Two years later the urine suddenly came through the umbilicus and continued to pass by this route, although her physician tried to close the opening by cauterization. The urachus was dissected out and the bladder opening closed. A fistula followed, and this still persisted up to the time that the case was reported. When she came under observation a granulation the size of a pea was detected at the umbilicus; in the center of this was a depression from which urine escaped. Behind the abdominal wall, in the median line, and below the umbilicus, and reaching to the symphysis, was a long, sausage-shaped tumor, which was soft and adherent to the umbilicus, but movable low down. Rectal examination showed that the lower end passed to the bladder. The urethra was normal.

After appropriate treatment for the cystitis a radical operation was undertaken. The fistulous tract was dissected out as far as the bladder, but the peritoneum tore at one point and the omentum protruded. It was wiped off and replaced and the peritoneum closed. The urachus was several millimeters thick, dark red, yielding, and lined with a membrane resembling mucosa. Here and there it was apparently lined with granulation tissue. It opened directly into the bladder. Microscopic examination showed that the canal was lined with transitional epithelium, next to which was connective tissue, and external to this non-stripped muscle-fiber. After operation the fistula persisted.

**Escape of Urine From the Umbilicus.**†—The patient was a married woman, forty years of age, suffering from what was said to be a vesico-umbilical fistula. This patient came under Freer's care while he was resident surgeon at the Ward's Island Hospital. She complained of a chronic purulent discharge from the umbilicus, as a result of which she had become so exhausted that she was scarcely able to walk. Freer discovered at the umbilicus a fistulous opening. A uterine sound was introduced and glided without obstruction downward almost its entire length, and by giving it a lateral motion, Freer found that it entered a cavity which had a breadth of almost three inches in its widest portion. On removal of the probe pus welled up from the opening, and when pressure was exercised from below upward, several ounces of pus escaped. The cavity was washed out with a 2 per cent carbolic-acid solution, and it was not until the disproportion between the amount of fluid injected and that which returned was noticed that the true nature of the case was surmised. This was afterward proved by the injection of a starchy solution, after which the bladder was emptied and the iodine test applied to the evacuated fluid, which yielded the characteristic appearance of the blue iodide of starch. The patient was put on a nourishing diet, and after local treatment in a short time the purulent discharge ceased and the fistula closed spontaneously. She stated that a similar result had been achieved at other hospitals on previous occasions, but that the fistula, after remaining closed for a short time, would then reopen, with a repetition of the above symptoms. Sometimes,

\* Bramann, F.: Zwei Fälle von offenem Urachus bei Erwachsenen. Arch. f. klin. Chir., 1887, xxxvi, 996.

† Freer, J. A.: Abnormalities of the Urachus. Annals of Surg., 1887, v, 107.

when she strained, urine would be forced up through the opening, but this was so infrequent that she considered it of slight importance. She had no difficulty in passing the urine by the natural channel.

**Cyst of the Urachus Communicating With the Bladder.**—Freer\* cites a case reported by Helmuth in *The Homeopathic Journal of Obstetrics*, 1884, vi, 24. This patient was a married woman, fifty-four years of age, of small stature and slight build. At the age of seven years her abdomen appeared to be enlarged; at fourteen a tumor the size of an apple appeared at the umbilicus and burst, sending forth a stream of fluid with considerable force. Her menses ceased at the age of forty-four, after which her abdomen became enlarged and sensitive to pressure. Incontinence of urine was a source of great discomfort to her, especially at night, when the dripping would awaken her. Helmuth withdrew with the aspirator about a quart of viscid, dark fluid, which showed "inflammatory" and pus corpuscles. Subsequently, when performing an ovariectomy, after dividing the peritoneum, he says: "I came upon a substance which puzzled me. It looked something like a cyst-wall, but was so densely adherent to the abdomen at the umbilicus that it was impossible to separate the adhesions. Laterally, on each side of the incision, the substance disappeared. After vainly endeavoring to push this sufficiently aside, I determined to incise it, which I did. A gush of fluid followed, and for a moment I believed I had opened the sac. Upon introducing my finger into the incision I soon discovered that the canal communicated directly with the bladder. I then forcibly drew this emptied sac aside, and without difficulty removed the [ovarian] tumor. From some experience in suprapubic lithotomy I determined to bring the wall of the bladder-cyst together with carbolized catgut, which I did. A self-retaining catheter was placed in the bladder and the woman put to bed. The patient died on the evening of the fifth day from peritonitis." Helmuth says the patulous and cystic urachus, leading from the fundus of the bladder to the umbilicus, accounts for many peculiar symptoms detailed by the patient.

That the bursting of the umbilicus in early life, when the "water spouted up to the ceiling," was due to the rupture of the external wall of the cyst was proved by the cicatrix, smooth and white, which occupied the site of the umbilicus.

**Persistence of the Urachus in Adult Women.**—Garrigues† did an autopsy on a woman aged forty-five. He found that, owing to the presence of a dilated urachus, the bladder extended as far as the navel, where it was closed. The patient had been operated on for myoma ten days before and had died of nephritis. The urachus was noted at the time of operation. The bladder extended to the umbilicus and lay between the aponeurosis of the abdominal muscles and the transversalis fascia on one side, and the peritoneum on the other.

**An Infected Urachus Communicating With the Bladder and Umbilicus.**—Graf‡ cites the case of a man aged twenty. At twelve years of age he had inflammation of the diaphragm, and four years later gastric fever. A year and a half before Graf saw him he had noticed that the urine escaped from the umbilicus. The tissue in the vicinity of the umbilicus was somewhat swollen, reddened, and painful. He did not know whether he had had fever. On admission he was found to be pale and anemic. He had a frequent desire to

\* Freer, J. A.: *Op. cit.* † Garrigues, H. J.: *Med. Record*, New York, 1899, lvi, 720.

‡ Graf, Fritz: *Urachus-fisteln und ihre Behandlung*. Inaug. Diss., Berlin, 1896, 16.



urinate. He had pain in the abdomen, and from time to time fluid escaped from the umbilicus. Passing downward in the mid-line from the umbilicus was a hard cord, as wide as two fingers, which could be felt going toward the bladder. The symptoms indicated a vesical catarrh, and there was a gonorrhoeal inflammation of the urethra. After lavage of the bladder, carried out for three weeks, the patient was better. The pus had stopped escaping from the umbilicus.

Operation.—The umbilicus was cut around and the cord dissected out. The peritoneum was opened over an area of 10 cm. It was walled off with iodoform gauze; the bladder opening, which was about 0.5 cm. in diameter, was closed. The patient made a good recovery.

The inner surface of the fistula consisted of granular tissue. In places it had grown into the lumen. Only near the umbilical opening had the cavity an epithelial lining, the cells being of the squamous type.

A Singular Case of Ischuria.\* — “On the 9th of April, 1814, M. H., aged twenty-three, was admitted an in-patient of the Worcester Infirmary. She represented herself as having been particularly healthy. Within the last week she had been exposed to cold, whilst the catamenia were flowing abundantly. For the first day or two she appeared to suffer only from feverish symptoms; soon afterward, however, the secretion of urine became very deficient, and she had difficulty in passing it.

“On the evening of her admission she became much worse, and complained specially of pain and tenderness over the whole of the lower part of the abdomen and in the loins. There was vomiting and a disposition to convulsions. The lower part of the abdomen was much distended. A catheter was introduced, and ten ounces of urine were drawn off, after which the pain was relieved. She was ordered to take a scruple of cathartic extract immediately, and one drachm of sulphate of magnesia, dissolved in camphor mixture, three times a day.

“The next morning the bowels had not been moved. She was afflicted with severe headache, as well as the abdominal pains. She had passed no water, and was delirious during the night.

“She was cupped on the back, and had a blister applied, and took cathartic mixture every four hours till the bowels moved freely; after which she went into a warm bath.

“The symptoms remained for several days very much in the same state. Delirium usually came on during the night. No urine was passed by the natural effort, but about three ounces were drawn off by the catheter in the course of twenty-four hours. She very frequently vomited, and suffered much from pain, tenderness, and tension of the lower part of the abdomen.

“On the evening of the 17th insensibility came on, for which a blister was applied to the back of the neck; the pulse was sixty. An active aperient was given.

“On the 19th no improvement had taken place, for the vomiting was incessant, and the pain in the abdomen and back was more severe. Pulse, 80. She was bled three days in succession, with some alleviation of the pain, but the abdomen became generally enlarged and very tender; there also ceased to be any urine drawn from the bladder by the catheter. This continued to be the case for five days. The bowels were open. She took saline diuretics without avail.

\* Hastings, Charles: London Med. and Phys. Jour., 1829, N. S., vi, 515.

“On the 25th there was much vomiting, pain, and distention of the abdomen, but she passed a little urine. Pulse, 80. She was bled to eight ounces.

“On the 27th a bloody discharge appeared at the umbilicus, after which the abdominal pain and tension were relieved. She also passed some urine by the urethra. The vomiting was, however, worse than it had previously been.

“The bloody discharge from the umbilicus and the other symptoms continued very much the same till the 2d of May, when there was a discharge, of urinous appearance and smell, from the umbilicus. She had passed no urine by the urethra for three days. The head was very painful, the pupils dilated; pulse, 56; bowels costive. Some leeches were applied to the temples, and a blister to the back of the neck; a brisk purge was administered. The catheter was introduced, but no urine found in the bladder.

“The discharge of urine from the umbilicus continued till the 5th, when the catamenia appeared, but quickly vanished. The abdomen became less tense and tender; there was not so much vomiting; the bowels were open.

“From the 7th to the 9th there was no discharge of urine from the umbilicus, nor was there any passed by the urethra; as a consequence, the abdomen became much distended and severe pain followed, with vomiting. The tension was most remarkable at the umbilicus, forming a circumscribed tumor.

“On the 10th, in the morning, six ounces of urine were drawn off by the catheter; and in an hour after, two quarts of urine of the same appearance gushed from the umbilicus. This was followed by much relief of the abdominal pains. The discharge of urine from the umbilicus continued for three days and was accompanied with great improvement of the general symptoms.

“The amendment, however, did not last, for the discharge from the umbilicus again ceased, and for three days the vomiting, the headache, the abdominal tension and pain returned with their former severity.

“On the 17th the catheter was introduced into the bladder and no urine was found. In an hour after this, two quarts of urine passed from the umbilicus, and soon afterward great relief was experienced.

“From this time to the 25th there was little variation; but the young woman suffered during that interval very much from vomiting and daily passed urine from the umbilicus. The catheter was passed every day, and no urine was found, but the bladder contracted strongly on the instrument; sometimes, immediately after the catheter was removed, a discharge of urine would take place by the umbilicus, and once as much as three quarts were thus passed.

“On the 26th, for the first time after many days, four ounces of urine were drawn from the bladder. Each succeeding day this quantity was now increased and the quantity passed by the umbilicus was diminished. There was also a general improvement of the symptoms, with the exception of vomiting; this continued obstinate. All this time the medicine that she took was confined chiefly to the class of purgatives; blisters were also applied to the neck and epigastrium.

“The bladder was regularly emptied every day by the catheter for more than a month after this date, during which time the abdominal pain and vomiting subsided, and there was no discharge from the umbilicus. Early in July she began to pass some urine, and the power over the bladder was gradually restored. She was

discharged in the middle of July in tolerable health, but still often complained of pain in the pelvic region. She menstruated.

“Observations.—This curious case of ischuria is well worthy of consideration. The remarkable sympathy observable between the brain, the stomach, the kidneys, is common to all cases of this description, and is so obvious as not to require any further comment.

“The very remarkable feature in the case is the occurrence of the urinary discharge from the umbilicus many days after the ischuria had been noticed. Such instances, although rare, are not without parallel in the annals of medicine. Schenck relates two instances of this kind. In the one, a male, the urine was discharged in consequence of an obstruction at the neck of the bladder, ‘*tanquam mictione ex umbilico,*’ for many months without any detriment to health. In the other, a female, and more resembling the one now related, ‘*cum suppressa per multas dies fuisset urina, tandem per umbilicum urinam profudit.*’ (Schenck, *Obs.*, Lib. iii, de Urina, p. 489.)

“The interesting question is to determine in what manner the urine is conveyed to the umbilicus in these instances. The urachus offers itself as a means by which the discharge may be determined to that part, and it seems probable that, in the case of mechanical obstruction related by Schenck at the neck of the bladder, a channel of communication was formed by the urachus between the bladder and the umbilicus. But, in the case we now remark upon, there had been no urine secreted into the bladder long before its appearance at the umbilicus, nor was there for some time after; and the first discharge from the umbilicus was not of a urinary but bloody nature. We must consequently, I think, regard the urinary discharge in this instance as vicarious, and as proceeding probably from the peritoneal surface. This view seems confirmed by the great abdominal distention, which took place for some time previous to the discharge from the umbilicus, when it was invariably found, from introducing the catheter, that the bladder was empty, and that it contracted on the instrument.

“Some cases of this description have been placed upon record by eminent men worthy of great credit. There is none, perhaps, more deserving of attention than that by Platerus, which is thus related by the renowned Sennertus: ‘*Puellae cuidam annos natae tredecim, cum aliquando copiose minxisset, urinam subito suppressam esse, atque tunc aquam serosam ex aure dextra adeo affatim coepisset effluere, ut una vice mensurae duae sæpe emanarint, idque dies aliquot.*’ He then adds that, on diuretics being administered, the urine was passed freely from the bladder, and the discharge from the ear ceased; but as soon as the diuretics were discontinued, the discharge again took place from the ear, but was altogether removed by general terebinthinate remedies, and local repellents to the ear. The health did not suffer. (Sennerti Opera, Lib. iii, p. 8, § ii, cap. ix.)

“In our case it was evident that much inflammatory action was going on in the pelvic viscera previous to and during the discharge of urine from the umbilicus; and there was a considerable sympathy of the general health with the local inflammatory action.

“I may further add, as a notice to this case, that the young woman was again admitted into the infirmary in May, 1827, for paralysis of the lower extremities, from which she recovered by appropriate remedies. The urine for a time was drawn off by the catheter, but there was no return of the former disease.”

**Umbilical Urinary Fistula in a Middle-aged Man.\***—Case IV.—The patient was a middle-aged man, who complained of a tender and irritable bladder when he was jolted. A fixed pain developed just above the pubes, and he noticed an increased desire to urinate. A hardness could be detected above the pubes. Suddenly the patient felt something give way, and pus passed from the bladder through the urethra. He was greatly relieved. Recovery followed, and three years later he was well. Hind thought that in this case there had been an abscess of the patent portion of a urachus.

**Cyst of the Urachus.**—In discussing Douglas's paper Ill† said that recently he had removed a cyst of the urachus as large as two fists without difficulty. The patient was a woman who had some prolapse of the anterior vaginal wall, and when she attempted to pass her urine, some of it passed into the cyst and some escaped through the urethra. This did not have the effect, however, of producing an inflammatory condition about the cyst. The condition was annoying to her, because she had to pass her urine in installments, as it were.

The operation consisted in removal of the cyst and ligation of that portion of the duct which entered the bladder. As he was closing the wound he said to himself: "This is a dangerous procedure, and it is likely that this ligature will not destroy the epithelium and that the bladder will open in a short time." Some infiltration of urine taking place, he removed the ligature, cut the duct very short, turned in the edges, and closed it over, as a surgeon would do with an appendix stump.

**Cystitis Followed by the Opening Up of a Partially Patent Urachus, Producing a Urinary Fistula at the Umbilicus.**—Lexer‡ reports the case of a poorly developed young man, twenty years old, who said that previously he had never noticed anything abnormal at the umbilicus. A year and a half before admission, after several weeks of difficulty in urinating, the urine being cloudy, he had pain in the region of the umbilicus, the tissue in the vicinity of the navel swelled up and became red. Shortly after a quantity of purulent fluid escaped from the umbilicus. The bladder discomfort became more severe; he frequently had fever and chills and became thinner. In addition to a marked degree of cystitis there was blennorrhœa of the urethra. Gonococci were isolated from the urethral discharge. On account of the swelling and inflammatory infiltration, the fistula at the umbilicus was not visible, but the umbilical funnel filled up when pressure was made by the patient, and when pressure on the bladder was exerted the umbilical cavity filled up with pus and foul-smelling urine.

The cystitis was first treated. In the washing-out of the bladder purulent flocculi escaped from the umbilicus, so that finally the entire fluid escaped from the umbilical opening. Nevertheless, it was impossible to introduce a sound farther than 2 cm. into the fistula. By the third week the patient had improved greatly. He had no further fever, the urine was passed without pain, he looked well, and the escape of pus from the umbilical fistula had ceased. Urine, however, continued to escape from the umbilicus as soon as the bladder contained an appreciable amount of fluid.

On account of the gonococcus infection it was felt wiser not to leave in a perma-

\* Hind, W.: Diseases of the Urachus and Umbilicus. Brit. Med. Jour., 1902, ii, 242.

† Ill, Edward J.: Amer. Jour. Obst., 1897, xxxvi, 568.

‡ Lexer, E.: Ueber die Behandlung der Urachusfistel. Arch. f. klin. Chir., 1893, lvii, 73.

ment catheter. The abdominal walls were not so painful on pressure, and one could now make out a hard cord, the thickness of a finger, in the mid-line, extending from the umbilicus to the bladder. After the cystitis had subsided, closure of the umbilical fistula was considered. As it was impossible to introduce a sound far, an excision of the upper portion of the cord was undertaken. The umbilicus was dissected free, and the fistulous tract about 2 cm. below this point was opened. Here there was a small lumen into which a sound could be introduced without difficulty and carried toward the bladder region. The farther dissection of the cord was easily accomplished without injury to the peritoneum. Midway between the umbilicus and symphysis, however, it was impossible to avoid entering the abdominal cavity. From the opening in the peritoneum one could see the relation of the bladder very well. This cord spread out and passed without any definite margin gradually into the upper portion of the bladder, just as is the case in the embryo. Care was taken not to injure the general peritoneal cavity. The urachus was freed to the point where it entered the bladder. It was then cut across transversely, so that the entire tract from the umbilicus to the bladder was excised. A funnel-like opening, 1.5 cm. wide, was left in the bladder. Examination of the inner surface of the bladder showed that this organ was a long, thick-walled tube, similar to that noted in Bramann's case. The opening in the bladder was closed, and a drain laid into the incision. The wound had healed completely in four weeks.

At the end of two and a half years there was no evidence of any fistula, and the patient was completely cured, the only discomfort being frequent urination.

A Case of Patent Urachus Over One Inch in Diameter Forming a Tubular Prolongation of the Bladder.—Marshall\* reports the case of a woman, aged forty-three, who had complete proidentia. On opening the abdomen to suspend the uterus, and while making a short incision midway between the pubes and umbilicus, he found the subperitoneal fat very abundant. On dividing this he could see what appeared to be peritoneum. A nick having been made into it, a pair of scissors was passed upward and then downward to enlarge the incision.

On lifting the retroflexed uterus up to the abdominal opening and thus compressing the bladder, Marshall noted an escape of some clear fluid into the lower part of the wound. This aroused his suspicions. A bougie introduced into the bladder through the urethra entered the abdominal incision through a large opening. What was at first thought to be peritoneum was in reality the anterior wall of a patent urachus. The first cut upward had slit through the upper blind end in the peritoneum into the abdominal cavity. The downward cut had opened the peritoneum and both walls of the urachus.

The urachal opening was  $1\frac{1}{4}$  inches in diameter and formed a large opening in the conic-shaped bladder. The bladder was closed with a double layer of continuous catgut sutures and a catheter was kept in for one week. The patient made a good recovery.

Suppuration of the Persistent Urachus With Rupture into the Bladder and the Abdominal Wall. †—In November, 1901, a forty-eight-year-old man came to Mikulicz's clinic. He had had a gonococcal

\* Marshall: Jour. of Obst. and Gyn. of the Brit. Empire, 1907, xi, 259.

† Matthias, F.: Vereiterung des persistierenden Urachus mit Durchbruch in die Blase und in die Bauchdecken. Beiträge z. klin. Chir.; herausg. von Paul Bruns, Tübingen, 1904, xlii, 339.

infection ten years before, which had not been promptly treated. For the last few years he had had an abundant discharge from the urethra. Apart from this the patient had been well. Six months before admission, he began to have a pressure in the lower abdominal region and suffered from a general feeling of malaise. The urine was cloudy and contained whitish threads and flocculi. There was a cramp-like, sticking pain in the urethra. During the three months following this the patient lost weight and the urine was cloudy. Two months later there was again pain in the lower abdomen, and a tumor could be felt above the top of the bladder. Mikulicz found a firm, ill-defined tumor lying below the umbilicus. This occupied the mid-line and extended a little more to the right. It commenced three fingerbreadths below the umbilicus, and ended 5 cm. above the symphysis. There was a cord passing from the tumor to the umbilicus. The umbilicus itself appeared normal. Mikulicz thought that he was dealing with an abscess of the abdominal wall, and one that communicated with the bladder, and that its origin was due to the extension of a cystitis by way of a persistent urachus. Bladder irrigations were employed. When there was a large quantity of pus in the urine, the tumor became smaller and the patient felt better. The reverse was the case when the urine contained but little pus. The difference in the size of the tumor was manifested in its transverse diameter. When a large amount of pus escaped in the urine and the tumor had diminished to half its volume, a cystoscopic examination was made. In the anterior bladder-wall, in the neighborhood of the top of the bladder and in the mid-line, was a transverse oval opening passing into a funnel-shaped diverticulum. The walls of this could be seen for some distance, but the point ended in darkness.

Operation.—A median incision was made. The skin was dissected free from the tumor, which was covered with thick and edematous fascia, and on the left side the peritoneal cavity was opened. From this point the tumor was separated from the abdominal wall, and in the lower angle of the incision the bladder was recognized by means of a metal catheter which had been introduced from below. The tumor sat on the top of the bladder, and on the right and on the left, between the tumor and bladder, was a loop of small bowel which was separated without injury. The tumor was the size of a billiard ball, and sat as a cap on the top of the bladder. The muscular covering of the bladder extended over on it, particularly on the posterior surface. The peritoneal cavity was well walled off and the tumor opened. Its walls were 12 mm. thick, and the cavity was the size of a walnut. From it escaped an old clot mixed with pus. An attempt was made, by filling the bladder with 300 c.c. of salt solution, to find a communication with the abscess cavity. In this the operator was unsuccessful; no fluid escaped, but a sound could be passed from the cavity into the bladder. The tumor was separated from the bladder. The small opening in the bladder-wall was closed with catgut, and the muscularis, which formed two flaps over the tumor, was brought together. A retention catheter was introduced into the bladder and kept in place for ten days. The urine then came away spontaneously, and the pus disappeared almost completely. The extirpated tumor was the size of an apple and irregularly round. Its walls varied from 2 to 20 mm. in thickness, and there were irregular dilatations in the interior. It consisted of striated, dense connective tissue. Here and there were citron-yellow portions, undoubtedly fatty tissue. The inner surface of the sac, apart from dilatations, was uneven; no mucosa was visible.

Microscopic Examination.—Sections showed that the wall was made up of smooth muscle-fibers, connective tissue, and an inner zone consisting of old connective tissue containing many round-cells and small blood-vessels. There were hemorrhages, and here and there the tissue was necrotic. There was no evidence of epithelium. Mikulicz found a small opening in the wall of the tumor. This was lined with epithelium. It could be traced for a distance of 2 mm. in serial sections, and had a breadth of 1 mm. The epithelium lining the canal was several layers thick; only in a few places did it consist of a single layer.

In conclusion Mikulicz said that very probably the normal dilatation of the opening of the urachus in the bladder, being funnel-shaped, had allowed the cystitis to extend to the urachus, and through breaking of the wall there had resulted abscess formation in the musculature of the bladder-wall and of the abdominal wall to the umbilicus. Since the abscess originally lay within the bladder musculature, its rupture into the interior of the bladder near the actual opening of the urachus was not exceptional.

[There is no doubt in this case that there was an abscess between the bladder and the umbilicus. It was probably of urachal origin, but Matthias's description is not particularly clear.—T. S. C.]

Escape of a Calculus From the Umbilicus.\*—This case had been reported by Gennaro in 1890. After a mucopurulent discharge from the umbilicus had lasted several days, a calculus escaped from the umbilical opening. It consisted of urate of soda, phosphate of lime, and magnesia. The urachus was a diverticulum of the bladder. Gennaro thought that the calculus was due to fermentation of the stagnant ammoniacal urine.

A Case of Dilated Urachus Accidentally Opened During an Abdominal Section for Peritonitis. Recovery. †—A boy, aged five, was brought to the Children's Hospital, Brighton, on February 18, 1896. There was a history of vomiting and diarrhea for two days. On admission he was suffering with severe abdominal pain, but there was no marked tenderness. His temperature was 102° F. The next day he was much worse, and lay on his left side, with his thighs fully flexed. The distention, tenderness, and pain were more severe. There was no localized swelling. His diarrhea was almost constant. His temperature was 103.6° F., his pulse, 108. In the next five days there was some improvement in his general condition. The abdomen was still distended, but the vomiting and diarrhea were improved. On the ninth day, in the region of the bladder and extending nearly to the umbilicus, there could be made out a certain amount of resistance that was fairly sharply defined. Micturition was frequent, but there was no dribbling. On the suspicion that the swelling might be the bladder, a catheter was passed, but only about half an ounce of urine was drawn off. This did not affect the size or position of the hypogastric fulness. On February 27th the general condition was better, except that he was passing a large quantity of mucus by bowel. The distention and hypogastric fulness were less marked. On the evening of the next day, twelve days after the first symptoms, the boy was much worse, his vomiting had returned, and the distention was

\* Monod, Jean: Des fistules urinaires ombilicales dues à la persistance de l'ouraqué. Thèse de Paris, 1899 (obs. 47), 168.

† Morgan, G.: The Lancet, 1896, ii, 1154.

very severe. His temperature was 103° F. and his condition so critical that it was decided to operate at once.

An incision was made extending from the umbilicus to a point near the pubes. The deeper abdominal layers were divided carefully over a director. An incision was made into what was taken for the subperitoneal fat and peritoneum, and there was a gush of about one ounce of clear urine. The wound was at once clamped and a catheter was passed. The bladder was found to be quite empty and lying in the pelvis, but the catheter could be passed up into the wound in the cyst where the clamp was. After carefully dissecting around the cyst, Morgan opened the abdominal cavity and found signs of recent peritonitis, with flakes of lymph, but no pus. The abdominal cavity was flushed with hot water, and the intestines were carefully sponged. The boy was too ill to have a prolonged examination or have the mass dissected out, but it was certain that the cyst was in the mid-line, running up to the umbilicus and communicating with the bladder. After the bladder and cyst had been washed out with boric acid solution, the wound in the bladder was closed with a double row of silk sutures, the stitches not penetrating to the mucous membrane. The abdominal wall was also carefully closed. On the following day the boy was much better, but on the fourth day pus began to well up from the suture line. Three stitches were taken out and the pus cavity was irrigated. For ten days after this there was some escape of urine from the abdominal wound, but this became less and less, and the boy's general condition improved. Twenty-six days after operation the wound was closed and the boy was quite well.

*A Rare Variety of Cyst of the Urinary Bladder, Probably Arising From the Urachus, Cured by Operation.\**—A. M'V., a miner, aged thirty-nine, was admitted to the Glasgow Royal Infirmary on October 21, 1895. He complained of severe pain in the hypogastric region. This had commenced four days before, and had continued ever since. Coincident with the onset of the pain he found that he was unable to micturate, and his doctor had to pass a catheter. When the urine was drawn off, it contained a large quantity of blood. Vomiting came on soon after the onset of the pain and was followed by attacks of diarrhea.

On admission he was suffering considerable pain, had an anxious expression and walked with difficulty. The skin over the region of the bladder was red and blistered from the use of hot fomentations and applications of mustard. The abdomen was considerably swollen, very tense over the region of the bladder, and from the umbilicus to the pubes it was absolutely dull on percussion. After admission a catheter was passed and 20 ounces of urine, containing a large quantity of blood, were drawn off. This gave the patient considerable relief, but even after the bladder had been completely emptied, the dulness in the hypogastric region did not disappear. From the 1st until the 8th of November the patient's condition steadily improved, and at the latter date he was able to pass his urine without difficulty. On examination the abdomen still showed a considerable amount of swelling in the hypogastric region. The swelling in appearance greatly resembled a distended bladder.

Operation.—A free incision was made in the mid-line, midway between the pubes

\* Newman, D.: Three Renal Cases, a Case of Cyst of the Urachus, and a Case of Strangulated Hernia. Treated in the Surgical Wards of the Glasgow Royal Infirmary. Glasgow Med. Jour., 1896, xlvi, 20.



and the umbilicus. On incision into the transversalis fascia, a large quantity of gelatinous fluid escaped which had a strongly ammoniacal odor. The cyst-wall was thin and smooth, and its anterior wall was not covered with peritoneum. The cyst extended from the apex of the bladder to the umbilicus. After evacuation of the contents the cyst was washed out with carbolic acid solution, and a drainage-tube inserted. In the evening the dressing was found to be soiled with urine which had a strongly ammoniacal odor.

On November 16th the greater part of the urine was passing through the abdominal wound and a retention catheter was now introduced into the urethra. Notwithstanding this the urine continued to escape from the wound, and not until December 16th did the cyst become completely obliterated and the wound in the abdomen close. On careful inquiry into the history of the patient it was found that he had noticed a swelling in the hypogastric region as long as he could remember, but until this occasion it had never given him any trouble.

Probably a Partially Patent Urachus with Infection.\*—This patient was observed by Chopart. She was pregnant, and had suffered from retention of urine for some time. The abdomen became tender and painful. Fluctuation was felt, and was specially marked in the region of the umbilicus. An incision was made between the right rectus muscle and the umbilicus, and much pus escaped. On the following day the bed and the apparel of the patient were soaked with urine. This escaped for some time by the umbilicus until, after repeated catheterization, the urine commenced to pass through the urethra and the umbilicus closed.

Dilatation of the Urachus; Communication with the Bladder.—Patel's† patient was a child three years of age who, from birth, had incontinence of urine both day and night. The urine did not escape drop by drop, but at frequent intervals and involuntarily. There were no malformations.

Below the umbilicus was a voluminous tumefaction, fusiform, and prominent in its central portion. In its middle portion it was the size of two fists. It was exactly in the median line; above it reached the umbilicus, and below passed into the pelvis, although its termination could not be felt. It was movable. Catheterization yielded a small glass of clear urine. There was evidently a tumor lying behind the abdominal walls, adherent to the umbilicus, and clinically independent of the bladder.

A median incision was made below the umbilicus. The tumor was found adherent to the umbilicus. Half a liter of pale-yellow fluid escaped, which contained large quantities of albumin. The sac was lined with an irregularly wrinkled muscular layer. Above the finger impinged on the umbilicus. The inferior end was very narrow and was dilated with difficulty. It led to a small circular cavity in which the vesical trigonum was recognized. Removal of the diverticulum was not undertaken on account of the size of the tumor and of its probable adhesion to the peritoneum, and on account of the patient's age. The walls of the sac were sutured much in the way that cavities resulting from removal of hydatids of the liver are obliterated. The walls were brought together and a catheter was left in the blad-

\* Nicaise: *Ombilic*. *Dict. encyclopéd. des sci. méd.*, Paris, 1881, 2. sér., xv, 140.

† Patel: *Malformation congénitale de l'ouraque*. *Dilatation kystique de la partie intérieure de l'ouraque demeuré en communication avec la vessie; incontinence d'urine symptomatique*. *Capitonnage de la poche*. *Rev. mens. des maladies de l'enfance*, Paris, 1904, xxii, 77.

der. During the five days that the catheter remained in place there was some discharge from the abdominal wall. When the child left the hospital, the abdomen was soft. The bladder was large enough and the child urinated about every three hours. There was no incontinence. Recovery was permanent.

This case was also reported by Gabriel Renard.\*

**The Diagnosis and Treatment of a Case of Patent Urachus.** †—The patient was a woman twenty-five years of age. Six months previously she had begun to have pain in the umbilical region. Two weeks later a swelling had appeared at the umbilicus. This had ruptured, and since then pus had been discharging, except during occasional intervals of a week. A probe was passed through the umbilicus into the bladder, and the end emerged at the external urinary meatus.

The urachus was opened on a director about two inches above the symphysis. It showed a dilatation in the middle, with a constriction above, and below, where it connected with the bladder. The actual cautery was used to destroy about one inch of the lower portion of the urachus. The portion above was packed, a piece of iodoform gauze being passed through the fistula to the umbilicus. The bladder was accidentally opened, but at once closed with catgut. The patient made a good recovery.

**Urachal Cyst Communicating with the Bladder.**—Robinson‡ says: "I worked several years in the dissecting room, paying special attention to visceral and pelvic anatomy, but did not see any urachal cyst in but one autopsy (Fig. 251)." In this case the urachus was dilated, forming a fusiform tumor. It opened into

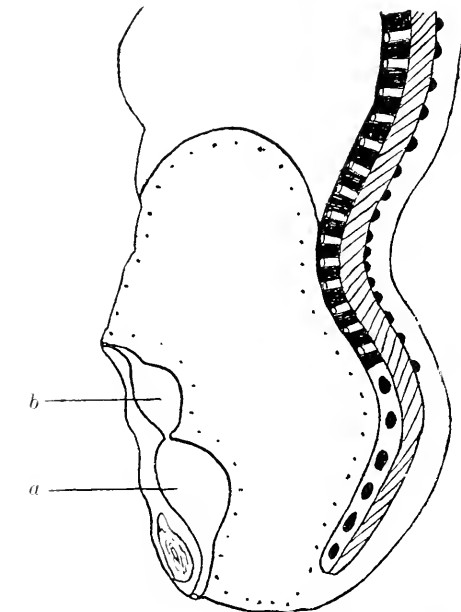


FIG. 251.—A DILATED URACHUS COMMUNICATING WITH THE BLADDER. (After F. BYRON ROBINSON.)

The urachus (*b*) is patent from the bladder (*a*) almost to the umbilicus. It is markedly dilated, and its cavity communicates directly with the bladder. It resembles a secondary bladder.

the bladder and extended upward as far as the umbilicus. . . . "I understand from veterinarians that the horse is one of the most typical animals to show urachal cysts, and that quite late in horse fetal life the urachus is found often quite a distance above the bladder."

**A Urachal Cyst Communicating With the Bladder.**—In Roser's§ case the urachal cyst had a small opening into the bladder (Fig. 252). When the patient wished to void, the contraction of the bladder muscles forced the

\* Renard, Gabriel: Sur un kyste de l'ouraque. Thèse de Lyon, 1905, No. 89.

† Reid, W. L.: Glasgow Hosp. Reports, 1899, ii, 76.

‡ Robinson, F. Byron: Annals of Surg., 1891, xiv, 336.

§ Roser, W.: Ueber Operation der Urachuscysten. Langenbeck's Arch. f. klin. Chir., 1877, xx, 473.

urine into the cyst more easily than through the urethra. The cyst, therefore, became more and more distended, until three or four liters of urine accumulated. When it was desired to empty the bladder, a catheter had to be introduced into it and the cyst was then pressed upon. In order to keep the patient free from trouble catheterization several times a day was necessary.

The patient had what appeared to be a greatly distended bladder when she was three months pregnant. A puncture was made in the linea alba above, and a large amount of urine removed. The pregnancy went to term. Four years later she had a similar attack when she was again pregnant. The old cyst had refilled. It was tapped from above, and the patient miscarried. The cyst again filled, and operation became necessary. The urine was ammoniacal, owing to stasis in the sac. There was foul urine in the cyst, which at that time had reached the umbilicus.

An extraperitoneal opening, about 3 cm. long, was made in the mid-line, and two chambers full of stinking ammoniacal purulent fluid escaped. There was temporary relief. A retention catheter failed to bring about closure of the bladder, and when last seen, the patient still had the urachal cyst opening into the bladder.

**Polypus of the Urinary Bladder with the Development of a Urinary Fistula at the Umbilicus.** — Savory's\* patient was a male, thirteen months old and sickly. Immediately beneath and partly surrounding the umbilicus was a firm, tense swelling, two or three inches in diameter. Its limits were not well defined. It was very tender, and pain was increased by attempts to void. The urine merely dribbled away. The child had been ill eight weeks. The first thing noticed was that micturition caused pain in the lower abdomen, followed by an almost constant desire to void. The stream was often interrupted temporarily and then started again.

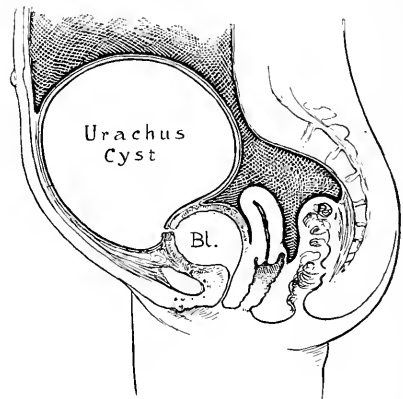


FIG. 252.—URACHAL CYST. (Redrawn by August Horn after W. Roser.)

The bladder itself looks normal, except that at the upper part anteriorly there is a small opening which communicates with a large cyst extending as high as the umbilicus.

The umbilical induration was incised and pus escaped; later urine appeared, and nearly all came this way.

**A u t o p s y .** — On section of the abdomen an abscess was found between the posterior surface of the abdominal parietes and the peritoneum and extending from the umbilicus almost to the symphysis. The omentum was adherent to the abdominal wall. The growth in the bladder stretched across behind the ureteral orifices, which were dilated. This mass was attached at each side, but was free in the center, and could block the urethra. It was a polyp. It was impossible to find the opening between the bladder and the abscess by which the urine escaped from the umbilicus.

**A Partially Patent Urachus.** † — Simon reports the case of a

\* Savory, W. S.: *Med. Times*, London, 1852, N. S., v, 106.

† Simon, Charles: *Quels sont les phénomènes et le traitement des fistules urinaires ombilicales?* Thèse de Paris, 1843, No. 80 (obs. 12), 26.

patient of Portal, a man forty-five years of age, who died shortly after a fall on the abdomen resulting in a severe injury to the bladder. Some time after the accident he had noticed that the urine was escaping at the umbilicus. Portal says: "On opening the body I found a tube which extended from the umbilicus to the bladder. This was cone-shaped. Its diameter toward the umbilicus was  $\frac{1}{4}$  inch and  $1\frac{1}{2}$  inches at the bladder. The thickness was unequal. The volume of the bladder did not exceed that of a small apple."

**An Infected Urachal Cyst Communicating With the Bladder.** \*—This patient, a man sixty-six years of age, came under Trendelenburg's observation on July 3, 1887. For a year or more he had had frequent urination. The urine was cloudy, and often much pressure was necessary to start it. Six months before he had noticed a swelling in the lower abdomen, above the symphysis. For three or four days he had had pain in this region, and soon after a spontaneous opening had appeared at the umbilicus from which a purulent fluid had escaped. Recently he had become weaker.

On admission to the hospital he showed, in the hypogastric region, a marked swelling about the size of a head. This began just above the symphysis and reached to the umbilicus. Rectal examination revealed an enlarged prostate, especially on the right, and above this a distended bladder. A very fine sound was passed from the umbilicus and entered into a large cavity. The fluid from the umbilicus showed round-cells undergoing fatty change. After catheterization with the removal of 1500 c.c. of cloudy urine the swelling to a large extent disappeared, but there persisted a long tumor reaching from the umbilicus to the symphysis.

**Operation.**—An incision was made between the umbilicus and the symphysis. Immediately behind the fascia was a sac containing about a liter of urine mixed with pus. A piece of the wall was removed, and the wound closed with drainage. A purulent fluid continued to escape from the sac. Microscopic examination of the wall showed it to be lined with one layer of squamous epithelium resembling that of the bladder. There was no muscle in the wall. The connective tissue contained many round-cells.

**A Dilated Urachus Communicating With the Bladder.** †—The patient was a very frail woman, weighing probably 85 pounds. At labor she had had a bad tear and developed a fever, from  $100^{\circ}$  to  $101.5^{\circ}$  F., for nearly six weeks. In the following spring she entered the hospital for operation, but later developed pain and swelling in the right side.

A median incision,  $2\frac{1}{2}$  inches long, was made. The peritoneum was exposed and cut, but the bladder was opened. The patient had just voided before the operation. The wound was closed, but the operator, in attempting to enter the peritoneum, got into the same cavity again. It proved to be an accessory bladder—really a dilated urachus—and contained  $1\frac{1}{2}$  to 2 pints of urine. A catheter introduced into the urethra could be passed into this cavity. It was closed and the patient recovered.

**Escape of Urine From the Umbilicus.**—Unterberger‡ reported the case of a woman, twenty-three years of age. She was supposed to have

\* Schnellenbach: Ueber die Urachuscysten. Inaug. Diss., Bonn, 1888.

† Timmerman, C. F.: Trans. Med. Soc. State of New York, 1904, 331.

‡ Unterberger: Retroversio-flexio uteri gravidi partialis incarcerata. Urachus-fistel. Monatschr. f. Geb. u. Gyn., 1900, xi, 657.

had an ovarian cyst that had ruptured through the umbilicus, and for three weeks clear fluid had continued to escape from the navel.

The trouble had begun with pain in the lower abdomen. This had become so severe that the patient had been forced to remain in bed and local applications had been applied. Urination and defecation at this time were normal.

The patient had fever and gradually became weaker. One month before her admission to the hospital urinary disturbances developed, and after a time the urine commenced to escape through the umbilicus and the pain disappeared. Pus sometimes escaped from the umbilicus with the urine.

For fourteen days before the patient entered the hospital no urine had been passed from the urethra. The umbilical opening had the caliber of a hair, and was surrounded by a small red zone. The abdominal walls were somewhat infiltrated. A catheter passed into the bladder entered for its entire length and about 2000 c.c. of urine mixed with pus were removed. The uterus, which contained a pregnancy, was retroverted and partially incarcerated. No operation was performed, but Unterberger regarded the case as one of patent urachus.

**A Dilated and Infected Urachus Communicating With the Bladder and Umbilicus.\***—A. W., white, male, aged forty, was admitted to the Georgetown University Hospital, June 21, 1904. When twenty years old he had gonorrhœa, from which he made a good recovery. His present trouble began when he was seventeen years of age, with pain in the suprapubic region extending to the umbilicus. There was induration and tenderness of the parts on pressure. These symptoms grew worse; poultices were applied, and two weeks later an opening appeared at the umbilicus through which was discharged a moderate amount of pus. From this time the fistula remained patulous almost constantly, with a discharge of pus and urine. Occasionally it would close—never longer than for two days, during which time there would be considerable pain, especially on urination. When the opening closed, the area around and below the navel would become inflamed, and when it was reëstablished, spontaneously or by the patient, there would be immediate relief from pain and the escape of a large quantity of dark, offensive-smelling fluid. The odor was worse after the fistula had been closed a day or two than when it was discharging freely, but at all times it was offensive, to a great extent barring the patient from the society of his friends. The discharge had always been most profuse during urination, and in the morning, when the patient would begin to move about, but there was at all times enough to keep his clothing soiled. At thirty-four years of age he had an attack of pain in the region of the right kidney, with nausea, vomiting, and elevation of temperature, and he had to keep to his bed for three weeks. Since then he had had other attacks of less severity, usually beginning with pain in the loin and extending to the testicle, sometimes accompanied by vomiting and the passage of blood through the urethra. The attacks had always been most severe after exertion.

Examination showed a large, robust, well-nourished man, with good color and apparently in excellent health. At the umbilicus was a flat area of scar tissue of a bluish color, containing a small opening through which a probe could be passed

\* Vaughan, George T.: Patent Urachus. Review of the Cases Reported. Operation on a Case Complicated with Stones in the Kidneys. A Note on Tumors and Cysts of the Urachus. *Trans. Amer. Surg. Assoc.*, 1905, xxiii, 273.

downward and slightly backward for a distance of three and one-half inches into a pouch which lay in front of the bladder.

The urine from the bladder contained urates and epithelial cells. A diagnosis of patent urachus with dilatation into a pouch and infection of its contents was made, and operation was advised.

Operation (June 25, 1904).—The bladder was distended with water through the urethra, and a grooved director was passed through the umbilical fistula to the bottom. The cavity was opened, and a considerable amount of bloody pus, with an offensive urinary odor, was evacuated. The sac was pyriform in shape, with the small end above: it lay in front of the peritoneum, and above and in front of the bladder, with which it communicated through a very small opening. The sac was about three inches in length, and had a capacity of about three ounces; it contained many laminated clots and resembled very much a small urinary bladder, the walls containing muscular and fibrous tissue and being lined with mucous membrane. The sac was carefully dissected out, the peritoneum being opened in two places accidentally, and the walls were brought together. Recovery was without incident except for the high temperature that occurred on the day after operation (107° F. in the axilla), and he was well three weeks after the operation.

On August 13, 1904, just a month after leaving the hospital, the patient had a severe attack of renal colic on the right side, with chills, vomiting, bloody urine, delirium, and swelling of the face and extremities. His pulse was 140, the temperature 104° F. On August 21st the right kidney was incised, and a round stone, half an inch in diameter, was removed. After this the patient had no further trouble until February, 1905, when he had an attack of renal colic on the left side, with the passage of several small, pea-sized calculi from the bladder. A month later he had another attack, which was much more severe and was complicated with almost complete suppression of urine for forty-eight hours, delirium, chills, and a temperature of 106° F. On May 1, 1905, the left kidney was incised and two stones were removed. Up to June 27, 1905, the patient had had no further trouble with his bladder, but had had an attack of appendicitis which he managed to pass through without operation.

Under date of May 12, 1915, Dr. Vaughan writes: "After an operation on both kidneys for stone the patient got along pretty well until December 6, 1906, when I had to operate on the left kidney again, removing a large oval stone. Patient recovered, but had trouble again during the summer of 1914 (during my absence), and Dr. Fowler removed stones from the right kidney. He is in pretty good condition now, but evidently has stones, probably in both kidneys. Since June 25, 1904, patient has had five operations—excision of urachus and two operations on each kidney."

Suppuration of a Urachal Cyst. — In Weiser's\* Case 3 the patient was a man aged seventy-three, who had always been well except for an attack of orchitis four months before the present sickness. For six months he had suffered with pain and soreness in the abdomen, but had noticed no tumor. Two weeks before Weiser's visit the abdominal wall had opened spontaneously two inches below the umbilicus, and discharged urine. There had never been any pus. When the patient was lying down quietly, the urine did not escape, but as soon as he assumed an upright position, there was a constant discharge. The old gentleman

\* Weiser, W. R.: *Annals of Surg.*, 1906, xliv, 529.

appeared perfectly well aside from this urinary sinus, which in caliber was about the size of a pencil, and entered immediately into a large sac, the lower limit of which Weiser could not reach with an eight-inch probe.

Weiser entered the peritoneal cavity above the sinus, and found the sac anterior to the parietal peritoneum. The sac extended to within one inch of the umbilicus, above which the urachus was not patulous (Fig. 253), and downward into the pelvis. It was intimately connected with the bladder at the point of urachal attachment, and was densely adherent to the posterior bladder-wall as well as to the intestines, the greater part of the sac being made up of abdominal viscera. After freeing the anterior wall of the cyst sufficiently, he made a plastic closure of the original point of rupture through the abdom-

inal wall. A catheter was placed in the bladder through the urethra and allowed to remain for several days. The abdominal wound was closed without drainage. The patient made a good recovery, and was about the house on the fourteenth day. Two months later Dr. Stowell, under whose care the patient had been originally, told Dr. Weiser that the abdominal wall had given way again a trifle lower down toward the symphysis, and urine was again discharging through a small sinus. Later the opening closed spontaneously.

A Very Large Abscess-sac Extending into the Pelvis, Opening at the Umbilicus, and Containing a Calculus. — This case in many respects suggests an umbilical abscess that reaches very large proportions and contains a concretion. On the other hand, it makes one think of certain cases of abscess of the urachus. I wrote Dr. Weiser\* as to the character of the calculus. From his reply it was evidently of urinary origin, and probably made up largely of oxalates.

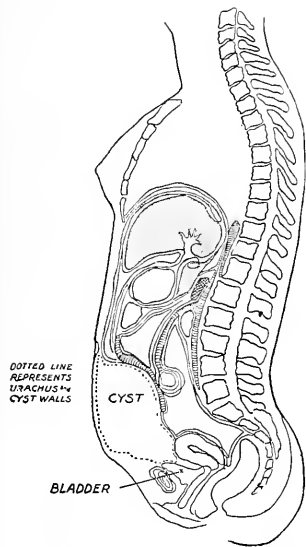


FIG. 254.—URACHAL CYST. (After W. R. Weiser.)

Revised from Case 1. At the operation Weiser tapped the cyst, evacuating five ounces of horribly fetid pus, followed by a calculus weighing 70 grains. The cyst had a thick and indurated wall and dipped well down into the pelvis. It was extraperitoneal. [Dr. Weiser tells me that in his article two of his pictures were not properly placed, hence the "revision."—T. S. C.]

A woman, seventy-five years of age, had for fifteen years suffered inconvenience from a discharge of pus from the umbilicus. The discharge was constant and at

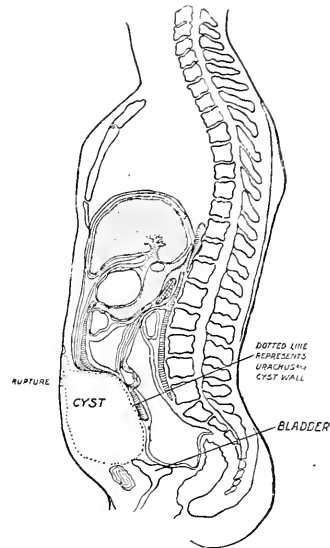


FIG. 253.—URACHAL CYST. (After W. R. Weiser, Case 3, Fig. 3.)

Male, aged seventy-three. The abdominal wall opened spontaneously two inches below the umbilicus and urine was discharged. The sac extended upward to within an inch of the umbilicus; downward into the pelvis. It was intimately attached to the fundus of the bladder.

\* Weiser, W. R.: *Annals of Surg.*, 1906, xlv, 531.

times profuse. At various times she had consulted a physician in reference to the condition, but, aside from prescribing various washes and ointments, no treatment or diagnosis was offered.

She finally consulted Dr. Weiser. The patient at this time was well nourished and active for her age. The abdomen was very fat, and a tumor the size of a cocoon presented in the median line, between the umbilicus and the symphysis. The mass could be raised with the abdominal wall and was apparently attached thereto.

There was a copious discharge of foul-smelling pus from the umbilicus, and an eight-inch probe, passed into the sinus, failed to reach the lower wall of the sac. The temperature was 101° F., her pulse, 100. She volunteered the information that the condition was no worse than usual, but that she was not feeling well generally, and during the past month there had been very frequent micturition.

Under ether Weiser excised the umbilicus and unhealthy skin surrounding it, and cutting down through two inches of fat, came upon a bulging mass extending from the umbilicus as far down as he could feel toward the symphysis (Fig. 254). This he tapped, and evacuated about five ounces of horribly fetid pus, followed by a calculus weighing 70 grains. Exploration with the finger demonstrated the fact that the cyst had a thick and indurated wall, and dipped well down into the pelvis. Up to this point in the operation he had not opened the peritoneal cavity. He now washed out the sac, packed it with gauze, and entered the peritoneal cavity, above the location of the tumor. To his surprise he found the mass densely adherent to the intestine posteriorly, and on passing his hand down into the pelvis on the outside of the cyst, discovered it to be closely associated with the bladder. He now concluded that he was dealing with a urachal cyst, and, as the posterior wall was almost entirely made up of intestines, he concluded to cut away such portions of the sac as seemed safe. He left the posterior wall intact, as well as that portion which dipped down into the pelvis. The wound was closed as far as the peritoneum, and the rest was walled off with a coffer-dam drain of iodoform gauze. Her recovery was uneventful, but it required three months for the sinus to close.

MARCH 11, 1912.

*My Dear Dr. Cullen:* Replying to your letter of the eighth inst. and referring to the urachal calculus: The stone was quite hard, and the surface was dark brown, resembling in color a type of gall-stone. Upon cutting open, the substance of the stone resembled a hard bladder stone in color and general appearance.

Unfortunately, this stone was lost before reaching the laboratory, but I think it was probably made up largely of oxalates. My opinion was that this was a urinary calculus which became discolored on its outer strata by lying in a bed of foul pus and being exposed through the discharging sinus at the umbilicus.

Cordially yours,

WALTER R. WEISER.

CASE OF VESICO-UMBILICAL FISTULA OF FOURTEEN YEARS' STANDING. — Worster\* reports the case of Miss H., aged twenty-one. She had good health until a severe attack of diphtheria when eight years old. Following this she had incontinence of urine and cystitis. From about this time she could not straighten herself up properly and had a habit of standing with the body bent forward at an angle of 45 degrees. She was also incapable of stooping to pick up any-

\* Worster, Joseph: *Med. Record*, 1877, xii, 196.



thing. Two years after the diphtheria she suffered from a cystitis, accompanied by a copious flow of purulent matter from the urethra, and shortly afterward a swelling was noted in the umbilical region, the appearance of which was followed by large and repeated discharges of pus from the umbilical opening, and subsequently of urine. The umbilical inflammation subsided, but pus escaped from time to time, and the urine continually. In her eleventh year, as a result of a contusion, an opening occurred below the umbilicus, from which urine escaped. Extending from the bladder to the umbilicus was a hard, cord-like mass, two inches in diameter and uniform in size.

Operation (April 14, 1875).—Two elliptic incisions were made and the umbilical area removed. Eight days after the operation urine escaped from the wound. A second operation was undertaken at once, with good results.

#### LITERATURE CONSULTED ON URACHAL CAVITIES COMMUNICATING WITH THE BLADDER OR UMBILICUS OR WITH BOTH.

- Ball, C. B.: A Case of Pervious Urachus with Remarkable Disease of Bladder. *Trans. Acad. Med. Ireland*, 1883–84, Dublin, 1884, ii, 376.
- Bourgeois: *Jour. gén. de méd.*, 1821, lxxvi, 219.
- Bramann, F.: Zwei Fälle von offenem Urachus bei Erwachsenen. *Arch. f. klin. Chir.*, 1887, xxxvi, 996.
- Freer, J. A.: Abnormalities of the Urachus. *Annals of Surg.*, 1887, v, 107.
- Garrigues, H. J.: Persistent Urachus in an Adult Woman. *Med. Record*, New York, 1899, lvi, 720.
- Graf, F.: Urachusfisteln und ihre Behandlung. *Inaug. Diss.*, Berlin, 1896.
- Hastings, C.: A Singular Case of Ischuria. *London Med. and Phys. Jour.*, 1829, N. S., vi, 515.
- Hind, W.: Diseases of the Urachus and Umbilicus. *Brit. Med. Jour.*, 1902, ii, 242.
- Ill, E. J.: Tumors of the Urachus. *Trans. Amer. Assoc. Obst. and Gyn.*, 1892, v, 238. *Amer. Jour. Obst.*, 1897, xxxvi, 568.
- Lexer, E.: Ueber die Behandlung der Urachusfistel. *Arch. f. klin. Chir.*, 1898, lvii, 73.
- Marshall, G. B.: Case of Patent Urachus over One Inch in diameter, forming a Tubular Prolongation of the Bladder. *Jour. Obst. and Gyn. of the Brit. Empire*, 1907, xi, 259.
- Matthias, F.: Vereiterung des persistierenden Urachus mit Durchbruch in die Blase und in die Bauchdecken. *Beiträge z. klin. Chir.*; herausg. von Paul Bruns, Tübingen, 1904, xlii, 339.
- Monod, J.: Des fistules urinaires ombilicales dues à la persistance de l'ouraque. *Thèse de Paris*, 1899, No. 62.
- Morgan, G.: A Case of Dilated Urachus Accidentally Opened Whilst Performing Abdominal Section for Peritonitis; Recovery. *The Lancet*, 1896, ii, 1154.
- Newman, D.: Three Renal Cases, a Case of Cyst of the Urachus, and a Case of Strangulated Hernia, Treated in the Surgical Wards of the Glasgow Royal Infirmary. *Glasgow Med. Jour.*, 1896, xlvi, 20.
- Nicaise: *Ombilic. Dict. encyclopéd. des sci. méd.*, Paris, 1881, 2. sér., xv, 140.
- Patel, M.: Malformation congénitale de l'ouraque; dilatation kystique de la partie intérieure de l'ouraque demeuré en communication avec la vessie; incontinence d'urine symptomatique. *Capitonnage de la poche. Rev. mensuelle des mal. de l'enfance*, Paris, 1904, xxii, 77.
- Reid, W. L.: On the Diagnosis and Treatment of a Case of Patent Urachus. *Glasgow Hosp. Rep.*, 1899, ii, 76.
- Renard, Gabriel: Sur un kyste de l'ouraque. *Thèse de Lyon*, 1905, No. 89.
- Robinson, F. B.: Cysts of the Urachus (Congenital Cysts, Extraperitoneal Cysts, or Dilatation of Functionless Ducts). *Annals of Surg.*, 1891, xiv, 336.
- Roser, W.: Ueber Operation der Urachuseysten. *Langenbeck's Arch. f. klin. Chir.*, 1877, xx, 473.
- Savory, W. S.: Polypus of the Urinary Bladder. *Med. Times*, London, 1852, N. S., v, 106.

Schnellenbach: Ueber die Urachusysten. Inaug. Diss., Bonn, 1888.

Simon, C.: Quels sont les phénomènes et le traitement des fistules urinaires ombilicales? Thèse de Paris, 1843, No. 80.

Timmerman, C. F.: Dilated Urachus. Trans. Med. Soc. State of New York, 1904, 331.

Unterberger: Retroversio-flexio uteri gravidi partialis incarcerata. Urachus-fistel. Monatsschr. f. Geb. u. Gyn., 1900, xi, 657.

Vaughan, G. T.: Patent Urachus. Review of the Cases Reported. Operation on a Case Complicated with Stones in the Kidneys. A Note on Tumors and Cysts of the Urachus. Trans. Amer. Surg. Assoc., 1905, xxiii, 273.

Weiser, W. R.: Cysts of the Urachus. Annals of Surg., 1906, xlv, 529.

Worster, J.: Case of Vesico-abdominal Fistula of Fourteen Years' Standing. Med. Record, 1877, xii, 196.

## CHAPTER XXXV.

### ACQUIRED URINARY FISTULA AT THE UMBILICUS.

General consideration.

Acquired umbilical urinary fistula, when no urethral obstruction exists.

Umbilical urinary fistula following partial or complete blockage of the urethra.

Urinary fistula at the umbilicus, with absence of the urethra.

Congenital phimosis, with a urinary umbilical fistula.

Umbilical urinary fistula following stricture of the urethra.

Umbilical urinary fistula associated with a growth in the bladder.

Vesical calculi obstructing the urethra and associated with escape of urine from the umbilicus; report of cases.

Umbilical urinary fistula associated with an enlarged prostate; report of cases.

Apparent escape of urine from the umbilicus, the breasts, and other parts of the body.

WE have already considered (p. 487) congenital umbilical urinary fistulæ due to a patent urachus, and also fistulæ resulting from the opening of a urachal sac (p. 578). We shall now discuss acquired umbilical urinary fistulæ, occurring apparently independently of urachal cyst formation.

These cases naturally fall into two classes:

1. Umbilical urinary fistulæ when no urethral obstruction exists.
2. Umbilical urinary fistulæ associated with partial or complete blockage of the urethra.

Monod, in his splendid thesis on Umbilical Urinary Fistulæ Due to Persistence of the Urachus, mentions a case recorded by Laurentius in 1600. A young woman had retention of urine for several days; this was followed by an escape of urine from the umbilicus. He also refers to an observation published by Fernel in 1638. A man, thirty years old, developed an umbilical urinary fistula following an obstruction at the neck of the bladder. In the same thesis reference is made to a case recorded by Peyer in 1721, in which, following retention of urine, a calculus escaped from the umbilicus. Scattered throughout the literature are isolated cases of acquired urinary umbilical fistulæ.

We have seen (p. 515) that remnants of the urachus are by no means rare. The urachus may remain as a small, patent filament connected with the bladder. In other cases the urachus at the bladder has been obliterated, but here and there along its course are small, spindle-like dilatations. In after-life these small bays or lakes may become connected up so that finally there is produced a fistulous tract between the bladder and umbilicus. Where there is obstruction of the urethra, it is only natural that the old channel through the urachus should open, but in those cases in which the urethra is of normal caliber, the reason for the reëstablishment of the urachal channel is more difficult to explain, unless the urachus has always been patent or unless there has been an inflammatory reaction in the urachal region.

ACQUIRED UMBILICAL URINARY FISTULA WHEN NO URETHRAL OBSTRUCTION EXISTS.

In none of the cases here recorded was any abnormality noted at the umbilicus at birth. Five of the patients were males and one was a female. The youngest was a small boy; the oldest, eighty. In all the cases the urine escaped from both the umbilicus and the urethra. The recognition of the condition was easy on account of the escape of urine from the umbilicus. In Binnie's case there was a line of induration between the symphysis and umbilicus. In Lévêque-Lasource's case the eighty-year-old patient had been passing his urine at intervals from the umbilicus for twenty-five years. In this case the possibility of an enlarged prostate cannot be excluded.

Florentin thought his patient had a urinary fistula at the umbilicus. The history, however, is not very conclusive.

A Partially Patent Urachus That Finally Opened at the Umbilicus, Causing a Urinary Fistula. — Binnie,\* in 1905, saw a woman twenty-nine years of age who for six years was supposed to have had cystitis of unknown origin. All her life she had complained of pain and tenderness in the hypogastrium, and Binnie found a line of induration between the bladder and umbilicus. Pus was escaping from the umbilicus. A little mass of granulation tissue was present at the umbilicus, and through this Binnie could pass a probe into the bladder. He excised the fistula, which was so closely attached to the peritoneum that the abdomen had to be opened. The fistula led into a small diverticulum at the fundus of the bladder.

On histologic examination the walls were found to consist of very vascular granulation tissue, together with sclerosed tissue. The lumen was lined with necrotic material. No epithelium was observed.

A Urinary Umbilical Fistula. † — The man was thirty years old. The urine escaped in jets from the umbilicus, but some of it was passed through the urethra.

Possibly a Urinary Fistula at the Umbilicus. — Florentin‡ reports a case narrated to him by Professor Froelich. A small boy, two years of age, was examined at the hospital of Nancy in January, 1906. At the umbilicus was a tumor the size of a gooseberry or currant. It had not increased in size. In the beginning there had been no discharge, but after several months a purulent fluid had commenced to escape in moderate amount from a small ulceration situated at the margin of the elevation, and still persisted. On examination there was seen at the base of the umbilical cicatrix a small, reddish tumor attached to the skin by a broad, short pedicle, from the base of which a little drop of pus was being discharged. The tumor was irreducible. There was a small ulceration with violet margins. In the center was a small depression, into which a probe could be introduced for 3 cm.

Operation.—The tumor was continuous with a fibrous cord, which extended down the median line. It was dissected out and tied off, the outer portion being removed. Healing took place. No microscopic examination was made. Floren-

\* Binnie, J. F.: Development of the Urachus. *Jour. Amer. Med. Assoc.*, 1905, ii, 109.

† Civiale, Jean: *Traité de l'affection calculuse*, Paris, 1838, 261.

‡ Florentin, P.: *Fongus de l'ombilic chez le nouveau-né et chez l'enfant*. Thèse de Nancy, 1908-09, No. 22 (obs. 8), 108.

tin diagnosed the condition as a urinary fistula, but the case would seem to be doubtful.

*E s c a p e o f U r i n e F r o m t h e U m b i l i c u s i n a n O l d M a n . \**—The patient was a farmer, eighty years of age, of stout build. He had a double inguinal hernia. He had also had for a long period an umbilical hernia, which was not larger than a chestnut. For twenty-five years at times the urine had passed from the umbilicus, and sometimes from the urethra. It did not escape as a jet, as the opening was too small, but there was enough urine to keep the clothes wet. No method of control had thus far been discovered. Lévêque-Lasource said that the condition was due to the reopening of the urachus.

*A C a s e o f F i s t u l a o f t h e U r a c h u s . †*—The patient was a soldier in active service, and had always been free from discomfort except that the pressure of the belt of his sword on the full bladder caused urine to escape from the umbilicus. At the umbilicus the opening was no larger than a hair in caliber, and even with a full bladder only a small amount of urine escaped. He was given a small quantity of potassium iodid and the urine soon contained an appreciable amount of iodin. The reaction was obtained from the umbilical urine by adding calomel, which at once gave it an intense yellow color.

*A V e s i c o - u m b i l i c a l F i s t u l a . ‡*—A boy, aged nine, had had incontinence of urine, and from time to time had complained of pain in the lower abdomen. For about six weeks urination had been frequent, and, three weeks before Trogneux saw him, moisture had been noted at the umbilicus, and later a few drops of urine had passed from the navel. The urine escaped both by the urethra and the umbilicus. Sometimes a large quantity came away from the navel, especially when the patient moved. The umbilical orifice was oval, elongated transversely, and the urine escaped from the bottom. The urethra was permeable. The bladder held 20 c.c. of fluid, and when more was introduced, it at once escaped by the umbilicus. The same result was obtained in the reverse direction. The urine contained pus.

*Operation.*—The tract was dissected out for 2 cm. and tied off. The upper part of the wound was closed. The canal was lined with what seemed to be macerated skin. On the tenth day the urine infiltrated the abdominal wall and escaped. The boy had tuberculosis in the apices of both lungs and was supposed to have tuberculosis of the bladder.

In this case the urachus did not open until the ninth year. The presence of the cystitis naturally hindered efforts at rectifying the condition.

#### UMBILICAL URINARY FISTULA FOLLOWING PARTIAL OR COMPLETE BLOCKAGE OF THE URETHRA.

Although in the majority of the cases the definite type of obstruction to the escape of urine from the urethra has been stated, in a few cases it is merely recorded that an obstruction existed.

Monod refers to an observation made by Fernel in 1638. A man, aged thirty,

\* Lévêque-Lasource: D'un cas particulier où les urines sortaient par l'ombilic. Jour. de méd., Paris, 1811, xxi, 124.

† Starcke: Deutsche militärärztliche Zeitschr., 1883, xii, 211.

‡ Trogneux, Albert: Contribution à l'étude des fistules ombilico-vésicales. Thèse de Paris, 1897, No. 129.

developed an umbilical urinary fistula following an obstruction at the neck of the bladder.

Littré\* reported the case of a boy twelve years of age who had passed nearly all his urine by the umbilicus. At autopsy an obstruction was found at the neck of the bladder and the urachus had remained as a patent canal. Littré, in the same article, says that he knew a man thirty years old from whom the urine escaped forcibly from the umbilicus, no doubt as the result of an obstruction at the neck of the bladder.

Simon (obs. 14) records a case reported by Chopart.† I have attempted to find the original article, but was unable to locate it. It is, however, probably correct, as Chopart has many cases scattered throughout his excellent book.

The patient was a woman, thirty-seven years of age. Shortly after the beginning of pregnancy she suffered from retention of urine, and twelve days later several drops of puriform urine escaped. The abdomen increased in size day by day, and when she entered the hospital on September 7, 1781, she complained of abdominal tenderness. The skin was inflamed, and there was marked fluctuation around the umbilicus; the patient voided only in small quantities. She had high fever. Anthelme, surgeon-in-chief of the hospital, made an incision in the linea alba between the umbilicus and the muscle on the right, and a good deal of pus and a large quantity of fetid urine escaped. On the following day the symptoms were less acute. The clothes and the body were inundated with urine, and a large quantity of pus also escaped. On the next day the clothes were soaked with urine. The fever and other symptoms had disappeared, and the surgeon attempted to establish the return of the urine by the urethra. He was unable to introduce a sound into the bladder on account of some obstruction. Later on he was able to pass an elastic catheter into the bladder. The amount of urine escaping from the umbilicus diminished, and the pus in the urine gradually decreased. The pregnancy continued, and the patient left the hospital perfectly well. Normal labor took place in February, 1782.

Simon‡ says that at the meeting of the Medical Society in Florence, July 13, 1828, Betti reported a case seen by Falaschi, in which, as a result of a complete occlusion of the urethra at its vesical orifice, there was an escape of urine from the umbilicus in a patient very advanced in years. This phenomenon was observed for several months before death.

The various causes of blockage of the urethra have been:

1. A congenitally closed urethra.
2. A congenital phimosis.
3. A stricture following gonorrhoea.
4. New-growths of the bladder.
5. A vesical calculus.
6. An enlarged prostate.

#### URINARY FISTULA AT THE UMBILICUS, WITH ABSENCE OF THE URETHRA.

The only case of congenital absence of the urethra with the escape of urine from the umbilicus with which I am familiar is that reported by Petit in 1837.

\* Littré: *Histoire de l'Académie Royale des Sciences de Paris*, Amsterdam, 1701, 27.

† Chopart: *Maladies des voies urinaires*, Paris, 1792.

‡ Simon: *Obs.* 17, p. 33.

Urinary Fistula at the Umbilicus, With Absence of the Urethra. \*—The child was born with a closed urethra. At the umbilical cicatrix was a tumor the size of a cherry, from which urine escaped. A bandage was applied. The bandage retained the urine very well, but she was often obliged to remove it in order to relieve herself. The bladder was sensitive and did not hold more than half a glass of urine. As soon as it reached this degree of dilatation the child suffered from pain in the abdomen, particularly in the region of the bladder and the kidneys.

#### CONGENITAL PHIMOSIS WITH A URINARY UMBILICAL FISTULA.

Freer, in his article on Abnormalities of the Urachus, refers to an article appearing in the Medical Record of August 18, 1871. A boy, a year old, commenced to pass his urine through a vesico-umbilical fistula. A few drops only passed by the urethra. An examination revealed a congenital phimosis with an orifice so small that the *vis à tergo* required to force the urine through it had exerted itself in an upward direction and had opened up the urachus, rendering that structure patent throughout. After this fistula had persisted for some time the cause was discovered, circumcision was performed, and the urachus closed spontaneously.

Freer says this case emphasizes the importance of examining carefully the urethra before proceeding to operate for the closure of the fistula.

#### UMBILICAL URINARY FISTULA FOLLOWING STRICTURE OF THE URETHRA.

This is a very rare condition, considering the enormous number of patients who suffer from urethral stricture. Jacoby reported a case in 1877, and Guisy two cases in 1903. One of Guisy's patients also had an enlarged prostate which was probably a contributory factor to the urethral obstruction.

Umbilical Fistula Following a Urethral Stricture. †  
—The patient was a boy, eighteen years of age, who had contracted gonorrhœa a year before and had developed a stricture. Later there was a perineal fistula. After taking balsam of copaiba he improved somewhat, but three months later the urine stopped completely for twenty-four hours. He suffered great pain and the umbilicus opened. Pus escaped, and then large quantities of urine, the continuous flow confining him to bed. When Jacoby saw him he had tuberculosis and syphilis. All the urine came from the umbilical fistula and none from the urethra. The fistula in the perineum was dry.

The umbilicus was flat. There was a very narrow fistula. Once the fistula closed and a small amount of urine escaped from the urethra. At the end of thirty hours, when the patient bore down heavily, the fistula reopened, and fully a quart of urine came away. This was mixed with pus and blood. The boy soon died. No autopsy is recorded.

An Umbilical Urinary Fistula Developing in a Man with Urethral Stricture and Enlarged Prostate.—Guisy's‡

\* Petit, J. L.: *Traité des mal. chirurg.*, Chap. xi, 3. *Oeuvres complètes*, 8°. Limoges, 1837. (Quoted by Simon, obs. S.)

† Jacoby, M.: *Zur Casuistik der Nabelfisteln*. Berlin. *klin. Wochenschr.*, 1877, 202.

‡ Guisy, B.: *Deux cas de perméabilité congénitale de l'ouraque*. *Ann. d. mal. d. org. génito-urin.*, Paris, 1903, xxi, 986.

patient was a man sixty years of age, who, for five years, had been passing urine from the umbilicus. His previous history showed that he had suffered many years before with gonorrhœa, and later with severe attacks of renal colic, accompanied by the passage of gravel from the urethra. He also had a urethral stricture. He developed pain and swelling about the navel. A physician opened the swelling and evacuated urine and pus, and thereafter the urine continued to flow by this route, as well as through the urethra. External urethrotomy was performed, and two large stones were removed from behind the stricture. The prostate was large. The urine ceased completely to flow from the umbilicus and recovery took place.

**E S C A P E O F U R I N E F R O M T H E U M B I L I C U S F O L L O W I N G S T R I C T U R E O F T H E U R E T H R A .**—Guisy's\* second patient was a man aged thirty-two years, who, on account of stricture following gonorrhœa, had had great difficulty in passing urine and for two years had suffered pain at the umbilicus. Later a swelling appeared, and one day, during complete retention, the tumor ruptured and urine and bloody mucus escaped. Thereafter for several months there was constant leakage from the navel. A small sound could be passed through the navel into the bladder. The urethral stricture was treated by internal urethrotomy and dilatation, and the escape of urine through the navel diminished materially.

#### **U M B I L I C A L U R I N A R Y F I S T U L A A S S O C I A T E D W I T H A G R O W T H I N T H E B L A D D E R .**

The only case of this character with which I am familiar is the one reported by Cadell in 1878.

**M A R K E D C Y S T I T I S I N A Y O U N G G I R L F O L L O W E D B Y E S C A P E O F U R I N E F R O M T H E U M B I L I C U S .** †—The patient was a delicate girl eight years of age. From her earliest childhood she had difficulty in making water. Micturition was frequent, and only a small amount of urine was passed. When she was six months old the lower abdomen and genitals became black and blue. The child went to school at four, but was taken home on account of pain and frequent urination. After an attack of typhoid fever at six years of age the other symptoms became more marked. Eight months before admission blood was noted in the urine. After a few days of great pain and swelling and hardness of the abdomen, the urine was observed to come in a small stream from the umbilicus. Nothing abnormal was noted in the appearance of the umbilicus or of the genitals. In the center of the umbilical depression was a fistulous opening into which a probe could be easily introduced and passed toward the bladder. A No. 2 elastic catheter introduced through the urethra was blocked by tenacious, mucopurulent masses in the bladder. The urethra was normal. No urine escaped by the urethra for several days. Later the urethra was dilated under anesthesia, and the procedure was followed by incontinence of urine.

The child died a few months later. At autopsy the bladder was found contracted and showed great thickening of the mucous and submucous coats. Protruding into the cavity were rounded nodules the size of peas. At the upper end of the bladder was the unobliterated urachus. It admitted the point of the little finger, gradually became narrower, and at the umbilicus admitted a No. 5 or No. 6 catheter. The

\* Guisy, B.: *Loc. cit.*

† Cadell, F.: Notes on a Case of Umbilical Urinary Fistula. *Edinburgh Med. Jour.*, 1878, xxiv, Part i, 221.



mucous membrane of the urachus was thin and pale. Between the umbilicus and the bladder were evidences of an old peritonitis, and the omentum was adherent to the anterior abdominal wall along the course of the urachus. There were dense adhesions binding the uterus to the posterior surface of the bladder.

The right kidney was twice the natural size, cystic, and filled with putrid and ammoniacal pus. There was complete atrophy of the kidney substance. The left kidney was one and a half times the natural size. The calices were distended with putrid pus, but the kidney substance had been only partially destroyed. Both ureters were dilated. Cadell says the urachus must have been partly open at birth.

#### VESICAL CALCULI OBSTRUCTING THE URETHRA AND ASSOCIATED WITH ESCAPE OF URINE FROM THE UMBILICUS.

Cases of this nature have been reported by Littré (1701), Raussin (1752), d'Auxiron (1766), Eustache (1789), Civiale (1838), Simon (1843), and Lexer (1898). In seven cases in which the sex was mentioned, five were in males and two in females. The ages varied from two and a half to seventy years. The age at which the patient came under observation is, however, no index as to when the symptoms first developed. For example, d'Auxiron's patient came under observation when he was seventy years old, but from the history it will be seen that he had had vesical symptoms since childhood. Eustache's patient, a boy six years old, had vesical symptoms shortly after birth.

The symptoms were usually those referable to a vesical calculus, and after various periods of time urine commenced to escape from the umbilicus. In some cases the umbilical fistula was preceded by an inflammatory reaction in the umbilical region; in other cases this phenomenon was apparently lacking.

Some of the patients were relieved by lateral lithotomy, and in Simon's case the stone was successfully removed suprapubically. After removal of the stone the umbilical fistula usually closed.

With our present mode of treatment these patients would naturally be operated upon soon after symptoms develop. If there be little or no infection, the fistulous tract should be dissected out and excised, and the stone removed suprapubically at the same time. When the inflammatory reaction is marked, the stone may be removed and the tract dissected out after the inflammation has subsided.

#### CASES OF VESICAL CALCULUS WITH ESCAPE OF URINE AT THE UMBILICUS.

*Vesical Calculi Followed by Escape of Urine at the Umbilicus.* \* — The patient was a priest, seventy years of age, who had suffered with vesical stone since childhood. He had piercing pains in the lower abdomen at times, and suffered from retention of urine, which sometimes lasted for several days.

For four or five years stones had blocked the urethra, and the urine had at times escaped from the umbilicus. There was a small opening with reddish margins at the umbilicus, out of which the urine oozed. Sometimes it came as a stream and could be caught in a vessel. When the urine escaped by the ordinary channel, the umbilical opening would close.

\* d'Auxiron: Une observation sur un homme qui rend ses urines par le nombril. Jour. de méd., Paris, 1766, xxiv, 58.

**E S C A P E O F U R I N E F R O M T H E U M B I L I C U S D U E T O A V E S I C A L C A L C U L U S . \***—In a patient seventy years old the urine escaped from the umbilicus in jets, in spite of the fact that the bladder was not extremely full. Each time it was found that a stone was obstructing the neck of the bladder.

**E S C A P E O F U R I N E F R O M T H E U M B I L I C U S , D U E T O T H E P R E S E N C E O F A V E S I C A L C A L C U L U S .**—Civiale† says that Fourquet, of Toulouse, narrated to him the history of a child, thirty-one months of age, who was relieved by lithotomy. The vesical stone was voluminous, weighing 5.5 “gros,” and enveloped in a covering of mucus and calcareous material. After about two months, as a result of considerable effort, the child expelled urine. It developed a urinary fistula at the umbilicus, from which three quarts or less of urine escaped. This closed after the operation.

**U M B I L I C A L U R I N A R Y F I S T U L A A S S O C I A T E D W I T H S T O N E S I T U A T E D I N T H E N E C K O F T H E B L A D D E R .**—Civiale also reports a case related by Covillard. The patient, a girl fifteen years of age, passed her urine from the umbilicus, and a stone was detected in the neck of the bladder. A lateral lithotomy effected an entire cure.

**U R A C H A L F I S T U L A A T T H E U M B I L I C U S A S S O C I A T E D W I T H A S T O N E I N T H E B L A D D E R .**—Lexer‡ reported a case that came under Goldschmidt's care. Goldschmidt operated on a ten-year-old boy on account of the gradual appearance of a fistula without signs of inflammation. This case was looked upon as one of urachal fistula of the abdominal wall, although no microscopic examination could be made. The boy had a large stone in the bladder. The fistula had produced an abscess-like dilatation below the umbilicus, and had been previously opened. At another time, when the cystitis had disappeared, the umbilical opening closed.

[This case is not particularly clear.—T. S. C.]

**B L O C K A G E O F T H E N E C K O F T H E B L A D D E R B Y A S T O N E ; P A R T I A L L Y P A T E N T U R A C H U S .**—Litré§ demonstrated before the Paris Academy the body of a young man of eighteen. The neck of the bladder was occupied by a stone, and the urachus at the neck of the bladder was open for five fingerbreadths. He says that when the urine finds great difficulty in passing along its ordinary route, it commences to travel through its ancient channel.

**A R E N A L C A L C U L U S A S S O C I A T E D W I T H E S C A P E O F U R I N E B Y T H E U M B I L I C U S .**—Raussin|| reported before the Academy the case of a man, aged thirty-two years, who had had a renal calculus. In making an effort to urinate, while an attendant held the vessel, expecting to see a small stone fall into the vessel, he was greatly surprised to see urine passing from the umbilicus and from the penis at the same time. The umbilical stream was well formed, and made an arch over the shoulder of the servant, who at the time was kneeling. The umbilicus of the patient was represented as a tumor the size of a medium-sized walnut, with an opening in it which discharged a little blood. The patient continued to urinate by the

\* Civiale, Jean: *Traité de l'affection calculeuse*, Paris, 1838, 257.

† Civiale, Jean: *Op. cit.*

‡ Lexer, E.: *Ueber die Behandlung der Urachusfistel*. *Arch. f. klin. Chir.*, 1898, lvii, 73.

§ Litré: *Sur un factus extraordinaire*. *Histoire de l'Académie Royale des Sciences de Paris*, Amsterdam, 1701, 27.

|| Raussin: *L'urine rendue par le nombril*. *Mém. de l'Acad. de Chir.*, Paris, 1752, iii, 10.

umbilicus more than by the urethra, and claimed to be able to urinate by one or the other, as he desired. After a time most of the urine passed by the urethra.

*Escape of Urine by the Umbilicus Due to Blockage of the Urethra by a Vesical Calculus.*\* — Dr. Eustache, surgeon-in-chief of the Hôtel-Dieu of Béziers, reported before the Academy of Surgery, in 1789, the case of a new-born boy who developed severe abdominal pain a few days after his birth. He was thought to have colic, but the usual remedies were given without success. At the thirteenth month he was weaned. The manner in which he urinated led to the supposition that he had a stone. When he was three years of age he drank to excess, and one day he consumed a pint of wine and became unconscious. The difficulty in urination increased. Sometimes he would have incontinence of urine, sometimes a dozen hours would pass without there being the escape of a drop. When five years of age he had complete retention of urine, and his abdomen was tender and painful, especially in the hypogastric region. His pulse was small and rapid, and the respiration was embarrassed. He had continual nausea. Pistré saw him on the third day, and at that time he had around the umbilicus a tumor which was inflamed, tender, and painful. Poultices were applied, and on the fourth day the child had not passed a drop of urine and was unconscious. On the fifth day there formed in the center of the umbilical tumor an opening about half an inch in diameter, and from this urine with pus escaped. Little by little the symptoms disappeared. The stomach retained nourishment, and he returned to the condition that he was in before the retention. The umbilical opening remained as a fistula and was the only passage by which the urine escaped. On the twenty-fourth of April, 1787, Eustache saw this patient, who was then six and a half years old. He had a slight fever and marasmus. Eustache confirmed the opinion of Pistré of the existence of a stone in the neck of the bladder, because a sound was arrested at this place and came in contact with a hard body. On the seventh of May of the same year, in the presence of several surgeons, Eustache extracted the stone through an incision in the perineum. It was in the shape of a large horn, and the lower extremity was engaged in the urethra. It was a little less than three inches long and  $1\frac{1}{2}$  inches in diameter. It was slightly concave toward the pubes, convex toward the rectum. After the extraction of the stone the urine commenced to escape through the wound, and in a short time the fistulous opening, which had been present for a year, closed. The urine contained much mucus. On the thirty-second day after the operation the urine commenced to pass by the urethra, and ten days later it passed entirely through this channel. The child made a good recovery.

*Escape of Urine From the Umbilicus Due to Blockage of the Urethra by a Vesical Calculus.* — Simon† reports the case of Marguerite P., aged twelve years, who had urinated by the umbilicus for four years. During this time not a drop of urine had escaped by the urethra. She had an enlargement of the abdomen, due to the escape of urine into the cellular tissue of the skin and of the muscle. She was brought to the hospital in May, 1786. With a sound an obstruction was found in the canal, which was preventing the flow of urine. The opening in the umbilical region offered a channel which communicated with the bladder. By this means it was possible to detect a stone fixed in the inner orifice of the urethra. The surgeon decided to pass a sound into the bladder by way of the urachus. The child was laid upon the table, the head and the buttocks being a little

\* Simon: Thèse de Paris, 1843 (obs. 19), 34.

† Simon: Op. cit. (obs. 25), 44.

elevated. After the sound had been introduced into the bladder by way of the urachus an incision was made in the skin for about the length of three fingerbreadths in the linea alba, and ending at the pubes. The sound acted as a guide. The bladder was opened. The stone was the size of a pigeon's egg. After the extraction of the stone the child was promptly put to bed, and a sound was introduced through the urethra. At the end of four months the urine escaped regularly by the urethra.

#### UMBILICAL URINARY FISTULA ASSOCIATED WITH AN ENLARGED PROSTATE.

Levié, Lexer, and Monod have recorded cases in which a urinary fistula developed at the umbilicus in patients suffering from an enlarged prostate.

In this connection it may be mentioned that, according to Kirmisson, Horion observed an umbilical fistula that had developed after retention caused by a prostatic abscess.

**A Patent Urachus Associated With an Enlarged Prostate.\***—The patient was a man seventy-nine years of age. After several years of dysuria due to an enlarged prostate, the urine commenced to escape from the umbilicus. At autopsy the urachus was found open. The opening into the bladder was tubular. The opening was from 1 to 1.5 mm. broad.

**Markedly Enlarged Prostate, Followed by Cystitis and Escape of Urine From the Umbilicus.**—Lexer † reports the case of a man, aged sixty-seven, who came to the clinic for three years on account of a prostatic hypertrophy and a resulting cystitis. He came whenever retention of urine developed. The urine was removed with a soft catheter, and the bladder washed out each time. The patient, on coming to the hospital later, said that, after there had been a stoppage of urine for twenty-four hours, it had commenced to come away by the umbilicus. He had noticed no unusual pain, and there was no inflammation in the region of the umbilicus. The entire flow of purulent, slimy urine escaped from the umbilicus.

On examination the patient was found to have a markedly enlarged prostate. A sound could be carried from the umbilicus for 6 cm. toward the bladder. From the umbilicus to the symphysis in the middle line a cord-like mass could be felt. [In such a case it would now be very easy to use bismuth paste and get a clear picture of the character of the fistulous tract by means of the *x*-ray.—T. S. C.]

Lexer said that the almost complete lack of symptoms in the development of the fistula was a strong indication against perforation of the bladder with infiltration of the urine. He says that, in view of the slow development and the fact that the position of the fistulous tract was exactly in the mid-line, the whole picture tends to prove that the case was one of urachal fistula.

[With the present brilliant results obtained by prostatectomy, as carried out by Young and others in this country, the first thing would be to remove the prostate; this would materially improve matters, and later, if necessary, the fistulous tract could be closed.—T. S. C.]

With a sound in the tract Lexer divided it. It was surrounded on all sides by very firm connective tissue, and about 5 cm. above the symphysis he found a cavity

\* Levié, L.: Een geval van profluvium urinæ per umbilicum ab uracho patente bij een volwassen persoon. *Nederlandsch. Tijdschrift voor Geneeskunde*, 1878, xiv, 501.

† Lexer, E.: *Loc. cit.*

the size of a walnut lined with slimy granulations and filled with purulent urine. This lay behind the abdominal wall and reached to the symphysis. The sac communicated with the bladder by a fistulous opening, the size of a lead-pencil. The entire wound was packed with iodoform gauze and a retention catheter left in.

The patient died fourteen days later with signs of uremia and fever. At autopsy a marked pyonephrosis was found on both sides. The small, thick-walled, ulcerated bladder ended in a small funnel just in the mid-line. Here it communicated with the opening in the abscess-sac. On the inner side of the abdominal wall was the median vesical ligament, appearing as a prominent cord 2 cm. broad.

From the results of the operation and from the autopsy specimen, it is clear that the bladder and umbilical fistula lay in the mid-line, and in the very markedly thickened median vesical ligament. The opening in the bladder was situated exactly in the middle of the vertex and in front of the peritoneum. In the fistulous tract it was impossible to make out any epithelium.

Lexer comes to the conclusion that these fistulous tracts should be dealt with early, before there is much inflammation; that is, in childhood.

**Umbilical Urinary Fistula Associated With Hypertrophy of the Prostate.** \* — This case is particularly interesting. In a man, sixty-two years of age, the umbilical fistula developed after a prostatic hypertrophy. On looking into the history it was found that the patient had urinated from the umbilicus from the time of birth until he was three weeks old. The fistula had then closed spontaneously after the application of appropriate bandages.

Enlargement of the prostate is relatively common, and notwithstanding the tension under which the bladder labors in some of these cases, the escape of urine from the umbilicus is exceptional. It really seems as if the umbilical fistula only develops in those cases in which the urachus has remained partially patent, or where its lumen has persisted almost to the umbilicus.

- Bardeleben and Chapin have also reported cases in which an enlarged prostate probably existed. Bardeleben's patient was ninety-two, Chapin's was sixty-six, years old.

**A Urinary Fistula at the Umbilicus Developing in a Man Ninety-two Years of Age.** — Bardeleben† says that, in the *Mémoires de l'Académie des Sciences* for 1769, there is a report of a man, ninety-two years old, who had severe pain in the neck of the bladder for several days. After the pain had ceased, he noticed that he voided less urine than usual and that his umbilicus was wet. A clear fluid (urine) was found escaping from the umbilicus. In fourteen days the urine by the urethra ceased. He died in six months. The fistula persisted until his death.

**Escape of Urine from the Umbilicus in a Man Sixty-six Years of Age.** — Chapin's‡ patient was a man, sixty-six years of age, who was seen in June with retention of urine. He suffered a great deal of pain and passed no urine for forty hours. The urine then began to dribble, and finally the bladder was emptied with a catheter. He suffered agony beyond expression during

\* Jaboulay: Reported by Monod, *Obs.* 53.

† Bardeleben: *Lehrbuch der Chirurgie und Operationslehre*, 1882, iv, 223.

‡ Chapin, Edward: *A Case of Open or Patent Urachus*. *North Amer. Jour. of Homœopathy*, New York, 1897, third series, xii, 286.

the retention. The catheter was used for several days, after which he developed a great deal of soreness over the upper part of the bladder. Palpation over this region was painful. His pulse was slightly accelerated, but he had no fever. He voided small quantities of strongly ammoniacal urine containing mucus. Later excoriations were noted around the umbilicus, and some pus escaped from this opening. The discharge became more watery and had the odor of urine. The amount of urine escaping gradually increased, and by November 5th fully three-fourths of the urine was coming from the umbilicus. A small stream came from the urethra, a large one from the umbilicus.

#### APPARENT ESCAPE OF URINE FROM THE UMBILICUS, THE BREASTS, AND OTHER PARTS OF THE BODY.

The accompanying remarkable case, recorded by Lynker in 1836, is difficult to interpret. I have found no similar case in the literature.

Lynker\* reports the case of a woman, aged twenty-four, who in 1831 had a bad fall and became sick. In 1833 she had paralysis of the lower extremities. Later she had dysuria and passed hardly any urine. Her breasts swelled up, and she passed what looked like urine from them, then from the umbilicus, and later from the legs, the rest of the body skin meanwhile being dry. She had marked pain and swelling in the lower abdomen.

Up to the time of writing no clue as to the cause had been obtained. The patient was still alive.

\* Lynker: *Rétention d'urine suivie de l'excrétion de ce liquide par des voies inaccoutumées.* *Gaz. méd. de Paris*, 1836, vii, 602.

#### LITERATURE CONSULTED ON ACQUIRED URINARY FISTULA AT THE UMBILICUS.

- d'Auxiron: Une observation sur un homme qui rend ses urines par le nombril. *Jour. de méd.*, Paris, 1766, xxiv, 58.
- Bardeleben: *Lehrbuch der Chirurgie und Operationslehre*, 1882, iv, 223.
- Binnie, J. F.: Development of the Urachus. *Jour. Amer. Med. Assoc.*, 1906, ii, 109.
- Cadell, F.: Notes on a Case of Umbilical Urinary Fistula. *Edinburgh Med. Jour.*, 1878, xxiv, Part i, 221.
- Chapin, E.: A Case of Open or Patent Urachus. *North Amer. Jour. of Homœopathy*, New York, 1897, third series, xii, 286.
- Civiale, J.: *Traité de l'affection calculuse*, Paris, 1838, 261.
- Florentin, P.: *Fongus de l'ombilic chez le nouveau-né et chez l'enfant.* *Thèse de Nancy*, 1908-09, No. 22.
- Freer, J. A.: Abnormalities of the Urachus. *Annals of Surg.*, 1887, v, 107.
- Guisy, B.: Deux cas de perméabilité congénitale de l'ouraqué. *Ann. d. mal. d. org. génito-urin.*, 1903, xxi, 986.
- Jacoby, M.: *Zur Casuistik der Nabelfisteln.* *Berlin. klin. Wochenschr.*, 1877, 202.
- Kirmisson: *Maladies congénitales de l'ombilic. Traité des mal. chirurg. d'origine congénitale*, Paris, 1898, 208.
- Lévêque-Lasource: D'un cas particulier où les urines sortaient par l'ombilic. *Jour. de méd.*, Paris, 1811, xxi, 124.
- Levié, L.: Een geval van profluvium urinæ per umbilicum abs uracho patente bij een volwassen persoon. *Nederlandsch. Tijdschrift voor Geneeskunde*, 1878, xiv, 501.
- Lexer, E.: Ueber die Behandlung der Urachusfistel. *Arch. f. klin. Chir.*, 1898, lvii, 73.
- Littre: *Sur un fœtus extraordinaire.* *Histoire de l'Académie Royale des Sciences de Paris*, Amsterdam, 1701, 27.

- Lynker: Rétenction d'urine suivie de l'excrétion de ce liquide par des voies inaccoutumées. *Gaz. méd. de Paris*, 1836, vii, 602.
- Monod, J.: Des fistules urinaires ombilicales dues à la persistance de l'ouraque. Thèse de Paris, 1899, No. 69.
- Petit, J. L.: *Traité des malad. chirurg.*, Chap. xi, 3. *Oeuvres complètes*, 8°. Limoges, 1837.
- Raussin: L'urine rendue par le nombril. *Mém. de l'Acad. de Chir.*, Paris, 1752, iii, 10.
- Simon, C.: Quels sont les phénomènes et le traitement des fistules urinaires ombilicales. Thèse de Paris, 1843, No. 80.
- Starcke: Fall von Urachusfistel. *Deutsche militärärztliche Zeitschr.*, 1883, xii, 211.
- Trogneux, A.: Contribution à l'étude des fistules ombilico-vésicales. Thèse de Paris, 1897, No. 129.

## CHAPTER XXXVI.

### URACHAL CONCRETIONS AND URINARY CALCULI ASSOCIATED WITH URACHAL REMAINS.

Historic sketch.

Urachal stones or concretions.

Urinary calculi in the urachus.

Removal of vesical stones through the umbilical opening.

Other calculi in the umbilical region.

PHILLIPS, in an article in Todd's *Cyclopædia of Anatomy and Physiology* (1835), said that in January, 1787, Boyer exhibited a bladder taken from a man thirty-six years of age. The urachus formed a canal  $1\frac{1}{2}$  inches long, and contained 12 urinary calculi each the size of a millet-seed. It was demonstrated that this canal was not a vesical sac or a prolongation of the vesical mucous membrane.

In 1838 Civiale, in his treatise on calculous affections, called attention to the fact that the anatomist Columbus had observed calculi at the umbilicus. Civiale refers to the case of a woman coming under Hagedorn's care, who had a very painful abdominal abscess which contained two calculi. He also refers to Vallisneri, who spoke of stones escaping from the umbilicus. In Helwig's case, cited by the same author, a woman seventy years old had an umbilical abscess; it broke, and several stones escaped, one of which weighed 15 grains. In another case a man discharged from the umbilicus a calculus which weighed about an ounce and was as large as a pigeon's egg. Civiale also referred to cases observed by Tolet, Rhodius, and Roesler. The stones varied from the size of the kernel of an olive to that of a hazelnut. They escaped from the umbilicus.

Simon, in 1843, mentioned the fact that calcareous concretions had been found along the course of the urachus and had also escaped through the umbilical ring. He said that Columbus, Donatus, Harder, Bartholin, and Cruveilhier had reported such cases.

Simon said that Rhodius and Helwig had reported cases similar in character. In the case of Helwig's patient, a man, the stone was the size of a pigeon's egg.

Concretions or calculi escaping from the umbilicus may originate from several sources. They may be formed in the bladder or in the urachus, which communicates with the bladder, and where, consequently, urinary salts can become concentrated, or, again, in a urachus, that is completely isolated from the bladder. Finally we have umbilical concretions. The escape of gall-stones from the umbilicus has been considered elsewhere.

Calculi developing in a urachus communicating with the bladder are identical in their composition with vesical stones. Those developing in the urachus, when no connection exists between it and the bladder, are very small; umbilical concretions are cheesy in character. These last have been considered in detail in Chapter XV (p. 247).

The majority of the cases mentioned in the historic sketch just given are not



sufficiently clear to enable one to determine with any degree of accuracy to which group they belong.

#### URACHAL STONES OR CONCRETIONS.

The careful and painstaking investigations of Luschka, published in 1862, give us a very comprehensive knowledge of the urachus. He says the urachal contents are not all alike. The fluid is usually pale yellow, thin, and translucent. It may, however, be cloudy, and brown or reddish in color. It contains a large number of cells, numerous fat-globules, and not infrequently corpora amylacea. In the dilata-tions and in the isolated cysts the contents are frequently sticky and of a dirty brown color, and scattered throughout the field are bodies which have a marked resemblance to prostatic concretions.

Urachal concretions were also described by Hoffmann in 1870.

Suchanek, in 1879, when describing the contents of a patent portion of the urachus, discussed the granular bodies. These, he said, judging from their reaction to acetic acid, are due to a degeneration of the epithelium, which is probably colloid or amyloid in character.

Wutz briefly details his findings in the cyst contents of the many cases he examined.

In Case 11 he noted that, a short distance from the bladder, the urachus contained an oval body 0.17 x 0.1 mm. It was brownish in color and homogeneous in consistence. In the further course of the tube were several diverticula and nipped-off cysts of various shapes. They contained firm brownish contents.

In Case 15 Wutz says that the cysts were filled with lumps of brownish and yellow material.

In Case 17 the cyst contents were yellowish white and friable.

In Case 18 Wutz found a spindle-shaped urachal cyst, 2 x 1 mm. Its contents were brownish yellow in color.

Wutz, in summing up his observations on cyst-contents, said that they consisted of fat-crystals, fat-droplets, free fat, large flat epithelial cells, brownish-yellow amorphous masses, isolated cholesterin crystals, and small, round, very glistening bodies. In one of the cysts in Case 22 he found a small, firm, stony hard, yellowish-brown, glistening body. Under the microscope this was irregular, nodular, and partly transparent. It was 0.37 x 0.36 mm. in diameter. On the addition of hydrochloric acid free carbonic acid escaped.

Ledderhose referred briefly to urachal concretions in 1890.

In Boyer's case, which we have already considered and in which 12 millet-seed-sized stones were found in the urachus, these bodies were urinary stones.

Rokitansky (1861) referred to a case in which 21 calculi the size of linseeds were found in a urachal dilatation 0.6 mm. above the top of the bladder.

Veiel, one of Luschka's pupils, in his dissertation on the urachus published in 1862, described his findings in the body of a man forty-five years old. "Passing downward in the mid-line from the umbilicus was a delicate cord 1 mm. broad. Three centimeters above the bladder it commenced to get thicker, and at the bladder was 1.2 cm. broad. The urachus could be divided into four sections. The lowest section, situated nearest the bladder, was 14 mm. long and patent. The next was 7 mm. long, solid, and thread-like. The third was 8 mm. long and was also patent. The fourth section—nearest the umbilicus—was solid. After the urachus had been

treated with acetic acid, three dilatations of the canal could be seen. They contained yellowish concretions.

Arrou, in 1910, in an article entitled *A Suppurating Cyst of the Urachus*, reported a case in which an abscess contained a stone or concretion the size of an olive; it was like a piece of incompletely dried mortar. [I should be inclined to look upon it as a simple umbilical concretion accompanied by inflammation, were it not for the fact that the lower end of the sac bore a definite relation to the urachus.—T. S. C.]

*Suppurating Cyst of the Urachus.*—Arrou\* reports the case of a patient operated upon by Tricot. A soldier with absolutely no history of bladder trouble complained of vague pain in the umbilical region. The pain became acute, and the patient when marching had to bend forward. There was no nausea and no intestinal disturbance. Urination was normal; there was no fever.

Examination revealed a painful plaque, as large as the palm of the hand, a little below the umbilicus. There was no edema or redness. Gradually a little swelling was noted over the painful area; this was accompanied by some fever.

Operation.—An exploratory incision was made under the supposition that there was an abscess in the abdominal wall, but when the patient was in the operating-room, there was an escape of a small amount of pus from the lower margin of the umbilicus. A probe introduced into the small orifice passed downward and backward into a cavity, measuring 6 cm. in its vertical direction. The patient was at once anesthetized and the cavity incised. It proved to be the size of a mandarin orange. It contained a calculus the size of an olive, that was like a piece of incompletely dried mortar. The cyst lining resembled an inflamed mucosa. Unfortunately, both sac and calculus were lost.

The upper end of the sac ended at the bottom of the umbilicus. The lower extremity terminated in a closed cul-de-sac. Attached to the lower portion of the sac was a large cord, the size of the little finger, which became smaller and terminated in the fundus of the bladder. Arrou was sure that it was the urachus. The peritoneum was opened above and laterally. The intestines were protected and the urachus was cut across with the cautery at a point several millimeters above the bladder. The sac was completely removed and the wound closed. The patient made a good recovery.

From the data at hand it is evident that urachal concretions or stones are very rare. They are usually no larger than linseed grains or millet-seeds. They are usually yellowish brown or brown in color, and may resemble corpora amylacea. They are too small to be a surgical factor, and are of interest only to the pathologist.

#### URINARY CALCULI IN THE URACHUS.

In 1877 Vosburgh reported his observations on a man aged fifty, who had been complaining of a soreness and constant pain at the navel. Examination showed redness, tenderness, and a hard swelling around the umbilicus. The tumor was incised, and at the depth of half an inch a stone, the size of a hickory-nut, was felt and at once removed. The stone was phosphatic in character and had a strong urinary odor. The wound healed. The patient stated that, about twenty years before, a stone had been removed in a similar manner from this location.

\* Arrou: *Kyste suppuré de l'ouraque.* Bull. et Mém. de la Soc. de chir., Paris, 1910, xxxvi, 832.

Monod, in 1899, referred to the stagnation of urine in the interior of the urachus as giving rise to calculi. He said that Columbus, Marcellus, Donatus, Harder, and Bartholin had cited examples of this kind. He added that the calculi may be eliminated through the umbilicus, as was noted by Hagendorn, Rhodius, and Helwig.

The same author mentions a case recorded by Peyer in 1721, in which a calculus escaped from the umbilicus after retention of urine. In the chapter on Urachal Infections I have referred to a case reported by Weiser (p. 603). The patient, a woman seventy-five years of age, had had a purulent discharge from the umbilicus for fifteen years. When Weiser saw her she had a tumor the size of a cocoon situated in the mid-line, between the umbilicus and symphysis. When this was opened, five ounces of very fetid pus escaped, and also a calculus weighing 70 grains. The wound healed in three months. Wishing to find out the character of this stone, I wrote Dr. Weiser, and from his reply it appears probable that it closely resembled a vesical calculus, but, as noted from the history, there was no opening into the bladder and no urine escaped from the incision during the patient's convalescence.

Probably one of the most interesting cases is the one recorded by Dykes. It might be claimed that the extravescical portion of the stone developed in a diverticulum of the bladder, but the location of the opening in the top of the bladder and in the median line leaves little doubt that the cavity was a dilated portion of the urachus, especially as the probe in the cavity could be carried up to within two inches of the umbilicus.

**P a t e n t U r a c h u s a n d E n c y s t e d U r i n a r y C a l c u l i . \* —**  
 "This case, which both in its clinical and pathologic bearings I believe to be of some interest, came under observation on January 27, 1908, at Rae Bareli Oudh:

"The patient was a Hindu male, aged about thirty years, apparently healthy apart from his urinary complaint, which dated back some five years or more. Owing to pressure of work I had not seen him until he was on the operating table, prepared for litholapaxy. The urine, I was informed, was acid and free from albumin. Several small concretions lay free on the base of the bladder, but on commencing to crush the first, the beak of the lithotrite impinged upon what appeared to be a much larger calculus, occupying a position at the apex of the half-distended bladder. After the first stone had been crushed the projecting portion of this larger calculus was easily seized between the blades of the lithotrite, but was found to be fixed to the bladder-wall.

"To crush this calculus *in situ* appeared dangerous, if not impossible, so lateral lithotomy was performed and the forefinger passed into the bladder. The calculus was now found just within reach of the finger. With the forefinger on the tip of the calculus and the other hand on the abdominal wall, it was estimated to be of considerable size, and its upper portion seemed very close under the examining hand beneath the abdominal wall in the middle line. It was evidently an 'hour-glass' stone, the deeper half being considerably larger than the projecting portion felt by the finger. The projecting portion being steadied in the grasp of the lithotomy forceps, the perforated end of a long probe was insinuated alongside the neck, and gradually manœuvered around the whole circumference, loosening the retaining tissue, until, by gentle traction and rotation of the forceps, an 'hour-glass' calculus was safely delivered. A second calculus immediately dropped from the same pocket into the bladder cavity. It, together with the three small concretions, the presence

\* Dykes, Campbell: The Lancet, 1910, i, 566.

of which, on the bladder floor, had already been detected, was now removed, and the débris of the small stone, first crushed, washed out. In case other concretions might still be lying in the pocket its recesses were explored with a probe. Nothing further was found, but the probe passed up in the middle line, easily palpable through the abdominal wall, to a point two inches below the umbilicus. At the upper end the pocket seemed to be contracted to a mere sinus. Convalescence was rapid and uncomplicated.

“The ‘hour-glass’ calculus weighed over  $1\frac{1}{2}$  ounces. Its neck was of about the thickness of a cedar pencil, but somewhat flattened. The deeper lobe was larger than the projecting head, which was capped by a pea-sized, rough, dark-colored concretion, easily broken off, when dry, from the head proper. This terminal concretion resembled exactly, in color and approximately in size, the four small concretions which had been found free in the bladder, differing only in being rough and not polished or faceted by attrition. This resemblance strongly suggested that these four also owned the same source, from the head of the ‘hour-glass’ calculus. Each weighed about 10 or 12 grains. The second encysted calculus showed a large oval facet corresponding to a like facet on the base of the ‘hour-glass’ calculus. Its longer axis had lain at right angles to that of the diverticulum in which it lay. It weighed just over half an ounce.

“Neither in recorded cases nor in museum specimens have I come across any instance in which an encysted calculus had occupied the apex of the bladder. All the records I have found refer to basal or lateral sacculi, such as are commonly associated with enlarged prostate and chronic cystitis. This is so, for instance, in all the cases of encysted calculus included in the late Sir Henry Thompson’s series of over 800 cases, the specimens of which are now in the museum of the Royal College of Surgeons of England. From the position and relations of the diverticulum this case appears to be an example of persistent patency of the lower end of the urachus, with calculus formation following, presumably on the accidental lodgment of a small concretion in it.

“While urachal cysts are much commoner in the female than in the male, a patent condition of the urachus leading to urinary umbilical fistula is much commoner in the male.”

**A Patent Urachus; Vesical Calculi; Sac-like Dilatations in the Urachus Containing Urinary Calculi; Removal of All the Calculi; Recovery.**—During the meeting of the Southern Surgical and Gynecological Association held in Cincinnati on December 13, 1915, the President, Dr. Bacon Saunders, of Fort Worth, Texas, told me of the following interesting case that came under his care several years ago.

The patient was a boy about eleven years of age. He had had all the classic symptoms of stone in the bladder since infancy. Examination disclosed a fistulous opening at the umbilicus through which escaped quantities of foul-smelling urine. On a line from the umbilicus to the pubic region were five nodules ranging in size from a hazelnut to an almond.

A number of small calculi, resembling prostatic stones were removed from the bladder. An incision was made over each of the nodules in the mid-line below the umbilicus and a stone removed from each. These stones were of the same character as those found in the bladder. Urine escaped from the multiple openings for a while, but these openings eventually all closed, and the boy made a satisfactory recovery.

## REMOVAL OF VESICAL STONES THROUGH THE UMBILICAL OPENING.

In the chapter on Congenital Umbilical Urinary Fistula (p. 507) I have quoted the well-known case of Paget and Bowman. The patient, John Conquest, an iron founder, forty years old, had had a urinary fistula at the umbilicus since birth. Paget detected a stone in the bladder. The umbilical opening being rather large, he introduced a finger, engaged the stone in the urachus, and brought it out through the umbilicus. This stone was irregularly ring-shaped, having developed around a curled-up hair (Fig. 221, p. 507). It was by getting the tip of his finger into the central hole in the stone that he was enabled to remove it by this route.

Nicaise refers to a case published by Faivre in the *Journal de méd. et chir.*, 1786. The patient, a small girl of twelve, had for four years passed her urine from the umbilicus. The urethra was obstructed by a calculus. Finally there was considerable engorgement of the surface of the abdomen, due to the urine escaping into the cellular tissue. Faivre entered the bladder through the umbilicus and removed the stone. A sound was introduced into the urethra, and the child made a complete recovery.

If urinary calculi develop in the urachus, they will naturally be found near the bladder, as indicated in Fig. 255.

## OTHER CALCULI IN THE UMBILICAL REGION.

On p. 337 we have discussed at length the escape of gall-stones at the umbilicus. The following cases, reported by Köstlin and by Bramann, while not strictly germane to the subject, are of considerable interest. Communication Between the Gall-bladder and the Urinary Bladder, With Escape of Gall-stones Through the Urinary Tract.—Köstlin\* cites the case of a patient whose history Faber had already reported in an inaugural dissertation. This woman first had

\* Köstlin, O.: Verbindung zwischen Gallenblase und Harnblase, mit Abgang von Gallensteinen durch die Harnwege. *Deutsche Klinik*, 1864, xvi, 116.

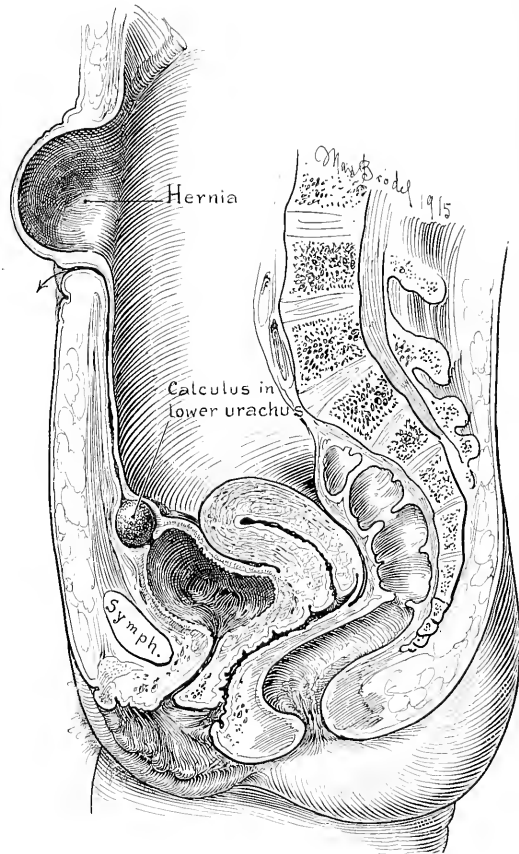


FIG. 255.—A PATENT URACHUS CONTAINING A VESICAL CALCULUS. (Schematic.)

The urachus is recognized as an open channel from the upper part of the bladder to the umbilicus. Just above the bladder it contains a spheric and rough vesical calculus. In the upper part of the umbilicus is a small umbilical hernia.

trouble when thirty-five years of age. In the autumn of 1834 she had signs of peritonitis, with pains in the umbilical region. Later the pain was more marked above the symphysis. In October, 1835, she was again ill, this time with bronchopneumonia. On the fourth day there was pain over the symphysis, and the urine was blackish green (bile). The patient soon passed gall-stones, large and small, by the urethra. The gall-stones were examined chemically. The patient was kept under observation for years. She died, at sixty-three, with symptoms of bronchial catarrh and asthma.

Autopsy.—The liver was normal, but the entire organ was situated lower than usual. From the middle of the lower edge a rounded cord extended to the base of the bladder, passing in front of the intestine and pushing the transverse colon downward and to the left. The cord consisted of two portions—the lower and larger half was 1" 7.6''' (about one and three-fourth inches long) and was composed of the urachus. The upper, shorter half belonged to the lower portion of the gall-bladder. The entire length of this was 3" 1.5''' (about 3 $\frac{1}{6}$  inches long). The route which the bile and gall-stones traveled was from the gall-bladder through the urachus to the urinary bladder.

Köstlin mentions a similar case, reported by Pelletan.\* In this case there was no autopsy.

Probably a Distended Gall-bladder Opening at the Umbilicus. †—The patient was a single woman, sixty-three years of age. She had had typhoid when thirteen. At the age of forty-five she had had sudden abdominal pain, accompanied by high fever, and there was much discomfort in the gall-bladder region. There was a tendency to vomit, and the abdomen was somewhat swollen. A tumor could be made out above and to the right of the umbilicus. It was the size of a fist and painful. The tumor persisted, grew slowly, and tended to pass more and more downward toward the symphysis.

Two years later a large quantity of foul pus escaped from the umbilicus. Pus continued to be discharged in varying amounts from the umbilicus for about sixteen years. The patient was otherwise in good condition.

On admission the abdomen was found to be slightly distended. The skin surrounding the umbilicus was covered with crusts, exfoliated epithelium, and small cysts. The umbilicus was drawn in, and in its center was a small discharging fistula. The escaping pus was foul-smelling. On palpation exactly in the mid-line a long, egg-shaped tumor was noted. At the umbilicus this was 5 cm. broad. It extended almost to the symphysis, and in its lower portion it was 7 to 8 cm. wide. The tumor lay distinctly behind the abdominal wall, and only in the neighborhood of the umbilicus was it intimately attached. In the lower part it was somewhat movable. On pressure it was found to be of dense consistence. A sound could be passed 12 cm. toward the symphysis and the cavity widened out. Calculi were detected at the bottom. Urination was always normal.

Operation.—The abdominal wall was incised for 8 cm. from the umbilicus downward. Four faceted calculi the size of pigeon's eggs were removed, and the tract was curetted out. Healing occurred after three months, but in the mean time it was necessary to curet the cavity several times. After several vain attempts Bramann found in some places many layers of squamous epithelium.

\* Pelletan: Jour. de chimie méd., 2. sér., ii, Nos. 11 et 12.

† Bramann, F.: Arch. f. klin. Chir., 1887, xxxvi, 996.

Microscopic examination of the calculi yielded cholesterin and bile-pigment; no urinary salts.

[The condition might well be explained by a gall-bladder extending into the pelvis and at the same time becoming adherent to the umbilicus. Everything points to this explanation, although Bramann considered the case to be one of open urachus. —T. S. C.]

#### LITERATURE CONSULTED ON URACHAL CONCRETIONS AND URINARY CALCULI ASSOCIATED WITH URACHAL REMAINS.

- Arrou: Kyste suppuré de l'ouraque. Bull. et Mém. de la Soc. de chir., Paris, 1910, xxxvi, 832.
- Bramann, F.: Zwei Fälle von offenem Urachus bei Erwachsenen. Arch. f. klin. Chir., 1887, xxxvi, 996.
- Civiale, J.: Traité de l'affection calculeuse, Paris, 1838, 257.
- Dykes, C.: Patent Urachus and Encysted Urinary Calculi. The Lancet, 1910, i, 566.
- Hoffmann, C. E. E.: Zur pathologisch-anatomischen Veränderung des Harnstrangs. Arch. der Heilkunde, 1870, xi, 373.
- Köstlin, O.: Verbindung zwischen Gallenblase und Harnblase, mit Abgang von Gallensteinen durch die Harnwege. Deutsche Klinik, 1864, xvi, 116.
- Ledderhose, G.: Chir. Erkrankungen des Nabels. Deutsche Chirurgie, 1890, Lief. 45 b.
- Luschka, H.: Ueber den Bau des menschlichen Harnstranges. Arch. f. pathologische Anatomie u. Physiologie u. f. klin. Med., 1862, xxiii, 1.
- Monod, J.: Des fistules urinaires ombilicales dues à la persistance de l'ouraque. Thèse de Paris, 1899, No. 62.
- Nicaise: Ombilic. Dict. encyclopédique des sciences médicales, Paris, 1881, 2. sér., xv, 140.
- Phillips, B.: Persistence of the Urachus. Todd's Cyclopædia of Anatomy and Physiology, 1835, i, 393.
- Rokitansky, C.: Pathologische Anatomie. 3. Aufl., Wien, 1861, iii, 372.
- Simon, C.: Quels sont les phénomènes et le traitement des fistules urinaires ombilicales. Thèse de Paris, 1843, No. 80.
- Suchannek, H.: Beiträge zur Kenntnis des Urachus. Inaug. Diss., Königsberg, 1879.
- Veiel, E.: Die Metamorphose des Urachus. Diss., Tübingen, 1862.
- Vosburgh, H. D.: Patent Urachus with Calculus. Medical Record, New York, 1877, 606.
- Weiser, W. R.: Cysts of Urachus. Annals of Surg., 1906, xlv, 529.
- Worster, J.: Case of Vesico-abdominal Fistula of Fourteen Years' Standing. Medical Record, 1877, xii, 196.
- Wütz, J. B.: Ueber Urachus und Urachusysten. Virchows Arch., 1883, xcii, 387.

## CHAPTER XXXVII.

### MALIGNANT CHANGES IN THE URACHUS.

Carcinoma of the urachus.

Historic sketch.

Symptoms.

Report of cases.

Sarcoma in the urachal region.

An extraperitoneal abdominal tumor.

A large multilocular carcinomatous cyst of the urachus; secondary growths in the pelvis (personal observation).

A rare umbilical cyst.

#### CARCINOMA OF THE URACHUS.

I HAVE been able to find three cases of carcinoma of the urachus recorded in the literature.

*S e x*. — All of the patients were men. Two of the patients had had congenital urinary fistulæ at the umbilicus, and in each of these the discharge of urine had ceased after the use of escharotics. The third patient also evidently had a congenital fistula, as he gave a history of "moisture at the umbilicus" during childhood. This had ceased without treatment.

*A g e*. — The patients were twenty-five, twenty-seven, and thirty-two respectively, indicating that, when carcinoma of the patent urachus develops, the malignant change occurs in early adult life.

Hoffmann and Fischer gave very careful and full histories of their cases. Hoffmann's patient, when twenty-seven years of age, noted a raised hardening between the umbilicus and symphysis. It was the size of a goose's egg, non-painful, and movable from side to side. It gradually extended toward the symphysis and right inguinal region.

Shortly after the tumor was noticed the patient experienced pain on urination. At times the urine was abundant, at times it came drop by drop. The man rapidly grew weaker and lost 25 pounds in four months. When Hoffmann saw him, the umbilicus presented a peculiar radiating appearance, while in the mid-line, just below the umbilicus, was a roundish, nodular tumor, 8 to 10 cm. long, adherent to the umbilicus and very painful. After the patient had urinated an area of tympany could be elicited between the tumor and the symphysis. On account of tenesmus, the patient urinated every hour. The urine contained pus and aggregations of epithelial cells.

The tumor became fluctuant, ruptured, and a large amount of purulent and bloody fluid escaped, but the growth did not diminish in size. From time to time onion-like balls escaped with the pus. These consisted of quantities of squamous epithelial cells that had become agglutinated. Precisely similar balls escaped in Fischer's case.

The urethra was normal.



The umbilical opening closed temporarily, but soon reopened, and in the late stages of the disease the inguinal glands were swollen.

As noted in the autopsy report, the cavity between the umbilicus and bladder had walls 1 cm. thick. Its inner surface had an irregular, ulcerated, and eaten-out appearance (Fig. 256). The bladder-wall had been involved by continuity, and also contained secondary nodules. The growth was a squamous-cell carcinoma.

Fischer's patient, when thirty-one years old, first noted a small, hard tumor the size of a pigeon's egg below the umbilicus. Seven or eight months later he had pain on micturition, and noticed a sediment in the urine. The nodule was incised on the supposition that it was fluctuant, and slimy, necrotic tissue escaped. The tumor soon grew out of the incision, bled a great deal, and finally left an ulcerated area, the walls of which were raised and hard, while the floor consisted of hard nodules. From the ulcerated area onion-like balls of epithelial cells escaped.

The inguinal glands on both sides became swollen. At autopsy the bladder mucosa showed a catarrhal swelling, but no involvement by the malignant growth. The prostate was normal. The growth was a carcinoma, evidently of the squamous-cell type, as indicated by the onion-like balls.

Death in these cases may occur from gradual weakening as a result of the disease, or from a perforation of the growth posteriorly into the abdominal cavity, causing a peritonitis. The occurrence of three cases of carcinoma of the urachus is another point in favor of the early removal of the patent urachus.

In the future cancer of the urachus, when met with, will undoubtedly be operated on early. The growth can be given a relatively wide berth, and the block dissection should include the inguinal glands on both sides.

#### CASES OF CARCINOMA OF THE URACHUS DEVELOPING YEARS AFTER THE CLOSURE OF A CONGENITAL PATENT URACHUS.

*Carcinoma Evidently Developing From Remains of the Urachus.* — Fischer\* saw this patient in consultation with Hanuschke in 1874. The man, thirty-two years of age, sought treatment on account of an ulcer of the umbilicus. During his childhood, when voiding, there was a moisture at the umbilicus. Later these symptoms disappeared and there was never any trouble with urination. Early in 1873 he casually noticed below the umbilicus a hard tumor the size of a pigeon's egg. This gave rise to no symptoms. It gradually grew, and seven or eight months later there were pain and a burning sensation on micturition and sediment in the urine. Toward the end of 1873 he consulted a physician. The difficulty in urination had increased, and the tumor had grown markedly. His general condition was not satisfactory. Hanuschke thought that the tumor was soft, and that he could make out fluctuation. Accordingly he made an incision, and purulent, slimy masses escaped—evidently pieces of necrotic tissue. The tumor mass grew out of the incision wound; it very soon broke down, with a good deal of bleeding, and an ulcer resulted. When Fischer saw the patient, he was pale and weak, had difficulty in micturition, and suffered from strangury. The ulcer was situated 2 cm. below the umbilicus, and formed a deep crater, which was heart-shaped. Its walls were elevated, hard, and extended below the level of the skin about 4 cm. Its greatest breadth was 8 cm. Its greatest length, 7 cm. The floor was very irregular

\* Fischer: Die Eiterungen im subumbilicalen Raume. Volkmann's Sammlung klin. Vorträge, n. F. No. 89 (Chir. No. 24), Leipzig, 1894, 519.

and covered with hard nodules. It reached a depth of 5 cm. below the skin surface. Surrounding the ulcer the tissue was hard. On pressure there escaped a thin, bloody, foul-smelling pus from the ulcer, and there were also portions of the tumor forced out as small balls suggesting onions. These were composed of quantities of flat epithelial cells.

The urine was acid, slightly cloudy, and had a purulent sediment. The inguinal glands on both sides were swollen.

Complete removal of the growth was impossible. The abdominal walls, however, were split in the mid-line as far as the symphysis, and beneath the muscle thick, pork-like tumor masses were found adherent. As much of the tumor as possible was removed, and the cautery was employed. The patient died fourteen days after the operation. Microscopic examination of the tumor mass showed it to be a carcinoma. At autopsy the inner surface of the bladder was found to show catarrhal swelling. It was intact. There was no abnormality in the prostate. The intestines were normal.

*A Patent Urachus, Closure; Later Carcinoma of the Urachus.* \*—This case was also mentioned in the *Deutsche Klinik*, 1864, xvi, 116. The patient was a man, twenty-eight years of age, who had a urachal fistula at birth. This was healed with escharotics. Twenty-five years later a tumor developed between the umbilicus and the symphysis. This broke and discharged pus and later urine. The autopsy revealed a carcinoma of the mucosa of the urachus, which had perforated into the umbilicus and into the bladder.

*A Patent Urachus Partly Closed by the Use of Escharotics; Later, Carcinoma of the Urachus.*—Hoffmann† first reports the case of Hermann R., in which there was an enormous sac formation and accumulation of fluid outside of the abdomen. This Hoffmann attributed to a dilated urachus.

Hoffmann reports the case of Alexander Wanner, a postal employee, who was born in 1841 with an opening at the umbilicus through which urine escaped, while it also passed from the urethra. This condition lasted until his third year, when the opening closed after the use of escharotics. The patient had no further difficulty, and with the exception of several inflammations of the eye was perfectly well. About the middle of the year 1868 he noticed between the umbilicus and the symphysis, near the umbilicus, a raised hardening of the abdomen about the size of a goose's egg, which was not painful and could be pushed from side to side. This gradually grew and extended toward the symphysis, and spread toward the right inguinal region. Shortly after the appearance of the tumor the patient began to have pain on urination. The urine sometimes came in an abundant stream; at other times only in drops. As a result the patient had a continuous desire to urinate. The pains became severe and he grew weaker. He had lost weight—in the last four months, 25 pounds. On admission to the hospital, November 10, 1868, he weighed 99 pounds, was poorly nourished, anemic, and had a peculiar radiating formation of the umbilicus, in the folds of which no opening could be discovered. Immediately below the umbilicus was a tumor, 8 to 10 cm. long, situated in the middle line. It

\* Graf, Fritz: *Urachusfisteln und ihre Behandlung*. Inaug. Diss., Berlin, 1896.

† Hoffmann: *Zur pathologisch-anatomischen Veränderung des Harnstrangs*. Arch. d. Heilkunde, 1870, xi, 373.

was roundish, nodular, very painful, and adherent to the umbilicus, but on both sides it was free. After urination, between the tumor and the symphysis was an area of tympany. On account of the tenesmus the patient urinated every hour, and the urine contained pus and aggregations of epithelial cells. The patient drank quantities of soda-water and local applications were made. His pain diminished, but the tumor continued to grow. The umbilicus became prominent, fluctuation was detected, and on December 1st the swelling broke and a large quantity of thick, purulent, bloody fluid escaped. The tumor, however, did not diminish in size, although the pain became less and less. In the fluid numerous onion-like balls were found. These consisted of large quantities of squamous epithelial cells which had become agglutinated.

Examination of the urethra with a bougie yielded nothing abnormal. The prostate was not enlarged, the bladder-wall was thick and did not contract completely after the escape of urine. From September 4th urine and purulent fluid often escaped from the umbilicus, and the urine passed from the bladder from that time on was cloudy. The opening at the umbilicus gradually contracted, and for some time only purulent fluid escaped from it. The tumor became smaller, and toward the middle of January, 1869, the umbilicus closed completely.

Diarrhea developed and marked emaciation. At the end of January the opening at the umbilicus reappeared, and a purulent-like material escaped. The pain became more severe. The inguinal glands were swollen and the patient grew weaker. On January 31st he weighed 88 pounds. He died in the middle of May, 1869.

Only an incomplete autopsy could be obtained. The family physician who made it said there were appearances of peritonitis. The umbilicus had a peculiar, radiating, stellar appearance, and there was an opening 3 mm. in diameter. Through this there was a passage going downward and backward into a canal which gradually widened. The cavity had walls 1 cm. thick. It extended from the umbilicus to the top of the bladder. It was 10 cm. in length, and in its middle portion was 2.5 cm. broad. The entire inner surface presented an ulcerated, irregular, much eaten-out, reddish appearance (Fig. 256).

At its lower part this cavity communicated with the bladder by an opening 3.3 cm. broad, and the posterior wall of the bladder was invaded by this ulcerated growth over an area 4 cm. in diameter. The bladder-walls, where invaded, were 1.8 cm. thick, while the unchanged portions were 0.8 cm. thick. At the point where the cavity communicated with the bladder posteriorly was a perforation, the exact size of which could not be determined on account of the tearing of the specimen. The bladder mucosa, on the whole, looked normal, but at one point in the anterior wall was a round nodule, 1 cm. in diameter; in the posterior wall were several smaller ones.

Microscopic examination showed that the growth of the urachus was a squamous-cell carcinoma, and that the secondary nodules were also carcinomatous.

Hoffmann says that this patient was born with a patent urachus. The opening at the umbilicus had closed after the use of escharotics in the third year. In the twenty-seventh year a carcinoma developed in the urachus and extended to the bladder. The perforation caused by the cancer led to a local peritonitis.

A Urachal Cyst and Cancer of the Bladder Occurring Independently. — Rotter's case may well be considered here. The urachus

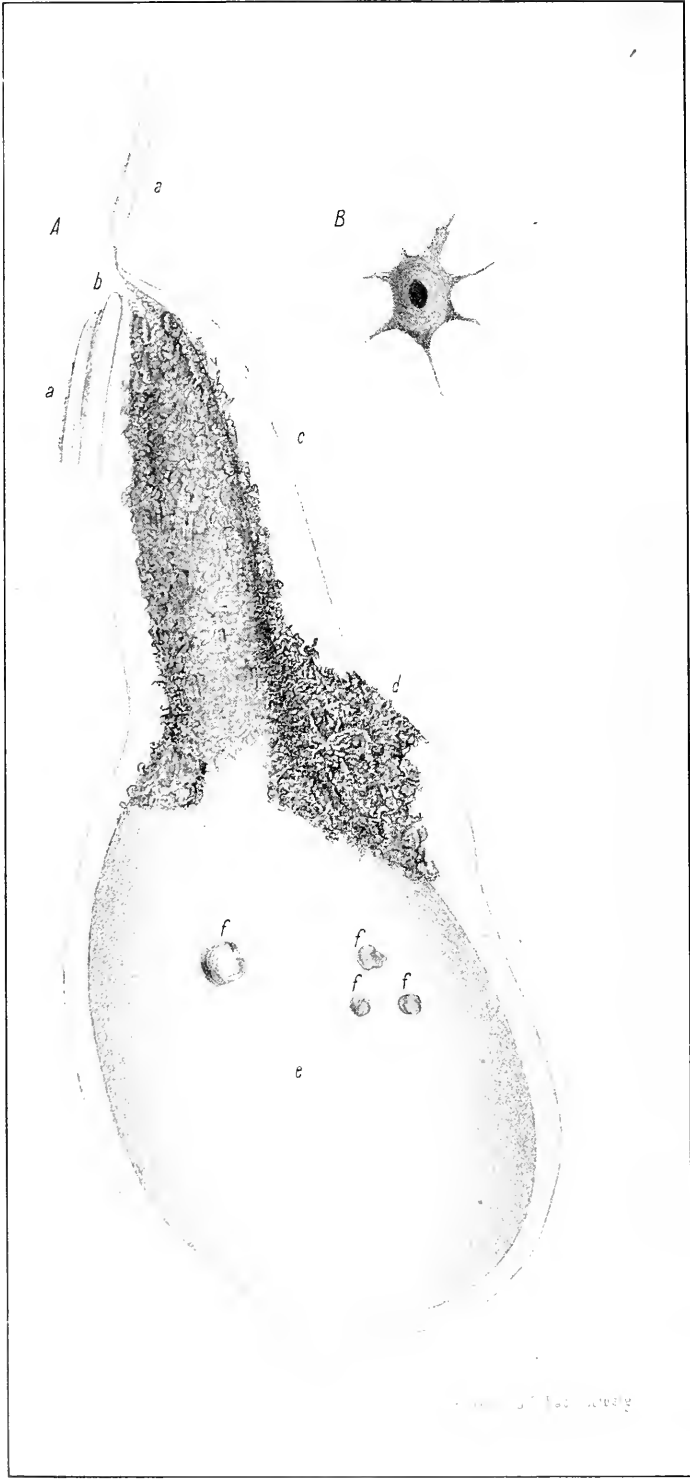


FIG. 256.—CARCINOMA OF THE PATENT URACHUS. (After C. E. E. Hoffmann.)

A is a partially diagrammatic picture: *a*, The anterior abdominal wall; *b*, the opening of the urachus at the umbilicus; *c*, the urachus, which is occupied by a carcinoma; at *d* the growth has broken through into the abdominal cavity; *e*, the bladder. At points *f, f, f, f*, on the bladder mucosa are small secondary carcinomatous masses. *B* represents the appearance of the umbilicus with the opening of the urachal fistula in its center.

was the seat of a cyst and the bladder showed a carcinoma. The one was absolutely independent of the other.

Rotter's\* patient was a forty-three-year-old man, who, for nine months, had had bleeding from the bladder. Cystoscopic examination showed a tumor in the upper portion of the bladder. This did not grow rapidly. Above the symphysis, and reaching to the umbilicus, was another tumor, which on aspiration yielded a fluid containing cholesterin. This tumor was diagnosed as a urachal cyst. At operation the upper tumor was found lying between the peritoneum and the abdominal muscles. In its upper portion it was free, but over the lower half it was so intimately blended with the peritoneum that it was necessary to remove a portion of the peritoneum with the tumor. The urachal tumor pressed so into the bladder muscle that it was also necessary to open this viscus.

The cancer of the bladder was removed, and a defect 7 by 8 cm. in the bladder closed by layers. This patient was shown by Rotter at the Berlin Surgical Society. Microscopic examination demonstrated carcinoma of the bladder. This had perforated at the point where the cyst was found. The cyst contained many polymorphous epithelial cells. There was no doubt that it was a urachal cyst.

Possibly an Adenocarcinoma of the Urachus.—I am at a loss where to place this case of Koslowski's.† The situation of the tumor suggests a urachal growth. Furthermore, the variation in the size of the glands might very readily correspond to the cyst-like spaces we have noted where isolated segments of the urachus have persisted. The invasion of the rectus sheath and of the rectus muscle naturally points toward malignancy. We shall accordingly leave this case among those of carcinoma of the urachus. Whether it really belongs here or not is problematic.

The patient was a man, fifty-five years of age, who five weeks before had noticed in the mid-line, between the symphysis and the umbilicus, a small, painful tumor which grew to the size of a walnut. This man was markedly emaciated, looked to be seventy years of age, had frequent diarrhea, and was bent over from guarding the abdominal muscles. Between the umbilicus and symphysis, near the mid-line, was a tumor which suggested a patella. The overlying skin was free. The tumor was slightly movable and very painful. It felt very tense, and gradually merged into the surrounding tissue. Passing from the tumor toward the umbilicus was a cord the size of a goose-quill. Koslowski thought the tumor was a malignant epithelial growth developing from remains of the urachus.

Operation.—A median incision showed that the linea alba and sheath of the rectus had been penetrated by the tumor. An elliptic incision encircled the umbilicus and the tumor. Removed with the tumor were portions of the sheath of the recti and some of the rectus muscle, the transversalis fascia, and peritoneum. After the abdomen was opened, the tumor was drawn up and brought into view fibrous cords passing to the umbilicus. The upper cord was the size of a goose-quill, firm, and infiltrated. The lower cord was less firm and contained veins; these passed into the vesico-umbilical ligament. The peritoneum covering the posterior surface of the tumor showed evidence of scar and of ulceration. The patient made a good recovery. The tumor in form resembled a patella. The peritoneum was firmly

\* Rotter: Blasencarcinom combinirt mit Urachuscyste. *Centralbl. f. Chir.*, 1897, xxiv, 604.

† Koslowski, B. S.: Ein Fall von wahrem Nabeladenom. *Deutsche Zeitschr. f. Chir.*, 1903, lxi, 469.

attached to it. The surrounding muscle was penetrated by the tumor. Microscopic examination showed that it was made up of glands of various sizes. They varied from the size of urinary tubules to those large enough to be noted with the naked eye. The diagnosis was fibro-adenoma submalignum. The glands resembled intestinal glands.

[It is difficult to establish the exact character of this tumor.—T. S. C.]

#### SARCOMA IN THE URACHAL REGION.

Frank, in 1893, recorded a very interesting case of sarcoma probably developing in the sheath of the urachus in a young lad. Unfortunately, the subsequent history of the case is lacking, but the histologic picture of the growth, the invasion of the muscles of the abdominal wall, and the secondary nodules in the omentum leave no doubt as to its malignancy.

Alban Doran reports a case of sarcoma developing in the wall of a cyst of the urachus. This is so interesting that I shall also record it in detail.

*Sarcoma Probably Developing in the Sheath of the Urachus.*—Frank\* gives a good résumé of the literature and reports the case of a boy eleven years of age. For several weeks he had had loss of appetite and was losing weight. About fourteen days before the boy came under observation the father noticed a swelling in the umbilical region, and from a small opening at the umbilicus a little pus could be pressed. There was no urinary difficulty and no discomfort on defecation. The urine, however, had recently become cloudy and stringy. The child's mother had died of pulmonary disease, otherwise the family history was good.

On examination the boy was found to be strong and well nourished. In the umbilical region was a hard, circumscribed thickening, only slightly painful on pressure, reaching about a fingerbreadth above the umbilicus. Here it could be traced three fingerbreadths to the right and to the left of the linea alba. Below it extended almost to the symphysis. The skin over the tumor was only slightly movable. A sound introduced into the sinus passed from 4 to 6 cm. downward. With a sharp curette friable, sanguineopurulent masses were removed. These on examination were found to consist of pus-cells, granulation tissue, and débris.

*Operation.*—An elliptic incision was made, commencing 3 cm. above the umbilicus. The recti muscles at the umbilicus were found to be infiltrated by the growth. The incision was then carried through healthy muscle to the peritoneum. Loops of small bowel were adherent to the peritoneal surfaces of the tumor, and nodules were found scattered throughout the omentum. The tumor was gradually turned outward and was removed without much difficulty. Its lower end was intimately adherent to the bladder, and the outer walls of this viscus were removed and the small opening in it was closed. The omentum was removed on account of the tumor nodules. The abdomen was closed with difficulty. The patient's recovery was slow.

The tumor, on section, was found to have invaded the recti in all directions. Its chief extension was along the course of the urachus as far as the bladder. The tumor itself, with the surrounding parts, was as large as a man's fist, and was nodular and uneven.

\* Frank, Theodor: Zur Casuistik der Urachustumoren. Inaug. Diss., Würzburg, 1893.

On microscopic examination the sarcomatous character of the tumor was evident. In the center of the tumor the intercellular substance was most marked, but toward the periphery it consisted almost entirely of spindle-cells with little connective tissue. The growth of the spindle-cells into the recti and into the bladder was especially evident. The entire picture indicated that the tumor had developed in the connective-tissue layers of the urachus and that it had then spread out in all directions.

The case is perfectly clear, but there is no after-history beyond two months, and no description of the omental nodules.

A U N I Q U E S P E C I M E N O F C Y S T I C S A R C O M A O F T H E U R A C H U S . \*  
—Alban Doran says: "Mr. F. S. Eve has presented to the Museum of the Royal College of Surgeons of England a unique specimen of cystic sarcoma of the urachus, and has kindly supplied me with the following notes:

"A man, aged thirty-eight years, was admitted into the London Hospital with a swelling in the hypogastrium noticed for several weeks and associated with pain after micturition. A cystic tumor filled the lower part of the abdomen, especially to the right, where it extended toward the loin. It did not dip into the pelvis. On puncture, dark blood came away; a few days later a rigor occurred, with vomiting and a rise of temperature to 104° F. Mr. Eve then operated, exposing a large cystic tumor; the parietal peritoneum was reflected over its anterior and superior surfaces. Five pints of dark, bloody material were removed. The cyst adhered to the omentum, which bore engorged veins, and to an inch and a half of small intestine which was infiltrated where adherent. The adherent portion of the wall of the gut was excised, and the wound closed with sutures. The lower part of the cyst was intimately connected with the bladder, the serous coat of which organ was reflected onto its surface. This peritoneal covering was divided, and the cyst carefully dissected away from the bladder. During the process the bladder was opened, for the vesical wall at this point was so thin that the cavities of the cyst and the bladder were only separated by the vesical mucous membrane covered by a few muscular fibers. The opening was sutured, but not without great difficulty, owing to the thinness of the walls at this point. The sutures were further protected by gauze packing. A gauze drain was passed into the pelvis, and a catheter retained for a while in the bladder. Neither flatus nor feces could be made to pass after the operation, and the patient died on the fourth day. There was no general peritonitis, but the pelvic peritoneum had become inflamed at the point where the gauze had been applied.'

"Mr. Eve examined the specimen and found that it was a large allantoic cyst separated from the posterior superior surface of the bladder by nothing except a very much thinned mucous membrane. Their cavities, however, did not communicate. The inner wall of the cyst was lined at certain points with very vascular polypoid masses, which proved to be, on microscopic examination, sarcomatous. The most unusual feature of this cyst was its malignancy, but its peritoneal relations were of greater importance in respect to the subject of this communication."

#### AN EXTRAPERITONEAL ABDOMINAL TUMOR.

The following interesting case, the specimen from which was exhibited by Dr. Aveling, may be considered here, although from the description one could not say

\* Doran, Alban H. G.: *The Lancet*, 1909, i, 1304.

that the growth was a sarcoma. It may serve, however, to form the nucleus around which similar cases may be collected.

Dr. Aveling\* exhibited before the British Gynecological Society a subperitoneal tumor which had grown in the anterior abdominal wall and reached from two inches above the umbilicus to the pubes. It was removed after death, the patient having succumbed after an exploratory operation. Sir Spencer Wells, who saw the tumor, said he had seen only two similar cases, and he classified the tumor, according to Virchow, as a fibroma molluscum cysticum abdominale. The specimen was referred to Mr. Bland-Sutton and Dr. Aveling for further examination.

The tumor was ovoid in shape, and measured 10 inches in length, 7 inches in width, and weighed  $4\frac{3}{4}$  pounds. It was surrounded by a distinct, thick, fibrous capsule. On section the tissue was of a dirty white color, and the cut surface looked like a sponge. The loculi were filled with gelatinous tissue, which readily broke down on scraping the cavities with the handle of a scalpel. Inside the growth six or seven hard nodules, of the size of walnuts, could be felt. These, when dissected out and divided, looked like small leiomyomata, such as occasionally exist in the uterus. They presented the same whorled arrangement of the fibers, and corresponded with them histologically. On microscopic examination of the tumor the outer portion was found to consist of non-stripped muscle-fibers, some of large size. Internal to this the cells assumed more the shape and characters of those seen in spindle-cell sarcomata, while the gelatinous material contained in the loculi was the result of mucoid degeneration of the sarcomatous elements.

Sutton and Aveling then go on to say that the specimen was of great interest from an etiologic standpoint. "Man, in common with other mammals, possesses a persistent pedicle of the allantois, familiar under the name of the urachus. This structure is frequently found dilated into a cyst, usually of small size. An account of these allantois cysts, with reference to a few recorded cases, will be found in the Path. Soc. Trans., xxxvi, 523." They drew attention to the fact that Mr. Lawson Tait, in his work on Diseases of the Ovaries, had described certain growths which he regarded as probably originating in the urachus, and which attained such considerable dimensions as to require operative interference.

They thought that, in the present case, they had to deal with an allantois cyst, the walls of which had become sarcomatous, thus affording another illustration of the great tendency exhibited so often by aberrant and ill-developed structures to become the seat of morbid growths, such as sarcoma or carcinoma.

[After a somewhat careful study of the literature on the subject of umbilical tumors, the interpretation of Bland-Sutton and Aveling is not altogether clear. It would rather seem as if we are dealing with a myoma. The gross description speaks of non-stripped muscle, and this the histologic picture substantiates. The gross and histologic appearance of the nodule coincides with the appearances presented by uterine myomata. The areas that were supposed to be sarcomatous and inclosed cavities presenting a mucoid appearance might very readily have been due to hyaline degeneration. Without an opportunity of examining their specimen we should hesitate to express any definite opinion as to this case, further than that their interpretation does not seem to tally with the recorded cases of secondary growths attributed to the allantois.—T. S. C.]

Doran\* says that Aveling and Bland-Sutton had already reported a case of

\* Aveling: Brit. Gyn. Jour., 1886-87, ii, 56 and 187.

† Doran, Alban H. G.: The Lancet, 1909, i, 1304.



multilocular myxosarcoma of the sheath of the urachus, but it did not involve the urachal canal, and was quite unconnected with the bladder. The specimen (No. 417 b) in the pathologic series of the Museum of the Royal College of Surgeons of England was supposed, when first examined, to have developed in the urachus, but Mr. J. H. Targett considered that it was a myxosarcoma which had originated in the connective tissue surrounding the bladder.

After I had made my comment on Aveling and Bland-Sutton's case, Alban Doran's note on the case came to my notice, clearly showing a lack of unanimity of opinion among those who had examined the specimen, not only as to the exact character of the tumor, but also as to its precise source of origin.

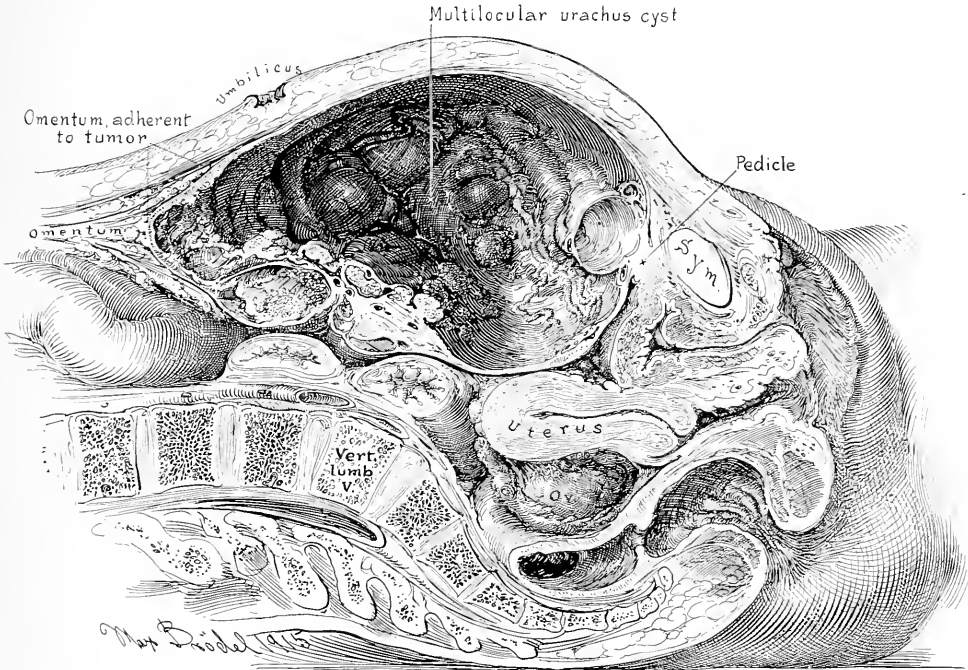


FIG. 257.—A MULTILOCULAR AND MALIGNANT CYST OF THE URACHUS.

Gyn.-Path. Nos. 10368 and 10488. The cyst lay between the abdominal muscles and the peritoneum of the anterior abdominal wall. Below it was attached by a pedicle near the top of the bladder. Upward it extended for a considerable distance above the umbilicus. The omentum was densely adherent to its upper surface. The cyst-wall anteriorly was so thin that I cut it, thinking that it was peritoneum. The cyst is composed of one large and many smaller cavities. Projecting into the large cyst are many smaller cysts, and papillary and solid growths spring from the inner surface of the cyst. Some of the smaller cysts have smooth walls, as is well seen in the one near the pedicle of the tumor. Cross-sections of other small cysts show that they are partially filled with secondary growths. It will be noted that the uterus, tubes, and ovaries are absolutely independent of the cystic tumor. They are, however, partially covered over with secondary cancerous nodules. (For the histologic appearances in this case see Figs. 261, 262, 263.)

#### A LARGE MULTILOCULAR CARCINOMATOUS CYST OF THE URACHUS; SECONDARY GROWTHS IN THE PELVIS.

I saw Mrs. W. W., aged thirty-seven, in consultation with Dr. E. S. Mann, of Dallastown, Pa., and had her admitted to the Johns Hopkins Hospital, October 6, 1906. This patient had never been pregnant. Her menses had commenced at fourteen and had always been regular until the previous year. Her last period had occurred sixteen months before admission. About two years before I saw her,

she had noticed, on moving, a sharp, sticking pain in the left lower abdomen. For about a year and a half she had had some abdominal enlargement, and eight weeks before admission the abdomen had commenced to swell a great deal. The feet and legs had also been swollen. The patient gave a history of having lost 20 pounds in



FIG. 258.—GIANT-CELLS IN THE WALL OF AN ADENOCARCINOMATOUS CYST OF THE URACHUS. ( $\times 90$  diam.)

Gyn.-Path. Nos. 10368 and 10488. Occupying the center of the field are slit-like spaces lined on one or both sides with giant-cells. The most perfect picture is that seen at *a*. At *b* is a giant-cell lying in the stroma. From this picture as a whole one gets the impression that these slit-like spaces may be due to the cracking of brittle giant-cells. At *c* are the epithelial cells lining a gland-like space of the carcinomatous cyst. Scattered throughout the field are quantities of small round-cells. Many of these have absorbed brown pigment, have swollen up, and at first sight look like vacuoles. In the center of these pale round or oval spaces the small round, deeply staining nucleus is still clearly visible. At *d* the stroma has undergone almost complete hyaline transformation.

the past six months. She had had dysuria, and had had to void four or five times during the night.

On admission it was noted that she was a well-nourished woman, weighing 172 pounds. The abdomen was markedly distended. It rose rather abruptly from the symphysis to the umbilicus, and then gradually shaded off to the xiphoid. On

percussion fluid was evident in all parts of the abdomen. About two months before she had noticed large and small lumps in various parts of the abdomen. Some of these were fully an inch in diameter, and they had sharp edges.

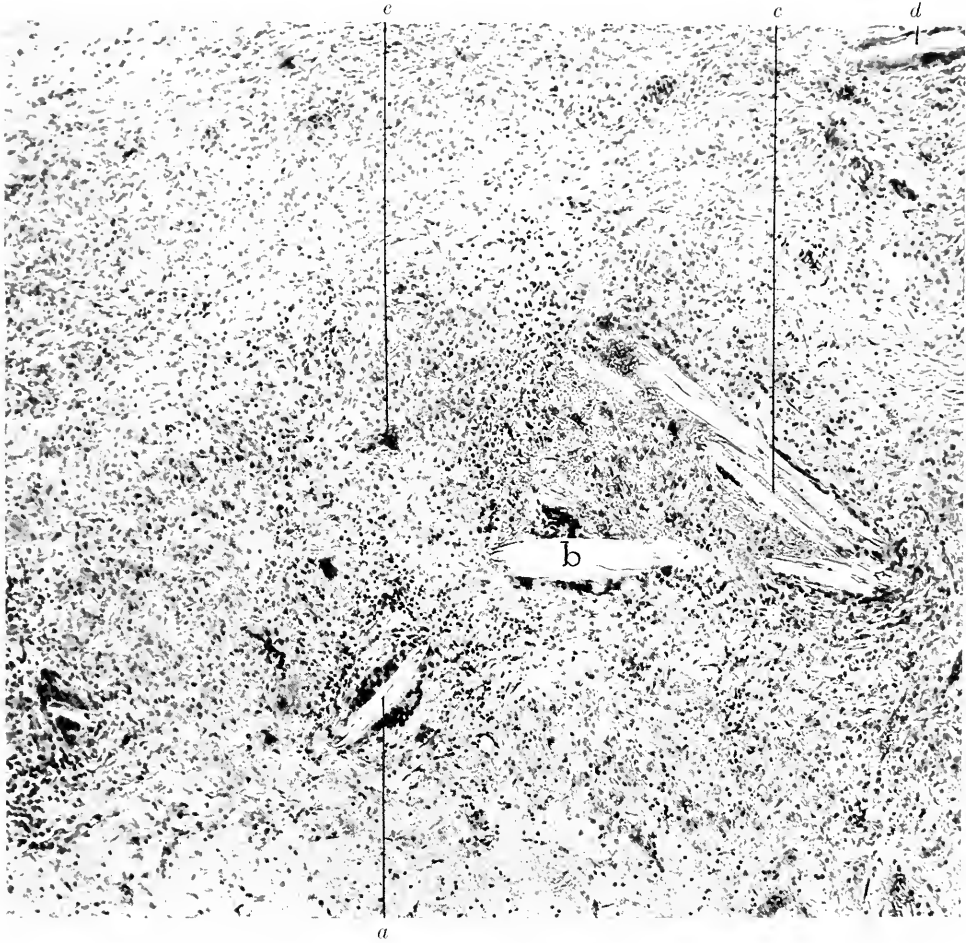
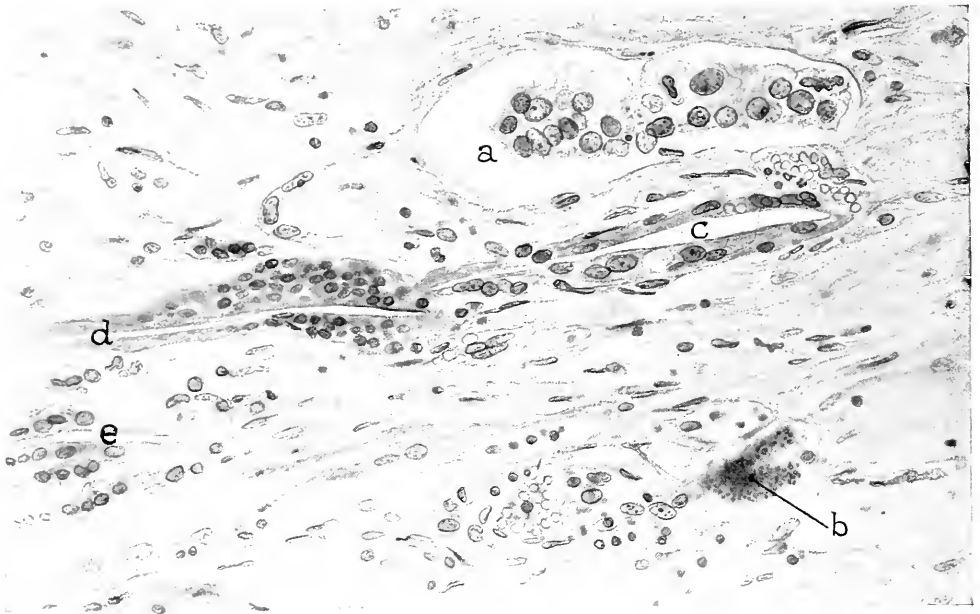


FIG. 259.—GIANT-CELLS IN THE WALL OF AN ADENOCARCINOMA OF THE URACHUS. ( $\times 90$  diam.)

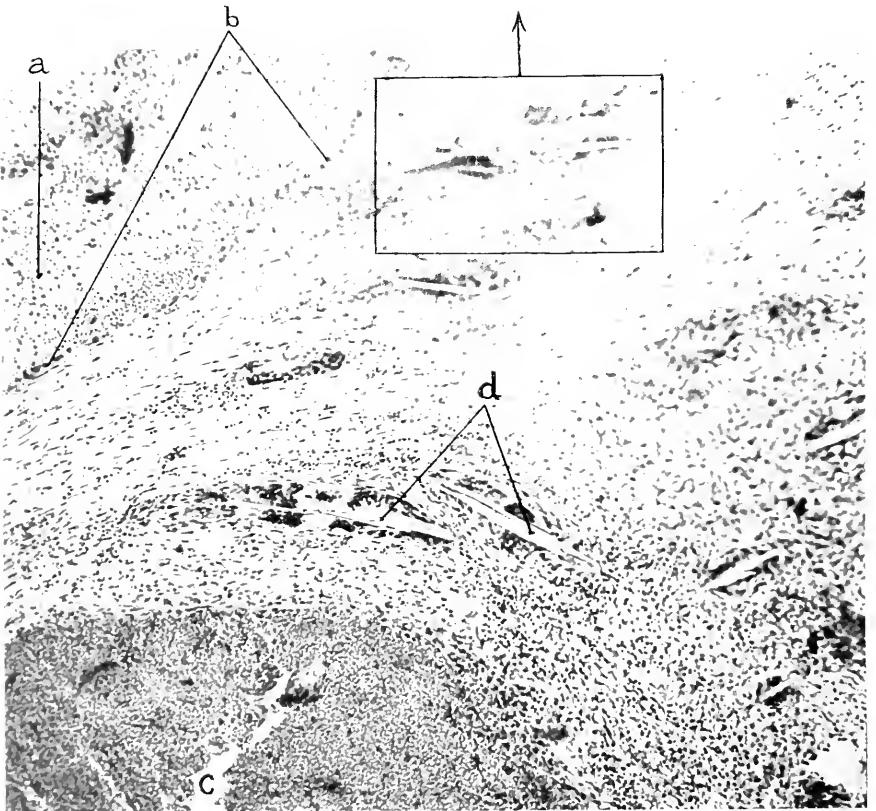
Gyn.-Path. Nos. 10368 and 10488. At *a* is a slit-like space lined on both sides with a large giant-cell. The nuclei of the giant-cells are irregularly distributed and stain deeply. Extending from one end of the space to the other is a delicate strand. This, under a higher power, was found to contain two small nuclei. At *b* is an irregular oblong space with a large giant-cell in the center of its upper margin, and an irregular mass of protoplasm containing numerous nuclei bordering its lower margin; projecting into the cavity from either end are delicate filaments of stroma devoid of nuclei. At *c* is a series of parallel slits. The tissue at this point consists of hyaline material. Most of these slits have no lining whatsoever, but both the upper and lower slit have small giant-cells attached to their margins. At *d* is a slit-like space lined with giant-cells. *e* is a giant-cell that could be clearly focused at another level. It was irregularly triangular in shape, and contained a quantity of oval, uniformly staining nuclei arranged chiefly at one end of the cell. There were other giant-cells scattered throughout the field. The protoplasm of some of these was brownish in color, apparently owing to the absorption of old blood-pigment. The stroma of the cyst-wall in this region consisted of fibrous tissue. In the vicinity of these giant-cells and in the neighborhood of the slit-like spaces it showed a great deal of hyaline transformation; many of the small round-cells that still persisted were swollen and contained a yellowish or brownish pigment—undoubtedly caused by old hemorrhage.

On pelvic examination the cervix was found to be perfectly normal; nothing further could be made out.

Operation (October 8, 1906).—On opening the abdomen I immediately came



B



A

FIG. 260.

in contact with the contents of a cyst. This cyst was large, multilocular, and intimately adherent to the anterior and lateral abdominal walls (Fig. 257). At first I thought it was impossible to remove it, but on continuing the incision upward we entered the general peritoneal cavity. I then delivered the tumor from above downward. Its pedicle sprang from the top of the bladder. This pedicle was 1 cm. broad and 2 mm. thick. Raw areas were left, both on the anterior and lateral abdominal walls. The bleeding was checked by sliding over the peritoneum as far as possible, thus bringing the raw areas together and diminishing the size of the denuded space.

Both ovaries were normal in size, but were somewhat glued down to the pelvic floor. As the pedicle of the cyst sprang from the bladder, I thought it advisable to turn it in, fearing that there might be an opening between the bladder and the cyst. In the pelvis were metastatic deposits, some of them very minute, others irregular, somewhat translucent, and fully 1 cm. in diameter. The appendix was removed, and the abdomen closed. The patient was discharged November 5, 1906. In answer to an inquiry Dr. Mann wrote me that the patient died January 8, 1908.

Gyn.-Path. Nos. 10368 and 10488.—The cyst-walls vary considerably in thickness. At some points they are thin and transparent; at others they reach the thickness of about 2 cm. These solid areas also contain cysts, and in the small cysts is a blackish-colored fluid. The entire specimen is vascular, and in some places friable and apparently malignant.

On histologic examination the walls are found to consist in part of fibrous tissue, with a definite laminated arrangement. In many places necrosis has taken place, and the tissue presents a homogeneous appearance or takes the stain very poorly. At other points in the walls the connective-tissue cells have taken up much brown pigment, evidently from a long-standing hemorrhage. Here and there throughout the walls are slit-like spaces, the smaller ones surrounded by giant-cells\* (Fig. 258). The giant-cells really consist of large masses of protoplasm containing oval or round, deeply staining nuclei (Fig. 260), and some of these nuclei are four or five times the size of the surrounding ones. Where the cavities are larger, giant-cells may be seen clinging to one side of the cavity, other portions of the cavity being devoid of a lining (Fig. 259). At certain points are aggregations of giant-cells, and interspersed are small, slit-like spaces. One is instantly reminded of the giant-cells and slit-like spaces noted by Bondi, and on careful examination we found here and

\* I am fully aware of the frequency with which foreign-body giant-cells are prone to occur in the walls of certain cysts and elsewhere, but the giant-cells in this case are rather unusual, hence I have described them more or less in detail.

FIG. 260.—GIANT-CELLS IN THE WALL OF AN ADENOCARCINOMATOUS CYST OF THE URACHUS. ( $\times 90$  and  $300$  diam.)

Gyn.-Path. Nos. 10368 and 10488. A. *a* seems to be a large, gland-like space filled with coagulated blood and exfoliated epithelium. It is lined with one layer of low cuboid epithelium, well seen at *b*. *c* is a large blood-vessel. Scattered throughout the stroma of the cyst-wall are giant-cells and quite a number of slit-like spaces lined with giant-cells. Traversing the slit-like spaces (*d*) are delicate strands, one of which contains very small nuclei.

B. This shows an enlargement of the oblong area in A. The stroma consists of fibrous tissue. At *a* is a nest of cancer-cells which has retracted from the surrounding connective tissue. *b* is a deposit of calcareous material near the wall of a blood-vessel. *c* and *d* are slit-like spaces. *c* is lined with a ribbon of protoplasm showing nuclei scattered fairly evenly throughout it. It is impossible to detect any division of the protoplasm into individual cells. The space *d* is lined with a wide zone of protoplasm showing many nuclei, uniform in size and staining properties, equally distributed throughout the protoplasm. *e* is another slit-like space lined with a ribbon of protoplasm containing only a single row of nuclei.

there crystals lying in the cavity, such as were also found by Bondi. Other portions of the tumor show gland-like spaces lined with one or more layers of epithelium (Fig. 261). The nuclei of the epithelial cells are oval and vesicular, or are deeply staining, and the epithelium itself is of the low cylindric variety. In some places the epithelium has proliferated to a moderate extent. The gland arrangement in

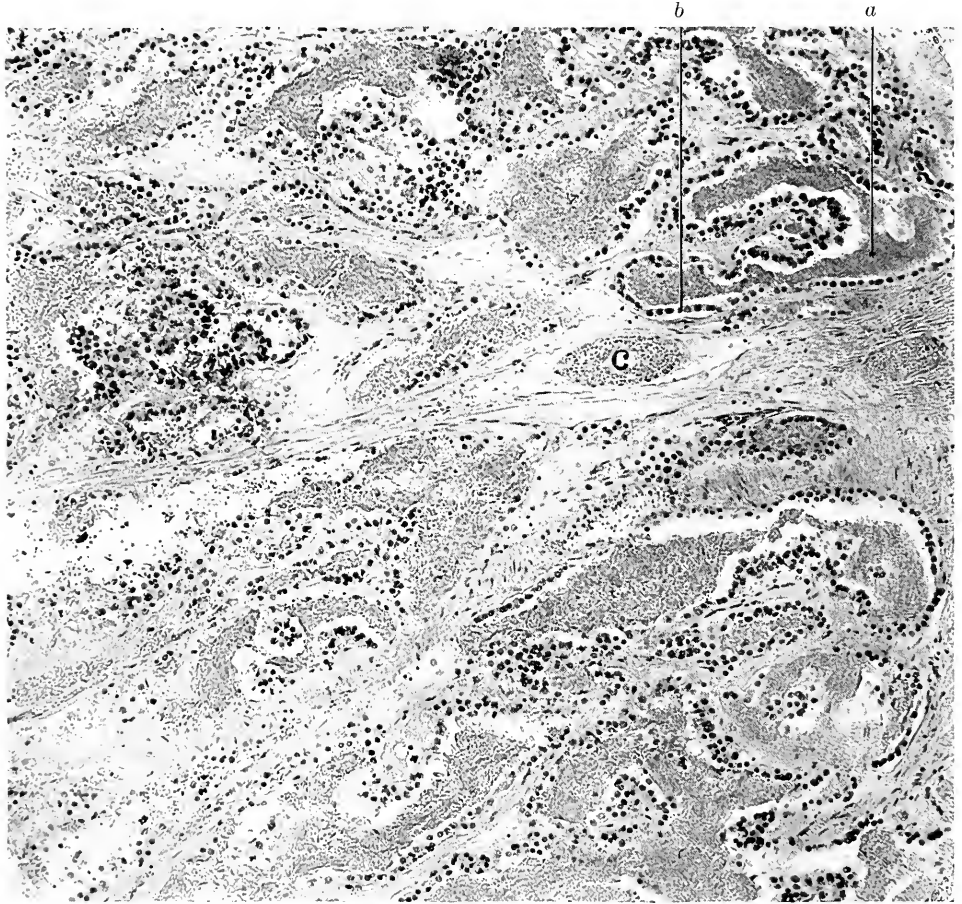

FIG. 261.—ADENOCARCINOMA OF THE URACHUS. ( $\times 90$ diam.)

Gyn.-Path. Nos. 10368 and 10488. The growth at this point bears considerable resemblance to a papilocystoma of the ovary; it consists of large and small irregular spaces lined almost exclusively with one layer of cuboid or low cylindric epithelium. *a* is a very good example of one of the spaces with a projection into it from the side. This space is lined with one layer of cuboid epithelium containing relatively round and deeply staining nuclei. These nuclei are particularly well seen at *b*. The granular contents in the gland-spaces consist of coagulated epithelial secretion. The epithelial elements in the left lower part of the picture have to a large extent melted away. The fibrous stroma of the growth contains very few nuclei. *c* is one of the blood-vessels in the stroma. From this picture alone one could not tell definitely whether the growth was malignant or not. That it is malignant, however, is definitely settled by a reference to Fig. 263, and also by the fact that at operation metastases were found.

some places suggests a papillary formation (Fig. 262), and the gland cavities are filled with a homogeneous material that takes the eosin stain. The epithelial cells at other points are almost flat. There does not seem to be much variation in the size of the cells, and such a picture alone would suggest a papilocystoma. At other points the epithelium has proliferated markedly, so that we have what



appears to be solid nests; or the epithelium has melted away, as is noted in colloid carcinoma.

There is no doubt we are dealing with a multilocular cyst that has become malignant. This cyst certainly belongs to a rare type. Of the malignancy, there can be no doubt, because metastases in the pelvic peritoneum were noted at operation (Fig. 263). It did not spring from the ovaries, as they were perfectly normal in

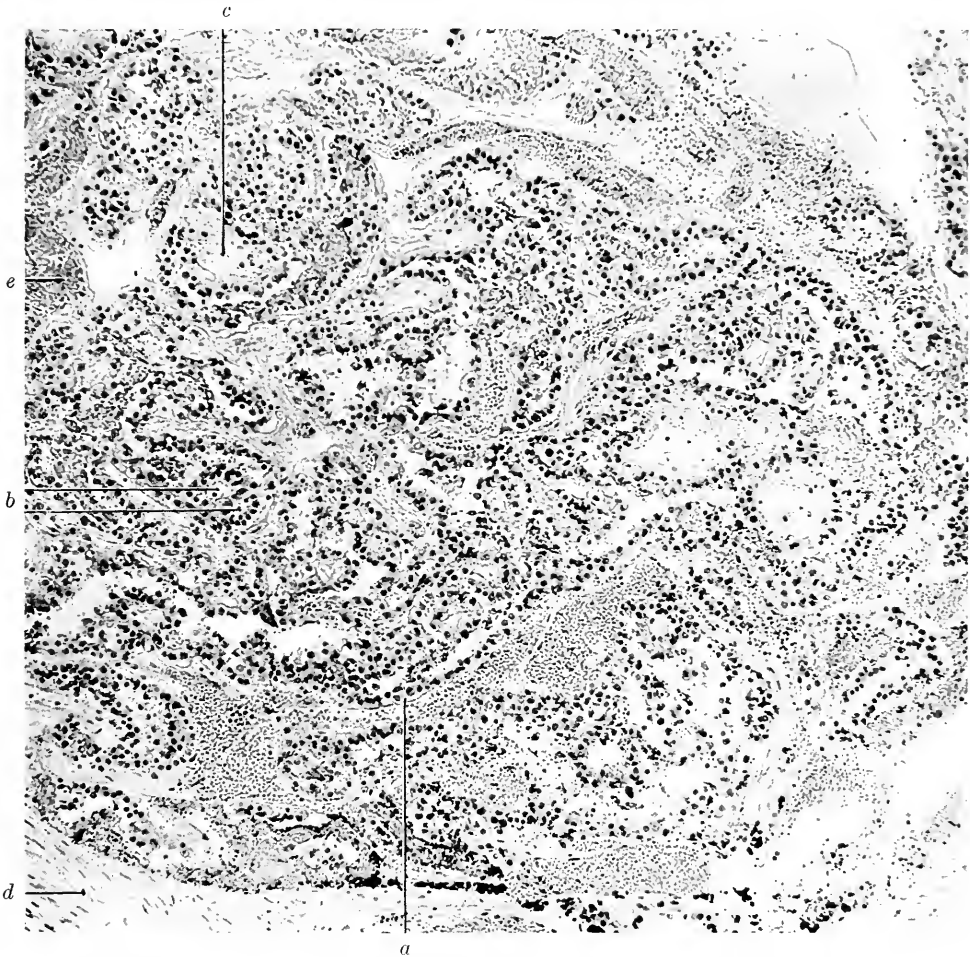


FIG. 262.—A PAPILLARY-LIKE AREA IN AN ADENOCARCINOMATOUS CYST OF THE URACHUS. ( $\times 90$  diam.)

Gyn.-Path. Nos. 10368 and 10488. The picture is a rather confused one. At *a* the complex papillary mass is seen covered with one layer of cuboid epithelium having round, uniformly staining nuclei. At *b* are two definite gland-like spaces. At *c* is a bluntish projection of the stroma into a gland-space. *d* indicates the stroma, consisting of spindle-shaped connective-tissue cells. The gland-spaces are filled with a granular, homogeneous material seen at *e*. (For the appearances of the metastases see Fig. 263.)

size and distant from the growth. Its pedicle, as noted from the history, sprang from the top of the bladder. It will further be noted that during the removal of the tumor a large part of the peritoneum of the anterior and lateral abdominal walls had to be sacrificed. This tumor evidently originated from the urachus.

The mode of origin of the giant-cells has been of especial interest to me. It will be noted that these giant-cells have been found almost entirely in the outer con-

nective-tissue wall of the large cyst, and that the cavities that they line are slit-like. This is particularly well seen in Fig. 258. Furthermore, in the vicinity of these slit-like spaces are well-formed giant-cells lying completely surrounded by stroma (Fig. 258, *b*). On examining the space *b* in Fig. 259, one gathers the impression that the tissue has been especially brittle, and that during the process of hardening the giant-cells may have split lengthwise; this impression is still further strengthened by examining the area *c* in Fig. 259. Here the protoplasm has apparently been split up into several long strands. At the upper end of this

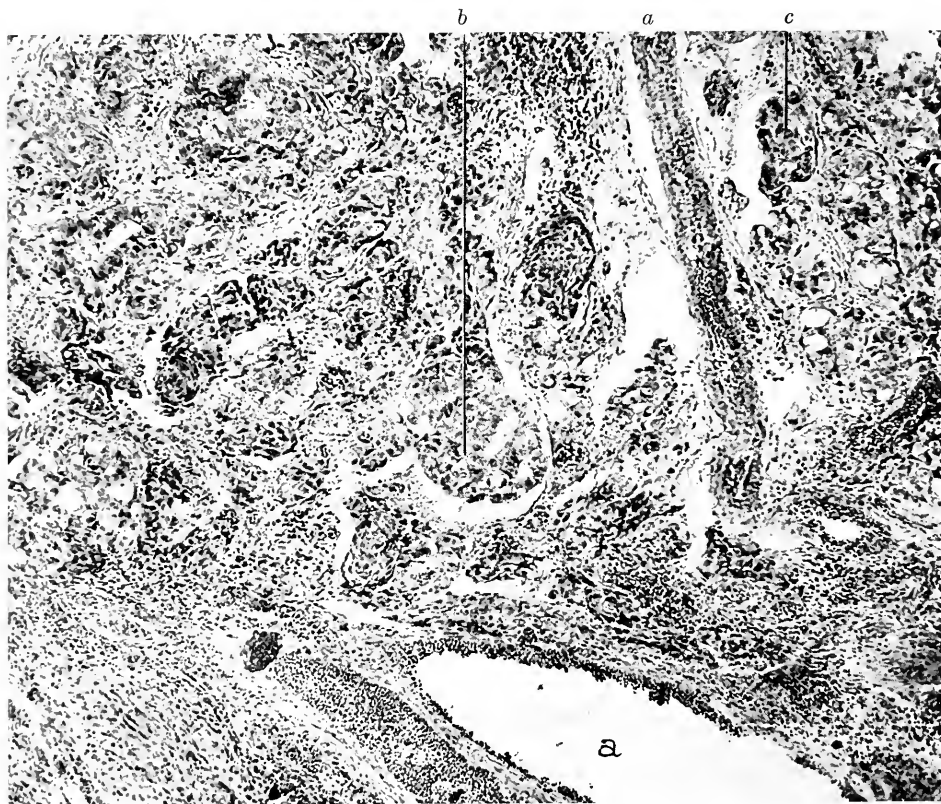


FIG. 263.—METASTASIS FROM ADENOCARCINOMA OF THE URACHUS. ( $\times 90$  diam.)

Gyn.-Path. Nos. 10368 and 10488. *a* and *a* are blood-vessels. Scattered throughout the field are nests of epithelial cells. Although originally the growth was glandular, the metastases have tended to form solid nests. At *b*, however, two gland-like spaces can be faintly made out. During the process of hardening the cancerous tissue tended to retract from the stroma. This is especially well seen at *c*. The stroma of the growth showed considerable small-round-cell infiltration.

area there is an intact giant-cell. The finer structure of the giant-cell is well seen in Fig. 260, *B*, *d*.

In an examination of a large number of ovarian cysts I have never seen a picture analogous to the one here depicted. To be sure, in very young dermoid cysts of the ovary, giant-cells are the rule, but here they are invariably lining or clinging to the walls of small cysts—such giant-cells are the embryonic stages of squamous epithelium.

Dr. William H. Welch informed me that he had occasionally seen giant-cells



similar to these in the walls of cysts and elsewhere, and suggested that they might be foreign-body giant-cells. He further suggested the possibility of their developing around crystals. On careful examination of many giant-cells I found just one crystal. This was irregular in form. Whether the giant-cells in this case are foreign-body cells or not I cannot say. This point, of course, is of interest only to the pathologist.

Bondi reported a small umbilical cyst of unknown origin. He found quantities of giant-cells analogous to those here depicted (Fig. 266), and in his case some of the giant-cells surrounded crystals. Although his cyst was not malignant, it is of such interest in connection with my case that I shall here report it somewhat in detail.

#### A RARE UMBILICAL CYST.

Bondi\* reports this case from Schauta's clinic. The patient was a woman, sixty-two years of age. She had had three normal labors. About twenty months before coming under observation she noticed that the umbilicus was larger than usual,

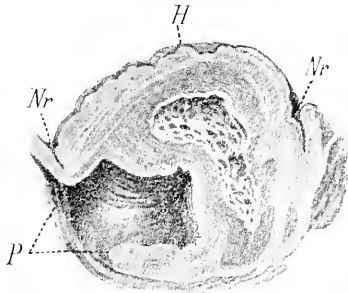


FIG. 264.—AN UMBILICAL CYST. (After Bondi.)

The original tumor was 5 cm. in diameter. The drawing has been made from the hardened specimen, which was much contracted. Nearly two years before operation the patient had noted an enlargement at the umbilicus. The overlying skin was brownish in color, tense, and elastic. It was slightly compressible. *H* is the skin covering the cyst; *Nr*, the confines of the umbilical depression; *P*, a prolongation of the peritoneal cavity into the mass. The walls of the cyst were composed of two layers—an outer, consisting of whitish tissue, and an inner, homogeneous zone, grayish brown in color. The cyst contents were spongy, yellowish brown, and soft. (For the histologic picture see Figs. 265 and 266.)

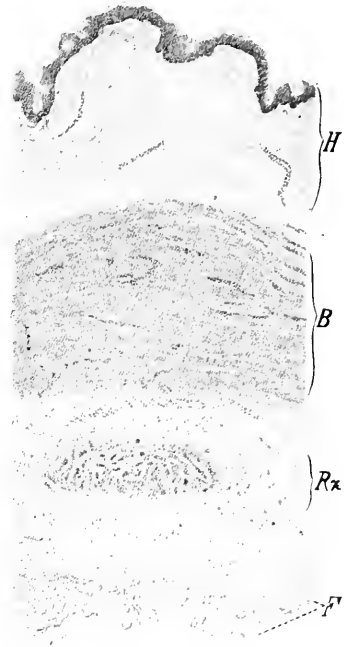


FIG. 265.—WALL OF AN UMBILICAL CYST. (After Bondi.)

This is a section of the cyst-wall seen in Fig. 264. *H* represents the skin, with connective tissue immediately beneath it; *B*, a dense layer of connective tissue; *Rx*, granulation tissue. In this are areas containing small spaces. These spaces, as seen in Fig. 266, are lined with giant-cells. The cells in this layer contain blood-pigment. The inner surface (*F*) consists of coarse and fine threads of fibrin.

and that the abdomen had increased in size. She had never noticed a tumor projecting outward beyond the level of the umbilicus.

At operation, at the umbilicus was a tumor 5 cm. in diameter, the skin over it being brownish in color. It was tense and elastic, showed no marked fluctuation, and was slightly compressible. The abdominal enlargement was due to a multilocular ovarian cyst the size of a man's head, with torsion of the pedicle to the extent of 180 degrees; the wall of the cyst was partially necrotic.

\* Bondi, J.: Zur Kasuistik der Nabeleysten. Monatschr. f. Geb. u. Gyn., 1905, xxi, 729.

In the hardened specimen the umbilical cyst was 2.5 cm. in diameter. It lay over an outward prolongation of the abdominal cavity, much as a cap would fit (Fig. 264). The walls of the cyst had two layers, the outer consisting of whitish tissue 2 mm. thick. It was adherent to the skin and to the peritoneum, and the inner zone consisted of a broad, homogeneous, gray-brown tissue. The cyst contents were spongy, yellowish brown, and soft. Its length in the hardened specimen was 2.5 cm., and its greatest thickness, 1.5 cm. The outer wall of the cyst consisted of fibrous tissue, which gradually passed over into the inner, homogeneous lining, consisting of young fibrous tissue. This gradually merged into the granulation tissue which lined the cavity. The granulation tissue here and there contained blood-pigment. Here and there near the inner surface were numerous spaces, often occurring in groups. These were regularly lined with giant-cells (Figs. 265 and 266). In these spaces were crystals showing that the spaces were not artefacts. Bondi

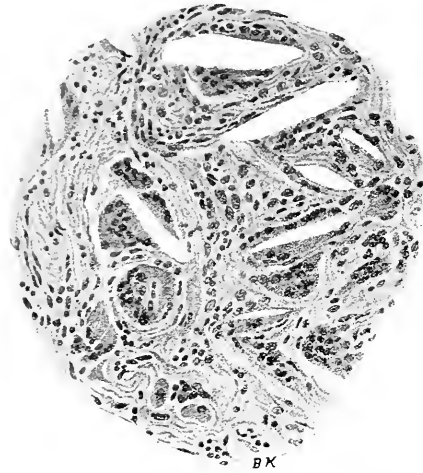


FIG. 266.—GIANT-CELLS IN THE WALL OF AN UMBILICAL CYST. (After Bondi.)

Scattered throughout the inner wall of the cyst (Fig. 265) were aggregations of small, slit-like spaces. Some of these are lined with one layer of epithelium, others with giant-cells. The nuclei of the giant-cells are uniform and fairly evenly distributed throughout the protoplasm.

says that it was not a dermoid, but a peritoneal cyst, into which a hemorrhage had occurred.

It is possible that these giant-cells were foreign-body giant-cells. As already pointed out, they bear a marked resemblance to those noted in the malignant cyst of the urachus I have just recorded so fully. (See Figs. 258, 259, and 260.)

#### LITERATURE CONSULTED ON MALIGNANT GROWTHS OF THE URACHUS AND URACHAL REGION.

- Aveling: *Brit. Gyn. Jour.*, 1886-87, ii, 56, 187.  
 Bondi, J.: *Zur Kasuistik der Nabelcysten.* *Monatsschr. f. Geb. u. Gyn.*, 1905, xxi, 729.  
 Doran, A.: *Stanley's Case of Patent Urachus with Observations on Urachal Cysts.* *St. Bartholomew's Hospital Reports*, 1898, xxxiv, 33.  
 Doran, A. H. G.: *Urachal Cyst Simulating Appendicular Abscess; Arrested Development of Genital Tract; with Notes on Recently Reported Cases of Urachal Cysts.* *The Lancet*, 1909, i, 1304.  
 Fischer, H.: *Die Eiterungen im subumbilicalen Raume.* *Volkman's Sammlung klin. Vorträge*, N. F., No. 89 (*Chir.* No. 24), Leipzig, 1894, 519.  
 Frank, T.: *Zur Casuistik der Urachstumoren.* *Inaug. Diss.*, Würzburg, 1893.  
 Graf, F.: *Urachusfisteln und ihre Behandlung.* *Inaug. Diss.*, Berlin, 1896.  
 Hoffmann, C. E. E.: *Zur pathologisch-anatomischen Veränderung des Harnstrangs.* *Arch. der Heilkunde*, 1870, xi, 373.  
 Koslowski, B. S.: *Ein Fall von wahrem Nabeladenom.* *Deutsche Zeitschr. f. Chir.*, 1903, lxi, 469.  
 Rotter: *Blasencarcinom kombinirt mit Urachuszyste.* *Centralbl. f. Chir.*, 1897, xxiv, 604.  
 Wolff, C. C.: *Beitrag zur Lehre von den Urachuszysten.* *Inaug. Diss.*, Marburg, 1873.

## CHAPTER XXXVIII.

### BLEEDING FROM THE URACHUS INTO THE BLADDER.

THE literature on this subject is a negligible quantity. W. Ramsay Smith\* reports a case which, although somewhat obscure, may be mentioned here.

The patient, a female infant, was born August 3d. The labor was short, and the child brought away with forceps. The cord appeared to be normal. On the second night, August 5th, a large quantity of bright-red blood was noticed on the infant's binder. It appeared on that night only, and the nurse noticed that it was coming not from the cord, but from the umbilicus at the side of the cord. Two days later (August 7th) the child had an attack of diarrhea, and there was a good deal of blood in the stools, and it was noticed that this blood was coming from the urethra. On August 8th the bleeding was very severe, there being over two teaspoonfuls at a time. The blood always appeared when the bowels moved, but it came from the urethra. The diarrhea ceased, and the bleeding stopped on August 9th. Smith thought that the bleeding took place from the hypogastries, and escaped to the bladder along the urachus. Ballantyne felt somewhat reluctant to accept this explanation, but said that, under the circumstances, it was difficult to suggest any that was more satisfactory.

A few years ago, while discussing diseases of the umbilical region with Dr. Edward Reynolds, of Boston, he mentioned the fact that on several occasions he had noted bleeding from the urachus into the bladder. Later I wrote asking him kindly to furnish me with the data he had bearing on the subject. His reply was as follows:

“With regard to my recent hematuric case, the patient was a physician about thirty-five years old, from whom I removed the appendix about two years ago. She came to me on the seventh of February, saying that, after very hard and long automobiling over rough country roads a few days before, she had been seized by a sudden urgent desire to urinate, and had passed a quantity of bloody urine. Since then urination had been normal, but the urine was slightly blood-stained. She informed me that she had noticed that the first part of the urine was clear and that the blood came with the last few drops. When I first looked into her bladder the small amount of urine was clear (she had just emptied it). I inspected the trigonum and fundus of a normal bladder carefully in the knee-chest position, and, on turning the point of the cystoscope forward, found that in the interval the urine had become distinctly pink. I then emptied the bladder thoroughly with the evacuator, and saw a small stream of blood flowing from the orifice of the urachus. The patient has written me since that the hematuria stopped within forty-eight hours after her visit to me, and that there was no recurrence. I told her that I thought there was no other treatment than the removal of the urachus; that I should not advise that unless the symptoms were persistent; that I should advise

\* Smith, W. Ramsay: *Obstet. Trans.*, Edinburgh, 1892-93, xviii, 53.

it if the hematuria were recurrent. I asked her to keep me informed of her progress, and I think that she will do so.

“This is not my first case of the kind. A good many years ago, when I was doing a large out-patient clinic and making a great many cystoscopic examinations, I saw a number of cases, I should guess from half a dozen to a dozen, in which minor vesical symptoms seemed to be associated with a reddened, eroded condition of the vesical mucous membrane immediately about a small orifice in the upper and anterior part of the bladder, which, after some study, I grew to consider as the orifice of a patent urachus, and which, on close inspection, I could recognize in a considerable proportion of bladders in which it was not making trouble. I believe that this slight anomaly is very common, and that it is a not unimportant lurking-place for bacteria in infected bladders. In at least two cases in these old days I saw bleeding from this orifice; I think in more than that number, but the conditions of the clinic made careful record keeping very difficult. I should say that the hematuria was transient but recurrent. I do not know the ultimate outcome. The patients in that clinic were all of a class which it is difficult to follow up afterward.”

Dr. Reynolds' observation clearly demonstrates that in some cases blood does escape from the persistent urachus into the bladder. His suggestion that the urachal opening is probably the lurking-place of bladder infections is fully borne out by the cystitis frequently noted where a partially patent urachus exists.

## CHAPTER XXXIX.

### TUBERCULOSIS OF THE PATENT URACHUS.

I HAVE been able to find only two cases of this character in the literature. The first case was recorded by Briddon and Eliot, the second by Eastman.

Dr. Thacher, who made the pathologic report on the extirpated urachus in Briddon and Eliot's case, after giving a very careful and guarded description, decided that the condition was probably tuberculous. Dr. Eastman sent us his specimen and we have been able to demonstrate tubercle bacilli in the urachus.

"**Tubercular Degeneration of the Patent Urachus in the Adult.**"—R. M., aged nineteen, Roumanian; married. Admitted July 17, 1899. No tubercular family or personal history. The patient has always been well until five weeks ago, when she began to have slight pain, with heat, redness, and swelling in the region of the umbilicus, the navel having previously been always normal in appearance. The symptoms increased for two weeks, at the end of which time there was a small red tumor, the size of a pea, in the region of the umbilicus. During this time the patient suffered intensely from severe, sharp pain, almost constantly present, in the hypogastric region, with well-marked vesical tenesmus, increased frequency of micturition (often voiding urine every hour), and occasionally a small amount of blood in the urine. At the end of the two weeks the swelling opened spontaneously, discharging some cloudy fluid with a uriferous and foul odor, the pain and swelling soon subsiding. About four days after the discharge of fluid at the umbilicus, she ceased to pass water normally, and since then she has had a constant discharge of cloudy fluid of a uriferous odor, at times slightly blood-stained, through the opening at the umbilicus. She has lost considerable flesh and strength during the period of five weeks.

"**Physical Examination.**—The patient is markedly anemic and is apathetic. The facies is flushed; the tongue is moist and not heavily coated. The superficial glands are not enlarged. In the heart there is a hemic murmur over the pulmonic area, systolic in time. Percussion of the lungs is normal, but the breathing is rather poor. The abdomen is soft, retracted, and no masses can be felt. At the inferior portion of the umbilicus is a small sinus with everted and ulcerated edges, which discharges a seropurulent fluid of uriferous odor. A probe introduced into the sinus goes downward and extends evidently as far as the bladder. The bladder does not percuss high, but there is some tenderness on pressure over the suprapubic region. Urine analysis at the time of admission showed very turbid and cloudy urine, with specific gravity of 1014, 15 per cent of sediment, reaction strongly alkaline, and odor foul and ammoniacal. There was 10 per cent of albumin, no blood, a large amount of mucus, much pus, and many vesical cells, with many crystals of triple phosphate. No casts were found. She was placed upon bladder irrigations twice daily, with warm 0.5 per cent. boric-acid solution, and salol (gr. v)

\* Briddon, C. K., and Eliot, E.: *Med. and Surg. Reports, Presbyterian Hospital, New York*, January, 1900, iv, 30.

three times a day. There was no improvement under this treatment, either in the character of the urine or in the patient's general condition, except that she had slightly less pain. At the end of a week the bladder irrigation was changed to carbolic acid, in strength of 1:120. This also seemed to have no effect upon the urine, frequent examinations up to the time of operation giving about the same result. As at the first analysis, the specific gravity never rose above 1014; the urine always remained alkaline and was full of pus and mucus. The temperature course was irregular, varying between 99.5° F. and 102° F., and did not seem to be influenced in any way by the bladder washing. During a period of several days of fairly constant low temperature the patient gave a moderately characteristic tuberculin reaction. The average daily amount of urine voided by the urachus varied from 15 to 20 ounces. At intervals of several days she voided a few drams or an ounce of urine *per urethram*.

"Owing to the obstinate, unyielding cystitis, it was thought advisable to do a suprapubic cystotomy for purposes of drainage.

"Operation (August 25th).—Dr. Eliot. Nitrous oxid and ether; asepsis; dorsal position. A catheter was introduced through the urethra into the bladder and urine was withdrawn. Four ounces of warm 1 per cent boric-acid solution were then gently thrown into the bladder by a fountain syringe, six ounces of water, injected into a Barnes dilator, having been previously inserted into the rectum. A 2½-inch median incision was then made above the pubis and deepened down to the space of Retzius. The soft cellular tissue here being pushed aside and the bladder presenting, two silk sutures were passed in a longitudinal fashion through its wall, separated by a distance of one inch, these sutures being placed for purposes of traction. The bladder was then opened between the silk sutures, the boric-acid fluid pouring out into the wound. The incision in the bladder-wall being subsequently enlarged upward, disclosed the urachus opening into the fundus of the bladder. There were several small areas of ulceration on the posterior wall of the bladder, and parts of the ulcers, together with a portion of the urachus, were secured for microscopic examination. The ulcerated areas upon the bladder-wall were cauterized with a thermocautery. The lumen of the urachus was packed with a strip of iodoform gauze, the cavity of the bladder being drained through the suprapubic wound in the usual way by means of a tube.

"Report by J. S. Thacher, Pathologist.—A. Minute fragment of tissue from urachus. Microscopic examination shows a mass of smooth muscle and connective tissue. The muscle-cells vary somewhat in size and shape, and are irregular in arrangement.

"B. Minute fragments from base of bladder. The epithelium is partly destroyed, and the tissues are much inflamed. The inflammation appears to be of some standing.

"The bladder was drained very satisfactorily for ten days by the siphon drainage apparatus, the suprapubic wound remaining comparatively clean and dry. The patient's temperature was increased for six days following the operation. Recovery was uneventful. Bladder irrigation with carbolic acid, 1:40, was employed, when the drainage apparatus was dispensed with, the urine clearing up slightly and the pain becoming much less severe. She seemed to improve in general health to a moderate degree. Urine was not voided normally after the suprapubic operation had been performed.

"September 25th: Urine, for about one week, has had much less pus and mucus in it, and hypogastric pain has been much less severe. It was then decided to attempt an extirpation of the patent urachus, leaving the suprapubic wound unmolested.

"Operation (September 27th).—Dr. Briddon; nitrous oxid and ether; asepsis; dorsal position. A median incision was made from the umbilicus down to the suprapubic wound of the previous operation, exposing the linea alba, which was split up in the line of the incision, exposing granulation tissue forming the wall of the patent urachus. By blunt dissection this tissue was then dissected free from the underlying thickened peritoneum, during which process the urachus was opened longitudinally through a portion of its extent. The walls of the urachus were nearly a quarter of an inch thick, and their diameter was about half an inch. At its point of junction with the bladder it was cut transversely and removed, the general cavity of the peritoneum not being opened. A clean surface was thus left, whose floor was formed by the thickened peritoneum, and its sides by the divided portion of the linea alba. This tract was closed by eight interrupted chromic catgut sutures, passing from one side to the other through the skin and linea alba, thus approximating the raw edges of the tract. A sterile dressing was placed on the sutured wound, a rubber drainage-tube and iodoform gauze being left in the suprapubic wound.

"Report of J. S. Thacher, Pathologist.—Extirpation of patent urachus. Microscopic examination: Granulation tissue; spots of marked infiltration by leukocytes; several small necrotic spots; many giant-cells; some tissue resembling tubercle tissue—probably tubercular.

"Recovery from the operation was uneventful. The bladder was drained satisfactorily for ten days, the wound for urachus extirpation healing by primary union without complication. Her general health rapidly improved, and she had gradually less hypogastric pain and discomfort. For a few weeks the patient voided no urine normally, all being discharged through the suprapubic wound. Since then she has passed almost every day one or more ounces of urine *per urethram*, in gradually increasing quantity. Her general condition is very much improved, the suprapubic wound is steadily closing, and urinary analysis now gives but 3 per cent. of albumin, with much less pus and mucus.

"Repeated examination of urine failed to discover any tubercle bacilli, and careful physical examination by G. A. Tuttle failed to detect any evidence of pulmonary or other visceral tuberculosis.

"Examination conducted by Dr. Tuttle, in the pathologic laboratory, of the small ulcers which were excised from the wall of the bladder at the time of the first operation, failed to yield positive indications of tuberculosis; conclusive evidence at last was furnished by the examination by Dr. Thacher of the urachus itself, removed by Dr. Briddon at the time of the second operation. Inferences are always uncertain, and although the statement that the tubercular process originated in the patent remnant of the duct itself is not entirely justifiable, nevertheless, the fact remains that examination of its wall after removal showed much more abundant evidence of tuberculosis than did the portion of the bladder-wall removed earlier by suprapubic cystotomy."

In the case under discussion the removal of the urachus was accomplished without opening the general peritoneal cavity.

I was particularly anxious to see a section from this case, and accordingly wrote Dr. Thacher. In his reply, dated New York, April 8, 1914, he gave me the results of his examination, but said the original slide could not be located.

**Tuberculosis of the Urachus.\***—Dr. Eastman has just recorded a very interesting case of tuberculosis of the urachus in a girl aged nineteen.

“Family History.—Father died of cancer of the stomach at the age of fifty-one; one brother died during infancy of meningitis; history otherwise negative, particularly as relates to tuberculosis or neoplasms.

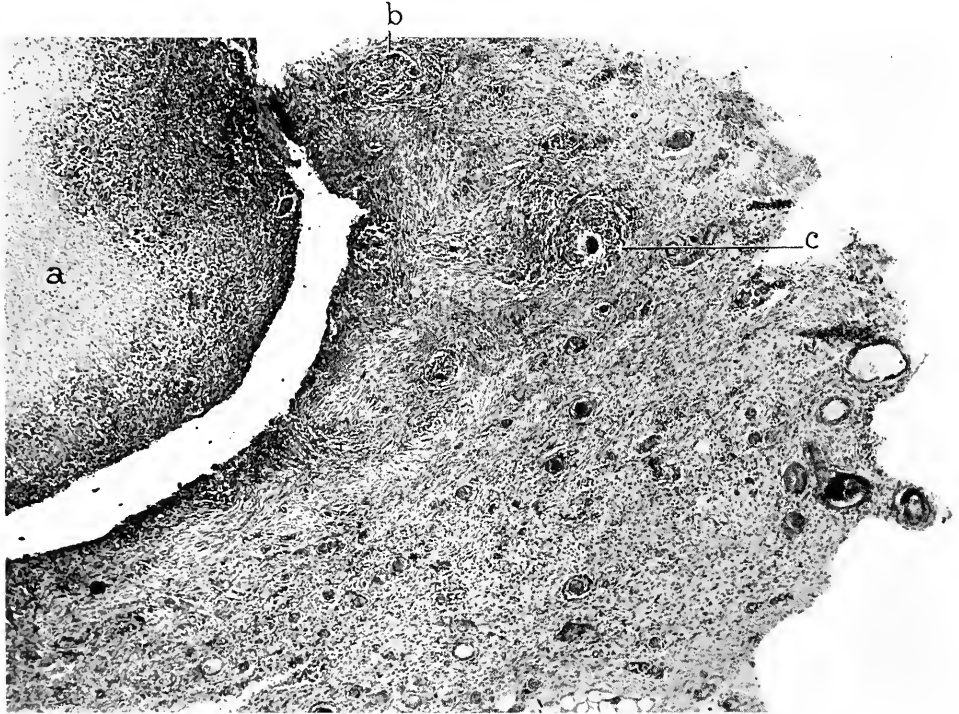


FIG. 267.—TUBERCULOSIS OF THE URACHUS.

This is a low-power photomicrograph from Dr. J. R. Eastman's case. At *a* is an area of caseation surrounded by tissue closely resembling that found in tuberculosis. The outer walls are composed of non-stripped muscle and fibrous tissue. Scattered throughout this tissue are localized foci more or less characteristic of those noted in tuberculosis. The areas *b* and *c* are very suggestive of tubercles.

The high-power picture of the area *b* is shown in Fig. 268; that of the area *c*, in Fig. 269.

“Personal History.—Typhoid at seventeen with good recovery; history otherwise negative; patient married two years and four months; one pregnancy, child living and well; at no time night-sweats or protracted cough; no characteristic temperature history; no other evidences of tuberculosis.

“Menstrual History.—Menstruation began at twelve; regular; duration five days and free; no change in type since marriage or labor.

“Urination.—No increase in frequency, no nocturnal urination. Three diurnal urinations; never any blood or burning or stinging.

“History of illness for which patient entered hospital.—This trouble began ten

\* Eastman, Joseph Rilus: Amer. Jour. of Obstetrics, 1915, lxxii, 640.



months before entrance. While working in the garden, pain was felt at a point in the mid-line of the abdomen between the symphysis pubis and the umbilicus. At this time patient noticed a lump at the point designated, the size of a small apple. There was not much actual pain nor soreness. The mass did not increase in size but the tenderness remained. This condition persisted for three months when a pin-point opening appeared in the mid-line of the anterior abdominal wall, half-way between the symphysis pubis and the umbilicus. This opening discharged a clear watery fluid for about a week. Then a serous crust closed the opening. The opening again discharged after about a week, continuing to do so for one week and again the crust was formed. This process of closing and opening continued for several months. The size of the tumor did not change. The tenderness still persisted. There had never been any disturbance of the bladder, intestines or uterus.

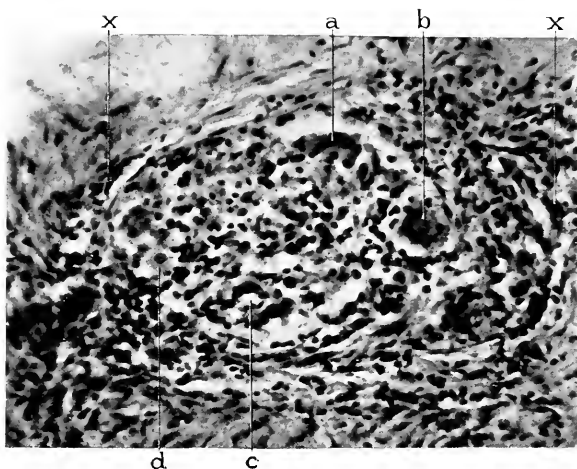


FIG. 268.—AN AREA SUGGESTING A TUBERCLE.

This picture is a high-power magnification of the area *b* in Fig. 267. Its confines are indicated by *x* and *x'*. Scattered throughout this area are spindle cells and round cells. At *a* and *b* are giant-cells. At *c* the cells are so arranged as to suggest a small gland. At *d* is a large cell bearing a strong resemblance to a squamous cell.

The discharge had always been free from odor. She is positive that the discharge never had a urinous odor.

“Status Præsens.—The patient’s general health was unimpaired. Urinalysis and physical examination of the chest and abdomen were negative. There were no evidences of pulmonary tuberculosis nor of tuberculosis elsewhere. Through the discharging sinus below the umbilicus a small sound could be passed downward behind the symphysis pubis.

“Operation.—The fistulous tract, upon being dissected free, was found to pass downward from the discharging orifice, coursing in front of the peritoneum, crossing the space of Retzius and terminating in a thin cord attached to the anterior bladder wall in the median line and near to the vesico-urethral junction. Upon being split open the definite tube-like structure was found to be thin-walled, showing no evidence of inflammation or other pathological condition except near the external discharging orifice, where an ulcerated mass about 2 cm. in width was situate upon the dorsal wall of the tube.

“Cystoscopic Examination.—Bladder distended with 8 ounces of water for

examination; vesical sphincter normal in outline; trigone normal; both ureteral openings and the mucosa surrounding them were normal as to contractility and rhythm. There were no ulcers, tubercles, or any other abnormalities upon the floor of the bladder. The vesical roof was examined carefully and this portion of the bladder was found to be absolutely devoid of any ulcer, tubercles, opening, or any other abnormality of the vesical mucous membrane; and there was not the slightest hint of any communication with the patent urachus.

“Chemical and Microscopic Urinalysis.—After operation as before the urine was normal.

“Clinical Course since Operation.—Wound closed slowly; there have been no

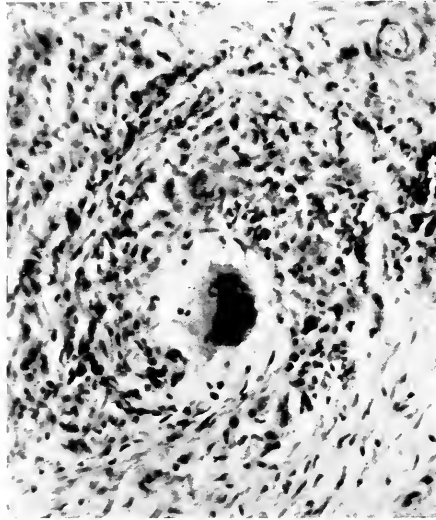


FIG. 269.—A TUBERCLE FROM DR. EASTMAN'S CASE OF TUBERCULOSIS OF THE URACHUS.

This is a high-power picture made by Mr. H. Schapiro from Fig. 267 at *c*.

The tubercle is oval in form and is fairly well differentiated from the surrounding stroma. The cells of the tubercle are spindle-shaped, oval, round, or irregular. In the lower part of the tubercle is a large giant cell containing a large number of nuclei arranged chiefly in its center. The grouping of the nuclei in this giant cell resembles to some extent that usually found in foreign-body giant cells, but the picture as a whole is strongly suggestive of tuberculosis.

symptoms of any kind relating to the genitourinary organs; there is no evidence of return of the disease.”

I wrote Dr. Eastman asking if he could send me sections of the urachus. This he promptly did. An examination of them shows the following:

The central portion of the specimen consists of granular tissue containing a few cells. It looks very much like caseous tissue (Fig. 267a). External to this is a tissue made up of young connective-tissue cells and fairly large round cells with small round nuclei, and beneath this a zone containing a few giant cells. The outer wall apparently consists of non-stripped muscle and connective tissue infiltrated with small round cells. In this are round or oval areas containing aggregations of epithelioid cells with giant cells scattered here and there throughout them (Figs. 268 and 269). External to this zone is the surrounding adipose tissue. The entire picture strongly indicates tuberculosis of the urachus.

Dr. Benjamin O. McCleary and Dr. George L. Stickney have each independently demonstrated tubercle bacilli in the sections; consequently this is a definite case of tuberculosis of the urachus.

## INDEX OF NAMES

NOTE.—As regards the majority of the authors quoted I have been able to consult their original publications, but in the few cases in which it was found impossible to locate the original article, I have given the name as it appeared in the secondary source from which it was secured. Much care has been exercised to have the names spelled correctly, and the fact that I have at times found discrepancies in the spelling of the same name in the different languages is responsible for some of the errors which may still be found.

- ADAIR, 70, 101, 104  
 Adams, 171  
 Adamson, 286  
 Ahlfeld, 1, 33, 101, 221, 463, 464, 480  
 Ajello, 403, 404, 411  
 Albinus, 502, 516, 519  
 Albrecht, 162  
 Aldis, 298, 300, 306  
 Allé (in Brünn), 341  
 Alric, 487, 488, 495, 513  
 Alsberg, 191, 212  
 Alsberg and Leisrink, 189, 191, 201, 213  
 Ammon, von, 482, 483  
 Anderson, 220, 221  
 Andrews, 528  
 Annandale, 487, 495, 513  
 Anthelme, 610  
 Ardouin, 189, 192, 212  
 Arndt, 223, 227, 236  
 Arrou, 569, 570, 571, 577, 622, 627  
 Ashhurst, 496, 513  
 Aslanian, 428, 429, 430, 436  
 Atlee, 539, 547, 565  
 Attimont, 412, 415, 418, 422  
 Auger, 415, 422  
 Auvard, 214, 215, 216, 218, 220  
 Auxiron (d'), 613, 618  
 Aveling, 458, 635, 636, 646  
 Aveling and Bland-Sutton, 636, 637  
 Avicenna, 328
- BABES, 90  
 Baginsky, 90, 315, 317, 326  
 Baizeau, 298, 299, 301, 302, 306  
 Bajardi, 128  
 Baldwin, 547, 565, 569, 570, 571, 572, 577  
 Ball, 125, 142, 582, 585, 605  
 Ballantyne, 647  
 Balluff, 416, 422  
 Banti, 272  
 Bantigny, 437, 438, 447  
 Bantock, 548, 549, 565
- Bardeleben, 617, 618  
 Barker, 373, 393, 394, 395, 399, 425, 426, 428  
 Barlow, 295, 296  
 Barnhardt, 524  
 Barraud and Tillaux, 403, 410, 412  
 Barres, 338, 340  
 Barth, 118, 120, 212, 222, 227, 228, 229, 236  
 Bartholin, 620, 623  
 Barton, 358, 366  
 Basevi, 222, 226, 229, 230, 236  
 Battle, 189, 192, 212  
 Baumann, 335  
 Baumgarten, 86  
 Beaucaire, 500  
 Beck, 160, 172  
 Bédel, 328, 331, 336  
 Bednar, 70, 74, 91, 92, 104  
 Behrend, 108  
 Beilman, 328, 329  
 Belfrage, 551  
 Bennett, 358, 366  
 Beonhardy, 303  
 Bérard, 297, 298, 337, 343, 344, 345, 458, 513  
 Bergeat, 446  
 Bergeron, 70, 80, 81, 104  
 Bergmann, von, 416, 587  
 Berner, 331, 336  
 Bernutz, 294  
 Bernutz and Guerin, 289  
 Bert and Viannay, 35, 36, 68  
 Bertherand, 315, 316, 317, 326  
 Bertherand and Merklen, 278, 279, 280, 281, 282, 284  
 Bertrand, 466  
 Besson, 400, 403, 404, 411, 422, 425  
 Betti, 610  
 Beudt, 502, 516, 519  
 Bianchi, 328  
 Bidone, 125, 142  
 Bienaisius, 159  
 Biermer and Fischer, 265  
 Billard, 70, 80

- Billroth, 191, 193, 212, 363  
 Binnie, 496, 513, 521, 522, 608, 618  
 Birch-Hirschfeld, 89, 92  
 Birdsall, 559  
 Bischoff, 181  
 Bize, 162, 163, 172  
 Blanc, 125, 126, 132, 142, 160, 172, 292, 457  
 Blanc and Weil, 125, 142  
 Blanchet, 331  
 Blandin, 47  
 Bland-Sutton, 524, 525, 564, 636  
 Bland-Sutton and Aveling, 636, 637  
 Blasius, 519  
 Blin, 222, 223, 226, 229, 236  
 Bloodgood (Joseph C.), 60, 164, 165  
 Blum, 247, 260, 278, 283, 284, 288, 350, 356,  
     363, 365, 456, 458  
 Boehmer, 516, 519  
 Boettiger, 67  
 Boire, 328  
 Boissard, 106  
 Boisse, Codet de, 352, 356, 417, 422  
 Bond and Pratt, 539, 560, 565  
 Bondi, 241, 278, 282, 284, 369, 641, 642, 645,  
     646  
 Bonvoisin, 403, 405, 411  
 Booker, 122, 126, 142  
 Borggreve, 328, 332, 336  
 Bottini, 328, 332, 336  
 Bottomley, 390, 391  
 Bouchet, 77  
 Bouffleur, 250, 260, 285  
 Bourgeois, 580, 581, 586, 605  
 Bourne, 564  
 Bowman and Paget, 506, 507, 513, 514, 625  
 Boyer, 353, 574, 620, 621  
 Bramann, 338, 339, 342, 343, 578, 581, 582,  
     587, 593, 605, 626, 627  
 Brehm, 466, 468  
 Breschet, 283  
 Bricheteau, 298, 300, 306  
 Briddon and Eliot, 649  
 Brindeau, 218, 220  
 Broadbent, 191, 193, 212  
 Broca, 123, 126, 142, 193, 194, 212  
 Brödel, 37, 45, 61, 63, 477. See Preface.  
 Broussolle, 360, 362, 366, 420  
 Bruce, 200  
 Brun, 120, 126, 142, 188, 194, 212, 465, 479,  
     480  
 Brünn (Allé in), 341  
 Bruns, 170, 367  
 Bryant, 358, 366, 456, 549, 565, 572, 577  
 Bryant and Hine, 297  
 Buchwald, 174, 180, 186  
 Buckmaster, 68, 100, 104  
 Budin, 282  
 Budin and Tarnier, 70, 99, 105  
 Buettner, 337  
 Bufalini, 250, 260  
 Buhl, 90, 91  
 Bunch, 286  
 Bureau, 194, 212, 235, 236, 237  
 Burkhart, 400, 403, 411, 412, 416, 422, 428,  
     430, 436  
 Burnam and Kelly, 486  
 Busch, 356  
 CABELL, 490, 496, 513  
 Cabrol, 487, 488, 495, 500  
 Cadell, 612, 613, 618  
 Cahn, 418  
 Cameron, 298, 299, 303, 306  
 Camuet, 413, 417, 422  
 Cantrell, 276  
 Capallaria, 328  
 Capette and Gauckler, 123, 126, 142  
 Cappola, 328  
 Carpenter and Makins, 136, 143  
 Carroll, 541, 549, 565  
 Caruso, 479, 480, 528, 531  
 Carwardine, 176, 177, 186  
 Casali, 332, 336  
 Castel, 306  
 Cat, 309, 314  
 Catoir, 458  
 Catteau, 34, 35, 36, 38, 68, 315, 318, 326, 437,  
     466, 468, 470, 480  
 Cazaban, 298, 299, 303, 306  
 Cazin, 1, 33, 118, 120, 160, 162, 163, 172, 174,  
     186, 200  
 Chandelix, 156, 158  
 Chapin, 617, 618  
 Charles, 487, 496, 513  
 Charon and Gevaert, 236  
 Charpy, 46, 53, 263  
 Chartier, 110, 114  
 Chassaignac, 353, 354, 356, 357  
 Cheaureau, 523  
 Cheyne, 220, 221  
 Chiarabba, 278, 285  
 Chiari, 226, 229  
 Chislett, 258, 260  
 Chopart, 597, 610  
 Christian, 392  
 Chuquet, 400, 411, 425, 426, 428, 437, 438,  
     447  
 Civiale, 516, 522, 608, 613, 614, 618, 620, 627  
 Clado, 369, 390  
 Cladus, 328, 350  
 Clairmont, 315, 318, 326  
 Clark (A.), 122, 137  
 Clark (J. G.), 346, 349  
 Clement, 338, 343

- Clendening, 521  
 Cockle, 340  
 Codet de Boisse, 352, 356, 417, 422  
 Coenen, 248, 250, 251, 252, 260, 360, 366  
 Cohn, 70, 93, 94, 104  
 Colman, 126, 142  
 Colmers, 174, 178, 180, 186, 187, 238, 239, 240, 241  
 Colombe, 112, 113, 114, 353, 354, 355, 356  
 Columbus, 620, 623  
 Coniac, 63, 69, 400, 412, 428, 437  
 Cornil, 364, 405, 410  
 Cornil and Ranvier, 422, 425  
 Cotte and Delore, 549, 565  
 Count, 539, 557, 565  
 Courvoisier, 337, 343  
 Covillard, 614  
 Coÿne, 479, 480  
 Craig, 106, 108, 110, 114  
 Credé, 464  
 Creulin, 328  
 Crooke, 315, 319, 326  
 Cruveilhier, 55, 620  
 Cullen, 1, 37, 56, 68, 276, 287, 349, 365, 366, 372, 382, 399, 400, 414, 423, 433, 436, 437, 440, 442, 447, 469, 470, 475, 637  
 Cullen and Goldsborough, 347, 349  
 Cullen and Welch, 541, 542, 543, 544  
 Cullen and Wilkins, 346, 349  
 Cumston, 70, 104, 106, 114  
 Cunéo and Marcille, 63, 64, 65, 66, 68  
 Curran, 288  
 Cuvier, 521
- DAMALIX, 358, 366  
 Damaschino, 420, 426, 446  
 Dandy, 2  
 Dannenberg, 403, 405, 411, 458  
 D'Arcy Power, 459, 460, 480  
 Darier and Wickham, 269  
 d'Auxiron, 613, 618  
 Davaine, 328, 329, 330, 336, 345  
 de Boisse, 352, 356, 417, 422  
 De Forest Willard, 512, 514, 528  
 Déjerine, 67  
 Déjerine and Sollier, 403, 405, 411, 412  
 Delagènière, 488, 496, 497, 513, 574  
 de Lignerolles, 297, 298, 337, 338, 339, 340, 341, 342, 343, 344, 345  
 Delore and Cotte, 549, 565  
 Demarquay, 361, 362, 366, 403, 405, 406, 411, 444, 448, 458  
 Démélin, 106  
 Demons and Verdelet, 428, 430, 436  
 de Mussy, 428, 431, 436  
 Denaire, 332
- Denucé, 145, 146, 147, 148, 149, 150, 155, 162, 172  
 Derville, 252, 260  
 Deschin, 118, 120, 189, 195, 200, 212  
 Després, 403, 406, 411  
 Dévé, 132, 162, 172, 233, 244, 368  
 de Villiers, 116, 117  
 Dickinson, 68, 70, 97, 98, 100, 102, 104  
 Diemberbroeck, 350, 501  
 Diez, 328, 329, 332, 336  
 Dittrich, 174, 187  
 Diwawin, 127, 142  
 Döderlein, 389, 403, 406, 407, 411  
 Donatus, 620, 623  
 Doran, 541, 549, 550, 551, 552, 553, 565, 570, 572, 634, 635, 636, 637, 646  
 Dorland, 104  
 Dössekker, 539, 553, 565  
 Douglas, 539, 546, 553, 565, 592  
 Dow, 195, 196  
 Draudt, 490, 497, 498, 499, 513  
 Dregogirone and Hamilton, 328  
 Dreschel, 144, 146, 153  
 Du Bois, 511  
 Dubois, 68, 74  
 Duboué, 346, 349  
 Ducellier, 405  
 Dugés, 363  
 du Laurent, 501  
 Duplay, 201, 254, 337, 343  
 Dupuytren, 120, 126, 188, 194, 283, 344, 345  
 Dupuytren and Roux, 499, 513  
 Durante and Porak, 70, 105  
 Dussaussy, 470  
 Dykes, 623, 627
- EASTMAN, 649, 652, 654  
 Ebner, 208  
 Ehrendorfer, 94  
 Ehrlich, 369, 370, 374, 382, 383, 384, 399  
 Eliot and Briddon, 649  
 Elliot, 165, 166, 172  
 Epstein, 89, 92, 94, 107  
 Erdmann, 487, 499, 513, 528  
 Eröss, 94  
 Eustache, 613, 615  
 Evans, 68, 69  
 Eve, 635  
 Eves, 188, 195, 212  
 Ewald, 171
- FABRÈGE, 120, 127, 142, 260  
 Fagge, 160  
 Faivre, 625  
 Falaschi, 610

- Falk, 244, 245, 246  
 Falkner, 125  
 Fay, 547  
 Fay, Smouse and Priestley, 287  
 Feli-Plater, 328  
 Fenby, 414  
 Féré, 253, 260  
 Féréol, 289, 291, 296  
 Ferguson, 555, 565  
 Fernel, 501, 607, 609  
 Feulard, 314, 326, 400, 411, 417, 422  
 Fiaschi, 114, 283, 284, 285  
 Finch, 523, 525  
 Findlay, 121, 137  
 Finger, 332  
 Finney (John M. T.), 113  
 Fischel, 107  
 Fischer, 259, 260, 263, 264, 265, 266, 267,  
     312, 314, 326, 345, 417, 422, 491, 570, 577,  
     628, 629, 646  
 Fischer and Biermer, 265  
 Fischer-Cöln, 356  
 Fitz, 118, 120, 159, 160, 161, 163, 171, 172,  
     174, 176, 179, 180, 186, 187, 189, 195, 197,  
     212, 242, 243, 244, 246, 352  
 Flagg, 68, 97, 99  
 Florentin, 116, 117, 118, 120, 156, 157, 158,  
     488, 500, 513, 608, 618  
 Foltz and Pétrequin, 350  
 Forestus, 328  
 Forgue, 521  
 Forgue and Riche, 116, 117, 403, 407, 411, 458  
 Forster, 444, 448  
 Förster, 160  
 Fort, 420  
 Foulerton, 247, 248, 249, 253, 260  
 Fournier, 283, 285  
 Fourquet, 614  
 Fowler, 99, 602  
 Fox and MacLeod, 142, 241, 268, 270, 271,  
     273, 401, 403, 409, 411  
 Frank, 634, 646  
 Freer, 1, 33, 500, 501, 513, 561, 578, 579, 582,  
     585, 587, 588, 605, 611, 618  
 Frémont and Lannelongue, 116, 117, 124, 135,  
     143, 188, 200, 213, 244, 366, 367, 369  
 French, 487, 489, 501, 513  
 Frincavello, 328  
 Fritze and Pfeffinger, 346  
 Froelich, 157, 197, 212, 500, 608  
 Fromantin, 313  
 Fronmüller, 313, 314  
 Froriep, 483  
 Fry (Henry), 110, 114  
 Fry (J. M.), 571, 572  
 Fulton, 260  
 Fürth, 88  
 GALLANT, 106, 114, 466, 478, 480  
 Gallet, 444, 445, 448  
 Gampert, 214, 215, 216, 220  
 Garcin, 108, 111, 114  
 Garnier, 457, 458  
 Garrigues, 588, 605  
 Gauckler and Capette, 123, 126, 142  
 Gauderon, 39, 45, 46, 51, 69, 290, 291, 296,  
     297, 298, 299, 302, 303, 304, 305, 306, 314,  
     466, 469, 470, 480  
 Gennaro, 595  
 Gerdès, 449  
 Gernet, 122, 123, 127, 128, 142  
 Gérota, 66  
 Gertler, 277, 278  
 Gesenius, 222, 226, 230, 236  
 Gevaert, 198, 212, 222, 231, 236  
 Gevaert and Charon, 236  
 Giani, 122, 128, 142  
 Giannettasio, 374, 387, 399  
 Gibb, 218, 219, 220, 226  
 Giessen, 328  
 Gilbert, 254  
 Giordano, 403, 407, 411  
 Girone, 332  
 Glos, 332  
 Goddard, 373, 390, 393, 399  
 Golding-Bird, 222, 231, 236  
 Goldsborough and Cullen, 347, 349  
 Goldschmidt, 614  
 Gonard, 253, 260  
 Gossehn, 294  
 Gould, 128, 142  
 Goupil, 487, 490, 501, 513  
 Graf, 491, 501, 513, 580, 588, 605, 630, 646  
 Grandidier, 106, 108  
 Grawitz, 312, 314  
 Green, 366, 373, 374, 375, 376, 378, 399  
 Greenhill, 350  
 Gremillon, 70, 104  
 Griffith, 496, 501, 513  
 Grinnell, 419  
 Gross, 423, 425  
 Gruet, 519, 521  
 Guattani, 344  
 Guelliot, 367, 369  
 Guelliot and Hue, 366  
 Gueneau de Mussy, 428, 431, 436  
 Guéniot, 499, 502, 513, 514, 519, 521  
 Guerin and Bernutz, 289  
 Gueterbock, 248, 254, 260  
 Guiselin, 352, 403, 407, 411  
 Guisy, 611, 612, 618  
 Guitéras, 325, 326  
 Gunthorpe and Parsons, 188, 122  
 Guobaux, 163  
 Gurlt, 523, 524, 525

- Gusserow, 93  
 Guthrie, 215, 217, 218, 220, 226  
 Guyon, 390, 454  
 Guyot, 469
- HABERSHON, 319**  
 Hagedorn, 620, 623  
 Haggard, 305, 306, 437, 442, 443, 448  
 Hahn, 254, 261  
 Haller, 502, 516, 519  
 Halsted (William S.), 542  
 Hamilton, 70, 80, 328, 330, 333, 336  
 Hamilton and Dregogirone, 328  
 Hannay, 402  
 Hansen, 189, 198, 204, 212  
 Hanuschke, 629  
 Haran, 503, 513  
 Harder, 620, 623  
 Hart, 428  
 Hartmann, 122, 125, 128, 142  
 Harttung, 364  
 Hartz, 113, 114, 278  
 Harvey, 516, 519  
 Hastings, 581, 582, 589, 605  
 Heaton, 198, 212  
 Hecking, 328, 333, 336  
 Heer, 329, 333  
 Heflin, 491, 492, 493, 494, 513  
 Heinrich, 314, 326, 577  
 Hektoen, 122, 123, 129, 130, 142  
 Heller, 171  
 Helmreich, 314  
 Helmuth, 500, 588  
 Helweg, 222, 223, 231, 232, 236  
 Helwig, 620, 623  
 Hendee, 176, 178, 187  
 Henke, 124, 130, 131, 142  
 Hennig, 174, 180, 186, 187, 259  
 Henoeh, 299, 305, 470  
 Hertz, 39, 69, 403, 407, 411  
 Herzenberg, 382, 399  
 Heslop, 563  
 Heuer, 541  
 Heurtaux, 262, 263, 264, 403, 408, 411  
 Heurtaux and Joüon, 263  
 Hickman, 198, 199, 212  
 Hicks, 355  
 Hilden, von, 360, 361  
 Hind, 489, 503, 513, 581, 592, 605  
 Hinds, 393  
 Hine and Bryant, 297  
 Hinsdale, 70, 104  
 Hippocrates, 70, 80  
 Hirst, 313  
 Hoffmann, 491, 518, 519, 522, 525, 621, 627,  
 628, 630, 631, 632, 646  
 Hollaendersky, 131, 142
- Holmes, 121, 131, 142, 189, 199, 212, 223, 232,  
 236  
 Holt, 116, 117, 124, 131, 132, 142  
 Homans, 195  
 Hope, 459  
 Horion, 616  
 Hörnig, 569, 573, 577  
 Hosick, 547  
 Hryntshak, 107  
 Hue, 122, 132, 133, 142, 233, 236, 244, 246,  
 368, 369, 487, 503, 513  
 Hue and Guelliot, 366  
 Hue and Jacquin, 403, 408, 411  
 Huggins, 166, 172, 488, 503, 513  
 Hunner, 371, 486  
 Hurdon (Elizabeth), 395  
 Hurdon (Elizabeth) and Kelly (H. A.), 160,  
 161, 162, 172, 297  
 Hutchinson, 417, 422  
 Hüter, 174, 187  
 Hutinel, 278, 281, 282, 285  
 Hüttenbrenner, 222, 224, 233, 236  
 Hutton, 556  
 Hyrtl, 47, 161
- ILL, 565, 592, 605**  
 Imbert, 504, 513  
 Ippolito, 403, 408, 412
- JABOULAY, 490, 506, 617**  
 Jacobi, 509  
 Jacoby, 189, 199, 212, 487, 504, 513, 611, 618  
 Jacquin and Hue, 403, 408, 411  
 Jahn, 487, 504, 505, 513  
 Jaksch, von, 146, 152  
 Jenkins, 106  
 Jobert, 230  
 Johnson, 121, 131  
 Johnston, 370  
 Johnstone, 564  
 Jones (E. G.), 370, 373, 395  
 Jones (H.), 164  
 Jordan, 167, 172  
 Jores, 50, 51, 403, 408, 412  
 Josenhans, 346, 349  
 Joüon, 263  
 Joüon and Heurtaux, 263
- KAREWSKI, 234**  
 Kaig, 272  
 Kaufmann, 449, 450, 451, 453, 458, 499  
 Keber, 96  
 Kehr, 189, 199, 212  
 Keibel, 24  
 Keith, 312

- Kelly, 210, 334  
 Kelly (Howard A.), 395, 431, 477, 484, 528, 531, 534  
 Kelly and Burnam, 486  
 Kelly and Hurdon, 160, 161, 162, 172, 297  
 Kennedy, 505, 513  
 Kern, 159, 173, 200, 212, 328, 336, 463, 480  
 Kidd and Patteson, 353, 356  
 King, 160, 161, 162, 163, 173, 188, 191, 212, 222, 223, 224, 226, 233, 236, 244, 245, 246  
 Kirmisson, 118, 120, 123, 124, 132, 133, 134, 143, 200, 212, 616, 618  
 Klebs and Schärer, 174  
 Klopp and Sängler, 174, 186  
 Knecht, 310, 311, 314  
 Koeberle, 356  
 Kolaczek, 122, 126, 133, 134, 143  
 Kölbing, 222, 223, 233, 236  
 Kommerell, 107, 108, 114  
 Körte, 200, 213  
 Koslowski, 410, 412, 633, 646  
 Köstlin, 625, 626, 627  
 Kraske, 200  
 Krause, 155  
 Krönlein, 553  
 Kulenkampff, 174, 180, 181, 186, 187  
 Kussmaul, 346, 422  
 Küster, 34, 69, 361, 363, 365, 366, 367, 369, 430, 445, 448  
 Küstner, 122, 132, 134, 136, 143  
 Küttner, 170, 171, 173, 250, 251  
  
 LAGE, 425, 426, 428  
 Lamb, 563  
 Lambert, 70, 95, 104  
 Lane, 303  
 Lannelongue, 505, 513  
 Lannelongue and Frémont, 116, 117, 124, 135, 143, 188, 200, 213, 244, 366, 367, 369  
 Largeau, 417, 422  
 Larrey, 586  
 Lasource (Lévêque), 618  
 Lassar, 283  
 Launois, 362  
 Laurent (du), 501  
 Laurentius, 607  
 Lavater, 159  
 Lawrence, 393, 460  
 Lawton, 352, 353, 354, 355, 356, 357  
 Lawton and Maunoir, 138  
 Lebert, 426  
 Le Blanc, 125, 126, 132, 142, 160, 172, 292, 457  
 Le Cat, 309, 314  
 Leclerc, 338, 342  
 Le Coniac, 63, 69, 400, 412, 428, 437  
 Le Count, 539, 557, 565  
 Ledderhose, 1, 3, 33, 116, 117, 190, 204, 213, 247, 254, 261, 299, 305, 306, 312, 314, 326, 336, 343, 352, 353, 356, 363, 366, 367, 369, 400, 412, 418, 422, 425, 466, 468, 470, 479, 480, 505, 513, 621, 627  
 Le Fort, 420  
 Legg, 573, 577  
 Legrand, 358, 366  
 Leguelinel de Lignerolles, 297, 298, 337, 338, 339, 340, 341, 342, 343, 344, 345  
 Leisrink and Alsberg, 189, 191, 201, 213  
 Le Roy, 138  
 Leroy des Barres, 338, 340  
 Leuckart, 328, 336  
 Levadoux, 39, 45, 46, 47, 48, 49, 50, 51, 52, 53, 54, 55, 60, 61, 62, 69, 365  
 Lévêque-Lasource, 608, 609  
 Lévié, 616, 618  
 Lewis, 403, 408, 412  
 Lexter, 145, 146, 147, 149, 150, 155, 491, 492, 497, 513, 574, 577, 580, 581, 582, 592, 605, 613, 614, 616, 617, 618  
 Leydhecker, 357, 454, 458  
 Lieberkühn, 565  
 Limange, 358  
 Lini, 333  
 Linthicum, 113  
 Lissner, 450  
 Lister, 96  
 Littré, 516, 519, 610, 613, 614, 618  
 Liveing, 431, 436  
 Löhlein, 174, 187  
 Lomer, 89  
 Longuet, 255  
 Longuet and Quénu, 63, 69, 400, 412, 437, 446, 448, 458  
 Lorain, 70, 80, 104  
 Lotzbeck, 366, 367, 479  
 Löwenstein, 124, 136, 160, 161, 173, 222, 223, 226, 234, 236  
 Löwy, 24, 33  
 Lucas-Championnière, 215  
 Ludwig, 188, 200  
 Lugeol, 490, 505, 513  
 Luschka, 498, 515, 516, 517, 518, 519, 522, 526, 531, 553, 621, 627  
 Lynker, 618, 619  
  
 MAAS, 137, 405  
 Macdonald, 539, 540, 558, 559, 565  
 Macewen, 409  
 MacLeod and Fox, 142, 241, 268, 270, 271, 273, 401, 403, 409, 411  
 MacMunn, 447  
 Macphail, 333, 336  
 MacSwiney, 210, 213, 330, 334, 336  
 Magnanini, 136, 143



- Mahomed, 244, 245, 246  
 Major, 160  
 Makins and Carpenter, 136, 143  
 Mall (Franklin P.), 7, 9, 12, 15, 33, 545  
 Mallet, 368  
 Mann, 637, 641  
 Marcellus, 623  
 Marchand, 151  
 Marcille and Cunéo, 63, 64, 65, 66, 68  
 Marjolin, 221  
 Maroni, 171  
 Marrotte, 294  
 Marshall, 201, 213, 593, 605  
 Marteau, 328, 334, 336  
 Martin, 311, 314, 528  
 Marx, 487, 499, 513  
 Matthias, 580, 582, 583, 593, 595, 605  
 Maunoir, 352, 353, 357  
 Maunoir and Lawton, 138  
 Mauriceau, 70, 80  
 Maurin, 292, 296  
 Maxwell, 550, 552  
 Mayer, 56  
 Maygrier, 70, 104  
 Maylard, 403, 409, 412  
 Mayo (W. J.), 475, 477, 528  
 McCleary (Benj. O.), 654  
 McGehee, 295  
 McGlannan, 474  
 McMurtry, 445, 448  
 Meckel, 159, 173, 242, 243, 463, 516, 519, 521, 525  
 Meredith, 139, 140  
 Mériel, 50, 521, 522  
 Merklen and Bertherand, 278, 279, 280, 281, 282, 284  
 Méry, 515, 522  
 Meyer, 15, 33, 70, 90, 105, 488, 506, 513  
 Meyer-Kempen, 505  
 Meynet, 70, 75, 76, 77, 78, 80, 105  
 Mikulicz, von, 504, 593, 594, 595  
 Millar, 116, 117  
 Millard, 470  
 Miller, 94  
 Miller (C.), 545  
 Miller (I.), 437, 439, 440  
 Milligan, 268, 273, 274, 275  
 Minelli, 145, 150, 155  
 Mintz, 374, 379, 380, 381, 382, 389, 399, 455  
 Mirallié, 418, 422  
 Mohler, 285  
 Monckton, 551  
 Monleng, 331  
 Monnier, 456  
 Monod, 1, 33, 418, 422, 490, 506, 513, 521, 522, 595, 605, 607, 609, 616, 617, 619, 623, 627  
 Montgomery, 68  
 Monti, 89  
 Moreau, 519  
 Morer, 521  
 Morestin, 366, 367, 368, 369, 527, 531  
 Morgagni, 159, 163, 466, 468  
 Morgan, 582, 595, 596, 605  
 Mori, 357, 366  
 Morian, 118, 120, 189, 191, 201, 202, 213  
 Morris (M.), 274, 275  
 Morris (R.), 276, 400, 412, 418, 419, 422, 445, 448  
 Morton, 136, 143  
 Mraček, 107  
 Müller, 91  
 Munro, 390, 391  
 Murchison, 312, 314, 337, 338, 339, 343  
 Mussy (de), 428, 431, 436  
  
 NADORY, 101, 105  
 Nagel, 259, 260  
 Nasse, 174, 187  
 Naundorf, 524  
 Neel, 537  
 Nélaton, 172, 445, 448, 574  
 Neurath, 202, 213  
 Neveu, 63, 69, 400, 412, 445, 448, 456, 458  
 Newman, 578, 581, 582, 596, 605  
 Nicaise, 67, 68, 69, 70, 105, 138, 191, 201, 213, 247, 254, 255, 261, 288, 289, 291, 292, 296, 297, 298, 306, 314, 315, 319, 326, 328, 336, 337, 338, 343, 344, 345, 352, 353, 356, 362, 365, 366, 453, 458, 461, 466, 468, 480, 519, 522, 577, 582, 597, 605, 625, 627  
 Nicolas, 220, 221, 310, 312, 313, 314  
 Nicolich, 328, 334, 336  
 Noble, 475  
 Noder, 208  
 Noël, 291  
 Noorden, von, 369, 370, 374, 382, 387, 388, 389, 399  
 Noreen, 515, 516  
 Nota, 465  
 Notta, 255  
 Nuck, 466  
  
 O'BRIEN, 455, 458, 523, 525  
 Olshausen, 457, 458  
 Ophüls, 118, 120, 223, 226, 227, 234, 237  
 Opitz, 528, 531  
 Orth, 219, 387  
 Osler (Sir William), 401, 412  
 Ossiander, 328, 335, 336  
 Owen, 314, 326

- PAGE, 569, 574, 577  
 Paget, 487, 507, 508  
 Paget and Bowman, 506, 507, 513, 514, 625  
 Paré, 70, 75, 80, 329, 350  
 Park, 189, 202, 213, 255, 261, 319, 326, 528,  
 549  
 Parker, 122, 136, 143, 400, 401, 403, 409, 412,  
 446, 448  
 Parsons and Gunthorpe, 188, 222  
 Pasteur, 96  
 Patel, 579, 582, 597, 605  
 Patry, 201, 202  
 Patteson and Kidd, 353, 356  
 Pauchet, 487, 508, 514  
 Paul, 328  
 Peake, 214, 217, 220, 226  
 Péan, 367  
 Pelletan, 626  
 Penny, 508, 514  
 Péraire, 360, 364, 365, 366  
 Pernice, 39, 116, 117, 118, 120, 143, 203, 213,  
 247, 248, 255, 256, 259, 261, 285, 352, 353,  
 356, 357, 359, 363, 364, 366, 369, 400, 402,  
 403, 409, 412, 419, 422, 425, 427, 428, 446,  
 448, 453, 456, 457, 458  
 Perrin, 466, 468, 480  
 Pestalozza, 244, 246  
 Petersen, 188, 205  
 Petit, 509, 514, 611, 619  
 Pétrequin and Foltz, 350  
 Peu, 519, 539  
 Peyer, 519, 607, 623  
 Pieffinger and Fritze, 346  
 Phillips, 620, 627  
 Phocas, 137, 143  
 Pic, 359, 366  
 Pierre, 509, 514  
 Pinch, 273, 275  
 Pineo-Hyannis, 466, 468  
 Pinkerton, 70, 105  
 Pistré, 615  
 Pitts, 277  
 Plagge, 425, 427, 428, 455, 458  
 Platerus, 591  
 Poirier, 55, 63, 65  
 Pokels, 521  
 Polaillon, 247, 256, 261, 359, 456  
 Pollak, 70, 74, 105  
 Poncet, 343  
 Porak, 70, 105  
 Porak and Durante, 70, 105  
 Portal, 516, 519, 600  
 Pouspin, 328  
 Poussin, 188, 194, 203, 213, 328, 330, 335, 336  
 Power, D'Arcy, 459, 460, 480  
 Pratt, 189, 191, 203, 213  
 Pratt and Bond, 539, 560, 565  
 Prestat, 190, 204, 213, 482  
 Preston, 509, 514  
 Priestley, Fay, and Smouse, 287  
 Pujol, 292  
 Putney, 196  
 QUÆT-FASLEM, 188, 189, 191, 204, 213  
 Quénu and Longuet, 63, 69, 400, 412, 437, 446,  
 448, 458  
 RACHFORD, 315, 319, 326  
 Raciborski, 468  
 Raesfeld, 174, 185  
 Railton, 205, 213  
 Ransohoff, 307, 308  
 Ranvier and Cornil, 422, 425  
 Raussin, 613, 614, 619  
 Recklinghausen, von, 539, 561, 566  
 Reed, 459, 460, 461, 480, 561, 566  
 Reichard, 109, 110, 115, 145, 146, 147, 150, 151,  
 155  
 Reid, 598, 605  
 Renard, 598, 605  
 Rendu, 297  
 Reynolds, 647, 648  
 Rhodius, 620, 623  
 Ribbert, 105  
 Richardson, 160, 161, 173  
 Riche and Forgue, 116, 117, 403, 407, 411,  
 458  
 Richelot, 247, 256, 261, 326  
 Richez, 46, 47, 48, 51, 52, 338, 339  
 Richter, 328, 331, 335, 336  
 Riefkohl, 161  
 Rille, 283, 285  
 Rimbach, 174, 176, 178, 187  
 Rintel, 315, 320, 326  
 Rippmann, 539, 561, 566  
 Ritter, 107  
 Rizzoli, 363  
 Robb, 572  
 Robert, 338, 341, 343  
 Robin, 48, 358, 521  
 Robinson, 598, 605  
 Roesler, 620  
 Roger, 444  
 Rokitansky, 160, 174, 621, 627  
 Rombeau, 321, 326  
 Ronis, 298  
 Roques, 247, 257, 261  
 Rose, 509, 514  
 Roser, 144, 145, 149, 151, 155, 239, 241, 582,  
 598, 599, 605  
 Rosthorn, von, 145, 146, 151, 152, 155  
 Roth, 118, 120, 174, 175, 176, 177, 178, 180,  
 181, 182, 183, 185, 186, 187, 189, 191, 250,  
 213

- Rotter, 631, 633, 646  
 Rouget, 257, 261  
 Routh, 548  
 Roux, 344, 345, 512  
 Roux and Dupuytren, 499, 513  
 Roy, 138  
 Ruge, 242, 246  
 Runge, 67, 69, 70, 85, 86, 87, 88, 89, 90, 91,  
   92, 95, 105, 107, 108, 109, 115, 227, 278, 282,  
   285, 461, 480  
 Runkel, 174, 187  
 Ruysch, 159
- SACHS, 51, 52  
 Sadler, 112, 115  
 Salge, 70, 105  
 Salvisberg, 523, 524, 525  
 Salzer, 191, 206, 207, 208, 213  
 Sanchez, 329, 335  
 Sanderson, 349, 462, 463, 480  
 Sandifort, 188, 200  
 Sänger and Klopp, 174, 186  
 Sappey, 50, 63, 358  
 Sauer, 208, 209, 213, 360, 366  
 Saundby, 563  
 Saunders, 624  
 Savory, 578, 581, 582, 599, 605  
 Scarpa, 460  
 Schaad, 185, 186, 187, 239, 539, 547, 562, 566  
 Schaffer, 208  
 Schapiro, 544  
 Schärer and Klebs, 174  
 Schauta, 645  
 Schenck, 591  
 Schlesinger, 420, 422, 423, 425  
 Schmid, 229  
 Schmitz, 315, 321, 327  
 Schnellbach, 581, 582, 600, 606  
 Scholz, 539, 562, 566  
 Schroeder, 160, 173, 188, 210, 213, 234, 237,  
   243, 456  
 Schrötter, 309, 314, 322, 324, 327, 335  
 Schulze, 188, 200  
 Scott, 323, 327  
 Segond, 361, 362, 365  
 Senn, 528  
 Sennertus, 591  
 Shattock, 247, 257, 261, 393, 553  
 Sheen, 123, 143, 168, 169, 170, 173, 246, 459,  
   480  
 Sheild, 275  
 Shepherd, 189, 210, 213  
 Sibert, 108, 111, 115  
 Sibold, 234, 237, 328, 331, 336  
 Simmons, 174, 333  
 Simon, 503, 509, 513, 514, 516, 522, 599, 606,  
   610, 613, 615, 619, 620, 627
- Simpson, 121, 137, 143  
 Singewald, 433  
 Siredey, 292  
 Sladen, 276  
 Smart, 567  
 Smit, 509, 514  
 Smith (F. B.), 339  
 Smith (F. R.), 56  
 Smith (J.), 363, 366  
 Smith (T.), 510, 514  
 Smith (T. B.), 461  
 Smith (W. A.), 528  
 Smith (W. R.), 647  
 Smouse, Fay, and Priestley, 287  
 Sollier and Déjerine, 403, 405, 411, 412  
 Soltmann, 96  
 Sottas, 291, 293  
 Sourdille, 359, 366, 456, 458  
 Spangenberg, 244, 246  
 Spiller, 66, 67  
 Spiller and Weisenburg, 67, 69  
 Spöring, 331  
 Stadfeldt, 510, 514  
 Stanley, 646  
 Starcke, 609, 619  
 Starr, 488, 510, 514  
 Stavely, 285  
 Steenken, 137, 143  
 Stevens, 488, 510, 514  
 Stewart, 164, 165, 462, 480  
 Stickney (George L.), 654  
 Stierlin, 210, 211, 213, 244, 487, 510, 511, 514  
 Stiles, 331, 336  
 Stites, 490, 511, 514  
 Stoltz, 68  
 Storer, 420, 422  
 Stori, 122, 137, 143, 403, 409, 412, 447, 448  
 Stowell, 603  
 Strada, 145, 152, 155  
 Stratz, 47  
 Strecker, 112, 115  
 Struthers, 160, 173  
 St. Sardi, 336  
 Stuart, 108, 112, 115  
 Suchanek, 498, 520, 621, 627  
 Swain, 524, 525
- TAIT, 531, 539, 540, 546, 547, 548, 555, 563,  
   564, 565, 566, 636  
 Tanchou, 401  
 Tannar, 347  
 Tansini, 411  
 Targett, 637  
 Tarnier and Budin, 70, 99, 105  
 Taylor, 303  
 Taylor (F. L.), 574  
 Taylor (J.), 108, 111, 112, 115

- Taylor (W. J.), 247, 257, 258, 261  
 Thacher, 649, 650, 651, 652  
 Thérémin, 223, 226, 235, 237  
 Thiersch, 153  
 Thompson, 344, 624  
 Tiedemann, 176, 177, 187, 188, 200  
 Tikhoff, 137, 143  
 Tillaux 405  
 Tillaux and Barraud, 403, 410, 412  
 Tilling, 188, 200  
 Tillmanns, 118, 120, 144, 145, 146, 149, 151, 152, 153, 154, 155, 163, 173, 234, 242, 246, 314, 316, 327, 331, 336, 361, 365, 366, 420, 422, 458, 519, 522  
 Timmerman, 582, 600, 606  
 Tisserand, 420, 422, 423, 425  
 Todd, 620  
 Tolet, 620  
 Traller, 328  
 Trélat, 310, 314  
 Tremontani, 247, 258, 261  
 Trendelenburg, 573, 600  
 Trépan, 307  
 Treves, 160, 173  
 Tripoulet, 298, 299, 304  
 Tricot, 571, 622  
 Trogneux, 521, 609, 619  
 Trouseau, 70, 74, 75, 77, 80, 105  
 Tscherning, 174, 187  
 Tuholske, 490, 511, 514  
 Turner (W.), 241, 268  
 Tuttle, 651
- UNDERWOOD, 70, 80  
 Unna, 272  
 Unterberger, 600, 601, 606
- VACHER, 340  
 Valette, 402, 413, 421, 422  
 Vallin, 315, 316, 323, 327  
 Vallisneri, 620  
 Vander Veer, 511, 514  
 Van Heukelom, 144, 145, 149, 152, 155  
 Van Hook, 569, 572, 573, 577  
 Van Horne, 466, 468  
 Vaughan, 1, 33, 501, 504, 513, 514, 521, 522, 578, 581, 582, 601, 602, 606  
 Vaussy, 290, 291, 293, 294, 296, 297, 306, 569, 570, 574, 577  
 Voïel, 518, 522, 524, 525, 526, 531, 621, 627  
 Velpeau, 511, 514, 521, 574  
 Verchère, 446, 447, 448  
 Verdelet and Demons, 428, 430, 436  
 Verdries, 516, 519  
 Verneuil, 256, 368  
 Vest, 439  
 Vetu, 306
- Viannay, 292  
 Viannay and Bert, 35, 36, 68  
 Vidal, 574  
 Vidal de Cassis, 51  
 Villar, 132, 138, 143, 247, 261, 278, 352, 357, 361, 362, 363, 365, 366, 368, 369, 390, 399, 400, 407, 412, 420, 422, 425, 426, 428, 454, 456, 458  
 Villiers (de), 116, 117  
 Violbing, 235, 237  
 Virchow, 121, 138, 143, 352, 356, 357, 449, 450, 451, 453, 458, 636  
 Vogler, 469  
 Voigt, 101  
 Volkmann, 248, 359, 402, 409, 419, 457, 577  
 Vosburgh, 622, 627
- WACHSMUTH, 107  
 Wagner, 403, 410, 412  
 Waller, 512, 514  
 Walshe, 401  
 Walter, 515, 516, 518, 519, 522  
 Walters, 247, 258, 261, 522  
 Walther, 122, 138, 143  
 Walton, 67  
 Walz, 478, 479, 480  
 Ward, 167, 173  
 Wassermann, 70, 105  
 Watson, 365  
 Weber, 107, 145, 146, 147, 154, 155, 356, 357, 363  
 Wehsarg, 454  
 Weigert, 154, 181  
 Weil and Blane, 125, 142  
 Weinlechner, 222, 225, 236, 237  
 Weisenburg and Spiller, 67, 69  
 Weiser, 528, 531, 539, 558, 560, 566, 569, 570, 575, 576, 577, 578, 582, 602, 603, 604, 606, 623, 627  
 Weiss, 107, 189, 191, 211, 213, 219, 220, 328, 329, 331, 332, 333, 335, 336, 350  
 Welch (William H.), 644  
 Welch (William H.) and Cullen (Thomas S.), 541, 542, 543, 544  
 Wells, 113, 636  
 Wernher, 211  
 West, 299, 305  
 Westphalen, 113  
 Wheaton, 155, 158, 232, 496  
 Wickham and Darier, 269  
 Widerhofer, 67, 86, 87, 88, 91, 92, 461  
 Wilkins, 116, 423  
 Wilkins and Cullen, 346, 349  
 Wilks, 167, 173, 211, 213  
 Willard, 512, 514, 528  
 Willey, W. T., 437, 438, 439  
 Williams, 104, 105, 247, 258, 261, 345

- Wilms, 445  
Wilson, 492  
Winckel, von, 449, 450, 452, 453, 458  
Winiwarter, 309, 310, 314  
Winterich, 335  
Witzel, 408  
Wolff, 512, 514, 539, 564, 566, 646  
Worster, 580, 582, 604, 606, 627  
Wrany, 365  
Wulckow, 412, 421, 422  
Wullstein, 369, 370, 374, 384, 385, 386, 387, 399
- Wutz, 498, 515, 519, 520, 521, 522, 526, 527,  
528, 530, 531, 539, 566, 576, 577, 621, 627  
Wyss, 180, 238, 239, 241, 527, 531
- YATES, 462, 463, 480, 512, 514  
Yot, 70, 84, 85, 105  
Young, 616
- ZIEHL, 314, 315, 324, 327  
Zumwinkel, 118, 120, 238, 240, 241



## INDEX

- ABDOMEN**, condition of, in abscess of abdominal wall due to infection of urachal remains or urachal cysts, 569  
 intestinal cysts lying relatively free in, 176  
 omphalomesenteric vessel lying free in, 244  
**Abdominal cavity**, free bile in, localized jaundice of umbilicus in presence of, 307  
 cyst originating from remnant of omphalomesenteric duct, 185  
 fluid, escape of, from umbilicus, 287  
 tumor attached to inner surface of umbilicus, 370  
   extraperitoneal, 635  
 wall, abscesses of, due to infection of urachal remains or urachal cysts, 567. See also *Abscess of abdominal wall*.  
   cysts in, due to remnants of omphalomesenteric duct, 238  
   defects of, clinical examples, 56  
   hematoma of, near umbilicus, 113  
   herniæ through weak spots in, 56, 60, 478  
   in new-born, epidemic of erysipelas of, 74  
   inflammatory changes in, umbilical concretions associated with, 247. See also *Umbilical concretions*.  
   layers of, in region of umbilicus, 34  
**Abscess breaking through into subumbilical space**, 265  
   fistulous, of umbilicus, 252  
   in subumbilical space, 262  
     differential diagnosis, 265  
     treatment, 267  
   of abdominal wall due to infection of urachal remains or urachal cysts, 567  
     abscess sac in, 570  
     cases illustrating, 571  
     clinical course, 569  
     symptoms, 569  
     treatment, 570  
   of broad ligament opening at umbilicus, 289  
     cases illustrating, 291  
     treatment, 291  
   of liver opening at umbilicus, 297  
     into subumbilical space, 265  
   of umbilical vein in an adult, 295  
   of vermiform appendix opening into subumbilical space, 266  
     opening of, at umbilicus, 296  
   Abscess of vermiform appendix, urachal cyst and, differentiation, 541, 550  
     periprostatic, opening at umbilicus, 288  
     sac in abscess of abdominal wall due to infection of urachal remains or urachal cysts, 570  
     subumbilical, tuberculous, 256  
     thoracic, opening at umbilicus, 288  
   Absence of umbilicus, 67  
     of urethra, escape of urine from umbilicus and, 610  
   Accessory pancreas situated at tip of Meckel's diverticulum, 162  
   Actinomycosis in subumbilical space, 266  
   Adair on bacteriologic study of umbilical stump, 101  
   Adenocarcinoma of umbilicus, primary, 402  
     age incidence, 403  
     report of cases, 404  
     sex incidence, 404  
     treatment of, 404  
   Adenoma of umbilicus, 124, 125  
   Adenomyoma of umbilicus, 373  
     historic sketch, 373  
     personal observation, 395  
     report of cases, 375  
   Adipose hernia of umbilicus, 365  
     tissue in umbilical region, disposition of, 54, 55  
   Allantois, embryology of, 1, 16, 21  
     patency of, 16  
   Amnion, embryology of, 1, 7  
     umbilicus, 8, 67  
   Amniotic hernia, 461  
   Amputation of umbilical cord, Buckmaster's method, 100  
     Dickinson's method, 98  
     Nadory's method, 101  
   Angioma of umbilicus, 352  
   Animals, Meckel's diverticulum in, 163  
     remnants of urachus in, 523  
     umbilicus in, anatomy of, 61  
     urachal fistula in, 523  
   Anomphalosis, 100  
   Anus or rectum, defective development of, patent omphalomesenteric duct associated with, 220  
     preternatural, found in portion of ileum protruded at umbilicus, 217

- Aponeurosis of umbilical ring, lymphatics of, 66
- Appendix, vermiform, abscess of, opening into subumbilical space, 266  
 opening of, at umbilicus, 296  
 urachal cyst and, differentiation, 541, 550, 583
- Arcola, umbilical, 68
- Arteries, omphalomesenteric, embryology of, 32  
 umbilical, embryology of, 26
- Arteritis, umbilical, etiology of, 91  
 in new-born, 89  
 complications of, 90  
 erysipelas of umbilicus complicating, 90, 93  
 pathogenesis of, 91  
 prognosis of, 91  
 prophylaxis of, 92  
 symptoms of, 91
- Artery, omphalomesenteric, persistence of, in bases of umbilical polyps, 244
- Ascites, cyst of urachus and, differentiation, 541  
 from a tumor depending from the navel externally, 370
- Atheromatous cysts of umbilicus, 366  
 cases illustrating, 367
- Atrophic tubercloid of umbilicus, 286
- BACTERIOLOGIC study of umbilical stump, 101
- Bile, free, in abdominal cavity, localized jaundice of umbilicus in presence of, 307
- Biliary fistula at umbilicus, 423  
 with escape of gall-stones, cases illustrating, 339
- Bladder, bleeding from urachus into, 647  
 calculus of, obstructing urethra, and associated with escape of urine from umbilicus, 613  
 cases illustrating, 613  
 removal through umbilical opening, 625  
 cancer of, 631  
 cyst of urachus communicating with, 578, 582  
 exstrophy of, 482  
 case illustrating, 484  
 growth in, umbilical urinary fistula associated with, 612  
 neuroma of, urachal cyst and, differentiation, 541  
 symptoms in abscess of abdominal wall due to infection of urachal remains or urachal cysts, 569  
 in urachal cavities communicating with bladder or umbilicus or both, 579  
 urachal cavities communicating with, 578.  
*See also Urachal cavities.*
- Bladder-wall, thickened, cyst of urachus and, differentiation, 541
- Bleeding from urachus into bladder, 647
- Blennorrhoea of umbilicus in new-born, 86
- Body-stalk, embryology of, 1, 15
- Brain, autopsy findings, in umbilical infections in new-born, 73
- Breasts, umbilicus, and other parts of body, apparent escape of urine from, 618
- Broad-ligament abscess opening at umbilicus, 289  
 cases illustrating, 291, 293  
 treatment, 291
- Buckmaster's treatment of umbilical cord, 100
- Burns, fecal fistula at umbilicus due to, 313
- CALCULUS, fecal, discharged at umbilicus, 198  
 in umbilical region, cases illustrating, 625  
 umbilical, 257. *See also Umbilical concretions.*  
 urachal, 482  
 associated with urachal remains, 620, 621  
 urinary, associated with urachal remains, 620, 622  
 vesical, obstructing urethra and associated with escape of urine from umbilicus, 613  
 cases illustrating, 613  
 removal of, through umbilical opening, 625
- Cancer. *See Carcinoma.*
- Canquoin's paste in epidemic of erysipelas and gangrene of umbilicus in new-born, 75
- Carcinoma of gall-bladder, carcinoma of umbilicus secondary to, 422  
 treatment, 425  
 of intestine, carcinoma of umbilicus secondary to, 425  
 cases illustrating, 426  
 of ovary, carcinoma of umbilicus secondary to, 428  
 cases illustrating, 429  
 of stomach, carcinoma of umbilicus secondary to, 412  
 age incidence, 412  
 cases illustrating, 415  
 gastric symptoms, 413  
 prognosis, 415  
 sex incidence, 412  
 trauma incidence, 412  
 treatment, 414  
 umbilical fistula due to, case illustrating, 418
- of umbilicus, 400  
 classification, 401  
 primary squamous-cell, 402  
 retroperitoneal carcinoma associated with, 447



- Carcinoma of umbilicus, secondary, cases in which source of primary growth was not determined, 437
- of urachus, 628
- age incidence, 628
- developing years after closure of congenital patent urachus, 629
- sex incidence, 628
- of uterus, carcinoma of umbilicus secondary to, 436
- retroperitoneal, associated with carcinoma of umbilicus, 447
- Carcinomatous cyst of urachus, multilocular, 637
- Cavities, urachal, communicating with bladder or umbilicus or both, 578. See also *Urachal cavities*.
- Chancre, syphilitic, of umbilicus, 283
- Cholesteatoma of umbilicus, 250, 251
- Cicatrix, umbilical, 34, 35, 36, 37
- variations in relationship of peritoneum of umbilicus to, 45
- Cloaca, embryology of, 3
- Coccidia, 269
- Cœlom, embryology of, 22
- Concretions, umbilical, 247-259
- Connective-tissue growths, benign, of umbilicus, 356
- Cord, fibrous, lymphatics of, 66
- umbilical. See *Umbilical cord*.
- Cords, vascular, of umbilicus, disposition of, 48
- Cow, urachal remains in, 524
- Cushion, umbilical, 36
- Cutaneous lymphatics of umbilical region in new-born, 66
- Cyst, abdominal, originating from remnant of omphalomesenteric duct, 185
- atheromatous, of umbilicus, 366
- cases illustrating, 367
- carcinomatous, of urachus, multilocular, 637
- dermoid, of umbilicus, 253, 254, 256, 257, 258, 366
- cases illustrating, 367
- echinococcus, in subumbilical space, 266
- of umbilicus, 344
- esophageal, in new-born, 180
- hydatid, in subumbilical space, 266
- of umbilicus, 344
- in abdominal wall due to remnants of omphalomesenteric duct, 238
- intestinal, 174. See also *Intestinal cysts*.
- of central portion of omphalomesenteric duct, 185
- of Meckel's diverticulum, 179
- of ovary, serous umbilical hernia associated with, 470
- of umbilicus, 478
- Cyst of umbilicus, rare case illustrating, 645
- of urachus, 481, 517, 526, 539
- cases illustrating, 528-538, 547-565
- communicating with bladder or umbilicus or both, 578
- in pig, 525
- infection, abscesses of abdominal wall due to, 567. See also *Abscess of abdominal wall*.
- large, 539
- abscess of appendix and, differentiation, 541, 550
- age incidence, 540
- ascites and, differentiation, 541
- differential diagnosis, 541
- fluid in, 540
- historic sketch, 539
- necrotic lymph in, 540
- neuroma of bladder and, differentiation, 541
- non-infected, cases illustrating, 547
- ovarian cysts and, differentiation, 541
- pain in, 540
- peritonitis and, differentiation, 541
- sex incidence, 540
- size of, 539
- symptoms, 540
- thickened bladder-wall and, differentiation, 541
- treatment of, 546
- small, 526
- cases illustrating, 528-538
- personal observations on, 531
- treatment of, 546
- Wutz's cases, 528
- treatment, 546
- ovarian, extra-abdominal multilocular, 56
- suppurating, piecemeal removal, through umbilicus, 306
- urachal cyst and, differentiation, 541
- suppurating, of urachus, case illustrating, 622
- Cystic dilatations at umbilicus, 144
- Cystic dilatations at umbilicus, 144
- sarcoma of urachus, case illustrating, 635
- DEFECTS of abdominal wall, clinical examples, 56
- Depression, umbilical, bottom of, 36
- elevation, 37
- smooth, 36
- inflammation in, 247
- walls of, 37
- Dermoid cysts of umbilicus, 253, 254, 256, 257, 258, 366
- cases illustrating, 367
- urachal cavities, communicating with bladder or umbilicus or both and, differentiation, 583

- Dickinson's treatment of umbilical cord, 97, 98  
 Dilatation, cystic, at umbilicus, 144  
   of Meckel's diverticulum, intestinal cyst due to, 178  
 Diphtheria of umbilicus, 277  
 Diverticulum, Meckel's, 33, 118, 159. See also *Meckel's diverticulum*.  
   umbilical, 55  
 Duct, omphalomesenteric, cyst of central portion, 185  
   embryology of, 3, 31  
   gastric mucosa in persistent, 144  
   intestinal cysts developing from, 119, 176  
   obliteration of, intestinal cyst from, 33  
   outer portion, persistence of, 155  
     cases illustrating, 156  
   patent, 33, 188, 214. See also *Patent omphalomesenteric duct*.  
   persistence of, intestinal occlusion caused by, 128  
   prolapse of, 194  
   remnants of, 33, 118  
     abdominal cyst, originating from, 185  
     cases illustrating, 131  
     cysts in abdominal wall due to, 238  
     intestinal obstruction due to, 166  
   vitelline. See *Omphalomesenteric duct*.  
 Ducts, Müller's, remnants of, umbilical tumors containing, 373
- ECHINOCOCCUS cyst in subumbilical space, 266  
   of umbilicus, 344  
 Eczema of umbilicus, 276  
 Embryology of allantoid, 1, 16  
   of amnion, 1, 7  
   of body-stalk, 1, 15  
   of cloaca, 3  
   of cælom, 22  
   of exocælom, 3, 4, 6, 22  
   of exocœlomic cavity, 26  
   of omphalomesenteric arteries, 32  
     duct, 3, 31  
     veins, 33  
   of primitive umbilical cord, 28  
   of umbilical arteries, 26  
     cord, 3, 28  
     region, 1  
     veins, 26  
     vesicle, 10, 14  
     vessels, 26  
   of urachus, 17  
   of vitelline duct, 3, 31  
   of yolk-sac, 1, 10  
 Empyema opening into subumbilical space, 265  
 Enlargement of prostate, umbilical urinary fistula associated with, 616  
 Enterocystoma, 174, 239  
   intramesenteric, 180  
 Enteroteratoma of umbilicus, 122, 124, 127  
 Epidemic of erysipelas of abdominal wall in new-born, 74  
   of umbilicus in new-born, 75  
     duration, 77  
     recovery from, 77  
     symptoms, 75  
   of gangrene of umbilicus in new-born, 75, 80  
     diagnosis, 81  
     duration, 77  
     etiology, 81  
     recovery from, 77  
     symptoms, 75, 80  
   of umbilical sepsis in new-born, 95  
 Epigastric glands of Gérota, 66  
 Erysipelas of abdominal wall in new-born, epidemic of, 74  
   of umbilicus complicating umbilical arteritis in new-born, 90, 93  
   in new-born, 92  
   epidemic of, 75  
     duration, 77  
     recovery from, 77  
     symptoms, 75  
   non-puerperal, 84  
 Esophageal cyst in new-born, 180  
 Exocælom, embryology of, 3, 4, 6, 22  
 Exocœlomic cavity, embryology of, 23, 26  
 Exstrophy of bladder, 482  
   case illustrating, 484  
 Extra-abdominal multilocular ovarian cyst, 56  
 Extraperitoneal abdominal tumor, 635  
 Extra-uterine pregnancy, sac opening into bladder in, 583  
 Extroversion of Meckel's diverticulum, 192
- FASCIA, umbilical, anatomy of, 46, 47, 51  
   relations of umbilical vein to, 53  
   varieties of, 51  
 Fatty fringes of umbilical peritoneum, 54  
   tissue in umbilical region, disposition of, 54, 55  
 Fecal concretion discharged at umbilicus, 198  
   fistula at umbilicus, 33, 309. See also *Fistula, fecal, at umbilicus*.  
 Fetal remains, escape of, through umbilicus, 345  
 Fibroma of umbilicus, 357  
   cases illustrating, 358  
 Fibrous cord, lymphatics of, 66  
   ring, varieties of, 47  
 Fistula, 33, 88, 118, 144, 155, 188, 214, 222, 247, 262, 287, 298, 306, 309, 312, 313, 314, 325, 328, 337, 344, 345, 350, 414, 415, 416, 423,

- 459, 468, 470, 481, 487, 491, 523, 569, 578, 607, 608, 609, 610, 611, 612, 613, 616, 620, 622, 625, 629, 649
- Fistula, biliary, at umbilicus, 337, 423  
 escape of foreign bodies from, 350  
 of hydatids, 344  
 of liquor amnii, 345  
 of purulent material, 247, 262, 287, 298, 306, 325, 569, 578  
 of serous fluid, 459, 468, 470  
 of worms, 328
- fecal, at umbilicus, 33, 88, 188, 214, 222, 309, 312, 313, 314, 328, 491  
 development of, in prolapse of intestine through patent omphalomesenteric duct, 222  
 due to burns, 313  
 due to carcinoma of stomach, case illustrating, 418  
 due to external injury, 312  
 due to gangrene, 312  
 due to ulceration of intestine, 310  
 historic sketch, 309  
 tuberculous peritonitis followed by, 314, 317  
 autopsy findings, 316  
 cases illustrating, 317  
 differential diagnosis, 316  
 symptoms, 314  
 treatment, 316
- gastric, 414, 415, 416  
 pseudogastric, 144  
 tuberculous, 649  
 urachal, 481, 487, 491, 523, 578, 607, 608, 609, 610, 611, 612, 613, 616, 622, 625, 629
- Fistulous abscess of umbilicus, 252
- Fitz on treatment of intestinal obstruction due to Meckel's diverticulum, 171
- Flesh umbilicus, 67
- Fluid in urachal cysts, 540  
 secreted by umbilical polyp or fistula, 145  
 action of, on skin surrounding umbilicus, 146  
 serous, escape of, from umbilicus, in case of tuberculous peritonitis, 470
- Foreign bodies, escape of, through umbilicus, 337, 350
- Fox and MacLeod's case of Paget's disease of umbilicus, 268
- Fungus, umbilical, 121, 124
- GALL-BLADDER, carcinoma of, carcinoma of umbilicus secondary to, 422  
 treatment, 425  
 opening at umbilicus, 626
- Gall-stones, escape of, from umbilicus, 337  
 cases illustrating, 339
- Gall-stones, escape of, umbilical changes, 338
- Gangrene, fecal fistula at umbilicus due to, 312  
 of umbilicus, 73  
 in new-born, 87  
 epidemic of, 75, 80  
 diagnosis, 81  
 duration, 77  
 etiology, 81  
 recovery from, 77  
 symptoms, 75, 80  
 prognosis, 88  
 symptoms, 88
- Gastric mucosa at umbilicus, 144. See also *Polyps, umbilical, congenital.*
- Glands, epigastric, of Gérota, 66
- Granuloma of umbilicus, 116  
 treatment, 117  
 umbilical polyp and, differentiation, 124
- Groove, umbilical, 51
- HARDENING of linea alba and umbilicus, case illustrating, 573
- Healing of wound of umbilicus in new-born, mild disturbances in, 86
- Heart, autopsy findings, in umbilical infections in new-born, 72
- Hematoma of abdominal wall near umbilicus, 113
- Hemorrhage, umbilical, 106. See also *Umbilical hemorrhage.*
- Heredity as cause of umbilical hemorrhage, 108
- Hernia, adipose, of umbilicus, 365  
 amniotic, 461  
 into umbilical cord, 459  
 of tip of Meckel's diverticulum, 161  
 through weak spots in abdominal wall, 56, 60, 478  
 umbilical, 459  
 congenital nipping-off of protrusion, 463  
 forms of, 459  
 in adults, 471  
 radical operation for, 474  
 case illustrating, 476  
 treatment, 473  
 in children, 465  
 Nota's operation for, 465  
 in new-born, 465  
 serous, 466  
 associated with large cystic myoma and abdominal ascites, 470  
 with ovarian cyst, 470  
 cases illustrating, 468  
 clinical course, 466  
 small, at birth, 465

- Heurtaux on phlegmonous subumbilical inflammation, 262
- Horn, umbilical, 259
- Horse, remnants of urachus in, 523  
serum in spontaneous umbilical hemorrhage of new born, 110
- Hydatid cyst in subumbilical space, 266  
of umbilicus, 344
- Hypertrophy of prostate, umbilical urinary fistula associated with, 616  
of umbilicus, 352
- ICTERUS, localized, of umbilicus, in presence of free bile in abdominal cavity, 307
- Ileum, volvulus of, strangulation of Meckel's diverticulum caused by, 165
- Ileus due to intussusception of Meckel's diverticulum, 170  
to persistence of omphalomesenteric duct, 167
- Infancy, umbilical hemorrhage after, 112
- Infection as cause of umbilical hemorrhage, 108  
umbilical, in new-born, 70, 93. See also *New-born, umbilical infections in.*  
wound, of umbilicus, in new-born, 85
- Inflammation in umbilical depression, 247  
of umbilical vein in new-born, 92  
vessels in new-born, 88  
of umbilicus in new-born, 87  
subumbilical, 262
- Inflammatory changes in abdominal wall, umbilical concretions associated with, 247. See also *Umbilical concretions.*
- Intestinal cysts, classification, 174  
developing from Meckel's diverticulum, 176, 177  
from omphalomesenteric duct, 119, 176  
due to dilatation of Meckel's diverticulum, 178  
formation from obliteration of omphalomesenteric duct, 33  
in new-born, 180  
lying between layers of mesentery, 180  
relatively free in abdomen, 176  
symptoms, 186  
treatment, 186  
obstruction due to Meckel's diverticulum, 163  
adherent to umbilicus, 165  
treatment, 171  
due to passage of intestine through a hole in mesentery of Meckel's diverticulum, 169  
due to patent omphalomesenteric duct, 195, 201  
due to persistence of omphalomesenteric duct, 128
- Intestinal cysts due to remains of omphalomesenteric duct, 166  
due to remnants of omphalomesenteric vessels, 244  
due to tip of Meckel's diverticulum becoming adherent to a distant point, 168  
in which Meckel's diverticulum was free, case illustrating, 163  
of Meckel's diverticulum, 177
- Intestine, carcinoma of, carcinoma of umbilicus secondary to, 425  
cases illustrating, 426  
inversion of Meckel's diverticulum into, 170  
prolapse of, through patent omphalomesenteric duct, 222. See also *Patent omphalomesenteric duct.*  
strangulation of, by diverticulum ilei, 163, 211  
ulceration of, fecal fistula at umbilicus due to, 310
- Intramesenteric enterocystoma, 180
- Inversion of Meckel's diverticulum into bowel, 170
- Ischuria, a singular case of, 589
- JAUNDICE, localized, of umbilicus, in presence of free bile in abdominal cavity, 307
- Jelly, Wharton's, 35
- Joints, infections of, autopsy findings, in umbilical infections in new-born, 73
- KIDNEYS, autopsy findings, in umbilical infections in new-born, 72
- LEGS, umbilicus, and breasts, apparent escape of urine from, 618
- Ligament, broad, abscess of, opening at umbilicus, 289  
cases illustrating, 291  
treatment, 291
- Linea alba and umbilicus, hardening of, case illustrating, 573  
nigra, 39
- Lipoma of umbilical region, 365
- Liquor amnii, escape of meconium into, through umbilicus, 218  
escape of, through umbilicus, 345
- Liver, abscess of, opening at umbilicus, 297  
into subumbilical space, 265  
autopsy findings, in umbilical infections in new-born, 71
- Lungs, autopsy findings, in umbilical infections in new-born, 71
- Luschka's observations on urachus, 516

- Lymph, necrotic, in urachal cysts, 540
- Lymphatics, cutaneous, of umbilical region in new-born, 66
- of aponeurosis of umbilical ring, 66
  - of fibrous cord, 66
  - of umbilical region, anatomic study, 62-66
- Lymphocle, umbilical, 356
- MAGGOTS in umbilicus, 260
- Malignant changes in urachus, 628
- Mamelon, 35, 36, 37
- Meckel's diverticulum, 33, 118, 159
- accessory pancreas situated at tip of, 162
  - adherent to umbilicus, intestinal obstruction due to, 165
  - cyst of, 179
  - dilatation of, intestinal cyst due to, 178
  - extroversion of, 192
  - hernia of tip of, 161
  - historic sketch, 159
  - in animals, 163
  - intestinal cysts developing from, 176, 177
    - obstruction due to, 163
      - due to tip of, becoming adherent to a distant point, 168
      - due to, treatment, 171
    - inversion of, into bowel, 170
    - length of, 160
    - mesenteric, 162
    - mesentery of, 160
      - hole in, intestinal obstruction due to passage of intestine through, 169
    - omphalomesenteric vessels accompanying, 243
    - strangulation of, caused by volvulus of ileum, 165
    - umbilical polyp associated with, 138
    - volvulus of, 177. See also *Omphalomesenteric* and *Vitelline duct*.
- Meconium, escape of, into liquor amnii through umbilicus, 218
- Melanotic sarcoma of umbilicus, 457
- Mesentery, intestinal cysts lying between layers of, 180
- of Meckel's diverticulum, 160, 162
    - hole in, intestinal obstruction due to passage of intestine through, 169
    - remnants of omphalomesenteric vessels at, 243
- Milligan's case of Paget's disease of umbilicus, 274
- Mucosa, gastric, at umbilicus, 144. See also *Polyps, umbilical, congenital*.
- uterine, umbilical tumors containing, 373
- Müller's ducts, remnants of, umbilical tumors containing, 373
- Multilocular carcinomatous cyst of urachus, 637
- Myxoma of umbilicus, 356
- Myxosarcoma of umbilicus, case illustrating, 427
- telangiectatic, of umbilicus, 449
- NADORY'S treatment of umbilical stump, 101
- Necrotic lymph in urachal cysts, 540
- Nélaton on treatment of intestinal obstruction due to Meckel's diverticulum, 172
- Nerve-supply, sensory, of umbilicus, 66
- Neuroma of bladder, urachal cyst and, differentiation, 541
- New-born, blennorrhœa of umbilicus in, 86
- cutaneous lymphatics of umbilical region, 66
  - diseases of umbilical vessels in, 88
  - erysipelas in, 92
    - of abdominal wall in, epidemic of, 74
  - esophageal cyst in, 180
  - gangrene of umbilicus in, 87
    - prognosis, 88
    - symptoms, 88
  - inflammation of umbilical vein in, 92
    - vessels in, 88
    - of umbilicus in, 87
  - intestinal cyst in, 180
  - omphalitis in, 87
  - septic pyemia of umbilicus in, 93
  - spontaneous hemorrhage from umbilicus, 109
  - tetanus in, from umbilical infection, 95
    - symptoms, 96
  - ulcer of umbilicus in, 87
  - umbilical arteritis in, 89
    - pneumonia complicating, 90,
    - umbilical erysipelas complicating, 90, 93
  - hemorrhage in, instances of, 110-112
  - hernia in, 465
  - infections in, 70, 93
    - autopsy findings, 71
      - brain, 73
      - heart, 72
      - infection of various joints, 73
      - kidneys, 72
      - liver, 71
      - lungs, 71
      - peritoneal cavity, 73
      - terminal infections, 73
      - umbilicus, 71
    - clinical history, 73
  - phlebitis in, 92
    - cases illustrating, 93
  - polyps in, 120
  - sepsis in, epidemic of, 95
  - wound infection of umbilicus in, 85
    - of umbilicus in, mild disturbances in healing of, 86

- Nota's operation for umbilical hernia in children, 465
- OMPHALITIS in new-born, 87
- Omphalomesenteric arteries, embryology of, 32
- artery, persistence of, in bases of umbilical polyps, 244
- duct, cyst of central portion, 185
- embryology of, 3, 31
- intestinal cysts developing from, 119, 176
- obliteration of, intestinal cyst formation from, 33
- outer portion, persistence of, 155
- cases illustrating, 156
- patency of, 33, 188, 214. See also *Patent omphalomesenteric duct*.
- persistence of, intestinal occlusion caused by, 128
- persistent, gastric mucosa in, 144
- prolapse of, 194
- remnants of, 33, 118, 144, 159, 174, 188, 214, 222, 238, 242
- abdominal cyst originating from, 185
- cases illustrating, 131
- cysts in abdominal wall due to, 238
- intestinal obstruction due to, 166
- solid tumor developing from, 178
- veins, embryology of, 33
- vessels, accompanying Meckel's diverticulum, 243
- patent omphalomesenteric duct, 243
- lying perfectly free in abdomen, 244
- persistence of, 242
- historic sketch, 242
- intestinal obstruction due to, 244
- remnants of, 131
- at mesentery, 243. See also *Meckel's diverticulum* and *Vitelline duct*.
- Ovarian cyst, extra-abdominal multilocular, 56
- serous umbilical hernia associated with, 470
- suppurating, piecemeal removal, through umbilicus, 306
- urachal cyst and, differentiation, 541
- Ovary, carcinoma of, carcinoma of umbilicus secondary to, 428
- cases illustrating, 429
- papilloma of, papilloma of umbilicus secondary to, 371
- Paget's disease of umbilicus, Milligan's case, 273
- radium treatment, 274
- Pancreas, accessory, situated at tip of Meckel's diverticulum, 162
- Papilloma of ovary, papilloma of umbilicus secondary to, 371
- of umbilicus, 360
- cases illustrating, 361
- secondary to papilloma of ovary, 371
- Paste, Canquoin's, in epidemic of erysipelas and gangrene of umbilicus in new-born, 75
- Patency of allantois, 16
- Patent omphalomesenteric duct, 33, 118, 188, 214
- age incidence, 188
- and patent urachus in same child, 491
- appearance of umbilicus, 189
- associated with defective development of rectum or anus, 220
- with imperforate sigmoid, 221
- cases illustrating, 191-211
- condition of child, 191
- of skin around fistula, 191
- of umbilical cord, 189
- discharge from fistula, 191
- historic sketch, 188
- intestinal obstruction due to, 195, 201
- omphalomesenteric vessels accompanying, 242
- opening into abdomen and discharging feces into abdominal cavity, 219
- opening of, on side of umbilical cord, 214, 215, 216
- prolapse of intestine through, 218, 222
- age incidence, 222
- autopsy findings, 226
- cases illustrating, 226-236
- development of umbilical fistula, 222
- historic sketch, 222
- results, 226
- treatment, 226
- sex incidence, 188
- treatment, 191
- with fecal matter escaping into liquor amnii, 218
- urachus, congenital, 487. See also *Urachus, patent, congenital*.
- tuberculosis of, 649
- Pearl tumor of umbilicus, 250
- Perforate umbilicus, 201
- Periprostatic abscess opening at umbilicus, 288
- Peritoneal cavity, autopsy findings, in umbilical infections in new-born, 73
- Peritoneum of umbilicus, diverticulum of, 55
- elevation of, in form of a mesentery, 54

PAGET'S DISEASE OF UMBILICUS, 268

Fox and MacLeod's case, 268

- Peritoneum of umbilicus, fatty fringes, 54  
variations in relationship of, to umbilical  
cicatrix, 45
- Peritonitis, tuberculous, escape of serous fluid  
from umbilicus in, 470  
tuberculous, followed by fecal fistula at  
umbilicus, 314. See also *Fistula, fecal, at  
umbilicus*.
- urachal cysts and, differentiation, 541  
with escape of pus at umbilicus, 294, 298  
age incidence, 298  
cases illustrating, 300  
causes, 299  
clinical picture, 298  
complications, 299  
differential diagnosis, 300  
recovery, 299  
symptoms, 298
- Peri-umbilical fossettes, 55  
veins, anatomy of, 50
- Phimosis, congenital, with urinary umbilical  
fistula, 611
- Phlebitis, umbilical, in new-born, 92, 93
- Phegmon, subumbilical, 262
- Pig, cyst of urachus in, 525  
urachal remains in, 524
- Plasmoma, 272
- Pocket, umbilical, 258
- Polyps, umbilical, 118, 120, 144  
associated with Meckel's diverticulum,  
cases illustrating, 125-142, 147  
danger of, 125  
fluid secreted by, 145  
action of, on skin surrounding umbili-  
cus, 146  
macroscopic appearance of umbilical re-  
gion, 145  
microscopic picture, 145  
multiple, 124  
persistence of omphalomesenteric artery  
in bases of, 244  
symptoms of, 122  
treatment of, 124  
umbilical granuloma and, differentiation,  
124
- Pregnancy, extra-uterine, sac opening into blad-  
der in, 583  
umbilicus during, 68
- Preternatural anus found in portion of ileum  
protruded at umbilicus, 217
- Primitive umbilical cord, embryology of, 28
- Prolapse of intestine through patent omphalo-  
mesenteric duct 222. See also *Patent om-  
phalomesenteric duct*.
- Prostate, enlargement of, umbilical urinary fis-  
tula associated with, 616
- Pseudopyloric mucous membrane, 144
- Pubes and umbilicus, tumor between, 481
- Pus, escape of, at umbilicus, peritonitis with,  
298. See also *Peritonitis*.
- Pyemia, septic, of umbilicus, in new-born, 93
- RADICAL operation for umbilical hernia, 474  
case illustrating, 476
- Radium treatment of Paget's disease of um-  
bilicus, 274
- Rectum or anus, defective development of,  
patent omphalomesenteric duct associated  
with, 220
- Remnants of omphalomesenteric duct, 33, 118,  
144, 159, 174, 188, 214, 222, 238, 242  
cysts in abdominal wall due to, 238. See  
also *Meckel's diverticulum*.  
of urachus, 515. See also *Urachus, remnants  
of*.  
of vitelline duct at navel, 129
- Retroperitoneal carcinoma associated with car-  
cinoma of umbilicus, 447  
fluid, escape of, from umbilicus, 287
- Ring, umbilical, aponeurosis of, lymphatics of,  
66  
fibrous, varieties of, 47
- Round umbilicus, 35, 36  
worms, escape of, from umbilicus, 328. See  
also *Worms, round*.
- Round-cell sarcoma of umbilicus, 457
- Runge on wound infection of umbilicus in new-  
born, 85
- SARCOMA, cystic, of urachus, case illustrating,  
635  
of umbilicus, 449  
melanotic, 457  
round-cell, 457  
spindle-cell, 453  
cases reported as, 454  
of urachus, 634
- Scar, umbilical, 34, 35, 36, 37  
variations in relationship of peritoneum of  
umbilicus to, 45
- Sebaceous umbilical tumor, 253
- Sensory nerve-supply of umbilicus, 66
- Sepsis, umbilical, epidemic of, in new-born, 70,  
95
- Septic pyemia of umbilicus in new-born, 93
- Serous fluid, escape of, from umbilicus in case  
of tuberculous peritonitis, 470  
umbilical hernia. 466. See also *Hernia, um-  
bilical, serous*.
- Serum, horse, in spontaneous umbilical hem-  
orrhage of new-born, 110

- Sinus, umbilical, 258  
 Skin, umbilicus, 67  
 Spindle-cell sarcoma of umbilicus, 453  
   cases reported as, 454  
 Squamous-cell carcinoma, primary, of umbilicus, 402  
 Steer, urachal remains in, 524  
 Stomach, carcinoma of, carcinoma of umbilicus  
   secondary to, 412  
   age incidence, 412  
   cases illustrating, 415  
   gastric symptoms, 413  
   prognosis, 415  
   sex incidence, 412  
   trauma incidence, 412  
   treatment, 414  
   umbilical fistula due to, case illustrating,  
   418  
 Stones. See *Calculus* and *Concretions*.  
 Strangulation of intestine by diverticulum ilei,  
 163  
 Stricture of urethra, umbilical urinary fistula  
 following, 611  
 Stump, umbilical, bacteriologic study, 101  
   care of, 101  
 Subumbilical fosses, 55  
   inflammation, 262  
   phlegmon, 262  
   space, abscess in, 262, 265  
     differential diagnosis, 265  
     treatment, 267  
   of appendix opening into, 266  
   actinomycosis in, 266  
   echinococcus cyst in, 266  
   empyema opening into, 265  
   hydatid cyst in, 266  
   liver abscess opening into, 265  
   tuberculous abscess, 256  
   tumor, 259  
 Sweat-glands, umbilical tumors consisting  
 chiefly of, 369  
 Symphysis and umbilicus, tumors between, ura-  
 chal remnant-producing, 526  
 Syphilis as cause of umbilical hemorrhage, 108  
   hæmorrhagica of umbilicus, 108  
   of umbilicus, 278  
   at or shortly after birth, 279,  
   in adult, 283  
 Syphilitic chancre of umbilicus, 283  
  
 TAPEWORMS, escaping from umbilicus, 330  
 Telangiectatic myxosarcoma of umbilicus, 449  
 Tetanus in new-born from umbilical infection,  
   95  
   symptoms, 96  
 Thoracic abscess opening at umbilicus, 288  
 Transverse umbilicus, 35, 36  
 Tube and ovary, suppuration of, with opening  
   at umbilicus, 292  
 Tuberculid, atrophic, of umbilicus, 286  
 Tuberculosis of patent urachus, 649  
   of umbilicus, 250, 285  
   of vas deferens, umbilical fistula due to, 325  
 Tuberculous abscess, subumbilical, 256  
   peritonitis, escape of serous fluid from um-  
   bilicus in, 470  
   followed by fecal fistula at umbilicus, 314.  
   See also *Fistula, fecal*, at *umbilicus*.  
 Tuft, umbilical, 61  
 Tumors, abdominal, attached to inner surface  
   of umbilicus, 370  
   between umbilicus and pubes, 481, 526  
   extraperitoneal abdominal, 635  
   of umbilicus, 120, 351  
   classification, 351  
   consisting chiefly of sweat-glands, 369  
   containing remnants of Müller's ducts, 373  
   uterine mucosa, 373  
   pearl, 250  
   sebaceous, 253  
   vascular, hemorrhage associated with, 113  
   subumbilical, 259, 539, 567  
  
 ULCER of umbilicus in new-born, 87  
 Ulceration of intestine, fecal fistula at umbili-  
 cus due to, 309  
 Umbilical areola, 68  
   arteries, embryology of, 26  
   arteritis, etiology, 91  
   in new-born, 89  
   complications, 90  
   erysipelas of umbilicus complicating, 90,  
   93  
   pathogenesis, 91  
   prognosis, 91  
   prophylaxis, 92  
   symptoms, 91  
   base, 36  
   canal, 47  
   cavity, 37  
   cicatrix, 34, 35, 36, 37  
     variations in relationship of peritoneum of  
     umbilicus to, 45  
   concretions, 247-259  
   cord, condition of, in patent omphalomesen-  
   teric duct, 189  
   embryology of, 3, 9, 16, 28  
   healing of, 86  
   hernia into, 459  
   persistent vitality of, 104  
   primitive embryology of, 28  
   treatment of, 97, 101



- Umbilical cord, treatment of, Buckmaster's method, 100  
 Dickinson's method, 97, 98  
 after-care, 99  
 Nadory's method, 101
- cushion, 36
- depression, bottom of, 36  
 elevation, 37  
 smooth, 36  
 inflammation in, 247  
 walls of, 37
- diverticulum, 55
- fascia, anatomy of, 46, 47, 51  
 defects of, 46, 52  
 relations of umbilical vein to, 53  
 varieties of, 51
- fecal fistula, 33, 118, 309
- fistula, 118  
 following puerperal sepsis, 292  
 congenital, 144. See also *Fistula, umbilical, congenital*.  
 due to carcinoma of stomach, case illustrating, 418  
 due to tuberculosis of vas deferens, 325
- fungus, 121, 124
- groove, 51
- hemorrhage, 106  
 after infancy, 112  
 associated with vascular tumor, 113  
 causes, 108  
 general considerations, 106  
 heredity as cause, 108  
 in new-born, instances of, 110-112  
 infection as cause, 108  
 nature's method of checking, 106, 107  
 spontaneous, in new-born, 109  
 syphilis as cause, 108  
 time of greatest danger, 106  
 treatment, 109
- hernia, 459. See also *Hernia, umbilical*.
- hollow, 36
- horn, 259
- infections in new-born, 70, 93, 95. See also *New-born, umbilical infections in*.  
 autopsy findings in, 71, 77
- mesentery, 54
- opening, removal of vesical stones through, 625
- phlebitis in new-born, 92  
 cases illustrating, 93
- pocket, 258
- polyps, 118, 120, 144
- region, adipose tissue in, disposition of, 54, 55  
 anatomy of, 34  
 appearance of, 34  
 calculi in, cases illustrating, 625  
 embryology of, 1
- Umbilical region, in animals, anatomy of, 62  
 layers of abdominal wall in, 34  
 lipomata of, 365  
 lymphatics of, anatomic study, 62-66  
 cutaneous, in new-born, 66  
 tuberculosis of, 324  
 ring, aponeurosis of, lymphatics of, 66  
 scar, 34, 35, 36, 37  
 variations in relationship of peritoneum of umbilicus to, 45
- sepsis, epidemics of, in new-born, 70
- sinus, 258
- structures, abnormal, 24
- stump, bacteriologic study, 101  
 care of, 101
- tuft, 61
- tumors, 121, 122, 351
- vein, abscess of, in adults, 295  
 embryology of, 26  
 inflammation of, in new-born, 92  
 relations of, to umbilical fascia, 53
- vesicle, embryology of, 10, 14
- vessels, diseases of, in new-born, 27, 88  
 disposition of, 48  
 embryology of, 26  
 inflammation of, in new-born, 88  
 obliteration of, 50
- Umbilicus, abdominal tumor attached to inner surface of, 370  
 abscess of appendix opening at, 296  
 of broad ligament opening at, 289  
 cases illustrating, 291  
 treatment, 291  
 of liver opening at, 297
- absence of, 67
- adenocarcinoma of, primary, 402  
 age incidence, 403  
 report of cases, 404  
 sex incidence, 404  
 treatment, 404
- adenoma of, 124, 125
- adenomyoma of, 373  
 historic sketch, 373  
 report of cases, 375
- adipose hernia of, 365
- amnion*, 8, 67
- amniotic*, 67, 461
- and linea alba, hardening of, case illustrating, 573
- and pubes, tumor between, 481
- and symphysis, tumors between, urachal remnants producing, 526
- angioma of, 352
- appearance of, 34  
 in congenital patent urachus, 488  
 in patent omphalomesenteric duct, 189
- appendix, abscess opening at, 296

- Umbilicus, atheromatous cysts of, 366  
 cases illustrating, 367  
 atrophic tuberculid of, 286  
 biliary fistula at, with escape of gall-stones,  
 cases illustrating, 339  
 blennorrhœa of, in new-born, 86  
 breasts, and other parts of body, apparent  
 escape of urine from, 618  
 calculus at, 257  
 carcinoma of, 400. See also *Carcinoma of  
 umbilicus*.  
 cholesteatoma of, 250  
 complete, 36  
 concretions at, 247  
 connective-tissue growths of, benign, 356  
 constituent elements of, 36  
 cystic dilatations at, 144-155  
 cysts of, 478  
 of urachus communicating with, 578  
 rare, cases illustrating, 645  
 dermoid cysts of, 253, 366  
 cases illustrating, 367  
 description of, 46  
 diphtheria of, 277  
 diseases of, classification of, 351  
 during pregnancy, 68  
 echinococcus cysts of, 344  
 eczema of, 276  
 enteroteratoma of, 122, 124, 127  
 erysipelas of, complicating umbilical arteritis  
 in new-born, 90, 93  
 epidemic of, in new-born, 74  
 duration, 77  
 recovery from, 77  
 symptoms, 75  
 non-puerperal, 84  
 escape of abdominal fluid from, 287  
 of fetal remains through, 345  
 of foreign bodies through, 337, 350  
 of gall-stones from, 337  
 cases illustrating, 339  
 umbilical changes, 338  
 of liquor amnii through, 345  
 of meconium into liquor amnii through, 218  
 of piece of wild-oat straw from, 260  
 of retroperitoneal fluid from, 287  
 of round worms from, 328. See also *Worms,  
 round*.  
 of serous fluid from, in case of tuberculous  
 peritonitis, 470  
 of tapeworms from, 330  
 of urine from, absence of urethra and, 610  
 in congenital patent urachus, 487  
 in urachal cavities, communicating with  
 bladder or umbilicus or both, 578  
 of vesical calculi obstructing urethra as-  
 sociated with, 613
- Umbilicus, escape of vesical calculi obstruct-  
 ing urethra, cases illustrating, 613  
 external injury of, fecal fistula at umbilicus  
 due to, 312  
 fecal concretion discharged at, 198  
 fistula at, 309. See also *Fistula, fecal, at  
 umbilicus*.  
 fibroma of, 357  
 cases illustrating, 358  
 fistula of, due to tuberculosis of vas deferens,  
 325  
*flesh*, 67  
 gangrene of, 73, 87  
 epidemic of, in new-born, 75, 80  
 diagnosis, 81  
 duration, 77  
 etiology, 81  
 recovery from, 77  
 symptoms, 75, 80  
 fecal fistula at umbilicus due to, 312  
 gastric mucosa at, 144. See also *Polyps, um-  
 bilical*.  
 granuloma of, 116  
 treatment, 117  
 umbilical polyp and, differentiation, 124  
 hematoma of abdominal wall near, 113  
 histologic appearance, 39  
 horn of, 259  
 hydatid cysts of, 344  
 hypertrophy of, 352  
 in animals, anatomy of, 61  
 in urachal cavities, communicating with blad-  
 der or umbilicus or both, 578  
 infection of, in new-born, 87, 93  
 jaundice of, 307  
 lipoma of, 365  
 lymphocele of, 356  
 maggots in, 260  
 Meckel's diverticulum adherent to, intestinal  
 obstruction caused by, 165  
 melanotic sarcoma of, 457  
 myxoma of, 356  
 myxosarcoma of, case illustrating, 427  
 telangiectatic, 449  
 outside of, relation of, to peritoneal side, 60  
 Paget's disease of, 268  
 Fox and MacLeod's case, 268  
 Milligan's case, 273  
 radium treatment, 274  
 papilloma of, 360  
 cases illustrating, 361  
 secondary to papilloma of ovary, 371  
 pearl tumor of, 250  
 perforate, 201  
 periprostatic abscess opening at, 288  
 peritoneum of, diverticulum of, 55  
 elevation, in form of a mesentery, 45

- Umbilicus, peritoneum of, fatty fringes, 54  
 variations in relationship of, to umbilical  
 cicatrix, 45  
 peritonitis with escape of pus at, 298. See  
 also *Peritonitis*.  
 piecemeal removal of suppurating ovarian  
 cyst through, 306  
 polyps of, 118, 120, 144. See also *Polyps*,  
*umbilical*.  
 relation of outside of, to peritoneal side, 60  
 remnants of vitelline duct. See *Polyps* and  
*Omphalomesenteric duct*.  
 round, 35, 36  
 round-cell sarcoma of, 457  
 sarcoma of, 449. See also *Sarcoma of um-*  
*bilicus*.  
 sensory nerve-supply of, 66  
 septic pyemia of, in new-born, 93  
*skin*, 67  
 spindle-cell sarcoma of, 453  
 cases reported as, 454  
 syphilis of, 278  
 at or shortly after birth, 279  
 in adults, 283  
 syphilitic chancre of, 283  
 thoracic abscess opening at, 288  
*transverse*, 35, 36  
 tuberculid of, atrophic, 286  
 tuberculosis of, 250, 285  
 tumors of, 120, 247, 351  
 classification, 351  
 consisting chiefly of sweat-glands, 369  
 containing remnants of Müller's ducts, 373  
 uterine mucosa, 373  
 sebaceous, 253  
 typical, of Catteau, 35  
 ulcer of, in new-born, 87  
 urachal cavities, communicating with, 578.  
 See also *Urachal cavities*.  
 urinary fistula at. See *Fistula, urachal*.  
 varieties of fibrous ring, 47  
 various forms of, 35, 37, 47  
 vascular cords, disposition of, 48  
 tumor of, hemorrhage associated with, 113  
*vertical*, 35, 36  
 worms escaping from, 328  
 wound infection of, in new-born, 85
- Urachal cavities, communicating with bladder  
 or umbilicus or both, 578  
 age incidence, 578  
 bladder symptoms, 579  
 cases illustrating, 585-605  
 differential diagnosis, 583  
 discharge of urine from umbilicus in,  
 581  
 pain in, 580  
 sex incidence, 578
- Urachal cavities, communicating with bladder,  
 symptoms, 578, 582  
 treatment, 584  
 umbilicus in, 581  
 concretions, 482, 620, 621  
 fistula in animals, 523  
 remains, 515
- Urachus, 481  
 bleeding from, into bladder, 647  
 calculi of, 482, 620, 621, 622  
 associated with urachal remains, 620, 621  
 carcinoma of, 628  
 age incidence, 628  
 developing years after closure of congenital  
 patent urachus, 629  
 sex incidence, 628  
 carcinomatous cyst of, multilocular, 637  
 contents of, 518  
 cystic sarcoma of, case illustrating, 635  
 cysts of, 481, 517, 539, 578  
 cases illustrating, 547-565  
 communicating with bladder or umbilicus  
 or both, 578  
 in pig, 525  
 infection of, abscesses of abdominal wall  
 due to, 567. See also *Abscess of ab-*  
*dominal wall*.  
 large, 539  
 abscess of appendix and, differentiation,  
 541, 550  
 age incidence, 540  
 differential diagnosis, 541  
 fluid in, 540  
 historic sketch, 539  
 necrotic lymph in, 540  
 neuroma of bladder and, differentiation,  
 541  
 non-infected, cases illustrating, 547  
 ovarian cysts and, differentiation, 541  
 pain in, 540  
 peritonitis and, differentiation, 541  
 sex incidence, 540  
 size of, 539  
 symptoms, 540  
 thickened bladder-wall and, differentia-  
 tion, 541  
 treatment, 546  
 multilocular carcinomatous, 637  
 small, 526  
 cases illustrating, 528-538  
 treatment, 546  
 Wutz's cases, 528  
 suppurating, case illustrating, 622  
 treatment, 546  
 diseases of, 481  
 embryology of, 16 (allantois)  
 fistula, urinary. See *Fistula, urachal*.

- Urachus, Luschka's observations on, 516  
 malignant changes in, 628  
 multilocular carcinomatous cyst of, 637  
 patent, congenital, 487  
   and patent omphalomesenteric duct in same child, 491  
   appearance of umbilicus in, 488  
   cases illustrating, 495-512  
   escape of urine from umbilicus in, 487  
   general condition of child, 490  
   irritation around umbilicus, 489  
   race incidence, 490  
   sex incidence, 489  
   size of umbilical opening, 489  
   symptoms of, 487  
   treatment of, 490  
 tuberculosis of, 649  
 remnants of, 515  
   historic sketch, 515  
   in animals, 523  
   infection of, abscesses of abdominal wall due to, 567. See also *Abscess of abdominal wall*.  
   Luschka's observations on, 516  
   producing tumors between umbilicus and symphysis, 526  
   urachal concretions associated with, 620  
   urinary calculi associated with, 620, 622  
   Wutz's observations on, 519  
 sarcoma of, 634  
   cystic, case illustrating, 635
- Urethra, absence of, escape of urine from umbilicus and, 610  
 blocking of, causes, 610  
   umbilical urinary fistula following, 609  
 stricture of, umbilical urinary fistula following, 611  
 vesical calculi obstructing, associated with escape of urine from umbilicus, 613  
   cases illustrating, 613
- Urinary calculi associated with urachal remains, 620, 622  
 fistula at umbilicus, 487, 607. See also *Fistula, urachal*.  
   associated with enlarged prostate, 616  
   with growth in bladder, 612  
   congenital phimosis with, 611  
   following blocking of urethra, 609  
   following stricture of urethra, 611  
   when no urethral obstruction exists, 608  
   with absence of urethra, 610
- Urine, escape of, apparent, from umbilicus, breasts, and other parts of body, 618  
 from umbilicus, absence of urethra and, 610  
 in congenital patent urachus, 487
- Urine, from umbilicus, in urachal cavities, communicating with bladder or umbilicus or both, 581  
 vesical calculi obstructing urethra associated with, 613  
 cases illustrating, 613
- Uterine mucosa, umbilical tumors containing, 373
- Uterus, carcinoma of, carcinoma of umbilicus secondary to, 436
- VALVE, Wutz's, 521
- Vas deferens, tuberculosis of, umbilical fistula due to, 325
- Vascular cords of umbilicus, disposition of, 48
- Vein, umbilical, abscess of, in adult, 295  
 inflammation of, in new-born, 92  
 relations of, to umbilical fascia, 53
- Veins, omphalomesenteric, embryology of, 33  
 peri-umbilical, anatomy of, 50  
 umbilical, embryology of, 26
- Vermiform appendix, abscess of, opening into subumbilical space, 266  
 opening of, at umbilicus, 296  
 urachal cyst and, differentiation, 541, 550
- Vertical umbilicus, 35, 36
- Vesical. See *Bladder*.
- Vesicle, umbilical, embryology of, 10, 14
- Vitelline duct, embryology of, 3, 31. See also *Omphalomesenteric duct*.
- Volvulus of ileum, strangulation of Meckel's diverticulum caused by, 165
- WHARTON'S jelly, 35
- Wild oat straw, escape of piece of, from umbilicus, 260
- Worms, escape of, from umbilicus, 328, 330  
 cause of fistula, 329  
 historic sketch, 328  
 report of cases, 331  
 symptoms, 329  
 treatment, 330
- Wound infection of umbilicus in new-born, 85
- Wutz's cases of small urachal cysts, 528  
 observations on urachus, 519  
 valve, 521
- YOLK-SAC, embryology of, 1, 10
- ZINC chlorid in epidemic of erysipelas and gangrene of umbilicus in new-born, 75





RC941  
C89  
1916

Cullen  
Umbilicus and disease.

